

World Journal of *Clinical Cases*

World J Clin Cases 2022 July 6; 10(19): 6341-6758



Contents

Thrice Monthly Volume 10 Number 19 July 6, 2022

MINIREVIEWS

- 6341** Review of clinical characteristics, immune responses and regulatory mechanisms of hepatitis E-associated liver failure
Chen C, Zhang SY, Chen L
- 6349** Current guidelines for *Helicobacter pylori* treatment in East Asia 2022: Differences among China, Japan, and South Korea
Cho JH, Jin SY
- 6360** Review of epidermal growth factor receptor-tyrosine kinase inhibitors administration to non-small-cell lung cancer patients undergoing hemodialysis
Lan CC, Hsieh PC, Huang CY, Yang MC, Su WL, Wu CW, Wu YK

ORIGINAL ARTICLE

Case Control Study

- 6370** Pregnancy-related psychopathology: A comparison between pre-COVID-19 and COVID-19-related social restriction periods
Chieffo D, Avallone C, Serio A, Kotzalidis GD, Balocchi M, De Luca I, Hirsch D, Gonzalez del Castillo A, Lanzotti P, Marano G, Rinaldi L, Lanzone A, Mercuri E, Mazza M, Sani G
- 6385** Intestinal mucosal barrier in functional constipation: Dose it change?
Wang JK, Wei W, Zhao DY, Wang HF, Zhang YL, Lei JP, Yao SK

Retrospective Cohort Study

- 6399** Identification of risk factors for surgical site infection after type II and type III tibial pilon fracture surgery
Hu H, Zhang J, Xie XG, Dai YK, Huang X

Retrospective Study

- 6406** Total knee arthroplasty in Ranawat II valgus deformity with enlarged femoral valgus cut angle: A new technique to achieve balanced gap
Lv SJ, Wang XJ, Huang JF, Mao Q, He BJ, Tong PJ
- 6417** Preliminary evidence in treatment of eosinophilic gastroenteritis in children: A case series
Chen Y, Sun M
- 6428** Self-made wire loop snare successfully treats gastric persimmon stone under endoscopy
Xu W, Liu XB, Li SB, Deng WP, Tong Q
- 6437** Neoadjuvant transcatheter arterial chemoembolization and systemic chemotherapy for the treatment of undifferentiated embryonal sarcoma of the liver in children
He M, Cai JB, Lai C, Mao JQ, Xiong JN, Guan ZH, Li LJ, Shu Q, Ying MD, Wang JH

- 6446** Effect of cold snare polypectomy for small colorectal polyps

Meng QQ, Rao M, Gao PJ

- 6456** Field evaluation of COVID-19 rapid antigen test: Are rapid antigen tests less reliable among the elderly?

Tabain I, Cucevic D, Skreb N, Mrzljak A, Ferencak I, Hruskar Z, Misic A, Kuzle J, Skoda AM, Jankovic H, Vilibic-Cavlek T

Observational Study

- 6464** Tracheobronchial intubation using flexible bronchoscopy in children with Pierre Robin sequence: Nursing considerations for complications

Ye YL, Zhang CF, Xu LZ, Fan HF, Peng JZ, Lu G, Hu XY

- 6472** Family relationship of nurses in COVID-19 pandemic: A qualitative study

Çelik MY, Kiliç M

META-ANALYSIS

- 6483** Diagnostic accuracy of ≥ 16 -slice spiral computed tomography for local staging of colon cancer: A systematic review and meta-analysis

Liu D, Sun LM, Liang JH, Song L, Liu XP

CASE REPORT

- 6496** Delayed-onset endophthalmitis associated with *Achromobacter* species developed in acute form several months after cataract surgery: Three case reports

Kim TH, Lee SJ, Nam KY

- 6501** Sustained dialysis with misplaced peritoneal dialysis catheter outside peritoneum: A case report

Shen QQ, Behera TR, Chen LL, Attia D, Han F

- 6507** Arteriovenous thrombotic events in a patient with advanced lung cancer following bevacizumab plus chemotherapy: A case report

Kong Y, Xu XC, Hong L

- 6514** Endoscopic ultrasound radiofrequency ablation of pancreatic insulinoma in elderly patients: Three case reports

Rossi G, Petrone MC, Capurso G, Partelli S, Falconi M, Arcidiacono PG

- 6520** Acute choroidal involvement in lupus nephritis: A case report and review of literature

Yao Y, Wang HX, Liu LW, Ding YL, Sheng JE, Deng XH, Liu B

- 6529** Triple A syndrome-related achalasia treated by per-oral endoscopic myotomy: Three case reports

Liu FC, Feng YL, Yang AM, Guo T

- 6536** Choroidal thickening with serous retinal detachment in BRAF/MEK inhibitor-induced uveitis: A case report

Kiraly P, Groznik AL, Valentinčič NV, Mekjavić PJ, Urbančič M, Ocvirk J, Mesti T

- 6543** Esophageal granular cell tumor: A case report

Chen YL, Zhou J, Yu HL

- 6548** Hem-o-lok clip migration to the common bile duct after laparoscopic common bile duct exploration: A case report
Liu DR, Wu JH, Shi JT, Zhu HB, Li C
- 6555** Chidamide and sintilimab combination in diffuse large B-cell lymphoma progressing after chimeric antigen receptor T therapy
Hao YY, Chen PP, Yuan XG, Zhao AQ, Liang Y, Liu H, Qian WB
- 6563** Relapsing polychondritis with isolated tracheobronchial involvement complicated with Sjogren's syndrome: A case report
Chen JY, Li XY, Zong C
- 6571** Acute methanol poisoning with bilateral diffuse cerebral hemorrhage: A case report
Li J, Feng ZJ, Liu L, Ma YJ
- 6580** Immunoabsorption therapy for Klinefelter syndrome with antiphospholipid syndrome in a patient: A case report
Song Y, Xiao YZ, Wang C, Du R
- 6587** Roxadustat for treatment of anemia in a cancer patient with end-stage renal disease: A case report
Zhou QQ, Li J, Liu B, Wang CL
- 6595** Imaging-based diagnosis for extraskeletal Ewing sarcoma in pediatrics: A case report
Chen ZH, Guo HQ, Chen JJ, Zhang Y, Zhao L
- 6602** Unusual course of congenital complete heart block in an adult: A case report
Su LN, Wu MY, Cui YX, Lee CY, Song JX, Chen H
- 6609** Penile metastasis from rectal carcinoma: A case report
Sun JJ, Zhang SY, Tian JJ, Jin BY
- 6617** Isolated cryptococcal osteomyelitis of the ulna in an immunocompetent patient: A case report
Ma JL, Liao L, Wan T, Yang FC
- 6626** Magnetic resonance imaging features of intrahepatic extramedullary hematopoiesis: Three case reports
Luo M, Chen JW, Xie CM
- 6636** Giant retroperitoneal liposarcoma treated with radical conservative surgery: A case report and review of literature
Lieto E, Cardella F, Erario S, Del Sorbo G, Reginelli A, Galizia G, Urraro F, Panarese I, Auricchio A
- 6647** Transplanted kidney loss during colorectal cancer chemotherapy: A case report
Pośpiech M, Kolonko A, Nieszporek T, Kozak S, Kozaczka A, Karkoszka H, Winder M, Chudek J
- 6656** Massive gastrointestinal bleeding after endoscopic rubber band ligation of internal hemorrhoids: A case report
Jiang YD, Liu Y, Wu JD, Li GP, Liu J, Hou XH, Song J

- 6664** Mills' syndrome is a unique entity of upper motor neuron disease with N-shaped progression: Three case reports
Zhang ZY, Ouyang ZY, Zhao GH, Fang JJ
- 6672** Entire process of electrocardiogram recording of Wellens syndrome: A case report
Tang N, Li YH, Kang L, Li R, Chu QM
- 6679** Retroperitoneal tumor finally diagnosed as a bronchogenic cyst: A case report and review of literature
Gong YY, Qian X, Liang B, Jiang MD, Liu J, Tao X, Luo J, Liu HJ, Feng YG
- 6688** Successful treatment of Morbihan disease with total glucosides of paeony: A case report
Zhou LF, Lu R
- 6695** Ant sting-induced whole-body pustules in an inebriated male: A case report
Chen SQ, Yang T, Lan LF, Chen XM, Huang DB, Zeng ZL, Ye XY, Wan CL, Li LN
- 6702** Plastic surgery for giant metastatic endometrioid adenocarcinoma in the abdominal wall: A case report and review of literature
Wang JY, Wang ZQ, Liang SC, Li GX, Shi JL, Wang JL
- 6710** Delayed-release oral mesalamine tablet mimicking a small jejunal gastrointestinal stromal tumor: A case report
Frosio F, Rausa E, Marra P, Boutron-Ruault MC, Lucianetti A
- 6716** Concurrent alcoholic cirrhosis and malignant peritoneal mesothelioma in a patient: A case report
Liu L, Zhu XY, Zong WJ, Chu CL, Zhu JY, Shen XJ
- 6722** Two smoking-related lesions in the same pulmonary lobe of squamous cell carcinoma and pulmonary Langerhans cell histiocytosis: A case report
Gencer A, Ozcibik G, Karakas FG, Sarbay I, Batur S, Borekci S, Turna A
- 6728** Proprotein convertase subtilisin/kexin type 9 inhibitor non responses in an adult with a history of coronary revascularization: A case report
Yang L, Xiao YY, Shao L, Ouyang CS, Hu Y, Li B, Lei LF, Wang H
- 6736** Multimodal imaging study of lipemia retinalis with diabetic retinopathy: A case report
Zhang SJ, Yan ZY, Yuan LF, Wang YH, Wang LF
- 6744** Primary squamous cell carcinoma of the liver: A case report
Kang LM, Yu DP, Zheng Y, Zhou YH
- 6750** Tumor-to-tumor metastasis of clear cell renal cell carcinoma to contralateral synchronous pheochromocytoma: A case report
Wen HY, Hou J, Zeng H, Zhou Q, Chen N

ABOUT COVER

Editorial Board Member of *World Journal of Clinical Cases*, Abdulqadir Jeprel Naswhan, MSc, RN, Director, Research Scientist, Senior Lecturer, Senior Researcher, Nursing for Education and Practice Development, Hamad Medical Corporation, Doha 576214, Qatar. anashwan@hamad.qa

AIMS AND SCOPE

The primary aim of *World Journal of Clinical Cases* (WJCC, *World J Clin Cases*) is to provide scholars and readers from various fields of clinical medicine with a platform to publish high-quality clinical research articles and communicate their research findings online.

WJCC mainly publishes articles reporting research results and findings obtained in the field of clinical medicine and covering a wide range of topics, including case control studies, retrospective cohort studies, retrospective studies, clinical trials studies, observational studies, prospective studies, randomized controlled trials, randomized clinical trials, systematic reviews, meta-analysis, and case reports.

INDEXING/ABSTRACTING

The WJCC is now indexed in Science Citation Index Expanded (also known as SciSearch®), Journal Citation Reports/Science Edition, Scopus, PubMed, and PubMed Central. The 2021 Edition of Journal Citation Reports® cites the 2020 impact factor (IF) for WJCC as 1.337; IF without journal self cites: 1.301; 5-year IF: 1.742; Journal Citation Indicator: 0.33; Ranking: 119 among 169 journals in medicine, general and internal; and Quartile category: Q3. The WJCC's CiteScore for 2020 is 0.8 and Scopus CiteScore rank 2020: General Medicine is 493/793.

RESPONSIBLE EDITORS FOR THIS ISSUE

Production Editor: Xu Guo; Production Department Director: Xiang Li; Editorial Office Director: Jin-Lai Wang.

NAME OF JOURNAL

World Journal of Clinical Cases

ISSN

ISSN 2307-8960 (online)

LAUNCH DATE

April 16, 2013

FREQUENCY

Thrice Monthly

EDITORS-IN-CHIEF

Bao-Gan Peng, Jerzy Tadeusz Chudek, George Kontogeorgos, Maurizio Serati, Ja Hyeon Ku

EDITORIAL BOARD MEMBERS

<https://www.wjgnet.com/2307-8960/editorialboard.htm>

PUBLICATION DATE

July 6, 2022

COPYRIGHT

© 2022 Baishideng Publishing Group Inc

INSTRUCTIONS TO AUTHORS

<https://www.wjgnet.com/bpg/gerinfo/204>

GUIDELINES FOR ETHICS DOCUMENTS

<https://www.wjgnet.com/bpg/GerInfo/287>

GUIDELINES FOR NON-NATIVE SPEAKERS OF ENGLISH

<https://www.wjgnet.com/bpg/gerinfo/240>

PUBLICATION ETHICS

<https://www.wjgnet.com/bpg/GerInfo/288>

PUBLICATION MISCONDUCT

<https://www.wjgnet.com/bpg/gerinfo/208>

ARTICLE PROCESSING CHARGE

<https://www.wjgnet.com/bpg/gerinfo/242>

STEPS FOR SUBMITTING MANUSCRIPTS

<https://www.wjgnet.com/bpg/GerInfo/239>

ONLINE SUBMISSION

<https://www.f6publishing.com>



Proprotein convertase subtilisin/kexin type 9 inhibitor non responses in an adult with a history of coronary revascularization: A case report

Liu Yang, Yan-Yan Xiao, Liang Shao, Chang-Sheng Ouyang, Yao Hu, Bin Li, Li-Feng Lei, Hong Wang

Specialty type: Medicine, research and experimental

Provenance and peer review:

Unsolicited article; Externally peer reviewed.

Peer-review model: Single blind

Peer-review report's scientific quality classification

Grade A (Excellent): 0
Grade B (Very good): 0
Grade C (Good): C
Grade D (Fair): D, D
Grade E (Poor): 0

P-Reviewer: Papadopoulos VP, Greece; Pradhan A, India

Received: February 12, 2022

Peer-review started: February 12, 2022

First decision: March 25, 2022

Revised: April 7, 2022

Accepted: April 30, 2022

Article in press: April 30, 2022

Published online: July 6, 2022



Liu Yang, Liang Shao, Chang-Sheng Ouyang, Yao Hu, Bin Li, Hong Wang, Department of Cardiology, Jiangxi Provincial People's Hospital, The First Affiliated Hospital of Nanchang Medical College, Nanchang 330006, Jiangxi Province, China

Yan-Yan Xiao, Postgraduate School of Jiangxi University of Traditional Chinese Medicine, Jiangxi University of Traditional Chinese Medicine, Nanchang 330008, Jiangxi Province, China

Li-Feng Lei, Department of Internal Medicine, Tonggu People's Hospital, Yichun 336299, Jiangxi Province, China

Corresponding author: Hong Wang, MD, Chief Physician, Department of Cardiology, Jiangxi Provincial People's Hospital, The First Affiliated Hospital of Nanchang Medical College, No. 152 Aiguo Road, Donghu District, Nanchang 330006, Jiangxi Province, China.
hongwangjx@21cn.com

Abstract

BACKGROUND

Familial hypercholesterolemia (FH) is an autosomal dominant disorder that is characterized by severely increased low-density lipoprotein (LDL) cholesterol levels. At the same time, elevated LDL levels accelerated the development of coronary heart disease. Several classes of drugs are currently in use to treat FH. Proprotein convertase subtilisin/kexin type 9 inhibitor (PCSK9i) is novel one of these.

CASE SUMMARY

This manuscript reports a case of FH that responded modestly after treatment with PCSK9i and statin drugs. Of even more concern is that the patient frequently admitted to the hospital during a 12-year follow-up period. Subsequently, we identified a heterozygous mutation, 1448G>A (W483X) of the LDL receptor (LDLR) in this patient. The serum levels of PCSK9 (proprotein convertase subtilisin/kexin type 9) in the patient was 71.30 ± 26.66 ng/mL, which is close the average level reported in the literature. This LDLR mutation affects LDLR metabolism or structure, which may make it unsuitable for use of PCSK9i.

CONCLUSION

Our outcome demonstrates that LDLR-W483X represents a partial loss-of-function

LDLR and may contribute to PCSK9i ineffective. In the meanwhile, additional measures are therefore required (particularly with gene sequencing or change the treatment plan) must be initiated as early as possible. Genetic testing for clinically challenging cases who do not respond to PCSK9i therapy is very helpful.

Key Words: Coronary artery disease; Familial hypercholesterolemia; Low-density lipoprotein receptor mutation; Non response; Proprotein convertase subtilisin/kexin type 9 inhibitor

©The Author(s) 2022. Published by Baishideng Publishing Group Inc. All rights reserved.

Core Tip: We report a male Chinese patient diagnosed with Familial hypercholesterolemia with a heterozygous mutation, 1448G>A (W483X), of the low-density lipoprotein receptor (LDLR). By reviewing the literature, we speculate that the mutation may affect LDLR metabolism or structure and may lead to that responded modestly after treatment with Proprotein convertase subtilisin/kexin type 9 inhibitor.

Citation: Yang L, Xiao YY, Shao L, Ouyang CS, Hu Y, Li B, Lei LF, Wang H. Proprotein convertase subtilisin/kexin type 9 inhibitor non responses in an adult with a history of coronary revascularization: A case report. *World J Clin Cases* 2022; 10(19): 6728-6735

URL: <https://www.wjgnet.com/2307-8960/full/v10/i19/6728.htm>

DOI: <https://dx.doi.org/10.12998/wjcc.v10.i19.6728>

INTRODUCTION

Coronary heart disease (CHD) is a major cause of hospitalization and mortality worldwide[1]. And elevated low-density lipoprotein (LDL) levels accelerated this process[2]. Here, we reported a patient diagnosed with familial hypercholesterolemia (FH) experienced seven percutaneous coronary interventions. It is no exaggeration to say that the patient is at a higher risk for cardiovascular events all the time. In previous reports, common causes of repeated coronary interventions are as follows: (1) Patients who do not consistently take the medicine or have missed doses; (2) Patients with clopidogrel resistance[3]; (3) Patients do not respond to hyperglycemia and hyperlipidemia drug therapy or nonattainment; and (4) Other reasons. Of these, FH is one of the most common causes of myocardial infarction[4]. The epidemiology of FH is complicated, and it is difficult to estimate the prevalence of FH in China because of underdiagnosed. Based on a population study in Arabian Gulf, the prevalence of heterozygous FH is approximately one in 300 individuals[5]. This patient had poor lipid control (Even though Proprotein convertase subtilisin/kexin type 9 inhibitor (PCSK9i) was used), which resulted in repeated coronary interventions. The purpose of this case report is to recommend lifestyle intervention and intensive lipid-lowering treatment beginning early in life to reduce the risk of coronary heart disease. This case is significant because it demonstrates the necessity of gene sequencing or switching medications.

CASE PRESENTATION

Chief complaints

A 43-year-old Chinese man came to our department with chest tightness for more than 4 d.

History of present illness

Chest tightness is located behind the sternum lasts about 2-3 min. And no other symptoms such as abdominal distension, abdominal pain, cold, and fever. According to the patient's Medical Record files, he had no known medication allergies.

History of past illness

On August 4, 2009, Due to frequent chest tightness, coronary angiography was performed on the patient. The coronary angiogram revealed severe vascular calcification and stenosis in the proximal and middle left anterior descending coronary artery, the middle segment of the right coronary artery and circumflex coronary arteries. Ultimately, he chose conservative treatment.

Subsequently, he presented to our hospital on September 17, 2009, with a complaint of chest tightness for more than 3 d. After angiography, the results showed stenosis in the left anterior descending artery

(60%-70%), the circumflex coronary arteries (80%-90%) and a total occlusion of the mid-right coronary artery. We implanted four stents (rapamycin-eluting stents, Lepu medical) into the stenotic segment at that time. Three months later, the patient came to the hospital again due to chest pain. Coronary angiography showed stenosis in the proximal (95%) and middle (60%) left anterior descending artery, and proximal mid-right coronary artery (60%). There was no in-stent restenosis of drug-eluting stents. At that time, two stents were implanted (proximal and middle left anterior descending coronary artery).

Four years later, the patient returned to our hospital for further treatment. During this hospital admission, angiography reveals results as follows: The stenosis in the proximal left anterior descending artery (85%), mid circumflex coronary arteries (70%) and a proximal of the right coronary artery (95%). However, there was no in-stent stenosis.

On August 25, 2013, he was admitted to our department with palpitation for 5 d. The results revealed there were no in-stent stenosis; the stenosis in the proximal-mid circumflex coronary arteries (70%) and distal portion of the right coronary artery (40%). At that time, no specific treatment was administered.

According to hospital data, the patient was admitted on December 29, 2015; July 27, 2019; and June 2021, respectively. All lesions were treated by Paclitaxel-coated balloon (2019-SeQuent Please NEO®, B. Braun; 2021-Vesselin®, Lepu medical).

Personal and family history

His mother and sister were also hospitalized with a diagnosis of FH. His mother had a history of sequelae of cerebral infarction for several years. In this case, we investigated the family diagnosed with FH (Figure 1). The proband was II-1 (the patient), who's average serum LDL was 222.76 mg/dL (5.77 mmol/L). A total of 3 members of this family (I-1, II-1, II-2) were diagnosed as FH.

Physical examination

Who weighed 72 kg and was 170 cm tall, with no changes in cardiopulmonary auscultation. All other associated signs: The varying sizes of the yellow nodules scattered throughout both upper limbs elbow joints and wrist joints. A soft mass, 45.5 mm in diameter, was palpable at the knee joints of both lower extremities. No other abnormality was found on physical examination.

Laboratory examinations

The major laboratory results of the patient are listed as follows: TG 94.8 mg/dL (1.07 mmol/L), TC 382.3 mg/dL (9.89 mmol/L), HDL 37.5mg/dL (0.97 mmol/L), LDL 289.6mg/dL (7.49 mmol/L) (Results at the first examination). Lipid profile in this patient (2009-2021) is presented in Figure 2. The lowest LDL value (grey solid line) is 141.10 mg/dL (3.65 mmol/L) (August, 2009) with the highest value 402.4 mg/dL (July 2009). The average value (222.76 mg/dL) is substandard. The results of routine blood tests (complete blood count, liver and renal function) were normal.

Imaging examinations

Chest X-ray was normal. Electrocardiogram showed sinus rhythm with a heart rate of 95 bpm, as well as incomplete left bundle branch block. Carotid ultrasound demonstrated atherosclerosis plaques bilaterally in carotid artery. LV ejection fraction was 55% with regional wall motion abnormality. B-mode ultrasound showed gallbladder stone with no notable abnormalities of the liver, pancreas or spleen.

FINAL DIAGNOSIS

This is a rare case that was diagnosed as definitive FH with coronary heart disease, according to the Dutch clinical lipid network (Family history-1; Clinical history-2; Physical examination-6; Investigation-5; Total 14-Definite FH>8). Criteria for the diagnosis of coronary artery disease: defined as 50% or more stenosis in one or more major epicardial vessels[6].

TREATMENT

The physicians made recommendations, and more detailed planning (coronary artery bypass surgery) and implementation were carried out in collaboration with the patient. However, the patient refused this treatment. It was too expensive for him. The patient had received aspirin 100 mg QD, clopidogrel 75 mg QD (clopidogrel resistance have been excluded) and simvastatin 20mg QN before the admission to our hospital. After admission to our hospital, we strengthened treatment. For that, bisoprolol 2.5 mg, once a day, benazepril hydrochloride tablets 5 mg QD were prescribed. On the third admission, treatment with tirofiban 0.1µg/ (kg·min) was added. In 2013, atorvastatin was increased from 20 mg QN to 40 mg QN and ezetimibe (10 mg, once daily), while clopidogrel 75 mg QD was changed to ticagrelor 90 mg BID. The patient did not reach the standard after 10 years of statin therapy. According to AHA

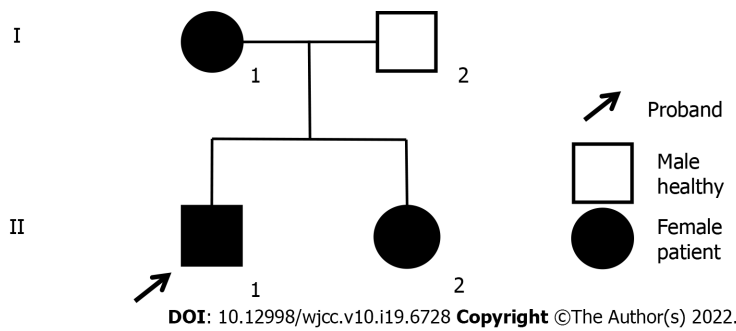


Figure 1 Pedigree analysis of family. Pedigree of family with three affected individuals: mother (I-1), daughter (II-2) and son (II-1). Circles represent females, while squares indicate males. Black shapes indicate affected individuals.

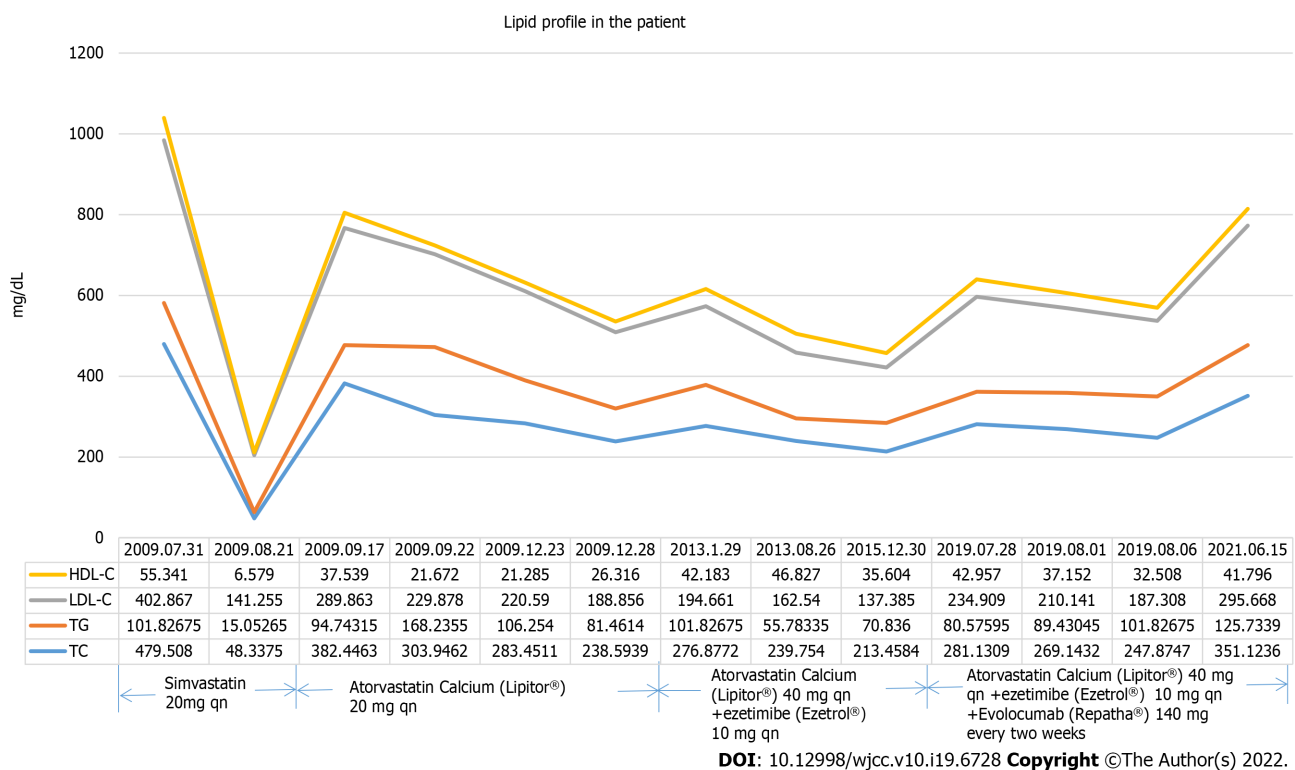


Figure 2 Lipid profile of this patient (2009-2021). Values are presented as mg/dL. HDL: High-density lipoprotein cholesterol; LDL: Low-density lipoprotein cholesterol; TG: Triglyceride; TC: Total cholesterol.

guidelines, PCSK9i (140mg, twice a month, Evolocumab Injection®, Amgen Manufacturing Limited.), as a new drug, was added for the treatment (since September, 2019)[7]. The patient was put on it for 6 months. During the follow-up period of 6 mo, proper technique for injection was confirmed. However, the effectiveness was unsatisfactory.

He said “I took my medication correctly”. The patient managed conservatively with a low-fat dietary. The LDL level gradually decreased from the month (July 2019) after using PCSK9i. The value declined approximately by 41.69% when compared to the highest values, whereas it hadn’t reached the standard [8]. We also realize that future experiments may be necessary to further treatment. The patient and his mother were informed and gave their informed consent. Blood samples were drawn from the patient and his mother. A mutational analysis was performed in the present case to detect mutations in the serum sample.

By means of high-throughput sequencing technology, two LDLR mutations and one APOB mutation were identified in the patient and his mother. There were two LDLR heterozygous mutations: (1) C.1448G>A (p.W483X); and (2) C.10700C>T (p.T3567M). The mutations described above were verified by verification of pedigree. Possible causative gene is c.1448G>A (p.W483X) according to the results (Figure 3).

Due to the mechanism of action of PCSK9i, meanwhile, we had to understand whether increased PCSK9 Level plays pivotal role during the process[9]. In this review, an algorithm to assess possible

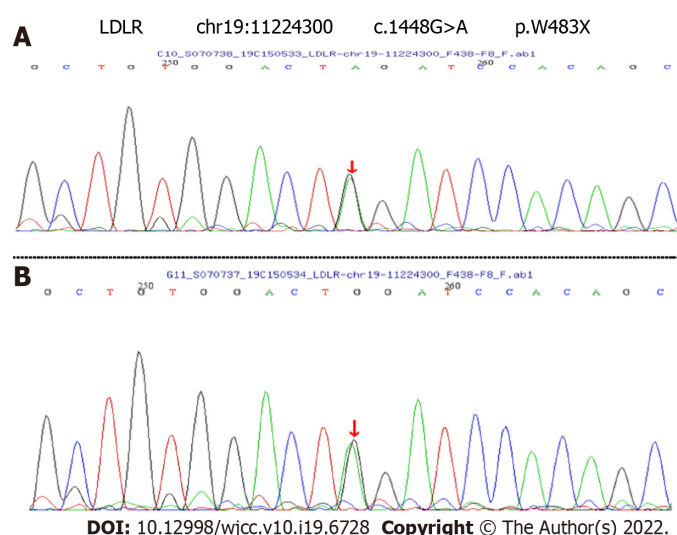


Figure 3 Results for genomic DNA analyses of the patient and his mother. A: DNA sequence of a LDLR, showing the heterozygous mutation 1448G>A (p.W483X) in the affected individual (II-1); B: DNA sequence of individual (I-1). LDLR: Low-density lipoprotein cholesterol receptor.

PCSK9i resistance has been proposed to classify hypo-responders and identify mechanism by Warden *et al*[9]. The algorithm was based on measuring plasma PCSK9 concentrations before and after treatment with a PCSK9i. In our case-report, the average serum level (the patient) of PCSK9 was 71.30 ± 26.66 ng/mL (prior to treatment). They are close the average reported in the literature (68.29 ± 28.73) ng/mL [10]. The difference was not statistically significant ($P > 0.05$). However, the patient was not well educated and he was not patient enough to complete all the measurements. So, plasma PCSK9 concentrations (after treatment) cannot be obtained.

OUTCOME AND FOLLOW-UP

Our patient is still alive now. The patient did not complain of chest tightness. The use of PCSK9i therapy was terminated due to the ineffectiveness. Further therapy (such as LDL apheresis) was discussed with the patient; however, due to the risk of complications and financial constraints, this was not started.

DISCUSSION

There is no doubt that there are indications for the use of PCSK9i among FH patients [11,12]. In previous studies, most FH patients presented with higher LDL levels. Even if three classes of lipid-lowering drugs (statin, ezetimibe and PCSK9i) are used, it is still very difficult to achieve treatment goal for LDL-C. However, few of the studies reported ineffectiveness of the drug (PCSK9i)[13]. The patient's average LDL value during his hospitalization was 222.763 mg/dL, that greatly exceed requirement 69.5mg/dL (the control goal)[14]. During the patient's hospitalization, his serum LDL level decreased by approximately 15.92% compared to baseline values. Undoubtedly, LDL level control was not achieved.

Due to the mechanism of action of PCSK9i, then, we had to understand whether increased PCSK9 Level or loss-of-function mutations in LDLR plays pivotal role during the process. Once before, scholars reported on that statin have been shown to increase serum PCSK9 Level among FH patients[15]. Moreover, elevated PCSK9 Levels were an independent predictor for adverse cardiovascular outcomes in diabetic patients with stable CHD[16,17]. Based on this, the PCSK9 Level in patient who still taking statins was measured (his sister and parents declined participation). The average serum levels of PCSK9 are close the average reported in the literature [10]. That suggesting that there are some other reasons for the ineffective of using PCSK9i.

Subsequent genetic testing was performed (Figure 3). Both the patient and his mother had a heterozygous pathogenic mutation in the LDLR gene (1448G>A, W483X). The mutation was determined to be pathogenic according to the ACMG guidelines. Nonsense mutations in LDLR may result in loss of gene functions. The site of the mutation had been reported[18,19]. The heterozygosity of the loci was investigated in his mother with pedigree-based and genomic analyses. We also note that one APOB mutation was identified in the patient and his mother. However, the LDL level in FH who caused by APOB gene mutations are significantly lower than the others. We think that mutation was not crucial for the patient's phenotype. Jiang L *et al*[18] concluded that either LDLR binding or internalization activity of

W483X was lower than the wild-type in transfected HEK-293 cells. Bioinformatics prediction and an *in vitro* function experiment showed that the W483X mutation is mainly retained in the ER and had serious functional defects caused by the truncated mutant protein. Therefore, we can speculate that the LDLR mutation induces lower LDLR mRNA levels in FH patients than in controls. Structural defects of the LDLR or LDLR level limit the efficacy of the drug because lacks internalization of LDL. This may explain the ineffective use of the PCSK9i in the patient. Delia Susan-Resiga.etc identified an FH patient presenting novel compound heterozygote mutations R410S and G592E of the LDL receptor (LDLR)[20]. The patient responded modestly to maximum rosuvastatin plus ezetimibe therapy, even in combination with a PCSK9i monoclonal antibody injection. The study demonstrates that LDLR-R410S of the LDL-R resulting in defective delivery of LDL to lysosomes, which is similar to that which we report here. Warden *et al*[9] also focus on several cases about unusual responses to PCSK9 inhibitors[21]. The authors explain why something can a fully blocked PCSK9 not exert an effect on plasma LDL-C levels. One of these reasons (mutations in LDL receptors or its ligands ApoB or ApoE that render them less susceptible to PCSK9 inhibition) was similar to our case report. In contrast, not all mutations are related to the ineffective of PCSK9i. Biochemical and cellular functional analyses suggest that some functional mutations such as D374Y result in a 10-to-25-fold increase in PCSK9 affinity for LDLR[22]. PCSK9i may be a very effective drug for these patients. In clinical treatment, however, this hypothesis remains unproved.

CONCLUSION

In any case, for patients with FH, the LDL level should be controlled and treated with early and timely diagnosis. If the outcome is poor, gene analysis should be performed in a timely manner. Based on this case, we strongly recommend that screening and treatment in young FH patients as early as possible. The mutation (W483X) may affect LDLR structure and lead to that responded modestly after treatment with PCSK9 inhibitor (PCSK9i). We are also looking forward to additional novel classes of lipid-lowering drugs

ACKNOWLEDGEMENTS

The authors would like to acknowledge the patients and their family members for taking part in this study.

FOOTNOTES

Author contributions: Shao L and Li B collected all the data; Xiao YY and Ouyang CS recorded the video; Hu Y, Lei LF and Xiao YY performed the literature review; Yang L wrote the manuscript; Wang H reviewed and revised the manuscript; all authors issued final approval for the version to be submitted and provided critical comments in the revision of the article.

Supported by the Doctor Start-up fund of Jiangxi provincial People's Hospital, The First Affiliated Hospital of Nanchang Medical College, No. 19-236.

Informed consent statement: Written informed consent for publication was obtained from the whole family.

Conflict-of-interest statement: The authors declare that they have no conflict of interest.

CARE Checklist (2016) statement: The authors have read the CARE Checklist (2016). The manuscript was prepared and revised according to the CARE Checklist (2016).

Open-Access: This article is an open-access article that was selected by an in-house editor and fully peer-reviewed by external reviewers. It is distributed in accordance with the Creative Commons Attribution NonCommercial (CC BY-NC 4.0) license, which permits others to distribute, remix, adapt, build upon this work non-commercially, and license their derivative works on different terms, provided the original work is properly cited and the use is non-commercial. See: <https://creativecommons.org/licenses/by-nc/4.0/>

Country/Territory of origin: China

ORCID number: Liu Yang 0000-0002-4272-7473; Yan-Yan Xiao 0000-0002-3659-1223; Liang Shao 0000-0003-2676-3332; Chang-Sheng Ouyang 0000-0002-0232-5576; Yao Hu 0000-0003-3173-8844; Bin Li 0000-0003-2987-9787; Li-Feng Lei 0000-0002-7601-2476; Hong Wang 0000-0003-1505-4469.

Corresponding Author's Membership in Professional Societies: Chinese Society of Cardiology.

S-Editor: Wang LL

L-Editor: A

P-Editor: Wang LL

REFERENCES

- 1 **Tuppo EE**, Trivedi MP, Kostis JB, Daevmer J, Cabrera J, Kostis WJ; Myocardial Infarction Data Acquisition System (MIDAS 39) Study Group. The role of public health vs invasive coronary interventions in the decline of coronary heart disease mortality. *Ann Epidemiol* 2021; **55**: 91-97 [PMID: [33152465](#) DOI: [10.1016/j.annepidem.2020.10.005](#)]
- 2 **Grundt SM**, Vega GL, Kesäniemi YA. Abnormalities in metabolism of low density lipoproteins associated with coronary heart disease. *Acta Med Scand Suppl* 1985; **701**: 23-37 [PMID: [3907293](#) DOI: [10.1111/j.0954-6820.1985.tb08887.x](#)]
- 3 **Lee K**, Lee SW, Lee JW, Kim SY, Youn YJ, Ahn MS, Kim JY, Yoo BS, Yoon J, Choe KH. The significance of clopidogrel low-responsiveness on stent thrombosis and cardiac death assessed by the verifynow p(2)y(12) assay in patients with acute coronary syndrome within 6 mo after drug-eluting stent implantation. *Korean Circ J* 2009; **39**: 512-518 [PMID: [20049136](#) DOI: [10.4070/kcj.2009.39.12.512](#)]
- 4 **Li S**, Zhang HW, Guo YL, Wu NQ, Zhu CG, Zhao X, Sun D, Gao XY, Gao Y, Zhang Y, Qing P, Li XL, Sun J, Liu G, Dong Q, Xu RX, Cui CJ, Li JJ. Familial hypercholesterolemia in very young myocardial infarction. *Sci Rep* 2018; **8**: 8861 [PMID: [29892007](#) DOI: [10.1038/s41598-018-27248-w](#)]
- 5 **Al-Rasadi K**, Al-Zakwani I, Alsheikh-Ali AA, Almahmeed W, Rashed W, Ridha M, Santos RD, Zubaid M. Prevalence, management, and outcomes of familial hypercholesterolemia in patients with acute coronary syndromes in the Arabian Gulf. *J Clin Lipidol* 2018; **12**: 685-692.e2 [PMID: [29574074](#) DOI: [10.1016/j.jacl.2018.02.003](#)]
- 6 **Chang SM**, Hakeem A, Nagueh SF. Predicting clinically unrecognized coronary artery disease: use of two-dimensional echocardiography. *Cardiovasc Ultrasound* 2009; **7**: 10 [PMID: [19267918](#) DOI: [10.1186/1476-7120-7-10](#)]
- 7 **Gidding SS**, Champagne MA, de Ferranti SD, Defesche J, Ito MK, Knowles JW, McCrindle B, Raal F, Rader D, Santos RD, Lopes-Virella M, Watts GF, Wierzbicki AS; American Heart Association Atherosclerosis, Hypertension, and Obesity in Young Committee of Council on Cardiovascular Disease in Young, Council on Cardiovascular and Stroke Nursing, Council on Functional Genomics and Translational Biology, and Council on Lifestyle and Cardiometabolic Health. The Agenda for Familial Hypercholesterolemia: A Scientific Statement From the American Heart Association. *Circulation* 2015; **132**: 2167-2192 [PMID: [26510694](#) DOI: [10.1161/CIR.0000000000000297](#)]
- 8 **Visseren FLJ**, Mach F, Smulders YM, Carballo D, Koskinas KC, Bäck M, Benetos A, Biffi A, Boavida JM, Capodanno D, Cosyns B, Crawford C, Davos CH, Desormais I, Di Angelantonio E, Franco OH, Halvorsen S, Hobbs FDR, Hollander M, Jankowska EA, Michal M, Sacco S, Sattar N, Tokgozoglu L, Tonstad S, Tsioufis KP, van Dis I, van Gelder IC, Wanner C, Williams B; ESC Scientific Document Group. 2021 ESC Guidelines on cardiovascular disease prevention in clinical practice. *Eur J Prev Cardiol* 2022; **29**: 5-115 [PMID: [34558602](#) DOI: [10.1093/eurjpc/zwab154](#)]
- 9 **Warden BA**, Fazio S, Shapiro MD. The PCSK9 revolution: Current status, controversies, and future directions. *Trends Cardiovasc Med* 2020; **30**: 179-185 [PMID: [31151804](#) DOI: [10.1016/j.tcm.2019.05.007](#)]
- 10 **Cui Q**, Ju X, Yang T, Zhang M, Tang W, Chen Q, Hu Y, Haas JV, Troutt JS, Pickard RT, Darling R, Konrad RJ, Zhou H, Cao G. Serum PCSK9 is associated with multiple metabolic factors in a large Han Chinese population. *Atherosclerosis* 2010; **213**: 632-636 [PMID: [21040917](#) DOI: [10.1016/j.atherosclerosis.2010.09.027](#)]
- 11 **Landmesser U**, Chapman MJ, Farnier M, Gencer B, Gielen S, Hovingh GK, Lüscher TF, Sinning D, Tokgozoglu L, Wiklund O, Zamorano JL, Pinto FJ, Catapano AL; European Society of Cardiology (ESC); European Atherosclerosis Society (EAS). European Society of Cardiology/European Atherosclerosis Society Task Force consensus statement on proprotein convertase subtilisin/kexin type 9 inhibitors: practical guidance for use in patients at very high cardiovascular risk. *Eur Heart J* 2017; **38**: 2245-2255 [PMID: [27789571](#) DOI: [10.1093/eurheartj/ehw480](#)]
- 12 **Langslet G**, Emery M, Wasserman SM. Evolocumab (AMG 145) for primary hypercholesterolemia. *Expert Rev Cardiovasc Ther* 2015; **13**: 477-488 [PMID: [25824308](#) DOI: [10.1586/14779072.2015.1030395](#)]
- 13 **Rallidis LS**, Liberopoulos EN, Vlachopoulos C, Skoumas I, Kolovou G, Anastasiou G, Dima I, Tousoulis D, Iliodromitis E. Very high-risk familial hypercholesterolaemia patients in real life: The remaining gap in achieving the current LDL-C targets despite the use of PCSK9 inhibitors. *Atherosclerosis* 2020; **309**: 67-69 [PMID: [32859385](#) DOI: [10.1016/j.atherosclerosis.2020.07.018](#)]
- 14 **Díaz Rodríguez Á**; Grupo de Trabajo de Lípidos de SEMERGEN. [Guidelines for the management of dyslipidemia]. *Semergen* 2014; **40** Suppl 4: 19-25 [PMID: [25595349](#) DOI: [10.1016/S1138-3593\(14\)74393-X](#)]
- 15 **Careskey HE**, Davis RA, Alborn WE, Troutt JS, Cao G, Konrad RJ. Atorvastatin increases human serum levels of proprotein convertase subtilisin/kexin type 9. *J Lipid Res* 2008; **49**: 394-398 [PMID: [18033751](#) DOI: [10.1194/jlr.M700437-JLR200](#)]
- 16 **Peng J**, Liu MM, Jin JL, Cao YX, Guo YL, Wu NQ, Zhu CG, Dong Q, Sun J, Xu RX, Li JJ. Association of circulating PCSK9 concentration with cardiovascular metabolic markers and outcomes in stable coronary artery disease patients with or without diabetes: a prospective, observational cohort study. *Cardiovasc Diabetol* 2020; **19**: 167 [PMID: [33023603](#) DOI: [10.1186/s12933-020-01142-0](#)]
- 17 **Li S**, Zhang Y, Xu RX, Guo YL, Zhu CG, Wu NQ, Qing P, Liu G, Dong Q, Li JJ. Proprotein convertase subtilisin-kexin type 9 as a biomarker for the severity of coronary artery disease. *Ann Med* 2015; **47**: 386-393 [PMID: [26153823](#) DOI: [10.3109/07853890.2015.1042908](#)]
- 18 **Jiang L**, Sun LY, Pan XD, Chen PP, Tang L, Wang W, Zhao LM, Yang SW, Wang LY. Characterization of the unique Chinese W483X mutation in the low-density lipoprotein-receptor gene in young patients with homozygous familial

- hypercholesterolemia. *J Clin Lipidol* 2016; **10**: 538-546.e5 [PMID: 27206941 DOI: 10.1016/j.jacl.2015.12.016]
- 19 **Jiang L**, Sun LY, Dai YF, Yang SW, Zhang F, Wang LY. The distribution and characteristics of LDL receptor mutations in China: A systematic review. *Sci Rep* 2015; **5**: 17272 [PMID: 26608663 DOI: 10.1038/srep17272]
- 20 **Susan-Resiga D**, Girard E, Kiss RS, Essalmani R, Hamelin J, Asselin MC, Awan Z, Butkinaree C, Fleury A, Soldara A, Dory YL, Baass A, Seidah NG. The Proprotein Convertase Subtilisin/Kexin Type 9-resistant R410S Low Density Lipoprotein Receptor Mutation: A NOVEL MECHANISM CAUSING FAMILIAL HYPERCHOLESTEROLEMIA. *J Biol Chem* 2017; **292**: 1573-1590 [PMID: 27998977 DOI: 10.1074/jbc.M116.769430]
- 21 **Warden BA**, Miles JR, Oleaga C, Ganda OP, Duell PB, Purnell JQ, Shapiro MD, Fazio S. Unusual responses to PCSK9 inhibitors in a clinical cohort utilizing a structured follow-up protocol. *Am J Prev Cardiol* 2020; **1**: 100012 [PMID: 34327453 DOI: 10.1016/j.ajpc.2020.100012]
- 22 **Cunningham D**, Danley DE, Geoghegan KF, Griffor MC, Hawkins JL, Subashi TA, Varghese AH, Ammirati MJ, Culp JS, Hoth LR, Mansour MN, McGrath KM, Seddon AP, Shenolikar S, Stutzman-Engwall KJ, Warren LC, Xia D, Qiu X. Structural and biophysical studies of PCSK9 and its mutants linked to familial hypercholesterolemia. *Nat Struct Mol Biol* 2007; **14**: 413-419 [PMID: 17435765 DOI: 10.1038/nsmb1235]



Published by **Baishideng Publishing Group Inc**
7041 Koll Center Parkway, Suite 160, Pleasanton, CA 94566, USA

Telephone: +1-925-3991568

E-mail: bpgoffice@wjgnet.com

Help Desk: <https://www.f6publishing.com/helpdesk>

<https://www.wjgnet.com>

