

# World Journal of *Clinical Cases*

*World J Clin Cases* 2022 June 6; 10(16): 5124-5517



## Contents

Thrice Monthly Volume 10 Number 16 June 6, 2022

### OPINION REVIEW

- 5124** Malignant insulinoma: Can we predict the long-term outcomes?  
*Cigrovski Berkovic M, Ulamec M, Marinovic S, Balen I, Mrzljak A*

### MINIREVIEWS

- 5133** Practical points that gastrointestinal fellows should know in management of COVID-19  
*Sahin T, Simsek C, Balaban HY*
- 5146** Nanotechnology in diagnosis and therapy of gastrointestinal cancer  
*Liang M, Li LD, Li L, Li S*
- 5156** Advances in the clinical application of oxycodone in the perioperative period  
*Chen HY, Wang ZN, Zhang WY, Zhu T*

### ORIGINAL ARTICLE

#### Clinical and Translational Research

- 5165** Circulating miR-627-5p and miR-199a-5p are promising diagnostic biomarkers of colorectal neoplasia  
*Zhao DY, Zhou L, Yin TF, Zhou YC, Zhou GYJ, Wang QQ, Yao SK*

#### Retrospective Cohort Study

- 5185** Management and outcome of bronchial trauma due to blunt *versus* penetrating injuries  
*Gao JM, Li H, Du DY, Yang J, Kong LW, Wang JB, He P, Wei GB*

#### Retrospective Study

- 5196** Ovarian teratoma related anti-N-methyl-D-aspartate receptor encephalitis: A case series and review of the literature  
*Li SJ, Yu MH, Cheng J, Bai WX, Di W*
- 5208** Endoscopic surgery for intraventricular hemorrhage: A comparative study and single center surgical experience  
*Wang FB, Yuan XW, Li JX, Zhang M, Xiang ZH*
- 5217** Protective effects of female reproductive factors on gastric signet-ring cell carcinoma  
*Li Y, Zhong YX, Xu Q, Tian YT*
- 5230** Risk factors of mortality and severe disability in the patients with cerebrovascular diseases treated with perioperative mechanical ventilation  
*Zhang JZ, Chen H, Wang X, Xu K*

- 5241** Awareness of initiative practice for health in the Chinese population: A questionnaire survey based on a network platform

*Zhang YQ, Zhou MY, Jiang MY, Zhang XY, Wang X, Wang BG*

- 5253** Effectiveness and safety of chemotherapy for patients with malignant gastrointestinal obstruction: A Japanese population-based cohort study

*Fujisawa G, Niikura R, Kawahara T, Honda T, Hasatani K, Yoshida N, Nishida T, Sumiyoshi T, Kiyotoki S, Ikeya T, Arai M, Hayakawa Y, Kawai T, Fujishiro M*

### Observational Study

- 5266** Long-term outcomes of high-risk percutaneous coronary interventions under extracorporeal membrane oxygenation support: An observational study

*Huang YX, Xu ZM, Zhao L, Cao Y, Chen Y, Qiu YG, Liu YM, Zhang PY, He JC, Li TC*

- 5275** Health care worker occupational experiences during the COVID-19 outbreak: A cross-sectional study

*Li XF, Zhou XL, Zhao SX, Li YM, Pan SQ*

### Prospective Study

- 5287** Enhanced recovery after surgery strategy to shorten perioperative fasting in children undergoing non-gastrointestinal surgery: A prospective study

*Ying Y, Xu HZ, Han ML*

- 5297** Orthodontic treatment combined with 3D printing guide plate implant restoration for edentulism and its influence on mastication and phonic function

*Yan LB, Zhou YC, Wang Y, Li LX*

### Randomized Controlled Trial

- 5306** Effectiveness of psychosocial intervention for internalizing behavior problems among children of parents with alcohol dependence: Randomized controlled trial

*Omkarappa DB, Rentala S, Nattala P*

### CASE REPORT

- 5317** Crouzon syndrome in a fraternal twin: A case report and review of the literature

*Li XJ, Su JM, Ye XW*

- 5324** Laparoscopic duodenojejunostomy for malignant stenosis as a part of multimodal therapy: A case report

*Murakami T, Matsui Y*

- 5331** Chordoma of petrosal mastoid region: A case report

*Hua JJ, Ying ML, Chen ZW, Huang C, Zheng CS, Wang YJ*

- 5337** Pneumatosis intestinalis after systemic chemotherapy for colorectal cancer: A case report

*Liu H, Hsieh CT, Sun JM*

- 5343** Mammary-type myofibroblastoma with infarction and atypical mitosis-a potential diagnostic pitfall: A case report

*Zeng YF, Dai YZ, Chen M*

- 5352** Comprehensive treatment for primary right renal diffuse large B-cell lymphoma with a renal vein tumor thrombus: A case report  
*He J, Mu Y, Che BW, Liu M, Zhang WJ, Xu SH, Tang KF*
- 5359** Ectopic peritoneal paragonimiasis mimicking tuberculous peritonitis: A case report  
*Choi JW, Lee CM, Kim SJ, Hah SI, Kwak JY, Cho HC, Ha CY, Jung WT, Lee OJ*
- 5365** Neonatal hemorrhage stroke and severe coagulopathy in a late preterm infant after receiving umbilical cord milking: A case report  
*Lu Y, Zhang ZQ*
- 5373** Heel pain caused by os subcalcis: A case report  
*Saijilafu, Li SY, Yu X, Li ZQ, Yang G, Lv JH, Chen GX, Xu RJ*
- 5380** Pulmonary lymphomatoid granulomatosis in a 4-year-old girl: A case report  
*Yao JW, Qiu L, Liang P, Liu HM, Chen LN*
- 5387** Idiopathic membranous nephropathy in children: A case report  
*Cui KH, Zhang H, Tao YH*
- 5394** Successful treatment of aortic dissection with pulmonary embolism: A case report  
*Chen XG, Shi SY, Ye YY, Wang H, Yao WF, Hu L*
- 5400** Renal papillary necrosis with urinary tract obstruction: A case report  
*Pan HH, Luo YJ, Zhu QG, Ye LF*
- 5406** Glomangiomas - immunohistochemical study: A case report  
*Wu RC, Gao YH, Sun WW, Zhang XY, Zhang SP*
- 5414** Successful living donor liver transplantation with a graft-to-recipient weight ratio of 0.41 without portal flow modulation: A case report  
*Kim SH*
- 5420** Treatment of gastric hepatoid adenocarcinoma with pembrolizumab and bevacizumab combination chemotherapy: A case report  
*Liu M, Luo C, Xie ZZ, Li X*
- 5428** Ipsilateral synchronous papillary and clear renal cell carcinoma: A case report and review of literature  
*Yin J, Zheng M*
- 5435** Laparoscopic radical resection for situs inversus totalis with colonic splenic flexure carcinoma: A case report  
*Zheng ZL, Zhang SR, Sun H, Tang MC, Shang JK*
- 5441** PIGN mutation multiple congenital anomalies-hypotonia-seizures syndrome 1: A case report  
*Hou F, Shan S, Jin H*

- 5446** Pediatric acute myeloid leukemia patients with i(17)(q10) mimicking acute promyelocytic leukemia: Two case reports  
*Yan HX, Zhang WH, Wen JQ, Liu YH, Zhang BJ, Ji AD*
- 5456** Fatal left atrial air embolism as a complication of percutaneous transthoracic lung biopsy: A case report  
*Li YW, Chen C, Xu Y, Weng QP, Qian SX*
- 5463** Diagnostic value of bone marrow cell morphology in visceral leishmaniasis-associated hemophagocytic syndrome: Two case reports  
*Shi SL, Zhao H, Zhou BJ, Ma MB, Li XJ, Xu J, Jiang HC*
- 5470** Rare case of hepatocellular carcinoma metastasis to urinary bladder: A case report  
*Kim Y, Kim YS, Yoo JJ, Kim SG, Chin S, Moon A*
- 5479** Osteotomy combined with the trephine technique for invisible implant fracture: A case report  
*Chen LW, Wang M, Xia HB, Chen D*
- 5487** Clinical diagnosis, treatment, and medical identification of specific pulmonary infection in naval pilots: Four case reports  
*Zeng J, Zhao GL, Yi JC, Liu DD, Jiang YQ, Lu X, Liu YB, Xue F, Dong J*
- 5495** Congenital tuberculosis with tuberculous meningitis and situs inversus totalis: A case report  
*Lin H, Teng S, Wang Z, Liu QY*
- 5502** Mixed large and small cell neuroendocrine carcinoma of the stomach: A case report and review of literature  
*Li ZF, Lu HZ, Chen YT, Bai XF, Wang TB, Fei H, Zhao DB*

**LETTER TO THE EDITOR**

- 5510** Pleural involvement in cryptococcal infection  
*Georgakopoulou VE, Damaskos C, Sklapani P, Trakas N, Gkoufa A*
- 5515** Electroconvulsive therapy plays an irreplaceable role in treatment of major depressive disorder  
*Ma ML, He LP*

**ABOUT COVER**

Editorial Board Member of *World Journal of Clinical Cases*, Shivanshu Misra, MBBS, MCh, MS, Assistant Professor, Surgeon, Department of Minimal Access and Bariatric Surgery, Shivani Hospital and IVF, Kanpur 208005, Uttar Pradesh, India. shivanshu\_medico@rediffmail.com

**AIMS AND SCOPE**

The primary aim of *World Journal of Clinical Cases* (WJCC, *World J Clin Cases*) is to provide scholars and readers from various fields of clinical medicine with a platform to publish high-quality clinical research articles and communicate their research findings online.

WJCC mainly publishes articles reporting research results and findings obtained in the field of clinical medicine and covering a wide range of topics, including case control studies, retrospective cohort studies, retrospective studies, clinical trials studies, observational studies, prospective studies, randomized controlled trials, randomized clinical trials, systematic reviews, meta-analysis, and case reports.

**INDEXING/ABSTRACTING**

The WJCC is now indexed in Science Citation Index Expanded (also known as SciSearch®), Journal Citation Reports/Science Edition, Scopus, PubMed, and PubMed Central. The 2021 Edition of Journal Citation Reports® cites the 2020 impact factor (IF) for WJCC as 1.337; IF without journal self cites: 1.301; 5-year IF: 1.742; Journal Citation Indicator: 0.33; Ranking: 119 among 169 journals in medicine, general and internal; and Quartile category: Q3. The WJCC's CiteScore for 2020 is 0.8 and Scopus CiteScore rank 2020: General Medicine is 493/793.

**RESPONSIBLE EDITORS FOR THIS ISSUE**

Production Editor: Xu Guo; Production Department Director: Xiang Li; Editorial Office Director: Jin-Lei Wang.

**NAME OF JOURNAL**

*World Journal of Clinical Cases*

**ISSN**

ISSN 2307-8960 (online)

**LAUNCH DATE**

April 16, 2013

**FREQUENCY**

Thrice Monthly

**EDITORS-IN-CHIEF**

Bao-Gan Peng, Jerzy Tadeusz Chudek, George Kontogeorgos, Maurizio Serati, Ja Hyeon Ku

**EDITORIAL BOARD MEMBERS**

<https://www.wjgnet.com/2307-8960/editorialboard.htm>

**PUBLICATION DATE**

June 6, 2022

**COPYRIGHT**

© 2022 Baishideng Publishing Group Inc

**INSTRUCTIONS TO AUTHORS**

<https://www.wjgnet.com/bpg/gerinfo/204>

**GUIDELINES FOR ETHICS DOCUMENTS**

<https://www.wjgnet.com/bpg/GerInfo/287>

**GUIDELINES FOR NON-NATIVE SPEAKERS OF ENGLISH**

<https://www.wjgnet.com/bpg/gerinfo/240>

**PUBLICATION ETHICS**

<https://www.wjgnet.com/bpg/GerInfo/288>

**PUBLICATION MISCONDUCT**

<https://www.wjgnet.com/bpg/gerinfo/208>

**ARTICLE PROCESSING CHARGE**

<https://www.wjgnet.com/bpg/gerinfo/242>

**STEPS FOR SUBMITTING MANUSCRIPTS**

<https://www.wjgnet.com/bpg/GerInfo/239>

**ONLINE SUBMISSION**

<https://www.f6publishing.com>



Prospective Study

# Orthodontic treatment combined with 3D printing guide plate implant restoration for edentulism and its influence on mastication and phonic function

Li-Bo Yan, Yu-Chao Zhou, Yang Wang, Li-Xin Li

**Specialty type:** Dentistry, Oral Surgery and Medicine

**Provenance and peer review:** Unsolicited article; Externally peer reviewed.

**Peer-review model:** Single blind

**Peer-review report's scientific quality classification**

Grade A (Excellent): 0  
Grade B (Very good): B  
Grade C (Good): C  
Grade D (Fair): 0  
Grade E (Poor): 0

**P-Reviewer:** Hung SI, Taiwan;  
Palacios S, Spain

**Received:** February 21, 2022

**Peer-review started:** February 21, 2022

**First decision:** March 23, 2022

**Revised:** April 20, 2022

**Accepted:** May 13, 2022

**Article in press:** May 13, 2022

**Published online:** June 6, 2022



**Li-Bo Yan, Yu-Chao Zhou, Yang Wang,** The Outpatient Department, Lintong Rehabilitation and Convalescent Center, Xi'an 710000, Shaanxi Province, China

**Li-Xin Li,** Department of Administration, Lintong Rehabilitation and Convalescent Center, Xi'an 710000, Shaanxi Province, China

**Corresponding author:** Li-Xin Li, BM, Physician, Department of Administration, Lintong Rehabilitation and Convalescent Center, No. 32 Huaqing Road, Lintong District, Xi'an 710000, Shaanxi Province, China. [lilixinlxlx58@163.com](mailto:lilixinlxlx58@163.com)

## Abstract

### BACKGROUND

Dentition defect, a common clinical oral disease developed in humans, not only causes masticatory dysfunction and articulation difficulties but also affects facial appearance and increases the burden on the intestinal tract. Restorative treatment is the primary option for this disease. However, traditional restorations have many drawbacks, such as mismatch with the body, low reliability, and incomplete occlusal function recovery.

### AIM

to analyze the efficacy of orthodontics combined with 3D printing guide plate implant restoration in treating patients with dentition defects and its influence on masticatory and phonic functions.

### METHODS

A prospective study was carried out in 86 patients with dentition defects who received implant prosthesis after orthodontic treatment in our hospital between January 2018 and January 2019. Those patients were divided into a control group and an intervention group with 43 patients in each group using a random number table. The control group received traditional implant restoration, whereas the intervention group received 3D printing guide plate implant restoration. Treatment outcomes, cosmetic appearance, dental function, implant deviation, and quality of life were compared between the two groups.

### RESULTS

The overall response rate in the intervention group was significantly higher than

that in the control group (95.35% *vs* 81.40%,  $\chi^2 = 4.071$ ,  $P = 0.044$ ). The number of cases with neatly trimmed cosmetic appearance ( $\chi^2 = 4.497$ ,  $P = 0.034$ ), complete coverage ( $\chi^2 = 4.170$ ,  $P = 0.041$ ), and normal occlusion ( $\chi^2 = 5.512$ ,  $P = 0.019$ ) in the intervention group was higher than that in the control group. After treatment, mastication, swallowing, and articulation were significantly improved in both groups. Masticatory ( $t = 2.980$ ,  $P = 0.004$ ), swallowing ( $t = 2.199$ ,  $P = 0.031$ ), and phonic functions ( $t = 3.950$ ,  $P = 0.004$ ) were better in the intervention group than those in the control group. The deviation value and the deviation angle ( $t = 5.440$ ,  $P = 0.000$ ) at the top ( $t = 6.320$ ,  $P = 0.000$ ) and middle parts of the implants ( $t = 22.295$ ,  $P = 0.000$ ) in the intervention group were lower than those in the control group after treatment. Functional limitations, psychosocial and physical pain and discomfort, and total scores decreased in both groups. The functional limitation ( $t = 2.379$ ,  $P = 0.020$ ), psychosocial ( $t = 2.420$ ,  $P = 0.000$ ), physical pain and discomfort ( $t = 6.581$ ,  $P = 0.000$ ), and total scores ( $t = 2.140$ ,  $P = 0.035$ ) were lower in the intervention group than those in the control group.

## CONCLUSION

Orthodontic treatment combined with 3D printing guide plate implant restoration can significantly improve the masticatory and phonic functions, quality of life, and psychological health of patients with dentition defects. Therefore, it is highly recommended in clinic application.

**Key Words:** Dentition defect; Orthodontics; 3D printing guide plate implant restoration; Masticatory function; Phonic function

©The Author(s) 2022. Published by Baishideng Publishing Group Inc. All rights reserved.

**Core Tip:** In the present prospective study, we included 86 patients with dentition defects who underwent implant restoration after orthodontic treatment at our hospital between January 2018 and 2019. The patients were divided into two groups using a random number table: the patients in the control group were treated with implant prosthesis, and those in the intervention group were treated with 3D printing guide plate implantation. In terms of oral function after treatment, the patients in the intervention group had significantly better chewing, swallowing, and phonic functions than those in the control group. The above results demonstrate that the consistency of the implant with the body was significantly improved after 3D printing guide plate implantation, which had a positive effect on muscle strength recovery at the local lesions. The results of the present study support 3D printing guide plate implantation in routine clinical use.

**Citation:** Yan LB, Zhou YC, Wang Y, Li LX. Orthodontic treatment combined with 3D printing guide plate implant restoration for edentulism and its influence on mastication and phonic function. *World J Clin Cases* 2022; 10(16): 5297-5305

**URL:** <https://www.wjgnet.com/2307-8960/full/v10/i16/5297.htm>

**DOI:** <https://dx.doi.org/10.12998/wjcc.v10.i16.5297>

## INTRODUCTION

Dentition defects is one of the most common oral diseases in clinical practice. Progression of this disease causes not only masticatory dysfunction and articulation difficulties but also aesthetic damage, seriously disturbing people's quality of life[1]. Furthermore, the ability to chew foods at the lesions is markedly reduced, which increases the intestinal burden among patients[2]. Long-term dentition defects also leads to compensatory ptosis of the corner of the mouth, deepening of wrinkles, and other marked changes in appearance. Currently, restorative treatment is the primary method used to fix dentition defects. Through such treatment, oral function and aesthetics of patients can be effectively improved. However, there is a gap between the conventional implant prosthesis and the receptor, resulting in lower reliability of the prosthesis[3] impeding the occlusal recovery of the body[4]. Moreover, in patients with long-term edentulism, the adjacent teeth on both sides tilt to a certain extent, thereby presenting challenges to the denture repair. A study found that implantation aided by 3D printing guide plate can improve the reliability of prosthesis[5]. This study analyzed the effect of orthodontic treatment combined with 3D printing guide plate implantation in dentition defects in an effort to provide scientific verification for its clinical application.



## MATERIALS AND METHODS

### **Clinical data**

This prospective study enrolled 86 patients with dentition defects who underwent implant restoration after orthodontic treatment at our hospital between January 2018 and 2019.

The inclusion criteria were as follows: (1) receiving treatment with orthodontics and desire for a fixed denture restoration; (2) no retention value among all residual teeth in the dentition defects; and (3) signing the informed consent. The exclusion criteria were as follows: (1) severe cardiovascular and cerebrovascular diseases; (2) cognitive dysfunction; (3) inability to perform in this study; and (4) intolerance to the implants or restorations used in this study. This study was approved by the Ethics Committee of our institution.

### **Methods**

All patients were given an oral health examination. According to the imaging data, orthodontic treatment was adopted, and straight-wire technique or edgewise archwire fixation technique was opted for treatment. By observing the dislocation and inclination of teeth, the tooth space was adjusted in time to correct the lesion occlusion relationship. The patients in the control group received implant restoration: it was carried out in time based on the severity of dentition defects. Before operation, their oral cavity and surrounding skin were disinfected, sterile swabs were laid, and lidocaine (2% concentration) was administered for local anesthesia. Under the action of the guide plate, L-shaped or H-shaped incision was made on the periosteum and bone surface at the implantation point. After fully exposing the alveolar bone, drilling on the top of the alveolar ridge was performed, and the implant restoration was carried out by the imaging characteristics. After the operation, normal saline was used to clean the lesion and bleeding is stopped. After placing appropriate screws, soft tissues were sutured. Patients were given antibiotics routinely after operation, and the sutures were removed 7-10 d after operation.

Patients in the intervention group were treated with 3D printing guide plate implant restoration. Their lesions were scanned with computed tomography (CT) before operation. The model data of the patients were obtained using a 3Shape D700 series scanners from the United States. The occlusal relationship was simultaneously recorded using cone-beam CT and rubber molding. Occlusal rim was adopted for patients without malocclusion. After the relationship between the length, direction, and position of the implant was clear, the aforementioned data were imported into the 3D tool again for 3D reconstruction, and the preoperative plaster cast was confirmed using a laser scanner. The implant guide plate was prepared simultaneously based on real-time data registration during data reconstruction. Thereafter, the implant restoration was completed. Routine antibiotic treatment was administered postoperatively.

### **Outcome measures**

**Efficacy:** The efficacy was compared in the two groups after surgery. When the dentition defect was repaired and there was no difference in the physiological function and color between the local lesions and normal tooth condition, the treatment was considered significantly effective. When the dentition defect was roughly repaired and there was a slight difference in the physiological function and color between the local lesions and normal tooth condition, the treatment was considered effective. When the dentition defect was not effectively repaired and there was a significant difference in the physiological function and color between the local lesions and normal tooth condition, the treatment was considered ineffective. The overall response rate was calculated as follows: (effective + significantly effective)/(total number of cases)[6].

**Cosmetic appearance:** Alignment, complete coverage, and occlusal normality after treatment were compared between the two groups.

**Dental function:** The masticatory, swallowing, and phonic functions were compared between the two groups before and six months after treatment. These variables were rated using a 5-level Likert scale, with higher scores indicating better outcomes[7].

**Implant deviations in the 3D plane:** Six months after treatment, CT was performed in both groups, and the data were inputted into the 3D tool for 3D reconstruction. The deviation values and the deviation angles at the top and middle parts of the implants were compared between the two groups.

**Quality of life:** The quality of life of patients was evaluated before and 6 mo after treatment using the Oral Health Impact Profile for Supported Partial Prostheses[8]. It was rated through the evaluation of the functional limitation, social interaction, and physical pain and discomfort of the patients. Higher scores it obtained, worse quality of life was among patients.

### **Statistical analysis**

Data was analyzed using the SPSS 19.0 in this study, in which measurement data were measured as

**Table 1 Comparison of the general data between the groups**

Group	Sex (male/female)	Dentition defects (full mouth/upper/lower)	Body mass index (kg/m <sup>2</sup> )	Age (yr)
Control group ( <i>n</i> = 43)	20/23	8/12/23	24.83 ± 2.24	45.60 ± 3.26
Intervention group ( <i>n</i> = 43)	22/21	9/18/16	24.97 ± 2.22	45.74 ± 4.37
$\chi^2/t$ value	0.186	2.515	0.291	0.168
<i>P</i> value	0.667	0.284	0.772	0.867

mean ± SD. An independent sample *t*-test was also conducted. Enumeration data were expressed as *n* (%), and comparison between groups were made by  $\chi^2$  test. *P* < 0.05 indicated statistical significance.

## RESULTS

### General data

There were 44 women and 42 men aged 36–61 years (average age: 45.67 ± 3.83 years). The average body mass index (BMI) was 24.90 ± 2.22 kg/m<sup>2</sup>. Seventeen patients had complete perioral dentition defect, 30 had lower tooth losses, and 39 had upper tooth losses. The patients were divided into two groups using a random number table; each group included 43 patients, and there was no significant difference in the types of dentition defect, sex, age, or BMI between the groups (*P* > 0.05) (Table 1).

### Treatment effects

The overall response rate of the intervention group was significantly higher than that of the control group (95.35% *vs* 81.40%,  $\chi^2 = 4.071$ , *P* = 0.044). Further details are provided in Table 2. Pictures of typical cases are shown in Figure 1.

### Cosmetic appearance

The number of cases with neatly arranged cosmetic appearance ( $\chi^2 = 4.497$ , *P* = 0.034), complete coverage ( $\chi^2 = 4.170$ , *P* = 0.041), and normal occlusion ( $\chi^2 = 5.512$ , *P* = 0.019) was significantly higher in the intervention group than that in the control group. Further details are provided in Table 3.

### Dental function

Before treatment, swallowing, masticatory, and phonic functions did not significantly differ between the groups (*P* > 0.05). After treatment, masticatory, swallowing, and phonic functions significantly improved in both groups. The masticatory (*t* = 2.980, *P* = 0.004), swallowing (*t* = 2.199, *P* = 0.031), and phonic functions (*t* = 3.950, *P* = 0.004) were significantly better in the intervention group than those in the control group. Further details are provided in Table 4.

### Implant deviations in the 3D plane

The deviation values and the deviation angle (*t* = 5.440, *P* = 0.000) at the top (*t* = 6.320, *P* = 0.000) and middle parts of the implants (*t* = 22.295, *P* = 0.000) in the intervention group were significantly lower than those in the control group (Table 5).

### Quality of life

Before treatment, functional limitation, psychosocial and physical pain and discomfort, and total scores did not significantly differ between the groups (*P* > 0.05). After treatment, functional limitation, psychosocial and physical pain and discomfort, and total scores decreased in both groups. Functional limitations (*t* = 2.379, *P* = 0.020), psychosocial (*t* = 2.420, *P* = 0.000), physical pain and discomfort (*t* = 6.581, *P* = 0.000), and total scores (*t* = 2.140, *P* = 0.035) were significantly lower in the intervention group than in the control group. Further details are provided in Table 6.

## DISCUSSION

Dentition defect is a prevalent oral disease, and related research has found that nearly 60% of the patients with such disease will develop dental malformation, aggravating the case, which can cause a vicious spiral[9]. Orthodontic treatment before implantation can alleviate malocclusion and jaw malformation, make the mouth more desirable, and maintain the normal physiological alignment between the implant and the normal teeth in the mouth for a longer time. However, implants can only repair dentures, which makes it difficult to improve the beauty and function of teeth in the mouth. If

**Table 2 Comparison of the treatment effect between the groups, *n* (%)**

Group	Significantly effective	Effective	Ineffective	Overall response rate
Control group ( <i>n</i> = 43)	15 (34.88)	20 (46.51)	8 (18.60)	35 (81.40)
Intervention group ( <i>n</i> = 43)	25 (58.14)	16 (37.21)	2 (4.65)	41 (95.35)
$\chi^2/U$ value	2.391			4.071
<i>P</i> value	0.014			0.044

**Table 3 Comparison of the cosmetic appearance between the groups, *n* (%)**

Group	Neatly trimmed cosmetic appearance	Complete coverage	Normal occlusion
Control group ( <i>n</i> = 43)	30 (69.77)	29 (67.44)	25 (58.14)
Intervention group ( <i>n</i> = 43)	38 (88.37)	37 (86.05)	35 (81.40)
$\chi^2$ value	4.497	4.170	5.512
<i>P</i> value	0.034	0.041	0.019

**Table 4 Comparison of the dental function between the groups (mean  $\pm$  SD)**

Group	Masticatory function		Swallowing function		Phonic function	
	Before	After	Before	After	Before	After
Control group ( <i>n</i> = 43)	1.91 $\pm$ 0.29	3.09 $\pm$ 0.43	2.65 $\pm$ 0.48	3.63 $\pm$ 0.54	2.56 $\pm$ 0.98	3.26 $\pm$ 0.98
Intervention group ( <i>n</i> = 43)	1.98 $\pm$ 0.27	3.37 $\pm$ 0.49	2.67 $\pm$ 0.47	3.86 $\pm$ 0.41	2.58 $\pm$ 0.59	3.97 $\pm$ 0.64
<i>t</i> value	1.154	2.821	0.225	2.255	0.133	4.052
<i>P</i> value	0.252	0.006	0.822	0.027	0.894	0.000

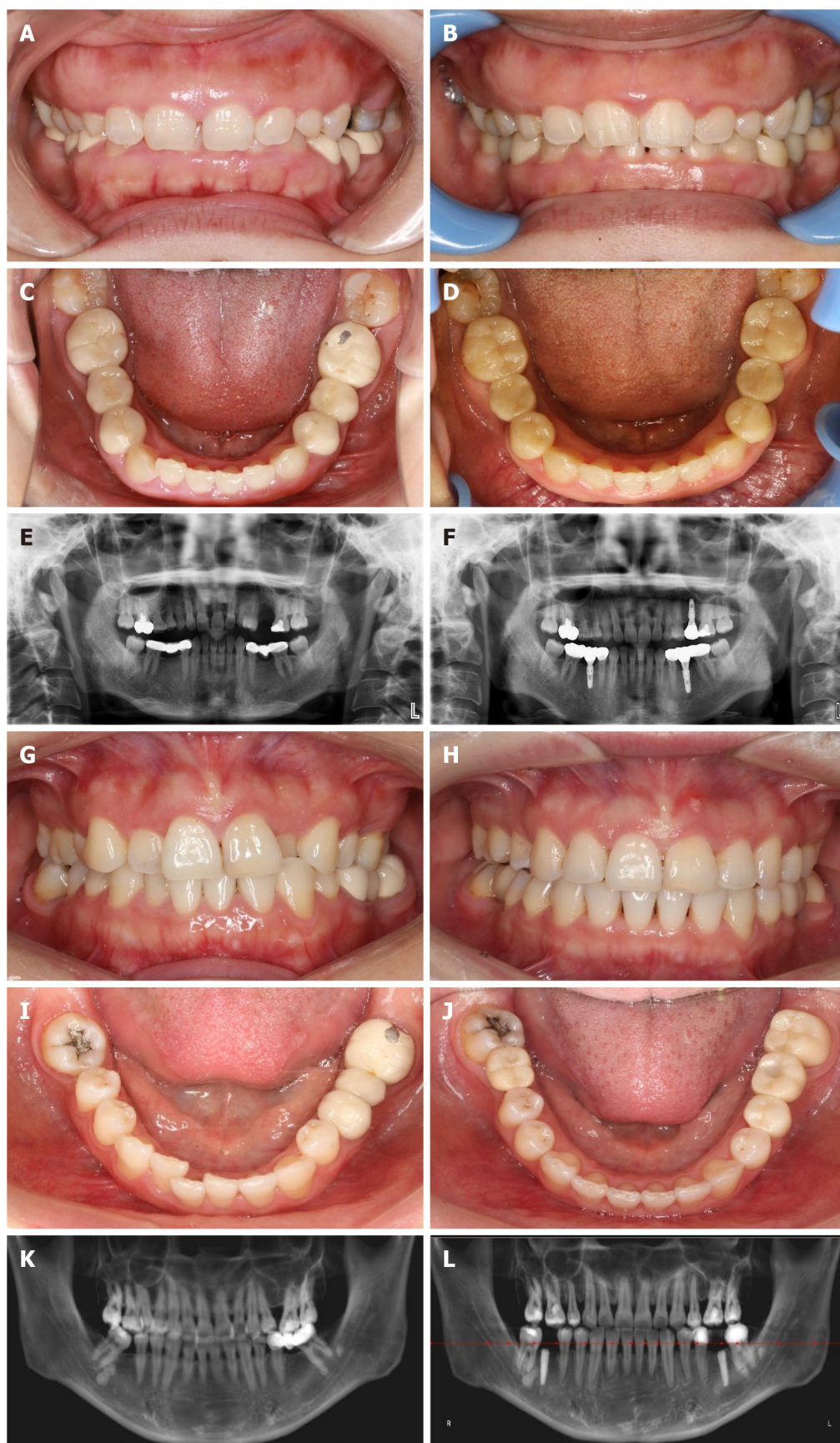
**Table 5 Comparison of the implant deviations in the three-dimensional plane between the groups (mean  $\pm$  SD)**

Group	Top (mm)	Middle (mm)	Angle (°)
Control group ( <i>n</i> = 43)	1.66 $\pm$ 0.97	1.51 $\pm$ 0.28	2.95 $\pm$ 1.23
Intervention group ( <i>n</i> = 43)	0.54 $\pm$ 0.34	0.43 $\pm$ 0.15	1.78 $\pm$ 0.69
<i>t</i> value	7.122	22.295	5.440
<i>P</i> value	0.000	0.000	0.000

**Table 6 Comparison of the quality of life between the groups (mean  $\pm$  SD)**

Group	Functional limitation		Physiological pain and discomfort		Psychological and social		Total score	
	Before	After	Before	After	Before	After	Before	After
Control group ( <i>n</i> = 43)	3.70 $\pm$ 1.52	1.70 $\pm$ 0.96	2.37 $\pm$ 1.57	1.21 $\pm$ 0.41	3.26 $\pm$ 1.54	1.56 $\pm$ 0.98	9.33 $\pm$ 2.54	4.47 $\pm$ 1.32
Intervention group ( <i>n</i> = 43)	3.74 $\pm$ 1.38	1.21 $\pm$ 0.68	2.33 $\pm$ 1.32	0.65 $\pm$ 0.48	3.21 $\pm$ 1.77	1.09 $\pm$ 0.75	9.28 $\pm$ 2.48	2.95 $\pm$ 1.11
<i>t</i> value	0.148	2.721	0.148	5.773	0.130	2.466	0.086	5.755
<i>P</i> value	0.882	0.008	0.882	0.000	0.897	0.016	0.932	0.000

implant restoration is directly implemented, it may expose the patients to the unfavorable implants and aesthetics, and reduce the repair effect because of abnormalities such as the loss of anterior teeth. Therefore, orthodontic treatment before implantation can potentially improve the outcomes of subsequent implant repair[10]. In the treatment of patients with dentition defects, an implant guide plate constitutes a pivotal part in the treatment of multiple missing teeth and poor alveolar bone[9]. Implant guide plates play a considerable guiding role, particularly for doctors with little experience.



DOI: 10.12998/wjcc.v10.i16.5297 Copyright ©The Author(s) 2022.

**Figure 1 Comparison of the treatment effect between the groups.** A: Preoperative frontal images of patients in the control group; B: Postoperative frontal images of patients in the control group; C: Preoperative occlusal images of patients in the control group; D: Postoperative occlusal images of patients in the control group; E: Preoperative panoramic radiography of patients in the control group; F: Postoperative panoramic radiography of patients in the control group; G: Preoperative frontal images of patients in the intervention group; H: Postoperative frontal images of patients in the intervention group; I: Preoperative occlusal images



of patients in the intervention group; J: Postoperative occlusal images of patients in the intervention group; K: Preoperative panoramic radiography of patients in the intervention group; L: Postoperative panoramic radiography of patients in the intervention group.

Therefore, in the course of implant application, the selection of an appropriate implant guide plate plays a decisive role[10]. The fabrication of implant guide plates has many advantages, and plaster casts are routinely used for their preparation. Although the fabrication process is simple, there have been few analyses of the internal bone tissue structure of the edentulous sites. After implantation, the risk of implant deviation increases markedly[11]. Simultaneously, it is necessary to rely on clinical experience during implantation[12]. During this process, the matching accuracy of the model and tooth may be insufficient owing to the use of the vacuum-formed pressure film technology. During model preparation, it was necessary to rotate the model repeatedly. This process may increase the unreliability of the implant guide plate and further enlarge the offset after treatment. With the continuous clinical application of 3D technology, the anatomical position of the dentition defect site is fully considered in the preparation of the model and its accuracy is greatly improved.

In this study, we found that the efficacy in the intervention group was better than that in the control group, and the aesthetics also significantly improved. In the treatment of dentition defects, a substantial inflammatory response inevitably occurs in the alveolar bone of the lesion site, which is markedly destructive to both the bone surface and the periosteal structure. A meta-analysis of studies comparing the clinical outcomes of denture restorations and implants for the treatment of edentulism showed that implant restorations are more effective in the treatment of edentulism than dentures[13]. However, challenges still exist. During implant restoration, the mismatch between the implant and anatomical position of the body[14] causes tooth wear in the gingival and oral tissues[15], and the continuous inflammatory response in gingival tissues[16] further damages the local aesthetics[17]. Involuntary muscle spasms can also be caused by mismatched implant restorations[17], and abnormal changes in appearance can occur as the disease progresses[18]. Complications, due to unpredictability such as pulpal necrosis, root resorption, loosening, and loss of teeth are often observed after dental implantation that therefore not often promoted clinically[19]. In this study, the deviation values at the top and middle parts of the implants in the intervention group were lower than those in the control group, which also confirmed the significant advantage of 3D printing guide plate implantation[20]. In a comparative study of traditional and 3D-printed implant plates, Suo *et al*[21] showed that 3D-printed implant plates had a significant accuracy advantage in the treatment of patients with dentition defects.

In terms of dental function after treatment, the masticatory, swallowing, and phonic functions of the intervention group were significantly better than those of the control group in our study, suggesting that with the use of 3D printing guide plate implantation, the matching of implants to the body is markedly improved, which has a positive role in the recovery of muscle strength at the local lesions. In addition, the quality of life of the intervention group was significantly higher than that of the control group, showing that through the improvement of the tooth function and aesthetics of the patients, the use of 3D printing guide plate implantation has a positive role in improving the quality of life of patients after surgery.

In summary, following the orthodontic treatment combined with 3D printing guide plate implant restoration in patients with dentition defects, the masticatory and phonic functions of the patients significantly improved, so did the quality of life and psychological health. On the basis of these findings, 3D printing guide plate implantation is recommended for clinical application.

## CONCLUSION

To sum up, we have confirmed the significant advantages of 3D printing guide plate implantation, including significant recovery of muscle strength, significant improvement in oral function and quality of life, and a more aesthetic facial appearance in patients at the local lesion site 3D printing guided implant reconstruction is conducive to improving masticatory and phonic functions, and is recommended for clinical application.

## ARTICLE HIGHLIGHTS

### Research background

Dentition defects are among the most common oral diseases in clinical practice. Progression of this disease causes not only masticatory dysfunction and articulation difficulties but also aesthetic damage among patients, seriously affecting their quality of life.

### **Research motivation**

There exists a gap between the conventional prosthesis and the body, resulting in a decrease in the reliability of the prosthesis, consequently impacting the recovery of the occlusal relationship of the body.

### **Research objectives**

This study aimed to investigate the influence of orthodontic treatment combined with 3D printing guide plate implantation on masticatory and language functions in patients with dentition defects.

### **Research methods**

The study included 86 patients with dentition defects who were divided into two groups using a random number table, with each group including 43 patients. The control group received traditional implant prosthesis, whereas the intervention group received 3D printing guide plate implantation.

### **Research results**

In terms of dental function after treatment, the masticatory, swallowing, and phonic functions of the intervention group were significantly better than those of the control group.

### **Research conclusions**

Orthodontics combined with 3D printing guide plate implant restoration can significantly improve the masticatory and language functions of patients with dentition defects.

### **Research perspectives**

The results of this study on orthodontics combined with 3D printing guide plate implant restoration will lay the foundation for further clinical utility of this method.

---

## **FOOTNOTES**

**Author contributions:** Yan LB contributed to methodology and writing - original draft preparation; Zhou YC contributed to software and validation; Wang Y contributed to data curation and investigation; Yan LB and Li LX contributed to data curation and investigation; Li LX contributed to supervision; and all authors have read and agreed to the published version of the manuscript.

**Institutional review board statement:** This study was approved by the Lintong Rehabilitation and Convalescent center.

**Clinical trial registration statement:** This study has not yet been registered.

**Informed consent statement:** All patients signed an informed consent form.

**Conflict-of-interest statement:** The authors have no competing interests to declare.

**Data sharing statement:** There is no additional data available.

**CONSORT 2010 statement:** The authors have read the CONSORT 2010 statement, and the manuscript was prepared and revised according to the CONSORT 2010 statement.

**Open-Access:** This article is an open-access article that was selected by an in-house editor and fully peer-reviewed by external reviewers. It is distributed in accordance with the Creative Commons Attribution NonCommercial (CC BY-NC 4.0) license, which permits others to distribute, remix, adapt, build upon this work non-commercially, and license their derivative works on different terms, provided the original work is properly cited and the use is non-commercial. See: <https://creativecommons.org/licenses/by-nc/4.0/>

**Country/Territory of origin:** China

**ORCID number:** Li-Bo Yan 0000-0003-3212-6313; Yu-Chao Zhou 0000-0002-0121-425X; Yang Wang 0000-0003-0981-0811; Li-Xin Li 0000-0002-3707-5204.

**S-Editor:** Wang JL

**L-Editor:** A

**P-Editor:** Wang JL

## REFERENCES

- 1 **Jie B**, Yao B, Li R, An J, Zhang Y, He Y. Post-traumatic maxillofacial reconstruction with vascularized flaps and digital techniques: 10-year experience. *Int J Oral Maxillofac Surg* 2020; **49**: 1408-1415 [PMID: [32404244](#) DOI: [10.1016/j.ijom.2020.04.012](#)]
- 2 **Bensi C**, Costacurta M, Belli S, Paradiso D, Docimo R. Relationship between preterm birth and developmental defects of enamel: A systematic review and meta-analysis. *Int J Paediatr Dent* 2020; **30**: 676-686 [PMID: [32243004](#) DOI: [10.1111/ipd.12646](#)]
- 3 **Schüttfort G**, Höfler S, Kann G, Königs C, de Leuw P, Herrmann E, Stephan C, Haberl A. Influence of tenofovir exposure in utero on primary dentition. *Eur J Pediatr* 2020; **179**: 1761-1768 [PMID: [32424746](#) DOI: [10.1007/s00431-020-03660-1](#)]
- 4 **Brignardello-Petersen R**. Preterm birth seems to be associated with diagnosis of developmental enamel defects in primary dentition. *J Am Dent Assoc* 2020; **151**: e91 [PMID: [32768143](#) DOI: [10.1016/j.adaj.2020.06.027](#)]
- 5 **Ye J**, Gong P. NGF-CS/HA-coating composite titanium facilitates the differentiation of bone marrow mesenchymal stem cells into osteoblast and neural cells. *Biochem Biophys Res Commun* 2020; **531**: 290-296 [PMID: [32800542](#) DOI: [10.1016/j.bbrc.2020.06.158](#)]
- 6 **Alkhalaf R**, Neves AA, Banerjee A, Hosey MT. Minimally invasive judgement calls: managing compromised first permanent molars in children. *Br Dent J* 2020; **229**: 459-465 [PMID: [33037366](#) DOI: [10.1038/s41415-020-2154-x](#)]
- 7 **Iturriaga MP**, Cocio JA, Barrs VR. Cluster of cases of congenital feline goitrous hypothyroidism in a single hospital. *J Small Anim Pract* 2020; **61**: 696-703 [PMID: [32974927](#) DOI: [10.1111/jsap.13231](#)]
- 8 **Malament KA**, Margvelashvili-Malament M, Natto ZS, Thompson V, Rekow D, Att W. Comparison of 16.9-year survival of pressed acid etched e.max lithium disilicate glass-ceramic complete and partial coverage restorations in posterior teeth: Performance and outcomes as a function of tooth position, age, sex, and thickness of ceramic material. *J Prosthet Dent* 2021; **126**: 533-545 [PMID: [33010922](#) DOI: [10.1016/j.prosdent.2020.08.013](#)]
- 9 **Yin R**, Zhao HJ, Li YC, Pan YP. [Evaluation of alveolar bone defects in patients with periodontitis with Angle Class II malocclusion and orthodontic history by cone beam CT]. *Zhonghua Kouqiang Yixue Zazhi* 2021; **56**: 769-776 [DOI: [10.3760/cma.j.cn112144-20210310-00107](#)]
- 10 **Meixner I**, Hagl B, Kröner CI, Spielberger BD, Paschos E, Dückers G, Niehues T, Hesse R, Renner ED. Retained primary teeth in STAT3 hyper-IgE syndrome: early intervention in childhood is essential. *Orphanet J Rare Dis* 2020; **15**: 244 [PMID: [32912316](#) DOI: [10.1186/s13023-020-01516-3](#)]
- 11 **Wu J**, Wang WN, Yu H, Gao B. [Application of digital technology to rehabilitate a patient with tooth and dentition defects: a case report]. *Zhonghua Kou Qiang Yi Xue Za Zhi* 2020; **55**: 754-756 [PMID: [33045787](#) DOI: [10.3760/cma.j.cn112144-20200528-00304](#)]
- 12 **Wang CL**, Lan ZD, Mao Q, Lin DF, Xu QJ, Liu CH. [Efficacy of Personalized Microanchorage Nail-assisted Rapid Expander in Expansion of Midpalatal Suture in Adults]. *Kouqiang Jibing Yufang* 2020; **28**: 657-663 [DOI: [10.12016/j.issn.2096-1456.2020.10.008](#)]
- 13 **Peng K**, Zhou Y, Dai Y, Wang Q, Hu Y, Dai Q. The effect of denture restoration and dental implant restoration in the treatment of dentition defect: a systematic review and meta-analysis. *Ann Palliat Med* 2021; **10**: 3267-3276 [PMID: [33849111](#) DOI: [10.21037/apm-21-421](#)]
- 14 **Tian MT**, Zhang MZ. [Development and Application of 3D Surgical Guide Combined with Periodontal Cortical Osteotomy]. *Yixue Yanjiu Zazhi* 2020; **26**: 738-742
- 15 **Kramer K**, Chavez MB, Tran AT, Farah F, Tan MH, Kolli TN, Dos Santos EJJ, Wimer HF, Millán JL, Suva LJ, Gaddy D, Foster BL. Dental defects in the primary dentition associated with hypophosphatasia from biallelic ALPL mutations. *Bone* 2021; **143**: 115732 [PMID: [33160095](#) DOI: [10.1016/j.bone.2020.115732](#)]
- 16 **Janssen NG**, Schreurs R, de Ruiter AP, Sylvester-Jensen HC, Blindheim G, Meijer GJ, Koole R, Vindenes H. Microstructured beta-tricalcium phosphate for alveolar cleft repair: a two-centre study. *Int J Oral Maxillofac Surg* 2019; **48**: 708-711 [PMID: [30594478](#) DOI: [10.1016/j.ijom.2018.11.009](#)]
- 17 **Batstone MD**. Reconstruction of major defects of the jaws. *Aust Dent J* 2018; **63** Suppl 1: S108-S113 [PMID: [29574815](#) DOI: [10.1111/adj.12596](#)]
- 18 **Ye H**, Ma Q, Hou Y, Li M, Zhou Y. Generation and evaluation of 3D digital casts of maxillary defects based on multisource data registration: A pilot clinical study. *J Prosthet Dent* 2017; **118**: 790-795 [PMID: [28449864](#) DOI: [10.1016/j.prosdent.2017.01.014](#)]
- 19 **Zhifang C**, Wei Z. [Clinical application on restoration of dentition defects using tooth-alveolar bone grafts]. *Hua Xi Kou Qiang Yi Xue Za Zhi* 2016; **34**: 364-368 [PMID: [28317353](#) DOI: [10.7518/hxkq.2016.04.009](#)]
- 20 **Liu CH**, Mao Q, Wang CL. [Application and research progress of maxillary transverse expansion technique]. *Kouqiang Jibing Yufang* 2020; **28**: 689-697 [DOI: [10.12016/j.issn.2096-1456.2020.11.002](#)]
- 21 **Suo WC**, Zhou C, Wang HT. [Comparison of clinical application of traditional implant guide plate and 3D printed implant guide plate in dental implant restoration]. *Shandong Yiyao* 2018; **58**: 75-77 [DOI: [10.3969/j.issn.1002-266X.2018.42.023](#)]



Published by **Baishideng Publishing Group Inc**  
7041 Koll Center Parkway, Suite 160, Pleasanton, CA 94566, USA

**Telephone:** +1-925-3991568

**E-mail:** [bpgoffice@wjgnet.com](mailto:bpgoffice@wjgnet.com)

**Help Desk:** <https://www.f6publishing.com/helpdesk>

<https://www.wjgnet.com>

