

World Journal of *Clinical Cases*

World J Clin Cases 2022 September 6; 10(25): 8808-9179



Contents

Thrice Monthly Volume 10 Number 25 September 6, 2022

MINIREVIEWS

- 8808 Ear, nose, and throat manifestations of COVID-19 and its vaccines
Al-Ani RM
- 8816 Potential influences of religiosity and religious coping strategies on people with diabetes
Onyishi CN, Eseadi C, Ilechukwu LC, Okoro KN, Okolie CN, Egbule E, Asogwa E

ORIGINAL ARTICLE

Case Control Study

- 8827 Effectiveness of six-step complex decongestive therapy for treating upper limb lymphedema after breast cancer surgery
Zhang HZ, Zhong QL, Zhang HT, Luo QH, Tang HL, Zhang LJ

Retrospective Study

- 8837 Hospital admissions from alcohol-related acute pancreatitis during the COVID-19 pandemic: A single-centre study
Mak WK, Di Mauro D, Pearce E, Karran L, Myintmo A, Duckworth J, Orabi A, Lane R, Holloway S, Manzelli A, Mossadegh S
- 8844 Indocyanine green plasma clearance rate and 99mTc-galactosyl human serum albumin single-photon emission computed tomography evaluated preoperative remnant liver
Iwaki K, Kaihara S, Kita R, Kitamura K, Hashida H, Uryuhara K
- 8854 Arthroscopy with subscapularis upper one-third tenodesis for treatment of recurrent anterior shoulder instability independent of glenoid bone loss
An BJ, Wang FL, Wang YT, Zhao Z, Wang MX, Xing GY
- 8863 Evaluation of the prognostic nutritional index for the prognosis of Chinese patients with high/extremely high-risk prostate cancer after radical prostatectomy
Yang F, Pan M, Nie J, Xiao F, Zhang Y

Observational Study

- 8872 Chlorine poisoning caused by improper mixing of household disinfectants during the COVID-19 pandemic: Case series
Lin GD, Wu JY, Peng XB, Lu XX, Liu ZY, Pan ZG, Qiu ZW, Dong JG
- 8880 Mental health of the Slovak population during COVID-19 pandemic: A cross-sectional survey
Kralova M, Brazinova A, Sivcova V, Izakova L

Prospective Study

- 8893** Arthroscopic anatomical reconstruction of lateral collateral ligaments with ligament advanced reinforcement system artificial ligament for chronic ankle instability
Wang Y, Zhu JX

SYSTEMATIC REVIEWS

- 8906** How to select the quantitative magnetic resonance technique for subjects with fatty liver: A systematic review
Li YW, Jiao Y, Chen N, Gao Q, Chen YK, Zhang YF, Wen QP, Zhang ZM
- 8922** Lymphocytic choriomeningitis virus: An under-recognized congenital teratogen
Ferenc T, Vujica M, Mrzljak A, Vilibic-Cavlek T

CASE REPORT

- 8932** Alagille syndrome associated with total anomalous pulmonary venous connection and severe xanthomas: A case report
Zeng HS, Zhang ZH, Hu Y, Zheng GL, Wang J, Zhang JW, Guo YX
- 8939** Colo-colonic intussusception with post-polypectomy electrocoagulation syndrome: A case report
Moon JY, Lee MR, Yim SK, Ha GW
- 8945** Portal vein gas combined with pneumatosis intestinalis and emphysematous cystitis: A case report and literature review
Hu SF, Liu HB, Hao YY
- 8954** Quadricuspid aortic valve and right ventricular type of myocardial bridging in an asymptomatic middle-aged woman: A case report
Sopek Merkaš I, Lakušić N, Paar MH
- 8962** Treatment of gastric carcinoma with lymphoid stroma by immunotherapy: A case report
Cui YJ, Ren YY, Zhang HZ
- 8968** Gallstone associated celiac trunk thromboembolisms complicated with splenic infarction: A case report
Wu CY, Su CC, Huang HH, Wang YT, Wang CC
- 8974** Extracorporeal membrane oxygenation for lung cancer-related life-threatening hypoxia: A case report
Yoo SS, Lee SY, Choi SH
- 8980** Multi-disciplinary treatment of maxillofacial skeletal deformities by orthognathic surgery combined with periodontal phenotype modification: A case report
Liu JY, Li GF, Tang Y, Yan FH, Tan BC
- 8990** X-linked recessive Kallmann syndrome: A case report
Zhang P, Fu JY
- 8998** Delayed complications of intradural cement leakage after percutaneous vertebroplasty: A case report
Ma QH, Liu GP, Sun Q, Li JG

- 9004** Coexistent Kaposi sarcoma and post-transplant lymphoproliferative disorder in the same lymph nodes after pediatric liver transplantation: A case report
Zhang SH, Chen GY, Zhu ZJ, Wei L, Liu Y, Liu JY
- 9012** Misdiagnosis of pancreatic metastasis from renal cell carcinoma: A case report
Liang XK, Li LJ, He YM, Xu ZF
- 9020** Discoid medial meniscus of both knees: A case report
Zheng ZR, Ma H, Yang F, Yuan L, Wang GD, Zhao XW, Ma LF
- 9028** Simultaneous laparoscopic and arthroscopic excision of a huge juxta-articular ganglionic cyst compressing the sciatic nerve: A case report
Choi WK, Oh JS, Yoon SJ
- 9036** One-stage revision arthroplasty in a patient with ochronotic arthropathy accompanied by joint infection: A case report
Wang XC, Zhang XM, Cai WL, Li Z, Ma C, Liu YH, He QL, Yan TS, Cao XW
- 9044** Bladder paraganglioma after kidney transplantation: A case report
Wang L, Zhang YN, Chen GY
- 9050** Total spinal anesthesia caused by lidocaine during unilateral percutaneous vertebroplasty performed under local anesthesia: A case report
Wang YF, Bian ZY, Li XX, Hu YX, Jiang L
- 9057** Ruptured splenic artery aneurysms in pregnancy and usefulness of endovascular treatment in selective patients: A case report and review of literature
Lee SH, Yang S, Park I, Im YC, Kim GY
- 9064** Gastrointestinal metastasis secondary to invasive lobular carcinoma of the breast: A case report
Li LX, Zhang D, Ma F
- 9071** Post-bulbar duodenal ulcer with anterior perforation with kissing ulcer and duodenocaval fistula: A case report and review of literature
Alzerwi N
- 9078** Modified orthodontic treatment of substitution of canines by first premolars: A case report
Li FF, Li M, Li M, Yang X
- 9087** Renal cell carcinoma presented with a rare case of icteric Stauffer syndrome: A case report
Popov DR, Antonov KA, Atanasova EG, Pentchev CP, Milatchkov LM, Petkova MD, Neykov KG, Nikolov RK
- 9096** Successful resection of a huge retroperitoneal venous hemangioma: A case report
Qin Y, Qiao P, Guan X, Zeng S, Hu XP, Wang B
- 9104** Malignant transformation of biliary adenofibroma combined with benign lymphadenopathy mimicking advanced liver carcinoma: A case report
Wang SC, Chen YY, Cheng F, Wang HY, Wu FS, Teng LS

- 9112** Congenital hepatic cyst: Eleven case reports
Du CX, Lu CG, Li W, Tang WB
- 9121** Endovascular treatment of a ruptured pseudoaneurysm of the internal carotid artery in a patient with nasopharyngeal cancer: A case report
Park JS, Jang HG
- 9127** Varicella-zoster virus meningitis after spinal anesthesia: A case report
Lee YW, Yoo B, Lim YH
- 9132** Chondrosarcoma of the toe: A case report and literature review
Zhou LB, Zhang HC, Dong ZG, Wang CC
- 9142** Tamsulosin-induced life-threatening hypotension in a patient with spinal cord injury: A case report
Lee JY, Lee HS, Park SB, Lee KH
- 9148** CCNO mutation as a cause of primary ciliary dyskinesia: A case report
Zhang YY, Lou Y, Yan H, Tang H
- 9156** Repeated bacteremia and hepatic cyst infection lasting 3 years following pancreatoduodenectomy: A case report
Zhang K, Zhang HL, Guo JQ, Tu CY, Lv XL, Zhu JD
- 9162** Idiopathic cholesterol crystal embolism with atheroembolic renal disease and blue toes syndrome: A case report
Cheng DJ, Li L, Zheng XY, Tang SF
- 9168** Systemic lupus erythematosus with visceral varicella: A case report
Zhao J, Tian M

LETTER TO THE EDITOR

- 9176** Imaging of fibroadenoma: Be careful with imaging follow-up
Ece B, Aydın S

ABOUT COVER

Editorial Board Member of *World Journal of Clinical Cases*, Mohsen Khosravi, MD, Assistant Professor, Department of Psychiatry and Clinical Psychology, Zahedan University of Medical Sciences, Zahedan 9819713955, Iran. m.khosravi@zaums.ac.ir

AIMS AND SCOPE

The primary aim of *World Journal of Clinical Cases* (WJCC, *World J Clin Cases*) is to provide scholars and readers from various fields of clinical medicine with a platform to publish high-quality clinical research articles and communicate their research findings online.

WJCC mainly publishes articles reporting research results and findings obtained in the field of clinical medicine and covering a wide range of topics, including case control studies, retrospective cohort studies, retrospective studies, clinical trials studies, observational studies, prospective studies, randomized controlled trials, randomized clinical trials, systematic reviews, meta-analysis, and case reports.

INDEXING/ABSTRACTING

The WJCC is now abstracted and indexed in Science Citation Index Expanded (SCIE, also known as SciSearch®), Journal Citation Reports/Science Edition, Current Contents®/Clinical Medicine, PubMed, PubMed Central, Scopus, Reference Citation Analysis, China National Knowledge Infrastructure, China Science and Technology Journal Database, and Superstar Journals Database. The 2022 Edition of Journal Citation Reports® cites the 2021 impact factor (IF) for WJCC as 1.534; IF without journal self cites: 1.491; 5-year IF: 1.599; Journal Citation Indicator: 0.28; Ranking: 135 among 172 journals in medicine, general and internal; and Quartile category: Q4. The WJCC's CiteScore for 2021 is 1.2 and Scopus CiteScore rank 2021: General Medicine is 443/826.

RESPONSIBLE EDITORS FOR THIS ISSUE

Production Editor: *Xu Guo*; Production Department Director: *Xiang Li*; Editorial Office Director: *Jin-Lei Wang*.

NAME OF JOURNAL

World Journal of Clinical Cases

ISSN

ISSN 2307-8960 (online)

LAUNCH DATE

April 16, 2013

FREQUENCY

Thrice Monthly

EDITORS-IN-CHIEF

Bao-Gan Peng, Jerzy Tadeusz Chudek, George Kontogeorgos, Maurizio Serati, Ja Hyeon Ku

EDITORIAL BOARD MEMBERS

<https://www.wjgnet.com/2307-8960/editorialboard.htm>

PUBLICATION DATE

September 6, 2022

COPYRIGHT

© 2022 Baishideng Publishing Group Inc

INSTRUCTIONS TO AUTHORS

<https://www.wjgnet.com/bpg/gerinfo/204>

GUIDELINES FOR ETHICS DOCUMENTS

<https://www.wjgnet.com/bpg/GerInfo/287>

GUIDELINES FOR NON-NATIVE SPEAKERS OF ENGLISH

<https://www.wjgnet.com/bpg/gerinfo/240>

PUBLICATION ETHICS

<https://www.wjgnet.com/bpg/GerInfo/288>

PUBLICATION MISCONDUCT

<https://www.wjgnet.com/bpg/gerinfo/208>

ARTICLE PROCESSING CHARGE

<https://www.wjgnet.com/bpg/gerinfo/242>

STEPS FOR SUBMITTING MANUSCRIPTS

<https://www.wjgnet.com/bpg/GerInfo/239>

ONLINE SUBMISSION

<https://www.f6publishing.com>



Retrospective Study

Arthroscopy with subscapularis upper one-third tenodesis for treatment of recurrent anterior shoulder instability independent of glenoid bone loss

Bai-Jing An, Feng-Lin Wang, Yao-Ting Wang, Zhe Zhao, Ming-Xin Wang, Geng-Yan Xing

Specialty type: Medicine, research and experimental

Provenance and peer review: Unsolicited article; Externally peer reviewed.

Peer-review model: Single blind

Peer-review report's scientific quality classification

Grade A (Excellent): 0
Grade B (Very good): B, B
Grade C (Good): C
Grade D (Fair): 0
Grade E (Poor): 0

P-Reviewer: Mastrantonakis K, Greece; Oommen AT, India

Received: February 16, 2022

Peer-review started: February 16, 2022

First decision: June 7, 2022

Revised: June 16, 2022

Accepted: July 22, 2022

Article in press: July 22, 2022

Published online: September 6, 2022



Bai-Jing An, Feng-Lin Wang, Yao-Ting Wang, Zhe Zhao, Ming-Xin Wang, Department of Sports Medicine, The Fourth Medical Center, PLA General Hospital, Beijing 100048, China

Feng-Lin Wang, Department of Clinical Laboratory, The Third Medical Center, PLA General Hospital, Beijing 100039, China

Geng-Yan Xing, Department of Orthopedics, The Third Medical Center, PLA General Hospital, Beijing 100039, China

Corresponding author: Feng-Lin Wang, MD, PhD, Professor, Department of Clinical Laboratory, The Third Medical Center, PLA General Hospital, No. 69 Yongding Road, Beijing 100039, China. gcp_wjzyy@tom.com

Abstract

BACKGROUND

Recurrent anterior shoulder instability is a common traumatic injury, the main clinical manifestation of which is recurrent anteroinferior dislocation of the humeral head. The current follow-up study showed that the effect of arthroscopic Bankart repair is unreliable.

AIM

To evaluate the clinical efficacy of arthroscopy with subscapularis upper one-third tenodesis for treatment of anterior shoulder instability, and to develop a method to further improve anterior stability and reduce the recurrence rate.

METHODS

Between January 2015 and December 2018, male patients with recurrent anterior shoulder instability were selected. One hundred and twenty patients had a glenoid defect < 20% and 80 patients had a glenoid defect > 20%. The average age was 25 years (range, 18–45 years). Patients with a glenoid defect < 20% underwent arthroscopic Bankart repair with a subscapularis upper one-third tenodesis. The patients with a glenoid defect > 20% underwent an arthroscopic iliac crest bone autograft with a subscapularis upper one-third tenodesis. All patients were assessed with Rowe and Constant scores.

RESULTS

The average shoulder forward flexion angle was $163.6^{\circ} \pm 8.3^{\circ}$ and $171.8^{\circ} \pm 3.6^{\circ}$ preoperatively and at the last follow-up evaluation, respectively. The average external rotation angle when abduction was 90° was $68.4^{\circ} \pm 13.6^{\circ}$ and $88.5^{\circ} \pm 6.2^{\circ}$ preoperatively and at the last follow-up evaluation, respectively. The mean Rowe scores preoperatively and at the last follow-up evaluation were 32.6 ± 3.2 and 95.2 ± 2.2 , respectively ($P < 0.05$). The mean Constant scores preoperatively and at the last follow-up evaluation were 75.4 ± 3.5 and 95.8 ± 3.3 , respectively ($P < 0.05$). No postoperative dislocations were recorded by the end of the follow-up period.

CONCLUSION

Arthroscopy with subscapularis upper one-third tenodesis was effective for treatment of recurrent anterior shoulder instability independent of the size of the glenoid bone defect, enhanced anterior stability of the shoulder, and did not affect postoperative range of motion of the affected limb.

Key Words: Arthroscopy; Subscapularis; Iliac crest bone autograft; Recurrent anterior shoulder instability; Glenoid bone loss

©The Author(s) 2022. Published by Baishideng Publishing Group Inc. All rights reserved.

Core Tip: Arthroscopy combined with subscapularis upper one-third tenodesis was effective for treatment of recurrent anterior shoulder instability independent of the size of the glenoid bone defect, enhanced anterior stability of the shoulder, and did not affect the postoperative range of motion of the affected limb.

Citation: An BJ, Wang FL, Wang YT, Zhao Z, Wang MX, Xing GY. Arthroscopy with subscapularis upper one-third tenodesis for treatment of recurrent anterior shoulder instability independent of glenoid bone loss. *World J Clin Cases* 2022; 10(25): 8854-8862

URL: <https://www.wjgnet.com/2307-8960/full/v10/i25/8854.htm>

DOI: <https://dx.doi.org/10.12998/wjcc.v10.i25.8854>

INTRODUCTION

Recurrent anterior shoulder instability is a common traumatic injury; the main clinical manifestation of which is recurrent anteroinferior dislocation of the humeral head. In the process of dislocation, the impact between the humeral head and the anteroinferior glenoid can lead to injury of the anterior glenoid labial ligament complex (Bankart lesion), and even an anterior labroligamentous periosteal sleeve avulsion (ALPSA). In some patients, the posterolateral collision between the glenoid and the humeral head in the process of recurrent dislocation may result in a bony glenoid defect (bony Bankart injury) and bone injury of the humeral head (Hill-Sachs injury), which increases the probability of re-dislocation. In recent years, the treatment of recurrent anterior shoulder instability has focused on labrum tear repair and bony structure reconstruction, which enhance the anterior stability of the shoulder. A number of studies have reported that arthroscopic surgery achieves satisfactory results[1, 2]. Currently, a labrum repair is generally performed in patients with a glenoid bone defect $< 20\%$ and an on-track Hill-Sachs injury. Anterior glenoid bone defects $> 20\%$ and off-track Hill-Sachs injuries should be treated with glenoid bone grafting (Latarjet surgery and iliac bone grafting) or the remplissage technique[3,4]. A follow-up study showed that the effect of arthroscopic Bankart repair is unreliable, perhaps because the anterior labrum contracture was incompletely resolved due to repeated dislocation over a long period of time[5]. The blocking force of arthroscopic anterior labrum repair is insufficient, and cannot prevent anterior dislocation of the shoulder. Therefore, the stability and function of the shoulder cannot be improved after a labrum repair. A review of the literature showed that subscapularis upper one-third tenodesis fixed anterior to the scapular glenoid prevents re-dislocation of the shoulder and enhances stability of the shoulder[6]. Therefore, we repaired the torn labrum or reconstructed the bony structure, but also enhanced the anterior shoulder stability with subscapularis tenodesis augmentation in the treatment of recurrent anterior shoulder instability.

MATERIALS AND METHODS

From July 2016 to December 2018, 200 male patients who were diagnosed with recurrent anterior shoulder instability and underwent arthroscopic surgery were enrolled. The average age at the time of surgery was 25 years (range, 18–45 years; Table 1). The inclusion criteria were as follows: (1) Anterior

Table 1 Demographic data

Parameters	Glenoid defects < 20%	Glenoid defects > 20%	Entire series
Number	120	80	200
Age (yr)	23 (18-40)	26 (18-45)	25 (18-45)
Follow-up (mo)	36 (24-48)	36 (26-60)	36 (24-60)
Dominant arm (right/left)	78/42	43/37	121/79
Dislocation before surgery	5 (3-10)	10 (3-50)	6 (3-50)

shoulder dislocations > 3; (2) Preoperative imaging examination confirmed anterior and inferior labrum tears or an accompanying bony defect; and (3) No stable operation was performed before participating in this study. The exclusion criteria were as follows: (1) Previous surgery of the affected shoulder; (2) Concomitant rotator cuff tear; (3) Concomitant remplissage or superior labrum anterior to posterior repair; (4) Concomitant epilepsy or psychiatric disease; and (5) Incomplete radiological or clinical follow-up. All patients had anteroposterior and oblique radiographs of the shoulder, a computed tomography (CT) scan, and magnetic resonance imaging (MRI) examination before surgery. MRI angiography was feasible for patients without an obvious labrum tear. Preoperative plain radiographs and CT scans with the population, intervention, control, and outcomes surface area measurement were obtained to accurately determine the glenoid deficit (Figure 1). This study was approved by the Institutional Review Board.

Surgical technique

The arthroscopic procedure was performed under locoregional anesthesia with the patient in the lateral decubitus position. Standard posterior, anterior and anterosuperior approaches were used. The posterior approach of the shoulder was established (2 cm down and 1 cm inward at the posterolateral angle of the acromion). Labrum tears were noted in all cases. Some patients also had ALPSA injuries; the anterior labrum had disappeared and presented as clip-like changes. The area of the glenoid defect and whether the trajectory of the humeral head was on- or off-track were evaluated intraoperatively. Anterior and anterosuperior approaches were established. Pre-positioned Pushlock anchors were arranged approximately 45° oblique to the coronal plane and perpendicular to the longitudinal axis of the labrum for patients with a glenoid defect < 20%. The labrum and the capsule were sutured with a threading device, and the suture line was pressed by Pushlock anchors to adjust the tension. An iliac crest bone autograft, 2.0 cm × 1 cm × 1 cm in size, from the ipsilateral anterior superior iliac spine was used for patients with a glenoid defect > 20%. Two 2.9-mm Pushlock anchor holes were drilled at the 3 and 5 o'clock positions in the left shoulder. A 3.0-mm suture anchor was drilled at the 4 o'clock position in the left shoulder, 1 cm from the upper edge of the glenoid surface. The bone graft was implanted through the anterosuperior approach. The cancellous bone surface of the bone block was attached to the defect surface of the glenoid, and the double anchor tail lines were fixed by two Pushlock anchors (Figures 2 and 3). The upper one-third of the subscapularis tendon was sutured and fixed at the 2 o'clock position in the left shoulder with both methods (Figure 4).

Postoperative protocol

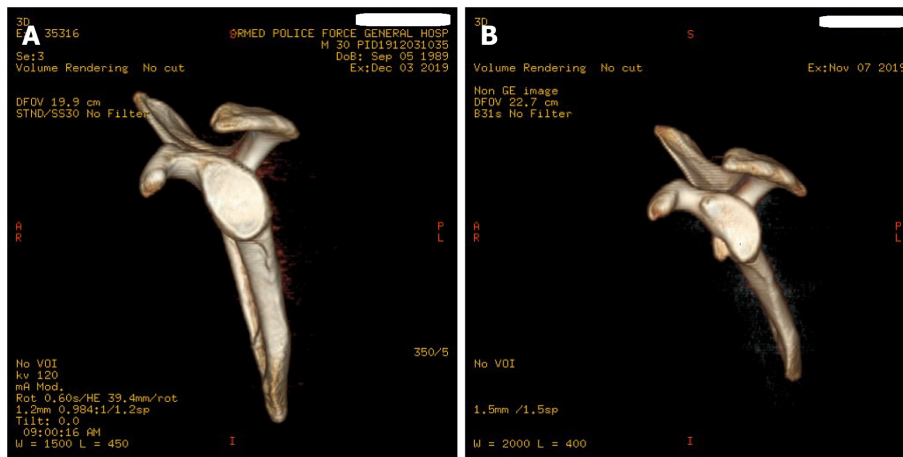
After surgical repair, the shoulder was strictly immobilized in a sling for 2 wk in patients without bone grafts and for 4 wk in patients with bone grafts. The patients began passive range-of-motion (ROM) exercises to increase joint mobility in the 3rd week postoperatively in patients without bone grafts and the 5th week postoperatively in patients with bone grafts. At 6-8 wk postoperatively, physiotherapy focused on recovery of full ROM in the shoulder. Strengthening exercises began 10-12 wk postoperatively. Full ROM of the shoulder was permitted 12 wk postoperatively. All sports activities were allowed 6 mo postoperatively.

Statistical analysis

Statistical analysis was performed using SPSS 23.0 software. Measurement data are shown as the mean ± SD. The Rowe and Constant scores of patients were normally distributed before and at the last follow-up evaluation. Paired *t*-tests were used for quantitative data. Two-sided *P* values were calculated and the level of significance was defined as *P* < 0.05.

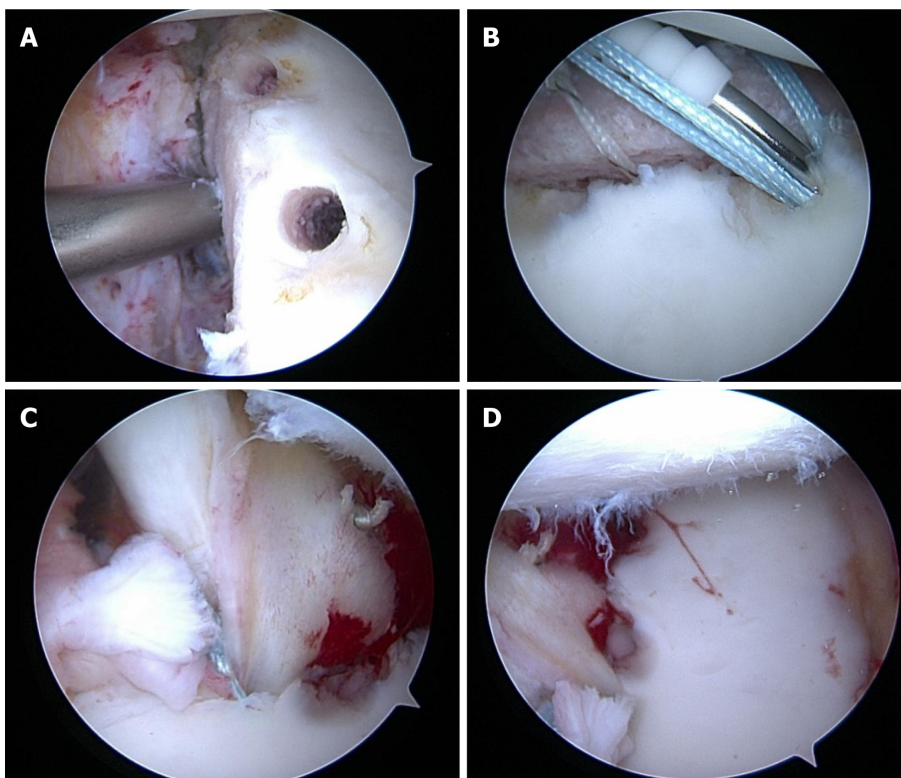
RESULTS

Patients were followed for an average of 3 years (2-5 years). Clinical efficacy was analyzed based on the patient's chief complaint, ROM of the shoulder, X-ray findings, and CT three-dimensional



DOI: 10.12998/wjcc.v10.i25.8854 Copyright ©The Author(s) 2022.

Figure 1 Computed tomography scan and three-dimensional reconstruction of the shoulder joint were routinely performed preoperatively, and the bone defect area was measured. A: Glenoid bone defect was < 20%; B: Glenoid bone defect was > 20%.



DOI: 10.12998/wjcc.v10.i25.8854 Copyright ©The Author(s) 2022.

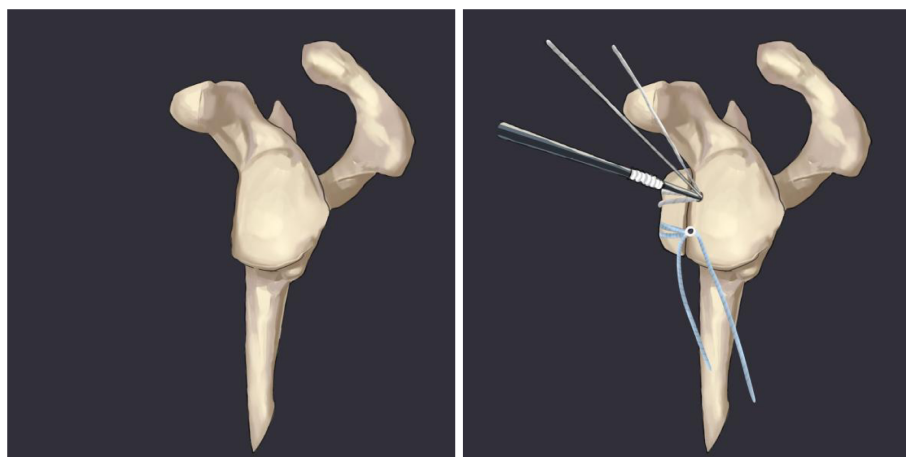
Figure 2 Subscapularis upper one-third tenodesis with bone autograft. A: A 3.0-mm suture anchor was drilled at the 4 o'clock position; B: Iliac crest bone autograft was implanted, and Pushlock anchors were inserted to compress the bone block; C: Upper one-third of the subscapularis tendon was tightened; D: Anterosuperior approach was observed again under arthroscopy. The humeral head was completely re-dislocated.

reconstruction (Figure 5). Pre- and postoperative shoulder function was evaluated by ROM, and Constant and Rowe scores. The average angle of shoulder forward flexion before surgery and at the last follow-up evaluation was $163.6^\circ \pm 8.3^\circ$ and $171.8^\circ \pm 3.6^\circ$, respectively. The average angle of external rotation with the arm in abduction before surgery and at the last follow-up evaluation was $68.4^\circ \pm 13.6^\circ$ and $88.5^\circ \pm 6.2^\circ$, respectively. The mean Constant scores before and at the last follow-up evaluation were 75.4 ± 3.5 and 95.8 ± 3.3 , respectively, which were significantly different from the before-treatment score ($P < 0.05$). The mean Rowe scores before and at the last follow-up evaluation were 32.6 ± 3.2 and 95.2 ± 2.2 , respectively, which were significantly higher than the before-treatment score ($P < 0.05$; Table 2). No recurrent dislocations occurred through the final follow-up evaluation.

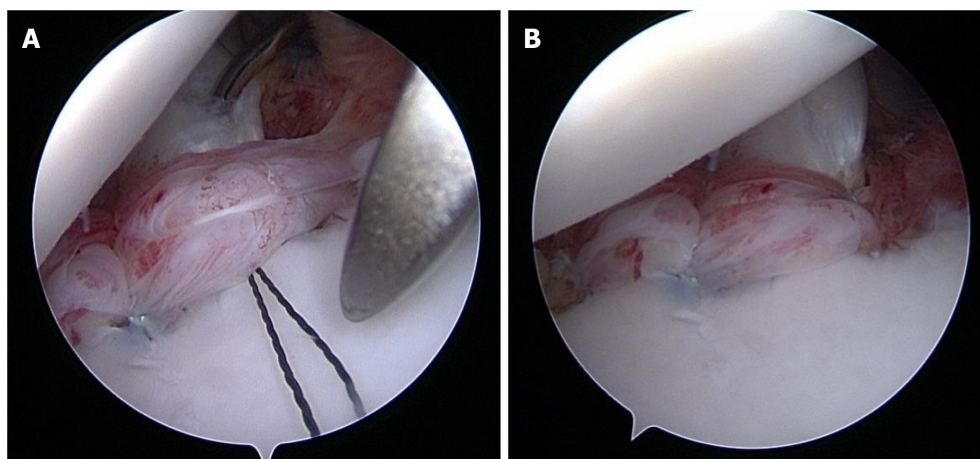
Table 2 Preoperative and follow-up clinical outcomes

	Preoperative	Follow-up	<i>P</i> value
Forward flexion	163.6 ± 8.3	171.8 ± 3.6	< 0.005
ER	68.4 ± 13.6	88.5 ± 6.2	< 0.005
Constant score	75.4 ± 3.5	95.8 ± 3.3	< 0.005
Rowe score	32.6 ± 3.2	95.2 ± 2.2	< 0.005

Data are presented as the mean ± SD, unless otherwise indicated. ER: External rotation with arm in abduction.



DOI: 10.12998/wjcc.v10.i25.8854 Copyright ©The Author(s) 2022.

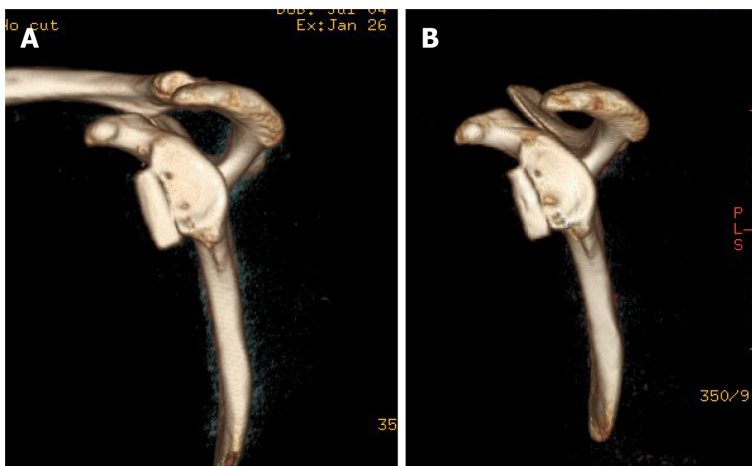
Figure 3 Surgical diagram: Iliac bone block was fixed with Pushlock anchors.

DOI: 10.12998/wjcc.v10.i25.8854 Copyright ©The Author(s) 2022.

Figure 4 Subscapularis upper one-third tenodesis. A: Upper one-third of the subscapular tendon was sutured; B: Suture line was pressed with a Pushlock anchor and the tension was adjusted appropriately.

DISCUSSION

Arthroscopic single labrum repair for recurrent anterior shoulder instability achieves good results; however, follow-up evaluations have shown that there is a high probability of recurrent shoulder re-dislocation[7]. The risk factors for re-dislocation of the shoulder after arthroscopic labrum repair include ALPSA injuries, Hill-Sachs injuries, and anterior glenoid bone defects[8]. In 2015 Klungsøyr *et al*[9] reported that arthroscopy with upper one-third subscapularis augmentation had satisfactory efficacy in the treatment of recurrent anterior shoulder instability. The recurrence rate was < 2.5%, and the external rotation function of the shoulder was not affected at the time of short-term follow-up evaluation because upper one-third subscapularis augmentation fixation increased the contact surface between the capsule



DOI: 10.12998/wjcc.v10.i25.8854 Copyright ©The Author(s) 2022.

Figure 5 Measurement of bone graft resorption (showing 1 wk and 1 yr postoperatively; left shoulder view on 3-dimensional computed tomography scan). A: 1 wk after surgery; B: 1 yr after surgery.

and bone. Maiotti and Massoni[6] conducted biomechanical studies in cadavers and showed that subscapularis augmentation acts as a barrier to the eccentric movement of the humeral head. In a multicenter study, Taverna *et al*[10] confirmed that Bankart injury repair with the subscapularis technique had good results, a low failure rate, and no impact on external rotation of the shoulder. Therefore, for patients who do not require bone grafting, the binding force of arthroscopic Bankart repair is insufficient for the humeral head. Inferior labrum and capsule augmentation cannot effectively prevent recurrent dislocation of the shoulder, thus the recurrence rate is high[11]. Several studies have shown that patients with recurrent anterior shoulder instability have severe anterior labrum tears; some patients even have an absent anterior labrum and the anterior capsule is clearly loosened[12]. Therefore, it is difficult to obtain sufficient stability with the Bankart repair alone, which leads to failure and recurrence. The subscapularis has an important role in maintaining forward stability of the shoulder. Suturing part of the subscapularis tendon and joint capsule to the anterior labrum effectively enhances the anterior blocking effect of the shoulder and does not have a significant impact on rotation of the shoulder[13,14]. We observed a reduction in movement of the humeral head during arthroscopic subscapular augmentation. Therefore, it is clear that contraction of some subscapular muscles has a role in blocking forward movement of the humeral head. Postoperative functional exercise will not affect rotation of shoulder, and no dislocations occurred in our study.

According to Ito *et al*[15], treatment of recurrent anterior shoulder instability should be based on the type of glenoid defect, the surface area as measured by CT scans, and repair of on-track Hill-Sachs injuries with soft tissue. Remplissage or Latarjet technology is required for off-track Hill-Sachs injuries. Burkhart and De Beer[16] summarized the strategies for treatment of recurrent anterior shoulder instability as follows: (1) Glenoid defects < 20% in on-track Hill-Sachs injuries are repaired by Bankart arthroscopy; (2) Articular glenoid defects < 20% accompanied by off-track Hill-Sachs injuries are repaired by arthroscopy Bankart plus remplissage; and (3) Latarjet surgery is performed for glenoid defects > 20%. Latarjet surgery, iliac crest bone autografts, and distal tibial allografts are the most widely used methods for glenoid defects. Compared with other surgical methods, an iliac crest bone autograft is an anatomic repair that is more consistent with the normal structural relationship of the shoulder. Autogenous iliac bone does not elicit a rejection reaction, reduces damage to the subscapular muscle, and facilitates satisfactory bone healing; however, Latarjet surgery is a nonanatomical reconstruction, the combined tendon has a traction effect on the bone graft postoperatively, healing of the bone graft is affected, the normal anatomical structure of the shoulder is distorted, and whether there is a long-term impact on the normal movement of the shoulder is currently unknown. The main complications of Latarjet surgery are failure of fixation, poor position, displacement, absorption, and secondary osteoarthritis and axillary nerve injury[17-21]. A recent randomized controlled trial by Moroder *et al*[22] reported that iliac crest bone graft transfer results in similar clinical results as the Latarjet procedure, but glenoid bone grafting may have several potential advantages over the Latarjet procedure, including an ability to accommodate a greater degree of glenoid bone loss and reduced risk of convulsion-related graft failure in patients. Moreover, there is no internal fixation material in the glenoid bone grafting and bone absorption is less. Glenoid bone grafting is more anatomical without damaging the sternoclavicular arch structure. Finally, the operating time for glenoid bone grafting is short when compared with that of Latarjet surgery[23], and upper one-third subscapular augmentation further compresses the contact between the bone graft and the glenoid, which is conducive to bone healing without affecting rotation of the shoulder.

Hill-Sachs injuries have recently received increased attention. The mechanism underlying Hill-Sachs injuries is a collision between the anterior-inferior aspect of the scapular glenoid and the posterior-superior aspect of the humeral head during anterior dislocation of the shoulder, resulting in a bony defect of the posterior-superior aspect of the humeral head and the anterior-inferior aspect of the scapular glenoid. Injury to the labrum or even a bony defect frequently coexist with Hill-Sachs injuries [24]. The most commonly used method for this type of injury is the remplissage procedure. It is believed that the remplissage procedure can effectively limit engagement of the glenoid and humeral head during external rotation and abduction of the shoulder, thereby reducing the occurrence of anterior instability of the humeral head. It has been reported that the remplissage procedure will cause limited external rotation of the shoulder [25]. Whether or not the bone graft was implanted, we used arthroscopic composite partial upper one-third subscapular augmentation instead of the remplissage procedure, which also achieved satisfactory results without affecting recovery of shoulder function. Historical surgery, such as the Putty-Platt and Magnuson-Stack procedures, involves entire tendon shortening, thus interfering with external rotation. In contrast, our method only involved the stretched portion of the subscapularis tendon upper border, thus leaving the middle and inferior subscapularis in the normal, anatomic position [26,27].

Therefore, the effect of arthroscopy with upper one-third subscapularis augmentation in the treatment of recurrent anterior shoulder instability is satisfactory, and compared with simple labrum repair, this method is more reliable, the recurrence rate is lower, and rotation of the shoulder is not affected. In addition, the postoperative rehabilitation process is equally important. It is necessary to resume physical activity when the shoulder joint is fully restored to the normal ROM; the entire rehabilitation cycle lasts approximately 6 mo.

CONCLUSION

Arthroscopy combined with subscapularis upper one-third tenodesis was shown to be effective for treatment of recurrent anterior shoulder instability independent of the size of the glenoid bone defect, enhanced the anterior stability of the shoulder, and did not affect the postoperative range of motion of the affected limb. This method is simple, and the selection of patients, proficiency of the surgical procedure, and postoperative functional exercises are the key to the success of the operation.

ARTICLE HIGHLIGHTS

Research background

Recurrent anterior shoulder instability is a common traumatic injury, the main clinical manifestation of which is recurrent anteroinferior dislocation of the humeral head. The current follow-up study showed that the effect of arthroscopic Bankart repair is unreliable.

Research motivation

To evaluate the clinical efficacy of arthroscopy with subscapularis upper one-third tenodesis in the treatment of anterior shoulder instability.

Research objectives

To seek a method to enhance anterior stability and reduce the recurrence rate.

Research methods

Patients with a glenoid defect < 20% underwent an arthroscopic Bankart repair combined with a subscapularis upper one-third tenodesis. Arthroscopic iliac crest bone autograft for the patients with a glenoid defect > 20% underwent an arthroscopic iliac crest bone autograft combined with a subscapularis upper one-third tenodesis. All patients were assessed with Rowe and Constant scores.

Research results

The average shoulder forward flexion angle was $163.6^\circ \pm 8.3^\circ$ and $171.8^\circ \pm 3.6^\circ$ preoperatively and at the last follow-up evaluation, respectively. When abduction was 90° , the average external rotation angle was $68.4^\circ \pm 13.6^\circ$ and $88.5^\circ \pm 6.2^\circ$, respectively. The mean Rowe scores preoperatively and at the last follow-up evaluation were 32.6 ± 3.2 and 95.2 ± 2.2 , respectively ($P < 0.05$). The mean Constant scores were 75.4 ± 3.5 and 95.8 ± 3.3 , respectively ($P < 0.05$). No postoperative dislocations were recorded by the end of the follow-up period.

Research conclusions

Arthroscopy combined with subscapularis upper one-third tenodesis was shown to be effective for

treatment of recurrent anterior shoulder instability independent of the size of the glenoid bone defect, enhanced the anterior stability of the shoulder, and did not affect the postoperative range of motion of the affected limb. This method is simple, and the selection of patients, proficiency of the surgical procedure, and postoperative functional exercises are the key to the success of the operation.

Research perspectives

We decided not only to repair the torn labrum or reconstruct the bony structure, but also to enhance the anterior shoulder stability with subscapularis tenodesis augmentation in the treatment of recurrent anterior shoulder instability.

FOOTNOTES

Author contributions: An BJ and Wang FL wrote the manuscript; An BJ and Wang YT collected data for review; all authors treated patients; all authors read and approved the final version of the manuscript.

Institutional review board statement: The study was reviewed and approved by The Third Medical Center of the Chinese People's Liberation Army General Hospital Medical Ethics Committee (approval No. KY2021-034).

Informed consent statement: All study participants, or their legal guardian, provided informed written consent prior to study enrollment.

Conflict-of-interest statement: All the authors report no relevant conflicts of interest for this article.

Data sharing statement: No additional data are available.

Open-Access: This article is an open-access article that was selected by an in-house editor and fully peer-reviewed by external reviewers. It is distributed in accordance with the Creative Commons Attribution NonCommercial (CC BY-NC 4.0) license, which permits others to distribute, remix, adapt, build upon this work non-commercially, and license their derivative works on different terms, provided the original work is properly cited and the use is non-commercial. See: <https://creativecommons.org/licenses/by-nc/4.0/>

Country/Territory of origin: China

ORCID number: Bai-Jing An 0000-0002-3434-2813; Feng-Lin Wang 0000-0002-9522-8715; Yao-Ting Wang 0000-0002-1512-6285; Zhe Zhao 0000-0003-3300-4756; Ming-Xin Wang 0000-0002-3269-6482; Geng-Yan Xing 0000-0003-3997-4964.

S-Editor: Gao CC

L-Editor: Kerr C

P-Editor: Zhang YL

REFERENCES

- 1 Shields E, Mirabelli M, Amsdell S, Thorsness R, Goldblatt J, Maloney M, Voloshin I. Functional and imaging outcomes of arthroscopic simultaneous rotator cuff repair and bankart repair after shoulder dislocations. *Am J Sports Med* 2014; **42**: 2614-2620 [PMID: 25261085 DOI: 10.1177/0363546514550993]
- 2 Willemot LB, Elhassan BT, Verborgt O. Bony Reconstruction of the Anterior Glenoid Rim. *J Am Acad Orthop Surg* 2018; **26**: e207-e218 [PMID: 29659379 DOI: 10.5435/JAAOS-D-16-00649]
- 3 Fedorka CJ, Mulcahey MK. Recurrent anterior shoulder instability: a review of the Latarjet procedure and its postoperative rehabilitation. *Phys Sportsmed* 2015; **43**: 73-79 [PMID: 25598036 DOI: 10.1080/00913847.2015.1005543]
- 4 Flinkkilä T, Sirniö K. Open Latarjet procedure for failed arthroscopic Bankart repair. *Orthop Traumatol Surg Res* 2015; **101**: 35-38 [PMID: 25555805 DOI: 10.1016/j.otsr.2014.11.005]
- 5 Argintar E, Heckmann N, Wang L, Tibone JE, Lee TQ. The biomechanical effect of shoulder remplissage combined with Bankart repair for the treatment of engaging Hill-Sachs lesions. *Knee Surg Sports Traumatol Arthrosc* 2016; **24**: 585-592 [PMID: 24912574 DOI: 10.1007/s00167-014-3092-4]
- 6 Maiotti M, Massoni C. Arthroscopic augmentation with subscapularis tendon in anterior shoulder instability with capsulolabral deficiency. *Arthrosc Tech* 2013; **2**: e303-e310 [PMID: 24266004 DOI: 10.1016/j.eats.2013.04.005]
- 7 Shibata H, Gotoh M, Mitsui Y, Kai Y, Nakamura H, Kanazawa T, Okawa T, Higuchi F, Shirahama M, Shiba N. Risk factors for shoulder re-dislocation after arthroscopic Bankart repair. *J Orthop Surg Res* 2014; **9**: 53 [PMID: 24993404 DOI: 10.1186/s13018-014-0053-z]
- 8 Neoral P, Holibka R, Kalina R, Mlčúchová D, Gallo J. [Arthroscopic stabilisation of the shoulder. Risk factors for its failure]. *Acta Chir Orthop Traumatol Cech* 2014; **81**: 51-56 [PMID: 24755057]
- 9 Klungsøyr PJ, Guldal F, Vagstad T, Klungsøyr JA. A new subscapular sling operation to stabilize the shoulder. A cadaver study. *J Exp Orthop* 2015; **2**: 12 [PMID: 26914880 DOI: 10.1186/s40634-015-0028-y]
- 10 Taverna E, D'Ambrosi R, Perfetti C, Garavaglia G. Arthroscopic bone graft procedure for anterior inferior glenohumeral

- instability. *Arthrosc Tech* 2014; **3**: e653-e660 [PMID: [25685669](#) DOI: [10.1016/j.eats.2014.08.002](#)]
- 11 **Gamulin A**, Dayer R, Lübbecke A, Miozzari H, Hoffmeyer P. Primary open anterior shoulder stabilization: a long-term, retrospective cohort study on the impact of subscapularis muscle alterations on recurrence. *BMC Musculoskelet Disord* 2014; **15**: 45 [PMID: [24555837](#) DOI: [10.1186/1471-2474-15-45](#)]
- 12 **Maiotti M**, Russo R, Zanini A, Schröter S, Massoni C, Bianchedi D. Arthroscopic Bankart repair and subscapularis augmentation: an alternative technique treating anterior shoulder instability with bone loss. *J Shoulder Elbow Surg* 2016; **25**: 898-906 [PMID: [26613984](#) DOI: [10.1016/j.jse.2015.09.025](#)]
- 13 **Russo R**, Maiotti M, Taverna E. Arthroscopic bone graft procedure combined with arthroscopic subscapularis augmentation (ASA) for recurrent anterior instability with glenoid bone defect: a cadaver study. *J Exp Orthop* 2018; **5**: 5 [PMID: [29484517](#) DOI: [10.1186/s40634-018-0121-0](#)]
- 14 **Maiotti M**, Massoni C, Russo R, Schroter S, Zanini A, Bianchedi D. Arthroscopic Subscapularis Augmentation of Bankart Repair in Chronic Anterior Shoulder Instability With Bone Loss Less Than 25% and Capsular Deficiency: Clinical Multicenter Study. *Arthroscopy* 2017; **33**: 902-909 [PMID: [27876488](#) DOI: [10.1016/j.arthro.2016.09.008](#)]
- 15 **Itoi E**, Yamamoto N, Kurokawa D, Sano H. Bone loss in anterior instability. *Curr Rev Musculoskelet Med* 2013; **6**: 88-94 [PMID: [23297102](#) DOI: [10.1007/s12178-012-9154-7](#)]
- 16 **Burkhart SS**, De Beer JF. Traumatic glenohumeral bone defects and their relationship to failure of arthroscopic Bankart repairs: significance of the inverted-pear glenoid and the humeral engaging Hill-Sachs lesion. *Arthroscopy* 2000; **16**: 677-694 [PMID: [11027751](#) DOI: [10.1053/jars.2000.17715](#)]
- 17 **Malahias MA**, Chytas D, Raoulis V, Chronopoulos E, Brilakis E, Antonogiannakis E. Iliac Crest Bone Grafting for the Management of Anterior Shoulder Instability in Patients with Glenoid Bone Loss: a Systematic Review of Contemporary Literature. *Sports Med Open* 2020; **6**: 12 [PMID: [32048101](#) DOI: [10.1186/s40798-020-0240-x](#)]
- 18 **Jeong JY**, Yoo YS, Kim T. Arthroscopic Iliac Bone Block Augmentation for Glenoid Reconstruction: Transglenoid Fixation Technique Using an All-Suture Anchor. *Arthrosc Tech* 2020; **9**: e351-e356 [PMID: [32226742](#) DOI: [10.1016/j.eats.2019.11.009](#)]
- 19 **Nzeako O**, Bakti N, Bawale R, Singh B. Bone block procedures for glenohumeral joint instability. *J Clin Orthop Trauma* 2019; **10**: 231-235 [PMID: [30828183](#) DOI: [10.1016/j.jcot.2018.10.002](#)]
- 20 **Ranalletta M**, Tanoira I, Bertona A, Maignon G, Bongiovanni S, Rossi LA. Autologous Tricortical Iliac Bone Graft for Failed Latarjet Procedures. *Arthrosc Tech* 2019; **8**: e283-e289 [PMID: [31019886](#) DOI: [10.1016/j.eats.2018.11.002](#)]
- 21 **Hurley ET**, Jamal MS, Ali ZS, Montgomery C, Pauzenberger L, Mullett H. Long-term outcomes of the Latarjet procedure for anterior shoulder instability: a systematic review of studies at 10-year follow-up. *J Shoulder Elbow Surg* 2019; **28**: e33-e39 [PMID: [30545784](#) DOI: [10.1016/j.jse.2018.08.028](#)]
- 22 **Moroder P**, Schulz E, Wierer G, Auffarth A, Habermeyer P, Resch H, Tauber M. Neer Award 2019: Latarjet procedure vs. iliac crest bone graft transfer for treatment of anterior shoulder instability with glenoid bone loss: a prospective randomized trial. *J Shoulder Elbow Surg* 2019; **28**: 1298-1307 [PMID: [31129017](#) DOI: [10.1016/j.jse.2019.03.035](#)]
- 23 **Hurley ET**, Matache BA, Wong I, Itoi E, Strauss EJ, Delaney RA, Neyton L, Athwal GS, Pauzenberger L, Mullett H, Jazrawi LM; Anterior Shoulder Instability International Consensus Group. Anterior Shoulder Instability Part II-Latarjet, Remplissage, and Glenoid Bone-Grafting-An International Consensus Statement. *Arthroscopy* 2022; **38**: 224-233.e6 [PMID: [34332052](#) DOI: [10.1016/j.arthro.2021.07.023](#)]
- 24 **Provencher MT**, Frank RM, Leclerc LE, Metzger PD, Ryu JJ, Bernhardtson A, Romeo AA. The Hill-Sachs lesion: diagnosis, classification, and management. *J Am Acad Orthop Surg* 2012; **20**: 242-252 [PMID: [22474094](#) DOI: [10.5435/JAAOS-20-04-242](#)]
- 25 **Brilakis E**, Mataragas E, Deligeorgis A, Maniatis V, Antonogiannakis E. Midterm outcomes of arthroscopic remplissage for the management of recurrent anterior shoulder instability. *Knee Surg Sports Traumatol Arthrosc* 2016; **24**: 593-600 [PMID: [24488221](#) DOI: [10.1007/s00167-014-2848-1](#)]
- 26 **Maiotti M**, Russo R, Zanini A, Castricini R, Castellarin G, Schröter S, Massoni C, Savoie FH 3rd. Bankart Repair With Subscapularis Augmentation in Athletes With Shoulder Hyperlaxity. *Arthroscopy* 2021; **37**: 2055-2062 [PMID: [33581299](#) DOI: [10.1016/j.arthro.2021.01.062](#)]
- 27 **Russo R**, Maiotti M, Cozzolino A, Della Rotonda G, Guastafierro A, Massoni C, Viglione S. Arthroscopic Iliac Crest Bone Allograft Combined With Subscapularis Upper-Third Tenodesis Shows a Low Recurrence Rate in the Treatment of Recurrent Anterior Shoulder Instability Associated With Critical Bone Loss. *Arthroscopy* 2021; **37**: 824-833 [PMID: [33359157](#) DOI: [10.1016/j.arthro.2020.11.037](#)]



Published by **Baishideng Publishing Group Inc**
7041 Koll Center Parkway, Suite 160, Pleasanton, CA 94566, USA

Telephone: +1-925-3991568

E-mail: bpgoffice@wjgnet.com

Help Desk: <https://www.f6publishing.com/helpdesk>

<https://www.wjgnet.com>

