

World Journal of *Clinical Cases*

World J Clin Cases 2022 August 26; 10(24): 8432-8807



Contents

Thrice Monthly Volume 10 Number 24 August 26, 2022

EDITORIAL

- 8432** Evolution of *World Journal of Clinical Cases* over the past 5 years
Muthu S

OPINION REVIEW

- 8436** NF- κ B: A novel therapeutic pathway for gastroesophageal reflux disease?
Zhang ML, Ran LQ, Wu MJ, Jia QC, Qin ZM, Peng YG

MINIREVIEWS

- 8443** Obligate aerobic, gram-positive, weak acid-fast, nonmotile bacilli, *Tsukamurella tyrosinosolvens*: Minireview of a rare opportunistic pathogen
Usuda D, Tanaka R, Suzuki M, Shimozawa S, Takano H, Hotchi Y, Tokunaga S, Osugi I, Katou R, Ito S, Mishima K, Kondo A, Mizuno K, Takami H, Komatsu T, Oba J, Nomura T, Sugita M
- 8450** Diffusion tensor imaging pipeline measures of cerebral white matter integrity: An overview of recent advances and prospects
Safri AA, Nassir CMNCM, Iman IN, Mohd Taib NH, Achuthan A, Mustapha M
- 8463** Graft choices for anterolateral ligament knee reconstruction surgery: Current concepts
Chalidis B, Pitsilos C, Kitridis D, Givissis P
- 8474** Overview of the anterolateral complex of the knee
Garcia-Mansilla I, Zicaro JP, Martinez EF, Astoul J, Yacuzzi C, Costa-Paz M
- 8482** Complication of lengthening and the role of post-operative care, physical and psychological rehabilitation among fibula hemimelia
Salimi M, Sarallah R, Javanshir S, Mirghaderi SP, Salimi A, Khanzadeh S

ORIGINAL ARTICLE

Clinical and Translational Research

- 8490** Pyroptosis-related genes play a significant role in the prognosis of gastric cancer
Guan SH, Wang XY, Shang P, Du QC, Li MZ, Xing X, Yan B

Retrospective Study

- 8506** Effects of propofol combined with lidocaine on hemodynamics, serum adrenocorticotrophic hormone, interleukin-6, and cortisol in children
Shi S, Gan L, Jin CN, Liu RF
- 8514** Correlation analysis of national elite Chinese male table tennis players' shoulder proprioception and muscle strength
Shang XD, Zhang EM, Chen ZL, Zhang L, Qian JH

- 8525** Clinical value of contrast-enhanced ultrasound in early diagnosis of small hepatocellular carcinoma (≤ 2 cm)

Mei Q, Yu M, Chen Q

- 8535** Identification of predictive factors for post-transarterial chemoembolization liver failure in hepatocellular carcinoma patients: A retrospective study

Yuan M, Chen TY, Chen XR, Lu YF, Shi J, Zhang WS, Ye C, Tang BZ, Yang ZG

- 8547** Clinical significance of half-hepatic blood flow occlusion technology in patients with hepatocellular carcinoma with cirrhosis

Liu D, Fang JM, Chen XQ

- 8556** Which octogenarian patients are at higher risk after cholecystectomy for symptomatic gallstone disease? A single center cohort study

D'Acapito F, Solaini L, Di Pietrantonio D, Tauceri F, Mirarchi MT, Antelmi E, Flamini F, Amato A, Framarini M, Ercolani G

Clinical Trials Study

- 8568** Computed tomography combined with gastroscopy for assessment of pancreatic segmental portal hypertension

Wang YL, Zhang HW, Lin F

Observational Study

- 8578** Psychological needs of parents of children with complicated congenital heart disease after admitting to pediatric intensive care unit: A questionnaire study

Zhu JH, Jin CD, Tang XM

Prospective Study

- 8587** Quantitative differentiation of malignant and benign thyroid nodules with multi-parameter diffusion-weighted imaging

Zhu X, Wang J, Wang YC, Zhu ZF, Tang J, Wen XW, Fang Y, Han J

Randomized Controlled Trial

- 8599** Application of unified protocol as a transdiagnostic treatment for emotional disorders during COVID-19: An internet-delivered randomized controlled trial

Yan K, Yusufi MH, Nazari N

- 8615** High-flow nasal cannula oxygen therapy during anesthesia recovery for older orthopedic surgery patients: A prospective randomized controlled trial

Li XN, Zhou CC, Lin ZQ, Jia B, Li XY, Zhao GF, Ye F

SYSTEMATIC REVIEWS

- 8625** Assessment tools for differential diagnosis of neglect: Focusing on egocentric neglect and allocentric neglect

Lee SH, Lim BC, Jeong CY, Kim JH, Jang WH

CASE REPORT

- 8634** Exome analysis for Cronkhite-Canada syndrome: A case report
Li ZD, Rong L, He YJ, Ji YZ, Li X, Song FZ, Li XA
- 8641** Discrepancy between non-invasive prenatal testing result and fetal karyotype caused by rare confined placental mosaicism: A case report
Li Z, Lai GR
- 8648** Paroxysmal speech disorder as the initial symptom in a young adult with anti-N-methyl-D-aspartate receptor encephalitis: A case report
Hu CC, Pan XL, Zhang MX, Chen HF
- 8656** Anesthetics management of a renal angiomyolipoma using pulse pressure variation and non-invasive cardiac output monitoring: A case report
Jeon WJ, Shin WJ, Yoon YJ, Park CW, Shim JH, Cho SY
- 8662** Traumatic giant cell tumor of rib: A case report
Chen YS, Kao HW, Huang HY, Huang TW
- 8667** Analysis of two naval pilots' ejection injuries: Two case reports
Zeng J, Liu XP, Yi JC, Lu X, Liu DD, Jiang YQ, Liu YB, Tian JQ
- 8673** Beware of the DeBakey type I aortic dissection hidden by ischemic stroke: Two case reports
Chen SQ, Luo WL, Liu W, Wang LZ
- 8679** Unilateral lichen planus with Blaschko line distribution: A case report
Dong S, Zhu WJ, Xu M, Zhao XQ, Mou Y
- 8686** Clinical features and progress of ischemic gastritis with high fatalities: Seven case reports
Shionoya K, Sasaki A, Moriya H, Kimura K, Nishino T, Kubota J, Sumida C, Tasaki J, Ichita C, Makazu M, Masuda S, Koizumi K, Kawachi J, Tsukiyama T, Kako M
- 8695** Retinoblastoma in an older child with secondary glaucoma as the first clinical presenting symptom: A case report
Zhang Y, Tang L
- 8703** Recurrent herpes zoster in a rheumatoid arthritis patient treated with tofacitinib: A case report and review of the literature
Lin QX, Meng HJ, Pang YY, Qu Y
- 8709** Intra-abdominal ectopic bronchogenic cyst with a mucinous neoplasm harboring a *GNAS* mutation: A case report
Murakami T, Shimizu H, Yamazaki K, Nojima H, Usui A, Kosugi C, Shuto K, Obi S, Sato T, Yamazaki M, Koda K
- 8718** Effects of intravascular photobiomodulation on motor deficits and brain perfusion images in intractable myasthenia gravis: A case report
Lan CH, Wu YC, Chiang CC, Chang ST

- 8728** Spontaneous acute epidural hematoma secondary to skull and dural metastasis of hepatocellular carcinoma: A case report
Lv GZ, Li GC, Tang WT, Zhou D, Yang Y
- 8735** Malignant melanotic nerve sheath tumors in the spinal canal of psammomatous and non-psammomatous type: Two case reports
Yeom JA, Song YS, Lee IS, Han IH, Choi KU
- 8742** When should endovascular gastrointestinal anastomosis transection Glissonean pedicle not be used in hepatectomy? A case report
Zhao J, Dang YL
- 8749** VARS2 gene mutation leading to overall developmental delay in a child with epilepsy: A case report
Wu XH, Lin SZ, Zhou YQ, Wang WQ, Li JY, Chen QD
- 8755** Junctional bradycardia in a patient with COVID-19: A case report
Aedh AI
- 8761** Application of 3 dimension-printed injection-molded polyether ether ketone lunate prosthesis in the treatment of stage III Kienböck's disease: A case report
Yuan CS, Tang Y, Xie HQ, Liang TT, Li HT, Tang KL
- 8768** High scored thyroid storm after stomach cancer perforation: A case report
Baik SM, Pae Y, Lee JM
- 8775** Cholecystitis-an uncommon complication following thoracic duct embolization for chylothorax: A case report
Dung LV, Hien MM, Tra My TT, Luu DT, Linh LT, Duc NM
- 8782** Endometrial squamous cell carcinoma originating from the cervix: A case report
Shu XY, Dai Z, Zhang S, Yang HX, Bi H
- 8788** Type 2 autoimmune pancreatitis associated with severe ulcerative colitis: Three case reports
Ghali M, Bensted K, Williams DB, Ghaly S
- 8797** Diffuse uterine leiomyomatosis: A case report and review of literature
Ren HM, Wang QZ, Wang JN, Hong GJ, Zhou S, Zhu JY, Li SJ

LETTER TO THE EDITOR

- 8805** Comment on "Posterior reversible encephalopathy syndrome in a patient with metastatic breast cancer: A case report"
Kunić S, Ibrahimagić OČ, Kojić B, Džananović D

ABOUT COVER

Editorial Board Member of *World Journal of Clinical Cases*, Ahmed Mohamed Ahmed Al-Emam, PhD, Associate Professor, Department of Pathology, King Khalid University, Abha 62521, Saudi Arabia. amalemam@kku.edu.sa

AIMS AND SCOPE

The primary aim of *World Journal of Clinical Cases* (WJCC, *World J Clin Cases*) is to provide scholars and readers from various fields of clinical medicine with a platform to publish high-quality clinical research articles and communicate their research findings online.

WJCC mainly publishes articles reporting research results and findings obtained in the field of clinical medicine and covering a wide range of topics, including case control studies, retrospective cohort studies, retrospective studies, clinical trials studies, observational studies, prospective studies, randomized controlled trials, randomized clinical trials, systematic reviews, meta-analysis, and case reports.

INDEXING/ABSTRACTING

The WJCC is now abstracted and indexed in Science Citation Index Expanded (SCIE, also known as SciSearch®), Journal Citation Reports/Science Edition, Current Contents®/Clinical Medicine, PubMed, PubMed Central, Scopus, Reference Citation Analysis, China National Knowledge Infrastructure, China Science and Technology Journal Database, and Superstar Journals Database. The 2022 Edition of Journal Citation Reports® cites the 2021 impact factor (IF) for WJCC as 1.534; IF without journal self cites: 1.491; 5-year IF: 1.599; Journal Citation Indicator: 0.28; Ranking: 135 among 172 journals in medicine, general and internal; and Quartile category: Q4. The WJCC's CiteScore for 2021 is 1.2 and Scopus CiteScore rank 2021: General Medicine is 443/826.

RESPONSIBLE EDITORS FOR THIS ISSUE

Production Editor: *Ying-Yi Yuan*; Production Department Director: *Xu Guo*; Editorial Office Director: *Jin-Lei Wang*.

NAME OF JOURNAL

World Journal of Clinical Cases

ISSN

ISSN 2307-8960 (online)

LAUNCH DATE

April 16, 2013

FREQUENCY

Thrice Monthly

EDITORS-IN-CHIEF

Bao-Gan Peng, Jerzy Tadeusz Chudek, George Kontogeorgos, Maurizio Serati, Ja Hyeon Ku

EDITORIAL BOARD MEMBERS

<https://www.wjgnet.com/2307-8960/editorialboard.htm>

PUBLICATION DATE

August 26, 2022

COPYRIGHT

© 2022 Baishideng Publishing Group Inc

INSTRUCTIONS TO AUTHORS

<https://www.wjgnet.com/bpg/gerinfo/204>

GUIDELINES FOR ETHICS DOCUMENTS

<https://www.wjgnet.com/bpg/GerInfo/287>

GUIDELINES FOR NON-NATIVE SPEAKERS OF ENGLISH

<https://www.wjgnet.com/bpg/gerinfo/240>

PUBLICATION ETHICS

<https://www.wjgnet.com/bpg/GerInfo/288>

PUBLICATION MISCONDUCT

<https://www.wjgnet.com/bpg/gerinfo/208>

ARTICLE PROCESSING CHARGE

<https://www.wjgnet.com/bpg/gerinfo/242>

STEPS FOR SUBMITTING MANUSCRIPTS

<https://www.wjgnet.com/bpg/GerInfo/239>

ONLINE SUBMISSION

<https://www.f6publishing.com>



Retinoblastoma in an older child with secondary glaucoma as the first clinical presenting symptom: A case report

Ying Zhang, Li Tang

Specialty type: Ophthalmology

Provenance and peer review:

Unsolicited article; Externally peer reviewed.

Peer-review model: Single blind

Peer-review report's scientific quality classification

Grade A (Excellent): 0

Grade B (Very good): B

Grade C (Good): C

Grade D (Fair): 0

Grade E (Poor): 0

P-Reviewer: Di Meglio L, Italy;
Salimi M, Iran

Received: February 23, 2022

Peer-review started: February 23, 2022

First decision: March 24, 2022

Revised: April 4, 2022

Accepted: July 20, 2022

Article in press: July 20, 2022

Published online: August 26, 2022



Ying Zhang, Li Tang, Department of Ophthalmology, West China Hospital, Sichuan University, Chengdu 610041, Sichuan Province, China

Corresponding author: Li Tang, PhD, Doctor, Professor, Department of Ophthalmology, West China Hospital, Sichuan University, No. 37 Guoxue Lane, Chengdu 610041, Sichuan Province, China. tangli-1a@163.com

Abstract

BACKGROUND

Retinoblastoma (Rb) is primarily found in infants or young children. The most common primary presenting sign of Rb is leukocoria. Rb is very rare in children who are 10 years old or older. Timely and correct diagnosis as well as proper treatment are the key factors affecting the prognosis of Rb.

CASE SUMMARY

A 10-year-old girl with symptoms of vision loss, redness, swelling and pain in the right eye for 2 mo was admitted to our Department of Ophthalmology. The visual acuity of the right eye was graded as hand movement. The intraocular pressure of the eye was 46.9 mmHg. No substantial space-occupying lesion or characteristic calcified plaque was found in the eye. The patient underwent anterior chamber irrigation under general anesthesia on the same day of admission, and 2 mL of irrigation solution was saved for pathological examination. Histopathological examination of the anterior chamber fluid revealed cancer cells. A diagnosis of Rb with masquerade syndrome was made. The patient underwent enucleation followed by 6 rounds of systematic chemotherapy. A follow-up examination almost 9 years later found no relapse of Rb.

CONCLUSION

For older pediatric patients who have secondary glaucoma and uveitis symptoms without a clear cause of the disease and have no space-occupying lesion found by imaging examination, aqueous humor or vitreous humor examination is recommended for timely and correct diagnosis and appropriate treatment.

Key Words: Retinoblastoma; Secondary glaucoma; Uveitis; Masquerade syndrome; Older children; Case report

©The Author(s) 2022. Published by Baishideng Publishing Group Inc. All rights reserved.

Core Tip: Retinoblastoma (Rb) is most commonly found in young pediatric patients, and is very rare in patients who are 10 years old or older. Here, we report a case of Rb in a 10-year-old girl with secondary glaucoma and other uveitis symptoms as clinical presenting signs. No obvious space-occupying lesions were found in the eye by imaging examination. However, anterior chamber fluid examination found cancer cells and was decisive in the diagnosis of Rb. This suggests the necessity of aqueous humor or vitreous humor examination in the diagnosis of Rb with atypical clinical symptoms.

Citation: Zhang Y, Tang L. Retinoblastoma in an older child with secondary glaucoma as the first clinical presenting symptom: A case report. *World J Clin Cases* 2022; 10(24): 8695-8702

URL: <https://www.wjgnet.com/2307-8960/full/v10/i24/8695.htm>

DOI: <https://dx.doi.org/10.12998/wjcc.v10.i24.8695>

INTRODUCTION

Retinoblastoma (Rb) is a type of cancer mostly found in infants or young children and can present unilaterally or bilaterally. It is the most common pediatric eye cancer and primarily originates in the eye, with an incidence of 1:16000 to 1:18000 in newborns[1,2]. It has been reported that two-thirds of Rb is found in patients younger than 3 years old. The incidence of Rb in children 5 years old or older is less than 5%, and it is very rare in children 10 years old or older[3].

Currently, the survival rate of Rb patients in developed countries has reached 95%, while it is only 50% worldwide. In addition to the difference in medical conditions and economic conditions in different countries, misdiagnosis and cancer metastasis were the main reasons for the death of patients. Therefore, timely and correct diagnosis is critical for the prognosis of patients.

The most common clinical symptom of Rb to present first is leukocoria. It represents 90% of the first clinical symptoms of Rb, followed by strabismus, redness and pain, proptosis and other signs[4]. However, in addition to the typical symptoms, Rb can also present with other atypical symptoms, such as conjunctival edema, pseudohypopyon in the anterior chamber, pseudocellulitis of the orbit and secondary intraocular hypertension, which may result in the wrong diagnosis and an inappropriate treatment plan. Current treatment of Rb includes cryotherapy, laser photocoagulation, systemic chemotherapy, enucleation, and local chemotherapy through intraocular, peribulbar and ophthalmic artery interventional approaches. In the present study, we reported a case of Rb in a 10-year-old girl with secondary glaucoma and uveitis symptoms as the presenting clinical signs. The diagnosis and treatment procedures were described and discussed.

CASE PRESENTATION

Chief complaints

A 10-year-old girl was admitted to the Department of Ophthalmology at West China Hospital, Sichuan University, on December 10, 2012, due to vision loss accompanied by redness, swelling, and pain in the right eye.

History of present illness

The patient started to suffer gradual vision loss with redness, swelling, and pain in the right eye 2 mo prior to hospital admission and was diagnosed with uveitis and secondary glaucoma in a local hospital. The prescribed treatment was dexamethasone ophthalmic, Azopt ophthalmic and atropine eye ointment. The symptoms were not relieved after treatment. The patient denied fever, headache, coughing, ulcer, skin diseases or arthropathy during the doctor visit.

History of past illness

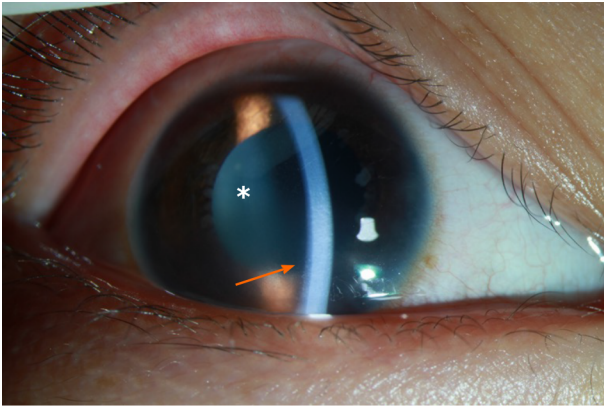
There was no remarkable illness history.

Personal and family history

There was no remarkable personal or family history.

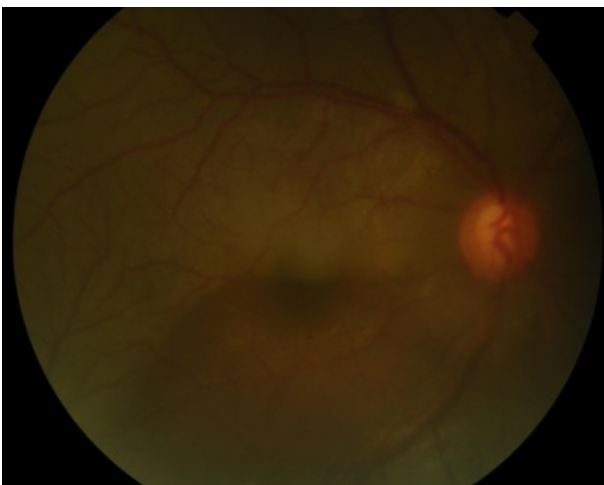
Physical examination

At the time of hospitalization, the visual acuity of the patient's right eye was hand movement; the visual acuity of the left eye was 20/20. Intraocular pressure of the right eye was 46.9 mmHg, and the left eye was 19.8 mmHg (1 mmHg = 0.133 kPa). The result of the ophthalmological examination was as follows: mutton-fat KP grading: ++; anterior chamber cell grading: +++. Multiple white, round nodules were



DOI: 10.12998/wjcc.v10.i24.8695 Copyright ©The Author(s) 2022.

Figure 1 Image of the anterior chamber in the right eye on Day 1 after hospitalization. The arrow shows corneal edema with haze. The depth of the anterior chamber was normal. Mutton-fat KP: ++ (arrow); anterior chamber cells: +++ (asterisk).



DOI: 10.12998/wjcc.v10.i24.8695 Copyright ©The Author(s) 2022.

Figure 2 Color image of the fundus of the right eye. The vitreous body was opaque, the C/D ratio of the optic disk was 0.55, retinal edema with bluish color, and the superior temporal retina was pale with occluded, line-like vessels.

found on the right eye near the pupillary margin on the surface of the iris (Figure 1). The dilated pupil size of the right eye was 5 mm with a slower response to light. The lens was clear, and the vitreous body was opaque. The optic cup/optic disc (C/D) ratio was approximately 0.55. Retinal edema with a bluish color was found in the right eye. The superior temporal retina was pale, with a portion of the vessels being occluded and line-like (Figure 2). No abnormalities were found in the anterior segment or the fundus of the left eye.

Laboratory examinations

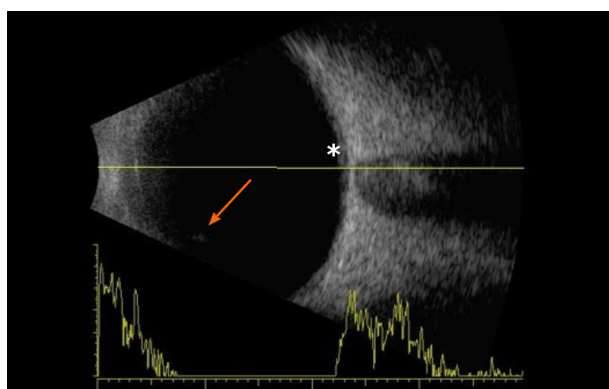
The white blood cell count was $13.02 \times 10^9/L$, and the percentage of segmented neutrophils was 65.8%.

Imaging examinations

The results of the B-mode ultrasound of the eyes suggested vitreous opacity and retinal edema in the right eye. No obvious space-occupying lesion was found intraocularly in the right eye (Figure 3). Ultrasound biomicroscopy examination found multiple ciliary body cysts (Figure 4). The results of computerized tomography (CT) scanning in the axial view and coronal view suggested normal findings in terms of eyeball shape. No space-occupying, intraocular or intraorbital lesions were found (Figure 5).

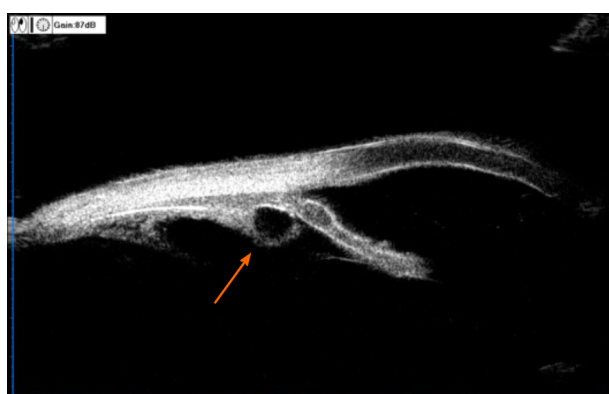
Immunocytochemical examinations

The pathological examination result was as follows: Cancer cells were seen by the liquid-based smear of the aqueous humor of the right eye. Immunocytochemical staining results found CD56 (+), Syna (+), CgA (+, but sporadic), PCK (-), Des (-), LCA (-), and 70% in terms of Ki-67 positivity.



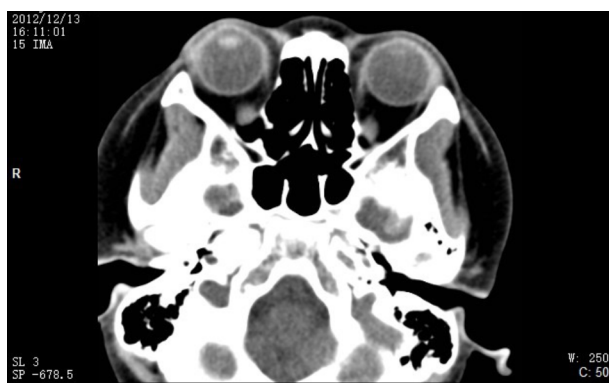DOI: 10.12998/wjcc.v10.i24.8695 Copyright ©The Author(s) 2022.

Figure 3 B-ultrasound image of the right eye. The images show the opacity of the vitreous body (arrow) and retinal edema (asterisk).



DOI: 10.12998/wjcc.v10.i24.8695 Copyright ©The Author(s) 2022.

Figure 4 Image of ultrasound biomicroscopy examination of the right eye. The result suggested multiple ciliary body cysts (arrow).



DOI: 10.12998/wjcc.v10.i24.8695 Copyright ©The Author(s) 2022.

Figure 5 Computerized tomography image from axial view and coronal view. No intraocular, space-occupying lesions were found.

FINAL DIAGNOSIS

The preliminary diagnosis was secondary glaucoma with undetermined causes, conjunctiva hyperemia and corneal edema with haze in the right eye. The patient underwent an anterior chamber irrigation procedure under general anesthesia on the day of hospitalization. The immunocytochemical examination results revealed cancer cells in the anterior chamber fluid. The final diagnosis was stage E Rb in the right eye based on the histopathological examination result of the enucleated eye tissue and other findings.

TREATMENT

The patient first underwent anterior chamber irrigation under general anesthesia on the same day as hospital admission in the Department of Emergency Medicine. Two milliliters of irrigation solution was saved for pathological examination. After cancer cells were found in the anterior chamber fluid, the patient underwent enucleation and prosthetic eye table implantation surgery in the right eye (affected eye) under general anesthesia. The patient was then transferred to the Department of Oncology for 6 rounds of systematic chemotherapy by intravenous infusion with vincristine, etoposide, and carboplatin once a week.

OUTCOME AND FOLLOW-UP

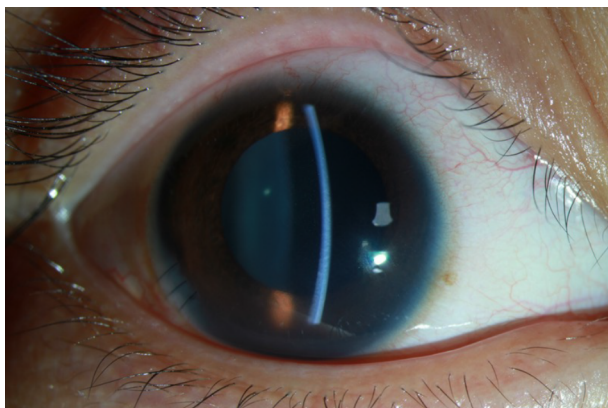
On the first day after the anterior chamber irrigation procedure, the visual acuity of the right eye (affected eye) was graded as hand movement. The intraocular pressure decreased to 13 mmHg. The cornea was clear. Anterior chamber cell grading was ++. No white nodules were found on the surface of the iris (Figure 6), and the vitreous body was opaque. Fundus examination results showed extensive retinal edema with sporadic bleeding in the macula and subretinal area (Figure 7). No abnormalities were found in the anterior segment or the fundus of the left eye. On the fourth day after the procedure, the intraocular pressure increased to 40 mmHg again. After enucleation and prosthetic eye table implantation, the histopathological examination results of the enucleated eye showed a white mass from the center of the pupil, with a size of 0.3 cm × 0.2 cm × 0.1 cm (Figure 8). No tumor cells were found in the lamina cribrosa of the optic nerve. The patient did not regularly visit the hospital for follow-up visits after chemotherapy.

In September 2021, the patient came to our department for a follow-up visit. The examination found the overall health of the right eye was as follows: a prosthetic eye was implanted into the right eye. No symptoms in the left eye were reported. Eye examination results showed that the size and morphology of both eyes were symmetric, and the position of the prosthetic eye and the eye table in the right eye was proper. The vision of the left eye was 20/63 without correction and 20/20 with correction. Examination results of the left eye were as follows: the intraocular pressure of the left eye was 14.8 mmHg; the cornea and lens were clear; the anterior chamber was clear with normal depth; and no abnormalities were found in the fundus.

DISCUSSION

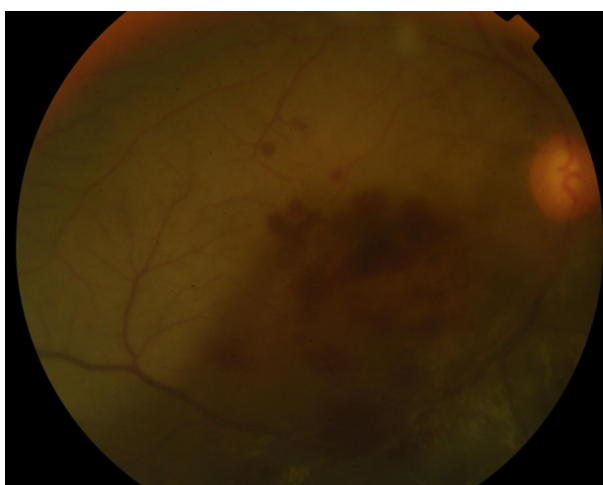
In the present case, we report a case of stage E Rb with atypical symptoms in a 10-year-old girl. More than 3 dozen Rb patients older than 10 years of age have been reported in the literature. Singh *et al*[5] reviewed 24 cases up to 2011. Domínguez-Varela *et al*[6] also described one case each in 2021. All were sporadic and, similar to our patient, unilateral[5,6]. Although the cure rate of Rb is relatively high, misdiagnosis and cancer metastasis are the main obstacles for further improvement of the prognosis of Rb. At the late stage, Rb tumor cells can invade the optic nerve and orbital tissue and metastasize to the intracranial region, circulatory system or lymph nodes, thereby endangering patients' lives[7]. The primary treatment strategy for Rb is enucleation of the affected eye(s), which results in a cure rate as high as 95%[8]. If the tumor mass breaks the sclera and spreads out of the eye or breaks the lamina cribrosa and invades the optic nerve, the tumor is considered extraocular Rb, and systematic chemotherapy and regional radiotherapy are required to treat the patient in addition to eye enucleation. At this stage, the 5-year survival rate is 55%-60%[9].

Typically, a diagnosis of Rb could be made based on the following clinical observations: the patient's age is younger than 3 years old; the presence of typical Rb symptoms, such as leukocoria and strabismus; yellow or white lesions found in the fundus with spreading lesions in the vitreous body or retina; retina detachment; and intraocular space-occupying lesions or calcified plaques found by imaging examinations. However, in the present case, the patient was 10 years old, and the first clinical symptoms were redness and pain in the right eye caused by acute high intraocular pressure, a result of uveitis. Multiple B-mode ultrasounds or CT examinations failed to find substantial space-occupying lesions or characteristic calcified plaques in the eye, which led to misdiagnosis initially. The diagnosis of malignant tumor combined with masquerade syndrome was made 2 mo after the initial doctor visit by histopathological examination of the anterior chamber fluid. Masquerade syndromes are disorders presenting with clinical symptoms similar to those of uveitis, but the disorders are malignant eye cancers. The syndromes are often seen in Rb, choroidal malignant melanoma, intraocular non-Hodgkin's lymphoma, and cancers metastasized to the eyes[10,11]. Aqueous humor or vitreous humor examination is the primary method used to distinguish masquerade syndrome from uveitis. Vitreous humor examination is superior to aqueous humor examination in regard to cancer cell screening rate. For diffuse anterior Rb, aqueous humor examination is adequate for diagnosis[12,13].



DOI: 10.12998/wjcc.v10.i24.8695 Copyright ©The Author(s) 2022.

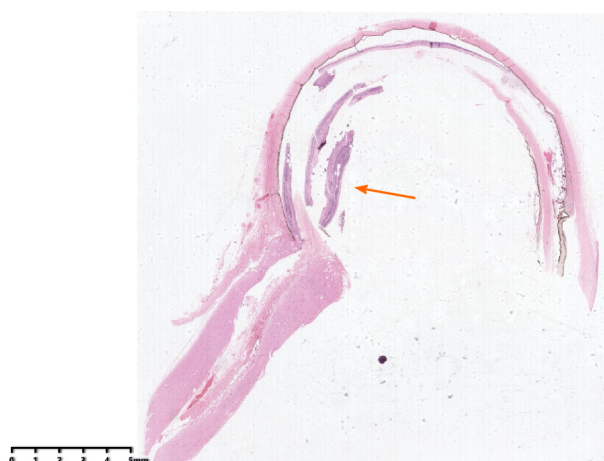
Figure 6 Image of the anterior segment of the right eye on Day 1 after the anterior chamber irrigation procedure. The cornea was clear. The depth of the anterior chamber was normal. KP: +; AR: +.



DOI: 10.12998/wjcc.v10.i24.8695 Copyright ©The Author(s) 2022.

Figure 7 Color image of the fundus of the right eye after the anterior chamber irrigation procedure. The image showed vitreous opacity, retinal edema with bluish color, and sporadic bleeding in the macular and subretinal area.

From this case, we were able to determine several pieces of information. First, the primary cause of misdiagnosis in the present case was the diversity and non-specificity of masquerade syndrome. For patients with secondary glaucoma who do not have a clear cause of the disease and a satisfactory result from the treatment for ocular hypertension, the possibility of cancer should be considered. The key step in treating secondary glaucoma without a clear cause of the disease is to correctly identify the cause of the disease. Second, for older pediatric Rb patients, the symptoms and signs are often not typical for Rb, such as conjunctival edema, pseudohypopyon in the anterior chamber, pseudocellulitis of the orbit and secondary intraocular hypertension. Patients with these symptoms are easily misdiagnosed as uveitis or infectious endophthalmitis. However, the pseudohypopyon presented in this case is different from the hypopyon found in patients with infectious endophthalmitis, which is characterized by yellow or white, thick empyema in the anterior chamber. The manifestations of pseudohypopyon are the accumulation of gray or white, different sized, granular or sponge-like tumor cells seeded in the lower part of the anterior chamber or diffusely seeded in the anterior chamber, the surface of the iris or the surface of the lens. Sometimes snowball-like or lumpy opaque nodules can be found in the vitreous cavity due to the seeding of cancer cells in older pediatric Rb patients. Third, for highly suspected intraocular cancer patients with atypical symptoms but without confirmative imaging examination results, anterior chamber fluid or vitreous fluid examination should be performed as soon as possible to make a correct diagnosis[14]. Last, the primary goal of Rb treatment was saving the patient's life, followed by the saving of the affected eyes and visual functions. For patients with late-stage Rb, enucleation with systematic chemotherapy and regional radiotherapy is recommended to improve the chance of survival of the patient[15,16].



DOI: 10.12998/wjcc.v10.i24.8695 Copyright ©The Author(s) 2022.

Figure 8 H&E staining of the enucleated eye. Arrow: Tumor mass.

CONCLUSION

We successfully diagnosed and treated a 10-year-old girl with stage E Rb with secondary glaucoma and other atypical symptoms as the first clinical manifestations. For such patients who have secondary glaucoma without a clear cause, the possibility of a malignant tumor should be considered.

FOOTNOTES

Author contributions: Zhang Y followed the patient and drafted the manuscript; Tang L was responsible for the revision and final approval of the manuscript; all authors have read and approved the final manuscript.

Informed consent statement: Informed written consent was obtained from the patient for publication of this report and any accompanying images.

Conflict-of-interest statement: The authors declare that they have no conflicts of interest.

CARE Checklist (2016) statement: The authors have read the CARE Checklist (2016), and the manuscript was prepared and revised according to the CARE Checklist (2016).

Open-Access: This article is an open-access article that was selected by an in-house editor and fully peer-reviewed by external reviewers. It is distributed in accordance with the Creative Commons Attribution NonCommercial (CC BY-NC 4.0) license, which permits others to distribute, remix, adapt, build upon this work non-commercially, and license their derivative works on different terms, provided the original work is properly cited and the use is non-commercial. See <https://creativecommons.org/licenses/by-nc/4.0/>.

Country/Territory of origin: China

ORCID number: Ying Zhang 0000-0001-8214-3256; Li Tang 0000-0001-7095-1512.

S-Editor: Yan JP

L-Editor: A

P-Editor: Yan JP

REFERENCES

- 1 AlAli A, Kletke S, Gallie B, Lam WC. Retinoblastoma for Pediatric Ophthalmologists. *Asia Pac J Ophthalmol (Phila)* 2018; 7: 160-168 [PMID: 29737052 DOI: 10.22608/APO.201870]
- 2 Broaddus E, Topham A, Singh AD. Incidence of retinoblastoma in the USA: 1975-2004. *Br J Ophthalmol* 2009; 93: 21-23 [PMID: 18621794 DOI: 10.1136/bjo.2008.138750]
- 3 Dimaras H, Kimani K, Dimba EA, Gronsdahl P, White A, Chan HS, Gallie BL. Retinoblastoma. *Lancet* 2012; 379: 1436-1446 [PMID: 22414599 DOI: 10.1016/S0140-6736(11)61137-9]
- 4 Fabian ID, Onadim Z, Karaa E, Duncan C, Chowdhury T, Scheimberg I, Ohnuma SI, Reddy MA, Sagoo MS. The

- management of retinoblastoma. *Oncogene* 2018; **37**: 1551-1560 [PMID: 29321667 DOI: 10.1038/s41388-017-0050-x]
- 5 **Singh SK**, Das D, Bhattacharjee H, Biswas J, Kuri G, Bhattacharjee K, Deka H, Deka AC. A rare case of adult onset retinoblastoma. *Oman J Ophthalmol* 2011; **4**: 25-27 [PMID: 21713237 DOI: 10.4103/0974-620X.77659]
- 6 **Dominguez-Varela IA**, Aguilera-Partida JA, Dalvin LA, Garza-Garza LA, Thompson-Garcia LM, Barbosa-Quintana A, Ancona-Lezama D. Retinoblastoma in an older Hispanic child masquerading as pars planitis: A case report. *Eur J Ophthalmol* 2022; **32**: NP71-NP74 [PMID: 33567900 DOI: 10.1177/1120672121994487]
- 7 **Ray A**, Gombos DS, Vats TS. Retinoblastoma: an overview. *Indian J Pediatr* 2012; **79**: 916-921 [PMID: 22421935 DOI: 10.1007/s12098-012-0726-8]
- 8 **McDaid C**, Hartley S, Bagnall AM, Ritchie G, Light K, Riemsma R. Systematic review of effectiveness of different treatments for childhood retinoblastoma. *Health Technol Assess* 2005; **9**: iii, ix-ix, 1 [PMID: 16336843 DOI: 10.3310/hta9480]
- 9 **Lee JH**, Han JW, Hahn SM, Lyu CJ, Kim DJ, Lee SC. Combined intravitreal melphalan and intravenous/intra-arterial chemotherapy for retinoblastoma with vitreous seeds. *Graefes Arch Clin Exp Ophthalmol* 2016; **254**: 391-394 [PMID: 26511530 DOI: 10.1007/s00417-015-3202-0]
- 10 **Peng MY**, Kersten RC. The Masquerade Syndrome. *JAMA Ophthalmol* 2017; **135**: 161-162 [PMID: 27930771 DOI: 10.1001/jamaophthalmol.2016.2890]
- 11 **Mehrabi Z**, Salimi M, Niknam K, Mohammadi F, Mamaghani HJ, Sasani MR, Ashraf MJ, Salimi A, Zahedroozegar MH, Erfani Z. Sinoorbital Mucormycosis Associated with Corticosteroid Therapy in COVID-19 Infection. *Case Rep Ophthalmol Med* 2021; **2021**: 9745701 [PMID: 34745674 DOI: 10.1155/2021/9745701]
- 12 **Zhang MF**. The diagnostic investigations should be efficient for patients with uveitis. *Zhonghua Yanke Zazhi* 2017; **53**: 721-723
- 13 **Yang M**, Yan JH. Diagnosis and treatment of masquerade syndrome, an analysis of 14 cases. *Zhongguo Shiyong Yanke Zazhi* 2012; **30**: 994-997
- 14 **Brennan RC**, Qaddoumi I, Billups CA, Free TL, Haik BG, Rodriguez-Galindo C, Wilson MW. Comparison of high-risk histopathological features in eyes with primary or secondary enucleation for retinoblastoma. *Br J Ophthalmol* 2015; **99**: 1366-1371 [PMID: 25873648 DOI: 10.1136/bjophthalmol-2014-306364]
- 15 **Wei WB**, Zhou N. Attach importance to standardized treatment of retinoblastoma to improve its treatment outcome. *Zhonghua Yandibing Zazhi* 2020; **36**: 413-418
- 16 **Faranoush M**, Mehrvar N, Tashvighi M, Fabian ID, Zloto O, Bascaran C, Ghorbani R, Ghasemi F, Naseripour M, Sedaghat A, Alebouyeh M, Mehrvar A. Retinoblastoma presentation, treatment and outcome in a large referral centre in Tehran: a 10-year retrospective analysis. *Eye (Lond)* 2021; **35**: 575-583 [PMID: 32367000 DOI: 10.1038/s41433-020-0907-z]



Published by **Baishideng Publishing Group Inc**
7041 Koll Center Parkway, Suite 160, Pleasanton, CA 94566, USA

Telephone: +1-925-3991568

E-mail: bpgoffice@wjgnet.com

Help Desk: <https://www.f6publishing.com/helpdesk>

<https://www.wjgnet.com>

