

World Journal of *Clinical Cases*

World J Clin Cases 2022 August 26; 10(24): 8432-8807



Contents

Thrice Monthly Volume 10 Number 24 August 26, 2022

EDITORIAL

- 8432** Evolution of *World Journal of Clinical Cases* over the past 5 years
Muthu S

OPINION REVIEW

- 8436** NF- κ B: A novel therapeutic pathway for gastroesophageal reflux disease?
Zhang ML, Ran LQ, Wu MJ, Jia QC, Qin ZM, Peng YG

MINIREVIEWS

- 8443** Obligate aerobic, gram-positive, weak acid-fast, nonmotile bacilli, *Tsukamurella tyrosinosolvens*: Minireview of a rare opportunistic pathogen
Usuda D, Tanaka R, Suzuki M, Shimozawa S, Takano H, Hotchi Y, Tokunaga S, Osugi I, Katou R, Ito S, Mishima K, Kondo A, Mizuno K, Takami H, Komatsu T, Oba J, Nomura T, Sugita M
- 8450** Diffusion tensor imaging pipeline measures of cerebral white matter integrity: An overview of recent advances and prospects
Safri AA, Nassir CMNCM, Iman IN, Mohd Taib NH, Achuthan A, Mustapha M
- 8463** Graft choices for anterolateral ligament knee reconstruction surgery: Current concepts
Chalidis B, Pitsilos C, Kitridis D, Givissis P
- 8474** Overview of the anterolateral complex of the knee
Garcia-Mansilla I, Zicaro JP, Martinez EF, Astoul J, Yacuzzi C, Costa-Paz M
- 8482** Complication of lengthening and the role of post-operative care, physical and psychological rehabilitation among fibula hemimelia
Salimi M, Sarallah R, Javanshir S, Mirghaderi SP, Salimi A, Khanzadeh S

ORIGINAL ARTICLE

Clinical and Translational Research

- 8490** Pyroptosis-related genes play a significant role in the prognosis of gastric cancer
Guan SH, Wang XY, Shang P, Du QC, Li MZ, Xing X, Yan B

Retrospective Study

- 8506** Effects of propofol combined with lidocaine on hemodynamics, serum adrenocorticotrophic hormone, interleukin-6, and cortisol in children
Shi S, Gan L, Jin CN, Liu RF
- 8514** Correlation analysis of national elite Chinese male table tennis players' shoulder proprioception and muscle strength
Shang XD, Zhang EM, Chen ZL, Zhang L, Qian JH

- 8525** Clinical value of contrast-enhanced ultrasound in early diagnosis of small hepatocellular carcinoma (≤ 2 cm)

Mei Q, Yu M, Chen Q

- 8535** Identification of predictive factors for post-transarterial chemoembolization liver failure in hepatocellular carcinoma patients: A retrospective study

Yuan M, Chen TY, Chen XR, Lu YF, Shi J, Zhang WS, Ye C, Tang BZ, Yang ZG

- 8547** Clinical significance of half-hepatic blood flow occlusion technology in patients with hepatocellular carcinoma with cirrhosis

Liu D, Fang JM, Chen XQ

- 8556** Which octogenarian patients are at higher risk after cholecystectomy for symptomatic gallstone disease? A single center cohort study

D'Acapito F, Solaini L, Di Pietrantonio D, Tauceri F, Mirarchi MT, Antelmi E, Flamini F, Amato A, Framarini M, Ercolani G

Clinical Trials Study

- 8568** Computed tomography combined with gastroscopy for assessment of pancreatic segmental portal hypertension

Wang YL, Zhang HW, Lin F

Observational Study

- 8578** Psychological needs of parents of children with complicated congenital heart disease after admitting to pediatric intensive care unit: A questionnaire study

Zhu JH, Jin CD, Tang XM

Prospective Study

- 8587** Quantitative differentiation of malignant and benign thyroid nodules with multi-parameter diffusion-weighted imaging

Zhu X, Wang J, Wang YC, Zhu ZF, Tang J, Wen XW, Fang Y, Han J

Randomized Controlled Trial

- 8599** Application of unified protocol as a transdiagnostic treatment for emotional disorders during COVID-19: An internet-delivered randomized controlled trial

Yan K, Yusufi MH, Nazari N

- 8615** High-flow nasal cannula oxygen therapy during anesthesia recovery for older orthopedic surgery patients: A prospective randomized controlled trial

Li XN, Zhou CC, Lin ZQ, Jia B, Li XY, Zhao GF, Ye F

SYSTEMATIC REVIEWS

- 8625** Assessment tools for differential diagnosis of neglect: Focusing on egocentric neglect and allocentric neglect

Lee SH, Lim BC, Jeong CY, Kim JH, Jang WH

CASE REPORT

- 8634** Exome analysis for Cronkhite-Canada syndrome: A case report
Li ZD, Rong L, He YJ, Ji YZ, Li X, Song FZ, Li XA
- 8641** Discrepancy between non-invasive prenatal testing result and fetal karyotype caused by rare confined placental mosaicism: A case report
Li Z, Lai GR
- 8648** Paroxysmal speech disorder as the initial symptom in a young adult with anti-N-methyl-D-aspartate receptor encephalitis: A case report
Hu CC, Pan XL, Zhang MX, Chen HF
- 8656** Anesthetics management of a renal angiomyolipoma using pulse pressure variation and non-invasive cardiac output monitoring: A case report
Jeon WJ, Shin WJ, Yoon YJ, Park CW, Shim JH, Cho SY
- 8662** Traumatic giant cell tumor of rib: A case report
Chen YS, Kao HW, Huang HY, Huang TW
- 8667** Analysis of two naval pilots' ejection injuries: Two case reports
Zeng J, Liu XP, Yi JC, Lu X, Liu DD, Jiang YQ, Liu YB, Tian JQ
- 8673** Beware of the DeBakey type I aortic dissection hidden by ischemic stroke: Two case reports
Chen SQ, Luo WL, Liu W, Wang LZ
- 8679** Unilateral lichen planus with Blaschko line distribution: A case report
Dong S, Zhu WJ, Xu M, Zhao XQ, Mou Y
- 8686** Clinical features and progress of ischemic gastritis with high fatalities: Seven case reports
Shionoya K, Sasaki A, Moriya H, Kimura K, Nishino T, Kubota J, Sumida C, Tasaki J, Ichita C, Makazu M, Masuda S, Koizumi K, Kawachi J, Tsukiyama T, Kako M
- 8695** Retinoblastoma in an older child with secondary glaucoma as the first clinical presenting symptom: A case report
Zhang Y, Tang L
- 8703** Recurrent herpes zoster in a rheumatoid arthritis patient treated with tofacitinib: A case report and review of the literature
Lin QX, Meng HJ, Pang YY, Qu Y
- 8709** Intra-abdominal ectopic bronchogenic cyst with a mucinous neoplasm harboring a *GNAS* mutation: A case report
Murakami T, Shimizu H, Yamazaki K, Nojima H, Usui A, Kosugi C, Shuto K, Obi S, Sato T, Yamazaki M, Koda K
- 8718** Effects of intravascular photobiomodulation on motor deficits and brain perfusion images in intractable myasthenia gravis: A case report
Lan CH, Wu YC, Chiang CC, Chang ST

- 8728** Spontaneous acute epidural hematoma secondary to skull and dural metastasis of hepatocellular carcinoma: A case report
Lv GZ, Li GC, Tang WT, Zhou D, Yang Y
- 8735** Malignant melanotic nerve sheath tumors in the spinal canal of psammomatous and non-psammomatous type: Two case reports
Yeom JA, Song YS, Lee IS, Han IH, Choi KU
- 8742** When should endovascular gastrointestinal anastomosis transection Glissonean pedicle not be used in hepatectomy? A case report
Zhao J, Dang YL
- 8749** VARS2 gene mutation leading to overall developmental delay in a child with epilepsy: A case report
Wu XH, Lin SZ, Zhou YQ, Wang WQ, Li JY, Chen QD
- 8755** Junctional bradycardia in a patient with COVID-19: A case report
Aedh AI
- 8761** Application of 3 dimension-printed injection-molded polyether ether ketone lunate prosthesis in the treatment of stage III Kienböck's disease: A case report
Yuan CS, Tang Y, Xie HQ, Liang TT, Li HT, Tang KL
- 8768** High scored thyroid storm after stomach cancer perforation: A case report
Baik SM, Pae Y, Lee JM
- 8775** Cholecystitis-an uncommon complication following thoracic duct embolization for chylothorax: A case report
Dung LV, Hien MM, Tra My TT, Luu DT, Linh LT, Duc NM
- 8782** Endometrial squamous cell carcinoma originating from the cervix: A case report
Shu XY, Dai Z, Zhang S, Yang HX, Bi H
- 8788** Type 2 autoimmune pancreatitis associated with severe ulcerative colitis: Three case reports
Ghali M, Bensted K, Williams DB, Ghaly S
- 8797** Diffuse uterine leiomyomatosis: A case report and review of literature
Ren HM, Wang QZ, Wang JN, Hong GJ, Zhou S, Zhu JY, Li SJ

LETTER TO THE EDITOR

- 8805** Comment on "Posterior reversible encephalopathy syndrome in a patient with metastatic breast cancer: A case report"
Kunić S, Ibrahimagić OČ, Kojić B, Džananović D

ABOUT COVER

Editorial Board Member of *World Journal of Clinical Cases*, Ahmed Mohamed Ahmed Al-Emam, PhD, Associate Professor, Department of Pathology, King Khalid University, Abha 62521, Saudi Arabia. amalemam@kku.edu.sa

AIMS AND SCOPE

The primary aim of *World Journal of Clinical Cases* (WJCC, *World J Clin Cases*) is to provide scholars and readers from various fields of clinical medicine with a platform to publish high-quality clinical research articles and communicate their research findings online.

WJCC mainly publishes articles reporting research results and findings obtained in the field of clinical medicine and covering a wide range of topics, including case control studies, retrospective cohort studies, retrospective studies, clinical trials studies, observational studies, prospective studies, randomized controlled trials, randomized clinical trials, systematic reviews, meta-analysis, and case reports.

INDEXING/ABSTRACTING

The WJCC is now abstracted and indexed in Science Citation Index Expanded (SCIE, also known as SciSearch®), Journal Citation Reports/Science Edition, Current Contents®/Clinical Medicine, PubMed, PubMed Central, Scopus, Reference Citation Analysis, China National Knowledge Infrastructure, China Science and Technology Journal Database, and Superstar Journals Database. The 2022 Edition of Journal Citation Reports® cites the 2021 impact factor (IF) for WJCC as 1.534; IF without journal self cites: 1.491; 5-year IF: 1.599; Journal Citation Indicator: 0.28; Ranking: 135 among 172 journals in medicine, general and internal; and Quartile category: Q4. The WJCC's CiteScore for 2021 is 1.2 and Scopus CiteScore rank 2021: General Medicine is 443/826.

RESPONSIBLE EDITORS FOR THIS ISSUE

Production Editor: *Ying-Yi Yuan*; Production Department Director: *Xu Guo*; Editorial Office Director: *Jin-Lei Wang*.

NAME OF JOURNAL

World Journal of Clinical Cases

ISSN

ISSN 2307-8960 (online)

LAUNCH DATE

April 16, 2013

FREQUENCY

Thrice Monthly

EDITORS-IN-CHIEF

Bao-Gan Peng, Jerzy Tadeusz Chudek, George Kontogeorgos, Maurizio Serati, Ja Hyeon Ku

EDITORIAL BOARD MEMBERS

<https://www.wjgnet.com/2307-8960/editorialboard.htm>

PUBLICATION DATE

August 26, 2022

COPYRIGHT

© 2022 Baishideng Publishing Group Inc

INSTRUCTIONS TO AUTHORS

<https://www.wjgnet.com/bpg/gerinfo/204>

GUIDELINES FOR ETHICS DOCUMENTS

<https://www.wjgnet.com/bpg/GerInfo/287>

GUIDELINES FOR NON-NATIVE SPEAKERS OF ENGLISH

<https://www.wjgnet.com/bpg/gerinfo/240>

PUBLICATION ETHICS

<https://www.wjgnet.com/bpg/GerInfo/288>

PUBLICATION MISCONDUCT

<https://www.wjgnet.com/bpg/gerinfo/208>

ARTICLE PROCESSING CHARGE

<https://www.wjgnet.com/bpg/gerinfo/242>

STEPS FOR SUBMITTING MANUSCRIPTS

<https://www.wjgnet.com/bpg/GerInfo/239>

ONLINE SUBMISSION

<https://www.f6publishing.com>



Effects of intravascular photobiomodulation on motor deficits and brain perfusion images in intractable myasthenia gravis: A case report

Chiao-Hsin Lan, Yu-Che Wu, Cheng-Chun Chiang, Shin-Tsu Chang

Specialty type: Medicine, research and experimental

Provenance and peer review: Unsolicited article; Externally peer reviewed.

Peer-review model: Single blind

Peer-review report's scientific quality classification

Grade A (Excellent): A
Grade B (Very good): 0
Grade C (Good): C
Grade D (Fair): 0
Grade E (Poor): 0

P-Reviewer: Han J, China; Liu YC, China

Received: March 14, 2022

Peer-review started: March 14, 2022

First decision: May 11, 2022

Revised: May 24, 2022

Accepted: July 16, 2022

Article in press: July 16, 2022

Published online: August 26, 2022



Chiao-Hsin Lan, Cheng-Chun Chiang, Shin-Tsu Chang, School of Medicine, National Defense Medical Center, Taipei 114201, Taiwan

Yu-Che Wu, Department of Medical Education and Research, Kaohsiung Veterans General Hospital, Kaohsiung 813414, Taiwan

Shin-Tsu Chang, Department of Physical Medicine and Rehabilitation, Kaohsiung Veterans General Hospital, Kaohsiung 813414, Taiwan

Shin-Tsu Chang, Department of Physical Medicine and Rehabilitation, Tri-Service General Hospital, Taipei 114202, Taiwan

Corresponding author: Shin-Tsu Chang, MD, MS, PhD, Director, Department of Physical Medicine and Rehabilitation, Kaohsiung Veterans General Hospital, No. 386 Dazhong 1st Road, Zuoying District, Kaohsiung 813414, Taiwan. ccdvlaser1959@gmail.com

Abstract

BACKGROUND

Myasthenia gravis (MG) is an autoimmune disorder caused by neuromuscular junction failure characterized by muscle weakness and fatigability. We herein report a case of MG that received intravascular laser irradiation of blood (ILIB) interventions and regained muscle power and better quality of life. To our knowledge, no previous study has investigated the benefits of ILIB treatment on patients with MG. We also evaluated the changes in brain perfusion scan and the MG activities of daily living (MG-ADL) and quantitative MG (QMG) scales.

CASE SUMMARY

A 59-year-old man presented to our outpatient hospital experiencing ptosis, diplopia, fibromyalgia, muscle fatigue, and fluctuating weakness in his limbs for 1 year. Based on his history, physical examination, and laboratory investigations, the final diagnosis was a flare-up of MG with poor endurance and muscle fatigue. The patient agreed to receive ILIB. Brain single-photon emission computed tomography (SPECT) was performed both before and after ILIB therapy. After receiving three courses of ILIB, the brain SPECT images showed greatly increased perfusion of the frontal lobe and anterior cingulate gyri. The patient's MG-ADL scale score decreased markedly from 17/24 to 3/24. The QMG scale score also decreased remarkably from 32/39 to 9/39. The symptoms of MG became barely

detectable and the patient was able to perform his activities of daily living and regain muscle power.

CONCLUSION

ILIB might have beneficial effects on MG, and brain SPECT images provided direct evidence of a positive correlation between ILIB and clinical performance.

Key Words: Myasthenia gravis; Intravascular laser irradiation of blood; Myasthenia gravis activities of daily living scale; Quantitative myasthenia gravis scale; Single-photon emission computed tomography; Case report

©The Author(s) 2022. Published by Baishideng Publishing Group Inc. All rights reserved.

Core Tip: Myasthenia gravis (MG) is an autoimmune disease without effective treatments. We herein report a case of intractable MG administered a novel therapy, intravascular laser irradiation of blood interventions (ILIB), which regained muscle power and improved quality of life. To our knowledge, this is the first study investigating the benefits of ILIB treatment in patients with MG. We also evaluated the changes in brain perfusion scan and MG activities of daily living scale, and quantitative MG scale scores. We report this case to trigger further research and facilitate the recovery of patients with MG.

Citation: Lan CH, Wu YC, Chiang CC, Chang ST. Effects of intravascular photobiomodulation on motor deficits and brain perfusion images in intractable myasthenia gravis: A case report. *World J Clin Cases* 2022; 10(24): 8718-8727

URL: <https://www.wjgnet.com/2307-8960/full/v10/i24/8718.htm>

DOI: <https://dx.doi.org/10.12998/wjcc.v10.i24.8718>

INTRODUCTION

Myasthenia gravis (MG) is an autoimmune disease that occurs due to the failure of neuromuscular transmission resulting from antibodies against the acetylcholine receptor, muscle-specific kinase, lipoprotein-related protein 4, or agrin in the postsynaptic membrane at the neuromuscular junction[1-4]. During the initial lifetime course of MG, patients often present with ocular symptoms of ptosis and diplopia[5,6]. About half of these patients progress to generalized disease within 2 years[7]. The clinical manifestation of this disorder is fluctuation and variable weakness in the ocular, bulbar, limb, and respiratory muscles, which lead to major symptoms such as dysarthria, dysphagia, fatigable chewing, fatigable limb, or axial weakness. Skeletal muscle fatigue manifests as weakened muscle contractile force[8-10].

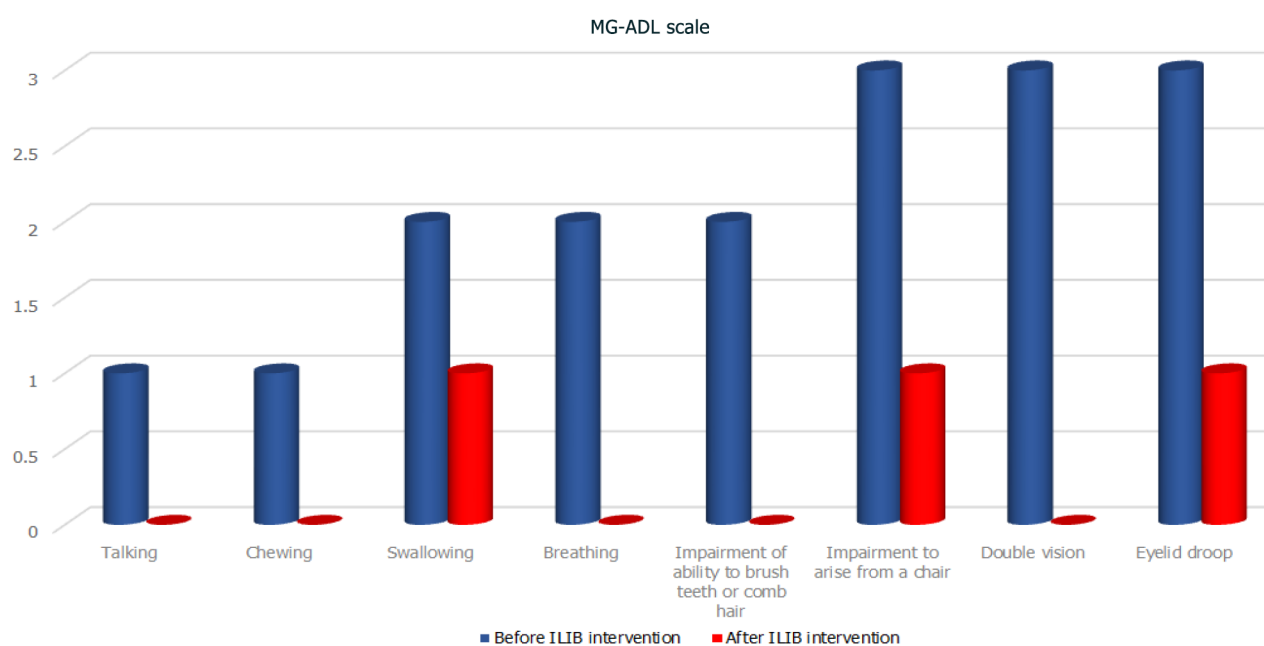
The conventional treatment of MG usually includes a combination of symptomatic therapy with acetylcholinesterase inhibitors (*e.g.*, pyridostigmine), immunosuppressive drugs, and immunotherapy using either intravenous immunoglobulin (IVIG) or plasma exchange in selected patients thymectomy [10-14]. The common therapeutic goal of these treatments is to help patients return to normal function as soon as possible while minimizing the side effects. However, patients receiving these treatments often experience adverse side effects and have difficulties in recovering[15].

A novel alternative therapy is intravascular photobiomodulation, also known as intravascular laser irradiation of blood (ILIB). ILIB treatment utilizes a helium-neon laser with a wavelength of 632.8 nm (red light). An optic fiber is inserted into a superficial vein to deliver the laser light[16]. ILIB is considered an alternative treatment for diseases such as chronic spinal cord injury, cerebral stroke, traumatic brain injury, rheumatoid arthritis, chronic Sjögren's syndrome, fibromyalgia, and chronic pain conditions, due to its effects in increasing microcirculation and improving oxygen supply[17-21]. Before this case, the usefulness of ILIB in patients with MG had not been reported. This study presents a case diagnosed with MG that was treated with ILIB therapy, which resulted in regained muscle power and improved quality of life.

CASE PRESENTATION

Chief complaints

A 59-year-old man experienced ptosis, diplopia, fibromyalgia, muscle fatigue, and fluctuating limb weakness for 1 year. Worsening weakness in bilateral lower limbs caused walking disability. The patient



DOI: 10.12998/wjcc.v10.i24.8718 Copyright ©The Author(s) 2022.

Figure 1 Myasthenia gravis activities of daily living scale. The symptoms of the patient with myasthenia gravis, including difficulties in talking, chewing, breathing, brushing teeth, and combing hair, as well as double vision were greatly ameliorated after intravascular laser irradiation of blood intervention, with grades dropping to zero. Swallowing, rising from a chair, and eyelid droop also showed good progress. MG-ADL: Myasthenia gravis activities of daily living; ILIB: Intravascular laser irradiation of blood.

then came to our outpatient hospital in hopes of regaining muscle power and better walking ability.

History of present illness

The patient's symptoms had started 1 year ago with recurrent episodes of weakness in four limbs. His eyelid dropped soon after he woke up and double vision appeared spontaneously. He also required a ventilator to maintain his daily sleeping.

History of past illness

The patient was initially diagnosed with MG on August 5, 2018, accompanied by severe ptosis, diplopia, and fibromyalgia. He visited a neurologist in a local medical center, who prescribed acetylcholinesterase inhibitor, pyridostigmine (oral: 60 mg/tab, 2 tabs three times daily), for 1 year. Later, the patient was treated with immunosuppressive drugs; namely, rituximab (intravenously: 375 mg/m², once weekly for 4 wk), and received six courses of IVIG to improve his conditions. However, the severe ptosis, diplopia, and fibromyalgia persisted without any sign of recovery. The patient reported no improvements in the weaknesses of his bilateral lower limbs, which caused walking disability and muscle fatigue, which severely affected his daily life.

Personal and family history

The patient had no significant personal or family history.

Physical examination

During his visit, the MG activities of daily living scale (MG-ADL scale)[22] total score was 20/24 (Figure 1, Table 1), while that for the quantitative MG scale (QMG scale)[23] was 32/39 (Figure 2, Table 2). The patient's vital signs were within the normal ranges. Repetitive stimulation test at 3 Hz revealed decremental responses (11.8%) in both orbicularis oculi muscles but not in the right abductor pollicis brevis muscle, which suggested the need to consider post-synaptic neuromuscular junctional disorder.

Laboratory examinations

Laboratory evaluation revealed positivity for acetylcholine receptor antibody (5.97 nmol/L). The blood biochemistry examinations revealed mildly decreased complement C3 (74.8 mg/dL) levels compared to normal values (79–152 mg/dL). The urine analysis showed normal values.

Imaging examinations

No abnormalities were noted on electrocardiograms and chest X-rays. Regional cerebral perfusion

Table 1 Myasthenia gravis activities of daily living scale

| MG-ADL scale | Before ILIB intervention | After ILIB intervention |
|---|--------------------------|-------------------------|
| Talking | 1 | 0 |
| Chewing | 1 | 0 |
| Swallowing | 2 | 1 |
| Breathing | 2 | 0 |
| Impairment of ability to brush teeth or comb hair | 2 | 0 |
| Impairment to arise from a chair | 3 | 1 |
| Double vision | 3 | 0 |
| Eyelid droop | 3 | 1 |
| Total | 17 | 3 |

The effect of intravascular laser irradiation of blood was assessed using the myasthenia gravis activities of daily living scale for the following eight criteria: talking, chewing, swallowing, breathing, brushing teeth or combing hair, rising from a chair, double vision, and eyelid droop. The numbers in the table represent grades from the maximum of 3 to the minimum of 0. MG-ADL: Myasthenia gravis activities of daily living; ILIB: Intravascular laser irradiation of blood.

Table 2 Quantitative myasthenia gravis scale

| Quantitative MG scale | Before ILIB intervention | After ILIB intervention |
|-----------------------------|--------------------------|-------------------------|
| Double vision sec. | 3 | 0 |
| Ptosis sec. | 3 | 0 |
| Facial muscles | 3 | 0 |
| Swallowing | 2 | 1 |
| Head, lifted sec. | 2 | 1 |
| Right arm outstretched sec. | 2 | 1 |
| Left arm outstretched sec. | 2 | 1 |
| Onset of dysarthria | 1 | 0 |
| Right leg outstretched | 3 | 1 |
| Left leg outstretched | 3 | 1 |
| Vital capacity (male) | 2 | 1 |
| Right hand grip | 3 | 1 |
| Left hand grip | 3 | 1 |
| Total | 32 | 9 |

The effect of intravascular laser irradiation of blood was measured based on 13 criteria from the quantitative myasthenia gravis scale. The numbers in the table represent grades from the maximum of 3 to the minimum of 0. MG: Myasthenia gravis; ILIB: Intravascular laser irradiation of blood.

(rCBF) scans by brain single-photon emission computed tomography (SPECT) were performed 30 min after the intravenous injection of 30.8 mCi Tc-99m ECD. Easy Z-score Imaging System was used for statistical analysis. The first brain SPECT showed decreased rCBF in the frontal regions and anterior cingulate gyri (Figures 3 and 4). Magnetic resonance imaging of the chest showed no evidence of a thymic mass.

Further diagnostic work-up

The results of the antinuclear autoantibodies (ANA) test were negative. The levels of RA factor (serum) were within normal limits (< 20 IU/mL). The levels in anti-cyclic citrullinated peptide (anti-CCP) screening were also normal (0.6 U/mL). The patient was negative for HLA-B27. Finally, the result of the myositis 16-specific Ag panel was unremarkable.

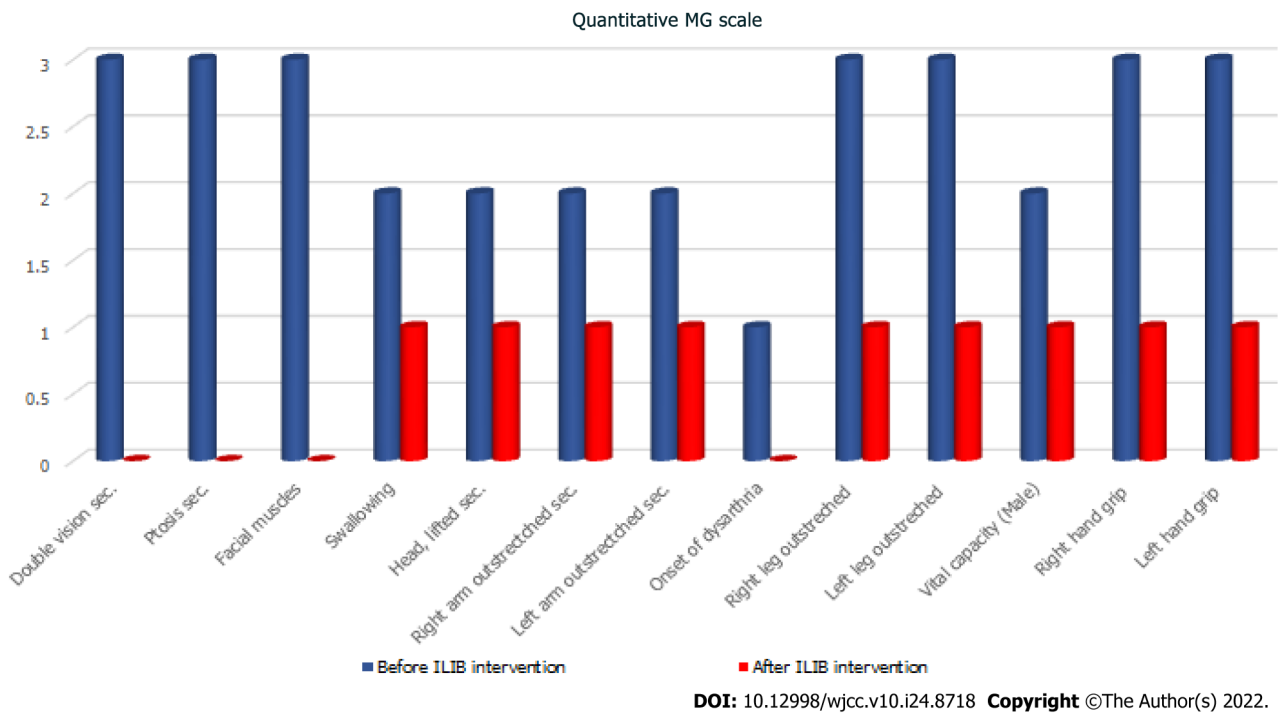


Figure 2 Quantitative myasthenia gravis scale. The effect of intravascular laser irradiation of blood was measured using 13 criteria of the quantitative myasthenia gravis scale. MG: Myasthenia gravis; ILIB: Intravascular laser irradiation of blood.

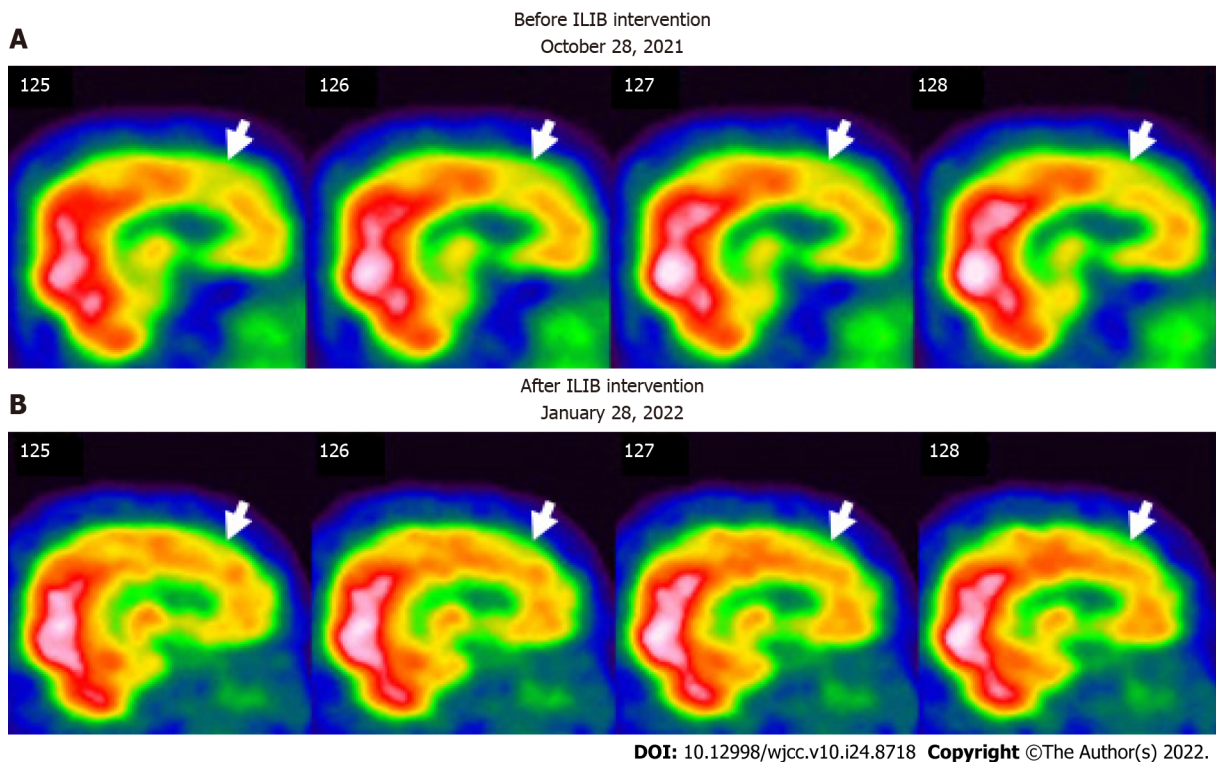


Figure 3 Regional perfusion brain single-photon emission computed tomography before and after therapeutic intravascular laser irradiation of blood intervention (sagittal view). The white to red and green to blue areas indicate high and low perfusion, respectively. A: The first single-photon emission computed tomography (SPECT) (before ILIB intervention) shows perfusion deficits in the frontal lobe (white arrows); B: The second SPECT [after the third course of intravascular laser irradiation of blood (ILIB) intervention] shows more blood flow in the frontal lobe (white arrows). ILIB: Intravascular laser irradiation of blood.

FINAL DIAGNOSIS

Based on the patient’s history, physical examinations, and laboratory investigations, the final diagnosis

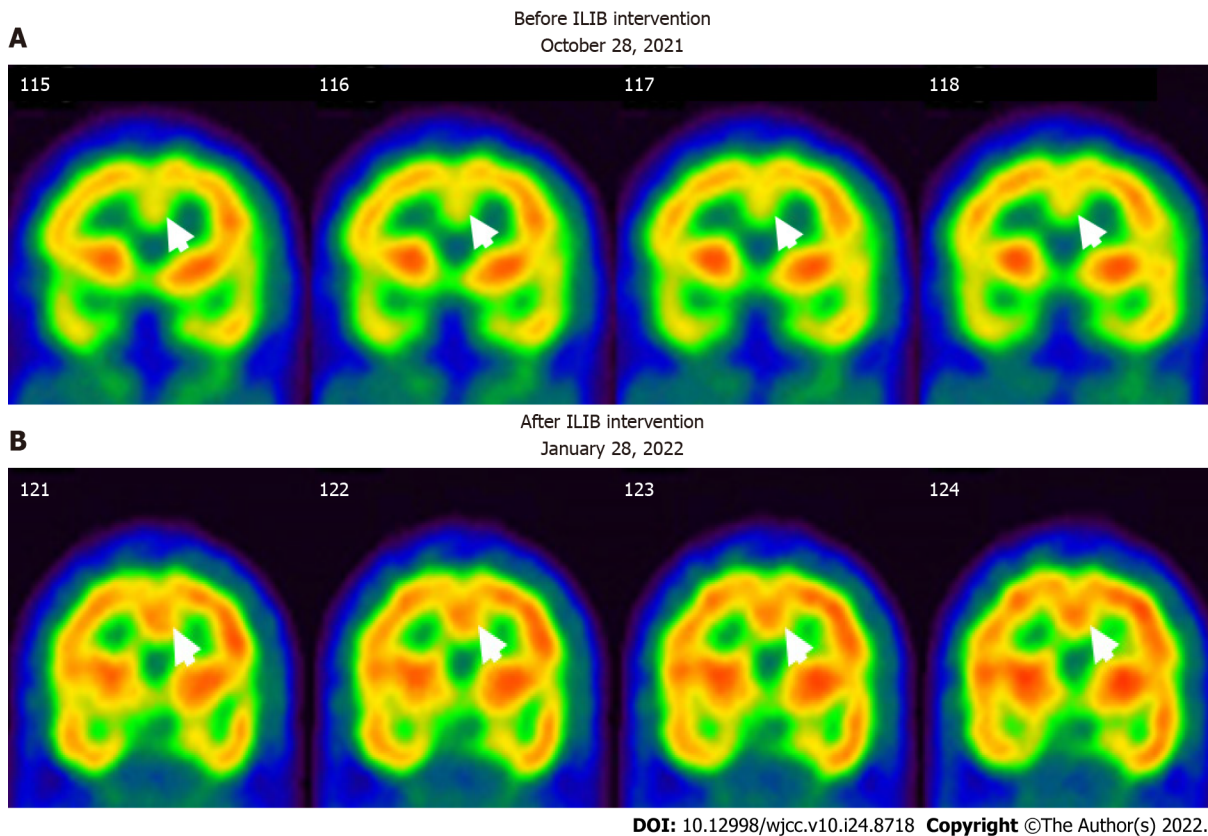


Figure 4 Regional perfusion brain single-photon emission computed tomography before and after therapeutic intravascular laser irradiation of blood intervention (coronal view). The white to red and green to blue areas indicate high and low perfusion, respectively. A: The first SPECT (before ILIB intervention) shows perfusion deficits at the anterior cingulate gyri (white arrows); B: The second SPECT (after the third course of ILIB intervention) shows high activity in the anterior cingulate gyri (black arrows). ILIB: Intravascular laser irradiation of blood; SPECT: Single-photon emission computed tomography.

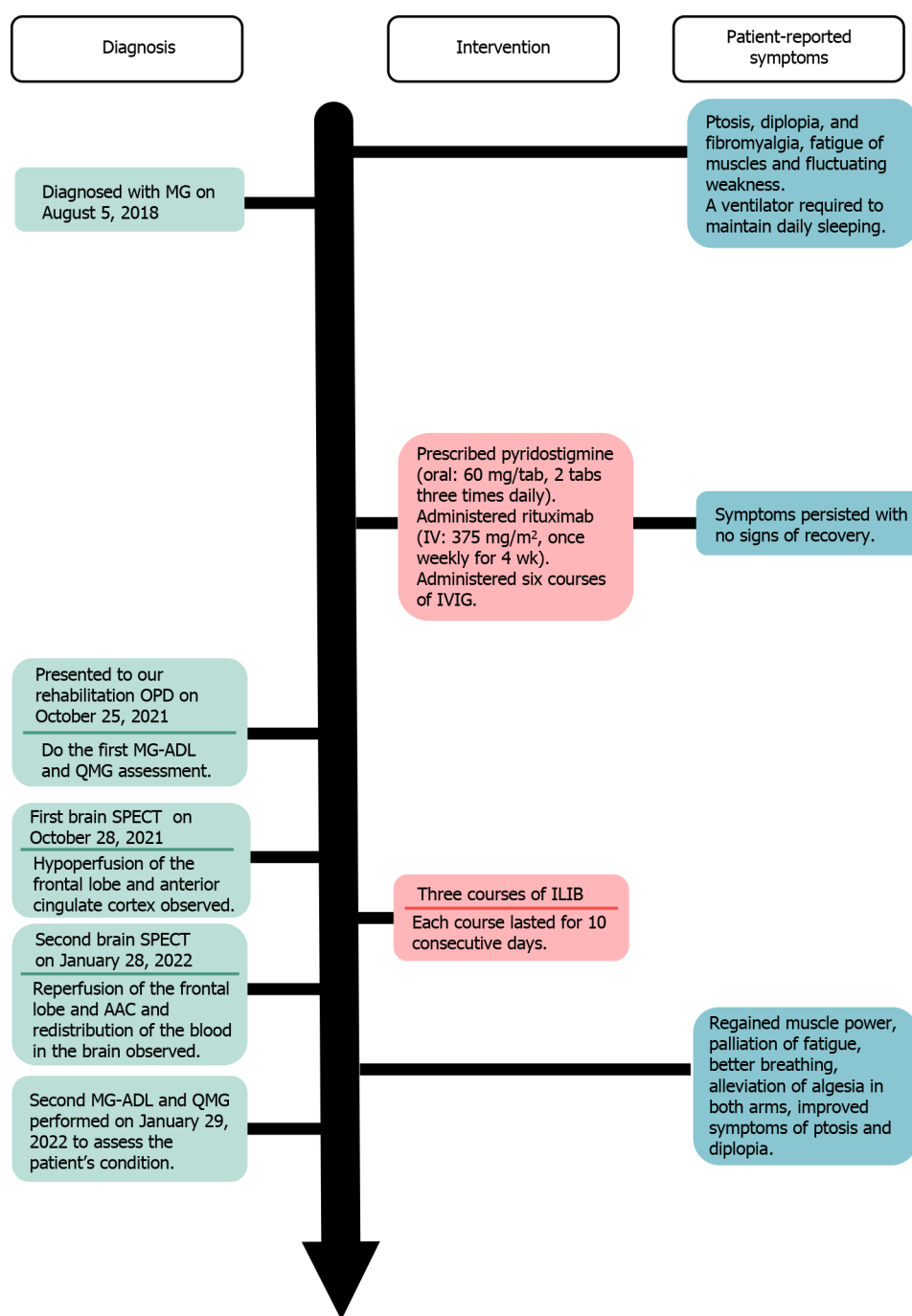
of the presented case was a flare-up of MG with poor endurance and muscle fatigue (Figure 5).

TREATMENT

The patient was advised to undergo ILIB and agreed. He received three courses of ILIB (60 min each session for 10 consecutive days per course, with a rest interval of 1–2 wk). A helium-neon (He-Ne) laser illuminator (TAIEX He-Ne Laser, YJ-ILIB-5, Bio-ILIB Human Energy Corporation, Taiwan) was applied with a wavelength of 632.8 nm, energy of 12.6 to 14.4 J, energy density of 6428.57 J/cm², power output of 2.5–3.5 w/cm², power intensity of 1.79–2.04 w/cm², and irradiation time of 3600 s/session[20]. The laser power was adjusted depending on the patient's responses.

OUTCOME AND FOLLOW-UP

After completing three courses of ILIB, the patient's double vision and eyelid-dropping were remarkably improved, with his MG-ADL scale total score decreasing from 17/24 to 3/24. The weaknesses in both upper and lower limbs changed as anticipated. In the QMG scale, the time for both arms outstretched (90° standing) increased from 0–10 s to 90–240 s, while that for both legs' outstretched (45° supine) increased from 0–10 s to 90–240 s. The patient's breathing also improved. The algnesia of both arms caused by fibromyalgia was also alleviated. Notably, the second total score of the QMG Scale decreased from 32/39 to 9/39. The second brain SPECT showed increased activities in the frontal regions and anterior cingulate gyri (Figures 3 and 4). The patient is content with the efficacy of ILIB treatment.



DOI: 10.12998/wjcc.v10.i24.8718 Copyright ©The Author(s) 2022.

Figure 5 Time course of the case and the patient's reported symptoms. IVIG: Intravenous immunoglobulin; OPD: Outpatient department; SPECT: Single-photon emission computed tomography; ILIB: Intravascular laser irradiation of blood; MG-ADL: Myasthenia gravis activities of daily living; QMG: Quantitative myasthenia gravis.

DISCUSSION

After several years of conventional treatments, including acetylcholinesterase inhibitors and immunosuppressive drugs without subjective improvement, the relatively rapid improvement in motor and respiratory function during ILIB treatment in our case suggests that the patient benefited significantly from ILIB therapy. This patient also made great clinical progress, according to his MG ADL and QMG scale scores. This is the first case report on the novel treatment of MG with ILIB. This is also the first study to describe the benefit of ILIB as a treatment for impaired motor function and analgesia by SPECT imaging of a patient with MG.

We used regional perfusion brain SPECT images to assess brain function before and after the ILIB intervention. We observed two intriguing findings in this study of a patient with MG.

First, we observed remarkably increased perfusion in the motor areas of the frontal lobe (Figure 3), which indicated a strong relationship between motor function and frontal lobe activity. Recent studies showed that ILIB therapy improved regional cerebral blood flow and provided faster repair of the affected nervous system through increased ATP production[24,25]. The motor cortex comprises three different areas of the frontal lobe, immediately anterior to the central sulcus. These areas are the primary motor cortex (Brodmann's area 4), the premotor cortex (PMC), and the supplementary motor area (SMA)[26]. Our SPECT images showed significantly increased perfusion in both the SMA and PMC after ILIB therapy, suggesting that blood flow might re-perfuse, contributing to the improvement in muscle weakness and fatigue.

Second, the SPECT images also showed higher activity in the anterior cingulate cortex (ACC) after ILIB therapy (Figure 4), which indicated a correlation between pain relief and the ACC. Davis *et al*[27] reported that the signal intensity changes within the ACC were correlated with pain intensity, sensory, cognitive processes, and motor function including voluntary movement[28]. Hence, higher activities in the ACC, considered a complicated integrative center, showed a re-distribution of blood flow in the brain, which resulted in pain relief in both arms and regained power in the skeletal muscles.

Furthermore, ILIB is considered a treatment that facilitates circulation in the frontal area of the cortex, especially in this case. ILIB may enhance muscular strength and relieve fluctuating and variable fatigue [29,30]. ILIB also plays a role as an immunomodulator through direct or indirect effects on the immune system[21], which was unbalanced in our case with MG. The post-treatment imaging study revealed that ILIB effectively facilitated circulation around the frontal area of the cortex, which improved the clinical symptoms of this patient with MG.

However, the role of the peripheral mechanism in contributing to the recovery of muscle power cannot be ignored. To sustain muscle contraction, ATP needs to be regenerated at a rate complementary to ATP demand. Three major ways are used to replenish ATP in muscle. These systems-phosphagen, glycolytic, and mitochondrial respiration-differ in the substrates used, products, maximal rate of ATP regeneration, capacity of ATP regeneration, and associated contributions to fatigue[31,32]. In addition, ILIB therapy has been reported to promote total cellular ATP synthesis, and antioxidant activity, which contributes to the alleviation of chronic conditions, such as chronic spinal cord injury and fibromyalgia [17,20]. Therefore, we believe that ILIB therapy might enhance muscle power by increasing ATP synthesis in the peripheral mechanism.

CONCLUSION

MG is an autoimmune disease that previously lacked effective treatments and detailed brain perfusion images. Our case showed the feasible management of this condition with ILIB treatment. The brain perfusion scan demonstrated increased activity in the prior deficit of the brain lesion. ILIB might have beneficial effects on MG and SPECT images could be a good monitor for any deficits in the brain.

FOOTNOTES

Author contributions: Lan CH reviewed the literature and contributed to manuscript drafting; Lan CH, Wu YC, and Chiang CC analyzed and interpreted the imaging findings; Chang ST were responsible for the revision of the manuscript for important intellectual content and supervised the study and managed the project; and All authors issued final approval for the version to be submitted.

Informed consent statement: Informed written consent was obtained from the patient for publication of this report and any accompanying images.

Conflict-of-interest statement: The authors declare that they have no conflicts of interest.

CARE Checklist (2016) statement: The authors have read the CARE Checklist (2016), and the manuscript was prepared and revised according to the CARE Checklist (2016).

Open-Access: This article is an open-access article that was selected by an in-house editor and fully peer-reviewed by external reviewers. It is distributed in accordance with the Creative Commons Attribution NonCommercial (CC BY-NC 4.0) license, which permits others to distribute, remix, adapt, build upon this work non-commercially, and license their derivative works on different terms, provided the original work is properly cited and the use is non-commercial. See: <https://creativecommons.org/licenses/by-nc/4.0/>

Country/Territory of origin: Taiwan

ORCID number: Chiao-Hsin Lan 0000-0001-8134-3619; Yu-Che Wu 0000-0001-6023-4245; Cheng-Chun Chiang 0000-0001-8423-0767; Shin-Tsu Chang 0000-0003-4005-2094.

S-Editor: Ma YJ

L-Editor: A

P-Editor: Ma YJ

REFERENCES

- Vincent A, Palace J, Hilton-Jones D. Myasthenia gravis. *Lancet* 2001; **357**: 2122-2128 [PMID: 11445126 DOI: 10.1016/S0140-6736(00)05186-2]
- Conti-Fine BM, Milani M, Kaminski HJ. Myasthenia gravis: past, present, and future. *J Clin Invest* 2006; **116**: 2843-2854 [PMID: 17080188 DOI: 10.1172/JCI29894]
- Konecny I, Herbst R. Myasthenia Gravis: Pathogenic Effects of Autoantibodies on Neuromuscular Architecture. *Cells* 2019; **8** [PMID: 31269763 DOI: 10.3390/cells8070671]
- Zhang B, Tzartos JS, Belimezi M, Ragheb S, Bealmear B, Lewis RA, Xiong WC, Lisak RP, Tzartos SJ, Mei L. Autoantibodies to lipoprotein-related protein 4 in patients with double-seronegative myasthenia gravis. *Arch Neurol* 2012; **69**: 445-451 [PMID: 22158716 DOI: 10.1001/archneurol.2011.2393]
- Dresser L, Wlodarski R, Rezaian K, Soliven B. Myasthenia Gravis: Epidemiology, Pathophysiology and Clinical Manifestations. *J Clin Med* 2021; **10** [PMID: 34064035 DOI: 10.3390/jcm10112235]
- Grob D, Brunner N, Namba T, Pagala M. Lifetime course of myasthenia gravis. *Muscle Nerve* 2008; **37**: 141-149 [PMID: 18059039 DOI: 10.1002/mus.20950]
- Kupersmith MJ, Latkany R, Homel P. Development of generalized disease at 2 years in patients with ocular myasthenia gravis. *Arch Neurol* 2003; **60**: 243-248 [PMID: 12580710 DOI: 10.1001/archneur.60.2.243]
- Hehir MK, Silvestri NJ. Generalized Myasthenia Gravis: Classification, Clinical Presentation, Natural History, and Epidemiology. *Neurol Clin* 2018; **36**: 253-260 [PMID: 29655448 DOI: 10.1016/j.ncl.2018.01.002]
- Gilhus NE, Tzartos S, Evoli A, Palace J, Burns TM, Verschuuren JJGM. Myasthenia gravis. *Nat Rev Dis Primers* 2019; **5**: 30 [PMID: 31048702 DOI: 10.1038/s41572-019-0079-y]
- Meriggioli MN, Sanders DB. Autoimmune myasthenia gravis: emerging clinical and biological heterogeneity. *Lancet Neurol* 2009; **8**: 475-490 [PMID: 19375665 DOI: 10.1016/S1474-4422(09)70063-8]
- Gold R, Schneider-Gold C. Current and future standards in treatment of myasthenia gravis. *Neurotherapeutics* 2008; **5**: 535-541 [PMID: 19019304 DOI: 10.1016/j.nurt.2008.08.011]
- Kumar V, Kaminski HJ. Treatment of myasthenia gravis. *Curr Neurol Neurosci Rep* 2011; **11**: 89-96 [PMID: 20927659 DOI: 10.1007/s11910-010-0151-1]
- Gilhus NE, Verschuuren JJ. Myasthenia gravis: subgroup classification and therapeutic strategies. *Lancet Neurol* 2015; **14**: 1023-1036 [PMID: 26376969 DOI: 10.1016/S1474-4422(15)00145-3]
- Gajdos P, Chevret S, Toyka KV. Intravenous immunoglobulin for myasthenia gravis. *Cochrane Database Syst Rev* 2012; **12**: CD002277 [PMID: 23235588 DOI: 10.1002/14651858.CD002277.pub4]
- Schneider-Gold C, Gilhus NE. Advances and challenges in the treatment of myasthenia gravis. *Ther Adv Neurol Disord* 2021; **14**: 17562864211065406 [PMID: 34987614 DOI: 10.1177/17562864211065406]
- Moskvin SV. Low-Level Laser Therapy for Herpesvirus Infections: A Narrative Literature Review. *J Lasers Med Sci* 2021; **12**: e38 [PMID: 34733761 DOI: 10.34172/jlms.2021.38]
- Huang SF, Tsai YA, Wu SB, Wei YH, Tsai PY, Chuang TY. Effects of intravascular laser irradiation of blood in mitochondria dysfunction and oxidative stress in adults with chronic spinal cord injury. *Photomed Laser Surg* 2012; **30**: 579-586 [PMID: 22891782 DOI: 10.1089/pho.2012.3228]
- Chiran DA, Weber M, Ailioaie LM, Moraru E, Ailioaie C, Litscher D, Litscher G. Intravenous laser blood irradiation and tocilizumab in a patient with juvenile arthritis. *Case Rep Med* 2014; **2014**: 923496 [PMID: 24715926 DOI: 10.1155/2014/923496]
- Yang WH, Lin SP, Chang ST. Case report: Rapid improvement of crossed cerebellar diaschisis after intravascular laser irradiation of blood in a case of stroke. *Medicine (Baltimore)* 2017; **96**: e5646 [PMID: 28079797 DOI: 10.1097/MD.0000000000005646]
- Momenzadeh S, Abbasi M, Ebadifar A, Aryani M, Bayrami J, Nematollahi F. The intravenous laser blood irradiation in chronic pain and fibromyalgia. *J Lasers Med Sci* 2015; **6**: 6-9 [PMID: 25699161]
- Liu EY, Chang ST. Benefits of intravascular laser irradiation of blood on motor and sensory recovery viewing from brain function images: Portrait of a case with chronic Sjögren's syndrome, transverse myelitis, and Guillain-Barré syndrome. *Biomed J Sci Tech Res* 2019; **14** [DOI: 10.26717/bjstr.2019.14.002572]
- Muppidi S. The myasthenia gravis--specific activities of daily living profile. *Ann N Y Acad Sci* 2012; **1274**: 114-119 [PMID: 23252905 DOI: 10.1111/j.1749-6632.2012.06817.x]
- Wolfe GI, Herbelin L, Nations SP, Foster B, Bryan WW, Barohn RJ. Myasthenia gravis activities of daily living profile. *Neurology* 1999; **52**: 1487-1489 [PMID: 10227640 DOI: 10.1212/wnl.52.7.1487]
- Dompe C, Moncrieff L, Matys J, Grzech-Leśniak K, Kocherova I, Bryja A, Bruska M, Dominiak M, Mozdziak P, Skiba TH, Shibli JA, Angelova Volponi A, Kempisty B, Dyszkiewicz-Konwińska M. Photobiomodulation-Underlying Mechanism and Clinical Applications. *J Clin Med* 2020; **9** [PMID: 32503238 DOI: 10.3390/jcm9061724]
- Tafur J, Mills PJ. Low-intensity light therapy: exploring the role of redox mechanisms. *Photomed Laser Surg* 2008; **26**: 323-328 [PMID: 18665762 DOI: 10.1089/pho.2007.2184]
- Schlaug G, Renga V. Transcranial direct current stimulation: a noninvasive tool to facilitate stroke recovery. *Expert Rev Med Devices* 2008; **5**: 759-768 [PMID: 19025351 DOI: 10.1586/17434440.5.6.759]
- Davis KD, Taylor SJ, Crawley AP, Wood ML, Mikulis DJ. Functional MRI of pain- and attention-related activations in the

- human cingulate cortex. *J Neurophysiol* 1997; **77**: 3370-3380 [PMID: [9212281](#) DOI: [10.1152/jn.1997.77.6.3370](#)]
- 28 **Kwan CL**, Crawley AP, Mikulis DJ, Davis KD. An fMRI study of the anterior cingulate cortex and surrounding medial wall activations evoked by noxious cutaneous heat and cold stimuli. *Pain* 2000; **85**: 359-374 [PMID: [10781909](#) DOI: [10.1016/S0304-3959\(99\)00287-0](#)]
 - 29 **Tomé RFF**, Silva DFB, Dos Santos CAO, de Vasconcelos Neves G, Rolim AKA, de Castro Gomes DQ. ILIB (intravascular laser irradiation of blood) as an adjuvant therapy in the treatment of patients with chronic systemic diseases- an integrative literature review. *Lasers Med Sci* 2020; **35**: 1899-1907 [PMID: [32656732](#) DOI: [10.1007/s10103-020-03100-4](#)]
 - 30 **Wang X**, Tian F, Soni SS, Gonzalez-Lima F, Liu H. Interplay between up-regulation of cytochrome-c-oxidase and hemoglobin oxygenation induced by near-infrared laser. *Sci Rep* 2016; **6**: 30540 [PMID: [27484673](#) DOI: [10.1038/srep30540](#)]
 - 31 **Baker JS**, McCormick MC, Robergs RA. Interaction among Skeletal Muscle Metabolic Energy Systems during Intense Exercise. *J Nutr Metab* 2010; **2010**: 905612 [PMID: [21188163](#) DOI: [10.1155/2010/905612](#)]
 - 32 **Hargreaves M**, Spriet LL. Skeletal muscle energy metabolism during exercise. *Nat Metab* 2020; **2**: 817-828 [PMID: [32747792](#) DOI: [10.1038/s42255-020-0251-4](#)]



Published by **Baishideng Publishing Group Inc**
7041 Koll Center Parkway, Suite 160, Pleasanton, CA 94566, USA

Telephone: +1-925-3991568

E-mail: bpgoffice@wjgnet.com

Help Desk: <https://www.f6publishing.com/helpdesk>

<https://www.wjgnet.com>

