

World Journal of *Clinical Cases*

World J Clin Cases 2022 August 26; 10(24): 8432-8807



Contents

Thrice Monthly Volume 10 Number 24 August 26, 2022

EDITORIAL

- 8432** Evolution of *World Journal of Clinical Cases* over the past 5 years
Muthu S

OPINION REVIEW

- 8436** NF- κ B: A novel therapeutic pathway for gastroesophageal reflux disease?
Zhang ML, Ran LQ, Wu MJ, Jia QC, Qin ZM, Peng YG

MINIREVIEWS

- 8443** Obligate aerobic, gram-positive, weak acid-fast, nonmotile bacilli, *Tsukamurella tyrosinosolvens*: Minireview of a rare opportunistic pathogen
Usuda D, Tanaka R, Suzuki M, Shimozawa S, Takano H, Hotchi Y, Tokunaga S, Osugi I, Katou R, Ito S, Mishima K, Kondo A, Mizuno K, Takami H, Komatsu T, Oba J, Nomura T, Sugita M
- 8450** Diffusion tensor imaging pipeline measures of cerebral white matter integrity: An overview of recent advances and prospects
Safri AA, Nassir CMNCM, Iman IN, Mohd Taib NH, Achuthan A, Mustapha M
- 8463** Graft choices for anterolateral ligament knee reconstruction surgery: Current concepts
Chalidis B, Pitsilos C, Kitridis D, Givissis P
- 8474** Overview of the anterolateral complex of the knee
Garcia-Mansilla I, Zicaro JP, Martinez EF, Astoul J, Yacuzzi C, Costa-Paz M
- 8482** Complication of lengthening and the role of post-operative care, physical and psychological rehabilitation among fibula hemimelia
Salimi M, Sarallah R, Javanshir S, Mirghaderi SP, Salimi A, Khanzadeh S

ORIGINAL ARTICLE

Clinical and Translational Research

- 8490** Pyroptosis-related genes play a significant role in the prognosis of gastric cancer
Guan SH, Wang XY, Shang P, Du QC, Li MZ, Xing X, Yan B

Retrospective Study

- 8506** Effects of propofol combined with lidocaine on hemodynamics, serum adrenocorticotrophic hormone, interleukin-6, and cortisol in children
Shi S, Gan L, Jin CN, Liu RF
- 8514** Correlation analysis of national elite Chinese male table tennis players' shoulder proprioception and muscle strength
Shang XD, Zhang EM, Chen ZL, Zhang L, Qian JH

- 8525** Clinical value of contrast-enhanced ultrasound in early diagnosis of small hepatocellular carcinoma (≤ 2 cm)

Mei Q, Yu M, Chen Q

- 8535** Identification of predictive factors for post-transarterial chemoembolization liver failure in hepatocellular carcinoma patients: A retrospective study

Yuan M, Chen TY, Chen XR, Lu YF, Shi J, Zhang WS, Ye C, Tang BZ, Yang ZG

- 8547** Clinical significance of half-hepatic blood flow occlusion technology in patients with hepatocellular carcinoma with cirrhosis

Liu D, Fang JM, Chen XQ

- 8556** Which octogenarian patients are at higher risk after cholecystectomy for symptomatic gallstone disease? A single center cohort study

D'Acapito F, Solaini L, Di Pietrantonio D, Tauceri F, Mirarchi MT, Antelmi E, Flamini F, Amato A, Framarini M, Ercolani G

Clinical Trials Study

- 8568** Computed tomography combined with gastroscopy for assessment of pancreatic segmental portal hypertension

Wang YL, Zhang HW, Lin F

Observational Study

- 8578** Psychological needs of parents of children with complicated congenital heart disease after admitting to pediatric intensive care unit: A questionnaire study

Zhu JH, Jin CD, Tang XM

Prospective Study

- 8587** Quantitative differentiation of malignant and benign thyroid nodules with multi-parameter diffusion-weighted imaging

Zhu X, Wang J, Wang YC, Zhu ZF, Tang J, Wen XW, Fang Y, Han J

Randomized Controlled Trial

- 8599** Application of unified protocol as a transdiagnostic treatment for emotional disorders during COVID-19: An internet-delivered randomized controlled trial

Yan K, Yusufi MH, Nazari N

- 8615** High-flow nasal cannula oxygen therapy during anesthesia recovery for older orthopedic surgery patients: A prospective randomized controlled trial

Li XN, Zhou CC, Lin ZQ, Jia B, Li XY, Zhao GF, Ye F

SYSTEMATIC REVIEWS

- 8625** Assessment tools for differential diagnosis of neglect: Focusing on egocentric neglect and allocentric neglect

Lee SH, Lim BC, Jeong CY, Kim JH, Jang WH

CASE REPORT

- 8634** Exome analysis for Cronkhite-Canada syndrome: A case report
Li ZD, Rong L, He YJ, Ji YZ, Li X, Song FZ, Li XA
- 8641** Discrepancy between non-invasive prenatal testing result and fetal karyotype caused by rare confined placental mosaicism: A case report
Li Z, Lai GR
- 8648** Paroxysmal speech disorder as the initial symptom in a young adult with anti-N-methyl-D-aspartate receptor encephalitis: A case report
Hu CC, Pan XL, Zhang MX, Chen HF
- 8656** Anesthetics management of a renal angiomyolipoma using pulse pressure variation and non-invasive cardiac output monitoring: A case report
Jeon WJ, Shin WJ, Yoon YJ, Park CW, Shim JH, Cho SY
- 8662** Traumatic giant cell tumor of rib: A case report
Chen YS, Kao HW, Huang HY, Huang TW
- 8667** Analysis of two naval pilots' ejection injuries: Two case reports
Zeng J, Liu XP, Yi JC, Lu X, Liu DD, Jiang YQ, Liu YB, Tian JQ
- 8673** Beware of the DeBakey type I aortic dissection hidden by ischemic stroke: Two case reports
Chen SQ, Luo WL, Liu W, Wang LZ
- 8679** Unilateral lichen planus with Blaschko line distribution: A case report
Dong S, Zhu WJ, Xu M, Zhao XQ, Mou Y
- 8686** Clinical features and progress of ischemic gastritis with high fatalities: Seven case reports
Shionoya K, Sasaki A, Moriya H, Kimura K, Nishino T, Kubota J, Sumida C, Tasaki J, Ichita C, Makazu M, Masuda S, Koizumi K, Kawachi J, Tsukiyama T, Kako M
- 8695** Retinoblastoma in an older child with secondary glaucoma as the first clinical presenting symptom: A case report
Zhang Y, Tang L
- 8703** Recurrent herpes zoster in a rheumatoid arthritis patient treated with tofacitinib: A case report and review of the literature
Lin QX, Meng HJ, Pang YY, Qu Y
- 8709** Intra-abdominal ectopic bronchogenic cyst with a mucinous neoplasm harboring a *GNAS* mutation: A case report
Murakami T, Shimizu H, Yamazaki K, Nojima H, Usui A, Kosugi C, Shuto K, Obi S, Sato T, Yamazaki M, Koda K
- 8718** Effects of intravascular photobiomodulation on motor deficits and brain perfusion images in intractable myasthenia gravis: A case report
Lan CH, Wu YC, Chiang CC, Chang ST

- 8728** Spontaneous acute epidural hematoma secondary to skull and dural metastasis of hepatocellular carcinoma: A case report
Ly GZ, Li GC, Tang WT, Zhou D, Yang Y
- 8735** Malignant melanotic nerve sheath tumors in the spinal canal of psammomatous and non-psammomatous type: Two case reports
Yeom JA, Song YS, Lee IS, Han IH, Choi KU
- 8742** When should endovascular gastrointestinal anastomosis transection Glissonean pedicle not be used in hepatectomy? A case report
Zhao J, Dang YL
- 8749** VARS2 gene mutation leading to overall developmental delay in a child with epilepsy: A case report
Wu XH, Lin SZ, Zhou YQ, Wang WQ, Li JY, Chen QD
- 8755** Junctional bradycardia in a patient with COVID-19: A case report
Aedh AI
- 8761** Application of 3 dimension-printed injection-molded polyether ether ketone lunate prosthesis in the treatment of stage III Kienböck's disease: A case report
Yuan CS, Tang Y, Xie HQ, Liang TT, Li HT, Tang KL
- 8768** High scored thyroid storm after stomach cancer perforation: A case report
Baik SM, Pae Y, Lee JM
- 8775** Cholecystitis-an uncommon complication following thoracic duct embolization for chylothorax: A case report
Dung LV, Hien MM, Tra My TT, Luu DT, Linh LT, Duc NM
- 8782** Endometrial squamous cell carcinoma originating from the cervix: A case report
Shu XY, Dai Z, Zhang S, Yang HX, Bi H
- 8788** Type 2 autoimmune pancreatitis associated with severe ulcerative colitis: Three case reports
Ghali M, Bensted K, Williams DB, Ghaly S
- 8797** Diffuse uterine leiomyomatosis: A case report and review of literature
Ren HM, Wang QZ, Wang JN, Hong GJ, Zhou S, Zhu JY, Li SJ

LETTER TO THE EDITOR

- 8805** Comment on "Posterior reversible encephalopathy syndrome in a patient with metastatic breast cancer: A case report"
Kunić S, Ibrahimagić OČ, Kojić B, Džananović D

ABOUT COVER

Editorial Board Member of *World Journal of Clinical Cases*, Ahmed Mohamed Ahmed Al-Emam, PhD, Associate Professor, Department of Pathology, King Khalid University, Abha 62521, Saudi Arabia. amalemam@kku.edu.sa

AIMS AND SCOPE

The primary aim of *World Journal of Clinical Cases* (WJCC, *World J Clin Cases*) is to provide scholars and readers from various fields of clinical medicine with a platform to publish high-quality clinical research articles and communicate their research findings online.

WJCC mainly publishes articles reporting research results and findings obtained in the field of clinical medicine and covering a wide range of topics, including case control studies, retrospective cohort studies, retrospective studies, clinical trials studies, observational studies, prospective studies, randomized controlled trials, randomized clinical trials, systematic reviews, meta-analysis, and case reports.

INDEXING/ABSTRACTING

The WJCC is now abstracted and indexed in Science Citation Index Expanded (SCIE, also known as SciSearch®), Journal Citation Reports/Science Edition, Current Contents®/Clinical Medicine, PubMed, PubMed Central, Scopus, Reference Citation Analysis, China National Knowledge Infrastructure, China Science and Technology Journal Database, and Superstar Journals Database. The 2022 Edition of Journal Citation Reports® cites the 2021 impact factor (IF) for WJCC as 1.534; IF without journal self cites: 1.491; 5-year IF: 1.599; Journal Citation Indicator: 0.28; Ranking: 135 among 172 journals in medicine, general and internal; and Quartile category: Q4. The WJCC's CiteScore for 2021 is 1.2 and Scopus CiteScore rank 2021: General Medicine is 443/826.

RESPONSIBLE EDITORS FOR THIS ISSUE

Production Editor: *Ying-Yi Yuan*; Production Department Director: *Xu Guo*; Editorial Office Director: *Jin-Lei Wang*.

NAME OF JOURNAL

World Journal of Clinical Cases

ISSN

ISSN 2307-8960 (online)

LAUNCH DATE

April 16, 2013

FREQUENCY

Thrice Monthly

EDITORS-IN-CHIEF

Bao-Gan Peng, Jerzy Tadeusz Chudek, George Kontogeorgos, Maurizio Serati, Ja Hyeon Ku

EDITORIAL BOARD MEMBERS

<https://www.wjgnet.com/2307-8960/editorialboard.htm>

PUBLICATION DATE

August 26, 2022

COPYRIGHT

© 2022 Baishideng Publishing Group Inc

INSTRUCTIONS TO AUTHORS

<https://www.wjgnet.com/bpg/gerinfo/204>

GUIDELINES FOR ETHICS DOCUMENTS

<https://www.wjgnet.com/bpg/GerInfo/287>

GUIDELINES FOR NON-NATIVE SPEAKERS OF ENGLISH

<https://www.wjgnet.com/bpg/gerinfo/240>

PUBLICATION ETHICS

<https://www.wjgnet.com/bpg/GerInfo/288>

PUBLICATION MISCONDUCT

<https://www.wjgnet.com/bpg/gerinfo/208>

ARTICLE PROCESSING CHARGE

<https://www.wjgnet.com/bpg/gerinfo/242>

STEPS FOR SUBMITTING MANUSCRIPTS

<https://www.wjgnet.com/bpg/GerInfo/239>

ONLINE SUBMISSION

<https://www.f6publishing.com>



When should endovascular gastrointestinal anastomosis transection Glissonean pedicle not be used in hepatectomy? A case report

Jian Zhao, Yan-Li Dang

Specialty type: Gastroenterology and hepatology

Provenance and peer review: Unsolicited article; Externally peer reviewed.

Peer-review model: Single blind

Peer-review report's scientific quality classification

Grade A (Excellent): 0
Grade B (Very good): B
Grade C (Good): C
Grade D (Fair): 0
Grade E (Poor): 0

P-Reviewer: Ghimire R, Nepal; Kumar S, India

Received: March 20, 2022

Peer-review started: March 20, 2022

First decision: April 13, 2022

Revised: April 16, 2022

Accepted: July 20, 2022

Article in press: July 20, 2022

Published online: August 26, 2022



Jian Zhao, Department of Hepatobiliary Surgery, The Affiliated Hospital of Yunnan University, Kunming 650000, Yunnan Province, China

Yan-Li Dang, Department of Obstetrics, First People's Hospital of Yunnan Province, Kunming 650000, Yunnan Province, China

Corresponding author: Yan-Li Dang, MD, PhD, Chief Doctor, Department of Obstetrics, First People's Hospital of Yunnan Province, No. 157 Jinbi Road, Wuhua District, Kunming 650000, Yunnan Province, China. happyli210@163.com

Abstract

BACKGROUND

The literature on post-hepatectomy bile duct injury (PHBDI) is limited, lacking large sample retrospective studies and high-quality experience summaries. Therefore, we reported a special case of iatrogenic bile duct injury caused by Glissonean pedicle transection with endovascular gastrointestinal anastomosis (endo-GIA) during a right hepatectomy, analyzed the causes of this injury, and summarized the experience with this patient.

CASE SUMMARY

We present the case of a 66-year-old woman with recurrent abdominal pain and cholangitis due to intrahepatic cholangiectasis (Caroli's disease). Preoperative evaluation revealed that the lesion and dilated bile ducts were confined to the right liver, with right hepatic atrophy, left hepatic hypertrophy, and hilar translocation. This problem can be resolved by performing a standard right hepatectomy. Although the operation went well, jaundice occurred soon after the operation. Iatrogenic bile duct injury was considered after magnetic resonance cholangiopancreatography review, and the second operation were performed 10 d later. During the second operation, it was found that the endo-GIA had damaged the lateral wall of the hepatic duct and multiple titanium nails remained in the bile duct wall. This led to severe stenosis of the duct wall, and could not be repaired. Therefore, the injured bile duct was transected, and a hepatic-jejunal-lateral Roux-Y anastomosis was performed at the healthy part of the left hepatic duct. After this surgery, the patient had a smooth postoperative recovery, and the total bilirubin gradually decreased to normal. The patient was discharged 41 d after operation. No anastomotic stenosis was found at the 6 mo of follow-up.

CONCLUSION

Not all cases are suitable for endo-GIA transection of Glissonean pedicle,

especially in cases of intrahepatic bile duct lesions. PHBDI caused by endo-GIA is very difficult to repair due to extensive ischemia, which requires special attention.

Key Words: Endovascular gastrointestinal anastomosis; Glissonean pedicle; Hepatectomy; Bile duct injury; Safety; Case report

©The Author(s) 2022. Published by Baishideng Publishing Group Inc. All rights reserved.

Core Tip: There have been few reports on post-hepatectomy bile duct injury (PHBDI). In this report, we present a case of PHBDI caused by the wrong choice of transection tool, such as endovascular gastrointestinal anastomosis (endo-GIA), which was successfully saved by reoperation. We wanted to draw attention to the fact that not all cases are suitable for endo-GIA transection of Glissonean pedicle.

Citation: Zhao J, Dang YL. When should endovascular gastrointestinal anastomosis transection Glissonean pedicle not be used in hepatectomy? A case report. *World J Clin Cases* 2022; 10(24): 8742-8748

URL: <https://www.wjgnet.com/2307-8960/full/v10/i24/8742.htm>

DOI: <https://dx.doi.org/10.12998/wjcc.v10.i24.8742>

INTRODUCTION

There have been more reports on iatrogenic bile duct injuries (BDIs) after laparoscopic cholecystectomy (LC), *i.e.*, LCBDIs, although its incidence has been reduced to 0.3%-0.7% [1]. However, the incidence of post-hepatectomy bile duct injury (PHBDI) is as high as 3.6%-17% [2], accounting for one-third of the post-hepatectomy mortality [3], and more attention should be paid to this type of injury to decrease its occurrence [4]. With the increasing popularity of laparoscopic and robotic hepatectomy worldwide [5,6] and the increasing reliance on the use of energy devices and Tric-staple™, as well as the difficulty in determining the spatial relationship between catheters due to the lack of complete stereoscopic vision and tactile feedback in the laparoscopic field of vision, the true incidence of PHBDI may be higher [7]. However, there is still a lack of large sample clinical studies and high-quality experience summaries specifically for its cause analysis and prevention strategies. Thus, we reported a specific case of PHBDI caused by Glissonean pedicle transection with endovascular gastrointestinal anastomosis (endo-GIA) during right a hemi-hepatectomy, analyzed its causes, and summarized the experience with this patient.

CASE PRESENTATION

Chief complaints

A 66-year-old Chinese female presented with recurrent abdominal pain for 20 years and fever for 1 wk.

History of present illness

The patient began to experience intermittent dull pain in the upper abdomen more than 20 years ago, with no obvious inducement, and spontaneously relieved by rest. Initially, no other concomitant symptoms were found, but the pain occurred 1-2 times per month. In the past 2 years, the frequency of abdominal pain increased to about 1-2 times a week. The patient developed chills and a fever 1 wk ago, with the highest body temperature of 38.3 °C, which were relieved after oral administration of antipyretic and analgesic drugs. No jaundice was evident.

History of past illness

The patient was diagnosed as type 2 diabetes and hypertension 2 years ago, which has been controlled well with oral medication.

Personal and family history

The patient had no special personal and family history.

Physical examination

At admission, the patient's consciousness was clear, with a body temperature of 37.3 °C, and a blood pressure on 145/85 mmHg, without skin and sclera jaundice. The abdomen was soft and flat, with percussive pain in the right upper quadrant and liver area, without tenderness or rebound pain.

Murphy's sign was negative.

Laboratory examinations

Laboratory tests indicated that only alkaline phosphatase and gamma-glutamyltransferase (γ -GTP) were slightly elevated at admission, with normal infection indicators, tumor markers, and total bilirubin (TBIL) (Table 1).

Imaging examinations

Contrast-enhanced abdominal magnetic resonance imaging demonstrates a dilated bile duct in right liver with a large cyst occupying the beginning of the right anterior and posterior hepatic ducts, accompanied by right liver atrophy, left liver hyperplasia, and counterclockwise hilar translocation (Figure 1A and B). The opening of left hepatic duct was very close to the cyst (Figure 1C), the right portal vein branch was not clearly seen, with no variation of extrahepatic bile duct and other blood vessels (Figure 1D and E). The peripheral bile ducts were full of stones (Figure 1F). According to the preoperative imaging evaluation, standard right hepatectomy could resolve this lesion.

FINAL DIAGNOSIS

According to clinical and imaging features, intrahepatic cholangiectasia (Caroli's disease, Todani type-V) with recurrent cholangitis, atrophy-hypertrophy complex, and hilar translocation was considered.

TREATMENT

After preoperative evaluation, it was considered that the lesion was confined to the right liver and could be resolved by standard right hepatectomy, so the first operation was performed. During the operation, obvious fibrosis and atrophy were found in the right liver (Figure 2A). The diseased bile duct was close to the bifurcation of the left and right hepatic ducts, and the extrahepatic bile duct was slender. The initial part of the right hepatic duct was first separated from extrasheathical dissection method, the right hepatic duct was then transected with endo-GIA (Figure 2B and C), and finally a standard right hepatectomy was performed along the demarcation line of the liver surface. No abnormalities were found during the operation. Postoperative reexamination found a gradual increase in TBIL, but there were no significant change in white blood cells (Table 1), and the patient did not complain of any special uncomfortable feeling. Magnetic resonance cholangiopancreatography (MRCP) was reexamined on the 5th postoperative day and no extrahepatic bile duct was found, and the left hepatic duct was dilated compared with the operation before (Figure 2D). At this point, we realized that a biliary tract injury had occurred, so a second operation was performed on the 10th day. During the second operation, the lateral wall of the hepatic duct damaged by endo-GIA was found, which had led to severe stenosis and occlusion. Residual titanium nails could be seen in the damaged bile duct wall, leading to locally significant inflammatory edema and ischemia (Figure 2E and F). The damage was about 4 cm long, which could not be repaired at this location. The portal vein and the hepatic artery were not damaged. Therefore, the injured hepatic duct was directly transected, the main trunk of the left hepatic duct was dissected and exposed, and the left hepatic duct and jejunum side-by-side anastomosis (Roux-Y anastomosis) was completed (Figure 2G). The patient recovered smoothly, and no additional complications occurred after re-operation. TBIL and γ -GTP levels gradually decreased, and liver function gradually improved (Table 1). Postoperative pathology found chronic inflammation of the bile duct wall, but no malignant cells were found (Figure 2H). The patient was discharged on the 41st day after operation.

OUTCOME AND FOLLOW-UP

After half a year of follow-up, the patient had no abdominal pain or fever, no anastomotic stenosis, and normal liver functions. The patient was later lost due to coronavirus disease 2019 pandemic.

DISCUSSION

Iatrogenic bile duct injury is a permanent pain for hepatobiliary surgeons[8]. However, the understanding of BDI is often limited to LCBDI, rather than PHBDI, as few scholars pay attention to this injury. Both injuries have significant differences in injury causes, risk factors, injury characteristics, clinical classification, preventive principles, and treatment methods[4]. The reviews of the literature on

Table 1 Laboratory findings

| | On admission | Day 3 postoperatively | Day 8 postoperatively | Day 13 postoperatively (day 3 after re-operation) | Day 35 postoperatively (day 25 after re-operation) |
|----------------------------|--------------|-----------------------|-----------------------|---|--|
| WBC ($\times 10^9/L$) | 4.53 | 12.81 | 13.21 | 16.3 | 6.41 |
| Hb (g/dL) | 13.2 | 11.9 | 12.9 | 12 | 13.5 |
| Plt ($\times 10^9/L$) | 210 | 243 | 288 | 179 | 231 |
| TBIL ($\mu\text{mol/L}$) | 17.6 | 68 | 158.7 | 135.1 | 15.6 |
| AST (U/L) | 17 | 891 | 780 | 860 | 14 |
| ALT (U/L) | 20 | 706 | 612 | 778 | 13 |
| γ -GTP (U/L) | 84 | 349 | 694 | 589 | 20 |
| ALP (U/L) | 75 | 344 | 481 | 450 | 57 |
| Alb (g/dL) | 42.4 | 34.5 | 31.6 | 29.7 | 39.6 |
| Cr ($\mu\text{mol/L}$) | 65.1 | 58 | 38.6 | 31.5 | 68 |
| PT (s) | 10.2 | 11.5 | 14.6 | 13.1 | 9.8 |
| CRP (mg/L) | 0.098 | 89.1 | 135.7 | 171.6 | 0.086 |
| CA19-9 (μmL) | 17.7 | | | | |
| CEA (ng/mL) | 2.3 | | | | |

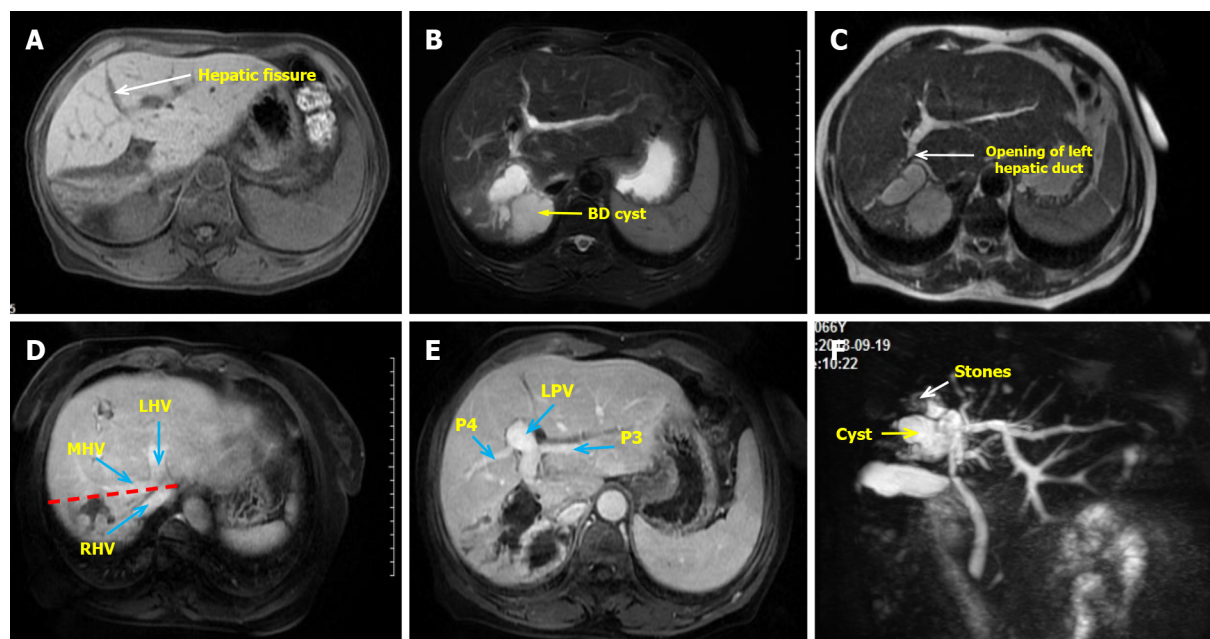
Alb: Albumin; ALP: Alkaline phosphatase; ALT: Alanine aminotransferase; AST: Aspartate aminotransferase; CA19-9: Carbohydrate antigen19-9; CEA: Carcinoembryonic antigen; Cr: Creatinine; CRP: C-reactive protein; γ -GTP: Gamma-glutamyltransferase; Hb: Hemoglobin; Plt: Platelets; PT: Prothrombin time; TBIL: Total bilirubin; WBC: White blood cells.

the clinical characteristics of PHBDI show that it mostly occurs to the high bile duct (the confluence of the left and right hepatic ducts and above) and is prone to vascular injury[9-10]. Injuries to laparoscopic hepatectomy are often related to the use of endo-GIA/Endo-Cutter, and energy equipment, with difficult repair and poor prognosis[9]. Clinical manifestations are hyperbiliary stenosis, obstruction, bile duct leakage, and bile duct bleeding. Most patients, already complicated with basic liver diseases (cirrhosis, cholangitis, liver cancer, *etc.*), can develop severe abdominal infection, liver failure, and even death[11].

The risk factors of PHBDI that should be a major concern for liver surgeons include[7,12]: (1) Variations in hilar bile duct anatomy, such as right anterior hepatic duct opening in left hepatic duct or right posterior hepatic duct low or ectone confluence in hepatic duct or gallbladder duct[3]; (2) The combination of hepatic atrophy and hyperplasia, as well as hilar translocation, which usually occurs in benign biliary lesions (such as hepatolithiasis and Caroli's disease), past hepatectomy, and mass effect of large hilar tumors; (3) Intraoperative overstretching causing the displacement of the reserved lateral bile duct; (4) Improper position of transverse hepatic pedicle; (5) Complex and difficult operations or combined hilar lymph node dissections that are easy to cause injury; (6) Blind clipping or disconnection performed in case of intraoperative misjudgment or deviation from the resection plane; and (7) Incorrect use of energy devices (such as ultrasound scalpel, electrocoagulating blood stopper, *etc.*) and endo-GIA.

The causes of the injury in our patient are various, including objective unfavorable factors, such as the lesion duct's location close to the reserved side bile duct and right liver atrophy leading to hilar translocation. However, the root cause of this case was the wrong choice of transection tools, such as endo-GIA, rather than the wrong process when using it. Initially, during the operation, the author and assistants repeatedly remind each other not to accidentally hurt the healthy side bile duct, and therefore, the injury was not likely caused by carelessness. Second, because the lesion bile duct of cystic dilation was too close to the common hepatic duct, there was no "safe boundary" when it was transected. Because endo-GIA's fuselage itself has a certain width, the tissue inside this objectively small width is invisible when transected. Predictably, in this particular type of case, if endo-GIA is used to transect the Glissonean pedicle, it is expected that there is a higher chance that BDI will occur. This is the contradiction between "removal of lesions thoroughness" and "surgical safety".

Therefore, the important points that we learned from this particular case include: (1) It is necessary to transect the Glissonean pedicle in or as close as possible to the liver, whether the Glissonean pedicle extrahepatic or intrahepatic dissection technology is adopted[13-15]; (2) Endo-GIA should not be selected for transection of the Glissonean pedicle in hepatectomy cases involving intrahepatic bile duct diseases, as we need to treat the intrahepatic bile duct separately to prevent the bile duct injury. It should not be recommended for cases such as intrahepatic cholangiectasia, intrahepatocholic stones,



DOI: 10.12998/wjcc.v10.i24.8742 Copyright ©The Author(s) 2022.

Figure 1 Preoperative clinical image of the abdomen. A: The right liver atrophy and compensatory hypertrophy of the left liver were seen, with the hepatic fissure (the white arrow) transposed to the right; B: Right hepatic duct cystic dilatation; C: The opening of left hepatic duct (the white arrow) is very close to the cyst; D: The red line shows the expected excision line and the blue arrows show the three major hepatic veins; E: No vascular variation was found and the left portal veins were also transposed to the right; F: Magnetic resonance cholangiopancreatography was used to evaluate intrahepatic and extrahepatic bile ducts. The end of the right hepatic duct is full of stones (the white arrow). LHV: Left hepatic vein; MHV: Middle hepatic vein; P3: Portal vein of Segment 3; P5: Portal vein of Segment 5; RHV: Right hepatic vein.

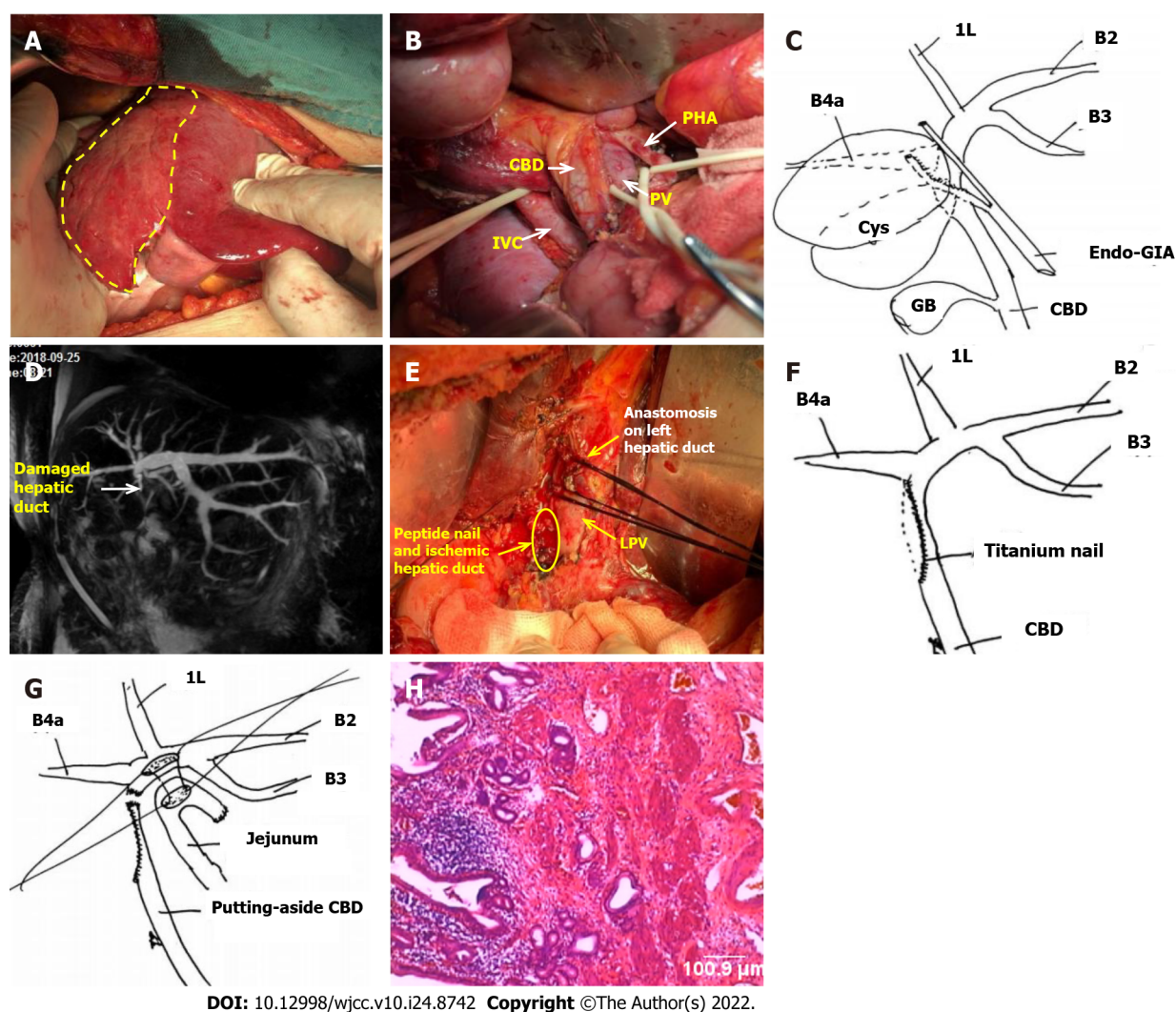
and Hilar cholangiocarcinoma, especially the special types of lesion bile ducts very close to the reserved side bile duct[3]; (3) In particular, it should be noted that the reason why the use of endo-GIA transection of the Glissonean pedicle is less accurate than ligation and suture is that the fuselage of gastrointestinal anastomosis has a certain width, and it is necessary to reserve a certain safety boundary during the operation to prevent the damage of bile duct on the reserved side; and (4) Based on the above discussion, we believe that a better way to avoid this situation is to replace the endo-GIA with a manual suture method.

Another important topic we would like to discuss regarding this case is that the damage to the sidewall of the bile duct caused by the endo-GIA is very difficult to reconstruct. The experience and methods we have accumulated in the past for the repair and reconstruction of the bile duct after LCBDI are totally inapplicable. The root cause was dense peptide nails that caused damage to the bile ducts, which led to an unimaginable range of ischemia, as shown in Figure 2E. If it is repaired by local plastic surgery or gastrointestinal muscle flaps, the consequences must be stenosis. Therefore, only a higher position of the hepatic duct and jejunum anastomosis can solve the problem. This opinion has not been mentioned in previous literature.

In conclusion, we would like to remind that the use of endo-GIA should also have certain indications and contraindications (it is usually safe, but not always). We need to understand endo-GIA's advantages and disadvantages, as well as a learning curve and operational experiences. Selecting the right patient with the right device is a key concern, and sometimes safety is more important than "radical resection". The treatment of PHBDI caused by Endo-GIA is difficult, and we may provide a reference to the successful treatment of this case.

CONCLUSION

Not all cases are suitable for endo-GIA transection of the Glissonean pedicle, especially in cases of intrahepatic bile duct lesions. PHBDI caused by Endo-GIA is very difficult to repair due to extensive ischemia, which requires special attention.



DOI: 10.12998/wjcc.v10.i24.8742 Copyright ©The Author(s) 2022.

Figure 2 Postoperative clinical images and surgical schematic diagram. A: The right liver atrophy and left liver hyperplasia were confirmed intraoperatively. The area within the yellow line is the right liver with fibrosis and atrophy; B: The portal vessels were dissected, and there was no variation in extrahepatic vessels; C: The right hepatic duct was transected by endovascular gastrointestinal anastomosis from its origin; D: Postoperative magnetic resonance cholangiopancreatography reexamination showed that the extrahepatic bile duct was not shown; E: Severe ischemia (the yellow area) was found due to titanium nail damage to the lateral wall of the hepatic duct during the reoperation exploration. The anastomosis of the left hepatic duct (the white arrow) was suspended by silk thread; F: Schematic diagram of the causes of bile duct injury; G: Schematic diagram of the side-by-side anastomosis of the hepatic duct and jejunum; H: Postoperative pathology ($\times 100$) showed chronic inflammation of the bile duct wall, and no malignant cells were found. 1L: Bile duct of Segment 1L; B2: Bile duct of Segment 2; B3: Bile duct of Segment 3; B4a: Bile duct of Segment 4a; CBD: Common bile duct; GB: Gall bladder; IVC: Inferior vena cava; LPV: Left portal vein; PV: Portal vein.

ACKNOWLEDGEMENTS

The authors thank Dr. Dang YL, Department of Obstetrics, The First People's Hospital of Yunnan Province, for participating in the discussion and conclusion.

FOOTNOTES

Author contributions: Zhao J and Dang YL designed this report; Zhao J wrote the paper.

Supported by Basic Research Foundation of Yunnan Province, No. 202101AY070001-282.

Informed consent statement: Informed written consent was obtained from the patient for publication of this report.

Conflict-of-interest statement: The authors declare that they have no competing interests.

CARE Checklist (2016) statement: The authors have read the CARE Checklist (2016), and the manuscript was prepared and revised according to the CARE Checklist (2016).

Open-Access: This article is an open-access article that was selected by an in-house editor and fully peer-reviewed by external reviewers. It is distributed in accordance with the Creative Commons Attribution NonCommercial (CC BY-NC 4.0) license, which permits others to distribute, remix, adapt, build upon this work non-commercially, and license their derivative works on different terms, provided the original work is properly cited and the use is non-commercial. See: <https://creativecommons.org/licenses/by-nc/4.0/>

Country/Territory of origin: China

ORCID number: Jian Zhao 0000-0001-8419-9202; Yan-Li Dang 0000-0003-3372-3566.

S-Editor: Yan JP

L-Editor: Filipodia

P-Editor: Yan JP

REFERENCES

- 1 **Marino MV**, Mirabella A, Guarrasi D, Lupo M, Komorowski AL. Robotic-assisted repair of iatrogenic common bile duct injury after laparoscopic cholecystectomy: Surgical technique and outcomes. *Int J Med Robot* 2019; **15**: e1992 [PMID: 30773791 DOI: 10.1002/rcs.1992]
- 2 **Erdogan D**, Busch OR, Gouma DJ, van Gulik TM. Prevention of biliary leakage after partial liver resection using topical hemostatic agents. *Dig Surg* 2007; **24**: 294-299 [PMID: 17657155 DOI: 10.1159/000103661]
- 3 **Fragulidis G**, Marinis A, Polydorou A, Konstantinidis C, Anastasopoulos G, Contis J, Voros D, Smyrniotis V. Managing injuries of hepatic duct confluence variants after major hepatobiliary surgery: an algorithmic approach. *World J Gastroenterol* 2008; **14**: 3049-3053 [PMID: 18494057 DOI: 10.3748/wjg.14.3049]
- 4 **Boonstra EA**, de Boer MT, Sieders E, Peeters PM, de Jong KP, Slooff MJ, Porte RJ. Risk factors for central bile duct injury complicating partial liver resection. *Br J Surg* 2012; **99**: 256-262 [PMID: 22190220 DOI: 10.1002/bjs.7802]
- 5 **Edwin B**, Nordin A, Kazaryan AM. Laparoscopic liver surgery: new frontiers. *Scand J Surg* 2011; **100**: 54-65 [PMID: 21482506 DOI: 10.1177/145749691110000110]
- 6 **Morise Z**. Developments and perspectives of laparoscopic liver resection in the treatment of hepatocellular carcinoma. *Surg Today* 2019; **49**: 649-655 [PMID: 30649611 DOI: 10.1007/s00595-019-1765-9]
- 7 **Zheng SG**. Characteristics and prevention strategies of bile duct injury during laparoscopic hepatectomy. *Zhongguo Shiyong Waikao Zazhi* 2018; **38**: 1012-1014 [DOI: 10.19538/j.cjps.issn1005-2208.2018.09.13]
- 8 **Dai HS**, Liang L, Zhang CC, Cheng ZJ, Peng YH, Zhang YM, Geng XP, Qin HJ, Wang K, Chen W, Yu C, Wang LF, Lau WY, Zhang LD, Zheng SG, Bie P, Shen F, Wu MC, Chen ZY, Yang T. Impact of iatrogenic biliary injury during laparoscopic cholecystectomy on surgeon's mental distress: a nationwide survey from China. *HPB (Oxford)* 2020; **22**: 1722-1731 [PMID: 32284280 DOI: 10.1016/j.hpb.2020.03.019]
- 9 **Sakamoto K**, Tamesa T, Yukio T, Tokuhisa Y, Maeda Y, Oka M. Risk Factors and Managements of Bile Leakage After Hepatectomy. *World J Surg* 2016; **40**: 182-189 [PMID: 26159119 DOI: 10.1007/s00268-015-3156-8]
- 10 **Lam CM**, Lo CM, Liu CL, Fan ST. Biliary complications during liver resection. *World J Surg* 2001; **25**: 1273-1276 [PMID: 11596889 DOI: 10.1007/s00268-001-0109-1]
- 11 **Ninomiya M**, Tomino T, Matono R, Nishizaki T. Clip on Staple Method to Prevent Bile Leakage in Anatomical Liver Resection Using Stapling Devices. *Anticancer Res* 2020; **40**: 401-404 [PMID: 31892593 DOI: 10.21873/anticancer.13966]
- 12 **Yang HC**, Huang SY, Wu CC, Chou CM. Delayed repair of post-hepatectomy bile duct injury by ducto-jejunostomy directly through a percutaneous transhepatic cholangial drainage tract: An easy alternative. *Asian J Surg* 2021; **44**: 926-927 [PMID: 33895053 DOI: 10.1016/j.asjsur.2021.04.007]
- 13 **Kim JH**, Choi JW. Intrahepatic Glissonian Approach to the Ventral Aspect of the Arantius Ligament in Laparoscopic Left Hemihepatectomy. *World J Surg* 2019; **43**: 1303-1307 [PMID: 30652216 DOI: 10.1007/s00268-019-04907-1]
- 14 **Lubikowski J**, Piotuch B, Stadnik A, Przedniczek M, Remiszewski P, Milkiewicz P, Silva MA, Wojcicki M. Difficult iatrogenic bile duct injuries following different types of upper abdominal surgery: report of three cases and review of literature. *BMC Surg* 2019; **19**: 162 [PMID: 31694627 DOI: 10.1186/s12893-019-0619-0]
- 15 **Scuderi V**, Troisi RI. Tissue management with tri-staple technology in major and minor laparoscopic liver resections. *Int Surg* 2014; **99**: 606-611 [PMID: 25216429 DOI: 10.9738/INTSURG-D-13-00101.1]



Published by **Baishideng Publishing Group Inc**
7041 Koll Center Parkway, Suite 160, Pleasanton, CA 94566, USA

Telephone: +1-925-3991568

E-mail: bpgoffice@wjgnet.com

Help Desk: <https://www.f6publishing.com/helpdesk>

<https://www.wjgnet.com>

