

World Journal of *Clinical Cases*

World J Clin Cases 2022 September 6; 10(25): 8808-9179



Contents

Thrice Monthly Volume 10 Number 25 September 6, 2022

MINIREVIEWS

- 8808 Ear, nose, and throat manifestations of COVID-19 and its vaccines
Al-Ani RM
- 8816 Potential influences of religiosity and religious coping strategies on people with diabetes
Onyishi CN, Eseadi C, Ilechukwu LC, Okoro KN, Okolie CN, Egbule E, Asogwa E

ORIGINAL ARTICLE

Case Control Study

- 8827 Effectiveness of six-step complex decongestive therapy for treating upper limb lymphedema after breast cancer surgery
Zhang HZ, Zhong QL, Zhang HT, Luo QH, Tang HL, Zhang LJ

Retrospective Study

- 8837 Hospital admissions from alcohol-related acute pancreatitis during the COVID-19 pandemic: A single-centre study
Mak WK, Di Mauro D, Pearce E, Karran L, Myintmo A, Duckworth J, Orabi A, Lane R, Holloway S, Manzelli A, Mossadegh S
- 8844 Indocyanine green plasma clearance rate and 99mTc-galactosyl human serum albumin single-photon emission computed tomography evaluated preoperative remnant liver
Iwaki K, Kaihara S, Kita R, Kitamura K, Hashida H, Uryuhara K
- 8854 Arthroscopy with subscapularis upper one-third tenodesis for treatment of recurrent anterior shoulder instability independent of glenoid bone loss
An BJ, Wang FL, Wang YT, Zhao Z, Wang MX, Xing GY
- 8863 Evaluation of the prognostic nutritional index for the prognosis of Chinese patients with high/extremely high-risk prostate cancer after radical prostatectomy
Yang F, Pan M, Nie J, Xiao F, Zhang Y

Observational Study

- 8872 Chlorine poisoning caused by improper mixing of household disinfectants during the COVID-19 pandemic: Case series
Lin GD, Wu JY, Peng XB, Lu XX, Liu ZY, Pan ZG, Qiu ZW, Dong JG
- 8880 Mental health of the Slovak population during COVID-19 pandemic: A cross-sectional survey
Kralova M, Brazinova A, Sivcova V, Izakova L

Prospective Study

- 8893** Arthroscopic anatomical reconstruction of lateral collateral ligaments with ligament advanced reinforcement system artificial ligament for chronic ankle instability
Wang Y, Zhu JX

SYSTEMATIC REVIEWS

- 8906** How to select the quantitative magnetic resonance technique for subjects with fatty liver: A systematic review
Li YW, Jiao Y, Chen N, Gao Q, Chen YK, Zhang YF, Wen QP, Zhang ZM
- 8922** Lymphocytic choriomeningitis virus: An under-recognized congenital teratogen
Ferenc T, Vujica M, Mrzljak A, Vilibic-Cavlek T

CASE REPORT

- 8932** Alagille syndrome associated with total anomalous pulmonary venous connection and severe xanthomas: A case report
Zeng HS, Zhang ZH, Hu Y, Zheng GL, Wang J, Zhang JW, Guo YX
- 8939** Colo-colonic intussusception with post-polypectomy electrocoagulation syndrome: A case report
Moon JY, Lee MR, Yim SK, Ha GW
- 8945** Portal vein gas combined with pneumatosis intestinalis and emphysematous cystitis: A case report and literature review
Hu SF, Liu HB, Hao YY
- 8954** Quadricuspid aortic valve and right ventricular type of myocardial bridging in an asymptomatic middle-aged woman: A case report
Sopek Merkaš I, Lakušić N, Paar MH
- 8962** Treatment of gastric carcinoma with lymphoid stroma by immunotherapy: A case report
Cui YJ, Ren YY, Zhang HZ
- 8968** Gallstone associated celiac trunk thromboembolisms complicated with splenic infarction: A case report
Wu CY, Su CC, Huang HH, Wang YT, Wang CC
- 8974** Extracorporeal membrane oxygenation for lung cancer-related life-threatening hypoxia: A case report
Yoo SS, Lee SY, Choi SH
- 8980** Multi-disciplinary treatment of maxillofacial skeletal deformities by orthognathic surgery combined with periodontal phenotype modification: A case report
Liu JY, Li GF, Tang Y, Yan FH, Tan BC
- 8990** X-linked recessive Kallmann syndrome: A case report
Zhang P, Fu JY
- 8998** Delayed complications of intradural cement leakage after percutaneous vertebroplasty: A case report
Ma QH, Liu GP, Sun Q, Li JG

- 9004** Coexistent Kaposi sarcoma and post-transplant lymphoproliferative disorder in the same lymph nodes after pediatric liver transplantation: A case report
Zhang SH, Chen GY, Zhu ZJ, Wei L, Liu Y, Liu JY
- 9012** Misdiagnosis of pancreatic metastasis from renal cell carcinoma: A case report
Liang XK, Li LJ, He YM, Xu ZF
- 9020** Discoid medial meniscus of both knees: A case report
Zheng ZR, Ma H, Yang F, Yuan L, Wang GD, Zhao XW, Ma LF
- 9028** Simultaneous laparoscopic and arthroscopic excision of a huge juxta-articular ganglionic cyst compressing the sciatic nerve: A case report
Choi WK, Oh JS, Yoon SJ
- 9036** One-stage revision arthroplasty in a patient with ochronotic arthropathy accompanied by joint infection: A case report
Wang XC, Zhang XM, Cai WL, Li Z, Ma C, Liu YH, He QL, Yan TS, Cao XW
- 9044** Bladder paraganglioma after kidney transplantation: A case report
Wang L, Zhang YN, Chen GY
- 9050** Total spinal anesthesia caused by lidocaine during unilateral percutaneous vertebroplasty performed under local anesthesia: A case report
Wang YF, Bian ZY, Li XX, Hu YX, Jiang L
- 9057** Ruptured splenic artery aneurysms in pregnancy and usefulness of endovascular treatment in selective patients: A case report and review of literature
Lee SH, Yang S, Park I, Im YC, Kim GY
- 9064** Gastrointestinal metastasis secondary to invasive lobular carcinoma of the breast: A case report
Li LX, Zhang D, Ma F
- 9071** Post-bulbar duodenal ulcer with anterior perforation with kissing ulcer and duodenocaval fistula: A case report and review of literature
Alzerwi N
- 9078** Modified orthodontic treatment of substitution of canines by first premolars: A case report
Li FF, Li M, Li M, Yang X
- 9087** Renal cell carcinoma presented with a rare case of icteric Stauffer syndrome: A case report
Popov DR, Antonov KA, Atanasova EG, Pentchev CP, Milatchkov LM, Petkova MD, Neykov KG, Nikolov RK
- 9096** Successful resection of a huge retroperitoneal venous hemangioma: A case report
Qin Y, Qiao P, Guan X, Zeng S, Hu XP, Wang B
- 9104** Malignant transformation of biliary adenofibroma combined with benign lymphadenopathy mimicking advanced liver carcinoma: A case report
Wang SC, Chen YY, Cheng F, Wang HY, Wu FS, Teng LS

- 9112** Congenital hepatic cyst: Eleven case reports
Du CX, Lu CG, Li W, Tang WB
- 9121** Endovascular treatment of a ruptured pseudoaneurysm of the internal carotid artery in a patient with nasopharyngeal cancer: A case report
Park JS, Jang HG
- 9127** Varicella-zoster virus meningitis after spinal anesthesia: A case report
Lee YW, Yoo B, Lim YH
- 9132** Chondrosarcoma of the toe: A case report and literature review
Zhou LB, Zhang HC, Dong ZG, Wang CC
- 9142** Tamsulosin-induced life-threatening hypotension in a patient with spinal cord injury: A case report
Lee JY, Lee HS, Park SB, Lee KH
- 9148** CCNO mutation as a cause of primary ciliary dyskinesia: A case report
Zhang YY, Lou Y, Yan H, Tang H
- 9156** Repeated bacteremia and hepatic cyst infection lasting 3 years following pancreatoduodenectomy: A case report
Zhang K, Zhang HL, Guo JQ, Tu CY, Lv XL, Zhu JD
- 9162** Idiopathic cholesterol crystal embolism with atheroembolic renal disease and blue toes syndrome: A case report
Cheng DJ, Li L, Zheng XY, Tang SF
- 9168** Systemic lupus erythematosus with visceral varicella: A case report
Zhao J, Tian M

LETTER TO THE EDITOR

- 9176** Imaging of fibroadenoma: Be careful with imaging follow-up
Ece B, Aydın S

ABOUT COVER

Editorial Board Member of *World Journal of Clinical Cases*, Mohsen Khosravi, MD, Assistant Professor, Department of Psychiatry and Clinical Psychology, Zahedan University of Medical Sciences, Zahedan 9819713955, Iran. m.khosravi@zaums.ac.ir

AIMS AND SCOPE

The primary aim of *World Journal of Clinical Cases* (WJCC, *World J Clin Cases*) is to provide scholars and readers from various fields of clinical medicine with a platform to publish high-quality clinical research articles and communicate their research findings online.

WJCC mainly publishes articles reporting research results and findings obtained in the field of clinical medicine and covering a wide range of topics, including case control studies, retrospective cohort studies, retrospective studies, clinical trials studies, observational studies, prospective studies, randomized controlled trials, randomized clinical trials, systematic reviews, meta-analysis, and case reports.

INDEXING/ABSTRACTING

The WJCC is now abstracted and indexed in Science Citation Index Expanded (SCIE, also known as SciSearch®), Journal Citation Reports/Science Edition, Current Contents®/Clinical Medicine, PubMed, PubMed Central, Scopus, Reference Citation Analysis, China National Knowledge Infrastructure, China Science and Technology Journal Database, and Superstar Journals Database. The 2022 Edition of Journal Citation Reports® cites the 2021 impact factor (IF) for WJCC as 1.534; IF without journal self cites: 1.491; 5-year IF: 1.599; Journal Citation Indicator: 0.28; Ranking: 135 among 172 journals in medicine, general and internal; and Quartile category: Q4. The WJCC's CiteScore for 2021 is 1.2 and Scopus CiteScore rank 2021: General Medicine is 443/826.

RESPONSIBLE EDITORS FOR THIS ISSUE

Production Editor: *Xu Guo*; Production Department Director: *Xiang Li*; Editorial Office Director: *Jin-Lei Wang*.

NAME OF JOURNAL

World Journal of Clinical Cases

ISSN

ISSN 2307-8960 (online)

LAUNCH DATE

April 16, 2013

FREQUENCY

Thrice Monthly

EDITORS-IN-CHIEF

Bao-Gan Peng, Jerzy Tadeusz Chudek, George Kontogeorgos, Maurizio Serati, Ja Hyeon Ku

EDITORIAL BOARD MEMBERS

<https://www.wjgnet.com/2307-8960/editorialboard.htm>

PUBLICATION DATE

September 6, 2022

COPYRIGHT

© 2022 Baishideng Publishing Group Inc

INSTRUCTIONS TO AUTHORS

<https://www.wjgnet.com/bpg/gerinfo/204>

GUIDELINES FOR ETHICS DOCUMENTS

<https://www.wjgnet.com/bpg/GerInfo/287>

GUIDELINES FOR NON-NATIVE SPEAKERS OF ENGLISH

<https://www.wjgnet.com/bpg/gerinfo/240>

PUBLICATION ETHICS

<https://www.wjgnet.com/bpg/GerInfo/288>

PUBLICATION MISCONDUCT

<https://www.wjgnet.com/bpg/gerinfo/208>

ARTICLE PROCESSING CHARGE

<https://www.wjgnet.com/bpg/gerinfo/242>

STEPS FOR SUBMITTING MANUSCRIPTS

<https://www.wjgnet.com/bpg/GerInfo/239>

ONLINE SUBMISSION

<https://www.f6publishing.com>



Discoid medial meniscus of both knees: A case report

Zhong-Ren Zheng, Hui Ma, Fei Yang, Long Yuan, Guo-Dong Wang, Xiao-Wei Zhao, Long-Fei Ma

Specialty type: Orthopedics

Provenance and peer review:

Unsolicited article; Externally peer reviewed.

Peer-review model: Single blind

Peer-review report's scientific quality classification

Grade A (Excellent): A

Grade B (Very good): B

Grade C (Good): C

Grade D (Fair): 0

Grade E (Poor): 0

P-Reviewer: Abulsoud MI, Egypt; Salimi M, Iran

Received: March 20, 2022

Peer-review started: March 20, 2022

First decision: June 16, 2022

Revised: June 29, 2022

Accepted: July 27, 2022

Article in press: July 27, 2022

Published online: September 6, 2022



Zhong-Ren Zheng, Long Yuan, School of Clinical Medicine, Jining Medical University, Jining 272067, Shandong Province, China

Hui Ma, Guo-Dong Wang, Xiao-Wei Zhao, Long-Fei Ma, Department of Orthopedics, The Affiliated Hospital of Jining Medical University, Jining 272000, Shandong Province, China

Fei Yang, Department of Orthopedics, The People's Hospital of Bozhou, Bozhou 236800, Anhui Province, China

Corresponding author: Long-Fei Ma, MD, Attending Doctor, Department of Orthopedics, The Affiliated Hospital of Jining Medical University, No. 89 Guhuai Road, Jining 272000, Shandong Province, China. doctormlf@yeah.net

Abstract

BACKGROUND

Discoid meniscus is a congenital anomaly that typically affects the lateral meniscus. The appearance of the discoid medial meniscus in both knees is extremely rare, with an incidence of only 0.012%.

CASE SUMMARY

Our patient was a 30-year-old female. Under no obvious predisposing causes, she began to experience pain in both knees, which worsened while walking and squatting. The pain was aggravated after exercise, and joint flexion and extension activities were accompanied by knee snapping. Apley's test was positive on physical examination, and there was a pressing pain in the medial articular space. Plain radiographs of both knees revealed no obvious abnormalities in the bilateral knee joint space. Partial meniscectomy as well as menisci reformation were performed on both knees under arthroscopy. Under the guidance of rehabilitation, the patient's range of motion in both knees returned to normal without pain and knee snapping.

CONCLUSION

This study showed that the clinical manifestations of the discoid medial meniscus injury are identical to those of the conventional medial meniscus injury, and arthroscopic surgery is effective.

Key Words: Medial discoid meniscus; Arthroscopy; Knee joint; Menisci reformation; Magnetic resonance imaging; Case report

©The Author(s) 2022. Published by Baishideng Publishing Group Inc. All rights reserved.

Core Tip: Discoid medial meniscus is very rare, and the bilateral discoid medial meniscus is extremely rare. We present the case of a 30-year-old female with features of a meniscal tear in two symptomatic knees and radiographic findings of discoid menisci in both knees. A provisional diagnosis of bilateral discoid medial menisci was made. Magnetic resonance imaging confirmed the discoid nature of the medial menisci in both knees. Both knees underwent partial meniscectomy and menisci reformation by arthroscopy. After 6 mo of follow-up, the patient had good clinical and functional outcomes.

Citation: Zheng ZR, Ma H, Yang F, Yuan L, Wang GD, Zhao XW, Ma LF. Discoid medial meniscus of both knees: A case report. *World J Clin Cases* 2022; 10(25): 9020-9027

URL: <https://www.wjgnet.com/2307-8960/full/v10/i25/9020.htm>

DOI: <https://dx.doi.org/10.12998/wjcc.v10.i25.9020>

INTRODUCTION

The meniscus is an annular wedge fibrous cartilage tissue with a thick edge and thin middle filling between the femur and tibia in the knee joint. The main function of the meniscus is to fill and lubricate the gap between the knee joint, making the upper and lower bones more stable, smooth, and uniformly stressed[1-3].

Discoid meniscus is an anatomical congenital abnormality in which the meniscus is thicker and larger than normal[4]. It usually affects the lateral meniscus of the knee joint and impacts both knees. The appearance of the discoid medial meniscus of the knee is extremely rare and even rarer in bilateral knees. Related reports show that the incidence of the discoid lateral meniscus is 1.2%–5.2%, and the incidence of the discoid meniscus on the medial meniscus is 0.12%–0.3%. The incidence of the bilateral knees with the discoid medial meniscus is only 0.012%[5,6]. Since Murdoch[7] reported the first case of the medial discoid meniscus in both knees in 1956, there have only been 20 reports of the medial discoid meniscus in both knees. In general, the bilateral discoid meniscus lesions do not cause notable clinical symptoms, and many people only visit the hospital when they experience severe pain, acid swelling, and motor dysfunction; thus, the actual incidence may be higher than the statistical data[8].

This article reports a patient with a medial discoid meniscus in both knees. Following magnetic resonance imaging (MRI) and arthroscopy confirmation of the diagnosis, partial meniscectomy as well as menisci reformation were performed on both knees by arthroscopy. The short-term follow-up results were satisfactory.

CASE PRESENTATION

Chief complaints

A 30-year-old female patient presented to our orthopedic outpatient clinic with pain in both knees with limited range of motion for more than 3 years.

History of present illness

Three years ago, under no obvious predisposing causes, she began to experience pain in both knees, which worsened while walking and squatting. The pain was aggravated after exercise, and joint flexion and extension activities were accompanied by knee snapping. She even displayed the symptom of joint locking.

History of past illness

The patient has no history of other diseases.

Personal and family history

The patient had no family or genetic disease history.

Physical examination

On specialized examination, the following results were observed: no bilateral knee joint swelling, normal skin temperature, no varus or valgus knee deformity, negative floating patella sign, positive Apley's test, pressing pain of the medial articular space, negative over-flexion test, positive McMurray test, negative drawer test, negative Lachman Test, and negative lateral stress test. The joint motion of the left knee was 0-110° and that of the right knee was 0-120°. The Lysholm score was 40.

Laboratory examinations

On preoperative laboratory examination, no abnormalities were found.

Imaging examinations

Plain radiographs of both knees revealed no significant abnormalities in the knee joint space (Figure 1). MRI is currently the imaging method of choice for diagnosing the discoid meniscus. The presence of three or more consecutive, 5-mm thick, sagittal images that demonstrate contiguity between the anterior and posterior horns of the meniscus is pathognomonic for discoid meniscus. The medial meniscus fills the medial joint space in the coronal view, extending to the medial side of the intercondylar fossa. However, the most accurate criterion for diagnosis is a ratio of the minimal meniscus width to the maximal tibial width of > 20% in the coronal plane. Three consecutive images at the sagittal position of the bilateral knee showed the anterior and posterior corners of the meniscus joined, body hypertrophy, and the medial meniscus was filled in the medial joint space extending to the intercondylar fossa in the coronal position. The medial meniscus showed a horizontal tear (Figures 2 and 3).

FINAL DIAGNOSIS

A medial discoid meniscus tear in both knees.

TREATMENT

After confirming the diagnosis of the meniscus injury in both knees with general anesthesia and a nerve block, the traditional anteromedial and anterolateral approaches under arthroscopy were used; thus, the left and right knee joints were explored successively. The intraoperative examination revealed left knee synovial hyperplasia, discoid medial meniscus, lamellar and longitudinal fissures, obvious edge relaxation, intermediate hypertrophy, intact lateral meniscus, and no obvious cruciate ligament or cartilage damage (Figure 4A). The examination of the right knee revealed synovial hyperplasia, discoid medial meniscus, lamellar and longitudinal fissures, obvious relaxation at the edge, hypertrophy in the middle, intact meniscus outside, and no obvious cruciate ligament or cartilage damage (Figure 4B). A partial meniscectomy was performed on both knees, and the discoid medial meniscus was reformed by saucerization.

The knee joint activity training, ankle pump exercise, and straight leg raising training were started immediately postoperatively; weight-bearing walking practice with crutches was started on the 1st postoperative day.

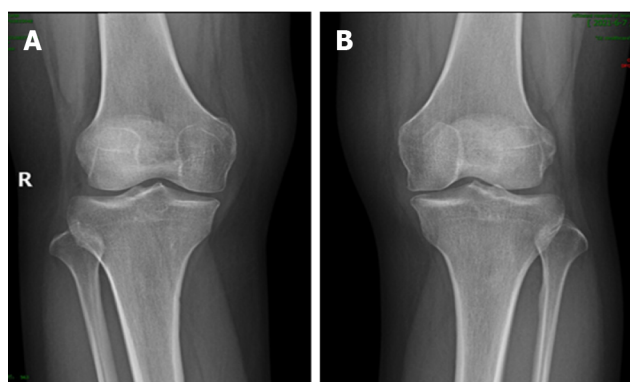
OUTCOME AND FOLLOW-UP

At the 1-mo postoperative follow-up, the wound had healed well and showed no signs of infection. The patient could walk without a brace, and normal activities were completely restored. Six months after the operation, outpatient and telephone follow-ups revealed that the joint motion of the bilateral knees was completely normal without pain and knee snapping. Her Lysholm score was raised to 95.

DISCUSSION

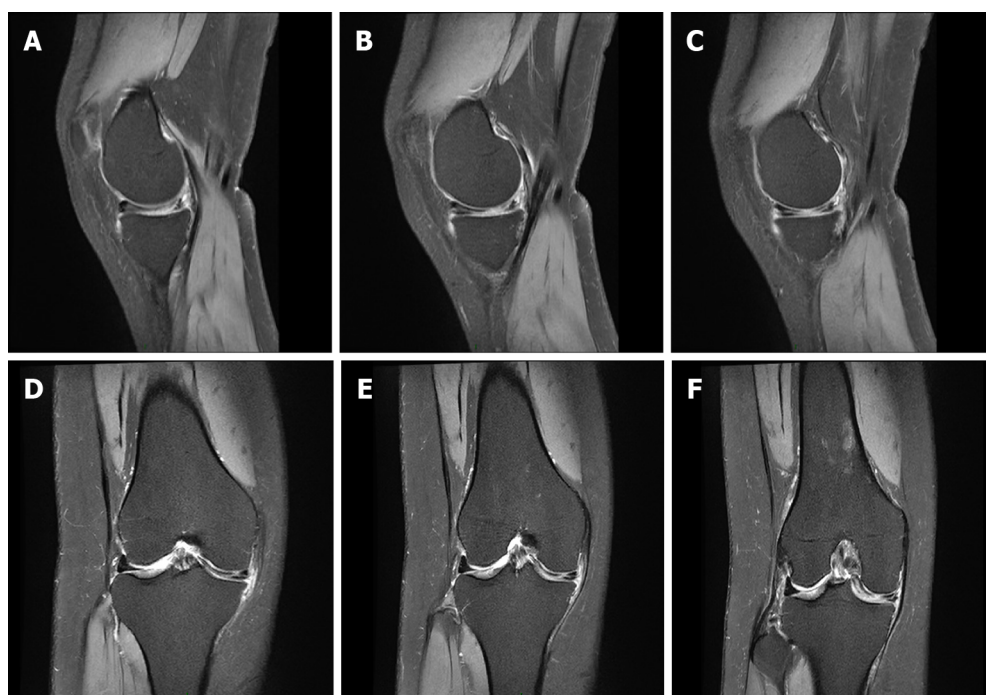
Congenital variations of the discoid meniscus always occur in the lateral meniscus of the knee. The medial discoid meniscus is rare, and cases of a discoid meniscus of the medial of both knees are even rarer. In 1889, an anatomical study by Young *et al*[9] found the first discoid meniscus in the lateral space of the knee joint, and people began to understand the discoid variation of the meniscus. In 1941, Cave [10] reported that the medial side of the knee joint can also have a discoid meniscus. Murdoch [7] reported the first case of the bilateral medial discoid meniscus in 1956. Since then, only 20 cases of the discoid meniscus on the medial knees have been reported.

Because most patients do not have any clinical symptoms, the current domestic and international studies on the incidence of the discoid medial meniscus have not been determined. Smillie [11] found 467 cases of the discoid lateral meniscus and only 7 (0.07%) cases of discoid medial meniscus among 10000 meniscectomy cases. Dickason *et al*[12], in a retrospective study of 14731 patients with a meniscus injury, studied 8040 cases of medial meniscus injury, of which only 10 (0.12%) cases were discoid meniscus, and 102 (1.5%) cases were discoid meniscus among 6691 cases of the lateral meniscus.



DOI: 10.12998/wjcc.v10.i25.9020 Copyright ©The Author(s) 2022.

Figure 1 X-ray. A and B: Representative radiographs of the knees show no abnormalities.

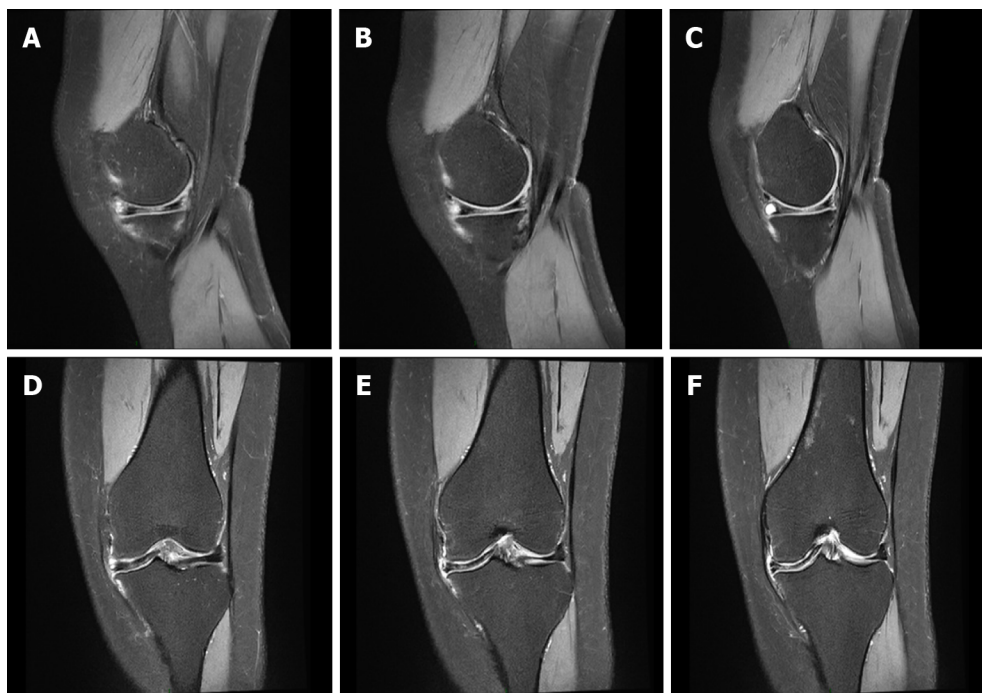


DOI: 10.12998/wjcc.v10.i25.9020 Copyright ©The Author(s) 2022.

Figure 2 Magnetic resonance imaging examination of the right knee. A-C: Three consecutive images in the sagittal view show a complete medial discoid meniscus; D-F: Coronal views showing a horizontal tear of the medial meniscus.

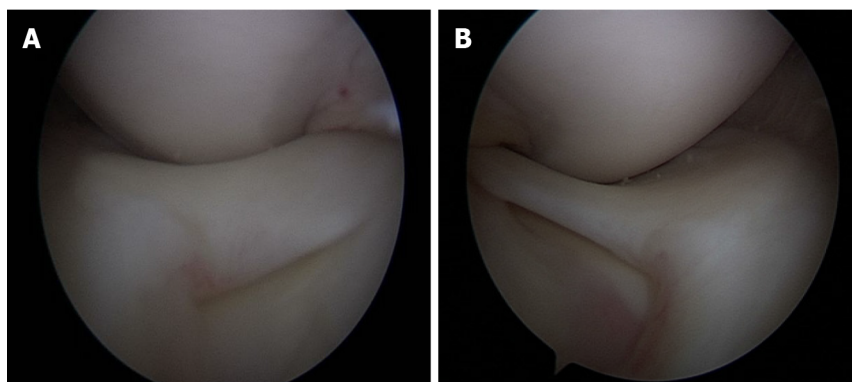
Discoid meniscus is more common in Asians than in westerners, whereas medial discoid meniscus is rare in both eastern and western populations. Fukuta *et al*[13] reported that the incidence of the discoid meniscus in China, Japan, and South Korea was approximately 13%. Kim *et al*[14] reported a discoid meniscus incidence of approximately 10.9% in South Korea. Rao *et al*[15] reported a study of 1643 knee arthroscopies in South Asia and found 95 cases of the discoid meniscus, with an incidence of 5.8%. Murlimanju *et al*[16] reported that the incidence of discoid lateral meniscus was approximately 17.9% in the autopsy of the South Indian population.

Currently, the causes of the discoid meniscus are unknown, and the hypotheses of strain hyperplasia, high mobility of the meniscus, embryonic development stagnation, genetic factors, and congenital factors are controversial[17]. Smillie[11] pointed out that the discoid meniscus is caused by a reabsorption disorder in the center of the cartilage disc from neonatal to adult development. Kaplan's [18] research showed that the meniscus in the early embryo was crescent-shaped rather than discoid. He believed mechanical stress factors, such as excessive root activity behind the meniscus, gradually formed the discoid meniscus. Ahmed Ali[19] reported a familial case of medial discoid meniscus tear, suggesting that discoid meniscus may be associated with a genetic abnormality. Recent studies have shown that a discoid meniscus is abnormal in both morphology and histomorphology. Papadopoulos *et al*[20] found that the collagen fibers in the discoid meniscus were heterogeneous leading to the destruction of the collagen network and speculated that this destruction weakened the ultrastructure of



DOI: 10.12998/wjcc.v10.i25.9020 Copyright ©The Author(s) 2022.

Figure 3 Magnetic resonance imaging examination of the left knee. A-C: Three consecutive images in the sagittal view show a complete medial discoid meniscus; D-F: Coronal views showing a horizontal tear of the medial meniscus.



DOI: 10.12998/wjcc.v10.i25.9020 Copyright ©The Author(s) 2022.

Figure 4 Arthroscopy. A: Left discoid medial meniscus; B: Right discoid medial meniscus.

the collagen, inducing a meniscus tear. However, there is no consensus on which theory of the medial discoid meniscus formation mechanism is correct.

Based on arthroscopic appearance, Watanabe *et al*[21] categorized the discoid meniscus into three different types: complete, incomplete, and Wrisberg-ligament type. This classification is currently the most widely used for lateral discoid meniscus. The size of the disc-shaped meniscus covering the tibial plateau determines the complete and incomplete types. In the Wrisberg-ligament type, only the Wrisberg ligament attaches to the lateral side of the medial femoral condyle, and structural abnormalities or the absence of the coronal ligament prevent the meniscus from properly attaching on the posterior side of the tibial plateau. As a result, the meniscus is pulled between the condyles when the knee is extended and repositioned when the knee is flexed. The lateral meniscus develops a secondary thickening and disc shape as a result of repeated abnormal activity and mechanical stimulation. At present, the medial discoid meniscus has only complete and incomplete types reported in the literature with no report on the Wrisberg-ligament type. Monllau *et al*[22] expanded on this basis with a fourth lateral discoid meniscus type: annular discoid meniscus with a normal attachment of the posterior horn of the meniscus to the posterior border of the tibial plateau. However, this additional classification is not used in clinical treatment decisions. Additionally, the value deserves further study.

The discoid meniscus is not strong enough to bear the body weight due to the shape and movement characteristics of the knee joint surface and is easily crushed and torn[23]. Because the medial articular surface of the knee is usually the primary weight-bearing part of the body, a medial disc meniscus tear is theoretically more likely than a lateral one. The most common symptom of a discoid medial meniscus injury is knee pain without obvious predisposing causes. Other symptoms depend on the stability of the meniscus[24]. When the meniscus is unstable, knee snapping may occur, and when the meniscus is torn, joint swelling, soft legs, and joint locking may occur. A positive McMurray's test can be detected during physical examination[25]. The mechanism of discoid medial meniscus injury is mainly through the internal knee rotation, and most of the injuries are longitudinal and lamellar fissures. Dickason *et al*[12] summarized the MRI findings of 18 cases of discoid meniscus injury on the medial side of the knee joint, including 10 cases of lamellar tears, 3 cases of Bucket-handle tears, 1 case of horizontal tear, and 4 cases without an obvious tear.

Because of the lack of typical clinical symptoms, the discoid meniscus is primarily diagnosed using MRI or arthroscopy. The MRI diagnosis of the discoid medial meniscus is the same as that of the discoid lateral meniscus[26]. The observations are as follows: the diagnosis is made when the anterior and posterior corners of the meniscus form a "bowknot" in the sagittal view, which can be seen at 3 or more continuous layers at 5-mm thickness intervals. At the coronal level, the discoid meniscus is diagnosed accurately when the ratio of the minimum meniscus width to the maximum tibial width is > 20%[27]. The X-ray film of the knee joint shows that the bony structure development is normal, but the extension of the edge of the discoid medial meniscus to the femoral intercondylar region of the femur can cause the widening of the medial space. The clinical manifestations are a "cup-like" appearance of the medial tibial plateau, the collapse of the proximal medial joint, flattening of the femoral condyle, and widening of the medial joint space[28]. With the widespread use of MRI, more cases of asymptomatic discoid medial meniscus are being diagnosed. However, MRI requires a lengthy examination and is unavailable in all centers. Moreover, it has limitations for claustrophobic patients or those with metal implants[29]. However, arthroscopy remains the "gold standard" for diagnosing a discoid meniscus.

The blood supply to the meniscus is very complex, with a very poor blood supply. As a result, it can barely heal on its own after injury, and conservative treatment is less effective. Meniscus repair surgery is often needed to relieve pain and restore joint function. Because the incidence of the discoid medial meniscus is very rare, there is no systematic summary of its treatment. Kramer *et al*[30] noted that the surgical indications for discoid medial meniscus injury are similar to those for normal meniscus, and asymptomatic discoid medial meniscus should be treated conservatively. If symptoms develop, surgery is required. The objective of the operation is to eliminate the symptoms and signs caused by the discoid meniscus while preserving as much meniscus function as possible.

Tachibana *et al*[31] performed arthroscopic menisci reformation on 4 cases of discoid medial meniscus, with satisfactory clinical results. Song *et al*[32] suggested that the central part of the discoid meniscus be removed during the formation of the discoid medial meniscus, while the intact meniscus tissue with a width of 6–8 mm be preserved. The short-term clinical effect of discoid meniscectomy is satisfactory, but the long-term effect is poor. Råber *et al*[33] studied 19.8 years of clinical follow-up after discoid lateral meniscus resection and found that the risk of osteoarthritis of the knee joint was significantly increased after discoid lateral meniscus resection.

In this study, the patient had obvious pain in the bilateral knees, which seriously affected her quality of life. Partial meniscectomy and menisci reformation were performed. The patient recovered well in postoperative follow-up. In general, whether to use partial or total meniscectomy is determined primarily by the location and severity of the discoid meniscus injury but also by the patients' age, whether associated with other injuries, the duration of symptoms, and the functional status of the knee joint itself. The meniscectomy of the discoid meniscus is best suited for older patients who have severe meniscus tears, poor meniscus texture, and so on[34]. Discoid menisci reformation is used to repair the meniscus to a natural arc and restore the thickness and width to normal ranges[35]. In general, the treatment of discoid meniscus must be individualized. Comprehensively, although the effect of arthroscopic treatment of discoid meniscus is satisfactory, a long follow-up is still needed to clarify its benefits and disadvantages[36].

CONCLUSION

Discoid meniscus on the medial knee is rare, and discoid meniscus of the bilateral knees is even rarer. A timely MRI examination of the knees can aid in preoperative diagnosis. When the discoid medial meniscus of the knee is detected on one side, an MRI examination of the contralateral knee is recommended to help the patient take preventive measures to avoid the recurrence of a similar injury in the contralateral asymptomatic knee. Arthroscopy is the "gold standard" for diagnosing and treating discoid meniscus. To diagnose discoid medial meniscus injury, comprehensive consideration of the patient's condition is essential.

ACKNOWLEDGEMENTS

We thank the patient for providing consent to publish this case report.

FOOTNOTES

Author contributions: Zheng ZR collected the data, imaging, and surgical reports and wrote the initial draft of the manuscript and subsequent revisions; Ma H and Yuan L were the primary physicians during the patient's hospital stay; Zhao XW, Wang GD, and Yang F were involved in editing and overseeing the text; Ma LF is the senior author who was the treating surgeon and was responsible for overseeing the report and editing the manuscript; All authors read and approved the final manuscript.

Supported by the National Natural Science Foundation of China, No. 81871814; and Jining City Key Research and Development Plan, No. 2021YXNS076.

Informed consent statement: The patient provided informed consent as evidenced by her signature.

Conflict-of-interest statement: The authors declare that they have no conflicts of interest.

CARE Checklist (2016) statement: The authors have read the CARE Checklist (2016), and the manuscript was prepared and revised following the CARE Checklist (2016).

Open-Access: This article is an open-access article that was selected by an in-house editor and fully peer-reviewed by external reviewers. It is distributed in accordance with the Creative Commons Attribution NonCommercial (CC BY-NC 4.0) license, which permits others to distribute, remix, adapt, build upon this work non-commercially, and license their derivative works on different terms, provided the original work is properly cited and the use is non-commercial. See: <https://creativecommons.org/licenses/by-nc/4.0/>

Country/Territory of origin: China

ORCID number: Zhong-Ren Zheng 0000-0002-0811-194X; Fei Yang 0000-0002-6665-6358; Long Yuan 0000-0001-8221-0615; Guo-Dong Wang 0000-0003-7596-8898; Xiao-Wei Zhao 0000-0003-3727-3112; Long-fei Ma 0000-0003-3419-6403.

S-Editor: Zhang H

L-Editor: Filipodia

P-Editor: Zhang H

REFERENCES

- 1 **Nguyen JC**, De Smet AA, Graf BK, Rosas HG. MR imaging-based diagnosis and classification of meniscal tears. *Radiographics* 2014; **34**: 981-999 [PMID: 25019436 DOI: 10.1148/rg.344125202]
- 2 **Hutchinson ID**, Moran CJ, Potter HG, Warren RF, Rodeo SA. Restoration of the meniscus: form and function. *Am J Sports Med* 2014; **42**: 987-998 [PMID: 23940202 DOI: 10.1177/0363546513498503]
- 3 **Barber BR**, McNally EG. Meniscal injuries and imaging the postoperative meniscus. *Radiol Clin North Am* 2013; **51**: 371-391 [PMID: 23622090 DOI: 10.1016/j.rcl.2012.10.008]
- 4 **Saavedra M**, Sepúlveda M, Jesús Tuca M, Birrer E. Discoid meniscus: current concepts. *EFORT Open Rev* 2020; **5**: 371-379 [PMID: 32818064 DOI: 10.1302/2058-5241.5.190023]
- 5 **Komatsu T**, Hashimoto Y, Sakanaka H, Gotani H, Yamano Y. Bilateral discoid medial menisci accompanied by distal arthrogryposis: a case report. *Knee Surg Sports Traumatol Arthrosc* 2007; **15**: 424-426 [PMID: 16983564 DOI: 10.1007/s00167-006-0178-7]
- 6 **Yang X**, Shao D. Bilateral discoid medial Meniscus: Two case reports. *Medicine (Baltimore)* 2019; **98**: e15182 [PMID: 30985708 DOI: 10.1097/MD.00000000000015182]
- 7 **MURDOCH G**. Congenital discoid medial semilunar cartilage. *J Bone Joint Surg Br* 1956; **38-B**: 564-566 [PMID: 13332004 DOI: 10.1302/0301-620X.38B2.564]
- 8 **Chico-Carpizo F**, Arauz de Robles S, Alonso-Hernández J. Symptomatic bilateral medial discoid meniscus treated with arthroscopic meniscal remodeling: clinical case. *Rev Esp Cir Ortop Traumatol (Engl Ed)* 2020; **64**: 350-354 [PMID: 32741686 DOI: 10.1016/j.recot.2020.02.005]
- 9 **Young RB**. The external semilunar cartilage as a complete disc. *Memoirs & Memoranda in Anatomy*
- 10 **Cave EF**. Congenital discoid meniscusA cause of internal derangement of the knee. *Am J Surg* 1941; **54**
- 11 **Smillie IS**. The congenital discoid meniscus. *J Bone Joint Surg Br* 1948; **30B**: 671-682 [PMID: 18894619]
- 12 **Dickason JM**, Del Pizzo W, Blazina ME, Fox JM, Friedman MJ, Snyder SJ. A series of ten discoid medial menisci. *Clin Orthop Relat Res* 1982; **75**: 75-79 [PMID: 6896680]
- 13 **Fukuta S**, Masaki K, Korai F. Prevalence of abnormal findings in magnetic resonance images of asymptomatic knees. *J Orthop Sci* 2002; **7**: 287-291 [PMID: 12077651 DOI: 10.1007/s007760200049]

- 14 **Kim SJ**, Lee YT, Kim DW. Intraarticular anatomic variants associated with discoid meniscus in Koreans. *Clin Orthop Relat Res* 1998; 202-207 [PMID: 9917685 DOI: 10.1097/00003086-199811000-00027]
- 15 **Rao PS**, Rao SK, Paul R. Clinical, radiologic, and arthroscopic assessment of discoid lateral meniscus. *Arthroscopy* 2001; 17: 275-277 [PMID: 11239348 DOI: 10.1053/jars.2001.19973]
- 16 **Murli Manju BV**, Nair N, Ray B, Pai MM, Amin S, Pai SR. Morphological variants of lateral meniscus of the knee: a cadaveric study in South Indian human fetuses. *Anat Sci Int* 2011; 86: 63-68 [PMID: 20549581 DOI: 10.1007/s12565-010-0088-0]
- 17 **Chen J**, Gao S, Chen B. Discoid medial meniscus with a horizontal cleavage tear: a juvenile who suffered for 3 years. *J Pediatr Orthop B* 2012; 21: 425-427 [PMID: 21912338 DOI: 10.1097/BPB.0b013e328349efba]
- 18 **Kaplan EB**. Discoid lateral meniscus of the knee joint; nature, mechanism, and operative treatment. *J Bone Joint Surg Am* 1957; 39-A: 77-87 [PMID: 13385265]
- 19 **Ahmed Ali R**, McKay S. Familial discoid medial meniscus tear in three members of a family: a case report and review of literature. *Case Rep Orthop* 2014; 2014: 285675 [PMID: 25548700 DOI: 10.1155/2014/285675]
- 20 **Papadopoulos A**, Kirkos JM, Kapetanos GA. Histomorphologic study of discoid meniscus. *Arthroscopy* 2009; 25: 262-268 [PMID: 19245988 DOI: 10.1016/j.arthro.2008.10.006]
- 21 **Watanabe M**, Ikeuchi H, Takeda S. Atlas of arthroscopy. Springer, 1978
- 22 **Monllau JC**, León A, Cugat R, Ballester J. Ring-shaped lateral meniscus. *Arthroscopy* 1998; 14: 502-504 [PMID: 9681543 DOI: 10.1016/s0749-8063(98)70079-9]
- 23 **Atay OA**, Doral MN, Leblebicioğlu G, Tetik O, Aydingöz U. Management of discoid lateral meniscus tears: observations in 34 knees. *Arthroscopy* 2003; 19: 346-352 [PMID: 12671616 DOI: 10.1053/jars.2003.50038]
- 24 **Tyler PA**, Jain V, Ashraf T, Saifuddin A. Update on imaging of the discoid meniscus. *Skeletal Radiol* 2022; 51: 935-956 [PMID: 34546382 DOI: 10.1007/s00256-021-03910-9]
- 25 **Lukas K**, Livock H, Kontio K, Carsen S. Bilateral Discoid Medial Menisci: A Case Report and Review of the Literature. *J Am Acad Orthop Surg Glob Res Rev* 2020; 4: e20.00069 [PMID: 32769707 DOI: 10.5435/JAAOSGlobal-D-20-00069]
- 26 **Luckenbill DB**, Peer CW. Ring-Shaped Lateral Meniscus Without a Bony Anterior Root Attachment. *Orthopedics* 2021; 44: e146-e147 [PMID: 33002180 DOI: 10.3928/01477447-20200923-06]
- 27 **Yaniv M**, Blumberg N. The discoid meniscus. *J Child Orthop* 2007; 1: 89-96 [PMID: 19308479 DOI: 10.1007/s11832-007-0029-1]
- 28 **Kim SJ**, Seo YJ. Bilateral discoid medial menisci: Incomplete type in one knee and complete type in opposite knee. *Knee* 2006; 13: 255-257 [PMID: 16531047 DOI: 10.1016/j.knee.2006.01.009]
- 29 **Sharafat Vaziri A**, Aghaghazvini L, Jahangiri S, Tahami M, Borazjani R, Tahmasebi MN, Rabie H, Mamaghani HJ, Vosoughi F, Salimi M. Determination of Normal Reference Values for Meniscal Extrusion Using Ultrasonography During the Different Range of Motion: A Pilot, Feasibility Study. *J Ultrasound Med* 2022 [PMID: 35137975 DOI: 10.1002/jum.15955]
- 30 **Kramer J**, Breitenseher M, Stöger A, Huber H, Scheurecker A. [MRI after meniscus and cruciate ligament surgery]. *Radiologe* 2006; 46: 36-45 [PMID: 16252126 DOI: 10.1007/s00117-005-1291-1]
- 31 **Tachibana Y**, Yamazaki Y, Ninomiya S. Discoid medial meniscus. *Arthroscopy* 2003; 19: E12-E18 [PMID: 12966402 DOI: 10.1016/s0749-8063(03)00688-1]
- 32 **Song IS**, Kim JB, Lee JK, Park BS. Discoid Medial Meniscus Tear, with a Literature Review of Treatments. *Knee Surg Relat Res* 2017; 29: 237-242 [PMID: 28854771 DOI: 10.5792/ksrr.15.054]
- 33 **Räber DA**, Friederich NF, Hefti F. Discoid lateral meniscus in children. Long-term follow-up after total meniscectomy. *J Bone Joint Surg Am* 1998; 80: 1579-1586 [PMID: 9840625 DOI: 10.2106/00004623-199811000-00003]
- 34 **Sevillano-Perez E**, Espejo-Reina A, Espejo-Reina MJ. Symptomatic Bilateral Torn Discoid Medial Meniscus Treated with Saucerization and Suture. *Case Rep Orthop* 2016; 2016: 8487194 [PMID: 27656305 DOI: 10.1155/2016/8487194]
- 35 **Franceschi F**, Longo UG, Ruzzini L, Simoni P, Zobel BB, Denaro V. Bilateral complete discoid medial meniscus combined with posterior cyst formation. *Knee Surg Sports Traumatol Arthrosc* 2007; 15: 266-268 [PMID: 16917782 DOI: 10.1007/s00167-006-0191-x]
- 36 **Kim SJ**, Lubis AM. Medial and lateral discoid menisci: a case report. *Sports Med Arthrosc Rehabil Ther Technol* 2010; 2: 21 [PMID: 20731824 DOI: 10.1186/1758-2555-2-21]



Published by **Baishideng Publishing Group Inc**
7041 Koll Center Parkway, Suite 160, Pleasanton, CA 94566, USA

Telephone: +1-925-3991568

E-mail: bpgoffice@wjgnet.com

Help Desk: <https://www.f6publishing.com/helpdesk>

<https://www.wjgnet.com>

