

World Journal of *Clinical Cases*

World J Clin Cases 2022 August 26; 10(24): 8432-8807



Contents

Thrice Monthly Volume 10 Number 24 August 26, 2022

EDITORIAL

- 8432** Evolution of *World Journal of Clinical Cases* over the past 5 years
Muthu S

OPINION REVIEW

- 8436** NF- κ B: A novel therapeutic pathway for gastroesophageal reflux disease?
Zhang ML, Ran LQ, Wu MJ, Jia QC, Qin ZM, Peng YG

MINIREVIEWS

- 8443** Obligate aerobic, gram-positive, weak acid-fast, nonmotile bacilli, *Tsukamurella tyrosinosolvens*: Minireview of a rare opportunistic pathogen
Usuda D, Tanaka R, Suzuki M, Shimozawa S, Takano H, Hotchi Y, Tokunaga S, Osugi I, Katou R, Ito S, Mishima K, Kondo A, Mizuno K, Takami H, Komatsu T, Oba J, Nomura T, Sugita M
- 8450** Diffusion tensor imaging pipeline measures of cerebral white matter integrity: An overview of recent advances and prospects
Safri AA, Nassir CMNCM, Iman IN, Mohd Taib NH, Achuthan A, Mustapha M
- 8463** Graft choices for anterolateral ligament knee reconstruction surgery: Current concepts
Chalidis B, Pitsilos C, Kitridis D, Givissis P
- 8474** Overview of the anterolateral complex of the knee
Garcia-Mansilla I, Zicaro JP, Martinez EF, Astoul J, Yacuzzi C, Costa-Paz M
- 8482** Complication of lengthening and the role of post-operative care, physical and psychological rehabilitation among fibula hemimelia
Salimi M, Sarallah R, Javanshir S, Mirghaderi SP, Salimi A, Khanzadeh S

ORIGINAL ARTICLE

Clinical and Translational Research

- 8490** Pyroptosis-related genes play a significant role in the prognosis of gastric cancer
Guan SH, Wang XY, Shang P, Du QC, Li MZ, Xing X, Yan B

Retrospective Study

- 8506** Effects of propofol combined with lidocaine on hemodynamics, serum adrenocorticotrophic hormone, interleukin-6, and cortisol in children
Shi S, Gan L, Jin CN, Liu RF
- 8514** Correlation analysis of national elite Chinese male table tennis players' shoulder proprioception and muscle strength
Shang XD, Zhang EM, Chen ZL, Zhang L, Qian JH

- 8525** Clinical value of contrast-enhanced ultrasound in early diagnosis of small hepatocellular carcinoma (≤ 2 cm)

Mei Q, Yu M, Chen Q

- 8535** Identification of predictive factors for post-transarterial chemoembolization liver failure in hepatocellular carcinoma patients: A retrospective study

Yuan M, Chen TY, Chen XR, Lu YF, Shi J, Zhang WS, Ye C, Tang BZ, Yang ZG

- 8547** Clinical significance of half-hepatic blood flow occlusion technology in patients with hepatocellular carcinoma with cirrhosis

Liu D, Fang JM, Chen XQ

- 8556** Which octogenarian patients are at higher risk after cholecystectomy for symptomatic gallstone disease? A single center cohort study

D'Acapito F, Solaini L, Di Pietrantonio D, Tauceri F, Mirarchi MT, Antelmi E, Flamini F, Amato A, Framarini M, Ercolani G

Clinical Trials Study

- 8568** Computed tomography combined with gastroscopy for assessment of pancreatic segmental portal hypertension

Wang YL, Zhang HW, Lin F

Observational Study

- 8578** Psychological needs of parents of children with complicated congenital heart disease after admitting to pediatric intensive care unit: A questionnaire study

Zhu JH, Jin CD, Tang XM

Prospective Study

- 8587** Quantitative differentiation of malignant and benign thyroid nodules with multi-parameter diffusion-weighted imaging

Zhu X, Wang J, Wang YC, Zhu ZF, Tang J, Wen XW, Fang Y, Han J

Randomized Controlled Trial

- 8599** Application of unified protocol as a transdiagnostic treatment for emotional disorders during COVID-19: An internet-delivered randomized controlled trial

Yan K, Yusufi MH, Nazari N

- 8615** High-flow nasal cannula oxygen therapy during anesthesia recovery for older orthopedic surgery patients: A prospective randomized controlled trial

Li XN, Zhou CC, Lin ZQ, Jia B, Li XY, Zhao GF, Ye F

SYSTEMATIC REVIEWS

- 8625** Assessment tools for differential diagnosis of neglect: Focusing on egocentric neglect and allocentric neglect

Lee SH, Lim BC, Jeong CY, Kim JH, Jang WH

CASE REPORT

- 8634** Exome analysis for Cronkhite-Canada syndrome: A case report
Li ZD, Rong L, He YJ, Ji YZ, Li X, Song FZ, Li XA
- 8641** Discrepancy between non-invasive prenatal testing result and fetal karyotype caused by rare confined placental mosaicism: A case report
Li Z, Lai GR
- 8648** Paroxysmal speech disorder as the initial symptom in a young adult with anti-N-methyl-D-aspartate receptor encephalitis: A case report
Hu CC, Pan XL, Zhang MX, Chen HF
- 8656** Anesthetics management of a renal angiomyolipoma using pulse pressure variation and non-invasive cardiac output monitoring: A case report
Jeon WJ, Shin WJ, Yoon YJ, Park CW, Shim JH, Cho SY
- 8662** Traumatic giant cell tumor of rib: A case report
Chen YS, Kao HW, Huang HY, Huang TW
- 8667** Analysis of two naval pilots' ejection injuries: Two case reports
Zeng J, Liu XP, Yi JC, Lu X, Liu DD, Jiang YQ, Liu YB, Tian JQ
- 8673** Beware of the DeBakey type I aortic dissection hidden by ischemic stroke: Two case reports
Chen SQ, Luo WL, Liu W, Wang LZ
- 8679** Unilateral lichen planus with Blaschko line distribution: A case report
Dong S, Zhu WJ, Xu M, Zhao XQ, Mou Y
- 8686** Clinical features and progress of ischemic gastritis with high fatalities: Seven case reports
Shionoya K, Sasaki A, Moriya H, Kimura K, Nishino T, Kubota J, Sumida C, Tasaki J, Ichita C, Makazu M, Masuda S, Koizumi K, Kawachi J, Tsukiyama T, Kako M
- 8695** Retinoblastoma in an older child with secondary glaucoma as the first clinical presenting symptom: A case report
Zhang Y, Tang L
- 8703** Recurrent herpes zoster in a rheumatoid arthritis patient treated with tofacitinib: A case report and review of the literature
Lin QX, Meng HJ, Pang YY, Qu Y
- 8709** Intra-abdominal ectopic bronchogenic cyst with a mucinous neoplasm harboring a *GNAS* mutation: A case report
Murakami T, Shimizu H, Yamazaki K, Nojima H, Usui A, Kosugi C, Shuto K, Obi S, Sato T, Yamazaki M, Koda K
- 8718** Effects of intravascular photobiomodulation on motor deficits and brain perfusion images in intractable myasthenia gravis: A case report
Lan CH, Wu YC, Chiang CC, Chang ST

- 8728** Spontaneous acute epidural hematoma secondary to skull and dural metastasis of hepatocellular carcinoma: A case report
Ly GZ, Li GC, Tang WT, Zhou D, Yang Y
- 8735** Malignant melanotic nerve sheath tumors in the spinal canal of psammomatous and non-psammomatous type: Two case reports
Yeom JA, Song YS, Lee IS, Han IH, Choi KU
- 8742** When should endovascular gastrointestinal anastomosis transection Glissonean pedicle not be used in hepatectomy? A case report
Zhao J, Dang YL
- 8749** VARS2 gene mutation leading to overall developmental delay in a child with epilepsy: A case report
Wu XH, Lin SZ, Zhou YQ, Wang WQ, Li JY, Chen QD
- 8755** Junctional bradycardia in a patient with COVID-19: A case report
Aedh AI
- 8761** Application of 3 dimension-printed injection-molded polyether ether ketone lunate prosthesis in the treatment of stage III Kienböck's disease: A case report
Yuan CS, Tang Y, Xie HQ, Liang TT, Li HT, Tang KL
- 8768** High scored thyroid storm after stomach cancer perforation: A case report
Baik SM, Pae Y, Lee JM
- 8775** Cholecystitis-an uncommon complication following thoracic duct embolization for chylothorax: A case report
Dung LV, Hien MM, Tra My TT, Luu DT, Linh LT, Duc NM
- 8782** Endometrial squamous cell carcinoma originating from the cervix: A case report
Shu XY, Dai Z, Zhang S, Yang HX, Bi H
- 8788** Type 2 autoimmune pancreatitis associated with severe ulcerative colitis: Three case reports
Ghali M, Bensted K, Williams DB, Ghaly S
- 8797** Diffuse uterine leiomyomatosis: A case report and review of literature
Ren HM, Wang QZ, Wang JN, Hong GJ, Zhou S, Zhu JY, Li SJ

LETTER TO THE EDITOR

- 8805** Comment on "Posterior reversible encephalopathy syndrome in a patient with metastatic breast cancer: A case report"
Kunić S, Ibrahimagić OČ, Kojić B, Džananović D

ABOUT COVER

Editorial Board Member of *World Journal of Clinical Cases*, Ahmed Mohamed Ahmed Al-Emam, PhD, Associate Professor, Department of Pathology, King Khalid University, Abha 62521, Saudi Arabia. amalemam@kku.edu.sa

AIMS AND SCOPE

The primary aim of *World Journal of Clinical Cases* (WJCC, *World J Clin Cases*) is to provide scholars and readers from various fields of clinical medicine with a platform to publish high-quality clinical research articles and communicate their research findings online.

WJCC mainly publishes articles reporting research results and findings obtained in the field of clinical medicine and covering a wide range of topics, including case control studies, retrospective cohort studies, retrospective studies, clinical trials studies, observational studies, prospective studies, randomized controlled trials, randomized clinical trials, systematic reviews, meta-analysis, and case reports.

INDEXING/ABSTRACTING

The WJCC is now abstracted and indexed in Science Citation Index Expanded (SCIE, also known as SciSearch®), Journal Citation Reports/Science Edition, Current Contents®/Clinical Medicine, PubMed, PubMed Central, Scopus, Reference Citation Analysis, China National Knowledge Infrastructure, China Science and Technology Journal Database, and Superstar Journals Database. The 2022 Edition of Journal Citation Reports® cites the 2021 impact factor (IF) for WJCC as 1.534; IF without journal self cites: 1.491; 5-year IF: 1.599; Journal Citation Indicator: 0.28; Ranking: 135 among 172 journals in medicine, general and internal; and Quartile category: Q4. The WJCC's CiteScore for 2021 is 1.2 and Scopus CiteScore rank 2021: General Medicine is 443/826.

RESPONSIBLE EDITORS FOR THIS ISSUE

Production Editor: *Ying-Yi Yuan*; Production Department Director: *Xu Guo*; Editorial Office Director: *Jin-Lei Wang*.

NAME OF JOURNAL

World Journal of Clinical Cases

ISSN

ISSN 2307-8960 (online)

LAUNCH DATE

April 16, 2013

FREQUENCY

Thrice Monthly

EDITORS-IN-CHIEF

Bao-Gan Peng, Jerzy Tadeusz Chudek, George Kontogeorgos, Maurizio Serati, Ja Hyeon Ku

EDITORIAL BOARD MEMBERS

<https://www.wjgnet.com/2307-8960/editorialboard.htm>

PUBLICATION DATE

August 26, 2022

COPYRIGHT

© 2022 Baishideng Publishing Group Inc

INSTRUCTIONS TO AUTHORS

<https://www.wjgnet.com/bpg/gerinfo/204>

GUIDELINES FOR ETHICS DOCUMENTS

<https://www.wjgnet.com/bpg/GerInfo/287>

GUIDELINES FOR NON-NATIVE SPEAKERS OF ENGLISH

<https://www.wjgnet.com/bpg/gerinfo/240>

PUBLICATION ETHICS

<https://www.wjgnet.com/bpg/GerInfo/288>

PUBLICATION MISCONDUCT

<https://www.wjgnet.com/bpg/gerinfo/208>

ARTICLE PROCESSING CHARGE

<https://www.wjgnet.com/bpg/gerinfo/242>

STEPS FOR SUBMITTING MANUSCRIPTS

<https://www.wjgnet.com/bpg/GerInfo/239>

ONLINE SUBMISSION

<https://www.f6publishing.com>



Junctional bradycardia in a patient with COVID-19: A case report

Abdullah Ibrahim Aedh

Specialty type: Infectious diseases

Provenance and peer review:

Unsolicited article; Externally peer reviewed.

Peer-review model: Single blind

Peer-review report's scientific quality classification

Grade A (Excellent): 0
Grade B (Very good): B, B
Grade C (Good): C
Grade D (Fair): 0
Grade E (Poor): 0

P-Reviewer: Hassan M, United States; Moreno-Gómez-Toledano R, Spain; Peng XC, China

Received: March 30, 2022

Peer-review started: March 30, 2022

First decision: June 16, 2022

Revised: June 29, 2022

Accepted: July 20, 2022

Article in press: July 20, 2022

Published online: August 26, 2022



Abdullah Ibrahim Aedh, Department of Internal Medicine, College of Medicine, Najran University, Najran 1988, Saudi Arabia

Corresponding author: Abdullah Ibrahim Aedh, MBBS, MD, Associate Professor, Department of Internal Medicine, College of Medicine, Najran University, King Abdulaziz Rd., Najran 1988, Saudi Arabia. dr.abuwaleed3733@hotmail.com

Abstract

BACKGROUND

Cardiac arrhythmias, including bradyarrhythmias, have been described as manifestations of coronavirus disease 2019 (COVID-19). Herein, we present a case of junctional bradycardia secondary to possible sinus node dysfunction in a patient with COVID-19.

CASE SUMMARY

The patient was a 32-year-old woman with no significant medical history. On the third day of hospitalization, she developed junctional bradycardia while being hemodynamically stable. The episodes of nodal dysrhythmia with a low heart rate persisted for the next few days and were associated with elevated levels of systemic inflammatory markers. The patient received antiviral and anti-inflammatory treatments for the viral infection but no antiarrhythmic medications. She had a normal sinus rhythm on day 12.

CONCLUSION

Cardiac rhythm monitoring, focusing on the association between cardiac arrhythmias and the systemic inflammatory response, is important in COVID-19 patients.

Key Words: Bradycardia; Case report; COVID-19; Heart rate; SARS-CoV-2; Sinus node dysfunction

©The Author(s) 2022. Published by Baishideng Publishing Group Inc. All rights reserved.

Core Tip: A variety of cardiovascular manifestations of COVID-19 have been described. Among these, bradyarrhythmias should be considered one of the main complications and clinical features of COVID-19. Herein, we present a case of junctional bradycardia in a patient with COVID-19. Bradyarrhythmias in COVID-19 patients has been linked to increased systemic inflammatory response and the subsequent dysfunctioning of the sino-atrial node. The inflammatory biomarker and cardiac rhythm monitoring should be considered in patients with COVID-19 during different stages of care.

Citation: Aedh AI. Junctional bradycardia in a patient with COVID-19: A case report. *World J Clin Cases* 2022; 10(24): 8755-8760

URL: <https://www.wjgnet.com/2307-8960/full/v10/i24/8755.htm>

DOI: <https://dx.doi.org/10.12998/wjcc.v10.i24.8755>

INTRODUCTION

Coronavirus disease 2019 (COVID-19) is caused by severe acute respiratory syndrome coronavirus-2 (SARS-CoV-2) and was declared a pandemic in March 2020 by the World Health Organization (WHO) [1]. Patients with COVID-19 have had various cardiovascular consequences throughout the pandemic, including acute cardiac damage, myocardial infarction, cardiogenic shock, acute congestive heart failure, and cardiac arrhythmias[2].

Bradyarrhythmia has been identified as a cardiac manifestation of COVID-19 in several studies. In a retrospective case series, Amaratunga *et al*[3] reported sinus bradycardia in four patients. These episodes lasted for 14 d. Transient sinus bradycardia may be a possible manifestation of COVID-19, and its development may be indicative of the onset of a severe cytokine storm. In another case series, severe bradyarrhythmias were reported in seven patients with COVID-19. The patients had or developed severe bradyarrhythmias during hospitalization and required pacing assistance. None of the patients had pre-existing cardiac diseases. Inflammatory marker levels were significantly elevated in all patients [4]. In another report, new-onset sinus bradycardia resulting from sinus node dysfunction in two elderly patients with COVID-19 was described by Peigh *et al*[5]. Both patients had persistent sinus bradycardia 2 wk after the onset of sinus node dysfunction. In a recent report from the United Arab Emirates, electrocardiogram (ECG) of a 36-year-old patient with COVID-19 revealed a junctional rhythm with atrial escape capture beats. A Holter study confirmed sinus node dysfunction with frequent pauses of the sinus node block alternating with sinus node arrest[6]. In a case series from India, bradyarrhythmias were reported in seven patients with COVID-19. Complete heart block was noted in five patients. Additionally, sick sinus syndrome was reported in two patients. Four of these patients had ventricular escape beats, and the remaining three had a junctional escape rhythm[7]. Herein, we describe a case of a patient with COVID-19 who developed junctional bradycardia.

CASE PRESENTATION

Chief complaints

A patient presented with chief complaints of headache, sore throat, dry cough, and fever for 3 d.

History of present illness

A 32-year old female presented with complaints of headache, sore throat, dry cough, and fever for 3 d. On presentation, the patient also complained of bone ache, fatigue, and malaise.

History of past illness

The patient had no significant past medical history.

Personal and family history

There was no family history of heart rhythm disorders.

Physical examination

The patient's physical examination revealed typical vital signs except for a body temperature of 38.9°C. The patient was hemodynamically stable and was not receiving any atrioventricular (AV) node blocking medications.

Laboratory examinations

Reverse transcription polymerase chain reaction for SARS-CoV-2 using a nasopharyngeal swab confirmed the presence of COVID-19. Laboratory findings revealed lymphopenia with a lymphocyte count of $0.88 \times 103/\mu\text{L}$ (reference range $1.0\text{--}4.0 \times 103/\mu\text{L}$), increased C-reactive protein (CRP) levels (95.79 mg/L ; reference range $< 10 \text{ mg/L}$), high serum ferritin levels ($171 \mu\text{g/L}$; reference range $12\text{--}150 \mu\text{g/L}$), and increased D-dimer levels (0.54 mg/L ; reference range $0\text{--}0.5 \text{ mg/L}$). The patient's alanine aminotransferase (115.1 U/L ; reference range $0\text{--}33 \text{ U/L}$) and aspartate aminotransferase (54.8 U/L ; reference range $0\text{--}32 \text{ U/L}$) levels were also elevated. There were no significant electrolyte abnormalities.

At baseline, the patient's ECG revealed atrial fibrillation with a slow ventricular response accompanied by moderately abnormal T waves. Three days later, the patient developed asymptomatic junctional bradycardia (Figure 1) with a heart rate of 47 beats per minute (BPM) while being awake. Her heart rate further dropped to 38 BPM during sleep. Moderate T wave abnormalities were observed. On day 5 after hospitalization, the ECG again revealed nodal arrhythmia. However, the patient was still asymptomatic and had good mobility and agility. Cardiac enzyme levels were normal, with a creatine kinase level of 48 U/L (reference range $39\text{--}308 \text{ U/L}$) and a creatine kinase-MB level of 12.3 U/L (reference range $0\text{--}25 \text{ U/L}$). Nodal dysrhythmia with bradycardia persisted for the next 4 days. The patient's CRP (216.15 mg/L ; reference range $< 10 \text{ mg/L}$) and D-dimer (0.84 mg/L ; reference range $0\text{--}0.5 \text{ mg/L}$) levels remained elevated during these episodes and became normal on day 12. Her CRP (4.38 mg/L ; reference range $< 10 \text{ mg/L}$) and D-dimer (0.36 mg/L ; reference range $0\text{--}0.5 \text{ mg/L}$) levels coincided with normal sinus rhythm.

Imaging examinations

The patient's chest computed tomography scan was normal.

FINAL DIAGNOSIS

The presence of clinical symptoms, such as new-onset fever, cough, and fatigue, along with these laboratory findings, are now known manifestations of COVID-19. The patient's ECG revealed junctional bradycardia.

TREATMENT

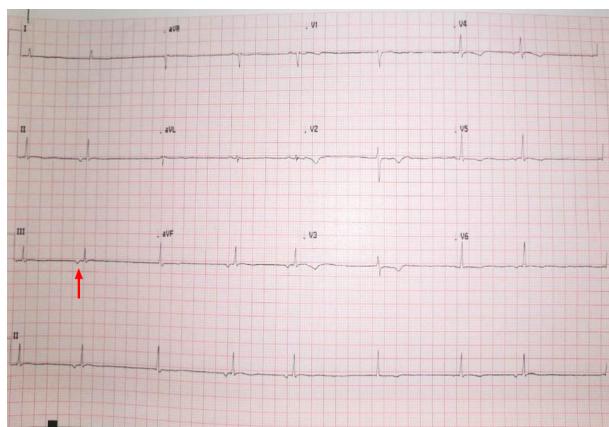
After confirmation of the diagnosis, the patient was started on the antiviral drug favipiravir at a dose of 1600 mg twice a day for 1 d, followed by 600 mg twice a day. She was also administered 8 mg of dexamethasone intravenously daily for its anti-inflammatory effects and 40 mg of subcutaneous enoxaparin daily as an anticoagulant. Additionally, the patient received intravenous paracetamol for fever, omeprazole as prophylaxis for gastrointestinal bleeding, and ondansetron for nausea (two doses).

OUTCOME AND FOLLOW-UP

The patient's symptoms significantly improved over the course of treatment. Besides the episodes of bradycardia, she was doing fine. On day 7, favipiravir was stopped following improvement in patient's condition. On day 9, she was discharged upon her request with the recommendation of daily ECG monitoring. The patient's heart rate gradually normalized and ECG on day 12 revealed a normal sinus rhythm (Figure 2). Figure 3 depicted the chronological flowchart of the patient's treatment course.

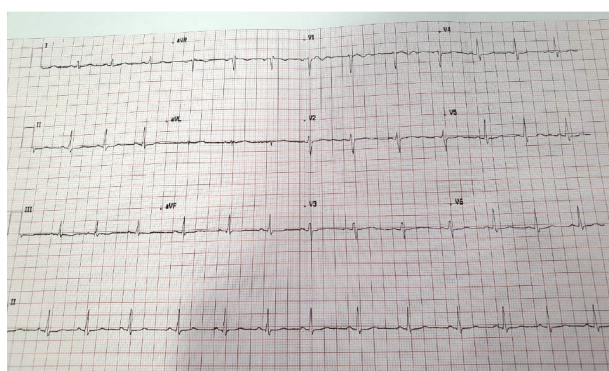
DISCUSSION

An array of cardiovascular complications of COVID-19, including cardiac arrhythmias, has been previously reported. However, the mechanisms underlying cardiac involvement in COVID-19 remain poorly understood. Multiple mechanisms may contribute to the development of arrhythmias in these patients. COVID-19 may cause acute bradycardia events by the following mechanisms: direct infiltration of myocardial cells and the conduction system *via* angiotensin-converting enzyme-2 (ACE2) receptors, aggravation of pre-existing conduction diseases during acute illness, cardiac injury, hemodynamic instability, alteration in the intrinsic cardiac nervous system leading to autonomic dysfunction, a secondary effect of hypoxia caused by pulmonary injury, electrolyte abnormalities, and an enhanced systemic inflammatory response[7-10]. SARS-CoV-2 may also activate the ACE2 receptor by utilizing the spike protein to enter the host cell. This event leads to down-regulation of ACE2 receptors and has been associated with conduction disturbances subsequent to adverse myocardial



DOI: 10.12998/wjcc.v10.i24.8755 Copyright ©The Author(s) 2022.

Figure 1 Patient's electrocardiograph showing junctional bradycardia. The inverted P wave, a key sign of junctional bradycardia, was shown by the red arrow.



DOI: 10.12998/wjcc.v10.i24.8755 Copyright ©The Author(s) 2022.

Figure 2 Patient's electrocardiograph showing normal sinus rhythm.

remodeling[9,10].

The patient developed junctional bradycardia, a slow heart rhythm that originates from the AV node instead of the sinoatrial (SA) node. It can develop from pathology in the SA node causing it to fail as a pacemaker, or from pathology in the AV node, causing it to misfire. While the patient's cardiac biomarker levels were normal, she had elevated levels of systemic inflammatory markers throughout the arrhythmic events. High levels of inflammatory mediators, such as cytokines, may directly affect the SA node and the conduction system, leading to the development of bradycardia. This event might have been the cause of bradycardia in our patient. Notably, the patient developed junctional bradycardia on day 6 of the illness, which is within the cytokine storm's onset timetable, similar to the case reported by Amaratunga *et al*[3].

The incidence of arrhythmias is often associated with disease severity[9,10]. However, in our case, the patient's condition was not severe and did not require admission to the intensive care unit. The patient did not receive any corrective treatment for bradycardia, as the episodes were asymptomatic and short-lived.

The patient had no pre-existing cardiac conduction abnormalities or structural heart disease, and she was not taking any AV node blocking medications that could have provoked bradycardia. The episodes of bradycardia in our patient may partly result from possible dysfunction of the sinus node by the direct or indirect effect of SARS-CoV-2 and systemic illness on the cardiovascular system.

Drugs used to treat COVID-19 may also contribute to conduction system disturbances[7-10]. Since dexamethasone was first assumed to be the cause of bradycardia, it was stopped on day 3. Dexamethasone was restarted after nodal dysrhythmia with bradycardia persisted from day 5 onwards, along with increased systemic inflammatory markers. In a recent case report from Qatar, favipiravir was attributed to asymptomatic severe sinus bradycardia with a heart rate of 30 BPM in a middle-aged woman. After the drug was stopped, the event resolved[11]. In addition, in the WHO database, bradycardia has been reported as a suspected adverse drug event to favipiravir[12]. However, in our case, the event of junctional bradycardia persisted even after the favipiravir was stopped on day 7 and the patient's heart rate gradually normalized as her condition improved on day 12 of presentation.

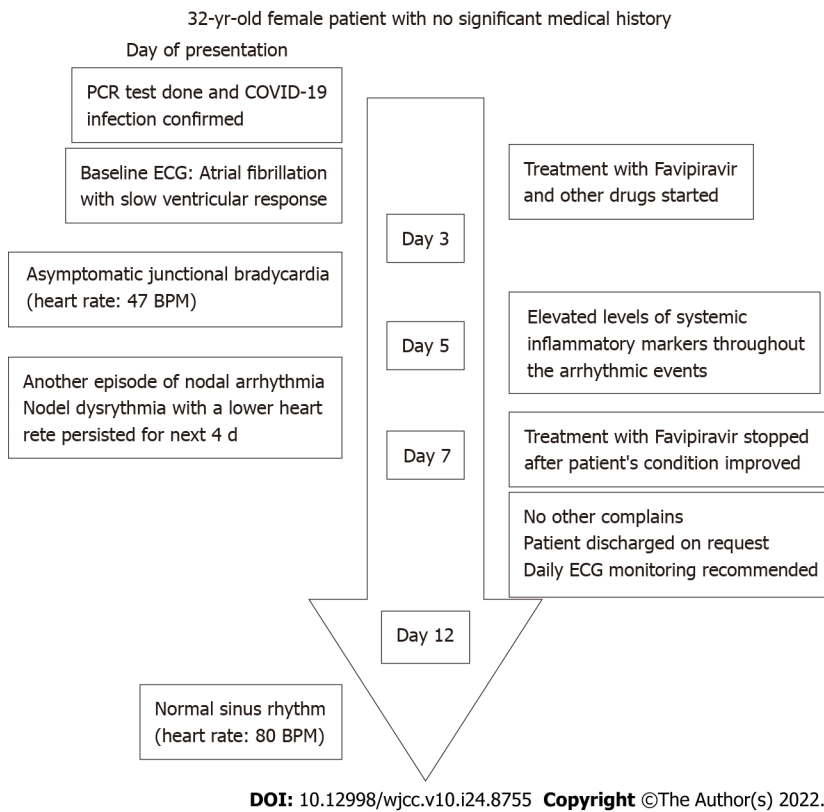


Figure 3 Patient's flowchart. BPM: Beats per minute; COVID-19: Coronavirus disease 2019; ECG: Electrocardiograph; PCR: Polymerase chain reaction.

CONCLUSION

Patients with COVID-19 are increasingly presenting with bradyarrhythmias. The specific mechanisms fundamental to the development of bradyarrhythmias in these patients remain indistinct, and they may be multifactorial. The development of bradyarrhythmias can be considered a clinical feature of COVID-19, which could imply cardiac involvement. Therefore, cardiac rhythm monitoring should be performed during therapy, recovery, and discharge and cardiac and inflammatory biomarker monitoring should also be considered.

FOOTNOTES

Author contributions: The author confirms being the sole contributor of this work and has approved it for publication.

Informed consent statement: Written informed consent was obtained from the patient for publication of this case report and any accompanying images.

Conflict-of-interest statement: The author declares no conflict of interest.

CARE Checklist (2016) statement: The author has read the CARE Checklist (2016), and the manuscript was prepared and revised according to the CARE Checklist (2016).

Open-Access: This article is an open-access article that was selected by an in-house editor and fully peer-reviewed by external reviewers. It is distributed in accordance with the Creative Commons Attribution NonCommercial (CC BY-NC 4.0) license, which permits others to distribute, remix, adapt, build upon this work non-commercially, and license their derivative works on different terms, provided the original work is properly cited and the use is non-commercial. See: <https://creativecommons.org/licenses/by-nc/4.0/>

Country/Territory of origin: Saudi Arabia

ORCID number: Abdullah Ibrahim Aedh 0000-0001-9831-4240.

S-Editor: Zhang H

L-Editor: A

P-Editor: Zhang H

REFERENCES

- 1 **World Health Organization.** Director-General's opening remarks at the media briefing on COVID-19. 2020 Mar 11 [cited 4 October 2021]. Available from: <https://www.who.int/director-general/speeches/detail/who-director-general-s-openingremarks-at-the-media-briefing-on-covid-19---11-march-2020>
- 2 **Long B**, Brady WJ, Koyfman A, Gottlieb M. Cardiovascular complications in COVID-19. *Am J Emerg Med* 2020; **38**: 1504-1507 [PMID: [32317203](#) DOI: [10.1016/j.ajem.2020.04.048](#)]
- 3 **Amaratunga EA**, Corwin DS, Moran L, Snyder R. Bradycardia in Patients With COVID-19: A Calm Before the Storm? *Cureus* 2020; **12**: e8599 [PMID: [32550090](#) DOI: [10.7759/cureus.8599](#)]
- 4 **Chinitz JS**, Goyal R, Harding M, Veseli G, Gruberg L, Jadonath R, Maccaro P, Gandotra P, Ong L, Epstein LM. Bradyarrhythmias in patients with COVID-19: Marker of poor prognosis? *Pacing Clin Electrophysiol* 2020; **43**: 1199-1204 [PMID: [32820823](#) DOI: [10.1111/pace.14042](#)]
- 5 **Peigh G**, Leya MV, Baman JR, Canteo EP, Knight BP, Flaherty JD. Novel coronavirus 19 (COVID-19) associated sinus node dysfunction: a case series. *Eur Heart J Case Rep* 2020; **4**: 1-6 [PMID: [33089039](#) DOI: [10.1093/ehjcr/ytta132](#)]
- 6 **Eid MM.** COVID-19 patient with symptomatic bradycardia. *Vis J Emerg Med* 2021; **22**: 100920 [PMID: [33200102](#) DOI: [10.1016/j.visj.2020.100920](#)]
- 7 **Gupta MD**, Qamar A, Mp G, Safal S, Batra V, Basia D, Mandal SK, Yusuf J, Mukhopadhyay S, Bansal A. Bradyarrhythmias in patients with COVID-19: A case series. *Indian Pacing Electrophysiol J* 2020; **20**: 211-212 [PMID: [32822746](#) DOI: [10.1016/j.ipej.2020.08.004](#)]
- 8 **Kochi AN**, Tagliari AP, Forleo GB, Fassini GM, Tondo C. Cardiac and arrhythmic complications in patients with COVID-19. *J Cardiovasc Electrophysiol* 2020; **31**: 1003-1008 [PMID: [32270559](#) DOI: [10.1111/jce.14479](#)]
- 9 **Dherange P**, Lang J, Qian P, Oberfeld B, Sauer WH, Koplan B, Tedrow U. Arrhythmias and COVID-19: A Review. *JACC Clin Electrophysiol* 2020; **6**: 1193-1204 [PMID: [32972561](#) DOI: [10.1016/j.jacep.2020.08.002](#)]
- 10 **Babapoor-Farrokhran S**, Rasekhi RT, Gill D, Babapoor S, Amanullah A. Arrhythmia in COVID-19. *SN Compr Clin Med* 2020; **2**: 1430-1435 [PMID: [32838188](#) DOI: [10.1007/s42399-020-00454-2](#)]
- 11 **Habib MB**, Elshafei M, Rahhal A, Mohamed MFH. Severe sinus bradycardia associated with favipiravir in a COVID-19 patient. *Clin Case Rep* 2021; **9**: e04566 [PMID: [34401155](#) DOI: [10.1002/ccr3.4566](#)]
- 12 **Kaur RJ**, Charan J, Dutta S, Sharma P, Bhardwaj P, Lugova H, Krishnapillai A, Islam S, Haque M, Misra S. Favipiravir Use in COVID-19: Analysis of Suspected Adverse Drug Events Reported in the WHO Database. *Infect Drug Resist* 2020; **13**: 4427-4438 [PMID: [33364790](#) DOI: [10.2147/IDR.S287934](#)]



Published by **Baishideng Publishing Group Inc**
7041 Koll Center Parkway, Suite 160, Pleasanton, CA 94566, USA

Telephone: +1-925-3991568

E-mail: bpgoffice@wjgnet.com

Help Desk: <https://www.f6publishing.com/helpdesk>

<https://www.wjgnet.com>

