

World Journal of *Clinical Cases*

World J Clin Cases 2022 October 6; 10(28): 9970-10390



Contents

Thrice Monthly Volume 10 Number 28 October 6, 2022

REVIEW

- 9970 COVID-19 and the heart

Xanthopoulos A, Bourazana A, Giamouzis G, Skoularigki E, Dimos A, Zagouras A, Papamichalis M, Leventis I, Magouliotis DE, Triposkiadis F, Skoularigis J

- 9985 Role of short chain fatty acids in gut health and possible therapeutic approaches in inflammatory bowel diseases

Caetano MAF, Castelucci P

MINIREVIEWS

- 10004 Review of the pharmacological effects of astragaloside IV and its autophagic mechanism in association with inflammation

Yang Y, Hong M, Lian WW, Chen Z

ORIGINAL ARTICLE

Clinical and Translational Research

- 10017 Effects of targeted-edited oncogenic insulin-like growth factor-1 receptor with specific-sgRNA on biological behaviors of HepG2 cells

Yao M, Cai Y, Wu ZJ, Zhou P, Sai WL, Wang DF, Wang L, Yao DF

Retrospective Study

- 10031 Analysis of the successful clinical treatment of 140 patients with parathyroid adenoma: A retrospective study

Peng ZX, Qin Y, Bai J, Yin JS, Wei BJ

- 10042 Efficacy of digital breast tomosynthesis combined with magnetic resonance imaging in the diagnosis of early breast cancer

Ren Y, Zhang J, Zhang JD, Xu JZ

- 10053 Prevention and management of adverse events following COVID-19 vaccination using traditional Korean medicine: An online survey of public health doctors

Kang B, Chu H, Youn BY, Leem J

- 10066 Clinical outcomes of targeted therapies in elderly patients aged ≥ 80 years with metastatic colorectal cancer

Jang HR, Lee HY, Song SY, Lim KH

- 10077 Endovascular treatment vs drug therapy alone in patients with mild ischemic stroke and large infarct cores

Kou WH, Wang XQ, Yang JS, Qiao N, Nie XH, Yu AM, Song AX, Xue Q

Clinical Trials Study

- 10085** One hundred and ninety-two weeks treatment of entecavir maleate for Chinese chronic hepatitis B predominantly genotyped B or C

Xu JH, Wang S, Zhang DZ, Yu YY, Si CW, Zeng Z, Xu ZN, Li J, Mao Q, Tang H, Sheng JF, Chen XY, Ning Q, Shi GF, Xie Q, Zhang XQ, Dai J

Observational Study

- 10097** Dementia-related contact experience, attitudes, and the level of knowledge in medical vocational college students

Liu DM, Yan L, Wang L, Lin HH, Jiang XY

SYSTEMATIC REVIEWS

- 10109** Link between COVID-19 vaccines and myocardial infarction

Zafar U, Zafar H, Ahmed MS, Khattak M

CASE REPORT

- 10120** Successful treatment of disseminated nocardiosis diagnosed by metagenomic next-generation sequencing: A case report and review of literature

Li T, Chen YX, Lin JJ, Lin WX, Zhang WZ, Dong HM, Cai SX, Meng Y

- 10130** Multiple primary malignancies - hepatocellular carcinoma combined with splenic lymphoma: A case report

Wu FZ, Chen XX, Chen WY, Wu QH, Mao JT, Zhao ZW

- 10136** Metastatic multifocal melanoma of multiple organ systems: A case report

Maksimaityte V, Reivytyte R, Milaknyte G, Mickys U, Razanskiene G, Stundys D, Kazenaite E, Valantinas J, Stundiene I

- 10146** Cavernous hemangioma of the ileum in a young man: A case report and review of literature

Yao L, Li LW, Yu B, Meng XD, Liu SQ, Xie LH, Wei RF, Liang J, Ruan HQ, Zou J, Huang JA

- 10155** Successful management of a breastfeeding mother with severe eczema of the nipple beginning from puberty: A case report

Li R, Zhang LX, Tian C, Ma LK, Li Y

- 10162** Short benign ileocolonic anastomotic strictures - management with bi-flanged metal stents: Six case reports and review of literature

Kasapidis P, Mavrogenis G, Mandrekas D, Bazerbachi F

- 10172** Simultaneous bilateral floating knee: A case report

Wu CM, Liao HE, Lan SJ

- 10180** Chemotherapy, transarterial chemoembolization, and nephrectomy combined treated one giant renal cell carcinoma (T3aN1M1) associated with Xp11.2/TFE3: A case report

Wang P, Zhang X, Shao SH, Wu F, Du FZ, Zhang JF, Zuo ZW, Jiang R

- 10186** Tislelizumab-related enteritis successfully treated with adalimumab: A case report

Chen N, Qian MJ, Zhang RH, Gao QQ, He CC, Yao YK, Zhou JY, Zhou H

- 10193** Treatment of refractory/relapsed extranodal NK/T cell lymphoma with decitabine plus anti-PD-1: A case report
Li LJ, Zhang JY
- 10201** Clinical analysis of pipeline dredging agent poisoning: A case report
Li YQ, Yu GC, Shi LK, Zhao LW, Wen ZX, Kan BT, Jian XD
- 10208** Follicular lymphoma with cardiac involvement in a 90-year-old patient: A case report
Sun YX, Wang J, Zhu JH, Yuan W, Wu L
- 10214** Twin reversed arterial perfusion sequence-a rare and dangerous complication form of monochorionic twins: A case report
Anh ND, Thu Ha NT, Sim NT, Toan NK, Thuong PTH, Duc NM
- 10220** Potential otogenic complications caused by cholesteatoma of the contralateral ear in patients with otogenic abscess secondary to middle ear cholesteatoma of one ear: A case report
Zhang L, Niu X, Zhang K, He T, Sun Y
- 10227** Myeloid sarcoma with ulnar nerve entrapment: A case report
Li DP, Liu CZ, Jeremy M, Li X, Wang JC, Nath Varma S, Gai TT, Tian WQ, Zou Q, Wei YM, Wang HY, Long CJ, Zhou Y
- 10236** Alpha-fetoprotein-producing hepatoid adenocarcinoma of the lung responsive to sorafenib after multiline treatment: A case report
Xu SZ, Zhang XC, Jiang Q, Chen M, He MY, Shen P
- 10244** Acute mesenteric ischemia due to percutaneous coronary intervention: A case report
Ding P, Zhou Y, Long KL, Zhang S, Gao PY
- 10252** Persistent diarrhea with petechial rash - unusual pattern of light chain amyloidosis deposition on skin and gastrointestinal biopsies: A case report
Bilton SE, Shah N, Dougherty D, Simpson S, Holliday A, Sahebjam F, Grider DJ
- 10260** Solitary splenic tuberculosis: A case report
Guo HW, Liu XQ, Cheng YL
- 10266** Coronary artery aneurysms caused by Kawasaki disease in an adult: A case report and literature review
He Y, Ji H, Xie JC, Zhou L
- 10273** Double filtration plasmapheresis for pregnancy with hyperlipidemia in glycogen storage disease type Ia: A case report
Wang J, Zhao Y, Chang P, Liu B, Yao R
- 10279** Treatment of primary tracheal schwannoma with endoscopic resection: A case report
Shen YS, Tian XD, Pan Y, Li H
- 10286** Concrescence of maxillary second molar and impacted third molar: A case report
Su J, Shao LM, Wang LC, He LJ, Pu YL, Li YB, Zhang WY

- 10293** Rare leptin in non-alcoholic fatty liver cirrhosis: A case report
Nong YB, Huang HN, Huang JJ, Du YQ, Song WX, Mao DW, Zhong YX, Zhu RH, Xiao XY, Zhong RX
- 10301** One-stage resection of four genotypes of bilateral multiple primary lung adenocarcinoma: A case report
Zhang DY, Liu J, Zhang Y, Ye JY, Hu S, Zhang WX, Yu DL, Wei YP
- 10310** Ectopic pregnancy and failed oocyte retrieval during *in vitro* fertilization stimulation: Two case reports
Zhou WJ, Xu BF, Niu ZH
- 10317** Malignant peritoneal mesothelioma with massive ascites as the first symptom: A case report
Huang X, Hong Y, Xie SY, Liao HL, Huang HM, Liu JH, Long WJ
- 10326** Subperiosteal orbital hematoma concomitant with abscess in a patient with sinusitis: A case report
Hu XH, Zhang C, Dong YK, Cong TC
- 10332** Postpartum posterior reversible encephalopathy syndrome secondary to preeclampsia and cerebrospinal fluid leakage: A case report and literature review
Wang Y, Zhang Q
- 10339** Sudden extramedullary and extranodal Philadelphia-positive anaplastic large-cell lymphoma transformation during imatinib treatment for CML: A case report
Wu Q, Kang Y, Xu J, Ye WC, Li ZJ, He WF, Song Y, Wang QM, Tang AP, Zhou T
- 10346** Relationship of familial cytochrome P450 4V2 gene mutation with liver cirrhosis: A case report and review of the literature
Jiang JL, Qian JF, Xiao DH, Liu X, Zhu F, Wang J, Xing ZX, Xu DL, Xue Y, He YH
- 10358** COVID-19-associated disseminated mucormycosis: An autopsy case report
Kyuno D, Kubo T, Tsujiwaki M, Sugita S, Hosaka M, Ito H, Harada K, Takasawa A, Kubota Y, Takasawa K, Ono Y, Magara K, Narimatsu E, Hasegawa T, Osanai M
- 10366** Thalidomide combined with endoscopy in the treatment of Cronkhite-Canada syndrome: A case report
Rong JM, Shi ML, Niu JK, Luo J, Miao YL
- 10375** Thoracolumbar surgery for degenerative spine diseases complicated with tethered cord syndrome: A case report
Wang YT, Mu GZ, Sun HL

LETTER TO THE EDITOR

- 10384** Are pregnancy-associated hypertensive disorders so sweet?
Thomopoulos C, Ilias I
- 10387** Tumor invasion front in oral squamous cell carcinoma
Cuevas-González JC, Cuevas-González MV, Espinosa-Cristobal LF, Donohue Cornejo A

ABOUT COVER

Editorial Board Member of *World Journal of Clinical Cases*, Kaleem Ullah, FCPS, MBBS, Assistant Professor, Solid Organ Transplantation and Hepatobiliary Surgery, Pir Abdul Qadir Shah Jeelani Institute of Medical Sciences, Gambat 66070, Sindh, Pakistan. drkaleempk@gmail.com

AIMS AND SCOPE

The primary aim of *World Journal of Clinical Cases* (WJCC, *World J Clin Cases*) is to provide scholars and readers from various fields of clinical medicine with a platform to publish high-quality clinical research articles and communicate their research findings online.

WJCC mainly publishes articles reporting research results and findings obtained in the field of clinical medicine and covering a wide range of topics, including case control studies, retrospective cohort studies, retrospective studies, clinical trials studies, observational studies, prospective studies, randomized controlled trials, randomized clinical trials, systematic reviews, meta-analysis, and case reports.

INDEXING/ABSTRACTING

The WJCC is now abstracted and indexed in Science Citation Index Expanded (SCIE, also known as SciSearch®), Journal Citation Reports/Science Edition, Current Contents®/Clinical Medicine, PubMed, PubMed Central, Scopus, Reference Citation Analysis, China National Knowledge Infrastructure, China Science and Technology Journal Database, and Superstar Journals Database. The 2022 Edition of Journal Citation Reports® cites the 2021 impact factor (IF) for WJCC as 1.534; IF without journal self cites: 1.491; 5-year IF: 1.599; Journal Citation Indicator: 0.28; Ranking: 135 among 172 journals in medicine, general and internal; and Quartile category: Q4. The WJCC's CiteScore for 2021 is 1.2 and Scopus CiteScore rank 2021: General Medicine is 443/826.

RESPONSIBLE EDITORS FOR THIS ISSUE

Production Editor: *Xu Guo*; Production Department Director: *Xiang Li*; Editorial Office Director: *Jin-Lei Wang*.

NAME OF JOURNAL

World Journal of Clinical Cases

ISSN

ISSN 2307-8960 (online)

LAUNCH DATE

April 16, 2013

FREQUENCY

Thrice Monthly

EDITORS-IN-CHIEF

Bao-Gan Peng, Jerzy Tadeusz Chudek, George Kontogeorgos, Maurizio Serati, Ja Hyeon Ku

EDITORIAL BOARD MEMBERS

<https://www.wjnet.com/2307-8960/editorialboard.htm>

PUBLICATION DATE

October 6, 2022

COPYRIGHT

© 2022 Baishideng Publishing Group Inc

INSTRUCTIONS TO AUTHORS

<https://www.wjnet.com/bpg/gerinfo/204>

GUIDELINES FOR ETHICS DOCUMENTS

<https://www.wjnet.com/bpg/GerInfo/287>

GUIDELINES FOR NON-NATIVE SPEAKERS OF ENGLISH

<https://www.wjnet.com/bpg/gerinfo/240>

PUBLICATION ETHICS

<https://www.wjnet.com/bpg/GerInfo/288>

PUBLICATION MISCONDUCT

<https://www.wjnet.com/bpg/gerinfo/208>

ARTICLE PROCESSING CHARGE

<https://www.wjnet.com/bpg/gerinfo/242>

STEPS FOR SUBMITTING MANUSCRIPTS

<https://www.wjnet.com/bpg/GerInfo/239>

ONLINE SUBMISSION

<https://www.f6publishing.com>

Tislelizumab-related enteritis successfully treated with adalimumab: A case report

Na Chen, Min-Jia Qian, Ru-Hui Zhang, Qi-Qi Gao, Chao-Chao He, Ya-Ke Yao, Jian-Ying Zhou, Hua Zhou

Specialty type: Pharmacology and pharmacy

Provenance and peer review: Unsolicited article; Externally peer reviewed.

Peer-review model: Single blind

Peer-review report's scientific quality classification

Grade A (Excellent): 0
Grade B (Very good): B, B
Grade C (Good): 0
Grade D (Fair): D
Grade E (Poor): 0

P-Reviewer: Dauey K, Kazakhstan; He DH, China; Poddighe D, Kazakhstan

Received: April 22, 2022

Peer-review started: April 22, 2022

First decision: June 8, 2022

Revised: June 17, 2022

Accepted: August 25, 2022

Article in press: August 25, 2022

Published online: October 6, 2022



Na Chen, Chao-Chao He, Department of Clinical Pharmacy, The First Affiliated Hospital, Zhejiang University School of Medicine, Hangzhou 310003, Zhejiang Province, China

Min-Jia Qian, Ru-Hui Zhang, Ya-Ke Yao, Jian-Ying Zhou, Hua Zhou, Department of Respiratory and Critical Care Medicine, The First Affiliated Hospital, Zhejiang University School of Medicine, Hangzhou 310003, Zhejiang Province, China

Min-Jia Qian, Department of Critical Care Medicine, Zhuji People's Hospital, Shaoxing 311800, Zhejiang Province, China

Qi-Qi Gao, Department of Pathology, The First Affiliated Hospital, Zhejiang University School of Medicine, Hangzhou 310003, Zhejiang Province, China

Chao-Chao He, Department of Pharmacy, Yiwu Central Hospital, Jinhua 322000, Zhejiang Province, China

Corresponding author: Hua Zhou, MD, Associate Chief Physician, Department of Respiratory and Critical Care Medicine, The First Affiliated Hospital, Zhejiang University School of Medicine, No. 79 Qingchun Road, Shangcheng District, Hangzhou 310003, Zhejiang Province, China. zhouhua1@zju.edu.cn

Abstract

BACKGROUND

With programmed death-1 (PD-1) inhibitors becoming the standard treatment for lung cancer, PD-1-related adverse reactions and treatment have gradually become prominent.

CASE SUMMARY

First reported case of tislelizumab-related enteritis successfully treated with adalimumab 40mg every 2 wk for 3 times in an advanced lung cancer patient who received first-line tislelizumab/pemetrexed/carboplatin for 4 cycles. The patient continued receiving the treatment of pemetrexed/carboplatin after symptoms, abdominal computed tomography and colonoscopy improved, significant diarrhea was not occurred.

CONCLUSION

Adalimumab can be an effective treatment option for patients with PD-1 antibody related enteritis if they do not respond well to glucocorticoid treatment.

Key Words: Tislelizumab; Adalimumab; Enteritis; Case report

©The Author(s) 2022. Published by Baishideng Publishing Group Inc. All rights reserved.

Core Tip: A patient with advanced lung cancer who developed diarrhea after receiving tislelizumab combined with pemetrexed and carboplatin, with poor response to glucocorticoid treatment. The symptoms were significantly improved after the use of adalimumab 10 mg, subcutaneous injection, every 2 wk for 3 times. Colonoscopy and intestinal mucosal pathology suggested improvement.

Citation: Chen N, Qian MJ, Zhang RH, Gao QQ, He CC, Yao YK, Zhou JY, Zhou H. Tislelizumab-related enteritis successfully treated with adalimumab: A case report. *World J Clin Cases* 2022; 10(28): 10186-10192

URL: <https://www.wjgnet.com/2307-8960/full/v10/i28/10186.htm>

DOI: <https://dx.doi.org/10.12998/wjcc.v10.i28.10186>

INTRODUCTION

With programmed death-1 (PD-1) inhibitors alone or combination as first-line treatment for advanced non-small lung cancer, treatment for PD-1-related adverse reactions also becomes one of challenges in cancer treatment. Tislelizumab (TISL), a humanized monoclonal antibody against PD-1[1], was launched in China in 2019. Compared with other PD-1 inhibitors, the biggest difference of TISL was modified in the constant region of the monoclonal antibody to remove its binding ability to FcγR receptor, so that it could no longer bind to type II macrophages with Fcγ receptor, thus the macrophages would no longer attack the T cells, thereby reducing the exhaustion of T cells and the potential mechanism of anti-PD-1 therapy resistance[1,2]. Grade 3-4 adverse events due to TISL have been reported to be about 10%, with a diarrhea incidence of < 1%[3,4]. Herein, we report the first use, to our knowledge, of adalimumab (ADA) in combination with methylprednisolone for TISL-related severe enteritis. The patient's symptoms were essentially relieved with treatment and he continued to receive chemotherapy-related treatment.

CASE PRESENTATION

Chief complaints

61-year-old man with diagnosis diarrhea, who was referred to our institution on day 19 after the last treatment for lung cancer, because of symptoms were aggravated, with the frequency of diarrhea up to 20-30 times/d.

History of present illness

The patient was diagnosed with lung cancer (right lung adenocarcinoma with multiple subcutaneous muscle metastases, cT3N2M1c, stage IV, KRAS mutation (G12C), PDL-1 50%) on September 14, 2020. From September 17, 2020 to December 2, 2020, the patient was given treatment of chemotherapy (pemetrexed 900 mg and Carboplatin 600 mg) plus TISL 200 mg every 21 to 28 d for 4 cycles. The date of the fourth treatment is December 2, 2020. Before the fourth treatment, the lung computed tomography (CT) showed that the lesion was smaller than that at diagnosis, and the subcutaneous nodule in buttock disappeared. The treatment result was assessed as partial response. On day 10 after the last treatment (hereafter day 10), the patient began to have fever (T_{max} 39.0 °C), abdominal pain, and diarrhea (watery stools, more than 10 times/d). After defecation, the abdominal pain could be relieved. The patient was suspected of gastroenteritis and received drugs for anti-infection, antidiarrheal, rehydration and other symptomatic treatment at local hospital.

History of past illness

The patient's past medical history was unremarkable except for hypertension.

Personal and family history

No positive personal or family history.

Physical examination

The patient had stable vital signs. Abdominal examination: flat and soft, positive tenderness, negative

rebound tenderness, hyperactive bowel sounds, 6 times/min.

Laboratory examinations

Routine laboratory tests of a same-day showed white blood cells: $8.5 \times 10^9/L$, C-reactive protein: 80.0 mg/L, procalcitonin: 0.13 ng/mL, interleukin-6: 2.04 pg/mL, interleukin-10 (IL-10): 2.57 pg/mL. A clinical diagnosis of PD-1 inhibitors induced enteritis was made, and the patient was asked to fast and oral methylprednisolone 16 mg bid was started. Subsequent tests for cytomegalovirus DNA, bacteria cultured in blood and feces, WBC and *Clostridium difficile* in stool were negative, fecal calprotectin was significantly increased to 218.4 ug/g.

Imaging examinations

Abdominal contrast-enhanced CT revealed edema and thickening of the small intestine, ascending colon, transverse colon, sigmoid colon, and rectum in the middle and lower abdomen, and multiple small diverticula in the blind ascending colon (Figure 1A and B). Colonoscopy showed extensive congestion and edema of the terminal ileum and colorectal mucosa (Figure 2A and B). Intestinal mucosal pathological examination revealed chronic inflammations of the mucosa with moderated dysplasia of glandular epithelium, and chronic inflammation of the mucosa with moderate-severe dysplasia of the glandular epithelium (Figure 3A and B).

FINAL DIAGNOSIS

Diagnosis of PD-1 antibody induced enteritis was confirmed.

TREATMENT

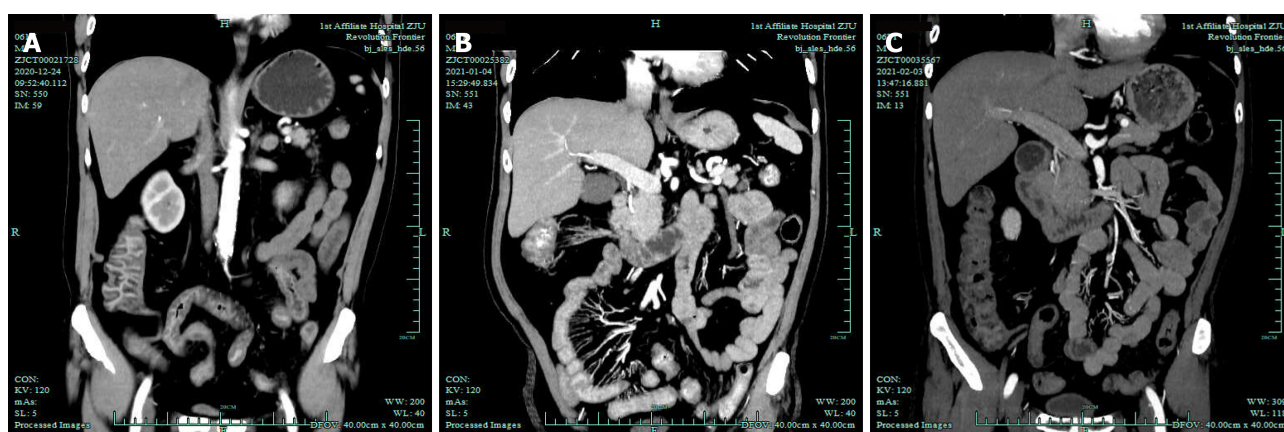
The patient was asked to fast and oral methylprednisolone 16 mg bid was started. On day 21, methylprednisolone was increased to 40 mg q12h intravenously, montmorillonite powder and probiotic treatment also were given. On day 23, ADA (biosimilar, HS016, China) 40 mg began to administered subcutaneously every 2 wk (on days 23, 37, 51) because previous treatments were ineffective. Fasting and intravenous nutritional support were also given, as well as drugs for symptomatic treatment including mesalazine, somatostatin, and loperamide. On day 29, the frequency of diarrhea decreased and the symptom of diarrhea disappeared on day 34. The patient tried to be given a small amount of liquid diet, but abdominal pain and diarrhea symptoms repeated after eating. the symptoms were improved after giving pinaverium bromide, during which montmorillonite powder, somatostatin, mesalamine and probiotics were gradually discontinued. On day 37, Methylprednisolone began to reduce to 40 mg qd intravenously, and the patient discharged on day 47 with methylprednisolone 16 mg bid po. The treatment process would be showed in Figure 4.

OUTCOME AND FOLLOW-UP

The patient had no abdominal pain, diarrhea, nausea or vomiting after discharge, and underwent abdominal enhanced CT and colonoscopy again on day 64. Abdominal CT showed no significant edema compared with before, and there were multiple small diverticula in the ascending colon (Figure 1C); Colonoscopy showed that the ileal mucosa was approximately normal, the ileocecal valve was labial, congested and eroded, the ileocecal junction and the ascending and transverse colon were scattered, the whole colon and rectal mucosa were congested, swollen and brittle (Figure 2C and D), and intestinal mucosal pathology revealed (ileocecal junction, ascending colon, transverse colon, descending colon, rectum) mucosal epithelial detachment and erosion, inflammatory granulation tissue hyperplasia was significantly reduced compared with the previous time (Figure 3C and D). On day 65, the patient continued to receive chemotherapy, once every 3-4 wk. There was no obvious diarrhea after chemotherapy. The dose of methylprednisolone was tapered to 8 mg/d after about 3 mo, and the tapering process was uneventful.

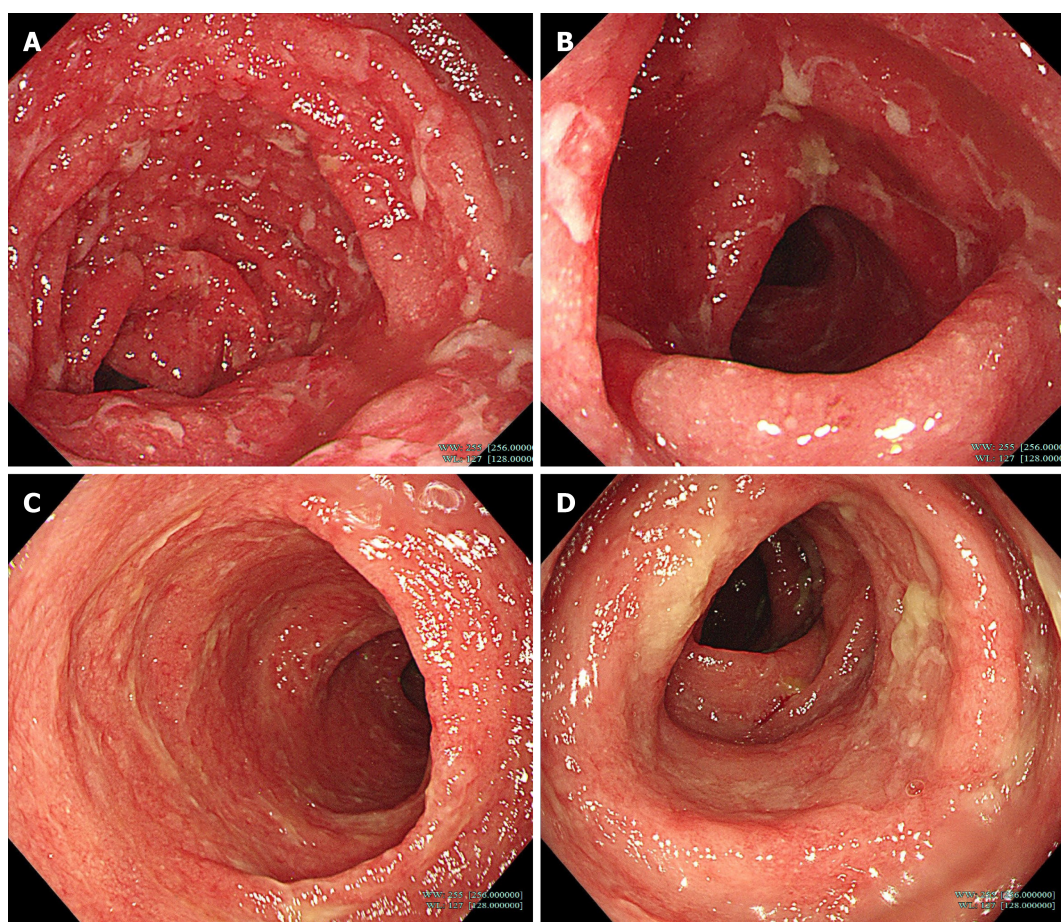
DISCUSSION

The majority of adverse events (AEs) reported in clinical trials related to TISL were grade 1-2, with the most common grade 3-4 AEs being hematotoxicity, followed by pneumonitis (2%) and colitis (0.5%-1%) [2,5]. The patient developed severe diarrhea after receiving 4 cycles of TISL combined with chemotherapy. The cause of infection was excluded, and it was considered to be TISL-induced immune-



DOI: 10.12998/wjcc.v10.i28.10186 Copyright ©The Author(s) 2022.

Figure 1 Abdominal contrast-enhanced computed tomography image of the patient at different stages of disease. A: Edema and thickening of the small intestine, ascending colon, transverse colon, sigmoid colon, and rectum in the middle and lower abdomen, and multiple small diverticula in the blind ascending colon; B: The small intestine and colon wall were still obviously edematous, which was similar to the computed tomography findings 10 d ago; C: No significant edema, and there were multiple small diverticula in the ascending colon.



DOI: 10.12998/wjcc.v10.i28.10186 Copyright ©The Author(s) 2022.

Figure 2 Colonoscopy manifestations of patients at different stages of disease. A and B: Extensive congestion and edema of the terminal ileum and colorectal mucosa, and necrosis and shedding on day 20; C and D: On day 64 showed that the mucosa in the venue was approximately normal, and there was still congestion and swelling of the whole colon and rectal mucosa, which was significantly improved than before.

related enteritis (Adverse Drug Reaction Probability Scale[6] score was 7). For the management of severe immune checkpoint inhibitor-induced enteritis, the guidelines[7,8] recommend prednisone/methylprednisolone at 1-2 mg/kg/day for 2 d, followed by the infliximab (IFX) and its analogues or vedolizumab for poor response. At that time, we could not obtain vedolizumab quickly, therefore considered the use of anti-tumor necrosis factor- α (TNF- α) monoclonal antibody. In contrast to

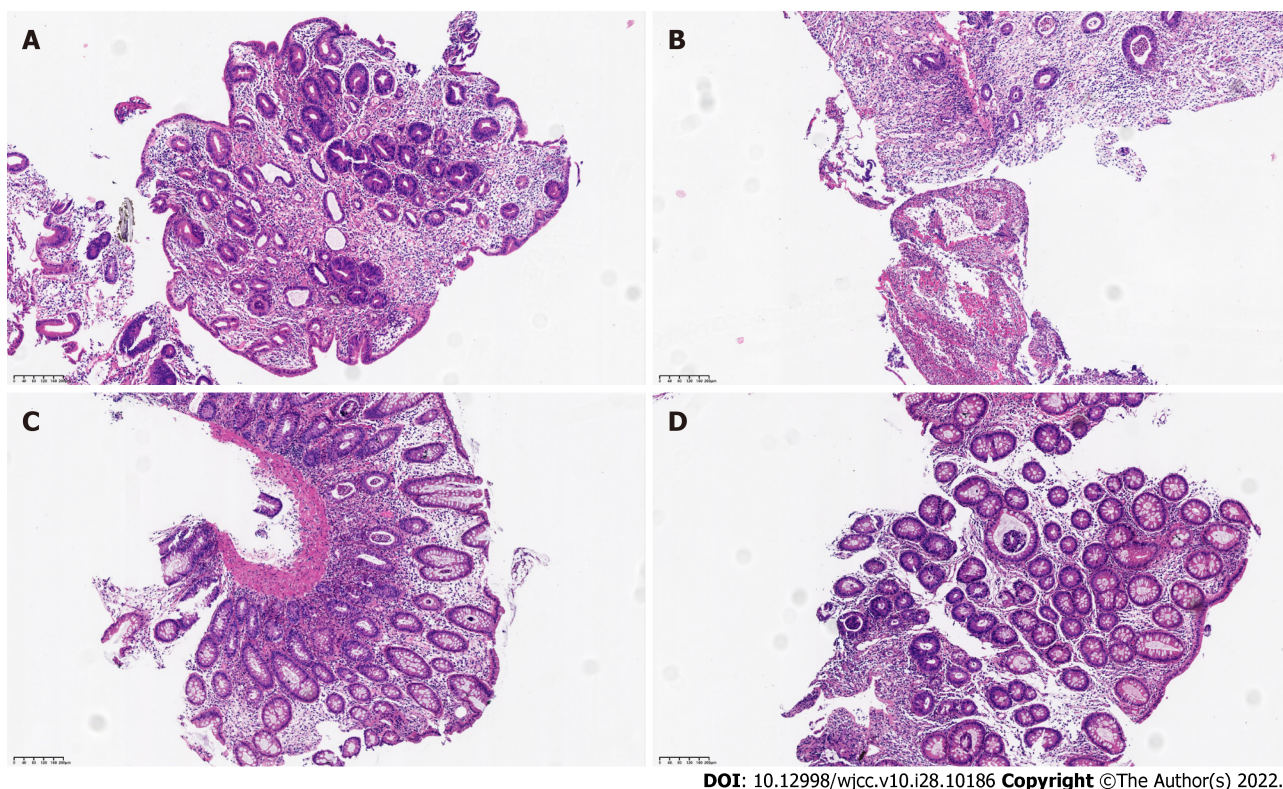


Figure 3 Pathological sections were examined by colonoscopy. Intestinal mucosal pathological examination revealed chronic inflammation of the mucosa (ileum, ascending colon, and descending colon) with moderate dysplasia of the glandular epithelium, and chronic inflammation of the mucosa (transverse colon and rectum) with moderate-severe dysplasia of the glandular epithelium. A: For the ileocecal junction on day 20; B: For the descending colon on day 20, mucosal epithelial sloughing erosion were not significant compared with the previous colonoscopy, but were still accompanied by moderate atypia and crypt abscess; C: For the ileocecal junction on day 64; D: For the descending colon on day 64.

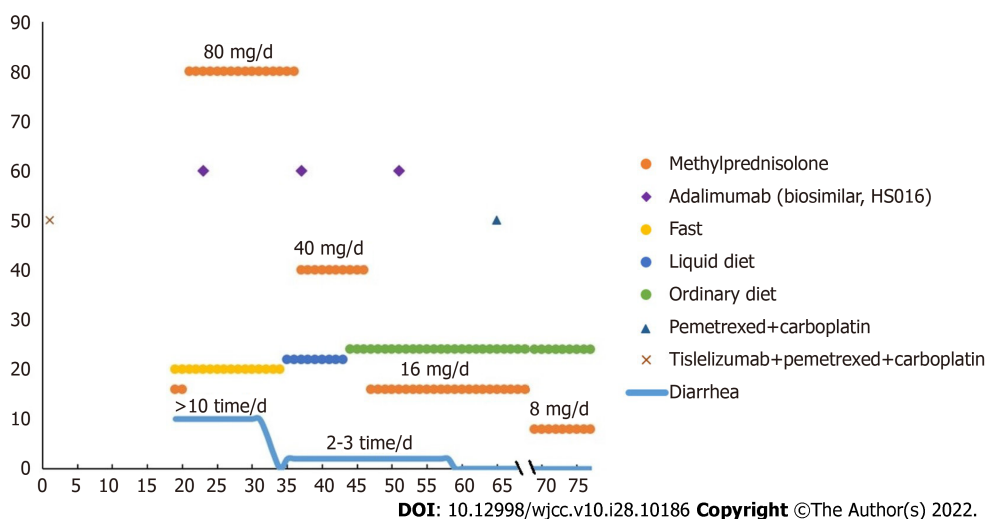


Figure 4 Treatment of tislelizumab-related enteritis.

the 25% murine chimeric monoclonal antibody of infliximab (IFX), ADA is a fully human monoclonal antibody that binds TNF- α . ADA has been approved with about 17 indications worldwide, including Crohn's disease, ulcerative colitis, rheumatoid arthritis and ankylosing spondylitis. ADA (biosimilar, HS016, China) is approved in China for rheumatoid arthritis, ankylosing spondylitis and psoriasis. Although the pathophysiology of immune checkpoint inhibitor-mediated immune-related adverse events (irAEs) were not yet fully understood, the role of immune checkpoint pathways in autoimmune diseases provides some clues: irAEs may be caused by some combination of autoreactive T cells, autoantibodies, and/or inflammatory cytokines, such as interleukin-17[9,10]. One potential mechanism is T-cell activity against antigens present in tumor cells and healthy tissues[11,12]. Inflammation in other

normal tissues may result from increased levels of inflammatory cytokines that are downstream effects of T cell activation[13,14]. It has been shown that the intestinal lamina propria of PD-1 inhibitor-induced enteritis is characterized by CD8 + T cell infiltration, accompanied by a certain concentration of TNF- α , and Treg cells predominate similar to inflammatory bowel disease[15]. ADA can prevent the significant decrease in intestinal mucosal epithelial resistance caused by TNF- α and prevent the internalization of tight junction proteins after cytokine exposure, and can also reverse the TNF- α -induced down-regulation of connexin-1, claudin-2, claudin-4, occludin and the activation of PI3K signaling in T-84 cells, thereby preventing barrier dysfunction induced by TNF- α at the functional and structural as well as at the signaling level[16].

The patient received subcutaneous injection of ADA 40 mg once every two weeks after poor response after treatment with 1-2 mg/kg methylprednisolone for 2 d. The symptoms began to improve 6 d after the first injection of ADA, the dose of methylprednisolone was gradually reduced after the second injection because of the symptoms gradually improved. The second colonoscopy and pathological sections also confirmed that the mucosal epithelial detachment and erosion were significantly improved than before. This case is the first report of enteritis caused by PD-1 inhibitors treated with ADA, and there has been a previous case of arthritis caused by pembrolizumab treated with ADA[17].

CONCLUSION

PD-1 inhibitor may also cause other colonic diseases than enteritis, for example acute diverticulitis[18], whether colonoscopy and pathological examination were important to distinguish enteritis and acute diverticulitis cause by PD-1 inhibitor. In addition, the duration of glucocorticoid therapy after the development of severe immune checkpoint inhibitor-induced enteritis can be as long as several months, during which clinical experts should be alert to the possibility of infection with various opportunistic pathogens[19], especially cytomegalovirus. With the advent of the era of immunotherapy, both physicians and pharmacists need to be more familiar with the judgment and treatment of irAEs, especially the selection and management of various immunosuppressive agents or monoclonal antibodies when serious adverse reactions occur.

ACKNOWLEDGEMENTS

The authors thank the staff engaged in clinical care of the patient.

FOOTNOTES

Author contributions: All authors made substantial contributions to conception and design, acquisition of data, or analysis and interpretation of data; took part in drafting the article or revising it critically for important intellectual content; agreed to submit to the current journal; gave final approval of the version to be published; and agree to be accountable for all aspects of the work.

Informed consent statement: Informed written consent was obtained from the patient for publication of this report and any accompanying images.

Conflict-of-interest statement: All the authors report no relevant conflicts of interest for this article.

CARE Checklist (2016) statement: The authors have read the CARE Checklist (2016), and the manuscript was prepared and revised according to the CARE Checklist (2016).

Open-Access: This article is an open-access article that was selected by an in-house editor and fully peer-reviewed by external reviewers. It is distributed in accordance with the Creative Commons Attribution NonCommercial (CC BY-NC 4.0) license, which permits others to distribute, remix, adapt, build upon this work non-commercially, and license their derivative works on different terms, provided the original work is properly cited and the use is non-commercial. See: <https://creativecommons.org/licenses/by-nc/4.0/>

Country/Territory of origin: China

ORCID number: Ru-Hui Zhang 0000-0002-1553-8538; Jian-Ying Zhou 0000-0002-8924-935X; Hua Zhou 0000-0001-6397-3203.

S-Editor: Xing YX

L-Editor: A

P-Editor: Xing YX

REFERENCES

- Zhang T**, Song X, Xu L, Ma J, Zhang Y, Gong W, Zhou X, Wang Z, Wang Y, Shi Y, Bai H, Liu N, Yang X, Cui X, Cao Y, Liu Q, Song J, Li Y, Tang Z, Guo M, Wang L, Li K. The binding of an anti-PD-1 antibody to FcγRI has a profound impact on its biological functions. *Cancer Immunol Immunother* 2018; **67**: 1079-1090 [PMID: [29687231](#) DOI: [10.1007/s00262-018-2160-x](#)]
- Liu SY**, Wu YL. Tislelizumab: an investigational anti-PD-1 antibody for the treatment of advanced non-small cell lung cancer (NSCLC). *Expert Opin Investig Drugs* 2020; **29**: 1355-1364 [PMID: [33044117](#) DOI: [10.1080/13543784.2020.1833857](#)]
- Shen L**, Guo J, Zhang Q, Pan H, Yuan Y, Bai Y, Liu T, Zhou Q, Zhao J, Shu Y, Huang X, Wang S, Wang J, Zhou A, Ye D, Sun T, Gao Y, Yang S, Wang Z, Li J, Wu YL. Tislelizumab in Chinese patients with advanced solid tumors: an open-label, non-comparative, phase 1/2 study. *J Immunother Cancer* 2020; **8** [PMID: [32561638](#) DOI: [10.1136/jitc-2019-000437](#)]
- Song Y**, Gao Q, Zhang H, Fan L, Zhou J, Zou D, Li W, Yang H, Liu T, Wang Q, Lv F, Guo H, Yang L, Elstrom R, Huang J, Novotny W, Wei V, Zhu J. Treatment of relapsed or refractory classical Hodgkin lymphoma with the anti-PD-1, tislelizumab: results of a phase 2, single-arm, multicenter study. *Leukemia* 2020; **34**: 533-542 [PMID: [31520078](#) DOI: [10.1038/s41375-019-0545-2](#)]
- Desai J**, Deva S, Lee JS, Lin CC, Yen CJ, Chao Y, Keam B, Jameson M, Hou MM, Kang YK, Markman B, Lu CH, Rau KM, Lee KH, Horvath L, Friedlander M, Hill A, Sandhu S, Barlow P, Wu CY, Zhang Y, Liang L, Wu J, Paton V, Millward M. Phase IA/IB study of single-agent tislelizumab, an investigational anti-PD-1 antibody, in solid tumors. *J Immunother Cancer* 2020; **8** [PMID: [32540858](#) DOI: [10.1136/jitc-2019-000453](#)]
- Naranjo CA**, Busto U, Sellers EM, Sandor P, Ruiz I, Roberts EA, Janecek E, Domecq C, Greenblatt DJ. A method for estimating the probability of adverse drug reactions. *Clin Pharmacol Ther* 1981; **30**: 239-245 [PMID: [7249508](#) DOI: [10.1038/clpt.1981.154](#)]
- Thompson JA**, Schneider BJ, Brahmer J, Andrews S, Armand P, Bhatia S, Budde LE, Costa L, Davies M, Dunnington D, Ernstoff MS, Frigault M, Kaffenberger BH, Lunning M, McGettigan S, McPherson J, Mohindra NA, Naidoo J, Olszanski AJ, Oluwole O, Patel SP, Pennell N, Reddy S, Ryder M, Santomasso B, Shofer S, Sosman JA, Wang Y, Weight RM, Johnson-Chilla A, Zuccarino-Catania G, Engh A. NCCN Guidelines Insights: Management of Immunotherapy-Related Toxicities, Version 1.2020. *J Natl Compr Canc Netw* 2020; **18**: 230-241 [PMID: [32135517](#) DOI: [10.6004/jnccn.2020.0012](#)]
- Haanen JBAG**, Carbone F, Robert C, Kerr KM, Peters S, Larkin J, Jordan K; ESMO Guidelines Committee. Management of toxicities from immunotherapy: ESMO Clinical Practice Guidelines for diagnosis, treatment and follow-up. *Ann Oncol* 2017; **28**: iv119-iv142 [PMID: [28881921](#) DOI: [10.1093/annonc/mdx225](#)]
- Postow MA**, Sidlow R, Hellmann MD. Immune-Related Adverse Events Associated with Immune Checkpoint Blockade. *N Engl J Med* 2018; **378**: 158-168 [PMID: [29320654](#) DOI: [10.1056/NEJMr1703481](#)]
- Esfahani K**, Miller WH Jr. Reversal of Autoimmune Toxicity and Loss of Tumor Response by Interleukin-17 Blockade. *N Engl J Med* 2017; **376**: 1989-1991 [PMID: [28514612](#) DOI: [10.1056/NEJMc1703047](#)]
- Johnson DB**, Balko JM, Compton ML, Chalkias S, Gorham J, Xu Y, Hicks M, Puzanov I, Alexander MR, Bloomer TL, Becker JR, Slosky DA, Phillips EJ, Pilkinton MA, Craig-Owens L, Kola N, Plautz G, Reshef DS, Deutsch JS, Deering RP, Olenchock BA, Lichtman AH, Roden DM, Seidman CE, Koralnik IJ, Seidman JG, Hoffman RD, Taube JM, Diaz LA Jr, Anders RA, Sosman JA, Moslehi JJ. Fulminant Myocarditis with Combination Immune Checkpoint Blockade. *N Engl J Med* 2016; **375**: 1749-1755 [PMID: [27806233](#) DOI: [10.1056/NEJMoa1609214](#)]
- Byrne EH**, Fisher DE. Immune and molecular correlates in melanoma treated with immune checkpoint blockade. *Cancer* 2017; **123**: 2143-2153 [PMID: [28543699](#) DOI: [10.1002/cncr.30444](#)]
- Tarhini AA**, Zahoor H, Lin Y, Malhotra U, Sander C, Butterfield LH, Kirkwood JM. Baseline circulating IL-17 predicts toxicity while TGF-β1 and IL-10 are prognostic of relapse in ipilimumab neoadjuvant therapy of melanoma. *J Immunother Cancer* 2015; **3**: 39 [PMID: [26380086](#) DOI: [10.1186/s40425-015-0081-1](#)]
- Harbour SN**, Maynard CL, Zindl CL, Schoeb TR, Weaver CT. Th17 cells give rise to Th1 cells that are required for the pathogenesis of colitis. *Proc Natl Acad Sci USA* 2015; **112**: 7061-7066 [PMID: [26038559](#) DOI: [10.1073/pnas.1415675112](#)]
- Musdal Y**, Govindarajan S, Mannervik B. Exploring sequence-function space of a poplar glutathione transferase using designed information-rich gene variants. *Protein Eng Des Sel* 2017; **30**: 543-549 [PMID: [28967959](#) DOI: [10.1093/protein/gzx045](#)]
- Fischer A**, Gluth M, Pape UF, Wiedenmann B, Theuring F, Baumgart DC. Adalimumab prevents barrier dysfunction and antagonizes distinct effects of TNF-α on tight junction proteins and signaling pathways in intestinal epithelial cells. *Am J Physiol Gastrointest Liver Physiol* 2013; **304**: G970-G979 [PMID: [23538493](#) DOI: [10.1152/ajpgi.00183.2012](#)]
- Oke AR**, Wheeler M, Karydis I, Wallis D. Successful use of adalimumab in immune checkpoint inhibitor-associated inflammatory arthritis. *Rheumatol Adv Pract* 2018; **2**: rky001 [PMID: [31431951](#) DOI: [10.1093/rap/rky001](#)]
- Tursi A**. Immune checkpoint inhibitors-induced acute diverticulitis. *Eur J Gastroenterol Hepatol* 2020; **32**: 893-895 [PMID: [32472816](#) DOI: [10.1097/MEG.0000000000001713](#)]
- Ni J**, Zhang X, Zhang L. Opportunistic bowel infection after corticosteroid dosage tapering in a stage IV lung cancer patient with tislelizumab-related colitis. *Thorac Cancer* 2020; **11**: 1699-1702 [PMID: [32239681](#) DOI: [10.1111/1759-7714.13401](#)]



Published by **Baishideng Publishing Group Inc**
7041 Koll Center Parkway, Suite 160, Pleasanton, CA 94566, USA

Telephone: +1-925-3991568

E-mail: bpgoffice@wjgnet.com

Help Desk: <https://www.f6publishing.com/helpdesk>

<https://www.wjgnet.com>

