

World Journal of *Clinical Cases*

World J Clin Cases 2022 September 6; 10(25): 8808-9179



Contents

Thrice Monthly Volume 10 Number 25 September 6, 2022

MINIREVIEWS

- 8808** Ear, nose, and throat manifestations of COVID-19 and its vaccines
Al-Ani RM
- 8816** Potential influences of religiosity and religious coping strategies on people with diabetes
Onyishi CN, Eseadi C, Ilechukwu LC, Okoro KN, Okolie CN, Egbule E, Asogwa E

ORIGINAL ARTICLE

Case Control Study

- 8827** Effectiveness of six-step complex decongestive therapy for treating upper limb lymphedema after breast cancer surgery
Zhang HZ, Zhong QL, Zhang HT, Luo QH, Tang HL, Zhang LJ

Retrospective Study

- 8837** Hospital admissions from alcohol-related acute pancreatitis during the COVID-19 pandemic: A single-centre study
Mak WK, Di Mauro D, Pearce E, Karran L, Myintmo A, Duckworth J, Orabi A, Lane R, Holloway S, Manzelli A, Mossadegh S
- 8844** Indocyanine green plasma clearance rate and 99mTc-galactosyl human serum albumin single-photon emission computed tomography evaluated preoperative remnant liver
Iwaki K, Kaihara S, Kita R, Kitamura K, Hashida H, Uryuhara K
- 8854** Arthroscopy with subscapularis upper one-third tenodesis for treatment of recurrent anterior shoulder instability independent of glenoid bone loss
An BJ, Wang FL, Wang YT, Zhao Z, Wang MX, Xing GY
- 8863** Evaluation of the prognostic nutritional index for the prognosis of Chinese patients with high/extremely high-risk prostate cancer after radical prostatectomy
Yang F, Pan M, Nie J, Xiao F, Zhang Y

Observational Study

- 8872** Chlorine poisoning caused by improper mixing of household disinfectants during the COVID-19 pandemic: Case series
Lin GD, Wu JY, Peng XB, Lu XX, Liu ZY, Pan ZG, Qiu ZW, Dong JG
- 8880** Mental health of the Slovak population during COVID-19 pandemic: A cross-sectional survey
Kralova M, Brazinova A, Sivcova V, Izakova L

Prospective Study

- 8893** Arthroscopic anatomical reconstruction of lateral collateral ligaments with ligament advanced reinforcement system artificial ligament for chronic ankle instability
Wang Y, Zhu JX

SYSTEMATIC REVIEWS

- 8906** How to select the quantitative magnetic resonance technique for subjects with fatty liver: A systematic review
Li YW, Jiao Y, Chen N, Gao Q, Chen YK, Zhang YF, Wen QP, Zhang ZM
- 8922** Lymphocytic choriomeningitis virus: An under-recognized congenital teratogen
Ferenc T, Vujica M, Mrzljak A, Vilibic-Cavlek T

CASE REPORT

- 8932** Alagille syndrome associated with total anomalous pulmonary venous connection and severe xanthomas: A case report
Zeng HS, Zhang ZH, Hu Y, Zheng GL, Wang J, Zhang JW, Guo YX
- 8939** Colo-colonic intussusception with post-polypectomy electrocoagulation syndrome: A case report
Moon JY, Lee MR, Yim SK, Ha GW
- 8945** Portal vein gas combined with pneumatosis intestinalis and emphysematous cystitis: A case report and literature review
Hu SF, Liu HB, Hao YY
- 8954** Quadricuspid aortic valve and right ventricular type of myocardial bridging in an asymptomatic middle-aged woman: A case report
Sopek Merkaš I, Lakušić N, Paar MH
- 8962** Treatment of gastric carcinoma with lymphoid stroma by immunotherapy: A case report
Cui YJ, Ren YY, Zhang HZ
- 8968** Gallstone associated celiac trunk thromboembolisms complicated with splenic infarction: A case report
Wu CY, Su CC, Huang HH, Wang YT, Wang CC
- 8974** Extracorporeal membrane oxygenation for lung cancer-related life-threatening hypoxia: A case report
Yoo SS, Lee SY, Choi SH
- 8980** Multi-disciplinary treatment of maxillofacial skeletal deformities by orthognathic surgery combined with periodontal phenotype modification: A case report
Liu JY, Li GF, Tang Y, Yan FH, Tan BC
- 8990** X-linked recessive Kallmann syndrome: A case report
Zhang P, Fu JY
- 8998** Delayed complications of intradural cement leakage after percutaneous vertebroplasty: A case report
Ma QH, Liu GP, Sun Q, Li JG

- 9004** Coexistent Kaposi sarcoma and post-transplant lymphoproliferative disorder in the same lymph nodes after pediatric liver transplantation: A case report
Zhang SH, Chen GY, Zhu ZJ, Wei L, Liu Y, Liu JY
- 9012** Misdiagnosis of pancreatic metastasis from renal cell carcinoma: A case report
Liang XK, Li LJ, He YM, Xu ZF
- 9020** Discoid medial meniscus of both knees: A case report
Zheng ZR, Ma H, Yang F, Yuan L, Wang GD, Zhao XW, Ma LF
- 9028** Simultaneous laparoscopic and arthroscopic excision of a huge juxta-articular ganglionic cyst compressing the sciatic nerve: A case report
Choi WK, Oh JS, Yoon SJ
- 9036** One-stage revision arthroplasty in a patient with ochronotic arthropathy accompanied by joint infection: A case report
Wang XC, Zhang XM, Cai WL, Li Z, Ma C, Liu YH, He QL, Yan TS, Cao XW
- 9044** Bladder paraganglioma after kidney transplantation: A case report
Wang L, Zhang YN, Chen GY
- 9050** Total spinal anesthesia caused by lidocaine during unilateral percutaneous vertebroplasty performed under local anesthesia: A case report
Wang YF, Bian ZY, Li XX, Hu YX, Jiang L
- 9057** Ruptured splenic artery aneurysms in pregnancy and usefulness of endovascular treatment in selective patients: A case report and review of literature
Lee SH, Yang S, Park I, Im YC, Kim GY
- 9064** Gastrointestinal metastasis secondary to invasive lobular carcinoma of the breast: A case report
Li LX, Zhang D, Ma F
- 9071** Post-bulbar duodenal ulcer with anterior perforation with kissing ulcer and duodenocaval fistula: A case report and review of literature
Alzerwi N
- 9078** Modified orthodontic treatment of substitution of canines by first premolars: A case report
Li FF, Li M, Li M, Yang X
- 9087** Renal cell carcinoma presented with a rare case of icteric Stauffer syndrome: A case report
Popov DR, Antonov KA, Atanasova EG, Pentchev CP, Milatchkov LM, Petkova MD, Neykov KG, Nikolov RK
- 9096** Successful resection of a huge retroperitoneal venous hemangioma: A case report
Qin Y, Qiao P, Guan X, Zeng S, Hu XP, Wang B
- 9104** Malignant transformation of biliary adenofibroma combined with benign lymphadenopathy mimicking advanced liver carcinoma: A case report
Wang SC, Chen YY, Cheng F, Wang HY, Wu FS, Teng LS

- 9112** Congenital hepatic cyst: Eleven case reports
Du CX, Lu CG, Li W, Tang WB
- 9121** Endovascular treatment of a ruptured pseudoaneurysm of the internal carotid artery in a patient with nasopharyngeal cancer: A case report
Park JS, Jang HG
- 9127** Varicella-zoster virus meningitis after spinal anesthesia: A case report
Lee YW, Yoo B, Lim YH
- 9132** Chondrosarcoma of the toe: A case report and literature review
Zhou LB, Zhang HC, Dong ZG, Wang CC
- 9142** Tamsulosin-induced life-threatening hypotension in a patient with spinal cord injury: A case report
Lee JY, Lee HS, Park SB, Lee KH
- 9148** CCNO mutation as a cause of primary ciliary dyskinesia: A case report
Zhang YY, Lou Y, Yan H, Tang H
- 9156** Repeated bacteremia and hepatic cyst infection lasting 3 years following pancreatoduodenectomy: A case report
Zhang K, Zhang HL, Guo JQ, Tu CY, Lv XL, Zhu JD
- 9162** Idiopathic cholesterol crystal embolism with atheroembolic renal disease and blue toes syndrome: A case report
Cheng DJ, Li L, Zheng XY, Tang SF
- 9168** Systemic lupus erythematosus with visceral varicella: A case report
Zhao J, Tian M

LETTER TO THE EDITOR

- 9176** Imaging of fibroadenoma: Be careful with imaging follow-up
Ece B, Aydın S

ABOUT COVER

Editorial Board Member of *World Journal of Clinical Cases*, Mohsen Khosravi, MD, Assistant Professor, Department of Psychiatry and Clinical Psychology, Zahedan University of Medical Sciences, Zahedan 9819713955, Iran. m.khosravi@zaums.ac.ir

AIMS AND SCOPE

The primary aim of *World Journal of Clinical Cases* (WJCC, *World J Clin Cases*) is to provide scholars and readers from various fields of clinical medicine with a platform to publish high-quality clinical research articles and communicate their research findings online.

WJCC mainly publishes articles reporting research results and findings obtained in the field of clinical medicine and covering a wide range of topics, including case control studies, retrospective cohort studies, retrospective studies, clinical trials studies, observational studies, prospective studies, randomized controlled trials, randomized clinical trials, systematic reviews, meta-analysis, and case reports.

INDEXING/ABSTRACTING

The WJCC is now abstracted and indexed in Science Citation Index Expanded (SCIE, also known as SciSearch®), Journal Citation Reports/Science Edition, Current Contents®/Clinical Medicine, PubMed, PubMed Central, Scopus, Reference Citation Analysis, China National Knowledge Infrastructure, China Science and Technology Journal Database, and Superstar Journals Database. The 2022 Edition of Journal Citation Reports® cites the 2021 impact factor (IF) for WJCC as 1.534; IF without journal self cites: 1.491; 5-year IF: 1.599; Journal Citation Indicator: 0.28; Ranking: 135 among 172 journals in medicine, general and internal; and Quartile category: Q4. The WJCC's CiteScore for 2021 is 1.2 and Scopus CiteScore rank 2021: General Medicine is 443/826.

RESPONSIBLE EDITORS FOR THIS ISSUE

Production Editor: *Xu Guo*; Production Department Director: *Xiang Li*; Editorial Office Director: *Jin-Lei Wang*.

NAME OF JOURNAL

World Journal of Clinical Cases

ISSN

ISSN 2307-8960 (online)

LAUNCH DATE

April 16, 2013

FREQUENCY

Thrice Monthly

EDITORS-IN-CHIEF

Bao-Gan Peng, Jerzy Tadeusz Chudek, George Kontogeorgos, Maurizio Serati, Ja Hyeon Ku

EDITORIAL BOARD MEMBERS

<https://www.wjnet.com/2307-8960/editorialboard.htm>

PUBLICATION DATE

September 6, 2022

COPYRIGHT

© 2022 Baishideng Publishing Group Inc

INSTRUCTIONS TO AUTHORS

<https://www.wjnet.com/bpg/gerinfo/204>

GUIDELINES FOR ETHICS DOCUMENTS

<https://www.wjnet.com/bpg/GerInfo/287>

GUIDELINES FOR NON-NATIVE SPEAKERS OF ENGLISH

<https://www.wjnet.com/bpg/gerinfo/240>

PUBLICATION ETHICS

<https://www.wjnet.com/bpg/GerInfo/288>

PUBLICATION MISCONDUCT

<https://www.wjnet.com/bpg/gerinfo/208>

ARTICLE PROCESSING CHARGE

<https://www.wjnet.com/bpg/gerinfo/242>

STEPS FOR SUBMITTING MANUSCRIPTS

<https://www.wjnet.com/bpg/GerInfo/239>

ONLINE SUBMISSION

<https://www.f6publishing.com>



Endovascular treatment of a ruptured pseudoaneurysm of the internal carotid artery in a patient with nasopharyngeal cancer: A case report

Jung-Soo Park, Hyoung Gyu Jang

Specialty type: Surgery

Provenance and peer review:

Unsolicited article; Externally peer reviewed.

Peer-review model: Single blind

Peer-review report's scientific quality classification

Grade A (Excellent): A

Grade B (Very good): 0

Grade C (Good): 0

Grade D (Fair): D

Grade E (Poor): 0

P-Reviewer: Oura S, Japan; Wang YJ, China

Received: April 13, 2022

Peer-review started: April 13, 2022

First decision: May 31, 2022

Revised: June 13, 2022

Accepted: July 25, 2022

Article in press: July 25, 2022

Published online: September 6, 2022



Jung-Soo Park, Hyoung Gyu Jang, Department of Neurosurgery, Jeonbuk National University Medical School and Hospital, Jeonju 54907, South Korea

Corresponding author: Hyoung Gyu Jang, MD, Attending Doctor, Department of Neurosurgery, Jeonbuk National University Medical School and Hospital, 20 Geonji-ro, Deokjin-gu, Jeonju 54709, South Korea. 23175@jbuh.co.kr

Abstract

BACKGROUND

Radiation therapy (RT) for nasopharyngeal cancer can cause several complications. In rare cases, an internal carotid artery pseudoaneurysm can occur, which can be fatal. We report the experience of a nasopharyngeal cancer patient who underwent radiation therapy and subsequently developed a fatal pseudoaneurysm of the petrous internal carotid artery.

CASE SUMMARY

A 39-year-old man was diagnosed with nasopharyngeal cancer 2 years ago (American Joint Committee on Cancer Stage T3N2M0) and received concurrent chemoradiation therapy. He subsequently relapsed and received chemotherapy. One week after the 4th cycle of chemotherapy, he was admitted to the emergency room of our hospital because of massive epistaxis accompanied by a headache. A pseudoaneurysm of the petrous internal carotid artery was confirmed by digital subtraction angiography (DSA). Stent-assisted endovascular coil embolization was performed and complete occlusion was achieved. No pseudoaneurysm was observed on DSA after coil embolization; however, intermittent epistaxis was maintained even after coil embolization. After seven days, a diagnostic laryngoscopy was performed. Massive bleeding occurred after aspiration of the blood clot during the laryngoscopy and the patient died of hypovolemic shock. In this case, epistaxis may have been a sign of pseudoaneurysm; therefore, treatment such as embolization should be performed promptly, and careful management should be undertaken after treatment.

CONCLUSION

This case highlights a rare, serious complication of RT in nasopharyngeal cancer and how it should be recognized and treated.

Key Words: Pseudoaneurysm; Nasopharyngeal cancer; Radiation therapy; Epistaxis; Carotid artery pseudoaneurysm; Case report

©The Author(s) 2022. Published by Baishideng Publishing Group Inc. All rights reserved.

Core Tip: We report a patient who developed pseudoaneurysm in a nasopharyngeal cancer patient. By reporting our mistakes, we hope that our readers will not make the same mistakes as us.

Citation: Park JS, Jang HG. Endovascular treatment of a ruptured pseudoaneurysm of the internal carotid artery in a patient with nasopharyngeal cancer: A case report. *World J Clin Cases* 2022; 10(25): 9121-9126

URL: <https://www.wjgnet.com/2307-8960/full/v10/i25/9121.htm>

DOI: <https://dx.doi.org/10.12998/wjcc.v10.i25.9121>

INTRODUCTION

Nasopharyngeal cancer (NPC) is a major type of head and neck cancer[1]. The main treatment for this cancer is radiation therapy[2]. However, radiation therapy destroys the normal tissues surrounding the tumor, which can lead to complications such as mucositis, dry mouth, dysphagia, hearing and visual loss, throat problems, neurological damage, carotid artery stenosis, and nasal or nasopharyngeal bleeding[3]. A pseudoaneurysm of the internal carotid artery (ICA), which is a serious complication of radiation therapy in NPC patients, can cause massive epistaxis with high mortality[4]. We report the experience of a NPC patient who underwent radiation therapy and subsequently developed a fatal pseudoaneurysm of the petrous ICA.

CASE PRESENTATION

Chief complaints

A 41-year-old man had an epistaxis.

History of present illness

A 41-year-old man was admitted to the emergency department of our hospital for epistaxis, accompanied by a headache.

History of past illness

The patient was diagnosed on the 31st April 2019 with NPC stage T2N2M0 and underwent concurrent chemoradiation therapy at a total radiation dose of 67.2 Gy/28 frs. The cancer recurred a year later, and salvage radiation therapy and chemotherapy were administered. One week after the 4th cycle of chemotherapy, he was admitted to the emergency department of our hospital.

Personal and family history

This patient had no special personal or family history.

Physical examination

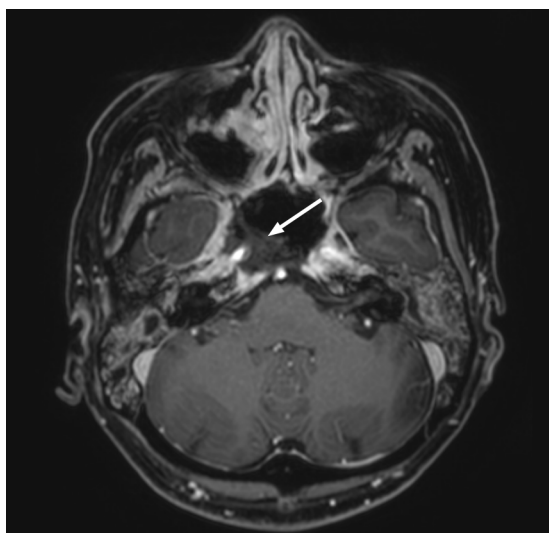
There were no specific findings on physical examination other than epistaxis.

Laboratory examinations

There were no specific findings on laboratory test.

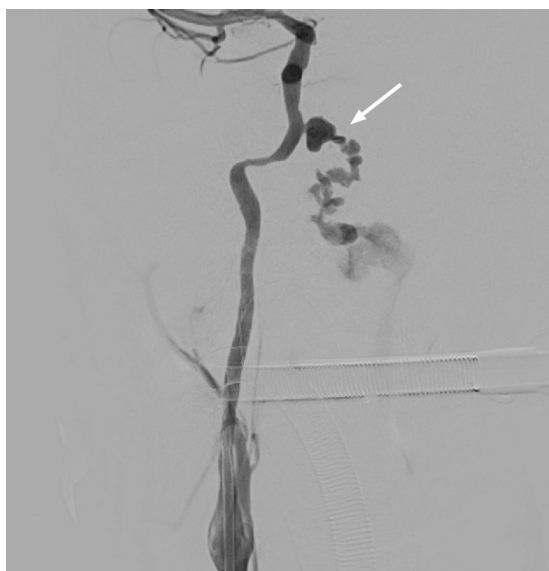
Imaging examinations

We performed a nasopharyngeal magnetic resonance imaging, which showed destruction of the petrous bone, sphenoid sinus floor, and clivus. In addition, necrosis of the soft tissues from the nasopharynx to the oropharynx, including the ICA was observed (Figure 1). Digital subtraction angiography (DSA) was performed for embolization because epistaxis occurred continuously. Incidentally, angiography of the right ICA revealed a ruptured 9 mm × 5 mm pseudoaneurysm in the petrous (Figure 2). Subsequently, stent-assisted endovascular coil embolization was planned.



DOI: 10.12998/wjcc.v10.i25.9121 Copyright ©The Author(s) 2022.

Figure 1 Axial contrast-enhanced T1-weighted magnetic resonance image shows bone destruction in the petrous bone, sphenoid sinus floor, and clivus. In addition, necrosis of the soft tissues from the nasopharynx to the oropharynx, including the internal carotid artery (white arrow) was observed.



DOI: 10.12998/wjcc.v10.i25.9121 Copyright ©The Author(s) 2022.

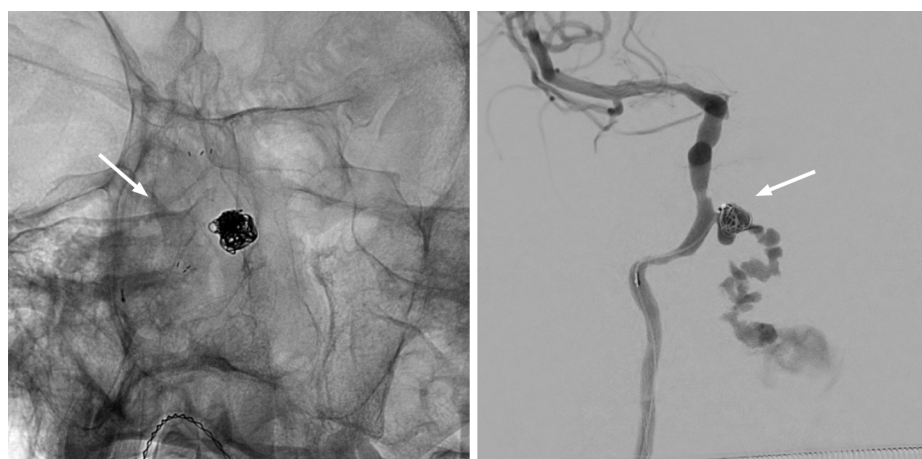Figure 2 Digital subtraction angiography shows a 9 mm × 5 mm pseudoaneurysm (white arrow) of the right petrous internal carotid artery.

FINAL DIAGNOSIS

The final diagnosis of the presented case was a pseudoaneurysm in an NPC patient caused by radiation treatment.

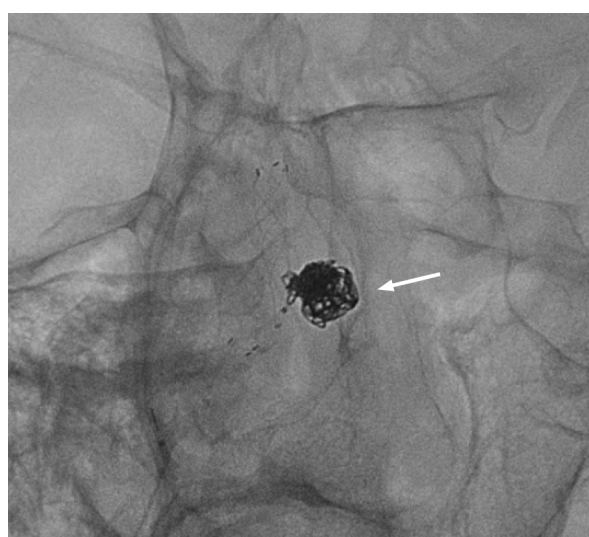
TREATMENT

Vaseline gauze packing was performed as an emergency measures, but a small amount of bleeding continued to occur. The patient developed massive epistaxis during general anesthesia preparation for coil embolization. Under general anesthesia, after a right femoral artery puncture, an 80 cm 7F guide catheter was advanced to the right cervical portion of the ICA. A 6-Fr soft torque able catheter optimized for intracranial access was inserted into the cervical segment of the right ICA under roadmap guidance.



DOI: 10.12998/wjcc.v10.i25.9121 Copyright ©The Author(s) 2022.

Figure 3 Neuroform Atlas (Boston) 4.0 mm × 21 mm stent was deployed and then a Guglielmi's detachable coil was placed into the aneurysm.

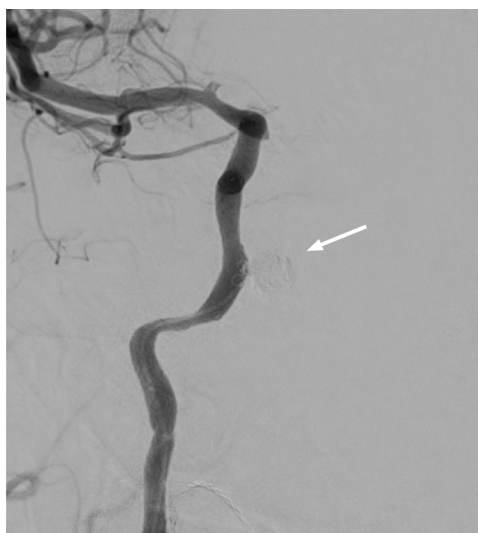

DOI: 10.12998/wjcc.v10.i25.9121 Copyright ©The Author(s) 2022.

Figure 4 Bleeding was observed continuously even after installing the coil into the initially deployed stent located at the orifice of the pseudoaneurysm. We additionally installed a self-expanding closed-cell low-profile visualized intraluminal support jr 3.5 mm × 18 mm stent.

Using roadmap guidance again, a Headway 17 for coil delivery was inserted into the aneurysm sac. Then, a Headway 21 microcatheter was navigated to a carotid segment of right ICA to deliver the stent. After this, a Neuroform Atlas 4.0 mm × 21 mm stent was deployed from the distal to the proximal petrous ICA. After the stent was fully installed, coil embolization was initiated. A Guglielmi's detachable coil was placed into the aneurysm (Figure 3). The procedure was carried out by pulling out the microcatheter slightly, while identifying the patency of the parent artery. Coils encroaching into the stent were not allowed throughout the procedure. However, bleeding was observed continuously, even after coil packing. While inserting the coil into the initially installed stent located at the orifice of the pseudoaneurysm, we additionally installed a self-expanding closed-cell low-profile visualized intraluminal support jr 3.5 mm × 18 mm stent (Figure 4).

A final angiographic image showed that bleeding was no longer observed, and that the epistaxis that persisted during the intervention was also relieved (Figure 5). No pseudoaneurysm was observed on DSA after coil embolization; however, intermittent epistaxis continued to occur even after coil embolization. After seven days, a diagnostic laryngoscopy was performed.



DOI: 10.12998/wjcc.v10.i25.9121 Copyright ©The Author(s) 2022.

Figure 5 Final angiography reveals complete embolization (white arrow) of pseudoaneurysm.

OUTCOME AND FOLLOW-UP

Massive bleeding occurred after aspiration of the blood clot during the laryngoscopy. The patient subsequently died of hypovolemic shock.

DISCUSSION

NPC is a relatively common malignant tumor, mainly treated with a combination of chemotherapy and radiation therapy[2]. Radiation therapy is one of the most effective treatments for NPC. However, its side effects include erythema, erosion, ulceration in the skin and mucosa, and in more severe cases, necrosis of the bone and cartilage[3]. One of the most severe complications that can occur is the rupture of major blood vessels, which was first reported in 1959 by Thomas and Forbus[5]. This usually occurs in the petrous and lacerum segments of the ICA and may present with life-threatening epistaxis. Therefore, it is a major post-treatment complication of NPC[6].

The mechanism of radiation-induced vascular injury is not fully understood, but may result from obliteration of the vasa vasorum, premature atherosclerosis, and weakening and necrosis of the arterial wall. Ischemic injury combined with peri-adventitial fibrosis may contribute to the rupture of irradiated large arteries and pseudoaneurysm formation[7]. In these patients, epistaxis can characteristically be observed when a pseudoaneurysm ruptures. The patient in this case also experienced epistaxis and was admitted to the emergency room.

Although our patient had epistaxis, we did not consider it as a symptom of a ruptured pseudoaneurysm. Initially, DSA was performed for embolization of the arterial branches of the external carotid artery, which have the potential to cause epistaxis. However, an unexpected pseudoaneurysm in the petrous ICA was found in the DSA. Only then was it possible to infer that the cause of the epistaxis was radiation-induced rupture of the pseudoaneurysm. Obliteration of the pseudoaneurysm was achieved by embolization; however, the patient had persistent epistaxis and after a careless laryngoscopy that may have been unnecessary, the patient experienced massive rebleeding epistaxis.

Many things were noted throughout the experience of this rare case. First, treatment should have been initiated considering the possibility of an ICA pseudoaneurysm, the most dangerous cause of epistaxis in NPC patients with a history of radiation therapy. Although obliteration of the pseudoaneurysm was confirmed after treatment, it is questionable whether this was the best line of treatment as the decision-making process was made in urgency. Second, due to the characteristics of pseudoaneurysms, a short-term imaging follow-up should have been performed. In addition, a small amount of epistaxis persisted even after coil embolization suggesting regrowth or recanalization of the pseudoaneurysm. If this was recognized in advance, additional treatments could have been implemented. Third, there was an unnecessary and careless laryngoscopy performed. Greater attention should have been paid to the process, and a DSA should have been re-executed rather than a laryngoscopy.

CONCLUSION

Pseudoaneurysms in NPC is a rare but fatal complication of radiotherapy. In this case, the occurrence of epistaxis may have been a sign of pseudoaneurysm; therefore, in these cases treatment such as embolization should be performed promptly, with careful management being carried out thereafter.

FOOTNOTES

Author contributions: Park JS wrote the manuscript; Park JS and Jang HG collected the data and participated in patient care; Jang HG reviewed and edited the manuscript.

Supported by Fund of Biomedical Research Institute, Jeonbuk National University Hospital.

Informed consent statement: Informed written consent was obtained from the patient for publication of this report and any accompanying images.

Conflict-of-interest statement: All the authors declare that they have no conflict of interest.

CARE Checklist (2016) statement: The authors have read the CARE Checklist (2016), and the manuscript was prepared and revised according to the CARE Checklist (2016).

Open-Access: This article is an open-access article that was selected by an in-house editor and fully peer-reviewed by external reviewers. It is distributed in accordance with the Creative Commons Attribution NonCommercial (CC BY-NC 4.0) license, which permits others to distribute, remix, adapt, build upon this work non-commercially, and license their derivative works on different terms, provided the original work is properly cited and the use is non-commercial. See: <https://creativecommons.org/licenses/by-nc/4.0/>

Country/Territory of origin: South Korea

ORCID number: Jung-Soo Park 0000-0002-4949-203X; Hyoung Gyu Jang 0000-0002-8252-5518.

S-Editor: Liu JH

L-Editor: A

P-Editor: Liu JH

REFERENCES

- 1 **Chou J**, Lin YC, Kim J, You L, Xu Z, He B, Jablons DM. Nasopharyngeal carcinoma--review of the molecular mechanisms of tumorigenesis. *Head Neck* 2008; **30**: 946-963 [PMID: 18446839 DOI: 10.1002/hed.20833]
- 2 **Sung H**, Ferlay J, Siegel RL, Laversanne M, Soerjomataram I, Jemal A, Bray F. Global Cancer Statistics 2020: GLOBOCAN Estimates of Incidence and Mortality Worldwide for 36 Cancers in 185 Countries. *CA Cancer J Clin* 2021; **71**: 209-249 [PMID: 33538338 DOI: 10.3322/caac.21660]
- 3 **Chua MLK**, Wee JTS, Hui EP, Chan ATC. Nasopharyngeal carcinoma. *Lancet* 2016; **387**: 1012-1024 [PMID: 26321262 DOI: 10.1016/S0140-6736(15)00055-0]
- 4 **Nazari P**, Tan LA, Wewel JT, Moftakhar R, Kasliwal MK. Massive epistaxis resulting from radiation-induced internal carotid artery pseudoaneurysm. *Neurol India* 2017; **65**: 380-382 [PMID: 28290404 DOI: 10.4103/neuroindia.NI_1259_15]
- 5 **THOMAS E**, FORBUS WD. Irradiation injury to the aorta and the lung. *AMA Arch Pathol* 1959; **67**: 256-263 [PMID: 13626327]
- 6 **Hanada Y**, Sasai H, Kamakura A, Nakamura M, Sakata Y, Miyahara H. [Rupture of an internal carotid artery pseudoaneurysm after irradiation for a nasopharyngeal carcinoma--case report]. *Nihon Jibiinkoka Gakkai Kaiho* 2013; **116**: 606-611 [PMID: 23819358 DOI: 10.3950/jibiinkoka.116.606]
- 7 **Okamura HO**, Kamiyama R, Takiguchi Y, Kimizuka K, Ishikawa N, Kishimoto S. Histopathological examination of ruptured carotid artery after irradiation. *ORL J Otorhinolaryngol Relat Spec* 2002; **64**: 226-228 [PMID: 12037392 DOI: 10.1159/000058030]



Published by **Baishideng Publishing Group Inc**
7041 Koll Center Parkway, Suite 160, Pleasanton, CA 94566, USA

Telephone: +1-925-3991568

E-mail: bpgoffice@wjgnet.com

Help Desk: <https://www.f6publishing.com/helpdesk>

<https://www.wjgnet.com>

