

World Journal of *Clinical Cases*

World J Clin Cases 2022 October 6; 10(28): 9970-10390



Contents

Thrice Monthly Volume 10 Number 28 October 6, 2022

REVIEW

- 9970 COVID-19 and the heart

Xanthopoulos A, Bourazana A, Giamouzis G, Skoularigki E, Dimos A, Zagouras A, Papamichalis M, Leventis I, Magouliotis DE, Triposkiadis F, Skoularigis J

- 9985 Role of short chain fatty acids in gut health and possible therapeutic approaches in inflammatory bowel diseases

Caetano MAF, Castelucci P

MINIREVIEWS

- 10004 Review of the pharmacological effects of astragaloside IV and its autophagic mechanism in association with inflammation

Yang Y, Hong M, Lian WW, Chen Z

ORIGINAL ARTICLE

Clinical and Translational Research

- 10017 Effects of targeted-edited oncogenic insulin-like growth factor-1 receptor with specific-sgRNA on biological behaviors of HepG2 cells

Yao M, Cai Y, Wu ZJ, Zhou P, Sai WL, Wang DF, Wang L, Yao DF

Retrospective Study

- 10031 Analysis of the successful clinical treatment of 140 patients with parathyroid adenoma: A retrospective study

Peng ZX, Qin Y, Bai J, Yin JS, Wei BJ

- 10042 Efficacy of digital breast tomosynthesis combined with magnetic resonance imaging in the diagnosis of early breast cancer

Ren Y, Zhang J, Zhang JD, Xu JZ

- 10053 Prevention and management of adverse events following COVID-19 vaccination using traditional Korean medicine: An online survey of public health doctors

Kang B, Chu H, Youn BY, Leem J

- 10066 Clinical outcomes of targeted therapies in elderly patients aged ≥ 80 years with metastatic colorectal cancer

Jang HR, Lee HY, Song SY, Lim KH

- 10077 Endovascular treatment vs drug therapy alone in patients with mild ischemic stroke and large infarct cores

Kou WH, Wang XQ, Yang JS, Qiao N, Nie XH, Yu AM, Song AX, Xue Q

Clinical Trials Study

- 10085** One hundred and ninety-two weeks treatment of entecavir maleate for Chinese chronic hepatitis B predominantly genotyped B or C

Xu JH, Wang S, Zhang DZ, Yu YY, Si CW, Zeng Z, Xu ZN, Li J, Mao Q, Tang H, Sheng JF, Chen XY, Ning Q, Shi GF, Xie Q, Zhang XQ, Dai J

Observational Study

- 10097** Dementia-related contact experience, attitudes, and the level of knowledge in medical vocational college students

Liu DM, Yan L, Wang L, Lin HH, Jiang XY

SYSTEMATIC REVIEWS

- 10109** Link between COVID-19 vaccines and myocardial infarction

Zafar U, Zafar H, Ahmed MS, Khattak M

CASE REPORT

- 10120** Successful treatment of disseminated nocardiosis diagnosed by metagenomic next-generation sequencing: A case report and review of literature

Li T, Chen YX, Lin JJ, Lin WX, Zhang WZ, Dong HM, Cai SX, Meng Y

- 10130** Multiple primary malignancies – hepatocellular carcinoma combined with splenic lymphoma: A case report

Wu FZ, Chen XX, Chen WY, Wu QH, Mao JT, Zhao ZW

- 10136** Metastatic multifocal melanoma of multiple organ systems: A case report

Maksimaityte V, Reivytyte R, Milaknyte G, Mickys U, Razanskiene G, Stundys D, Kazenaite E, Valantinas J, Stundiene I

- 10146** Cavernous hemangioma of the ileum in a young man: A case report and review of literature

Yao L, Li LW, Yu B, Meng XD, Liu SQ, Xie LH, Wei RF, Liang J, Ruan HQ, Zou J, Huang JA

- 10155** Successful management of a breastfeeding mother with severe eczema of the nipple beginning from puberty: A case report

Li R, Zhang LX, Tian C, Ma LK, Li Y

- 10162** Short benign ileocolonic anastomotic strictures - management with bi-flanged metal stents: Six case reports and review of literature

Kasapidis P, Mavrogenis G, Mandrekas D, Bazerbachi F

- 10172** Simultaneous bilateral floating knee: A case report

Wu CM, Liao HE, Lan SJ

- 10180** Chemotherapy, transarterial chemoembolization, and nephrectomy combined treated one giant renal cell carcinoma (T3aN1M1) associated with Xp11.2/TFE3: A case report

Wang P, Zhang X, Shao SH, Wu F, Du FZ, Zhang JF, Zuo ZW, Jiang R

- 10186** Tislelizumab-related enteritis successfully treated with adalimumab: A case report

Chen N, Qian MJ, Zhang RH, Gao QQ, He CC, Yao YK, Zhou JY, Zhou H

- 10193** Treatment of refractory/relapsed extranodal NK/T cell lymphoma with decitabine plus anti-PD-1: A case report
Li LJ, Zhang JY
- 10201** Clinical analysis of pipeline dredging agent poisoning: A case report
Li YQ, Yu GC, Shi LK, Zhao LW, Wen ZX, Kan BT, Jian XD
- 10208** Follicular lymphoma with cardiac involvement in a 90-year-old patient: A case report
Sun YX, Wang J, Zhu JH, Yuan W, Wu L
- 10214** Twin reversed arterial perfusion sequence-a rare and dangerous complication form of monochorionic twins: A case report
Anh ND, Thu Ha NT, Sim NT, Toan NK, Thuong PTH, Duc NM
- 10220** Potential otogenic complications caused by cholesteatoma of the contralateral ear in patients with otogenic abscess secondary to middle ear cholesteatoma of one ear: A case report
Zhang L, Niu X, Zhang K, He T, Sun Y
- 10227** Myeloid sarcoma with ulnar nerve entrapment: A case report
Li DP, Liu CZ, Jeremy M, Li X, Wang JC, Nath Varma S, Gai TT, Tian WQ, Zou Q, Wei YM, Wang HY, Long CJ, Zhou Y
- 10236** Alpha-fetoprotein-producing hepatoid adenocarcinoma of the lung responsive to sorafenib after multiline treatment: A case report
Xu SZ, Zhang XC, Jiang Q, Chen M, He MY, Shen P
- 10244** Acute mesenteric ischemia due to percutaneous coronary intervention: A case report
Ding P, Zhou Y, Long KL, Zhang S, Gao PY
- 10252** Persistent diarrhea with petechial rash - unusual pattern of light chain amyloidosis deposition on skin and gastrointestinal biopsies: A case report
Bilton SE, Shah N, Dougherty D, Simpson S, Holliday A, Sahebjam F, Grider DJ
- 10260** Solitary splenic tuberculosis: A case report
Guo HW, Liu XQ, Cheng YL
- 10266** Coronary artery aneurysms caused by Kawasaki disease in an adult: A case report and literature review
He Y, Ji H, Xie JC, Zhou L
- 10273** Double filtration plasmapheresis for pregnancy with hyperlipidemia in glycogen storage disease type Ia: A case report
Wang J, Zhao Y, Chang P, Liu B, Yao R
- 10279** Treatment of primary tracheal schwannoma with endoscopic resection: A case report
Shen YS, Tian XD, Pan Y, Li H
- 10286** Concrescence of maxillary second molar and impacted third molar: A case report
Su J, Shao LM, Wang LC, He LJ, Pu YL, Li YB, Zhang WY

- 10293** Rare leptin in non-alcoholic fatty liver cirrhosis: A case report
Nong YB, Huang HN, Huang JJ, Du YQ, Song WX, Mao DW, Zhong YX, Zhu RH, Xiao XY, Zhong RX
- 10301** One-stage resection of four genotypes of bilateral multiple primary lung adenocarcinoma: A case report
Zhang DY, Liu J, Zhang Y, Ye JY, Hu S, Zhang WX, Yu DL, Wei YP
- 10310** Ectopic pregnancy and failed oocyte retrieval during *in vitro* fertilization stimulation: Two case reports
Zhou WJ, Xu BF, Niu ZH
- 10317** Malignant peritoneal mesothelioma with massive ascites as the first symptom: A case report
Huang X, Hong Y, Xie SY, Liao HL, Huang HM, Liu JH, Long WJ
- 10326** Subperiosteal orbital hematoma concomitant with abscess in a patient with sinusitis: A case report
Hu XH, Zhang C, Dong YK, Cong TC
- 10332** Postpartum posterior reversible encephalopathy syndrome secondary to preeclampsia and cerebrospinal fluid leakage: A case report and literature review
Wang Y, Zhang Q
- 10339** Sudden extramedullary and extranodal Philadelphia-positive anaplastic large-cell lymphoma transformation during imatinib treatment for CML: A case report
Wu Q, Kang Y, Xu J, Ye WC, Li ZJ, He WF, Song Y, Wang QM, Tang AP, Zhou T
- 10346** Relationship of familial cytochrome P450 4V2 gene mutation with liver cirrhosis: A case report and review of the literature
Jiang JL, Qian JF, Xiao DH, Liu X, Zhu F, Wang J, Xing ZX, Xu DL, Xue Y, He YH
- 10358** COVID-19-associated disseminated mucormycosis: An autopsy case report
Kyuno D, Kubo T, Tsujiwaki M, Sugita S, Hosaka M, Ito H, Harada K, Takasawa A, Kubota Y, Takasawa K, Ono Y, Magara K, Narimatsu E, Hasegawa T, Osanai M
- 10366** Thalidomide combined with endoscopy in the treatment of Cronkhite-Canada syndrome: A case report
Rong JM, Shi ML, Niu JK, Luo J, Miao YL
- 10375** Thoracolumbar surgery for degenerative spine diseases complicated with tethered cord syndrome: A case report
Wang YT, Mu GZ, Sun HL

LETTER TO THE EDITOR

- 10384** Are pregnancy-associated hypertensive disorders so sweet?
Thomopoulos C, Ilias I
- 10387** Tumor invasion front in oral squamous cell carcinoma
Cuevas-González JC, Cuevas-González MV, Espinosa-Cristobal LF, Donohue Cornejo A

ABOUT COVER

Editorial Board Member of *World Journal of Clinical Cases*, Kaleem Ullah, FCPS, MBBS, Assistant Professor, Solid Organ Transplantation and Hepatobiliary Surgery, Pir Abdul Qadir Shah Jeelani Institute of Medical Sciences, Gambat 66070, Sindh, Pakistan. drkaleempk@gmail.com

AIMS AND SCOPE

The primary aim of *World Journal of Clinical Cases* (WJCC, *World J Clin Cases*) is to provide scholars and readers from various fields of clinical medicine with a platform to publish high-quality clinical research articles and communicate their research findings online.

WJCC mainly publishes articles reporting research results and findings obtained in the field of clinical medicine and covering a wide range of topics, including case control studies, retrospective cohort studies, retrospective studies, clinical trials studies, observational studies, prospective studies, randomized controlled trials, randomized clinical trials, systematic reviews, meta-analysis, and case reports.

INDEXING/ABSTRACTING

The WJCC is now abstracted and indexed in Science Citation Index Expanded (SCIE, also known as SciSearch®), Journal Citation Reports/Science Edition, Current Contents®/Clinical Medicine, PubMed, PubMed Central, Scopus, Reference Citation Analysis, China National Knowledge Infrastructure, China Science and Technology Journal Database, and Superstar Journals Database. The 2022 Edition of Journal Citation Reports® cites the 2021 impact factor (IF) for WJCC as 1.534; IF without journal self cites: 1.491; 5-year IF: 1.599; Journal Citation Indicator: 0.28; Ranking: 135 among 172 journals in medicine, general and internal; and Quartile category: Q4. The WJCC's CiteScore for 2021 is 1.2 and Scopus CiteScore rank 2021: General Medicine is 443/826.

RESPONSIBLE EDITORS FOR THIS ISSUE

Production Editor: *Xu Guo*; Production Department Director: *Xiang Li*; Editorial Office Director: *Jin-Lei Wang*.

NAME OF JOURNAL

World Journal of Clinical Cases

ISSN

ISSN 2307-8960 (online)

LAUNCH DATE

April 16, 2013

FREQUENCY

Thrice Monthly

EDITORS-IN-CHIEF

Bao-Gan Peng, Jerzy Tadeusz Chudek, George Kontogeorgos, Maurizio Serati, Ja Hyeon Ku

EDITORIAL BOARD MEMBERS

<https://www.wjnet.com/2307-8960/editorialboard.htm>

PUBLICATION DATE

October 6, 2022

COPYRIGHT

© 2022 Baishideng Publishing Group Inc

INSTRUCTIONS TO AUTHORS

<https://www.wjnet.com/bpg/gerinfo/204>

GUIDELINES FOR ETHICS DOCUMENTS

<https://www.wjnet.com/bpg/GerInfo/287>

GUIDELINES FOR NON-NATIVE SPEAKERS OF ENGLISH

<https://www.wjnet.com/bpg/gerinfo/240>

PUBLICATION ETHICS

<https://www.wjnet.com/bpg/GerInfo/288>

PUBLICATION MISCONDUCT

<https://www.wjnet.com/bpg/gerinfo/208>

ARTICLE PROCESSING CHARGE

<https://www.wjnet.com/bpg/gerinfo/242>

STEPS FOR SUBMITTING MANUSCRIPTS

<https://www.wjnet.com/bpg/GerInfo/239>

ONLINE SUBMISSION

<https://www.f6publishing.com>



Twin reversed arterial perfusion sequence-a rare and dangerous complication form of monochorionic twins: A case report

Nguyen Duy Anh, Nguyen-Thi Thu Ha, Nguyen-Thi Sim, Nguyen Khac Toan, Phan-Thi Huyen Thuong, Nguyen Minh Duc

Specialty type: Medicine, research and experimental

Provenance and peer review: Unsolicited article; Externally peer reviewed.

Peer-review model: Single blind

Peer-review report's scientific quality classification

Grade A (Excellent): 0
Grade B (Very good): B
Grade C (Good): 0
Grade D (Fair): D
Grade E (Poor): 0

P-Reviewer: Aldiansyah D, Indonesia; Singhal A, India

Received: April 21, 2022

Peer-review started: April 21, 2022

First decision: May 30, 2022

Revised: June 9, 2022

Accepted: August 23, 2022

Article in press: August 23, 2022

Published online: October 6, 2022



Nguyen Duy Anh, Nguyen-Thi Sim, Fetal Medicine Center, Hanoi Obstetrics and Gynecology Hospital, Hanoi 100000, Vietnam

Nguyen-Thi Thu Ha, Department of Assisted Reproduction, Hanoi Obstetrics and Gynecology Hospital, Hanoi 100000, Vietnam

Nguyen Khac Toan, Phan-Thi Huyen Thuong, Department of Obstetrics and Gynecology, Hanoi University of Medicine and Pharmacy, Hanoi 100000, Vietnam

Nguyen Minh Duc, Department of Radiology, Pham Ngoc Thach University of Medicine, Ho Chi Minh City 700000, Vietnam

Corresponding author: Nguyen Minh Duc, MD, Department of Radiology, Pham Ngoc Thach University of Medicine, 2 Duong Quang Trung Ward 12 District 10, Ho Chi Minh City 700000, Vietnam. bsnguyenminhduc@pnt.edu.vn

Abstract

BACKGROUND

Twin reversed arterial perfusion (TRAP) sequence is an extremely rare congenital anomaly in monochorionic (MC) twins. The condition is characterized by a malformed fetus (acardiac twin) without cardiac activities being perfused by a structurally normal one (pump twin) *via* an artery-to-artery anastomosis in a reverse direction.

CASE SUMMARY

We described the first case of TRAP to receive laser surgery in Vietnam. The 26-wk pregnancy was originally misdiagnosed in another hospital as MC twins with single intrauterine fetal death. Following admission to our center, the diagnosis was amended to a 26-wk TRAP sequence stage IIb. The acardiac twin was 7.5 cm at the longest length, the ratio of the weight of the acardiac twin to the weight of the pump twin was more than 90%, the pump twin showed fetal distress with absent diastolic flow in umbilical artery of pump twin, and the peak systolic velocity in the middle cerebral artery = 1.6 MoM. We performed emergency laser photocoagulation of the acardiac twin's umbilical cord. After surgery, we successfully maintained the pregnancy for 8 wk and ended it electively by cesarean section at 34 wk of gestation due to rupture of membranes.

CONCLUSION

TRAP should be appropriately diagnosed and treated early to avoid complications of the pump twin. Fetoscopic laser photocoagulation is a new and effective treatment for this condition.

Key Words: Twin reversed arterial perfusion; Acardiac twin; Pump twin; Laser; Case report

©The Author(s) 2022. Published by Baishideng Publishing Group Inc. All rights reserved.

Core Tip: It is an easy mistake to misdiagnose twin reversed arterial perfusion as a single intrauterine fetal death, especially in our case, as the acardiac twin has a head, body, and full limbs. Intrauterine fetal intervention is necessary when the pump twin shows signs of fetal distress. After surgery, the problem of premature rupture of membranes and delivery should be noted. The indication to terminate the pregnancy depends on the mother's condition, fetal condition, and the acardiac twin's longest size.

Citation: Anh ND, Thu Ha NT, Sim NT, Toan NK, Thuong PTH, Duc NM. Twin reversed arterial perfusion sequence-a rare and dangerous complication form of monochorionic twins: A case report. *World J Clin Cases* 2022; 10(28): 10214-10219

URL: <https://www.wjgnet.com/2307-8960/full/v10/i28/10214.htm>

DOI: <https://dx.doi.org/10.12998/wjcc.v10.i28.10214>

INTRODUCTION

Twin reversed arterial perfusion (TRAP) sequence only occurs in monochorionic (MC) twins and has a bad prognosis. The incidence is 1/35000 pregnancies and 1/100 MC twins[1]. In this condition, one fetus has partial or complete lack of cardiac development (called an "acardiac twin") and is perfused with blood by a normal co-twin (called a "pump twin") through abnormal vascular anastomosis connections. As a result, the pump twin shows signs of anemia, heart failure, hydrops fetalis, and the risk of stillbirth. The pump twin has a mortality rate of up to 55%[2-4]. The acardiac twin receives blood from the pump twin, so it continues to grow even larger than the normal co-twin, and postpartum mortality is 100%[2,5]. Early diagnosis by Doppler examination of the umbilical arteries of the two fetuses is necessary for appropriate antenatal management and treatment planning[6,7]. Today, many countries worldwide have successfully intervened in the amniotic cavity to treat TRAP complications, saving 80% of pump twin's lives[6,7].

This report describes the first TRAP sequence case with successful fetal intervention by intrauterine laser therapy in Vietnam.

CASE PRESENTATION

Chief complaints

A 28-year-old pregnant woman was transferred to our fetal medicine center because of polyhydramnios and was diagnosed with stage IIb TRAP sequence from ultrasound images.

History of present illness

This patient at 26 wk of gestation was diagnosed with a MC diamniotic (MCDA) twin with single intrauterine fetal death (SIUD) in another hospital.

History of past illness

Medical records were normal.

Personal and family history

There was no personal or family history of other diseases.

Physical examination

Physical examination was not special.

Laboratory examinations

Blood tests at presentation was in normal range.

Imaging examinations

The pump twin had normal morphology with a three-vessel umbilical cord, polyhydramnios, a maximum vertical pocket (MVP) of 100 mm and an estimated weight of 700 g. Doppler signs of anemia were RI = 1, absent diastolic flow in umbilical artery of pump twin, peak systolic velocity in the middle cerebral artery = 1.6 MoM. The acardiac twin mass was edematous in the whole body; its brain and heart structures were not observed, but it had a torso, four limbs, and a two-vessel umbilical cord. The acardiac twin's longest length was 7.5 cm and it had an estimated weight of 650 g following formula has been proposed to estimate the weight of acardiac fetus: Weight (g) = $1.2 \times (\text{longest length in cm})^2 - (1.7 \times \text{longest length in cm})$ of Moore *et al*[8]. The ratio of the weight of the acardiac twin to the weight of the pump twin was over 90%. Doppler imaging showed reversed blood flow from the pump twin to the acardiac twin (Figure 1).

FINAL DIAGNOSIS

MC twins with stage IIb TRAP sequence.

TREATMENT

The patient was consulted and indicated for emergency surgery of the uterus, using laser photocoagulation to coagulate the umbilical cord of the acardiac twin and block the circulation from the pump twin to the acardiac twin (Figure 2). Combining general anesthesia (intravenous sedation) and local anesthesia was used for the anesthesia procedure (using Lidocaine 1 percent). The procedure was carried out in a chamber designated specifically for fetal surgery. For cord occlusion, a diode laser with a 600 fiber was utilized. The fetoscopic Image IS 4U by Karl Storz (Tuttlingen, Germany), the Medilas D MultiBeam by Dornier, and the Laser Light Guide by Dornier Medtech were utilized. Under ultrasound guidance, the Seldinger method was utilized to access the polyhydramnios cavity. The scope had a 2 mm diameter. The acardiac twin's umbilical cord was reduced using laser photocoagulation. Under direct view, the umbilical cord vessels were ablated; full blockage required power levels between 50 and 60 W. When the whole umbilical cord blood artery was blocked in the acardiac twin, the procedure was deemed successful. The lack of umbilical cord flow at the ablation location as shown by a doppler ultrasonography examination served as proof of that. Then the MVP was emptied until it was within the typical range (MVP 5 or 6 cm).

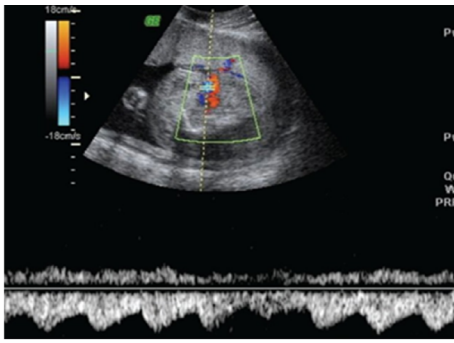
OUTCOME AND FOLLOW-UP

Following surgery, expectant mothers underwent examinations, ultrasounds, and corticosteroid medication at 28 wk of gestation, 48 h, 7 d, and every 2 wk until delivery. Continued monitoring did not show any abnormal signs. After 8 wk and at 34 wk pregnant, the patient suffered from a ruptured membrane and had emergency surgery at Hanoi Obstetrics and Gynecology Hospital to remove the female baby (1400 g, apgar 8-9). The acardiac twin had edema, a small head, torso, all limbs, a weight of 780 g, and normal chromosomes (Figure 3).

DISCUSSION

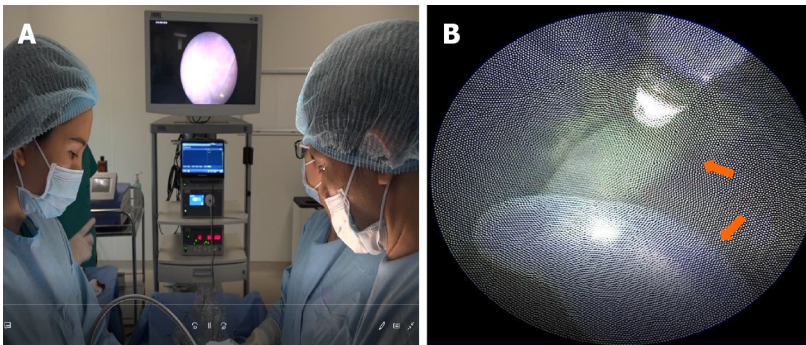
An uncommon problem with MC twins is a sequence known as TRAP. The actual etiology, physiological processes, and pathophysiology are not well understood[8,9]. The acardiac twin may continue to develop throughout an MC pregnancy because of the blood supply provided by the vascular anastomoses. TRAP sequence refers to the way that deoxygenated blood flows from the healthy "pump" twin in the opposite direction into the cord of its deceased "acardiac" co-twin through an artery-to-artery anastomosis. Blood that has been severely hypoxic returns to the pump *via* a vein-to-vein anastomosis. Bypassing the placenta in this manner, the acardiac twin is devoid of a functioning placental area. The health of the pump twin is imperiled by the parasitic acardiac twin in two crucial ways. First, the perfusion of the acardiac twin may result in polyhydramnios and high-output heart failure[8]. A vein-to-vein anastomosis is used to circulate highly deoxygenated blood back to the pump twin, further lowering the oxygen level and resulting in hypoxemia[9].

Due to the development of ultrasound, TRAP syndrome can be diagnosed as early as 11 wk of gestation[7]. The characteristic ultrasound sign that helps diagnose TRAP syndrome is MC twins with one morphologically normal fetus and one structurally highly abnormal fetus without a heart or cardiac activity. Doppler imaging of the umbilical artery shows reverse arterial blood flow to the acardiac twin



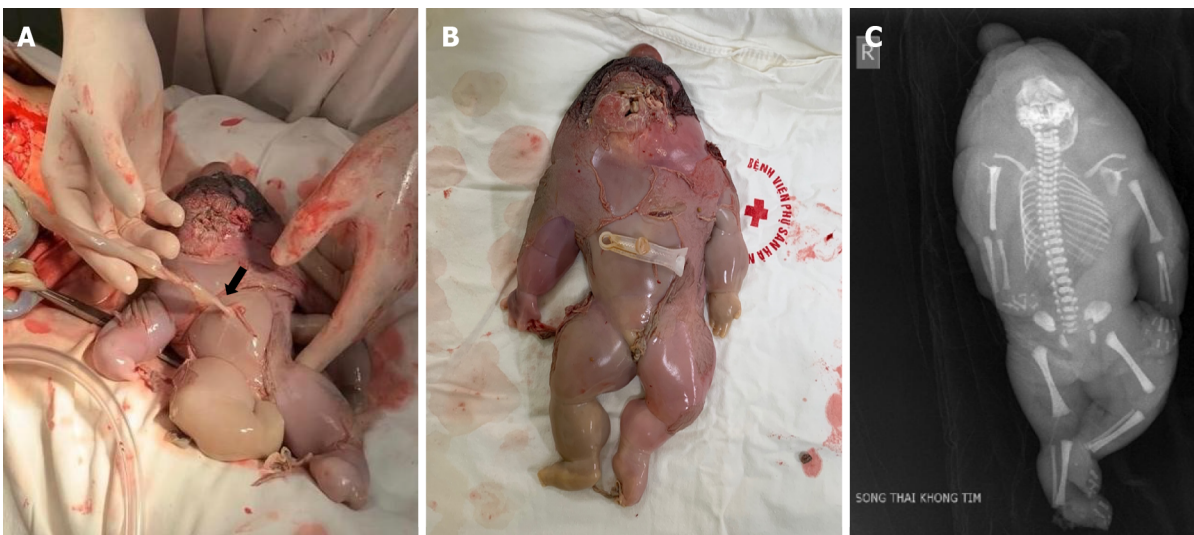
DOI: 10.12998/wjcc.v10.i28.10214 Copyright ©The Author(s) 2022.

Figure 1 Color Doppler image showing an edema acardiac twin with reverse perfusion through the umbilical cord.



DOI: 10.12998/wjcc.v10.i28.10214 Copyright ©The Author(s) 2022.

Figure 2 Intrauterine laser therapy, application of laser coagulation to coagulate acardiac twin's umbilical cord. A: Fetoscopic laser photocoagulation; B: Acardiac twin's umbilical cord (orange arrow).



DOI: 10.12998/wjcc.v10.i28.10214 Copyright ©The Author(s) 2022.

Figure 3 Acardiac twin. A: Laser coagulation site in the acardiac fetal's umbilical cord (black arrow); B: Acardiac twin had edema, a small head, torso and all limbs; C: X-ray image of acardiac twin.

[6,7,10,11]. Our case was diagnosed late due to being previously misdiagnosed as MCDA twins with sIUD. It was an easy mistake to misdiagnose TRAP, especially in our clinical case, as the acardiac twin had a complete structure, including the head, torso, four limbs, and no fetal cardiac activity. The acardiac twin in our case was of the acardius anceps type, accounting for approximately only 10% of TRAP cases (Figure 3)[12]. Therefore, it is essential in clinical practice to closely monitor twins to diagnose the number of placentas, especially in the first trimester. Both MC twin fetuses should be checked for fetal structure, cardiac activity and monitored for size progression. Furthermore, caution

should be exercised in diagnosing stillbirth when the stillbirth mass is still increasing in size. Doppler ultrasound was deemed essential in MC twins to detect abnormalities and for early diagnosis of TRAP syndrome.

The survival of the pump twin and achieving term for delivery are the major objectives in the management of the TRAP sequence[11]. Indications for treatment, including pregnancy management and surgical intervention, depend on the condition of the pump twin[11]. Wong and Sepulveda[11] proposed a classification to help predict the management of the acardiac twin. In our case, despite the delayed diagnosis, it was fortunate that the pump twin had not previously shown signs of anemia or fetal distress. The two fetuses could still develop in the uterus[11]. Fortunately, the patient transferred to our center was diagnosed with TRAP sequence stage IIB, according to Wong and Sepulveda's classification[11]. The pump twin showed signs of anemia and fetal distress, requiring timely intervention. In the following years, the acardius's umbilical cord ablation was identified as a principal target of therapeutic techniques. The most popular methods for treating TRAP sequence appear to be intrauterine laser therapy and radiofrequency ablation, which are both safe and dependable. Our case was treated with laser photocoagulation of the acardiac twin's umbilical cord.

Following surgery, we maintained the pregnancy for a further 8 wk for delivery at 34 wk. Premature rupture of membranes has been one of the most common complications following preterm surgery because laparoscopic laser amniotomy is an interventional procedure. Therefore, it is important to pay attention to treating threatened preterm labor after surgery to increase its success rate. In our case, maintaining the pregnancy for a further 8 wk and increasing the gestational age to 34 wk improved the newborn's survival odds. An elective cesarean section was performed in our clinical case, due to the enormous cardiac fetus, with a diameter of 12 cm at the widest point. Removing the heartless fetus from the uterus was more problematic, despite the elective cesarean section. The indication for pregnancy termination by cesarean section or vaginal delivery depended not only on the mother and fetus' situation but also on the size of the non-cardiac mass. There had been cases of threatened uterine rupture during vaginal deliveries due to large cardiac fetus size[4-6,11]. Thus, the prognosis of delivery in the TRAP sequence depended on the mother's condition, the pump twin, and the maximum diameter of the acardiac twin.

CONCLUSION

TRAP is diagnosed using ultrasound; it is necessary to differentiate it from malformation or sIUD, especially when of the acardius anceps type. Furthermore, it is vital to carefully monitor both fetuses with a weekly Doppler ultrasound to detect complications early, especially signs of heart failure and anemia in the pump twin. If the fetus has signs of poor prognosis requiring interventional treatment, it should be transferred to a fetal intervention center for treatment. The delivery prognosis is based on three factors: The mother's condition, the pump twin's condition, and the acardiac twin's size.

FOOTNOTES

Author contributions: Anh ND and Thu Ha NT contributed equally to this article; Anh ND and Thu Ha NT contributed to the case file retrieval and case summary preparation; Thuong PHT and Duc NM contributed to the preparation of manuscript and editing; All authors read and approved the final manuscript.

Informed consent statement: All study participants or their legal guardian provided informed written consent about personal and medical data collection prior to study enrolment.

Conflict-of-interest statement: All the authors report no relevant conflicts of interest for this article.

CARE Checklist (2016) statement: The authors have read the CARE Checklist (2016), and the manuscript was prepared and revised according to the CARE Checklist (2016).

Open-Access: This article is an open-access article that was selected by an in-house editor and fully peer-reviewed by external reviewers. It is distributed in accordance with the Creative Commons Attribution NonCommercial (CC BY-NC 4.0) license, which permits others to distribute, remix, adapt, build upon this work non-commercially, and license their derivative works on different terms, provided the original work is properly cited and the use is non-commercial. See: <https://creativecommons.org/licenses/by-nc/4.0/>

Country/Territory of origin: Viet Nam

ORCID number: Nguyen Duy Anh 0000-0003-1362-0332; Nguyen Minh Duc 0000-0001-5411-1492.

S-Editor: Fan JR

L-Editor: Filipodia

P-Editor: Fan JR

REFERENCES

- 1 **Hecher K**, Ville Y, Nicolaides KH. Color Doppler ultrasonography in the identification of communicating vessels in twin-twin transfusion syndrome and acardiac twins. *J Ultrasound Med* 1995; **14**: 37-40 [PMID: [7707475](#) DOI: [10.7863/jum.1995.14.1.37](#)]
- 2 **Emery SP**, Bahtiyar MO, Dashe JS, Wilkins-Haug LE, Johnson A, Paek BW, Moon-Grady AJ, Skupski DW, O'Brien BM, Harman CR, Simpson LL. The North American Fetal Therapy Network Consensus Statement: prenatal management of uncomplicated monochorionic gestations. *Obstet Gynecol* 2015; **125**: 1236-1243 [PMID: [25932853](#) DOI: [10.1097/AOG.0000000000000723](#)]
- 3 **Van Allen MI**, Smith DW, Shepard TH. Twin reversed arterial perfusion (TRAP) sequence: a study of 14 twin pregnancies with acardius. *Semin Perinatol* 1983; **7**: 285-293 [PMID: [6658475](#)]
- 4 **Barré M**, Le Vaillant C, Boog G, Joubert M, Winer N, Philippe H. [Acardiac twins: pronostics markers' study]. *Gynecol Obstet Fertil* 2012; **40**: 93-98 [PMID: [22099976](#) DOI: [10.1016/j.gyobfe.2011.08.011](#)]
- 5 **Bharadwaj MK**, Mohana Priya N. A rare complication of monochorionic twin pregnancy: Twin-reversed arterial perfusion (TRAP) sequence. *Med J Armed Forces India* 2015; **71**: S114-S115 [PMID: [26265801](#) DOI: [10.1016/j.mjafi.2013.06.008](#)]
- 6 **Pagani G**, D'Antonio F, Khalil A, Papageorgiou A, Bhide A, Thilaganathan B. Intrafetal laser treatment for twin reversed arterial perfusion sequence: cohort study and meta-analysis. *Ultrasound Obstet Gynecol* 2013; **42**: 6-14 [PMID: [23640771](#) DOI: [10.1002/uog.12495](#)]
- 7 **Bornstein E**, Monteagudo A, Dong R, Schwartz N, Timor-Tritsch IE. Detection of twin reversed arterial perfusion sequence at the time of first-trimester screening: the added value of 3-dimensional volume and color Doppler sonography. *J Ultrasound Med* 2008; **27**: 1105-1109 [PMID: [18577678](#) DOI: [10.7863/jum.2008.27.7.1105](#)]
- 8 **Moore TR**, Gale S, Benirschke K. Perinatal outcome of forty-nine pregnancies complicated by acardiac twinning. *Am J Obstet Gynecol* 1990; **163**: 907-912 [PMID: [2206078](#) DOI: [10.1016/0002-9378\(90\)91094-s](#)]
- 9 **Peyvandi S**, Feldstein VA, Hirose S, Rand L, Brook MM, Moon-Grady AJ. Twin-reversed arterial perfusion sequence associated with decreased fetal cerebral vascular impedance. *Ultrasound Obstet Gynecol* 2015; **45**: 447-451 [PMID: [25157457](#) DOI: [10.1002/uog.14650](#)]
- 10 **Sepúlveda WH**, Quiroz VH, Giuliano A, Henríquez R. Prenatal ultrasonographic diagnosis of acardiac twin. *J Perinat Med* 1993; **21**: 241-246 [PMID: [8229616](#) DOI: [10.1515/jpme.1993.21.3.241](#)]
- 11 **Wong AE**, Sepulveda W. Acardiac anomaly: current issues in prenatal assessment and treatment. *Prenat Diagn* 2005; **25**: 796-806 [PMID: [16170844](#) DOI: [10.1002/pd.1269](#)]
- 12 **Napolitani FD**, Schreiber I. The acardiac monster. A review of the world literature and presentation of 2 cases. *Am J Obstet Gynecol* 1960; **80**: 582-589 [PMID: [13727747](#) DOI: [10.1016/s0002-9378\(16\)36520-6](#)]



Published by **Baishideng Publishing Group Inc**
7041 Koll Center Parkway, Suite 160, Pleasanton, CA 94566, USA

Telephone: +1-925-3991568

E-mail: bpgoffice@wjgnet.com

Help Desk: <https://www.f6publishing.com/helpdesk>

<https://www.wjgnet.com>

