

World Journal of *Clinical Cases*

World J Clin Cases 2022 October 26; 10(30): 10823-11213



Contents

Thrice Monthly Volume 10 Number 30 October 26, 2022

REVIEW

- 10823** New insights into the interplay between intestinal flora and bile acids in inflammatory bowel disease
Zheng L
- 10840** Role of visfatin in obesity-induced insulin resistance
Abdalla MMI

MINIREVIEWS

- 10852** Hyperthermic intraperitoneal chemotherapy and colorectal cancer: From physiology to surgery
Ammerata G, Filippo R, Laface C, Memeo R, Solaini L, Cavaliere D, Navarra G, Ranieri G, Currò G, Ammendola M
- 10862** New-onset diabetes secondary to acute pancreatitis: An update
Yu XQ, Zhu Q
- 10867** Ketosis-prone diabetes mellitus: A phenotype that hospitalists need to understand
Boike S, Mir M, Rauf I, Jama AB, Sunesara S, Mushtaq H, Khedr A, Nitesh J, Surani S, Khan SA
- 10873** 2022 Monkeypox outbreak: Why is it a public health emergency of international concern? What can we do to control it?
Ren SY, Li J, Gao RD

ORIGINAL ARTICLE

Retrospective Cohort Study

- 10882** Clinical characteristics and prognosis of non-small cell lung cancer patients with liver metastasis: A population-based study
Wang JF, Lu HD, Wang Y, Zhang R, Li X, Wang S

Retrospective Study

- 10896** Prevalence and risk factors for *Candida* esophagitis among human immunodeficiency virus-negative individuals
Chen YH, Jao TM, Shiue YL, Feng IJ, Hsu PI
- 10906** Prognostic impact of number of examined lymph nodes on survival of patients with appendiceal neuroendocrine tumors
Du R, Xiao JW

Observational Study

- 10921** Clinical and epidemiological features of ulcerative colitis patients in Sardinia, Italy: Results from a multicenter study
Magri S, Demurtas M, Onidi MF, Picchio M, Elisei W, Marzo M, Miculan F, Manca R, Dore MP, Quarta Colosso BM, Cicu A, Cugia L, Carta M, Binaghi L, Usai P, Lai M, Chicco F, Fantini MC, Armuzzi A, Mocci G

- 10931** Clinical observation of laparoscopic cholecystectomy combined with endoscopic retrograde cholangiopancreatography or common bile duct lithotripsy

Niu H, Liu F, Tian YB

Prospective Study

- 10939** Patient reported outcome measures in anterior cruciate ligament rupture and reconstruction: The significance of outcome score prediction

Al-Dadah O, Shepstone L, Donell ST

SYSTEMATIC REVIEWS

- 10956** Body mass index and outcomes of patients with cardiogenic shock: A systematic review and meta-analysis

Tao WX, Qian GY, Li HD, Su F, Wang Z

META-ANALYSIS

- 10967** Impact of being underweight on peri-operative and post-operative outcomes of total knee or hip arthroplasty: A meta-analysis

Ma YP, Shen Q

- 10984** Branched-chain amino acids supplementation has beneficial effects on the progression of liver cirrhosis: A meta-analysis

Du JY, Shu L, Zhou YT, Zhang L

CASE REPORT

- 10997** Wells' syndrome possibly caused by hematologic malignancy, influenza vaccination or ibrutinib: A case report

Šajin M, Luzar B, Zver S

- 11004** Giant cutaneous squamous cell carcinoma of the popliteal fossa skin: A case report

Wang K, Li Z, Chao SW, Wu XW

- 11010** Right time to detect urine iodine during papillary thyroid carcinoma diagnosis and treatment: A case report

Zhang SC, Yan CJ, Li YF, Cui T, Shen MP, Zhang JX

- 11016** Two novel mutations in the *VPS33B* gene in a Chinese patient with arthrogryposis, renal dysfunction and cholestasis syndrome 1: A case report

Yang H, Lin SZ, Guan SH, Wang WQ, Li JY, Yang GD, Zhang SL

- 11023** Effect of electroacupuncture for Pisa syndrome in Parkinson's disease: A case report

Lu WJ, Fan JQ, Yan MY, Mukaeda K, Zhuang LX, Wang LL

- 11031** Neonatal Cri du chat syndrome with atypical facial appearance: A case report

Bai MM, Li W, Meng L, Sang YF, Cui YJ, Feng HY, Zong ZT, Zhang HB

- 11037** Complete colonic duplication presenting as hip fistula in an adult with pelvic malformation: A case report

Cai X, Bi JT, Zheng ZX, Liu YQ

- 11044** Autoimmune encephalitis with posterior reversible encephalopathy syndrome: A case report
Dai SJ, Yu QJ, Zhu XY, Shang QZ, Qu JB, Ai QL
- 11049** Hypophysitis induced by anti-programmed cell death protein 1 immunotherapy in non-small cell lung cancer: Three case reports
Zheng Y, Zhu CY, Lin J, Chen WS, Wang YJ, Fu HY, Zhao Q
- 11059** Different intraoperative decisions for undiagnosed paraganglioma: Two case reports
Kang D, Kim BE, Hong M, Kim J, Jeong S, Lee S
- 11066** Hepatic steatosis with mass effect: A case report
Hu N, Su SJ, Li JY, Zhao H, Liu SF, Wang LS, Gong RZ, Li CT
- 11074** Bone marrow metastatic neuroendocrine carcinoma with unknown primary site: A case report and review of the literature
Shi XB, Deng WX, Jin FX
- 11082** Child with adenylosuccinate lyase deficiency caused by a novel complex heterozygous mutation in the ADSL gene: A case report
Wang XC, Wang T, Liu RH, Jiang Y, Chen DD, Wang XY, Kong QX
- 11090** Recovery of brachial plexus injury after bronchopleural fistula closure surgery based on electrodiagnostic study: A case report and review of literature
Go YI, Kim DS, Kim GW, Won YH, Park SH, Ko MH, Seo JH
- 11101** Severe *Klebsiella pneumoniae* pneumonia complicated by acute intra-abdominal multiple arterial thrombosis and bacterial embolism: A case report
Bao XL, Tang N, Wang YZ
- 11111** Spontaneous bilateral femur neck fracture secondary to grand mal seizure: A case report
Senocak E
- 11116** Favorable response after radiation therapy for intraductal papillary mucinous neoplasms manifesting as acute recurrent pancreatitis: A case report
Harigai A, Kume K, Takahashi N, Omata S, Umezawa R, Jingu K, Masamune A
- 11122** Acute respiratory distress syndrome following multiple wasp stings treated with extracorporeal membrane oxygenation: A case report
Cai ZY, Xu BP, Zhang WH, Peng HW, Xu Q, Yu HB, Chu QG, Zhou SS
- 11128** Morphological and electrophysiological changes of retina after different light damage in three patients: Three case reports
Zhang X, Luo T, Mou YR, Jiang W, Wu Y, Liu H, Ren YM, Long P, Han F
- 11139** Perirectal epidermoid cyst in a patient with sacroccygeal scoliosis and anal sinus: A case report
Ji ZX, Yan S, Gao XC, Lin LF, Li Q, Yao Q, Wang D

- 11146** Synchronous gastric cancer complicated with chronic myeloid leukemia (multiple primary cancers): A case report
Zhao YX, Yang Z, Ma LB, Dang JY, Wang HY
- 11155** Giant struma ovarii with pseudo-Meigs's syndrome and raised cancer antigen-125 levels: A case report
Liu Y, Tang GY, Liu L, Sun HM, Zhu HY
- 11162** Longest survival with primary intracranial malignant melanoma: A case report and literature review
Wong TF, Chen YS, Zhang XH, Hu WM, Zhang XS, Lv YC, Huang DC, Deng ML, Chen ZP
- 11172** Spontaneous remission of hepatic myelopathy in a patient with alcoholic cirrhosis: A case report
Chang CY, Liu C, Duan FF, Zhai H, Song SS, Yang S
- 11178** Cauda equina syndrome caused by the application of DuraSeal™ in a microlaminectomy surgery: A case report
Yeh KL, Wu SH, Fuh CS, Huang YH, Chen CS, Wu SS
- 11185** Bioceramics utilization for the repair of internal resorption of the root: A case report
Riyahi AM
- 11190** Fibrous hamartoma of infancy with bone destruction of the tibia: A case report
Qiao YJ, Yang WB, Chang YF, Zhang HQ, Yu XY, Zhou SH, Yang YY, Zhang LD
- 11198** Accidental esophageal intubation *via* a large type C congenital tracheoesophageal fistula: A case report
Hwang SM, Kim MJ, Kim S, Kim S
- 11204** Ventral hernia after high-intensity focused ultrasound ablation for uterine fibroids treatment: A case report
Park JW, Choi HY

LETTER TO THE EDITOR

- 11210** C-Reactive protein role in assessing COVID-19 deceased geriatrics and survivors of severe and critical illness
Nori W

ABOUT COVER

Editorial Board Member of *World Journal of Clinical Cases*, Rajeev Gurunath Redkar, FRCS, FRCS (Ed), FRCS (Gen Surg), MBBS, MCh, MS, Dean, Professor, Surgeon, Department of Pediatric Surgery, Lilavati Hospital and Research Centre, Mumbai 400050, Maharashtra, India. rajeev.redkar@gmail.com

AIMS AND SCOPE

The primary aim of *World Journal of Clinical Cases* (WJCC, *World J Clin Cases*) is to provide scholars and readers from various fields of clinical medicine with a platform to publish high-quality clinical research articles and communicate their research findings online.

WJCC mainly publishes articles reporting research results and findings obtained in the field of clinical medicine and covering a wide range of topics, including case control studies, retrospective cohort studies, retrospective studies, clinical trials studies, observational studies, prospective studies, randomized controlled trials, randomized clinical trials, systematic reviews, meta-analysis, and case reports.

INDEXING/ABSTRACTING

The WJCC is now abstracted and indexed in Science Citation Index Expanded (SCIE, also known as SciSearch®), Journal Citation Reports/Science Edition, Current Contents®/Clinical Medicine, PubMed, PubMed Central, Scopus, Reference Citation Analysis, China National Knowledge Infrastructure, China Science and Technology Journal Database, and Superstar Journals Database. The 2022 Edition of Journal Citation Reports® cites the 2021 impact factor (IF) for WJCC as 1.534; IF without journal self cites: 1.491; 5-year IF: 1.599; Journal Citation Indicator: 0.28; Ranking: 135 among 172 journals in medicine, general and internal; and Quartile category: Q4. The WJCC's CiteScore for 2021 is 1.2 and Scopus CiteScore rank 2021: General Medicine is 443/826.

RESPONSIBLE EDITORS FOR THIS ISSUE

Production Editor: *Ying-Yi Yuan*; Production Department Director: *Xu Guo*; Editorial Office Director: *Jin-Lei Wang*.

NAME OF JOURNAL

World Journal of Clinical Cases

ISSN

ISSN 2307-8960 (online)

LAUNCH DATE

April 16, 2013

FREQUENCY

Thrice Monthly

EDITORS-IN-CHIEF

Bao-Gan Peng, Jerzy Tadeusz Chudek, George Kontogeorgos, Maurizio Serati, Ja Hyeon Ku

EDITORIAL BOARD MEMBERS

<https://www.wjgnet.com/2307-8960/editorialboard.htm>

PUBLICATION DATE

October 26, 2022

COPYRIGHT

© 2022 Baishideng Publishing Group Inc

INSTRUCTIONS TO AUTHORS

<https://www.wjgnet.com/bpg/gerinfo/204>

GUIDELINES FOR ETHICS DOCUMENTS

<https://www.wjgnet.com/bpg/GerInfo/287>

GUIDELINES FOR NON-NATIVE SPEAKERS OF ENGLISH

<https://www.wjgnet.com/bpg/gerinfo/240>

PUBLICATION ETHICS

<https://www.wjgnet.com/bpg/GerInfo/288>

PUBLICATION MISCONDUCT

<https://www.wjgnet.com/bpg/gerinfo/208>

ARTICLE PROCESSING CHARGE

<https://www.wjgnet.com/bpg/gerinfo/242>

STEPS FOR SUBMITTING MANUSCRIPTS

<https://www.wjgnet.com/bpg/GerInfo/239>

ONLINE SUBMISSION

<https://www.f6publishing.com>



Hypophysitis induced by anti-programmed cell death protein 1 immunotherapy in non-small cell lung cancer: Three case reports

Yun Zheng, Chen-Yu Zhu, Jing Lin, Wang-Shan Chen, Yu-Jie Wang, Hong-Ye Fu, Qiong Zhao

Specialty type: Medicine, research and experimental

Provenance and peer review: Unsolicited article; Externally peer reviewed.

Peer-review model: Single blind

Peer-review report's scientific quality classification

Grade A (Excellent): 0
Grade B (Very good): 0
Grade C (Good): C, C
Grade D (Fair): 0
Grade E (Poor): 0

P-Reviewer: Hashimoto K, Japan; Shalaby MN, Egypt

Received: May 12, 2022

Peer-review started: May 12, 2022

First decision: June 16, 2022

Revised: July 9, 2022

Accepted: September 16, 2022

Article in press: September 16, 2022

Published online: October 26, 2022



Yun Zheng, Chen-Yu Zhu, Qiong Zhao, Zhejiang University School of Medicine, Zhejiang University, Hangzhou 310030, Zhejiang Province, China

Yun Zheng, Chen-Yu Zhu, Jing Lin, Wang-Shan Chen, Yu-Jie Wang, Hong-Ye Fu, Qiong Zhao, Department of Thoracic Oncology, Shulan (Hangzhou) Hospital affiliated to Zhejiang Shuren University Shulan International Medical College, Hangzhou 310000, Zhejiang Province, China

Yu-Jie Wang, Hong-Ye Fu, Zhejiang Chinese Medical University, Hangzhou 311402, Zhejiang Province, China

Corresponding author: Qiong Zhao, PhD, Doctor, Zhejiang University School of Medicine, Zhejiang University, No. 866 Yuhangtang Road, Xihu District, Hangzhou 310030, Zhejiang Province, China. jade1972@126.com

Abstract

BACKGROUND

Hypophysitis induced by programmed cell death 1 protein (PD-1) immune checkpoint inhibitors is rare and poorly described. We report three patients with non-small cell lung cancer who developed hypophysitis after anti-PD-1 immunotherapy.

CASE SUMMARY

Both case 1 and case 2 presented with common symptoms of fatigue, nausea, and vomiting. However, case 3 showed rare acute severe symptoms such as hoarse voice, bucking, and difficulty in breathing even when sitting. Following two cycles of immunotherapy in case 3, the above severe symptoms and pituitary gland enlargement were found on magnetic resonance imaging at the onset of hypophysitis. These symptoms were relieved after 10 d of steroid treatment. Case 3 was the first patient with these specific symptoms, which provided a new insight into the diagnosis of hypophysitis. In addition, we found that the clinical prognosis of patients with hypophysitis was related to the dose of steroid therapy. Case 3 was treated with high-dose hormone therapy and her pituitary-corticotrophic axis dysfunction returned to normal after more than 6 mo of steroid treatment. Cases 1 and 2 were treated with the low-dose hormone, and dysfunction of the pituitary-corticotrophic axis was still present after up to 7 mo of steroid treatment.

CONCLUSION

The clinical symptoms described in this study provide a valuable reference for the

diagnosis and treatment of immune-related hypophysitis.

Key Words: Programmed cell death protein 1; Immunotherapy; Hypophysitis; Lung cancer; Case reports

©The Author(s) 2022. Published by Baishideng Publishing Group Inc. All rights reserved.

Core Tip: Hypophysitis induced by programmed cell death 1 protein (PD-1) inhibitor treatment in non-small cell lung cancer (NSCLC) was rarely reported. In this study, we report three patients with NSCLC who developed hypophysitis induced by PD-1 immune checkpoint inhibitor treatment. Our study suggested that unexpected fatigue, appetite decreases, nausea, vomiting, hoarse voice, bucking, and difficulty breathing were largely correlated with immune-related hypophysitis. We also found that the clinical prognosis of patients with hypophysitis was related to the dose of steroid therapy. This work provided a reference for the diagnosis and timely treatment of hypophysitis in the clinic.

Citation: Zheng Y, Zhu CY, Lin J, Chen WS, Wang YJ, Fu HY, Zhao Q. Hypophysitis induced by anti-programmed cell death protein 1 immunotherapy in non-small cell lung cancer: Three case reports. *World J Clin Cases* 2022; 10(30): 11049-11058

URL: <https://www.wjgnet.com/2307-8960/full/v10/i30/11049.htm>

DOI: <https://dx.doi.org/10.12998/wjcc.v10.i30.11049>

INTRODUCTION

Immunotherapy of tumors has become a new treatment method in addition to traditional malignant tumor treatment such as surgery, radiotherapy, and chemotherapy. Recently, immune checkpoint inhibitors (ICIs) have attracted more and more attention due to their more favorable clinical outcome than conventional therapy in terminal cancer. ICIs can enhance anti-tumor activity by targeting key points in the immune system, such as cytotoxic T-lymphocyte protein 4 (CTLA4), programmed death 1 (PD-1), and its ligand programmed cell death 1 ligand 1 (PD-L1)[1]. Several immunotherapeutic drugs have been approved for the treatment of melanoma, lung cancer, and urinary tract cancer[2].

Due to the regulatory effect of ICIs on the immune system, they may induce several immune-related adverse events (irAEs) as they lack specificity and result in generalized immune activation. The irAEs occur in various organs such as the skin, gastrointestinal tract, and liver, and induce frequent dysfunction of the endocrine system[3]. Thyroid dysfunction is the most common side effect in the endocrine system; 6.5% of patients treated with ICIs developed hypothyroidism and 2.9% developed hyperthyroidism[4]. Thyroid dysfunction commonly occurs in patients treated with PD-1 or PD-L1 inhibitors. Immune-related hypophysitis (IRH) is the second most common adverse event caused by ICI treatment, which is largely induced by CTLA4 inhibitors with an incidence between 5.6% and 13.6%[5]. However, it is less common with PD-1 inhibitors (0.5%-1.1%)[6] and PD-L1 inhibitors (less than 0.1%).

Hypophysitis induced by CTLA4 inhibitors has been well documented. However, PD-1 and PD-L1 inhibitor-induced hypophysitis has been newly proposed and poorly described, probably because these drugs were approved later than CTLA4 inhibitors[7]. In the present study, we retrospectively analyzed 56 patients with advanced non-small-cell lung cancer (NSCLC) treated with an anti-PD-1 drug from 2019 to 2020 at Shulan (Hangzhou) Hospital. Three cases were diagnosed with IRH. We report these three cases of hypophysitis induced by anti-PD-1 treatment to provide new insights into its diagnosis and treatment.

CASE PRESENTATION

Chief complaints

Case 1: A 57-year-old man was diagnosed with lung squamous cell carcinoma (pT2N3M0, stage IIIB). He then received the anti-tumor treatment but he presented fatigue (grade 1 according to CTCAE version 4.0), decreased appetite (grade 1), and liver damage (grade 1).

Case 2: A 74-year-old man was diagnosed with lung adenosquamous carcinoma (pT2bN2M1, stage IV). After receiving the anti-tumor treatment, he presented severe nausea and vomiting (grade 3).

Case 3: A 54-year-old female patient was diagnosed with lung adenocarcinoma and bone metastases (pT4N2M1, stage IV). After treatment, the patient complained of fatigue, hoarse voice, bucking, and

difficulty in breathing even when sitting (grade 3).

History of present illness

Case 1: The patient refused radiotherapy and underwent four cycles of combination treatment with chemotherapy (docetaxel 75 mg/m² plus nedaplatin 80 mg/m²) and anti-PD-1 drug (toripalimab 240 mg). He then received maintenance therapy with the anti-PD-1 drug only.

Case 2: The patient was treated with adjuvant combination chemotherapy (docetaxel 75 mg/m² plus nedaplatin 80 mg/m²) and an anti-PD-1 drug (pembrolizumab 200 mg) for 4 cycles. The patient did not receive continuous maintenance therapy with pembrolizumab as he developed immune-related pneumonia. He was then followed every 3 mo without any treatment. Four months later, he was taken to hospital due to severe nausea and vomiting (grade 3).

Case 3: After the patient was diagnosed, she was treated with a combination of chemotherapy (pemetrexed 500 mg/m² and nedaplatin 80 mg/m²), targeted therapy (bevacizumab 7.5 mg/kg), and anti-PD-1 (toripalimab 240 mg) therapy. Two cycles later, chest computed tomography (CT) reexamination demonstrated that the lung lesions had diminished and the curative effect was considered a significant partial remission. Unfortunately, the patient complained of fatigue, hoarse voice, bucking, and difficulty in breathing even when sitting.

History of past illness

Case 1: The patient had no history of autoimmunity.

Case 2: The patient underwent radical resection of the left lung cancer and presented with pleural metastasis.

Case 3: The patient did not have a history of autoimmunity.

Personal and family history

All patients have no family history of autoimmune disorders.

Physical examination

Case 1: The Eastern Cooperative Oncology Group (ECOG) score was 1 and Nutritional Risk Screening (NRS) score was 0. Murphy's sign was negative. Other physical examination was unremarkable.

Case 2: The ECOG score was 1 and NRS score was 0. Murphy's sign was negative. Other physical examination was unremarkable.

Case 3: The ECOG score was 1 and NRS score was 1. The psychological reflection was normal and no pathological reflection was induced. Other physical examination was unremarkable.

Laboratory examinations

Case 1: The patient had no epidermal growth factor receptor (EGFR) mutations or anaplastic lymphoma kinase (ALK) rearrangements. Thyroid stimulating hormone (TSH), free thyroxine (FT4), adrenocorticotrophic hormone (ACTH), and cortisol levels were all normal before immunotherapy in 2020. The levels of TSH and FT4 were slightly abnormal (Figure 1E, January 29, 2020) after anti-PD-1 treatment.

Case 2: The patient had no EGFR mutations or ALK rearrangements and no history of autoimmunity. The PD-L1 tumor proportion score was greater than 50%. The levels of TSH and FT4 were normal (Figure 2E, April 15, 2020).

Case 3: After the patient was diagnosed, the patient presented no EGFR mutations or ALK rearrangements. When the symptoms such as fatigue and hoarse voice appeared, the levels of ACTH (5.37 pg/mL) and cortisol (2 µg/dL) were lower than the normal range (Figure 3F).

Imaging examinations

Case 1: Magnetic resonance imaging (MRI) showed that the pituitary morphology (Figure 1A) was normal before immunotherapy in 2020. When the patient first exhibited fatigue, decreased appetite, and liver damage, the pituitary enlargement was also not found (Figure 1B).

Case 2: We performed cranial MRI and lumbar puncture, but no pituitary abnormalities (Figure 2A) or meningeal metastasis were found.

Case 3: The baseline chest CT is presented in Figure 3A. When the symptoms such as fatigue and hoarse voice appeared, we performed a 3T laryngoscopy but found no vocal cord disorders. We then performed pituitary MRI, and found that the pituitary gland was slightly enlarged (Figure 3D) compared with that at baseline (Figure 3C).

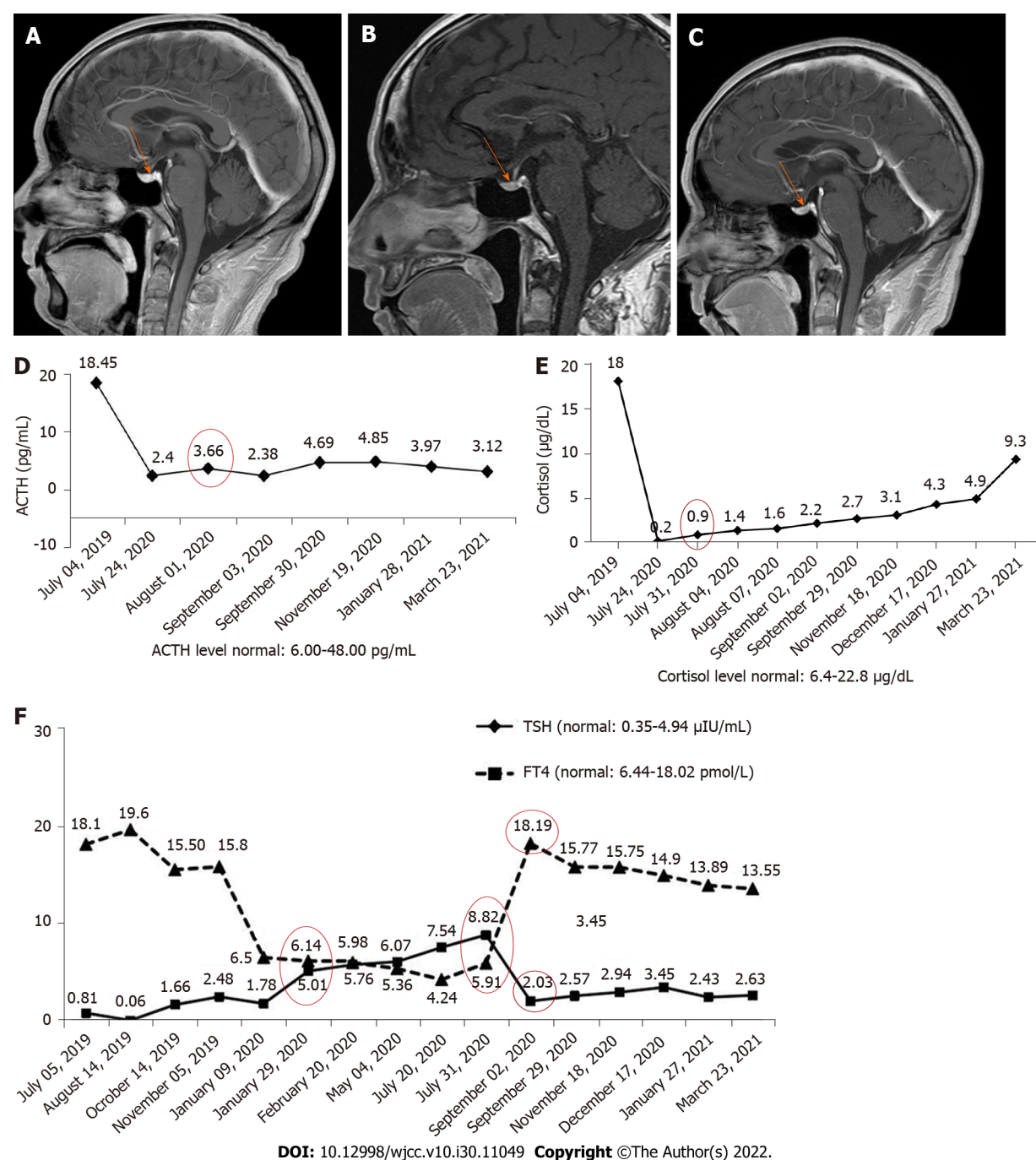


Figure 1 Pituitary magnetic resonance imaging and laboratory examination results in case 1. A: The pituitary was normal before starting immunotherapy (November 30, 2019); B: Pituitary enlargement was not found at the onset of immune-related hypophysitis (July 26, 2020); C: The pituitary was normal after steroid treatment (December 18, 2020); D: The levels of adrenocorticotrophic hormone and cortisol; E: The levels of thyroid stimulating hormone and free thyroxine. ACTH: Adrenocorticotrophic hormone; TSH: Thyroid stimulating hormone; FT4: Free thyroxine.

FINAL DIAGNOSIS

Case 1: The patient was diagnosed with hypothyroidism and secondary adrenal insufficiency induced by hypophysitis due to anti-PD-1 treatment according to his medical history, clinical features, and laboratory measurements.

Case 2: According to his treatment history and clinical symptoms, the patient was diagnosed with hypothyroidism induced by anti-PD-1 treatment.

Case 3: Following a multidisciplinary consultation, the diagnosis of IRH was made after excluding all other possible cause.

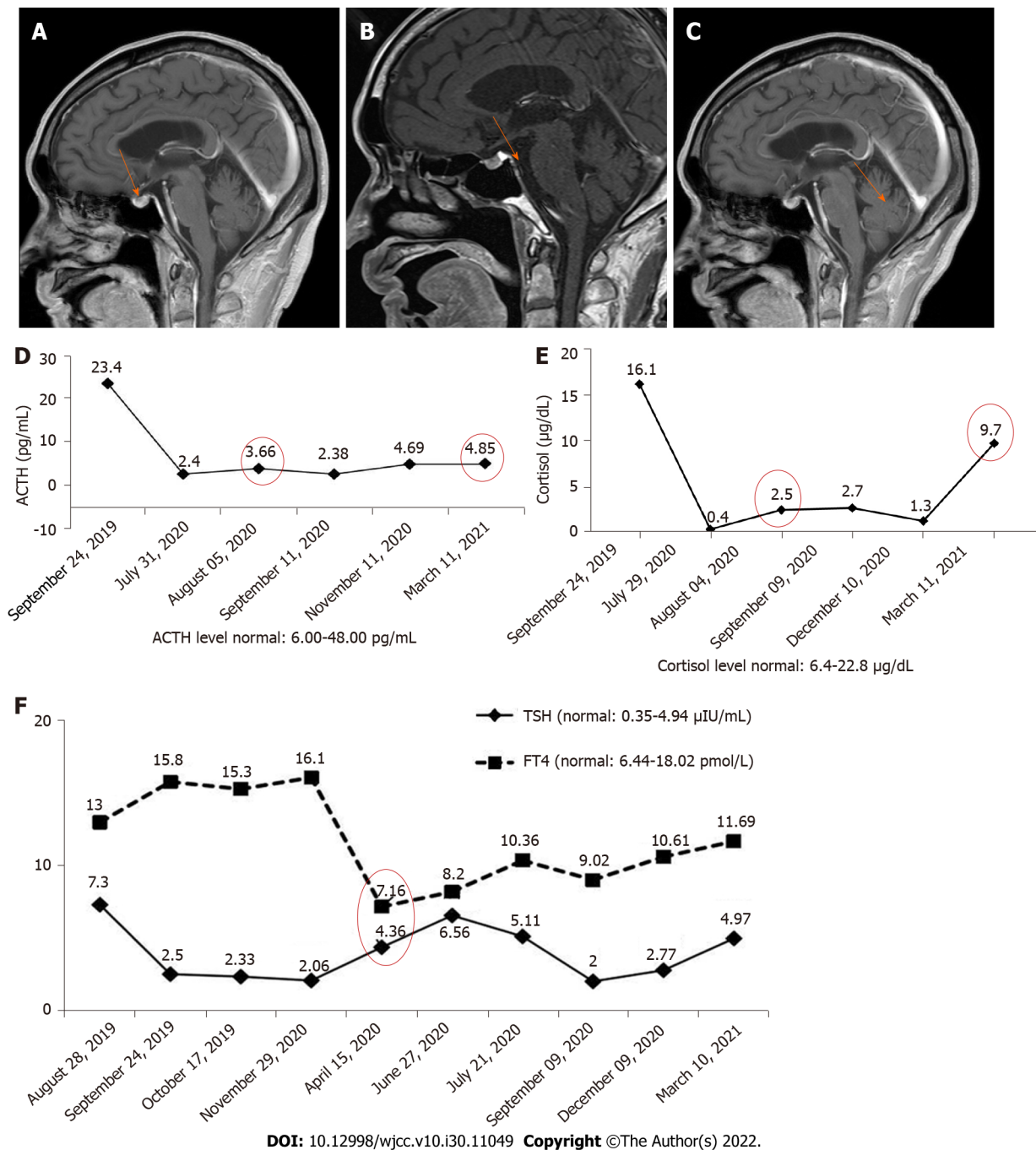


Figure 2 Pituitary magnetic resonance imaging and laboratory examination results in case 2. A: The pituitary was normal when the patient developed nausea and vomiting for the first time; B: Pituitary enlargement was not found when the patient complained of nausea and vomiting for the second time; C: The pituitary was normal after 2 mo of steroid treatment; D: Adrenocorticotrophic hormone and cortisol levels; E: Thyroid stimulating hormone and free thyroxine. ACTH: Adrenocorticotrophic hormone; TSH: Thyroid stimulating hormone; FT4: Free thyroxine.

TREATMENT

Case 1: When the patient first exhibited fatigue, decreased appetite, and liver damage, we decreased the frequency of toripalimab administration. After one cycle of maintenance treatment, he was hospitalized again due to increased fatigue, severe nausea, and vomiting (grade 3). The patient discontinued anti-PD-1 maintenance treatment. The frequency of anti-PD-1 treatment was then adjusted and the patient was continuously treated for 6 mo, but the levels of TSH and FT4 were still abnormal (July 31, 2020). We also found abnormal levels of ACTH (3.66 pg/mL) and cortisol (0.9 μg/dL) (Figure 1D) at this time, suggesting that the symptoms were caused by secondary adrenal insufficiency. The patient was subsequently treated with hormone and thyroxine replacement therapy. He took oral hydrocortisone 50 mg/d and then given oral prednisone 25 mg/d. The dose of prednisone was then tapered to 1 tablet every 14 d, and finally reduced to 1 tablet.

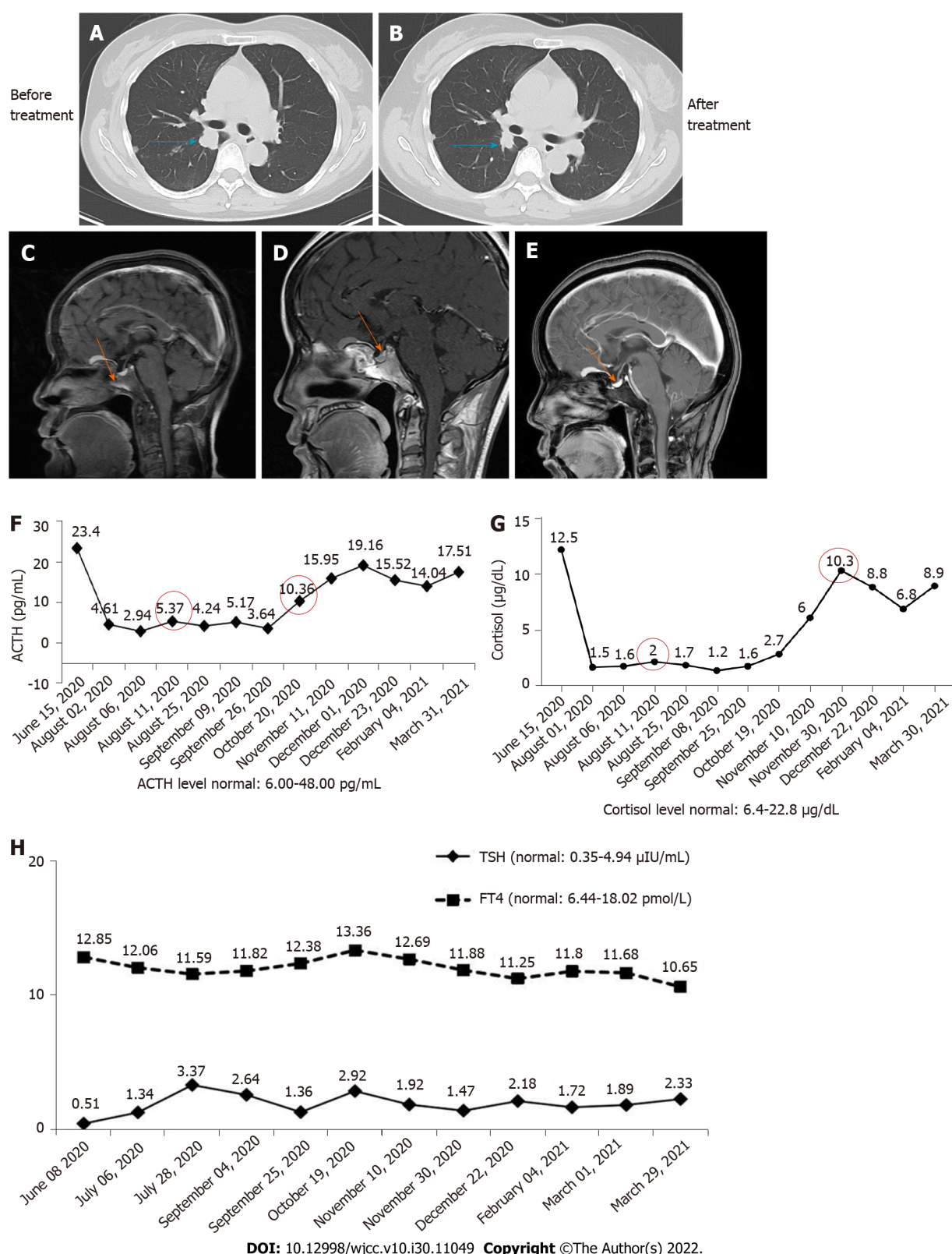


Figure 3 Imaging examination and laboratory results in case 3. A: Chest computed tomography (CT) image at baseline; B: Chest CT image after two cycles of combination therapy; C: The pituitary was normal before combination therapy (June 9, 2020); D: Pituitary enlargement was found after two cycles of combination therapy (August 8, 2020); E: The pituitary was normal after nearly 2 mo of steroid treatment (September 27, 2020); F: Adrenocorticotrophic hormone and cortisol levels; G: Thyroid stimulating hormone and free thyroxine. ACTH: Adrenocorticotrophic hormone; TSH: Thyroid stimulating hormone; FT4: Free thyroxine.

Case 2: After the patient visited our hospital, we treated the patient with an antiemetic agent and his discomfort was relieved but prone to recurrence. After 3 mo of antiemetic treatment, he complained of nausea and vomiting exacerbation and a 5 kg weight loss. Pituitary MRI was performed again, but revealed no enlargement of the pituitary (Figure 2B). However, an empty sella was found on the

pituitary MRI. At the same time, the levels of ACTH (3.66 pg/mL) and cortisol (2.5 µg/mL) were abnormally lower than the normal range (Figure 2D). Obvious dysfunction of the pituitary-thyroid axis was not found. He subsequently received hormone therapy. Oral prednisone was administered at a dosage of 2.5 mg bid.

Case 3: The patient received hormone shock therapy. First, 200 mg/d methylprednisolone was injected for 4 d, and then 160 mg/d and 120 mg/d methylprednisolone for 3 d, respectively. After hormone therapy, the patient's discomfort was gradually relieved. Next, we discontinued anti-PD-1 treatment and the patient received continuous administration of combined chemotherapy and targeted therapy for two cycles. Pemetrexed and bevacizumab were then administered as uninterrupted maintenance therapy. We also adjusted the administration of hormone therapy. Methylprednisolone 80 mg/d was given for 8 d and 5 g/d allotyped for 5 d. Although her discomfort completely disappeared, the levels of ACTH and cortisol were not obviously changed. The dose of methylprednisolone was then reduced by 20%-30% every 7 d to 5 mg/d.

OUTCOME AND FOLLOW-UP

Case 1: When the patient took oral hydrocortisone for 1 wk, his discomfort was significantly reduced. After 1 mo of steroid treatment, the levels of TSH and FT4 were found to be in the normal range (September 2, 2020). In addition, dysfunction of the pituitary-gonadal axis and abnormality of pituitary morphology (Figure 1C) were not found. However, function of the pituitary-adrenal axis was abnormal for an extended period (Figure 1D).

Case 2: After 2 wk of hormone treatment, the patient's symptoms were significantly relieved. Four months later, the pituitary gland was normal (Figure 2C), but the pituitary-corticotrophic axis was still abnormal after 7 mo of steroid treatment (ACTH = 4.85 pg/mL).

Case 3: After almost 2 mo of hormone therapy, pituitary enlargement diminished (Figure 3E). Three months later, the level of ACTH (10.36 pg/mL) returned to normal, and cortisol level (10.3 µg/dL) also returned to normal after more than 4 mo of hormone therapy. No dysfunction of the pituitary-thyroid axis (Figure 3G) or the pituitary-gonadal axis was observed during the treatment period.

DISCUSSION

It is acknowledged that several human cancers can escape immune surveillance through the expression of PD-1. PD-1 is able to inhibit T-cell action against tumor cells; therefore, anti-PD-1 treatment has become an effective therapy by promoting the anti-tumor immune response. However, the main function of PD-1 in the healthy body is to suppress the autoimmune response, and inhibition of this system also triggers the T-cell inflammatory response against any susceptible healthy tissues[8]. Despite anti-PD-1 treatment having a remarkable impact on advanced cancers, it also induces wide-ranging irAEs.

The mechanism of irAEs remains unknown. Dysfunction of the endocrine system is one of the most common irAEs caused by anti-PD-1 treatment. It was reported that hypothyroidism frequently occurs in patients treated with anti-PD-1 drugs. In addition, hypophysitis was commonly found in patients treated with CTLA4 inhibitors[6,9]. This difference may be supported by the fact that there is no ectopic PD-1 expression in normal hypophysis tissue[10,11]. In the present study, only one case presented with hypothyroidism. IRH is a pituitary disorder with one or multiple anterior pituitary hormone deficiencies (mostly ACTH and/or TSH)[12]. In our study, three cases all displayed isolated ACTH insufficiency after anti-PD-1 treatment, which was consistent with a previous study[13]. It is worth mentioning that combination therapy with PD-1 and CTLA4 inhibitors increased the occurrence of hypophysitis, which ranged from 8.8% to 10.5%[14,15]. The frequency of hypophysitis occurrence may be under-estimated in oncological trials that did not systematically screen for this adverse event that has a non-specific clinical presentation[16].

The general symptoms associated with IRH are fatigue, decreased appetite, nausea, and vomiting. These common symptoms were also present in cases 1 and 2 in the present report. However, the symptoms including hoarse voice, bucking, and difficulty in breathing even when sitting in case 3 are rare, and this is the first case showing such specific symptoms in our clinical experience. This may provide oncologists with a new understanding of the symptoms caused by IRH. The adverse event of immune-mediated hypophysitis commonly occurs within 8-12 cycles after the initiation of anti-PD-1 therapy[17]. In the present study, it occurred after eight cycles of immunotherapy in case 1 and after four cycles in case 2. Whereas, case 3 developed hypophysitis after two cycles of immunotherapy. This may be related to the insufficient sample size and heterogeneity between patients. Heterogeneity is derived from the patient's constitution, treatment profile, psychological pressure, and so on.

MRI is an imaging technique used in the diagnosis of pituitary inflammation. Pituitary enlargement is usually found in patients diagnosed with hypophysitis. However, due to a lack of experience among clinicians, brain or pituitary MRI is not performed at baseline before immunotherapy. Pituitary MRI is generally performed following the development of hypophysitis. Therefore, clinicians are not able to fully assess hypophysitis. It was found that 25% of patients showed a normal pituitary MRI during the acute phase of pituitary inflammation[18-20]; therefore, hypophysitis is easily misdiagnosed if the clinician lacks experience. In this study, the pituitary gland was enlarged in case 3 when hypophysitis developed, but was still considered to be in the normal range. Although pituitary enlargement is not found in most patients at the onset of hypophysitis, pituitary MRI is necessary at baseline before immunotherapy. In addition, the clinician should inform the radiologist of the patient's medical history in order to make the correct diagnosis.

In terms of treatment for IRH, hormone replacement is commonly administered by clinicians. After treatment, thyroid function can return to normal, but dysfunction of the pituitary-gonadal axis and pituitary-corticotrophic axis may still persist[21,22]. Our study also confirmed this situation. Thyroid function in case 1 recovered soon after almost 1 mo of steroid treatment, but function of the pituitary-corticotrophic axis in cases 1 and 2 was still abnormal after up to 7 mo of steroid treatment. However, the pituitary-corticotrophic axis in case 3 returned to normal after more than 6 mo of steroid treatment. The reason for this difference may be related to the dose of hormone administered, as case 3 was treated with high-dose hormone therapy while cases 1 and 2 were treated with the low-dose hormone therapy. Our study provides a reference for the treatment of IRH. A previous study reported that the overall survival of patients with IRH was not improved by steroid therapy[23]. We speculate that the poor prognosis may be related to the dose of steroid therapy.

Besides the focus on the side effects caused by PD-1 inhibitors, the expression rate of PD-1 and PD-L1 is also important. It has been reported that the expression rate was correlated with the disease types and subtypes[24]. In addition, the inflammatory cytokines can affect the PD-1 or PD-L1 expression. Ribas and Hu-Lieskovan[25] reported that inflammatory cytokines induced the PD-L1 expression, and particularly, the involvement of interferon- γ in immune checkpoint induction has been reported[26]. At present, no research reported the involvement of inflammatory cytokines in related hypophysitis caused by PD-1 expression. The investigation of inflammatory cytokines might be conducive to monitoring the hypophysitis caused by PD-1 inhibitor treatment.

CONCLUSION

This study describes three patients receiving anti-PD-1 treatment for NSCLC who ultimately developed hypophysitis, simultaneously leading to hypothyroidism and/or isolated ACTH deficiency. PD-1 inhibitor induced-hypophysitis presented with less obvious clinical and radiological signs, and the lack of a clinical presentation can lead to delayed diagnosis. It is necessary to perform a systematic and regular hormonal evaluation in patients treated with ICIs. When unexpected fatigue, decreased appetite, nausea, vomiting, hoarse voice, bucking, and difficulty in breathing develop, IRH should be considered.

FOOTNOTES

Author contributions: Zheng Y and Zhu CY designed the study, drafted the manuscript, and reviewed the manuscript; Zheng Y, Zhu CY, and Lin J performed the literature review; Lin J was involved in supervision and manuscript review and editing; Chen WS contributed to the data curation and investigation; Wang YJ and Fu HY conducted the study and suggested pertinent modification; Zhao Q supervised the study process and reviewed the manuscript; and all authors have read and approved the final manuscript.

Informed consent statement: Informed written consent was obtained from the patients for publication of this report and any accompanying images.

Conflict-of-interest statement: All the authors report no relevant conflicts of interest for this article.

CARE Checklist (2016) statement: The authors have read the CARE Checklist (2016), and the manuscript was prepared and revised according to the CARE Checklist (2016).

Open-Access: This article is an open-access article that was selected by an in-house editor and fully peer-reviewed by external reviewers. It is distributed in accordance with the Creative Commons Attribution NonCommercial (CC BY-NC 4.0) license, which permits others to distribute, remix, adapt, build upon this work non-commercially, and license their derivative works on different terms, provided the original work is properly cited and the use is non-commercial. See: <https://creativecommons.org/licenses/by-nc/4.0/>

Country/Territory of origin: China

ORCID number: Yun Zheng 0000-0003-0837-3656; Qiong Zhao 0000-0001-7523-4432.

S-Editor: Wang JJ

L-Editor: Wang TQ

P-Editor: Wang JJ

REFERENCES

- 1 Yshii LM, Hohlfeld R, Liblau RS. Inflammatory CNS disease caused by immune checkpoint inhibitors: status and perspectives. *Nat Rev Neurol* 2017; **13**: 755-763 [PMID: 29104289 DOI: 10.1038/nrneuro.2017.144]
- 2 Gedye C, van der Westhuizen A, John T. Checkpoint immunotherapy for cancer: superior survival, unaccustomed toxicities. *Intern Med J* 2015; **45**: 696-701 [PMID: 25444021 DOI: 10.1111/imj.12653]
- 3 Boutros C, Tarhini A, Routier E, Lambotte O, Ladurie FL, Carbonnel F, Izzeddine H, Marabelle A, Champiat S, Berdelou A, Lanoy E, Texier M, Libenciuc C, Eggermont AM, Soria JC, Mateus C, Robert C. Safety profiles of anti-CTLA-4 and anti-PD-1 antibodies alone and in combination. *Nat Rev Clin Oncol* 2016; **13**: 473-486 [PMID: 27141885 DOI: 10.1038/nrclinonc.2016.58]
- 4 Barroso-Sousa R, Barry WT, Garrido-Castro AC, Hodi FS, Min L, Krop IE, Tolane SM. Incidence of Endocrine Dysfunction Following the Use of Different Immune Checkpoint Inhibitor Regimens: A Systematic Review and Meta-analysis. *JAMA Oncol* 2018; **4**: 173-182 [PMID: 28973656 DOI: 10.1001/jamaoncol.2017.3064]
- 5 Solinas C, Porcu M, De Silva P, Musi M, Aspeslagh S, Scartozzi M, Willard-Gallo K, Mariotti S, Saba L. Cancer immunotherapy-associated hypophysitis. *Semin Oncol* 2018; **45**: 181-186 [PMID: 30352754 DOI: 10.1053/j.seminoncol.2018.09.002]
- 6 de Filette J, Andreescu CE, Cools F, Bravenboer B, Velkeniers B. A Systematic Review and Meta-Analysis of Endocrine-Related Adverse Events Associated with Immune Checkpoint Inhibitors. *Horm Metab Res* 2019; **51**: 145-156 [PMID: 30861560 DOI: 10.1055/a-0843-3366]
- 7 Levy M, Abeillon J, Dalle S, Assaad S, Borson-Chazot F, Disse E, Raverot G, Cugnet-Anceau C. Anti-PD1 and Anti-PDL1-Induced Hypophysitis: A Cohort Study of 17 Patients with Longitudinal Follow-Up. *J Clin Med* 2020; **9** [PMID: 33066179 DOI: 10.3390/jcm9103280]
- 8 Mekki A, Dercle L, Lichtenstein P, Marabelle A, Michot JM, Lambotte O, Le Pavec J, De Martin E, Balleyguier C, Champiat S, Ammari S. Detection of immune-related adverse events by medical imaging in patients treated with anti-programmed cell death 1. *Eur J Cancer* 2018; **96**: 91-104 [PMID: 29698933 DOI: 10.1016/j.ejca.2018.03.006]
- 9 Seejore K, Giannoudi M, Osborn D, Lynch JM, Al-Qaissi A, Dunwoodie E, Hook J, Marples M, Murray RD. Characterisation of the onset and severity of adrenal and thyroid dysfunction associated with CTLA4-related hypophysitis. *Eur J Endocrinol* 2021; **186**: 83-93 [PMID: 34735371 DOI: 10.1530/EJE-21-0760]
- 10 Byun DJ, Wolchok JD, Rosenberg LM, Girotra M. Cancer immunotherapy - immune checkpoint blockade and associated endocrinopathies. *Nat Rev Endocrinol* 2017; **13**: 195-207 [PMID: 28106152 DOI: 10.1038/nrendo.2016.205]
- 11 González-Rodríguez E, Rodríguez-Abreu D, Spanish Group for Cancer Immuno-Biotherapy (GETICA). Immune Checkpoint Inhibitors: Review and Management of Endocrine Adverse Events. *Oncologist* 2016; **21**: 804-816 [PMID: 27306911 DOI: 10.1634/theoncologist.2015-0509]
- 12 Dillard T, Yedinak CG, Alumkal J, Flaseriu M. Anti-CTLA-4 antibody therapy associated autoimmune hypophysitis: serious immune related adverse events across a spectrum of cancer subtypes. *Pituitary* 2010; **13**: 29-38 [PMID: 19639414 DOI: 10.1007/s11102-009-0193-z]
- 13 Kitajima K, Ashida K, Wada N, Suetsugu R, Takeichi Y, Sakamoto S, Uchi H, Matsushima T, Shiratsuchi M, Ohnaka K, Furue M, Nomura M. Isolated ACTH deficiency probably induced by autoimmune-related mechanism evoked with nivolumab. *Jpn J Clin Oncol* 2017; **47**: 463-466 [PMID: 28334791 DOI: 10.1093/jjco/hyx018]
- 14 Kassi E, Angelousi A, Asonitis N, Diamantopoulos P, Anastasopoulou A, Papaxoinis G, Kokkinos M, Giovanopoulos I, Kyriakakis G, Petychaki F, Savelli A, Benopoulou O, Gogas H. Endocrine-related adverse events associated with immune-checkpoint inhibitors in patients with melanoma. *Cancer Med* 2019; **8**: 6585-6594 [PMID: 31518074 DOI: 10.1002/cam4.2533]
- 15 Spain L, Walls G, Julve M, O'Meara K, Schmid T, Kalaitzaki E, Turajlic S, Gore M, Rees J, Larkin J. Neurotoxicity from immune-checkpoint inhibition in the treatment of melanoma: a single centre experience and review of the literature. *Ann Oncol* 2017; **28**: 377-385 [PMID: 28426103 DOI: 10.1093/annonc/mdw558]
- 16 Faje A, Reynolds K, Zubiri L, Lawrence D, Cohen JV, Sullivan RJ, Nachtigall L, Tritos N. Hypophysitis secondary to nivolumab and pembrolizumab is a clinical entity distinct from ipilimumab-associated hypophysitis. *Eur J Endocrinol* 2019; **181**: 211-219 [PMID: 31176301 DOI: 10.1530/EJE-19-0238]
- 17 Ji HH, Tang XW, Dong Z, Song L, Jia YT. Adverse Event Profiles of Anti-CTLA-4 and Anti-PD-1 Monoclonal Antibodies Alone or in Combination: Analysis of Spontaneous Reports Submitted to FAERS. *Clin Drug Investig* 2019; **39**: 319-330 [PMID: 30674039 DOI: 10.1007/s40261-018-0735-0]
- 18 Sekizaki T, Kameda H, Oba C, Yong Cho K, Nakamura A, Miyoshi H, Osawa T, Shinohara N, Atsumi T. Nivolumab-induced hypophysitis causing secondary adrenal insufficiency after transient ACTH elevation. *Endocr J* 2019; **66**: 937-941 [PMID: 31217401 DOI: 10.1507/endocrj.EJ19-0076]
- 19 Mishima Y, Fukaishi T, Inase N, Isogai S. Nivolumab-induced Hypophysitis, Secondary Adrenal Insufficiency and Destructive Thyroiditis in a Patient with Lung Adenocarcinoma. *Intern Med* 2019; **58**: 693-697 [PMID: 30449786 DOI: 10.2169/internalmedicine.1268-18]
- 20 Thapi S, Leiter A, Galsky M, Gallagher EJ. Recovery from secondary adrenal insufficiency in a patient with immune checkpoint inhibitor therapy induced hypophysitis. *J Immunother Cancer* 2019; **7**: 248 [PMID: 31511065 DOI: 10.1136/jit-2019-000248]

- 10.1186/s40425-019-0729-3]
- 21 **Ntali G**, Kassi E, Alevizaki M. Endocrine sequelae of immune checkpoint inhibitors. *Hormones (Athens)* 2017; **16**: 341-350 [PMID: [29518754](#) DOI: [10.14310/horm.2002.1754](#)]
- 22 **Weber JS**, Yang JC, Atkins MB, Disis ML. Toxicities of Immunotherapy for the Practitioner. *J Clin Oncol* 2015; **33**: 2092-2099 [PMID: [25918278](#) DOI: [10.1200/JCO.2014.60.0379](#)]
- 23 **Min L**, Hodi FS, Giobbie-Hurder A, Ott PA, Luke JJ, Donahue H, Davis M, Carroll RS, Kaiser UB. Systemic high-dose corticosteroid treatment does not improve the outcome of ipilimumab-related hypophysitis: a retrospective cohort study. *Clin Cancer Res* 2015; **21**: 749-755 [PMID: [25538262](#) DOI: [10.1158/1078-0432.CCR-14-2353](#)]
- 24 **Hashimoto K**, Nishimura S, Ito T, Akagi M. Characterization of PD-1/PD-L1 immune checkpoint expression in soft tissue sarcomas. *Eur J Histochem* 2021; **65** [PMID: [34218652](#) DOI: [10.4081/ejh.2021.3203](#)]
- 25 **Ribas A**, Hu-Lieskovan S. What does PD-L1 positive or negative mean? *J Exp Med* 2016; **213**: 2835-2840 [PMID: [27903604](#) DOI: [10.1084/jem.20161462](#)]
- 26 **Liang SC**, Latchman YE, Buhlmann JE, Tomczak MF, Horwitz BH, Freeman GJ, Sharpe AH. Regulation of PD-1, PD-L1, and PD-L2 expression during normal and autoimmune responses. *Eur J Immunol* 2003; **33**: 2706-2716 [PMID: [14515254](#) DOI: [10.1002/eji.200324228](#)]



Published by **Baishideng Publishing Group Inc**
7041 Koll Center Parkway, Suite 160, Pleasanton, CA 94566, USA

Telephone: +1-925-3991568

E-mail: bpgoffice@wjgnet.com

Help Desk: <https://www.f6publishing.com/helpdesk>

<https://www.wjgnet.com>

