

World Journal of *Clinical Cases*

World J Clin Cases 2022 October 26; 10(30): 10823-11213



Contents

Thrice Monthly Volume 10 Number 30 October 26, 2022

REVIEW

- 10823** New insights into the interplay between intestinal flora and bile acids in inflammatory bowel disease
Zheng L
- 10840** Role of visfatin in obesity-induced insulin resistance
Abdalla MMI

MINIREVIEWS

- 10852** Hyperthermic intraperitoneal chemotherapy and colorectal cancer: From physiology to surgery
Ammerata G, Filippo R, Laface C, Memeo R, Solaini L, Cavaliere D, Navarra G, Ranieri G, Currò G, Ammendola M
- 10862** New-onset diabetes secondary to acute pancreatitis: An update
Yu XQ, Zhu Q
- 10867** Ketosis-prone diabetes mellitus: A phenotype that hospitalists need to understand
Boike S, Mir M, Rauf I, Jama AB, Sunesara S, Mushtaq H, Khedr A, Nitesh J, Surani S, Khan SA
- 10873** 2022 Monkeypox outbreak: Why is it a public health emergency of international concern? What can we do to control it?
Ren SY, Li J, Gao RD

ORIGINAL ARTICLE

Retrospective Cohort Study

- 10882** Clinical characteristics and prognosis of non-small cell lung cancer patients with liver metastasis: A population-based study
Wang JF, Lu HD, Wang Y, Zhang R, Li X, Wang S

Retrospective Study

- 10896** Prevalence and risk factors for *Candida* esophagitis among human immunodeficiency virus-negative individuals
Chen YH, Jao TM, Shiue YL, Feng IJ, Hsu PI
- 10906** Prognostic impact of number of examined lymph nodes on survival of patients with appendiceal neuroendocrine tumors
Du R, Xiao JW

Observational Study

- 10921** Clinical and epidemiological features of ulcerative colitis patients in Sardinia, Italy: Results from a multicenter study
Magri S, Demurtas M, Onidi MF, Picchio M, Elisei W, Marzo M, Miculan F, Manca R, Dore MP, Quarta Colosso BM, Cicu A, Cugia L, Carta M, Binaghi L, Usai P, Lai M, Chicco F, Fantini MC, Armuzzi A, Mocci G

- 10931** Clinical observation of laparoscopic cholecystectomy combined with endoscopic retrograde cholangiopancreatography or common bile duct lithotripsy

Niu H, Liu F, Tian YB

Prospective Study

- 10939** Patient reported outcome measures in anterior cruciate ligament rupture and reconstruction: The significance of outcome score prediction

Al-Dadah O, Shepstone L, Donell ST

SYSTEMATIC REVIEWS

- 10956** Body mass index and outcomes of patients with cardiogenic shock: A systematic review and meta-analysis

Tao WX, Qian GY, Li HD, Su F, Wang Z

META-ANALYSIS

- 10967** Impact of being underweight on peri-operative and post-operative outcomes of total knee or hip arthroplasty: A meta-analysis

Ma YP, Shen Q

- 10984** Branched-chain amino acids supplementation has beneficial effects on the progression of liver cirrhosis: A meta-analysis

Du JY, Shu L, Zhou YT, Zhang L

CASE REPORT

- 10997** Wells' syndrome possibly caused by hematologic malignancy, influenza vaccination or ibrutinib: A case report

Šajin M, Luzar B, Zver S

- 11004** Giant cutaneous squamous cell carcinoma of the popliteal fossa skin: A case report

Wang K, Li Z, Chao SW, Wu XW

- 11010** Right time to detect urine iodine during papillary thyroid carcinoma diagnosis and treatment: A case report

Zhang SC, Yan CJ, Li YF, Cui T, Shen MP, Zhang JX

- 11016** Two novel mutations in the *VPS33B* gene in a Chinese patient with arthrogryposis, renal dysfunction and cholestasis syndrome 1: A case report

Yang H, Lin SZ, Guan SH, Wang WQ, Li JY, Yang GD, Zhang SL

- 11023** Effect of electroacupuncture for Pisa syndrome in Parkinson's disease: A case report

Lu WJ, Fan JQ, Yan MY, Mukaeda K, Zhuang LX, Wang LL

- 11031** Neonatal Cri du chat syndrome with atypical facial appearance: A case report

Bai MM, Li W, Meng L, Sang YF, Cui YJ, Feng HY, Zong ZT, Zhang HB

- 11037** Complete colonic duplication presenting as hip fistula in an adult with pelvic malformation: A case report

Cai X, Bi JT, Zheng ZX, Liu YQ

- 11044** Autoimmune encephalitis with posterior reversible encephalopathy syndrome: A case report
Dai SJ, Yu QJ, Zhu XY, Shang QZ, Qu JB, Ai QL
- 11049** Hypophysitis induced by anti-programmed cell death protein 1 immunotherapy in non-small cell lung cancer: Three case reports
Zheng Y, Zhu CY, Lin J, Chen WS, Wang YJ, Fu HY, Zhao Q
- 11059** Different intraoperative decisions for undiagnosed paraganglioma: Two case reports
Kang D, Kim BE, Hong M, Kim J, Jeong S, Lee S
- 11066** Hepatic steatosis with mass effect: A case report
Hu N, Su SJ, Li JY, Zhao H, Liu SF, Wang LS, Gong RZ, Li CT
- 11074** Bone marrow metastatic neuroendocrine carcinoma with unknown primary site: A case report and review of the literature
Shi XB, Deng WX, Jin FX
- 11082** Child with adenylosuccinate lyase deficiency caused by a novel complex heterozygous mutation in the ADSL gene: A case report
Wang XC, Wang T, Liu RH, Jiang Y, Chen DD, Wang XY, Kong QX
- 11090** Recovery of brachial plexus injury after bronchopleural fistula closure surgery based on electrodiagnostic study: A case report and review of literature
Go YI, Kim DS, Kim GW, Won YH, Park SH, Ko MH, Seo JH
- 11101** Severe *Klebsiella pneumoniae* pneumonia complicated by acute intra-abdominal multiple arterial thrombosis and bacterial embolism: A case report
Bao XL, Tang N, Wang YZ
- 11111** Spontaneous bilateral femur neck fracture secondary to grand mal seizure: A case report
Senocak E
- 11116** Favorable response after radiation therapy for intraductal papillary mucinous neoplasms manifesting as acute recurrent pancreatitis: A case report
Harigai A, Kume K, Takahashi N, Omata S, Umezawa R, Jingu K, Masamune A
- 11122** Acute respiratory distress syndrome following multiple wasp stings treated with extracorporeal membrane oxygenation: A case report
Cai ZY, Xu BP, Zhang WH, Peng HW, Xu Q, Yu HB, Chu QG, Zhou SS
- 11128** Morphological and electrophysiological changes of retina after different light damage in three patients: Three case reports
Zhang X, Luo T, Mou YR, Jiang W, Wu Y, Liu H, Ren YM, Long P, Han F
- 11139** Perirectal epidermoid cyst in a patient with sacroccygeal scoliosis and anal sinus: A case report
Ji ZX, Yan S, Gao XC, Lin LF, Li Q, Yao Q, Wang D

- 11146** Synchronous gastric cancer complicated with chronic myeloid leukemia (multiple primary cancers): A case report
Zhao YX, Yang Z, Ma LB, Dang JY, Wang HY
- 11155** Giant struma ovarii with pseudo-Meigs' syndrome and raised cancer antigen-125 levels: A case report
Liu Y, Tang GY, Liu L, Sun HM, Zhu HY
- 11162** Longest survival with primary intracranial malignant melanoma: A case report and literature review
Wong TF, Chen YS, Zhang XH, Hu WM, Zhang XS, Lv YC, Huang DC, Deng ML, Chen ZP
- 11172** Spontaneous remission of hepatic myelopathy in a patient with alcoholic cirrhosis: A case report
Chang CY, Liu C, Duan FF, Zhai H, Song SS, Yang S
- 11178** Cauda equina syndrome caused by the application of DuraSeal™ in a microlaminectomy surgery: A case report
Yeh KL, Wu SH, Fuh CS, Huang YH, Chen CS, Wu SS
- 11185** Bioceramics utilization for the repair of internal resorption of the root: A case report
Riyahi AM
- 11190** Fibrous hamartoma of infancy with bone destruction of the tibia: A case report
Qiao YJ, Yang WB, Chang YF, Zhang HQ, Yu XY, Zhou SH, Yang YY, Zhang LD
- 11198** Accidental esophageal intubation *via* a large type C congenital tracheoesophageal fistula: A case report
Hwang SM, Kim MJ, Kim S, Kim S
- 11204** Ventral hernia after high-intensity focused ultrasound ablation for uterine fibroids treatment: A case report
Park JW, Choi HY

LETTER TO THE EDITOR

- 11210** C-Reactive protein role in assessing COVID-19 deceased geriatrics and survivors of severe and critical illness
Nori W

ABOUT COVER

Editorial Board Member of *World Journal of Clinical Cases*, Rajeev Gurunath Redkar, FRCS, FRCS (Ed), FRCS (Gen Surg), MBBS, MCh, MS, Dean, Professor, Surgeon, Department of Pediatric Surgery, Lilavati Hospital and Research Centre, Mumbai 400050, Maharashtra, India. rajeev.redkar@gmail.com

AIMS AND SCOPE

The primary aim of *World Journal of Clinical Cases* (WJCC, *World J Clin Cases*) is to provide scholars and readers from various fields of clinical medicine with a platform to publish high-quality clinical research articles and communicate their research findings online.

WJCC mainly publishes articles reporting research results and findings obtained in the field of clinical medicine and covering a wide range of topics, including case control studies, retrospective cohort studies, retrospective studies, clinical trials studies, observational studies, prospective studies, randomized controlled trials, randomized clinical trials, systematic reviews, meta-analysis, and case reports.

INDEXING/ABSTRACTING

The WJCC is now abstracted and indexed in Science Citation Index Expanded (SCIE, also known as SciSearch®), Journal Citation Reports/Science Edition, Current Contents®/Clinical Medicine, PubMed, PubMed Central, Scopus, Reference Citation Analysis, China National Knowledge Infrastructure, China Science and Technology Journal Database, and Superstar Journals Database. The 2022 Edition of Journal Citation Reports® cites the 2021 impact factor (IF) for WJCC as 1.534; IF without journal self cites: 1.491; 5-year IF: 1.599; Journal Citation Indicator: 0.28; Ranking: 135 among 172 journals in medicine, general and internal; and Quartile category: Q4. The WJCC's CiteScore for 2021 is 1.2 and Scopus CiteScore rank 2021: General Medicine is 443/826.

RESPONSIBLE EDITORS FOR THIS ISSUE

Production Editor: *Ying-Yi Yuan*; Production Department Director: *Xu Guo*; Editorial Office Director: *Jin-Lei Wang*.

NAME OF JOURNAL

World Journal of Clinical Cases

ISSN

ISSN 2307-8960 (online)

LAUNCH DATE

April 16, 2013

FREQUENCY

Thrice Monthly

EDITORS-IN-CHIEF

Bao-Gan Peng, Jerzy Tadeusz Chudek, George Kontogeorgos, Maurizio Serati, Ja Hyeon Ku

EDITORIAL BOARD MEMBERS

<https://www.wjgnet.com/2307-8960/editorialboard.htm>

PUBLICATION DATE

October 26, 2022

COPYRIGHT

© 2022 Baishideng Publishing Group Inc

INSTRUCTIONS TO AUTHORS

<https://www.wjgnet.com/bpg/gerinfo/204>

GUIDELINES FOR ETHICS DOCUMENTS

<https://www.wjgnet.com/bpg/GerInfo/287>

GUIDELINES FOR NON-NATIVE SPEAKERS OF ENGLISH

<https://www.wjgnet.com/bpg/gerinfo/240>

PUBLICATION ETHICS

<https://www.wjgnet.com/bpg/GerInfo/288>

PUBLICATION MISCONDUCT

<https://www.wjgnet.com/bpg/gerinfo/208>

ARTICLE PROCESSING CHARGE

<https://www.wjgnet.com/bpg/gerinfo/242>

STEPS FOR SUBMITTING MANUSCRIPTS

<https://www.wjgnet.com/bpg/GerInfo/239>

ONLINE SUBMISSION

<https://www.f6publishing.com>



Different intraoperative decisions for undiagnosed paraganglioma: Two case reports

Dongho Kang, Bo-eun Kim, Minjae Hong, Joungmin Kim, Seongtae Jeong, Seongheon Lee

Specialty type: Surgery

Provenance and peer review:

Unsolicited article; Externally peer reviewed.

Peer-review model: Single blind

Peer-review report's scientific quality classification

Grade A (Excellent): 0

Grade B (Very good): B

Grade C (Good): C

Grade D (Fair): 0

Grade E (Poor): 0

P-Reviewer: Maurea S, Italy;
Moshref RH, Saudi Arabia

Received: June 24, 2022

Peer-review started: June 24, 2022

First decision: August 7, 2022

Revised: August 20, 2022

Accepted: September 12, 2022

Article in press: September 12, 2022

Published online: October 26, 2022



Dongho Kang, Bo-eun Kim, Minjae Hong, Joungmin Kim, Seongtae Jeong, Seongheon Lee,
Department of Anesthesiology and Pain Medicine, Chonnam National University Medical
School, Chonnam National University Hospital, Gwangju 61469, South Korea

Corresponding author: Seongheon Lee, MD, PhD, Assistant Professor, Department of
Anesthesiology and Pain Medicine, Chonnam National University Medical School, Chonnam
National University Hospital, 160 Baekseo-ro, Dong-gu, Gwangju 61469, South Korea.
aneshead@gmail.com

Abstract

BACKGROUND

Paragangliomas may be preoperatively misdiagnosed as non-functioning retroperitoneal tumors and are sometimes suspected only at the time of intraoperative manipulation. Without preoperative alpha blockade preparation, a hypertensive crisis during tumor manipulation and hypotension after tumor removal may result in critical consequences. Therefore, primary consideration should be given to the continuation or discontinuation of surgery on the basis of the possibility of gentle surgical manipulation and hemodynamic stabilization. We report two cases of paragangliomas detected intraoperatively.

CASE SUMMARY

A 65-year-old woman underwent laparoscopic small-bowel wedge resection. A hypertensive crisis occurred during manipulation of the mass, and an unrecognized catecholamine-producing paraganglioma was suspected. The surgeon and anesthesiologists believed that tumor excision could be performed with minimal manipulation of the tumor because the tumor was in a favorable location. Serious hemodynamic instability did not occur with aggressive use of vasoactive drugs. A week later, a 54-year-old man underwent open resection of a 3-cm-sized retroperitoneal mass and showed the same findings during mass manipulation. For this patient, continuous manipulation of the mass seemed inevitable due to adhesion between the right adrenal gland and the mass in a narrow surgical field. The surgeon and anesthesiologists decided to cancel the surgical procedure and planned to perform a reoperation after alpha blockade therapy. Two weeks later, the tumor was uneventfully removed with small doses of vasoactive drugs.

CONCLUSION

When an undiagnosed paraganglioma is suspected intraoperatively, reoperation after adequate preparation should be considered as an option to avoid fatal

outcomes.

Key Words: Paraganglioma; Undiagnosed diseases; Hypertensive crisis; Preoperative alpha blockade; Surgery cancellation; Neuroendocrine tumors; Case report

©The Author(s) 2022. Published by Baishideng Publishing Group Inc. All rights reserved.

Core Tip: Undiagnosed paragangliomas may be suspected at the time of intraoperative manipulation. Tumor removal without preoperative alpha blockade preparation can lead to serious hemodynamic instability. The present case report describes different intraoperative decisions for two patients with undiagnosed paragangliomas. Intraoperative cancellation of surgery may not always be feasible or practical, but it should be considered as an option in cases requiring frequent manipulation of the tumor.

Citation: Kang D, Kim BE, Hong M, Kim J, Jeong S, Lee S. Different intraoperative decisions for undiagnosed paraganglioma: Two case reports. *World J Clin Cases* 2022; 10(30): 11059-11065

URL: <https://www.wjgnet.com/2307-8960/full/v10/i30/11059.htm>

DOI: <https://dx.doi.org/10.12998/wjcc.v10.i30.11059>

INTRODUCTION

Paragangliomas are rare neuroendocrine tumors derived from extra-adrenal chromaffin cells, which are catecholamine-producing postganglionic sympathetic neurons[1-3]. Similar to pheochromocytomas, these tumors can show life-threatening complications such as hypertensive crisis and hemodynamic instability during surgery. To reduce these complications, preoperative preparation with an adrenal blockade is essential. However, paragangliomas may be preoperatively misdiagnosed as non-functioning retroperitoneal tumors since patients have no specific preoperative symptoms, such as palpitation. In these patients, paragangliomas may be suspected at the time of intraoperative manipulation.

Previous reports of undiagnosed catecholamine-producing tumors have described successful operations with careful surgical resection and intensive anesthetic management[4-6]. However, most cases involved a hypertensive crisis, which was followed by severe postoperative hypotension. The patients may even show intraoperative acute catecholamine cardiomyopathy and sudden cardiac arrest [7]. Adequate preparation may prevent these lethal situations. Therefore, when a catecholamine-producing paraganglioma is suspected during surgery, primary consideration should be given to the continuation or discontinuation of surgery. Surgeons and anesthesiologists should discuss the possibility of gentle surgical manipulation, intraoperative hemodynamic stabilization, and postoperative complications.

We report two cases of intraoperatively detected paragangliomas.

CASE PRESENTATION

Chief complaints

Case 1: A 65-year-old woman was admitted for laparoscopic small-bowel wedge resection of a 6-cm-sized mass suspected to be a small-bowel gastrointestinal stromal tumor (GIST). During laparoscopic manipulation of the mass, systolic blood pressure suddenly increased to 250-280 mmHg.

Case 2: A 54-year-old man was admitted for open resection of a 3-cm-sized retroperitoneal mass suspected to be leiomyosarcoma. During careful dissection of the mass superior to the right adrenal gland, systolic blood pressure and pulse rate increased to 200-230 mmHg and 130-150 bpm, respectively.

History of present illness

Case 1: The patient's blood pressure was 178/85 mmHg, and her heart rate was 65 bpm on arrival to the operating room. General anesthesia was induced and maintained with propofol and remifentanyl. The mass became visible 20 min after the start of laparoscopic surgery. When the surgeon manipulated the mass, systolic blood pressure increased to 250-300 mmHg. Repeated doses of nicardipine (1-mg doses with a total dose of 3 mg) were administered, and the systolic blood pressure decreased to 120 mmHg. Within 5 min, the blood pressure increased again, and the patient showed tachycardia (110-130 bpm). Nicardipine and esmolol were then administered repeatedly, and the anesthetic depth was increased by

increasing the doses of propofol and remifentanyl. However, adequate control of blood pressure could not be achieved.

Case 2: The patient's blood pressure and heart rate on arrival to the operating room were 136/82 mmHg and 79 bpm, respectively. General anesthesia was maintained with desflurane and remifentanyl after anesthesia induction with propofol. The mass became visible 35 min after the start of the operation. When the surgeon manipulated the mass, the systolic blood pressure suddenly increased to 185 mmHg. After administration of nicardipine (0.5 mg), the blood pressure normalized. Anesthetic depth was also increased by increasing the doses of desflurane and remifentanyl. However, systolic blood pressure and pulse rate increased to 200-230 mmHg and 130-150 bpm, respectively, during careful dissection of the mass superior to the right adrenal gland. The blood pressure and heart rate were not adequately controlled by administering multiple doses of nicardipine and esmolol.

History of past illness

Case 1: The patient had been receiving an angiotensin-2 receptor blocker and thiazide for the treatment of hypertension from 2016. Her blood pressure was well controlled until the morning of the surgery. She had been in a euthyroid state with levothyroxine medication after undergoing total thyroidectomy in 2006.

Case 2: The patient was receiving clopidogrel owing to a history of deep vein thrombosis. Clopidogrel was withheld for 5 d before surgery. The patient had no history of hypertension.

Personal and family history

None of the two patients had any relevant personal or family history.

Physical examination

Cases 1 and 2: The results of preoperative physical examination were unremarkable. During general anesthesia, the depth of anesthesia and arterial blood pressure were continuously monitored. No prominent elevation of blood pressure or heart rate was observed during tracheal intubation, skin incision, or laparoscopic port insertion. Deep neuromuscular blockade was maintained with continuous infusion of rocuronium under neuromuscular monitoring.

Laboratory examinations

The results of preoperative laboratory tests and electrocardiography were normal.

Imaging examinations

Case 1: Abdominal computed tomography (CT) showed an approximately 6-cm-sized well-circumscribed heterogeneously enhancing mass around the duodenal flexure (**Figure 1A**). The initial radiographic impression was a GIST.

Case 2: Abdominal CT showed an approximately 3-cm-sized heterogeneously enhancing mass in the retrocaval space (**Figure 1B**). The mass pushed the inferior vena cava forward and abutted the liver in the lateral portion. The initial radiographic impression was a leiomyosarcoma with possible invasion of the liver.

FINAL DIAGNOSIS

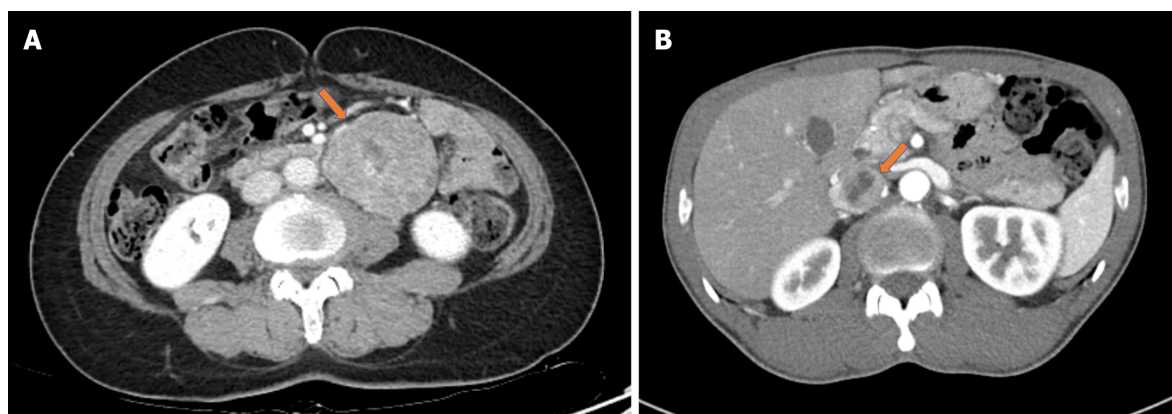
An unrecognized catecholamine-producing paraganglioma was highly suspected based on the high blood pressure and heart rate induced by intraoperative manipulation of the mass.

TREATMENT

The surgeon was asked to stop the manipulation of the tumor to prevent further hypertensive crises. Surgical procedures involving undiagnosed paragangliomas without adequate preoperative preparation may lead to increased morbidity and mortality. Therefore, the surgeon and anesthesiologists discussed whether to proceed with the surgical procedure or cancel it.

Case 1

The surgeon thought that tumor excision could be performed with minimal manipulation of the tumor because the tumor seemed to have a relatively clear margin without invasion to the surrounding tissue. The anesthesiologists then agreed to resume the surgical procedure and prepare cardiovascular drugs for intensive hemodynamic control. For quick and safe excision, the laparoscopic procedure was



DOI: 10.12998/wjcc.v10.i30.11059 Copyright ©The Author(s) 2022.

Figure 1 Abdominal computed tomography. A: Abdominal computed tomography (CT) showing a 6-cm-sized well-circumscribed heterogeneously enhancing mass around duodenojejunal flexure; B: Abdominal CT showing an approximately 3-cm-sized retroperitoneal mass in the retrocaval space with anterior displacement of the inferior vena cava.

converted to open surgery in accordance with the surgeon's decision.

During tumor excision, esmolol and nicardipine were continuously infused with intermittent bolus injections to minimize severe hypertension and tachycardia. The mass was completely removed 70 min after the start of surgery. Following mass removal, systolic blood pressure decreased to 75 mmHg. Aggressive fluid resuscitation was performed with continuous administration of dopamine and norepinephrine until the patient was hemodynamically stable.

Case 2

Continuous manipulation of the mass seemed inevitable due to adhesion between the right adrenal gland and the mass in a narrow surgical field. The possibility of the inferior vena cava invasion and massive bleeding also could not be ruled out. The surgeon and anesthesiologists decided to cancel the surgical procedure and planned to perform a reoperation after adequate preparation a few weeks later.

An endocrinologist in the general ward evaluated the patient. The results of 24-h urinary metanephrine and catecholamine (metanephrine 2700 µg/d, norepinephrine 133.8 µg/d, and epinephrine 79.2 µg/d) strongly suggested the presence of a catecholamine-producing paraganglioma. We decided to proceed with reoperation after an alpha-1 adrenergic receptor antagonist (doxazosin mesylate) regimen for two weeks.

OUTCOME AND FOLLOW-UP

Case 1

The patient was transferred to the intensive care unit (ICU) after surgery for close monitoring of vital signs. All vasopressors were stopped 7 h after ICU admission. She was transferred to the general ward on postoperative day (POD) 2 and discharged without any complications on POD 4. The mass was histopathologically confirmed as an extra-adrenal paraganglioma.

Case 2

The patient returned to the operating room after alpha blockade therapy for two weeks. Anesthesia induction was uneventful. During tumor manipulation, the increase in blood pressure was easily controlled with small doses of nicardipine. Modest hypotension (85/40 mmHg) occurred after tumor excision and was treated with short-term infusion of norepinephrine and fluids. The patient was transferred to the ICU after surgery and was hemodynamically stable without any vasopressors. He was transferred to the general ward on POD 1 and discharged without any complications on POD 12. The mass was histopathologically confirmed to be an extra-adrenal paraganglioma.

DISCUSSION

The present case report describes different intraoperative decisions for two patients with undiagnosed paragangliomas. We aimed to clarify the decision-making regarding continuation of surgery when a paraganglioma was identified intraoperatively. This issue has not been emphasized in previous literatures.

Patients with paragangliomas do not always show catecholamine-related symptoms, making proper preoperative diagnosis difficult. The incidence of headache, palpitations, perspiration, pallor, and hypertension has been reported to be 26%, 21%, 25%, 12%, and 64%, respectively[8]. Although the first patient had hypertension, her preoperative blood pressure was well-controlled. The second patient had no history of hypertension and did not show any symptoms associated with catecholamine-secreting tumors. Therefore, the possibility of paraganglioma was overlooked and hormonal studies were not conducted in either case.

When an adrenal or retroperitoneal mass without clinical symptom is incidentally detected, results of imaging studies may sometimes indicate the need for biochemical screening for catecholamine-producing tumors. Therefore, previous images should be interpreted with caution, taking into consideration of additional imaging studies. For example, degree of attenuation on unenhanced CT images[9, 10] or signal intensity on T2-weighted magnetic resonance (MR) images[11,12] of the mass could provide presumptive criteria to characterize production of catecholamine. Functional imaging such as scintigraphy with metaiodobenzylguanidine (MIBG) or positron-emission tomography (PET) scanning is also effective in localizing metastatic disease or multiple paragangliomas[13-15].

Elective surgery in patients with undiagnosed paragangliomas or pheochromocytomas can be life-threatening. Previous studies have reported the occurrence of a hypertensive crisis primarily during tumor manipulation and/or induction of anesthesia. The complications arising from alarmingly high blood pressure include cerebrovascular hemorrhage, hypertensive encephalopathy, neurological deficits, severe arterial spasms causing unconsciousness, metabolic acidemia, heart failure, arrhythmias, and myocardial infarction[16]. Severe hypotension after tumor removal, rather than hypertension during tumor manipulation, can lead to even more disastrous consequences, including cardiac arrest and death. In the cases described in this report, serious complications related to hypotension did not occur. However, severe hypotension developed after tumor removal in the first patient (case 1), who was not treated preoperatively. Conversely, modest and transient hypotension was observed after tumor removal in the second patient (case 2), who was treated with doxazosin. This finding emphasizes the importance of appropriate preoperative preparation in patients with suspected catecholamine-producing tumors.

The clinical practice guidelines for pheochromocytoma and paraganglioma issued by the Endocrine Society continue to recommend alpha-adrenergic blockade for at least 7 d preoperatively to prevent unpredictable instability in blood pressure during surgery[12]. Although the concept of adrenergic blockade-free management is evolving[17,18], there is no consensus supporting this approach[15]. High levels of catecholamines in patients with paraganglioma/pheochromocytoma produce chronic vasoconstriction and a subsequent decrease in blood volume. Therefore, in combination with the use of alpha-adrenergic receptor blockers, preoperative fluid replacement is essential for gradual restoration of catecholamine-induced blood volume contraction[12] and can reduce the risk of severe and sustained hypotension after tumor removal[19].

Paragangliomas are frequently found in areas that are difficult to resect, as observed in the second patient. Although intraoperative cancellation of the surgery was not an easy decision, the surgeon and anesthesiologists believed that continuous manipulation of the tumor without adequate preparation might result in disastrous consequences. Fortunately, the mass in the first patient was in a favorable location, and serious hemodynamic instability could be avoided by minimal manipulation under aggressive use of vasoactive drugs.

CONCLUSION

Hemodynamic management of patients with catecholamine-producing tumors remains a challenge for anesthesiologists, especially when preoperative alpha blockade has not been established. When an undiagnosed paraganglioma or pheochromocytoma is suspected during surgery, immediate and coordinated responses by surgeons and anesthesiologists are required to avoid fatal outcomes. Intraoperative cancellation of surgery may not always be feasible or practical, but it should be considered as an option in cases requiring frequent manipulation of the tumor.

FOOTNOTES

Author contributions: Kang D and Kim B wrote the manuscript; Hong M and Kim J performed literature analysis; Jeong S was the anesthesiologist in charge of the patient; Lee S revised the manuscript for important intellectual content; all authors approved the final version of the manuscript to be submitted.

Informed consent statement: Informed written consents were obtained from the patients for publication of this report and any accompanying images.

Conflict-of-interest statement: The authors declare that they have no conflict of interest to disclose.

CARE Checklist (2016) statement: The authors have read the CARE Checklist (2016), and the manuscript was prepared and revised according to the CARE Checklist (2016).

Open-Access: This article is an open-access article that was selected by an in-house editor and fully peer-reviewed by external reviewers. It is distributed in accordance with the Creative Commons Attribution NonCommercial (CC BY-NC 4.0) license, which permits others to distribute, remix, adapt, build upon this work non-commercially, and license their derivative works on different terms, provided the original work is properly cited and the use is non-commercial. See: <https://creativecommons.org/licenses/by-nc/4.0/>

Country/Territory of origin: South Korea

ORCID number: Dongho Kang 0000-0002-5299-6861; Bo-eun Kim 0000-0002-4923-6829; Minjae Hong 0000-0003-1160-8700; Joungmin Kim 0000-0003-1135-1968; Seongtae Jeong 0000-0002-6245-9779; Seongheon Lee 0000-0002-2675-2521.

S-Editor: Chen YL

L-Editor: A

P-Editor: Chen YL

REFERENCES

- Joynt KE, Moslehi JJ, Baughman KL. Paragangliomas: etiology, presentation, and management. *Cardiol Rev* 2009; **17**: 159-164 [PMID: 19525677 DOI: 10.1097/CRD.0b013e3181a6de40]
- Renard J, Clerici T, Licker M, Triponez F. Pheochromocytoma and abdominal paraganglioma. *J Visc Surg* 2011; **148**: e409-e416 [PMID: 21862435 DOI: 10.1016/j.jvisurg.2011.07.003]
- Lee JA, Duh QY. Sporadic paraganglioma. *World J Surg* 2008; **32**: 683-687 [PMID: 18224469 DOI: 10.1007/s00268-007-9360-4]
- Fox WC, Read M, Moon RE, Moretti EW, Colin BJ. An Undiagnosed Paraganglioma in a 58-Year-Old Female Who Underwent Tumor Resection. *Case Rep Anesthesiol* 2017; **2017**: 5796409 [PMID: 29163991 DOI: 10.1155/2017/5796409]
- Han IS, Kim YS, Yoo JH, Lim SS, Kim TK. Anesthetic management of a patient with undiagnosed paraganglioma -a case report-. *Korean J Anesthesiol* 2013; **65**: 574-577 [PMID: 24427467 DOI: 10.4097/kjae.2013.65.6.574]
- Mahmoud S, Salami M, Salman H. A rare serious case of retroperitoneal paraganglioma misdiagnosed as duodenal gastrointestinal stromal tumor: a case report. *BMC Surg* 2020; **20**: 49 [PMID: 32178651 DOI: 10.1186/s12893-020-00712-z]
- Chen X, Liu X, Tian S, Wang X, Tang H, Yu Y, Zhang D, Peng Y. Cardiac arrest and catecholamine cardiomyopathy secondary to a misdiagnosed ectopic pheochromocytoma. *Endokrynol Pol* 2020; **71**: 479-480 [PMID: 32716044 DOI: 10.5603/EP.a2020.0040]
- Erickson D, Kudva YC, Ebersold MJ, Thompson GB, Grant CS, van Heerden JA, Young WF Jr. Benign paragangliomas: clinical presentation and treatment outcomes in 236 patients. *J Clin Endocrinol Metab* 2001; **86**: 5210-5216 [PMID: 11701678 DOI: 10.1210/jcem.86.11.8034]
- Canu L, Van Hemert JAW, Kerstens MN, Hartman RP, Khanna A, Kraljevic I, Kastelan D, Badiu C, Ambroziak U, Tabarin A, Haissaguerre M, Buitenwerf E, Visser A, Mannelli M, Arlt W, Chortis V, Bourdeau I, Gagnon N, Buchy M, Borson-Chazot F, Deutschbein T, Fassnacht M, Hubalewska-Dydejczyk A, Motyka M, Rzepka E, Casey RT, Challis BG, Quinkler M, Vroonen L, Spyroglou A, Beuschlein F, Lamas C, Young WF, Bancos I, Timmers HJLM. CT Characteristics of Pheochromocytoma: Relevance for the Evaluation of Adrenal Incidentaloma. *J Clin Endocrinol Metab* 2019; **104**: 312-318 [PMID: 30383267 DOI: 10.1210/jc.2018-01532]
- Dinnes J, Bancos I, Ferrante di Ruffano L, Chortis V, Davenport C, Bayliss S, Sahdev A, Guest P, Fassnacht M, Deeks JJ, Arlt W. MANAGEMENT OF ENDOCRINE DISEASE: Imaging for the diagnosis of malignancy in incidentally discovered adrenal masses: a systematic review and meta-analysis. *Eur J Endocrinol* 2016; **175**: R51-R64 [PMID: 27257145 DOI: 10.1530/EJE-16-0461]
- Maurea S, Caracò C, Klain M, Mainolfi C, Salvatore M. Imaging characterization of non-hypersecreting adrenal masses. Comparison between MR and radionuclide techniques. *Q J Nucl Med Mol Imaging* 2004; **48**: 188-197 [PMID: 15499292]
- Lenders JW, Duh QY, Eisenhofer G, Gimenez-Roqueplo AP, Grebe SK, Murad MH, Naruse M, Pacak K, Young WF Jr; Endocrine Society. Pheochromocytoma and paraganglioma: an endocrine society clinical practice guideline. *J Clin Endocrinol Metab* 2014; **99**: 1915-1942 [PMID: 24893135 DOI: 10.1210/jc.2014-1498]
- Maurea S, Cuocolo A, Reynolds JC, Neumann RD, Salvatore M. Diagnostic imaging in patients with paragangliomas. Computed tomography, magnetic resonance and MIBG scintigraphy comparison. *Q J Nucl Med* 1996; **40**: 365-371 [PMID: 9050342]
- Lastoria S, Maurea S, Vergara E, Acampa W, Varrella P, Klain M, Muto P, Bernardy JD, Salvatore M. Comparison of labeled MIBG and somatostatin analogs in imaging neuroendocrine tumors. *Q J Nucl Med* 1995; **39**: 145-149 [PMID: 9002775]
- Neumann HPH, Young WF Jr, Eng C. Pheochromocytoma and Paraganglioma. *N Engl J Med* 2019; **381**: 552-565 [PMID: 31390501 DOI: 10.1056/NEJMra1806651]
- Livingstone M, Duttchen K, Thompson J, Sunderani Z, Hawboldt G, Sarah Rose M, Pasioka J. Hemodynamic Stability During Pheochromocytoma Resection: Lessons Learned Over the Last Two Decades. *Ann Surg Oncol* 2015; **22**: 4175-4180 [PMID: 25822781 DOI: 10.1245/s10434-015-4519-y]
- Groeben H, Nottebaum BJ, Alesina PF, Traut A, Neumann HP, Walz MK. Perioperative α -receptor blockade in

- phaeochromocytoma surgery: an observational case series. *Br J Anaesth* 2017; **118**: 182-189 [PMID: [28100521](#) DOI: [10.1093/bja/aew392](#)]
- 18 **Shao Y**, Chen R, Shen ZJ, Teng Y, Huang P, Rui WB, Xie X, Zhou WL. Preoperative alpha blockade for normotensive pheochromocytoma: is it necessary? *J Hypertens* 2011; **29**: 2429-2432 [PMID: [22025238](#) DOI: [10.1097/HJH.0b013e32834d24d9](#)]
- 19 **Pacak K**. Preoperative management of the pheochromocytoma patient. *J Clin Endocrinol Metab* 2007; **92**: 4069-4079 [PMID: [17989126](#) DOI: [10.1210/jc.2007-1720](#)]



Published by **Baishideng Publishing Group Inc**
7041 Koll Center Parkway, Suite 160, Pleasanton, CA 94566, USA

Telephone: +1-925-3991568

E-mail: bpgoffice@wjgnet.com

Help Desk: <https://www.f6publishing.com/helpdesk>

<https://www.wjgnet.com>

