


World Journal of *Gastroenterology*

World J Gastroenterol 2022 October 7; 28(37): 5383-5514



STANDARD AND CONSENSUS

- 5383 Baishideng's *Reference Citation Analysis* database announces the first *Journal Article Influence Index* of 101 core journals and a list of high-quality academic journals in gastroenterology and hepatology
Wang JL, Ma YJ, Ma L, Ma N, Guo DM, Ma LS

OPINION REVIEW

- 5395 Milestones in the discovery of hepatitis C
Campollo O, Amaya G, McCormick PA

REVIEW

- 5403 Immunotherapy-based novel nanoparticles in the treatment of gastrointestinal cancer: Trends and challenges
Ding YN, Xue M, Tang QS, Wang LJ, Ding HY, Li H, Gao CC, Yu WP

ORIGINAL ARTICLE

Basic Study

- 5420 Lentivirus-mediated short hairpin RNA interference of CENPK inhibits growth of colorectal cancer cells with overexpression of Cullin 4A
Li X, Han YR, Xuefeng X, Ma YX, Xing GS, Yang ZW, Zhang Z, Shi L, Wu XL

Retrospective Cohort Study

- 5444 Prognostic performance of an index based on lactic dehydrogenase and transaminases for patients with liver steatosis and COVID-19
Macías-Rodríguez RU, Solís-Ortega AA, Ornelas-Arroyo VJ, Ruiz-Margáin A, González-Huezo MS, Urdiales-Morán NA, Román-Calleja BM, Mayorquín-Aguilar JM, González-Regueiro JA, Campos-Murguía A, Toledo-Coronado IV, Chapa-Ibargüengoitia M, Valencia-Peña B, Martínez-Cabrera CF, Flores-García NC

Retrospective Study

- 5457 Efficacy of endoscopic ultrasound in the evaluation of small gastrointestinal stromal tumors
Ge QC, Wu YF, Liu ZM, Wang Z, Wang S, Liu X, Ge N, Guo JT, Sun SY
- 5469 Online calculator for predicting the risk of malignancy in patients with pancreatic cystic neoplasms: A multicenter, retrospective study
Jiang D, Chen ZX, Ma FX, Gong YY, Pu T, Chen JM, Liu XQ, Zhao YJ, Xie K, Hou H, Wang C, Geng XP, Liu FB

Observational Study

- 5483 Application of an artificial intelligence system for endoscopic diagnosis of superficial esophageal squamous cell carcinoma
Meng QQ, Gao Y, Lin H, Wang TJ, Zhang YR, Feng J, Li ZS, Xin L, Wang LW

- 5494** Insights into hepatitis E virus epidemiology in Croatia

Jelicic P, Ferenc T, Mrzljak A, Jemersic L, Janev-Holcer N, Milosevic M, Bogdanic M, Barbic L, Kolaric B, Stevanovic V, Vujica M, Jurekovic Z, Pavicic Saric J, Vilibic M, Vilibic-Cavlek T

CASE REPORT

- 5506** Massive bleeding from gastric submucosal arterial collaterals secondary to splenic artery thrombosis: A case report

Martino A, Di Serafino M, Zito FP, Maglione F, Bennato R, Orsini L, Iacobelli A, Niola R, Romano L, Lombardi G

ABOUT COVER

Editorial Board Member of *World Journal of Gastroenterology*, Masahiro Iizuka, MD, PhD, Director, Akita Health Care Center, Akita Red Cross Hospital, 3-4-23 Nakadori, Akita-shi, Akita 010-0001, Japan.
maiizuka@woody.ocn.ne.jp

AIMS AND SCOPE

The primary aim of *World Journal of Gastroenterology* (WJG, *World J Gastroenterol*) is to provide scholars and readers from various fields of gastroenterology and hepatology with a platform to publish high-quality basic and clinical research articles and communicate their research findings online. WJG mainly publishes articles reporting research results and findings obtained in the field of gastroenterology and hepatology and covering a wide range of topics including gastroenterology, hepatology, gastrointestinal endoscopy, gastrointestinal surgery, gastrointestinal oncology, and pediatric gastroenterology.

INDEXING/ABSTRACTING

The WJG is now abstracted and indexed in Science Citation Index Expanded (SCIE, also known as SciSearch®), Current Contents/Clinical Medicine, Journal Citation Reports, Index Medicus, MEDLINE, PubMed, PubMed Central, Scopus, Reference Citation Analysis, China National Knowledge Infrastructure, China Science and Technology Journal Database, and Superstar Journals Database. The 2022 edition of Journal Citation Reports® cites the 2021 impact factor (IF) for WJG as 5.374; IF without journal self cites: 5.187; 5-year IF: 5.715; Journal Citation Indicator: 0.84; Ranking: 31 among 93 journals in gastroenterology and hepatology; and Quartile category: Q2. The WJG's CiteScore for 2021 is 8.1 and Scopus CiteScore rank 2021: Gastroenterology is 18/149.

RESPONSIBLE EDITORS FOR THIS ISSUE

Production Editor: *Ying-Yi Yuan*; Production Department Director: *Xiang Li*; Editorial Office Director: *Jia-Ru Fan*.

NAME OF JOURNAL

World Journal of Gastroenterology

ISSN

ISSN 1007-9327 (print) ISSN 2219-2840 (online)

LAUNCH DATE

October 1, 1995

FREQUENCY

Weekly

EDITORS-IN-CHIEF

Andrzej S Tarnawski

EDITORIAL BOARD MEMBERS

<http://www.wjgnet.com/1007-9327/editorialboard.htm>

PUBLICATION DATE

October 7, 2022

COPYRIGHT

© 2022 Baishideng Publishing Group Inc

INSTRUCTIONS TO AUTHORS

<https://www.wjgnet.com/bpg/gerinfo/204>

GUIDELINES FOR ETHICS DOCUMENTS

<https://www.wjgnet.com/bpg/GerInfo/287>

GUIDELINES FOR NON-NATIVE SPEAKERS OF ENGLISH

<https://www.wjgnet.com/bpg/gerinfo/240>

PUBLICATION ETHICS

<https://www.wjgnet.com/bpg/GerInfo/288>

PUBLICATION MISCONDUCT

<https://www.wjgnet.com/bpg/gerinfo/208>

ARTICLE PROCESSING CHARGE

<https://www.wjgnet.com/bpg/gerinfo/242>

STEPS FOR SUBMITTING MANUSCRIPTS

<https://www.wjgnet.com/bpg/GerInfo/239>

ONLINE SUBMISSION

<https://www.f6publishing.com>



Retrospective Study

Efficacy of endoscopic ultrasound in the evaluation of small gastrointestinal stromal tumors

Qi-Chao Ge, Yu-Fan Wu, Zi-Ming Liu, Zhe Wang, Sheng Wang, Xiang Liu, Nan Ge, Jin-Tao Guo, Si-Yu Sun

Specialty type: Gastroenterology and hepatology

Provenance and peer review: Unsolicited article; Externally peer reviewed.

Peer-review model: Single blind

Peer-review report's scientific quality classification

Grade A (Excellent): A, A

Grade B (Very good): B

Grade C (Good): 0

Grade D (Fair): 0

Grade E (Poor): 0

P-Reviewer: Kim HJ, South Korea; Sundaram S, India; Villa E, United States

Received: June 22, 2022

Peer-review started: June 22, 2022

First decision: September 2, 2022

Revised: September 14, 2022

Accepted: September 20, 2022

Article in press: September 20, 2022

Published online: October 7, 2022



Qi-Chao Ge, Yu-Fan Wu, Zi-Ming Liu, Sheng Wang, Xiang Liu, Nan Ge, Jin-Tao Guo, Si-Yu Sun, Department of Gastroenterology, Shengjing Hospital of China Medical University, Shenyang 110004, Liaoning Province, China

Zhe Wang, Department of Pathology, Shengjing Hospital of China Medical University, Shenyang 110004, Liaoning Province, China

Corresponding author: Jin-Tao Guo, MD, PhD, Professor, Department of Gastroenterology, Shengjing Hospital of China Medical University, No. 36 Sanhao Street, Shenyang 110004, Liaoning Province, China. guojt@sj-hospital.org

Abstract

BACKGROUND

Gastrointestinal stromal tumors (GISTs) with a diameter of < 2 cm are called small GISTs. Currently, endoscopic ultrasound (EUS) is widely used as a regular follow-up method for GISTs, which can also provide a preliminary basis for judging the malignancy potential of lesions. However, there are no studies on the accuracy of EUS to assess the malignant potential of small GISTs.

AIM

To evaluate the efficacy of EUS in the diagnosis and risk assessment of small GISTs.

METHODS

We collected data from patients with small GISTs who were admitted to Shengjing Hospital of China Medical University between October 2014 and July 2019. The accurate diagnosis and risk classifications of patients were based on the pathological assessment according to the modified National Institute of Health criteria after endoscopic resection or laparoscopic surgery. Preoperative EUS features (marginal irregularity, cystic changes, homogeneity, ulceration, and strong echogenic foci) were retrospectively analyzed. The assessment results based on EUS features were compared with the pathological features.

RESULTS

A total of 256 patients (69 men and 187 women) were enrolled. Pathological results included 232, 16, 7, and 1 very low-, low-, intermediate-, and high-risk cases, respectively. The most frequent tumor location was the gastric fundus (78.1%), and mitoses were calculated as > 5/50 high power field in 8 (3.1%)

patients. Marginal irregularity, ulceration, strong echo foci, and heterogeneity were detected in 1 (0.4%), 2 (0.8%), 22 (8.6%), and 67 (65.1%) patients, respectively. However, cystic changes were not detected. Tumor size was positively correlated with the mitotic index ($P < 0.001$). Receiver operating curve analysis identified 1.48 cm as the best cut-off value to predict malignant potential (95% confidence interval: 0.824–0.956). EUS heterogeneity with tumor diameters > 1.48 cm was associated with higher risk classification ($P < 0.05$).

CONCLUSION

Small GISTs (diameters > 1.48 cm) with positive EUS features should receive intensive surveillance or undergo endoscopic surgery. EUS and dissection are efficient diagnostic and therapeutic approaches for small GISTs.

Key Words: Gastrointestinal stromal tumors; Endoscopic ultrasound; Diagnosis; Risk classification

©The Author(s) 2022. Published by Baishideng Publishing Group Inc. All rights reserved.

Core Tip: Endoscopic ultrasound (EUS) has been the recommended follow-up method for small gastrointestinal stromal tumors (GISTs); however, it is not clear whether positive EUS features can predict the malignant potential of small GISTs. Besides, undergoing close follow-up is an economic and mental burden on patients with small GISTs. This study illustrates an optimal cut-off value for the tumor size (1.48 cm) of small GISTs and uses heterogeneity to evaluate risk prediction. Overall, small GISTs with diameters > 1.48 cm with positive EUS features should receive more intensive follow-up or undergo endoscopic surgery.

Citation: Ge QC, Wu YF, Liu ZM, Wang Z, Wang S, Liu X, Ge N, Guo JT, Sun SY. Efficacy of endoscopic ultrasound in the evaluation of small gastrointestinal stromal tumors. *World J Gastroenterol* 2022; 28(37): 5457-5468

URL: <https://www.wjgnet.com/1007-9327/full/v28/i37/5457.htm>

DOI: <https://dx.doi.org/10.3748/wjg.v28.i37.5457>

INTRODUCTION

Gastrointestinal stromal tumors (GISTs) are the most common mesenchy-derived tumors of the gastrointestinal tract[1,2]. They occur most frequently in the stomach, accounting for approximately 60% of all cases[3,4]. Most GISTs contain mutations that activate the c-kit or platelet-derived growth factor receptor α gene[5,6]. The golden standard for the diagnosis of GISTs relies on pathological features assessed by methods, such as hematoxylin and eosin (H&E) and immunohistochemical staining. Currently, the risk classification of GISTs is mainly based on the National Institute of Health (NIH) 2008 (modified) or Fletcher criteria[7,8], which include tumor size (2, 5, and 10 cm), mitotic index, primary tumor sites, and tumor rupture.

GISTs with a diameter of < 2 cm are called small GISTs[9]. Currently, the management of small GISTs is controversial. There is no consensus on the treatment of GIST with a diameter of < 2 cm in the latest guidelines of the National Comprehensive Cancer Network (NCCN) (United States), European Society for Medical Oncology (ESMO), and Chinese Society of Clinical Oncology (CSCO)[10-12]. Most small GISTs are discovered incidentally during regular endoscopic scanning, and they are now easier to be detected than before using endoscopic ultrasound (EUS). EUS has been the widely recommended surveillance method for small GISTs. In addition, EUS elastography, contrast-enhanced EUS, and EUS-guided fine needle aspiration and biopsy (EUS-FNA/FNB) have further improved their diagnostic accuracy[13-16]. Furthermore, EUS features have been used in some studies to predict the risk degree of GISTs[17-19]. However, the management of small GISTs remains controversial, and endoscopic resection *via* endoscopic submucosal dissection (ESD) or endoscopic full-thickness resection (EFTR) is not recommended as a routine treatment. Conversely, no study has focused on the positive EUS features for determining the degree of risk for small GISTs. Therefore, in this study, we aimed to identify the efficiency of EUS in the risk assessment and safety of endoscopic dissection for small GISTs.

MATERIALS AND METHODS

Patients

Data on consecutive patients with pathologically confirmed GISTs who were admitted to Shengjing Hospital of China Medical University between September 2014 and July 2019 were collected. The study included patients who underwent endoscopic resection and were pathologically or genotypically diagnosed with GISTs with a diameter of ≤ 2 cm. All the patients underwent preoperative EUS examination. Patients with other sarcomatous malignancies and/or with incomplete data were excluded. This study was approved by the Institutional Review Board and the Ethics Committee of China Medical University (No. 2022PS009K), and all the patients provided informed consent to participate in the study.

EUS examination

Linear EUS (EG3870UT; Pentax, Tokyo, Japan) was used for the examination. Two experienced endoscopists, who were blinded to the pathological results of these lesions, retrospectively evaluated the characteristics of the EUS images to determine whether there were positive features, including irregular borders, cystic changes, ulcerations, strong echogenic foci, heterogeneity, and the presence of an exogenous type of development (Figures 1 and 2). According to the NCCN guidelines, one or more positive EUS features indicate the malignant potential of small GISTs.

Endoscopic resection procedure

The equipment and accessories used during the endoscopic procedure included a standard single-channel gastroscope (EG29-i10, Pentax, Tokyo, Japan) and a transparent cap. Triangle- (TT knife, Olympus Corporation, Tokyo, Japan) and insulation- tipped knives (IT knife, Olympus Corporation, Tokyo, Japan) were used for the dissection and resection of tumors. During the procedure, hot biopsy forceps (FD-410LR, Olympus Corporation, Tokyo, Japan) were used for hemostasis. Metal clips (Boston Resolution™, Boston, United States) and an over-the-scope clips (OTSC) (Ovesco Endoscopy GmbH, Tuebingen, Germany) were used for the closure of defects.

All endoscopic resections were performed by skilled gastroenterologists, following the standard endoscopic treatment regimen. All procedures were performed using propofol sedation under continuous cardiorespiratory monitoring. Ligation-assisted endoscopic resection, ESD, and EFTR were performed to resect gastric GISTs.

Pathological examination

All resected GIST specimens were routinely processed using a standard surgical pathology protocol after overnight fixation in 10% neutral buffered formalin solution. The details of the tumor site, size, shape, surface color, and consistency were documented by a surgical pathologist. Conventional immunochemistry with a panel of antibodies, such as CD117 (c-kit), CD34, Dog-1, S-100, and smooth muscle actin, was used to support the histopathological diagnosis of GIST. Based on the modified NIH criteria, patients with GISTs were divided into very low-, low-, intermediate-, and high-risk groups (Table 1).

Follow-up strategy

All the patients were routinely followed-up with conventional endoscopic surveillance at 1, 3, 6, and 12 mo after resection. This was followed by annual abdominal computed tomography (CT) for 3 years to rule out recurrence and metastasis. If no residual tumor or tumor recurrence was observed, endoscopic examinations were performed once every 2 years. The follow-up period was up to October 2020. If residual tumor or tumor recurrence was detected, endoscopic resection or surgery could be performed.

Statistical analysis

Data processing was performed using the SPSS statistical software (SPSS 23.0, Chicago, IL, United States). Continuous data are expressed as the mean \pm SD, and categorical data are displayed as number (*n*) or percentage (%). The accuracy of the diagnostic test was evaluated by sensitivity, specificity, false negative and positive rates, positive and negative likelihood ratios, and Youden's index. The Chi-square test was applied for intergroup comparisons. A receiver operating characteristic (ROC) curve was performed to determine the optimal tumor diameter for predicting malignant potential. Lesions with positive EUS features or mitoses more than 5/50 high power field (HPF) were defined as true positives. *P* value < 0.05 was considered statistically significant.

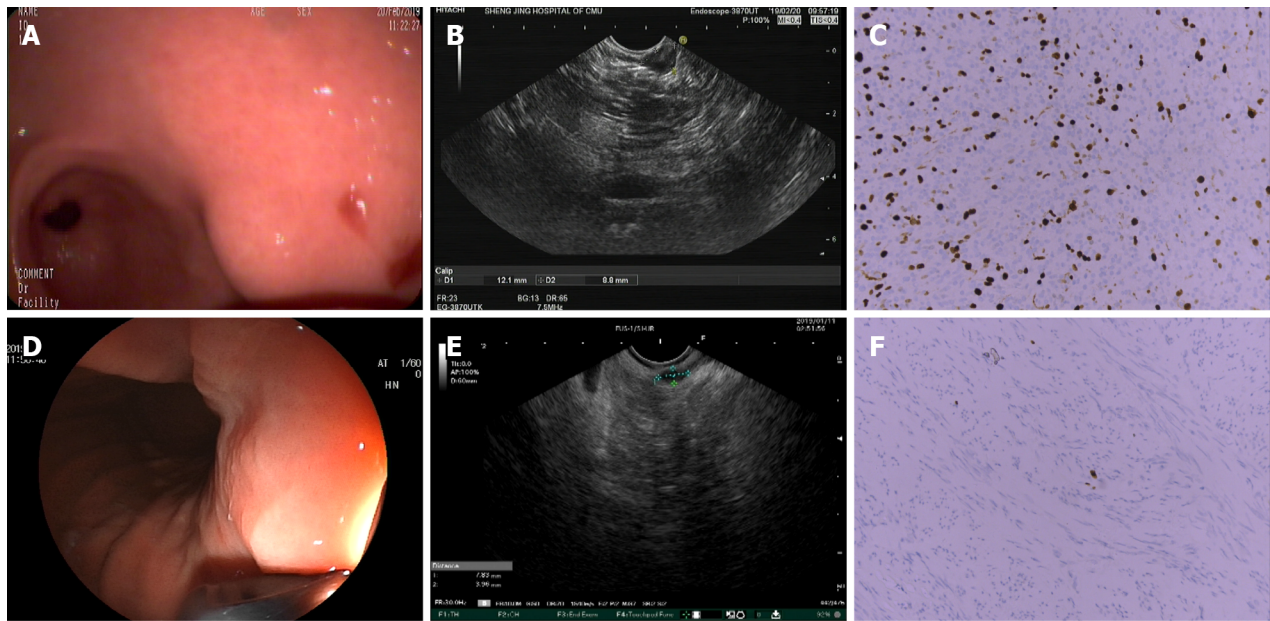
RESULTS

Clinical and pathological features of small gastric GISTs

A total of 256 patients, including 69 men (27%) and 187 women (73%), were enrolled in the study

Table 1 The modified National Institute of Health risk classification of small Gastrointestinal stromal tumors		
Risk classification	Tumor diameter (d/cm)	Mitotic count (number/50 HPF)
Very-low	D ≤ 2	Mitotic ≤ 5
Intermediate	D ≤ 2	5 < mitotic ≤ 10
High	D ≤ 2	Mitotic > 10

HPF: High power field.



DOI: 10.3748/wjg.v28.i37.5457 Copyright ©The Author(s) 2022.

Figure 1 Endoscopic ultrasound imaging features were consistent with the postoperative pathological results. A: A lesion with a diameter of approximately 1.2 cm was observed in the gastric antrum using an endoscope; B: Heterogeneity was observed as a characteristic of endoscopic ultrasound (EUS) imaging; C: Gastric stromal tumor (intermediate risk). The spindle of the tumor cells is arranged in sheets and bundles with nuclear division of approximately 8-9/50 high power field. Immunohistochemistry: CD117 (+); CD34 (-); Desmin (-); Dog1 (+); Ki-67 (35%+); smooth muscle actin (+); and S-100 (-); D: A lesion with a diameter of approximately 0.6 cm was observed in the gastric fundus using an endoscope; E: EUS images were characterized by a hypoechoic mass in the muscularis propria; F: Gastric stromal tumor (very low risk). The spindle of the tumor cells is arranged in spindle and bundles without obvious nuclear division. Immunohistochemistry: CD117 (+); CD34 (-); Desmin (-); Dog1 (+); Ki-67 (< 1%+); smooth muscle actin (-); and S-100 (-).

(Table 2), with an average age of 57.4 ± 8.6 years. The most frequent locations of the tumors were the gastric fundus (78.1%) and body (17.2%), and the average diameter of all lesions was 1.05 cm (range, 0.30–2.00 cm). These patients were eventually diagnosed with GISTs mainly based on pathological standards, such as H&E and immunohistochemistry staining. According to the modified NIH criterion, mitoses were calculated as $> 5/50$ HPF and $\leq 5/50$ HPF in 8 (3.1%) and 248 (96.9%) patients, respectively. The patients' features in the EUS images are shown in Table 2, illustrating that 67 (65.1%) and 22 (8.6%) cases were identified with heterogenous and hyperechoic foci, respectively. However, a lobular border and ulceration were detected in only 3 cases (1.2%).

ROC curve analysis

To determine a suitable cut-off value for predicting the higher risk potential of small GISTs, aggressive biological behaviors were expanded to mitoses more than 5/50 HPF. Lesions with mitoses more than 5/50 HPF were defined as true positives. A tumor diameter of 1.48 cm was finally identified as the optimal cut-off value, with the area under the curve (AUC) being 0.89 (95% confidence interval: 0.824–0.956; $P < 0.001$) (Figure 3A), a sensitivity of 0.875, and a specificity of 0.828 (Figure 3B). Subsequently, 208 and 48 patients were classified into groups with tumor size ≤ 1.48 cm and > 1.48 cm, respectively. The comparison of the clinicopathological characteristics between the two groups is presented in Table 3. In the > 1.48 cm group, a higher percentage of patients had more than 5 mitotic indexes/50 HPFs compared to those in the ≤ 1.48 cm group (14.58% *vs* 0.48%, $P < 0.001$). Moreover, patients with larger tumor diameter tended to display positive EUS features (56.25% *vs* 31.25%, $P = 0.002$).

Table 2 Clinicopathological characteristics of the patients

Characteristics	Cases (n = 256)
Age (year)	57.4 ± 8.6
Sex, n (%)	
Male	69 (27.0)
Female	187 (73.0)
Tumor location, n (%)	
Cardia	6 (2.3)
Fundus	200 (78.1)
Body	44 (17.2)
Antrum	6 (2.4)
Endoscopic resection, n (%)	
ESD	136 (53.1)
EFTR	120 (46.9)
Tumor size (cm), n (%)	
≤ 1.48	208 (81.3)
>1.48	48 (18.7)
Mitotic index (/50HPF), n (%)	
≤ 5	248 (96.9)
> 5	8 (3.1)
Modified NIH classification, n (%)	
Very-low	232 (90.6)
Low	16 (6.3)
Intermediate	7 (2.7)
High	1 (0.4)
Positive EUS features, n (%)	
Heterogenous	67 (65.1)
Hyperechoic foci	22 (8.6)
Lobular border	1 (0.4)
Ulceration	2 (0.8)

ESD: Endoscopic submucosal dissection; EFTR: Endoscopic full-thickness resection; EUS: Endoscopic ultrasound; HPF: High power field; NIH: National Institute of Health.

Comparison of non-low-risk and low-risk GISTs in terms of EUS features

We compared the consistency of positive EUS features and pathological risk classification of small GISTs, and found that intermediate- and very low-risk cases presented with heterogeneous (Figure 1A-C) and hypoechoic (Figure 1D-F) EUS findings, respectively. This suggests that EUS imaging features were consistent with the postoperative pathological results. However, some cases showed that EUS imaging features were inconsistent with the postoperative pathological results [intermediate-risk case with hypoechoic mass (Figure 2A-C) and very-low-risk case with strong echogenic foci (Figure 2D-F)]. To further identify the efficiency of positive EUS features in the risk assessment of small GISTs, we divided these patients into non-low-risk and low-risk groups (Table 4). Five of eight patients with non-low-risk GISTs (62.5%) and 62 of 248 patients with low-risk GISTs (25%) had heterogeneous features. There was a significant difference ($P = 0.031$) in the heterogeneous features between low- and high-grade risk GISTs. However, there was no statistical difference in hyperechoic foci and ulceration between low- and high-grade risk GISTs. Hyperechoic foci were found in 0 of 8 (0%) and 22 of 248 (8.87%) non-low- and low-risk groups, respectively. The ulcerative appearance was found in 0 of 8 (0%) and 2 of 248 (0.8%) non-low- and low-risk groups, respectively. Furthermore, other positive EUS

Table 3 Comparisons of clinicopathological and endoscopic ultrasonographic features between ≤ 1.48 cm and > 1.48 cm groups

Characteristic	Tumor size		P value
	≤ 1.48 cm group	> 1.48 cm group	
Age (year)	57.3 \pm 8.6	58.2 \pm 8.4	0.49
Sex			0.368
Men	59	10	
Women	149	38	
Tumor location			0.01
Fundus	168	32	
Body	34	10	
Antrum	4	2	
Cardia	2	4	
Mitotic index (/50 HPFs)			< 0.001
≤ 5	207	41	
> 5	1	7	
Positive EUS features ¹			0.002
Yes	65	25	
No	143	23	

¹Marginal irregularity, cystic changes, ulcers, strong echo foci, and heterogeneity. EUS: Endoscopic ultrasound; HPF: High power field.

Table 4 Comparisons of positive endoscopic ultrasonographic features between the pathologically non-low-risk group and low-risk group

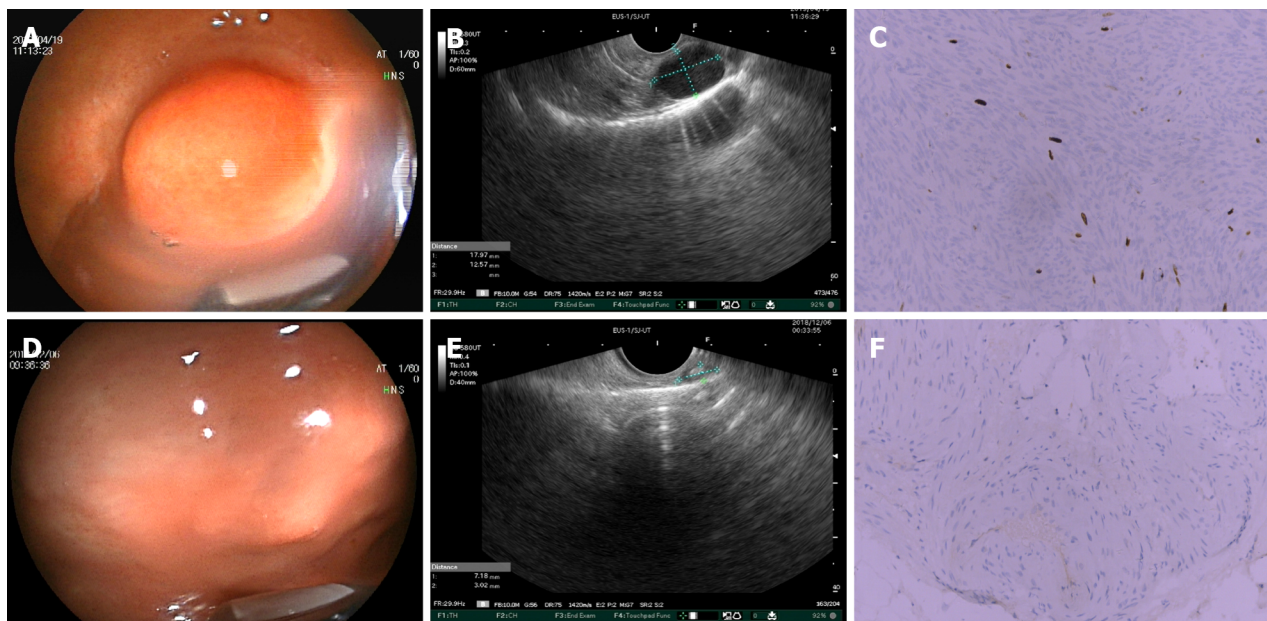
Positive EUS features	Risk classification		P value
	Intermediate/high	Very low/low	
Heterogeneous			0.031
Yes	5	62	
No	3	186	
Hyperechoic foci			NS
Yes	0	22	
No	8	226	
Ulcers			NS
Yes	0	2	
No	8	246	

EUS: Endoscopic ultrasound; NS: No significant.

features, such as marginal irregularity and cystic changes, were not detected in small GISTs.

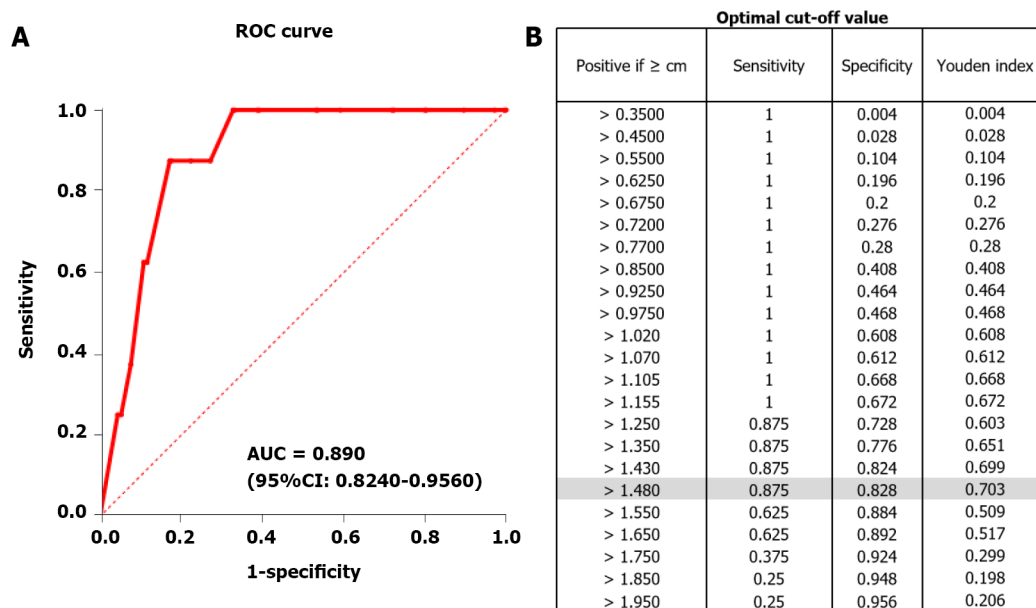
DISCUSSION

The incidence of GIST ranges from 6 to 22 cases *per* 10⁶ individuals *per* year[20,21], while that of small GISTs might be higher as more cases of asymptomatic small GISTs have been detected clinically due to the growing popularity of endoscopy in the recent years. Currently, there is no consensus on whether small GISTs (≤ 2 cm) require resection or yearly surveillance in the latest guidelines, including NCCN, ESMO, and CSCO[10-12,22]. However, the ESMO recommends that resection should be the standard



DOI: 10.3748/wjg.v28.i37.5457 Copyright ©The Author(s) 2022.

Figure 2 Endoscopic ultrasound imaging features were inconsistent with the postoperative pathological results. A: A lesion with a diameter of approximately 2 cm was observed in the gastric fundus using an endoscope; B: Endoscopic ultrasound (EUS) images were characterized by a hypoechoic mass in the muscularis propria; C: Gastric stromal tumor (intermediate risk). The spindle of the tumor cells is arranged in a spindle and braided pattern with nuclear division of approximately 8/50 high power field. Immunohistochemistry: CD117 (+); CD34 (-); Desmin (-); Dog1 (+); Ki-67 (10%+); smooth muscle actin (-); and S-100 (-); D: A lesion with a diameter of approximately 0.6 cm was observed in the gastric fundus using an endoscope; E: Strong echogenic foci and heterogeneity were observed as characteristics of EUS imaging; F: Gastric stromal tumor (very low risk). The spindle of the tumor cells is arranged in spindle and bundles without obvious nuclear division. Some tissues calcify. Immunohistochemistry: CD117 (+); CD34 (+); Desmin (-); Ki-67 (1%+); smooth muscle actin (+); and S-100 (-).



DOI: 10.3748/wjg.v28.i37.5457 Copyright ©The Author(s) 2022.

Figure 3 Receiver operating characteristic curve. A: The receiver operating characteristic curve of the cut-off (1.48 cm); B: The optimal cut-off (1.48 cm) with a sensitivity of 0.875 and a specificity of 0.828. ROC: Receiver operating characteristic; AUC: Area under the curve.

treatment for histologically confirmed small GISTs[21]. Small GISTs are generally considered to have a low malignant potential, and few of them may progress to clinically relevant tumors. However, a population-based study reviewed 378 patients with small GISTs found that approximately 11.4% of small GISTs were accompanied by local progression or even distant metastasis when first diagnosed and claimed that small GISTs might progress and become life-threatening, with a mortality of 12% at 5 years[23]. Additionally, some scholars believe that the conservative observational methods for small GISTs can only evaluate whether the tumor diameter has increased, which will cause psychological

burden and risk to patients as clinicians would only passively wait for the tumor size to increase before performing surgical resection[24]. Therefore, it is critical to choose optimal approaches for accurately evaluating the clinical features and providing risk suggestions for small GISTs before their progression.

EUS has been recommended as an optimal method for the diagnosis and follow-up of small GISTs, while its efficacy in risk assessment of small GISTs is still not clear. The NCCN guidelines recommend that conservative follow-up should be performed in small GISTs lacking high-risk EUS features (marginal irregularity, cystic changes, ulcers, strong echo foci, and heterogeneity)[10]. Moreover, in recent years, many studies have shown that EUS can provide a preliminary basis for assessing the malignant potential of lesions. Palazzo *et al*[25] showed that EUS was reliable in predicting the malignant potential of GISTs, including three most predictive EUS features (one or more of the following: Irregular border, cystic changes, and lymph nodes with a malignant pattern) with a sensitivity of 91% and a specificity of 88%[25]. Jeon *et al*[26] found that the best predictor of high-risk GISTs was the combination of endoscopic and EUS features, including a tumor diameter > 3 cm, irregular border, mucosal ulceration, and a non-oval shape[26]. Concerning small GISTs, Gao *et al*[18] studied 69 patients suspected to have GISTs as indicated by EUS and concluded that the tumor size of > 9.5 mm was significantly correlated with tumor progression, which was of great value in predicting the malignant potential of the GISTs[18]. Wang *et al*[27] examined 648 cases of small GISTs and concluded that GISTs with a diameter of < 1.45 cm had an overall good prognosis; however, those with a diameter > 1.45 cm required intensive monitoring or had to undergo endoscopic surgery[27,28].

Our study enrolled a total of 256 patients who underwent ESD or EFTR during 2014–2019 in Shengjing Hospital including 248 very low- or low-risk cases and 8 intermediate/high-risk cases based on the modified NIH classification. We generated a ROC curve based on the potential malignancy predictor (mitoses more than 5/50 HPF) to determine the optimal cut-off value of tumor size. A tumor diameter of 1.48 cm was identified as the optimal cutoff value, with a sensitivity of 87.5%, a specificity of 82.8%, and an AUC of 0.89. Of all the 256 patients with small gastric GISTs included in our study, EUS features for malignancy prediction were studied retrospectively. Heterogeneous, hyperechoic foci, lobular border, and ulceration were detected in 67 (65.1%), 22 (8.6%), 1 (0.4%) and 2 (0.8%) patients, respectively. According to the optimal cut-off value, patients were subsequently divided into two groups: ≤ 1.48 cm and > 1.48 cm. We identified that tumors with a diameter > 1.48 cm were more likely to present positive EUS features ($P = 0.002$). To further identify whether positive EUS features can predict the malignant potential of small GISTs, we compared EUS features between the non-low- and low-risk groups. The results showed that there was a significant difference between the two groups regarding the heterogeneity, which might suggest that patients with GISTs experiencing this EUS feature should be followed-up more frequently while considering endoscopic surgery when regular follow-up is not feasible or EUS-guided tissue acquisition for pathological assessment. However, there was no statistical difference in hyperechoic foci and ulceration features between the two groups. We believed that limited cases with these two EUS features might have resulted in a partial evaluation. Therefore, a larger scale study is needed to further comprehensively evaluate the efficacy of EUS for the risk prediction of small GISTs.

Other studies have shown that contrast-enhanced harmonic EUS and EUS-elastography can distinguish GISTs from other submucosal tumors, but the risk grade of GISTs cannot be evaluated[14, 29]. Moreover, another study suggests that EUS-FNA/FNB can be used to obtain tissue for assessing the malignancy risk of tumors[30]. However, for small GISTs, the diagnostic rate of EUS-FNA is low, and due to the small size of the lesion and certain mobility limitations, puncturing the tumor is difficult and the possibility of obtaining sufficient samples is low[31,32]. A study of 53 patients[33] showed that the successful diagnostic rate of an adequate specimen was related to the lesion size: Only 71% of lesions measuring < 20 mm had complications led by repeated needle puncture[34,35]. In contrast, with the advance of endoscopic techniques, complete treatment has become possible *via* endoscopic surgery, such as ESD and EFTR. ESD is currently the most widely used endoscopic treatment for resecting GISTs. Studies have shown that ESD is safe and effective for treating GISTs that originate from the muscularis propria layer, with a diameter ≤ 3 cm and without extra-gastrointestinal invasion or abdominal metastasis[36–38]. The main adverse events of this technique are bleeding and perforation[39,40]. EFTR is mainly suitable for patients whose lesions are located in the deep muscularis propria layer and are closely connected to the serosal layer, in which metal clips, OTSCs, and other methods are used for rapid closure of defects to prevent pneumoperitoneum and peritonitis. In this study, only one patient treated with endoscopy developed delayed bleeding; however, the patient recovered well after endoscopic hemostasis was performed. Furthermore, all patients who underwent endoscopic resection had no recurrence or metastasis during a mean follow-up period of 40 mo (range, 15–72 mo), suggesting that endoscopic surgery is feasible and safe for small GISTs.

This study had a few limitations. First, the results of this retrospective study may be affected by selection bias. Second, the follow-up period was relatively short, which may result in missing cases of recurrence. Third, limited samples may affect the comprehensive evaluation of positive EUS features for risk classification. Therefore, multicenter randomized controlled trials should be conducted in the future to enhance the robustness of these conclusions.

CONCLUSION

In conclusion, partial EUS features, such as heterogeneity, can be applied to predict higher-risk small GISTs with a diameter > 1.48 cm. These tumors with diameters > 1.48 cm should undergo more intensive surveillance. Endoscopic surgery should be strongly recommended for small GISTs if regular follow-up is infeasible for low recurrence rate and metastatic rate.

ARTICLE HIGHLIGHTS

Research background

Small gastrointestinal stromal tumors (GISTs) have a high incidence, and their prognosis and treatment remain controversial.

Research motivation

Endoscopic ultrasound (EUS) plays a pivotal role in the diagnosis of GISTs, but its ability to assess the prognosis of small GISTs remains to be explored.

Research objectives

To evaluate the efficacy of EUS in the diagnosis and risk assessment of small GISTs.

Research methods

We collected data from patients with small GISTs, the diagnosis and risk classifications of which were based on the pathological assessment according to the modified National Institute of Health criteria after endoscopic resection or laparoscopic surgery. The assessment results based on EUS features (marginal irregularity, cystic changes, homogeneity, ulceration, and strong echogenic foci) were compared with the pathological features.

Research results

A total of 256 patients (69 men and 187 women) were enrolled. Tumor size was positively correlated with the mitotic index ($P < 0.001$). Receiver operating curve analysis identified 1.48 cm as the best cut-off value to predict malignant potential (95% confidence interval: 0.824–0.956). EUS heterogeneity with tumor diameters > 1.48 cm was associated with higher risk classification ($P < 0.05$).

Research conclusions

Small GISTs (diameters, > 1.48 cm) with positive EUS features should receive intensive surveillance or undergo endoscopic surgery. EUS and dissection are efficient diagnostic and therapeutic approaches for small GISTs.

Research perspectives

EUS provides reference evidence for the precise assessment and early risk assessment of small GISTs.

ACKNOWLEDGEMENTS

We thank Professor Si-Yu Sun, for his support and guidance during this study. We also thank all other doctors who participated in this study.

FOOTNOTES

Author contributions: Ge QC wrote a majority portion of manuscript, prepared the figures and tables, and performed statistical analysis; Wu YF collected the data of patients; Liu ZM helped with the statistical analysis and manuscript writing; Wang Z provided and confirmed the pathological data of all the patients; Wang S, Liu X, and Ge N took part in the design of the study outline and performed tumor dissection; Guo JT and Sun SY were responsible for the revision of the manuscript for important intellectual content and supervised the study; all the authors read and gave their final approval for the manuscript to be submitted.

Supported by National Natural Science Foundation of China, No. 81900601; The University Innovation Team and Innovative Talent Support Program of Liaoning Province, No. LR2019073; and Shenyang Young and Middle-aged Science and Technology Innovation Talent Support Program, No. RC200438.

Institutional review board statement: This study was approved by the Ethics Review Committee of Shengjing

Hospital of China Medical University, No. 2022PS009K.

Informed consent statement: All the individual involved gave their informed consent prior to study inclusion.

Conflict-of-interest statement: All the authors report no relevant conflicts of interest for this article.

Data sharing statement: No additional data are available.

Open-Access: This article is an open-access article that was selected by an in-house editor and fully peer-reviewed by external reviewers. It is distributed in accordance with the Creative Commons Attribution NonCommercial (CC BY-NC 4.0) license, which permits others to distribute, remix, adapt, build upon this work non-commercially, and license their derivative works on different terms, provided the original work is properly cited and the use is non-commercial. See: <https://creativecommons.org/licenses/by-nc/4.0/>

Country/Territory of origin: China

ORCID number: Qi-Chao Ge 0000-0003-3412-2033; Yu-Fan Wu 0000-0003-4290-8263; Zi-Ming Liu 0000-0001-6123-4466; Zhe Wang 0000-0003-1877-826X; Sheng Wang 0000-0002-1531-7655; Nan Ge 0000-0002-5764-7054; Jin-Tao Guo 0000-0001-5722-6359; Si-Yu Sun 0000-0002-7308-0473.

S-Editor: Fan JR

L-Editor: A

P-Editor: Fan JR

REFERENCES

- 1 Di Vita M, Zanghi A, Cavallaro A, Cardi F, Uhlig M, Ursi P, Lo Menzo E, Panebianco V, Cappellani A. Gastric GIST and prognostic models. Which is the best to predict survival after surgery? *Ann Ital Chir* 2019; **90**: 31-40 [PMID: 30942768]
- 2 Xu C, Han H, Wang J, Zhang B, Shao Y, Zhang L, Wang H, Wu Y, Li X, Li R, Tian Y. Diagnosis value of CD117 and PDGFRA, alone or in combination DOG1, as biomarkers for gastrointestinal stromal tumors. *Ann Transl Med* 2015; **3**: 308 [PMID: 26697468 DOI: 10.3978/j.issn.2305-5839.2015.10.07]
- 3 Soreide K, Sandvik OM, Soreide JA, Giljaca V, Jureckova A, Bulusu VR. Global epidemiology of gastrointestinal stromal tumours (GIST): A systematic review of population-based cohort studies. *Cancer Epidemiol* 2016; **40**: 39-46 [PMID: 26618334 DOI: 10.1016/j.canep.2015.10.031]
- 4 Wang M, Xu J, Zhang Y, Tu L, Qiu WQ, Wang CJ, Shen YY, Liu Q, Cao H. Gastrointestinal stromal tumor: 15-years' experience in a single center. *BMC Surg* 2014; **14**: 93 [PMID: 25403624 DOI: 10.1186/1471-2482-14-93]
- 5 Corless CL, Barnett CM, Heinrich MC. Gastrointestinal stromal tumours: origin and molecular oncology. *Nat Rev Cancer* 2011; **11**: 865-878 [PMID: 22089421 DOI: 10.1038/nrc3143]
- 6 Hirota S, Isozaki K, Moriyama Y, Hashimoto K, Nishida T, Ishiguro S, Kawano K, Hanada M, Kurata A, Takeda M, Muhammad Tunio G, Matsuzawa Y, Kanakura Y, Shinomura Y, Kitamura Y. Gain-of-function mutations of c-kit in human gastrointestinal stromal tumors. *Science* 1998; **279**: 577-580 [PMID: 9438854 DOI: 10.1126/science.279.5350.577]
- 7 Murphey MD. World Health Organization classification of bone and soft tissue tumors: modifications and implications for radiologists. *Semin Musculoskelet Radiol* 2007; **11**: 201-214 [PMID: 18260031 DOI: 10.1055/s-2008-1038310]
- 8 Fletcher CD, Berman JJ, Corless C, Gorstein F, Lasota J, Longley BJ, Miettinen M, O'Leary TJ, Remotti H, Rubin BP, Shmookler B, Sobin LH, Weiss SW. Diagnosis of gastrointestinal stromal tumors: A consensus approach. *Hum Pathol* 2002; **33**: 459-465 [PMID: 12094370 DOI: 10.1053/hupa.2002.123545]
- 9 Demetri GD, von Mehren M, Antonescu CR, DeMatteo RP, Ganjoo KN, Maki RG, Pisters PW, Raut CP, Riedel RF, Schuetze S, Sundar HM, Trent JC, Wayne JD. NCCN Task Force report: update on the management of patients with gastrointestinal stromal tumors. *J Natl Compr Canc Netw* 2010; **8** Suppl 2: S1-41; quiz S42 [PMID: 20457867 DOI: 10.6004/jnccn.2010.0116]
- 10 von Mehren M, Randall RL, Benjamin RS, Boles S, Bui MM, Ganjoo KN, George S, Gonzalez RJ, Heslin MJ, Kane JM, Keedy V, Kim E, Koon H, Mayerson J, McCarter M, McGarry SV, Meyer C, Morris ZS, O'Donnell RJ, Pappo AS, Paz IB, Petersen IA, Pfeifer JD, Riedel RF, Ruo B, Schuetze S, Tap WD, Wayne JD, Bergman MA, Scavone JL. Soft Tissue Sarcoma, Version 2.2018, NCCN Clinical Practice Guidelines in Oncology. *J Natl Compr Canc Netw* 2018; **16**: 536-563 [PMID: 29752328 DOI: 10.6004/jnccn.2018.0025]
- 11 ESMO/European Sarcoma Network Working Group. Gastrointestinal stromal tumours: ESMO Clinical Practice Guidelines for diagnosis, treatment and follow-up. *Ann Oncol* 2014; **25** Suppl 3: iii21-iii26 [PMID: 25210085 DOI: 10.1093/annonc/mdl255]
- 12 Li J, Ye Y, Wang J, Zhang B, Qin S, Shi Y, He Y, Liang X, Liu X, Zhou Y, Wu X, Zhang X, Wang M, Gao Z, Lin T, Cao H, Shen L; Chinese Society Of Clinical Oncology CSCO Expert Committee On Gastrointestinal Stromal Tumor. Chinese consensus guidelines for diagnosis and management of gastrointestinal stromal tumor. *Chin J Cancer Res* 2017; **29**: 281-293 [PMID: 28947860 DOI: 10.21147/j.issn.1000-9604.2017.04.01]
- 13 Hu J, Ge N, Wang S, Liu X, Guo J, Wang G, Sun S. The Role of Endoscopic Ultrasound and Endoscopic Resection for Gastric Glomus: A Case Series and Literature Review. *J Transl Int Med* 2019; **7**: 149-154 [PMID: 32010601 DOI: 10.2478/jtim-2019-0030]
- 14 Kovacevic B, Vilman P. EUS tissue acquisition: From A to B. *Endosc Ultrasound* 2020; **9**: 225-231 [PMID: 32655082]

- DOI: [10.4103/eus.eus_21_20](https://doi.org/10.4103/eus.eus_21_20)]
- 15 **Fabbri C**, Fornelli A, Fuccio L, Giovanelli S, Tarantino I, Antonini F, Liotta R, Frazzoni L, Gusella P, La Marca M, Barresi L, Macarri G, Traina M, De Biase D, Fiorino S, Jovine E, Larghi A, Cennamo V. High diagnostic adequacy and accuracy of the new 20G procure needle for EUS-guided tissue acquisition: Results of a large multicentre retrospective study. *Endosc Ultrasound* 2019; **8**: 261-268 [PMID: [31115386](https://pubmed.ncbi.nlm.nih.gov/31115386/) DOI: [10.4103/eus.eus_14_19](https://doi.org/10.4103/eus.eus_14_19)]
 - 16 **Ang TL**, Li JW, Kwek ABE, Thurairajah PH, Wang LM. The difference in histological yield between 19G EUS-FNA and EUS-fine-needle biopsy needles. *Endosc Ultrasound* 2019; **8**: 255-260 [PMID: [31115385](https://pubmed.ncbi.nlm.nih.gov/31115385/) DOI: [10.4103/eus.eus_12_19](https://doi.org/10.4103/eus.eus_12_19)]
 - 17 **Săftoiu A**, Vilmann P, Ciurea T. Utility of endoscopic ultrasound for the diagnosis and treatment of submucosal tumors of the upper gastrointestinal tract. *Rom J Gastroenterol* 2003; **12**: 215-229 [PMID: [14502323](https://pubmed.ncbi.nlm.nih.gov/14502323/)]
 - 18 **Gao Z**, Wang C, Xue Q, Wang J, Shen Z, Jiang K, Shen K, Liang B, Yang X, Xie Q, Wang S, Ye Y. The cut-off value of tumor size and appropriate timing of follow-up for management of minimal EUS-suspected gastric gastrointestinal stromal tumors. *BMC Gastroenterol* 2017; **17**: 8 [PMID: [28077094](https://pubmed.ncbi.nlm.nih.gov/28077094/) DOI: [10.1186/s12876-016-0567-4](https://doi.org/10.1186/s12876-016-0567-4)]
 - 19 **Kim GH**, Kim KB, Lee SH, Jeon HK, Park DY, Jeon TY, Kim DH, Song GA. Digital image analysis of endoscopic ultrasonography is helpful in diagnosing gastric mesenchymal tumors. *BMC Gastroenterol* 2014; **14**: 7 [PMID: [24400772](https://pubmed.ncbi.nlm.nih.gov/24400772/) DOI: [10.1186/1471-230X-14-7](https://doi.org/10.1186/1471-230X-14-7)]
 - 20 **Kim HJ**, Lim SJ, Park K, Yuh YJ, Jang SJ, Choi J. Multiple gastrointestinal stromal tumors with a germline c-kit mutation. *Pathol Int* 2005; **55**: 655-659 [PMID: [16185297](https://pubmed.ncbi.nlm.nih.gov/16185297/) DOI: [10.1111/j.1440-1827.2005.01885.x](https://doi.org/10.1111/j.1440-1827.2005.01885.x)]
 - 21 **Sanborn RE**, Blanke CD. Gastrointestinal stromal tumors and the evolution of targeted therapy. *Clin Adv Hematol Oncol* 2005; **3**: 647-657 [PMID: [16167051](https://pubmed.ncbi.nlm.nih.gov/16167051/)]
 - 22 **Casali PG**, Abecassis N, Aro HT, Bauer S, Biagini R, Bielack S, Bonvalot S, Boukovinas I, Bovee JVMG, Brodowicz T, Broto JM, Buonadonna A, De Álava E, Dei Tos AP, Del Muro XG, Dileo P, Eriksson M, Fedenko A, Ferraresi V, Ferrari A, Ferrari S, Frezza AM, Gasperoni S, Gelderblom H, Gil T, Grignani G, Gronchi A, Haas RL, Hassan B, Hohenberger P, Issels R, Joensuu H, Jones RL, Judson I, Jutte P, Kaal S, Kasper B, Kopeckova K, Krákorová DA, Le Cesne A, Lugowska I, Merimsky O, Montemurro M, Pantaleo MA, Piana R, Picci P, Piperno-Neumann S, Pousa AL, Reichardt P, Robinson MH, Rutkowski P, Safwat AA, Schöffski P, Sleijfer S, Stacchiotti S, Sundby Hall K, Unk M, Van Coevorden F, van der Graaf WTA, Whelan J, Wardelmann E, Zaikova O, Blay JY; ESMO Guidelines Committee and EURACAN. Gastrointestinal stromal tumours: ESMO-EURACAN Clinical Practice Guidelines for diagnosis, treatment and follow-up. *Ann Oncol* 2018; **29**: iv68-iv78 [PMID: [29846513](https://pubmed.ncbi.nlm.nih.gov/29846513/) DOI: [10.1093/annonc/mdy095](https://doi.org/10.1093/annonc/mdy095)]
 - 23 **Coe TM**, Fero KE, Fanta PT, Mallory RJ, Tang CM, Murphy JD, Sicklick JK. Population-Based Epidemiology and Mortality of Small Malignant Gastrointestinal Stromal Tumors in the USA. *J Gastrointest Surg* 2016; **20**: 1132-1140 [PMID: [27025710](https://pubmed.ncbi.nlm.nih.gov/27025710/) DOI: [10.1007/s11605-016-3134-y](https://doi.org/10.1007/s11605-016-3134-y)]
 - 24 **Fang YJ**, Cheng TY, Sun MS, Yang CS, Chen JH, Liao WC, Wang HP. Suggested cutoff tumor size for management of small EUS-suspected gastric gastrointestinal stromal tumors. *J Formos Med Assoc* 2012; **111**: 88-93 [PMID: [22370287](https://pubmed.ncbi.nlm.nih.gov/22370287/) DOI: [10.1016/j.jfma.2011.01.002](https://doi.org/10.1016/j.jfma.2011.01.002)]
 - 25 **Palazzo L**, Landi B, Cellier C, Cuillerier E, Roseau G, Barbier JP. Endosonographic features predictive of benign and malignant gastrointestinal stromal cell tumours. *Gut* 2000; **46**: 88-92 [PMID: [10601061](https://pubmed.ncbi.nlm.nih.gov/10601061/) DOI: [10.1136/gut.46.1.88](https://doi.org/10.1136/gut.46.1.88)]
 - 26 **Jeon SW**, Park YD, Chung YJ, Cho CM, Tak WY, Kweon YO, Kim SK, Choi YH. Gastrointestinal stromal tumors of the stomach: endosonographic differentiation in relation to histological risk. *J Gastroenterol Hepatol* 2007; **22**: 2069-2075 [PMID: [18031362](https://pubmed.ncbi.nlm.nih.gov/18031362/) DOI: [10.1111/j.1440-1746.2006.04767.x](https://doi.org/10.1111/j.1440-1746.2006.04767.x)]
 - 27 **Wang M**, Xue A, Yuan W, Gao X, Fu M, Fang Y, Wang L, Shu P, Li H, Hou Y, Shen K, Sun Y, Qin X. Clinicopathological Features and Prognosis of Small Gastric Gastrointestinal Stromal Tumors (GISTs). *J Gastrointest Surg* 2019; **23**: 2136-2143 [PMID: [31012047](https://pubmed.ncbi.nlm.nih.gov/31012047/) DOI: [10.1007/s11605-018-04070-3](https://doi.org/10.1007/s11605-018-04070-3)]
 - 28 **Tsuji Y**, Kusano C, Gotoda T, Itokawa F, Fukuzawa M, Sofuni A, Matsubayashi J, Nagao T, Itoi T, Moriyasu F. Diagnostic potential of endoscopic ultrasonography-elastography for gastric submucosal tumors: A pilot study. *Dig Endosc* 2016; **28**: 173-178 [PMID: [26530730](https://pubmed.ncbi.nlm.nih.gov/26530730/) DOI: [10.1111/den.12569](https://doi.org/10.1111/den.12569)]
 - 29 **Pesenti C**, Bories E, Caillol F, Ratone JP, Godat S, Monges G, Poizat F, Raoul JL, Ries P, Giovannini M. Characterization of subepithelial lesions of the stomach and esophagus by contrast-enhanced EUS: A retrospective study. *Endosc Ultrasound* 2019; **8**: 43-49 [PMID: [30264741](https://pubmed.ncbi.nlm.nih.gov/30264741/) DOI: [10.4103/eus.eus_89_17](https://doi.org/10.4103/eus.eus_89_17)]
 - 30 **Kuwatani M**, Sakamoto N. Evolution and a promising role of EUS-FNA in gene and future analyses. *Endosc Ultrasound* 2020; **9**: 151-153 [PMID: [32584309](https://pubmed.ncbi.nlm.nih.gov/32584309/) DOI: [10.4103/eus.eus_29_20](https://doi.org/10.4103/eus.eus_29_20)]
 - 31 **Okubo K**, Yamao K, Nakamura T, Tajika M, Sawaki A, Hara K, Kawai H, Yamamura Y, Mochizuki Y, Koshikawa T, Inada K. Endoscopic ultrasound-guided fine-needle aspiration biopsy for the diagnosis of gastrointestinal stromal tumors in the stomach. *J Gastroenterol* 2004; **39**: 747-753 [PMID: [15338368](https://pubmed.ncbi.nlm.nih.gov/15338368/) DOI: [10.1007/s00535-004-1383-0](https://doi.org/10.1007/s00535-004-1383-0)]
 - 32 **Attila T**, Aydın Ö. Lesion size determines diagnostic yield of EUS-FNA with onsite cytopathologic evaluation for upper gastrointestinal subepithelial lesions. *Turk J Gastroenterol* 2018; **29**: 436-441 [PMID: [30249558](https://pubmed.ncbi.nlm.nih.gov/30249558/) DOI: [10.5152/tjg.2018.17876](https://doi.org/10.5152/tjg.2018.17876)]
 - 33 **Akahoshi K**, Sumida Y, Matsui N, Oya M, Akinaga R, Kubokawa M, Motomura Y, Honda K, Watanabe M, Nagaie T. Preoperative diagnosis of gastrointestinal stromal tumor by endoscopic ultrasound-guided fine needle aspiration. *World J Gastroenterol* 2007; **13**: 2077-2082 [PMID: [17465451](https://pubmed.ncbi.nlm.nih.gov/17465451/) DOI: [10.3748/wjg.v13.i14.2077](https://doi.org/10.3748/wjg.v13.i14.2077)]
 - 34 **Hunt GC**, Smith PP, Faigel DO. Yield of tissue sampling for submucosal lesions evaluated by EUS. *Gastrointest Endosc* 2003; **57**: 68-72 [PMID: [12518134](https://pubmed.ncbi.nlm.nih.gov/12518134/) DOI: [10.1067/mge.2003.34](https://doi.org/10.1067/mge.2003.34)]
 - 35 **Sepe PS**, Moparty B, Pitman MB, Saltzman JR, Brugge WR. EUS-guided FNA for the diagnosis of GI stromal cell tumors: sensitivity and cytologic yield. *Gastrointest Endosc* 2009; **70**: 254-261 [PMID: [19482280](https://pubmed.ncbi.nlm.nih.gov/19482280/) DOI: [10.1016/j.gie.2008.11.038](https://doi.org/10.1016/j.gie.2008.11.038)]
 - 36 **Levy MJ**, Jondal ML, Clain J, Wiersema MJ. Preliminary experience with an EUS-guided trucut biopsy needle compared with EUS-guided FNA. *Gastrointest Endosc* 2003; **57**: 101-106 [PMID: [12518144](https://pubmed.ncbi.nlm.nih.gov/12518144/) DOI: [10.1067/mge.2003.49](https://doi.org/10.1067/mge.2003.49)]
 - 37 **Bai J**, Wang Y, Guo H, Zhang P, Ling X, Zhao X. Endoscopic resection of small gastrointestinal stromal tumors. *Dig Dis Sci* 2010; **55**: 1950-1954 [PMID: [20204697](https://pubmed.ncbi.nlm.nih.gov/20204697/) DOI: [10.1007/s10620-010-1168-7](https://doi.org/10.1007/s10620-010-1168-7)]
 - 38 **Yu C**, Liao G, Fan C, Yu J, Nie X, Yang S, Bai J. Long-term outcomes of endoscopic resection of gastric GISTs. *Surg*

- Endosc* 2017; **31**: 4799-4804 [PMID: [28424911](#) DOI: [10.1007/s00464-017-5557-2](#)]
- 39 **Li B**, Chen T, Qi ZP, Yao LQ, Xu MD, Shi Q, Cai SL, Sun D, Zhou PH, Zhong YS. Efficacy and safety of endoscopic resection for small submucosal tumors originating from the muscularis propria layer in the gastric fundus. *Surg Endosc* 2019; **33**: 2553-2561 [PMID: [30478693](#) DOI: [10.1007/s00464-018-6549-6](#)]
- 40 **An W**, Sun PB, Gao J, Jiang F, Liu F, Chen J, Wang D, Li ZS, Shi XG. Endoscopic submucosal dissection for gastric gastrointestinal stromal tumors: a retrospective cohort study. *Surg Endosc* 2017; **31**: 4522-4531 [PMID: [28374257](#) DOI: [10.1007/s00464-017-5511-3](#)]



Published by **Baishideng Publishing Group Inc**
7041 Koll Center Parkway, Suite 160, Pleasanton, CA 94566, USA

Telephone: +1-925-3991568

E-mail: bpgoffice@wjgnet.com

Help Desk: <https://www.f6publishing.com/helpdesk>

<https://www.wjgnet.com>

