

World Journal of *Clinical Cases*

World J Clin Cases 2022 October 26; 10(30): 10823-11213



Contents

Thrice Monthly Volume 10 Number 30 October 26, 2022

REVIEW

- 10823** New insights into the interplay between intestinal flora and bile acids in inflammatory bowel disease
Zheng L
- 10840** Role of visfatin in obesity-induced insulin resistance
Abdalla MMI

MINIREVIEWS

- 10852** Hyperthermic intraperitoneal chemotherapy and colorectal cancer: From physiology to surgery
Ammerata G, Filippo R, Laface C, Memeo R, Solaini L, Cavaliere D, Navarra G, Ranieri G, Currò G, Ammendola M
- 10862** New-onset diabetes secondary to acute pancreatitis: An update
Yu XQ, Zhu Q
- 10867** Ketosis-prone diabetes mellitus: A phenotype that hospitalists need to understand
Boike S, Mir M, Rauf I, Jama AB, Sunesara S, Mushtaq H, Khedr A, Nitesh J, Surani S, Khan SA
- 10873** 2022 Monkeypox outbreak: Why is it a public health emergency of international concern? What can we do to control it?
Ren SY, Li J, Gao RD

ORIGINAL ARTICLE

Retrospective Cohort Study

- 10882** Clinical characteristics and prognosis of non-small cell lung cancer patients with liver metastasis: A population-based study
Wang JF, Lu HD, Wang Y, Zhang R, Li X, Wang S

Retrospective Study

- 10896** Prevalence and risk factors for *Candida* esophagitis among human immunodeficiency virus-negative individuals
Chen YH, Jao TM, Shiue YL, Feng IJ, Hsu PI
- 10906** Prognostic impact of number of examined lymph nodes on survival of patients with appendiceal neuroendocrine tumors
Du R, Xiao JW

Observational Study

- 10921** Clinical and epidemiological features of ulcerative colitis patients in Sardinia, Italy: Results from a multicenter study
Magri S, Demurtas M, Onidi MF, Picchio M, Elisei W, Marzo M, Miculan F, Manca R, Dore MP, Quarta Colosso BM, Cicu A, Cugia L, Carta M, Binaghi L, Usai P, Lai M, Chicco F, Fantini MC, Armuzzi A, Mocci G

- 10931** Clinical observation of laparoscopic cholecystectomy combined with endoscopic retrograde cholangiopancreatography or common bile duct lithotripsy

Niu H, Liu F, Tian YB

Prospective Study

- 10939** Patient reported outcome measures in anterior cruciate ligament rupture and reconstruction: The significance of outcome score prediction

Al-Dadah O, Shepstone L, Donell ST

SYSTEMATIC REVIEWS

- 10956** Body mass index and outcomes of patients with cardiogenic shock: A systematic review and meta-analysis

Tao WX, Qian GY, Li HD, Su F, Wang Z

META-ANALYSIS

- 10967** Impact of being underweight on peri-operative and post-operative outcomes of total knee or hip arthroplasty: A meta-analysis

Ma YP, Shen Q

- 10984** Branched-chain amino acids supplementation has beneficial effects on the progression of liver cirrhosis: A meta-analysis

Du JY, Shu L, Zhou YT, Zhang L

CASE REPORT

- 10997** Wells' syndrome possibly caused by hematologic malignancy, influenza vaccination or ibrutinib: A case report

Šajin M, Luzar B, Zver S

- 11004** Giant cutaneous squamous cell carcinoma of the popliteal fossa skin: A case report

Wang K, Li Z, Chao SW, Wu XW

- 11010** Right time to detect urine iodine during papillary thyroid carcinoma diagnosis and treatment: A case report

Zhang SC, Yan CJ, Li YF, Cui T, Shen MP, Zhang JX

- 11016** Two novel mutations in the *VPS33B* gene in a Chinese patient with arthrogryposis, renal dysfunction and cholestasis syndrome 1: A case report

Yang H, Lin SZ, Guan SH, Wang WQ, Li JY, Yang GD, Zhang SL

- 11023** Effect of electroacupuncture for Pisa syndrome in Parkinson's disease: A case report

Lu WJ, Fan JQ, Yan MY, Mukaeda K, Zhuang LX, Wang LL

- 11031** Neonatal Cri du chat syndrome with atypical facial appearance: A case report

Bai MM, Li W, Meng L, Sang YF, Cui YJ, Feng HY, Zong ZT, Zhang HB

- 11037** Complete colonic duplication presenting as hip fistula in an adult with pelvic malformation: A case report

Cai X, Bi JT, Zheng ZX, Liu YQ

- 11044** Autoimmune encephalitis with posterior reversible encephalopathy syndrome: A case report
Dai SJ, Yu QJ, Zhu XY, Shang QZ, Qu JB, Ai QL
- 11049** Hypophysitis induced by anti-programmed cell death protein 1 immunotherapy in non-small cell lung cancer: Three case reports
Zheng Y, Zhu CY, Lin J, Chen WS, Wang YJ, Fu HY, Zhao Q
- 11059** Different intraoperative decisions for undiagnosed paraganglioma: Two case reports
Kang D, Kim BE, Hong M, Kim J, Jeong S, Lee S
- 11066** Hepatic steatosis with mass effect: A case report
Hu N, Su SJ, Li JY, Zhao H, Liu SF, Wang LS, Gong RZ, Li CT
- 11074** Bone marrow metastatic neuroendocrine carcinoma with unknown primary site: A case report and review of the literature
Shi XB, Deng WX, Jin FX
- 11082** Child with adenylosuccinate lyase deficiency caused by a novel complex heterozygous mutation in the ADSL gene: A case report
Wang XC, Wang T, Liu RH, Jiang Y, Chen DD, Wang XY, Kong QX
- 11090** Recovery of brachial plexus injury after bronchopleural fistula closure surgery based on electrodiagnostic study: A case report and review of literature
Go YI, Kim DS, Kim GW, Won YH, Park SH, Ko MH, Seo JH
- 11101** Severe *Klebsiella pneumoniae* pneumonia complicated by acute intra-abdominal multiple arterial thrombosis and bacterial embolism: A case report
Bao XL, Tang N, Wang YZ
- 11111** Spontaneous bilateral femur neck fracture secondary to grand mal seizure: A case report
Senocak E
- 11116** Favorable response after radiation therapy for intraductal papillary mucinous neoplasms manifesting as acute recurrent pancreatitis: A case report
Harigai A, Kume K, Takahashi N, Omata S, Umezawa R, Jingu K, Masamune A
- 11122** Acute respiratory distress syndrome following multiple wasp stings treated with extracorporeal membrane oxygenation: A case report
Cai ZY, Xu BP, Zhang WH, Peng HW, Xu Q, Yu HB, Chu QG, Zhou SS
- 11128** Morphological and electrophysiological changes of retina after different light damage in three patients: Three case reports
Zhang X, Luo T, Mou YR, Jiang W, Wu Y, Liu H, Ren YM, Long P, Han F
- 11139** Perirectal epidermoid cyst in a patient with sacroccygeal scoliosis and anal sinus: A case report
Ji ZX, Yan S, Gao XC, Lin LF, Li Q, Yao Q, Wang D

- 11146** Synchronous gastric cancer complicated with chronic myeloid leukemia (multiple primary cancers): A case report
Zhao YX, Yang Z, Ma LB, Dang JY, Wang HY
- 11155** Giant struma ovarii with pseudo-Meigs's syndrome and raised cancer antigen-125 levels: A case report
Liu Y, Tang GY, Liu L, Sun HM, Zhu HY
- 11162** Longest survival with primary intracranial malignant melanoma: A case report and literature review
Wong TF, Chen YS, Zhang XH, Hu WM, Zhang XS, Lv YC, Huang DC, Deng ML, Chen ZP
- 11172** Spontaneous remission of hepatic myelopathy in a patient with alcoholic cirrhosis: A case report
Chang CY, Liu C, Duan FF, Zhai H, Song SS, Yang S
- 11178** Cauda equina syndrome caused by the application of DuraSeal™ in a microlaminectomy surgery: A case report
Yeh KL, Wu SH, Fuh CS, Huang YH, Chen CS, Wu SS
- 11185** Bioceramics utilization for the repair of internal resorption of the root: A case report
Riyahi AM
- 11190** Fibrous hamartoma of infancy with bone destruction of the tibia: A case report
Qiao YJ, Yang WB, Chang YF, Zhang HQ, Yu XY, Zhou SH, Yang YY, Zhang LD
- 11198** Accidental esophageal intubation *via* a large type C congenital tracheoesophageal fistula: A case report
Hwang SM, Kim MJ, Kim S, Kim S
- 11204** Ventral hernia after high-intensity focused ultrasound ablation for uterine fibroids treatment: A case report
Park JW, Choi HY

LETTER TO THE EDITOR

- 11210** C-Reactive protein role in assessing COVID-19 deceased geriatrics and survivors of severe and critical illness
Nori W

ABOUT COVER

Editorial Board Member of *World Journal of Clinical Cases*, Rajeev Gurunath Redkar, FRCS, FRCS (Ed), FRCS (Gen Surg), MBBS, MCh, MS, Dean, Professor, Surgeon, Department of Pediatric Surgery, Lilavati Hospital and Research Centre, Mumbai 400050, Maharashtra, India. rajeev.redkar@gmail.com

AIMS AND SCOPE

The primary aim of *World Journal of Clinical Cases* (WJCC, *World J Clin Cases*) is to provide scholars and readers from various fields of clinical medicine with a platform to publish high-quality clinical research articles and communicate their research findings online.

WJCC mainly publishes articles reporting research results and findings obtained in the field of clinical medicine and covering a wide range of topics, including case control studies, retrospective cohort studies, retrospective studies, clinical trials studies, observational studies, prospective studies, randomized controlled trials, randomized clinical trials, systematic reviews, meta-analysis, and case reports.

INDEXING/ABSTRACTING

The WJCC is now abstracted and indexed in Science Citation Index Expanded (SCIE, also known as SciSearch®), Journal Citation Reports/Science Edition, Current Contents®/Clinical Medicine, PubMed, PubMed Central, Scopus, Reference Citation Analysis, China National Knowledge Infrastructure, China Science and Technology Journal Database, and Superstar Journals Database. The 2022 Edition of Journal Citation Reports® cites the 2021 impact factor (IF) for WJCC as 1.534; IF without journal self cites: 1.491; 5-year IF: 1.599; Journal Citation Indicator: 0.28; Ranking: 135 among 172 journals in medicine, general and internal; and Quartile category: Q4. The WJCC's CiteScore for 2021 is 1.2 and Scopus CiteScore rank 2021: General Medicine is 443/826.

RESPONSIBLE EDITORS FOR THIS ISSUE

Production Editor: *Ying-Yi Yuan*; Production Department Director: *Xu Guo*; Editorial Office Director: *Jin-Lei Wang*.

NAME OF JOURNAL

World Journal of Clinical Cases

ISSN

ISSN 2307-8960 (online)

LAUNCH DATE

April 16, 2013

FREQUENCY

Thrice Monthly

EDITORS-IN-CHIEF

Bao-Gan Peng, Jerzy Tadeusz Chudek, George Kontogeorgos, Maurizio Serati, Ja Hyeon Ku

EDITORIAL BOARD MEMBERS

<https://www.wjgnet.com/2307-8960/editorialboard.htm>

PUBLICATION DATE

October 26, 2022

COPYRIGHT

© 2022 Baishideng Publishing Group Inc

INSTRUCTIONS TO AUTHORS

<https://www.wjgnet.com/bpg/gerinfo/204>

GUIDELINES FOR ETHICS DOCUMENTS

<https://www.wjgnet.com/bpg/GerInfo/287>

GUIDELINES FOR NON-NATIVE SPEAKERS OF ENGLISH

<https://www.wjgnet.com/bpg/gerinfo/240>

PUBLICATION ETHICS

<https://www.wjgnet.com/bpg/GerInfo/288>

PUBLICATION MISCONDUCT

<https://www.wjgnet.com/bpg/gerinfo/208>

ARTICLE PROCESSING CHARGE

<https://www.wjgnet.com/bpg/gerinfo/242>

STEPS FOR SUBMITTING MANUSCRIPTS

<https://www.wjgnet.com/bpg/GerInfo/239>

ONLINE SUBMISSION

<https://www.f6publishing.com>



Spontaneous bilateral femur neck fracture secondary to grand mal seizure: A case report

Eyup Senocak

Specialty type: Orthopedics

Provenance and peer review:

Unsolicited article; Externally peer reviewed.

Peer-review model: Single blind

Peer-review report's scientific quality classification

Grade A (Excellent): 0

Grade B (Very good): 0

Grade C (Good): C, C

Grade D (Fair): 0

Grade E (Poor): 0

P-Reviewer: Beran RG, Australia;

Liu J, United States

Received: June 4, 2022

Peer-review started: June 4, 2022

First decision: July 29, 2022

Revised: July 29, 2022

Accepted: September 20, 2022

Article in press: September 20, 2022

Published online: October 26, 2022



Eyup Senocak, Department of Orthopedics and Traumatology, Erzurum City Hospital, Erzurum 25144, Turkey

Corresponding author: Eyup Senocak, MD, Doctor, Department of Orthopedics and Traumatology, Erzurum City Hospital, Catyolu Caddesi Erzurum Sehir Hastanesi Ortopedi Klinigi, Erzurum 25144, Turkey. eyupsenocakmd@gmail.com

Abstract

BACKGROUND

Spontaneous bilateral femur neck fracture is a rare entity in the general population.

CASE SUMMARY

A 17-year-old immobile, developmentally delayed male with the sequelae of cerebral palsy fractured both femoral necks during a grand mal epileptic seizure. He had been treated with valproic acid as an antiseizure medication for about 10 years; otherwise, he had no history of drug use. The laboratory analysis was normal except a marked vitamin D deficiency. Closed reduction and osteosynthesis with percutaneous cannulated screws were performed. Solid union was observed at 6 mo, and rapid postoperative rehabilitation was started.

CONCLUSION

A femoral neck fracture may occur in a person with epilepsy presenting with hip pain in the emergency department.

Key Words: Grand mal seizure; Bilateral femur neck fracture; Antiepileptic drugs; Immobile patient; Valproic acid use; Spontan fracture; Case report

©The Author(s) 2022. Published by Baishideng Publishing Group Inc. All rights reserved.

Core Tip: Spontaneous bilateral femoral neck fracture is a very rare entity and may develop in association with metabolic diseases, bone diseases, high-energy traumas, and epileptic seizures. It should be predicted that complications such as nonunion, loss of reduction, and avascular necrosis may develop secondary to these fractures, which are theoretically considered to be associated with metabolic diseases.

Citation: Senocak E. Spontaneous bilateral femur neck fracture secondary to grand mal seizure: A case report. *World J Clin Cases* 2022; 10(30): 11111-11115
URL: <https://www.wjgnet.com/2307-8960/full/v10/i30/11111.htm>
DOI: <https://dx.doi.org/10.12998/wjcc.v10.i30.11111>

INTRODUCTION

Femoral neck fractures in young patients account for approximately 3% of all femoral neck fractures and are usually secondary to high-energy trauma[1,2]. Spontaneous bilateral femoral neck fracture is very rare and may occur in association with metabolic or bone diseases, high-energy trauma, and epileptic seizures[3]. Complications of these fractures include nonunion, loss of reduction, and avascular necrosis, which are potentially associated with metabolic diseases. Early anatomical reduction, fixation, and rehabilitation are the primary goals. Spontaneous bilateral femoral neck fractures have been rarely reported[4,5].

CASE PRESENTATION

Chief complaints

A 17-year-old developmentally delayed immobile male with epilepsy as a sequela of cerebral palsy was brought to the emergency service due to pain in both hips after a sudden generalized tonic-clonic seizure 3 d previously.

History of present illness

The patient had pain in both hips after a sudden generalized tonic-clonic seizure 3 d previously, as reported by his family (Figure 1).

History of past illness

The patient had epilepsy as a sequela of cerebral palsy, and he had been treated with the antiseizure medication valproic acid for 10 years.

Personal and family history

The patient had no history of drug use other than valproic acid.

Physical examination

On physical examination, both lower extremities were in external rotation and there was pain and tenderness with movement.

Laboratory examinations

The patient's vitamin D level was relatively low (9 nmol/L), because he lacked sun exposure due to immobility (Table 1).

Imaging examinations

The patient had bilateral femur subcapital Garden type 4 fracture as revealed by a direct pelvis antero-posterior radiograph (Figure 1A).

FINAL DIAGNOSIS

The patient was diagnosed as having bilateral Garden type 4 femur neck fracture secondary to a grand mal seizure.

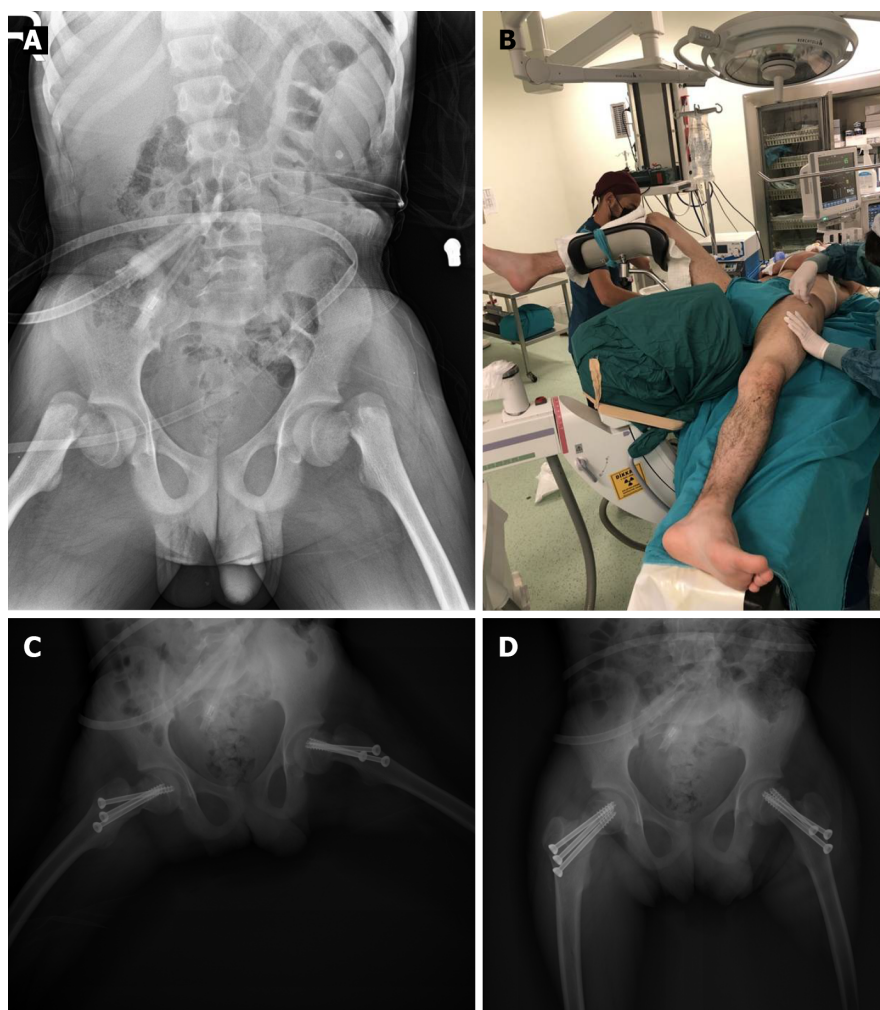
TREATMENT

Both hips were reduced anatomically and fixed with three 6.5-mm titanium cannulated screws. The hip joint capsules were not opened during surgery. Acceptable reduction and fixation were confirmed in the anteroposterior and lateral planes in the postoperative radiographs (Figure 1C and D).

Table 1 Preoperative biochemical blood values of the patient

	Value	Referans value
Ca	9.9 nmol/L	8.6 nmol/L-10.2 nmol/L
ALP	91 nmol/L	46 nmol/L-116 nmol/L
P	4.3 nmol/L	2.4 nmol/L-5.1 nmol/L
PTH	45 nmol/L	38 nmol/L-78 nmol/L
25-OH D VİT	9 nmol/L	20 nmol/L-60 nmol/L
Mg	2.1 nmol/L	1.6 nmol/L-2.6 nmol/L

ALP: Alkaline phosphatase.



DOI: 10.12998/wjcc.v10.i30.11111 Copyright ©The Author(s) 2022.

Figure 1 Images. A: Preoperative anteroposterior radiographic view of bilateral femur neck fracture of the patient; B: The patient's surgery position; C and D: Postoperative anteroposterior and frog leg radiographic view of the patient.

OUTCOME AND FOLLOW-UP

A rapid rehabilitation program was initiated to prevent hip stiffness in the patient, who was normally immobile. After a neurology consultation, the antiseizure treatment was revised due to the potential osteoporotic effect of valproic acid. Maintenance treatment was started with phenytoin, which is a less osteolytic agent. Since his hormone levels were normal according to an endocrinology consultation, only vitamin D replacement therapy was started (Table 1).

DISCUSSION

We present a 17-year-old immobile patient who took antiseizure medication and fractured both femoral necks during an epileptic seizure. Spontaneous bilateral femoral neck fractures are extremely rare. All reported cases were secondary to high-energy trauma, epileptic seizures, electric shock, and bone metabolism disorders[4,6,7]. Several cases of bilateral femoral neck fracture secondary to epileptic seizures have been reported[8-10]. It is thought that the rigid shear force between the femoral shaft and neck, together with the sudden muscle contractions secondary to the seizure, cause the fractures[11]. Our case suggested that the femoral neck fractures resulted from the strong tonic-clonic contractions that occurred despite the use of antiseizure medication. However, we think that the long-term use of valproic acid exacerbated the fractures by decreasing bone mineral density. Our patient's immobility promoted fracture development due to the associated decrease in bone quality.

Bilateral femoral neck fractures treated by total hip replacement have been reported in elderly patients[12,13]. Another study reported closed reduction and percutaneous screw fixation in a 30-year-old patient with bilateral femoral neck fractures after a hypoglycemic attack[14]. A 24-year-old Turkish patient with bilateral femoral neck fractures and osteopenia on postoperative bone densitometry was treated with closed reduction and percutaneous cannulated screws[5].

Since our patient was immobile, used antiseizure drugs, and had sequelae of cerebral palsy, we deemed it appropriate to perform closed reduction with three percutaneous cannulated screws after considering the patient's condition, as it is the least invasive rigid fixation and also protects the bone. The risk of avascular necrosis in femoral neck fractures is 12%-40% in Garden type 3-4 displaced fractures[15]. Our patient was brought to our clinic 3 d after the fracture and treated quickly. Callus formation was seen 6 mo postoperatively and there was no avascular necrosis. With regular rehabilitation, there were no problems with the hip movements.

CONCLUSION

As antiseizure medication may decrease bone density, bone densitometry should be performed regularly in cases with long-term use of these drugs. Although the fixation method varies by patient age and activity level, bone-sparing surgery is preferred in young patients. Patients with epilepsy who have dislocated shoulders should also be evaluated for femoral neck fractures.

FOOTNOTES

Author contributions: Senocak E contributed to the writing and data analysis.

Informed consent statement: Informed written consent was obtained from the patient for the publication of this report and any accompanying images.

Conflict-of-interest statement: The author has no conflict of interest to disclose.

CARE Checklist (2016) statement: The authors have read the CARE Checklist (2016), and the manuscript was prepared and revised according to the CARE Checklist (2016).

Open-Access: This article is an open-access article that was selected by an in-house editor and fully peer-reviewed by external reviewers. It is distributed in accordance with the Creative Commons Attribution NonCommercial (CC BY-NC 4.0) license, which permits others to distribute, remix, adapt, build upon this work non-commercially, and license their derivative works on different terms, provided the original work is properly cited and the use is non-commercial. See: <https://creativecommons.org/licenses/by-nc/4.0/>

Country/Territory of origin: Turkey

ORCID number: Eyup Senocak 0000-0002-9804-9309.

Corresponding Author's Membership in Professional Societies: TOTBID, No. 2323.

S-Editor: Chen YL

L-Editor: Wang TQ

P-Editor: Chen YL

REFERENCES

- 1 **Robinson CM**, Court-Brown CM, McQueen MM, Christie J. Hip fractures in adults younger than 50 years of age. Epidemiology and results. *Clin Orthop Relat Res* 1995; 238-246 [PMID: [7634609](#)]
- 2 **Askin SR**, Bryan R. Femoral neck fractures in young adults. *Clin Orthop Relat Res* 1976; **114**: 259-264 [DOI: [10.1097/00003086-197601000-00029](#)]
- 3 **Kalaci A**, Yanat AN, Sevinç TT, Doğramaci Y. Insufficiency fractures of both femoral necks in a young adult caused by osteoporosis: a case report. *Arch Orthop Trauma Surg* 2008; **128**: 865-868 [PMID: [18449548](#) DOI: [10.1007/s00402-008-0647-1](#)]
- 4 **Haronian E**, Silver JW, Mesa J. Simultaneous bilateral femoral neck fracture and greater tuberosity shoulder fracture resulting from seizure. *Orthopedics* 2002; **25**: 757-758 [PMID: [12138963](#) DOI: [10.3928/0147-7447-20020701-17](#)]
- 5 **Cagırmaz T**, Yapici C, Orak MM, Guler O. Bilateral femoral neck fractures after an epileptic attack: A case report. *Int J Surg Case Rep* 2015; **6C**: 107-110 [PMID: [25528038](#) DOI: [10.1016/j.ijscr.2014.12.003](#)]
- 6 **Yoon BH**, Kwon MS. Atraumatic Bilateral Fracture of the Femoral Neck in Young Male Patient with Suspected Osteomalacia. *J Bone Metab* 2017; **24**: 197-200 [PMID: [28955696](#) DOI: [10.11005/jbm.2017.24.3.197](#)]
- 7 **Nekkanti S**, C V, Js ST, R R, Raj S. An unusual case of simultaneous bilateral neck of femur fracture following electrocution injury-A case report and review of literature. *J Orthop Case Rep* 2016; **6**: 70-72 [PMID: [28116275](#) DOI: [10.13107/jocr.2250-0685.514](#)]
- 8 **Rahman MM**, Awada A. Bilateral simultaneous hip fractures secondary to an epileptic seizure. *Saudi Med J* 2003; **24**: 1261-1263 [PMID: [14647567](#)]
- 9 **Pappademos PC**, Hamilton WG. Bilateral displaced femoral neck fractures after myoclonic seizure treated with bilateral total hip arthroplasties. *Am J Orthop (Belle Mead NJ)* 2009; **38**: 88-89 [PMID: [19340371](#)]
- 10 **Grimaldi M**, Vouaillat H, Tonetti J, Merloz P. Simultaneous bilateral femoral neck fractures secondary to epileptic seizures: treatment by bilateral total hip arthroplasty. *Orthop Traumatol Surg Res* 2009; **95**: 555-557 [PMID: [19801211](#) DOI: [10.1016/j.otsr.2009.04.018](#)]
- 11 **Finelli PF**, Cardi JK. Seizure as a cause of fracture. *Neurology* 1989; **39**: 858-860 [PMID: [2725885](#) DOI: [10.1212/wnl.39.6.858](#)]
- 12 **Sood A**, Rao C, Holloway I. Bilateral femoral neck fractures in an adult male following minimal trauma after a simple mechanical fall: a case report. *Cases J* 2009; **2**: 92 [PMID: [19173750](#) DOI: [10.1186/1757-1626-2-92](#)]
- 13 **McGoldrick NP**, Dodds MK, Green C, Synnott K. Management of simultaneous bilateral neck of femur fractures in an elderly patient. *Geriatr Orthop Surg Rehabil* 2013; **4**: 71-73 [PMID: [24319617](#) DOI: [10.1177/2151458513511626](#)]
- 14 **M Shah H**, Grover A, Gadi D, Sudarshan K. Bilateral neck femur fracture following a generalized seizure- a rare case report. *Arch Bone Jt Surg* 2014; **2**: 255-257 [PMID: [25692154](#)]
- 15 **Kawasaki M**, Hasegawa Y, Sakano S, Sugiyama H, Tajima T, Iwasada S, Iwata H. Prediction of osteonecrosis by magnetic resonance imaging after femoral neck fractures. *Clin Orthop Relat Res* 2001; 157-164 [PMID: [11302307](#) DOI: [10.1097/00003086-200104000-00024](#)]



Published by **Baishideng Publishing Group Inc**
7041 Koll Center Parkway, Suite 160, Pleasanton, CA 94566, USA

Telephone: +1-925-3991568

E-mail: bpgoffice@wjgnet.com

Help Desk: <https://www.f6publishing.com/helpdesk>

<https://www.wjgnet.com>

