

World Journal of *Clinical Cases*

World J Clin Cases 2022 October 26; 10(30): 10823-11213



Contents

Thrice Monthly Volume 10 Number 30 October 26, 2022

REVIEW

- 10823** New insights into the interplay between intestinal flora and bile acids in inflammatory bowel disease
Zheng L
- 10840** Role of visfatin in obesity-induced insulin resistance
Abdalla MMI

MINIREVIEWS

- 10852** Hyperthermic intraperitoneal chemotherapy and colorectal cancer: From physiology to surgery
Ammerata G, Filippo R, Laface C, Memeo R, Solaini L, Cavaliere D, Navarra G, Ranieri G, Currò G, Ammendola M
- 10862** New-onset diabetes secondary to acute pancreatitis: An update
Yu XQ, Zhu Q
- 10867** Ketosis-prone diabetes mellitus: A phenotype that hospitalists need to understand
Boike S, Mir M, Rauf I, Jama AB, Sunesara S, Mushtaq H, Khedr A, Nitesh J, Surani S, Khan SA
- 10873** 2022 Monkeypox outbreak: Why is it a public health emergency of international concern? What can we do to control it?
Ren SY, Li J, Gao RD

ORIGINAL ARTICLE

Retrospective Cohort Study

- 10882** Clinical characteristics and prognosis of non-small cell lung cancer patients with liver metastasis: A population-based study
Wang JF, Lu HD, Wang Y, Zhang R, Li X, Wang S

Retrospective Study

- 10896** Prevalence and risk factors for *Candida* esophagitis among human immunodeficiency virus-negative individuals
Chen YH, Jao TM, Shiue YL, Feng IJ, Hsu PI
- 10906** Prognostic impact of number of examined lymph nodes on survival of patients with appendiceal neuroendocrine tumors
Du R, Xiao JW

Observational Study

- 10921** Clinical and epidemiological features of ulcerative colitis patients in Sardinia, Italy: Results from a multicenter study
Magrì S, Demurtas M, Onidi MF, Picchio M, Elisei W, Marzo M, Miculan F, Manca R, Dore MP, Quarta Colosso BM, Cicu A, Cugia L, Carta M, Binaghi L, Usai P, Lai M, Chicco F, Fantini MC, Armuzzi A, Mocci G

- 10931** Clinical observation of laparoscopic cholecystectomy combined with endoscopic retrograde cholangiopancreatography or common bile duct lithotripsy

Niu H, Liu F, Tian YB

Prospective Study

- 10939** Patient reported outcome measures in anterior cruciate ligament rupture and reconstruction: The significance of outcome score prediction

Al-Dadah O, Shepstone L, Donell ST

SYSTEMATIC REVIEWS

- 10956** Body mass index and outcomes of patients with cardiogenic shock: A systematic review and meta-analysis

Tao WX, Qian GY, Li HD, Su F, Wang Z

META-ANALYSIS

- 10967** Impact of being underweight on peri-operative and post-operative outcomes of total knee or hip arthroplasty: A meta-analysis

Ma YP, Shen Q

- 10984** Branched-chain amino acids supplementation has beneficial effects on the progression of liver cirrhosis: A meta-analysis

Du JY, Shu L, Zhou YT, Zhang L

CASE REPORT

- 10997** Wells' syndrome possibly caused by hematologic malignancy, influenza vaccination or ibrutinib: A case report

Šajin M, Luzar B, Zver S

- 11004** Giant cutaneous squamous cell carcinoma of the popliteal fossa skin: A case report

Wang K, Li Z, Chao SW, Wu XW

- 11010** Right time to detect urine iodine during papillary thyroid carcinoma diagnosis and treatment: A case report

Zhang SC, Yan CJ, Li YF, Cui T, Shen MP, Zhang JX

- 11016** Two novel mutations in the *VPS33B* gene in a Chinese patient with arthrogryposis, renal dysfunction and cholestasis syndrome 1: A case report

Yang H, Lin SZ, Guan SH, Wang WQ, Li JY, Yang GD, Zhang SL

- 11023** Effect of electroacupuncture for Pisa syndrome in Parkinson's disease: A case report

Lu WJ, Fan JQ, Yan MY, Mukaeda K, Zhuang LX, Wang LL

- 11031** Neonatal Cri du chat syndrome with atypical facial appearance: A case report

Bai MM, Li W, Meng L, Sang YF, Cui YJ, Feng HY, Zong ZT, Zhang HB

- 11037** Complete colonic duplication presenting as hip fistula in an adult with pelvic malformation: A case report

Cai X, Bi JT, Zheng ZX, Liu YQ

- 11044** Autoimmune encephalitis with posterior reversible encephalopathy syndrome: A case report
Dai SJ, Yu QJ, Zhu XY, Shang QZ, Qu JB, Ai QL
- 11049** Hypophysitis induced by anti-programmed cell death protein 1 immunotherapy in non-small cell lung cancer: Three case reports
Zheng Y, Zhu CY, Lin J, Chen WS, Wang YJ, Fu HY, Zhao Q
- 11059** Different intraoperative decisions for undiagnosed paraganglioma: Two case reports
Kang D, Kim BE, Hong M, Kim J, Jeong S, Lee S
- 11066** Hepatic steatosis with mass effect: A case report
Hu N, Su SJ, Li JY, Zhao H, Liu SF, Wang LS, Gong RZ, Li CT
- 11074** Bone marrow metastatic neuroendocrine carcinoma with unknown primary site: A case report and review of the literature
Shi XB, Deng WX, Jin FX
- 11082** Child with adenylosuccinate lyase deficiency caused by a novel complex heterozygous mutation in the ADSL gene: A case report
Wang XC, Wang T, Liu RH, Jiang Y, Chen DD, Wang XY, Kong QX
- 11090** Recovery of brachial plexus injury after bronchopleural fistula closure surgery based on electrodiagnostic study: A case report and review of literature
Go YI, Kim DS, Kim GW, Won YH, Park SH, Ko MH, Seo JH
- 11101** Severe *Klebsiella pneumoniae* pneumonia complicated by acute intra-abdominal multiple arterial thrombosis and bacterial embolism: A case report
Bao XL, Tang N, Wang YZ
- 11111** Spontaneous bilateral femur neck fracture secondary to grand mal seizure: A case report
Senocak E
- 11116** Favorable response after radiation therapy for intraductal papillary mucinous neoplasms manifesting as acute recurrent pancreatitis: A case report
Harigai A, Kume K, Takahashi N, Omata S, Umezawa R, Jingu K, Masamune A
- 11122** Acute respiratory distress syndrome following multiple wasp stings treated with extracorporeal membrane oxygenation: A case report
Cai ZY, Xu BP, Zhang WH, Peng HW, Xu Q, Yu HB, Chu QG, Zhou SS
- 11128** Morphological and electrophysiological changes of retina after different light damage in three patients: Three case reports
Zhang X, Luo T, Mou YR, Jiang W, Wu Y, Liu H, Ren YM, Long P, Han F
- 11139** Perirectal epidermoid cyst in a patient with sacroccygeal scoliosis and anal sinus: A case report
Ji ZX, Yan S, Gao XC, Lin LF, Li Q, Yao Q, Wang D

- 11146** Synchronous gastric cancer complicated with chronic myeloid leukemia (multiple primary cancers): A case report
Zhao YX, Yang Z, Ma LB, Dang JY, Wang HY
- 11155** Giant struma ovarii with pseudo-Meigs's syndrome and raised cancer antigen-125 levels: A case report
Liu Y, Tang GY, Liu L, Sun HM, Zhu HY
- 11162** Longest survival with primary intracranial malignant melanoma: A case report and literature review
Wong TF, Chen YS, Zhang XH, Hu WM, Zhang XS, Lv YC, Huang DC, Deng ML, Chen ZP
- 11172** Spontaneous remission of hepatic myelopathy in a patient with alcoholic cirrhosis: A case report
Chang CY, Liu C, Duan FF, Zhai H, Song SS, Yang S
- 11178** Cauda equina syndrome caused by the application of DuraSeal™ in a microlaminectomy surgery: A case report
Yeh KL, Wu SH, Fuh CS, Huang YH, Chen CS, Wu SS
- 11185** Bioceramics utilization for the repair of internal resorption of the root: A case report
Riyahi AM
- 11190** Fibrous hamartoma of infancy with bone destruction of the tibia: A case report
Qiao YJ, Yang WB, Chang YF, Zhang HQ, Yu XY, Zhou SH, Yang YY, Zhang LD
- 11198** Accidental esophageal intubation *via* a large type C congenital tracheoesophageal fistula: A case report
Hwang SM, Kim MJ, Kim S, Kim S
- 11204** Ventral hernia after high-intensity focused ultrasound ablation for uterine fibroids treatment: A case report
Park JW, Choi HY

LETTER TO THE EDITOR

- 11210** C-Reactive protein role in assessing COVID-19 deceased geriatrics and survivors of severe and critical illness
Nori W

ABOUT COVER

Editorial Board Member of *World Journal of Clinical Cases*, Rajeev Gurunath Redkar, FRCS, FRCS (Ed), FRCS (Gen Surg), MBBS, MCh, MS, Dean, Professor, Surgeon, Department of Pediatric Surgery, Lilavati Hospital and Research Centre, Mumbai 400050, Maharashtra, India. rajeev.redkar@gmail.com

AIMS AND SCOPE

The primary aim of *World Journal of Clinical Cases* (WJCC, *World J Clin Cases*) is to provide scholars and readers from various fields of clinical medicine with a platform to publish high-quality clinical research articles and communicate their research findings online.

WJCC mainly publishes articles reporting research results and findings obtained in the field of clinical medicine and covering a wide range of topics, including case control studies, retrospective cohort studies, retrospective studies, clinical trials studies, observational studies, prospective studies, randomized controlled trials, randomized clinical trials, systematic reviews, meta-analysis, and case reports.

INDEXING/ABSTRACTING

The WJCC is now abstracted and indexed in Science Citation Index Expanded (SCIE, also known as SciSearch®), Journal Citation Reports/Science Edition, Current Contents®/Clinical Medicine, PubMed, PubMed Central, Scopus, Reference Citation Analysis, China National Knowledge Infrastructure, China Science and Technology Journal Database, and Superstar Journals Database. The 2022 Edition of Journal Citation Reports® cites the 2021 impact factor (IF) for WJCC as 1.534; IF without journal self cites: 1.491; 5-year IF: 1.599; Journal Citation Indicator: 0.28; Ranking: 135 among 172 journals in medicine, general and internal; and Quartile category: Q4. The WJCC's CiteScore for 2021 is 1.2 and Scopus CiteScore rank 2021: General Medicine is 443/826.

RESPONSIBLE EDITORS FOR THIS ISSUE

Production Editor: *Ying-Yi Yuan*; Production Department Director: *Xu Guo*; Editorial Office Director: *Jin-Lei Wang*.

NAME OF JOURNAL

World Journal of Clinical Cases

ISSN

ISSN 2307-8960 (online)

LAUNCH DATE

April 16, 2013

FREQUENCY

Thrice Monthly

EDITORS-IN-CHIEF

Bao-Gan Peng, Jerzy Tadeusz Chudek, George Kontogeorgos, Maurizio Serati, Ja Hyeon Ku

EDITORIAL BOARD MEMBERS

<https://www.wjgnet.com/2307-8960/editorialboard.htm>

PUBLICATION DATE

October 26, 2022

COPYRIGHT

© 2022 Baishideng Publishing Group Inc

INSTRUCTIONS TO AUTHORS

<https://www.wjgnet.com/bpg/gerinfo/204>

GUIDELINES FOR ETHICS DOCUMENTS

<https://www.wjgnet.com/bpg/GerInfo/287>

GUIDELINES FOR NON-NATIVE SPEAKERS OF ENGLISH

<https://www.wjgnet.com/bpg/gerinfo/240>

PUBLICATION ETHICS

<https://www.wjgnet.com/bpg/GerInfo/288>

PUBLICATION MISCONDUCT

<https://www.wjgnet.com/bpg/gerinfo/208>

ARTICLE PROCESSING CHARGE

<https://www.wjgnet.com/bpg/gerinfo/242>

STEPS FOR SUBMITTING MANUSCRIPTS

<https://www.wjgnet.com/bpg/GerInfo/239>

ONLINE SUBMISSION

<https://www.f6publishing.com>



Longest survival with primary intracranial malignant melanoma: A case report and literature review

Tang-Fai Wong, Yin-Sheng Chen, Xiang-Heng Zhang, Wan-Ming Hu, Xiao-Shi Zhang, Yan-Chun Lv, Dong-Cun Huang, Mei-Ling Deng, Zhong-Ping Chen

Specialty type: Medicine, research and experimental

Provenance and peer review:

Unsolicited article; Externally peer reviewed.

Peer-review model: Single blind

Peer-review report's scientific quality classification

Grade A (Excellent): 0
Grade B (Very good): 0
Grade C (Good): C, C
Grade D (Fair): 0
Grade E (Poor): 0

P-Reviewer: He R, China;
Jabbarpour Z, Iran

Received: July 2, 2022

Peer-review started: July 2, 2022

First decision: August 1, 2022

Revised: August 10, 2022

Accepted: September 7, 2022

Article in press: September 7, 2022

Published online: October 26, 2022



Tang-Fai Wong, Department of Neurosurgery, Macao Kiang Wu Hospital, Macao 999078, Sichuan Province, China

Tang-Fai Wong, Yin-Sheng Chen, Xiang-Heng Zhang, Zhong-Ping Chen, Department of Neurosurgery/Neuro-Oncology, State Key Laboratory of Oncology in South China, Collaborative Innovation Center for Cancer Medicine, Sun Yat-Sen University Cancer Center, Guangzhou 510060, Guangdong Province, China

Wan-Ming Hu, Department of Pathology, State Key Laboratory of Oncology in South China, Collaborative Innovation Center for Cancer Medicine, Sun Yat-Sen University Cancer Center, Guangzhou 510060, Guangdong Province, China

Xiao-Shi Zhang, Department of Biotherapy, State Key Laboratory of Oncology in South China, Collaborative Innovation Center for Cancer Medicine, Sun Yat-Sen University Cancer Center, Guangzhou 510060, Guangdong Province, China

Yan-Chun Lv, Dong-Cun Huang, Department of Medical Imaging, Sun Yat-sen University Cancer Center, Collaborative Innovation Center for Cancer Medicine, Guangzhou 510060, Guangdong Province, China

Mei-Ling Deng, Department of Radiotherapy, State Key Laboratory of Oncology in South China, Collaborative Innovation Center for Cancer Medicine, Sun Yat-Sen University Cancer Center, Guangzhou 510060, Guangdong Province, China

Corresponding author: Zhong-Ping Chen, MD, PhD, Chief Doctor, Neurosurgeon, Professor, Department of Neurosurgery/Neuro-Oncology, State Key Laboratory of Oncology in South China, Collaborative Innovation Center for Cancer Medicine, Sun Yat-Sen University Cancer Center, No. 651 Dongfeng East Road, Yuexiu District, Guangzhou 510060, Guangdong Province, China. chenzhp@sysucc.org.cn

Abstract

BACKGROUND

Primary intracranial malignant melanoma (PIMM) is rare, and its prognosis is very poor. It is not clear what systematic treatment strategy can achieve long-term survival. This case study attempted to identify the optimal strategy for long-term survival outcomes by reviewing the PIMM patient with the longest survival following comprehensive treatment and by reviewing the related literature.

CASE SUMMARY

The patient is a 47-year-old Chinese man who suffered from dizziness and gait disturbance. He underwent surgery for right cerebellum melanoma and was subsequently diagnosed by pathology in June 2000. After the surgery, the patient received three cycles of chemotherapy but relapsed locally within 4 mo. Following the second surgery for total tumor resection, the patient received an injection of Newcastle disease virus-modified tumor vaccine, interferon, and β -elemene treatment. The patient was tumor-free with a normal life for 21 years before the onset of the recurrence of melanoma without any symptoms in July 2021. A third gross-total resection with adjuvant radiotherapy and temozolomide therapy was performed. Brain magnetic resonance imaging showed no residual tumor or recurrence 3 mo after the 3rd operation, and the patient recovered well without neurological dysfunction until the last follow-up in June 2022, which was 22 years following the initial treatment.

CONCLUSION

It is important for patients with PIMM to receive comprehensive treatment to enable the application of the most appropriate treatment strategies. Long-term survival is not impossible in patients with these malignancies.

Key Words: Primary intracranial malignant melanoma; Immunotherapy; Newcastle disease virus-modified tumor vaccine; β -elemene; Long-term survival; Case report

©The Author(s) 2022. Published by Baishideng Publishing Group Inc. All rights reserved.

Core Tip: Primary intracranial malignant melanoma (PIMM) is quite rare, and its prognosis is poor. Comprehensive treatment, including the surgical resection and the maintenance of postoperative adjuvant treatments by Newcastle disease virus-modified tumor vaccine, interferon, and β -elemene may prolong patient survival. We hope that the PIMM case reported in this paper, which describes a patient whose life was extended by 22 years, can provide useful information for the reference of medical practitioners and patients alike, thereby boosting their confidence in adopting the treatment reported herein.

Citation: Wong TF, Chen YS, Zhang XH, Hu WM, Zhang XS, Lv YC, Huang DC, Deng ML, Chen ZP. Longest survival with primary intracranial malignant melanoma: A case report and literature review. *World J Clin Cases* 2022; 10(30): 11162-11171

URL: <https://www.wjgnet.com/2307-8960/full/v10/i30/11162.htm>

DOI: <https://dx.doi.org/10.12998/wjcc.v10.i30.11162>

INTRODUCTION

Malignant melanoma (MM) is the most dangerous type of skin cancer. Melanoma accounts for approximately 10% of all patients who develop brain metastases. Approximately one-third of patients with newly diagnosed metastatic melanoma are estimated to have brain metastases[1]. Primary central nervous system (CNS) melanoma accounts for approximately 1% of all melanomas[2,3]. The diagnosis is very challenging. Three criteria have been proposed to diagnose primary CNS melanoma: (1) No melanoma on the skin or eyeball; (2) No surgery history of skin or eyeball melanoma; and (3) No metastatic melanoma in internal organs. Currently, it is believed that the source of primary CNS malignant melanoma may be the melanocytes of the pia mater. From a molecular point of view, the collision of the key structures of these cells leads to focal neurological symptoms, which in turn leads to the formation of malignant melanoma. This disease usually occurs in people under the age of 50, and there is no obvious sex difference. Generally, the disease course is short, and the survival period is usually several months to several years. The survival period is not significantly related to a patient's age. The diagnosis is usually confirmed by pathological biopsy of specimens obtained by surgery. The histopathology has the following characteristics: Tumor cells are of different sizes, most of which are larger than normal cells; the cells are polygonal in shape; the nuclei are round; the nucleoli are obvious; and most of them have obvious nuclear divisions. The cells are consistent with the appearance of malignant melanoma in other parts. In terms of immunohistochemistry, immunohistochemical markers specific to malignant melanoma include HMB45, S100, and SOX10. The positive rate is usually greater than 90%, which is a reliable basis for diagnosis[4]. In terms of treatment, surgical resection is the main treatment for CNS malignant melanoma. Removal of the tumor can prolong survival to a certain extent, but the overall prognosis is very poor. Due to the presence of the blood-brain barrier, chemotherapy

usually does not take effect. Radiotherapy can delay tumor recurrence, but it does not significantly help prolong the survival of patients. Therefore, it can be used but with little significance. Immunotherapy is only effective for metastatic malignant melanoma[5]. It has been reported recently that bevacizumab has a certain effect on patients with malignant melanoma brain metastases[6]. However, more treatment methods for primary CNS malignant melanoma still need to be developed.

CASE PRESENTATION

Chief complaints

A 47-year-old man visited our hospital for regular brain magnetic resonance imaging (MRI) follow-up after surgery to treat primary intracranial malignant melanoma (PIMM) 21 years ago.

History of present illness

All symptoms were denied, and clinical examination findings were negative. The regular brain MRI in July 2021 showed a mixed iso-/hyperdense mass in the right cerebellopontine angle (CPA) measuring 34 mm × 21 mm with a clear margin, so the recurrence of the melanoma was regarded as highly possible again. No melanoma was found on the skin or eyeball. Surgical treatment with gross-total resection (GTR) was arranged on August 12, 2021, which was the third operation.

History of past illness

In June 2000, the patient suffered from dizziness and gait disturbance. Brain MRI revealed a lesion in the right cerebellum, and surgical treatment was applied. Melanoma was diagnosed by histopathology examination. The patient received three cycles of adjuvant chemotherapy with dacarbazine 400 mg (d1-5), vindesine 4 mg (d1, d5), cisplatin 30 mg (d1-5), and interferon 3 µm subcutaneously 3 times a week. However, the tumor relapsed locally 4 mo after the operation (Figure 1). The patient received a second surgical treatment in October 2000. Histopathology examination revealed melanoma (Figure 1). After the two operations, it was considered that melanoma was not sensitive to radiotherapy and chemotherapy. To prolong his survival period and improve his quality of life, our team used the experimental treatment of Newcastle disease virus (NDV)-modified tumor vaccine through subcutaneous injection twice[6]. Additionally, the patient received interferon (3 µm subcutaneously 2 times a week) and β-elemene (500 mg QD for 14 d each month) for the first 6 mo, followed by maintenance treatment of interferon and β-elemene every 3 to 4 mo, resulting in a total treatment course of 43 mo up to November 2004. He had undergone regular follow-up, and his condition had been healthy, including tumor-free survival during these 21 years.

Personal and family history

The patient had no specific personal or family history.

Physical examination

The patient had no neurological symptoms. No melanoma was found on the skin or eyeball.

Laboratory examinations

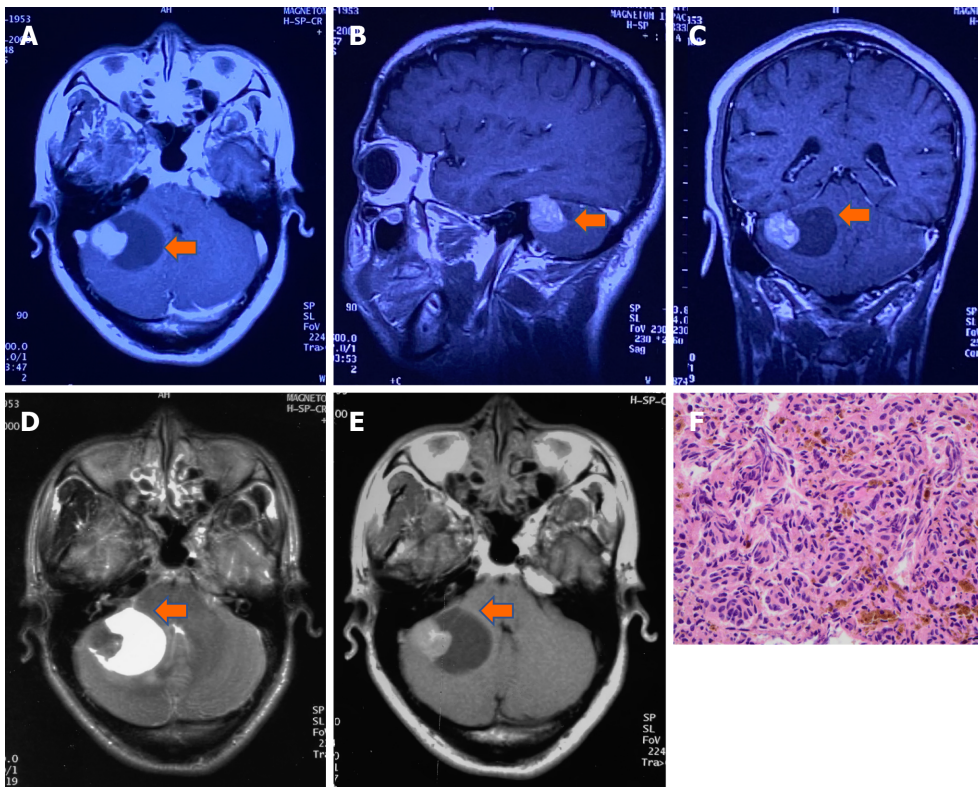
No specific findings of routine blood tests, blood biochemistry, or immune indices were noted.

Imaging examinations

The regular brain MRI in July 2021 showed a mixed iso-/hyperdense mass in the right cerebellopontine angle (CPA) measuring 34 mm × 21 mm with a clear margin (Figure 2), so the recurrence of the melanoma was regarded as highly possible again.

REVIEW OF CASES AND LITERATURE

We searched the PIMM in English and Chinese language papers using the search engine of PubMed and Medline-based with keywords of primary intracranial melanoma or primary cerebral melanoma and surgery or radiotherapy or chemotherapy or immunotherapy. All studies published during the period from 1993 to 2021 were collected. Metastases of CNS melanocytic neoplasm and intracranial meningeal melanocytoma were ruled out. In addition, metastatic melanoma without a known primary tumor was also ruled out, as patients who did not undergo workup with positron emission tomography (PET) or whole-body computed tomography (CT) were not enrolled in this study. Sampson *et al*[1] reported that the overall median survival of patients without treatment for MM was 3 to 4 mo, the 1-year survival rate was 9% to 19%, and only rare patients had prolonged survival. After MM was treated with stereotactic radiosurgery followed by either immunotherapy or targeted therapy, the median overall survival (OS)



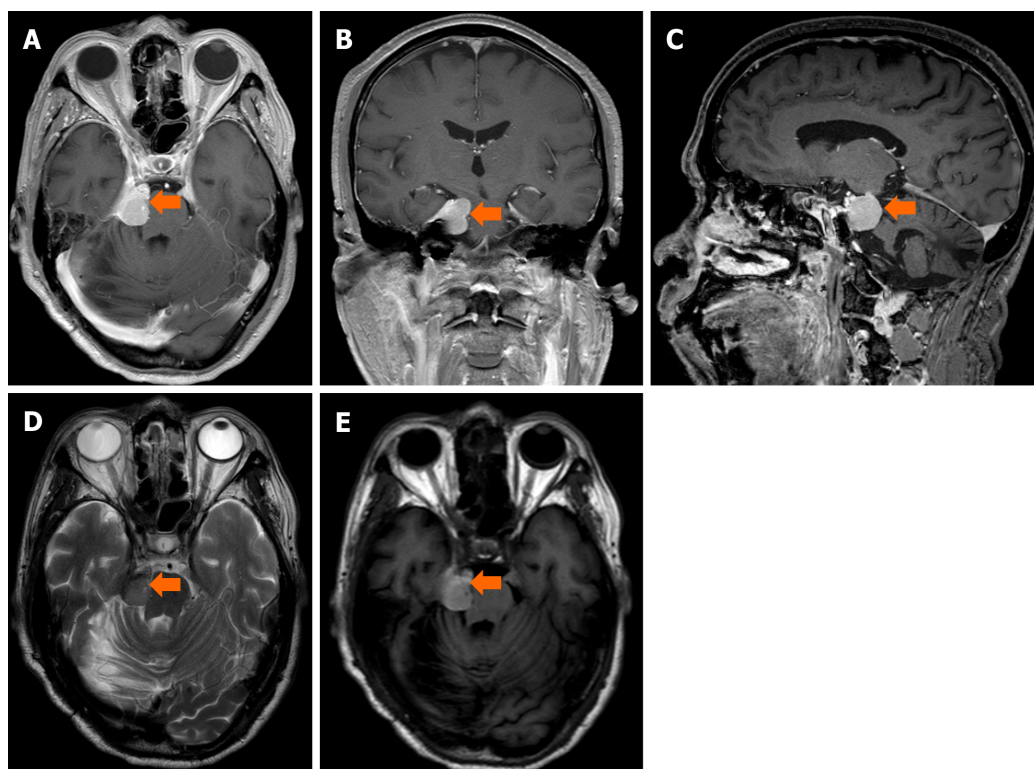
DOI: 10.12998/wjcc.v10.i30.11162 Copyright ©The Author(s) 2022.

Figure 1 Magnetic resonance imaging and pathology at first recurrence. A-C: Brain magnetic resonance imaging (MRI) T1-weighted postcontrast image (A) axial, (B) sagittal, (C) transverse, which indicates hyperintensity and intracapsular hypointense signals after contrast enhancement in the right cerebellopontine angle tumor (arrow); D and E: Axial MRI T2-weighted image shows a heterogeneous lightly hypointense node beside the hyperintense capsule, while axial MRI T1-weighted image (E) shows a heterogeneous lightly hyperintense node and hypointense capsule (October 24, 2000, before the 2nd operation); F: Histology shows recurrent melanoma (hematoxylin-eosin staining, magnification × 400).

was 11 mo, and the 1- and 2-year OS rates were 49.5% and 27.4%, respectively, according to Gaudy-Marqueste *et al*[7], which dramatically improved survival in MM. Baena *et al*[8] and Arai *et al*[9] summarized 130 patients with PIMM over the past 30 years. They reported that the mean age of PIMM patients was 45.8 years. No significant sex difference was found. Intracranial hypertension and focal neurologic deficits were commonly observed. The mean OS after gross total resection (> 22 mo) was significantly better than that after surgeries leaving behind residual tumor (12 mo). While there was no significant difference in the survival period between patients with and without adjuvant therapies, leptomeningeal enhancement diagnosed on the initial MRI was the worst prognostic factor. Nakagawa *et al*[10] reported a patient with PIMM who survived for 9 years and 6 mo after three surgeries to remove the tumor and after receiving adjuvant chemoimmunoradiotherapy in 1989. Önal *et al*[11] reported a long-term OS of 17 years in a patient who underwent gross total resection of PIMM and received adjuvant chemotherapy with methyl-CCNU in 2006. Li *et al*[12] established an OS rate of 62.8% at 6 mo and over 5 years at 17.2%, with an estimated median survival time (EMST) of 12 mo. The EMST was better in patients with a solitary-type lesion (13 mo) than in those with a diffuse-type lesion (5 mo). In their review of all patients, those receiving gross total resection with adjuvant radiation therapy and/or chemotherapy had significantly higher 1- and 5-year OS rates, which were 73% and 40.1%, respectively, and a longer EMST (53 mo) than patients who underwent gross total resection alone (20.5 mo) or radiation and/or chemotherapy without resection (13.0 mo). In our case, a 47-year-old male patient was initially diagnosed with PIMM and survived for 22 years after comprehensive treatment, including surgical removal of the tumor three times, adjuvant chemoimmunoradiotherapy, and β -elemene, an extract from the natural plant turmeric with antitumor activity. This is the longest OS case ever reported in the English and Chinese literature according to a search of the PubMed and MEDLINE databases.

MULTIDISCIPLINARY EXPERT CONSULTATION

Not applicable.



DOI: 10.12998/wjcc.v10.i30.11162 Copyright ©The Author(s) 2022.

Figure 2 Magnetic resonance imaging at second recurrence. A-C: Brain magnetic resonance imaging (MRI) T1-weighted postcontrast image (A) axial, (B) transverse, (C) sagittal, which shows irregular soft tissue with heterogeneous hyperintense signals and subtle contrast enhancement in the right cerebellopontine angle cistern and annular cistern (arrow); D and E: Axial MRI T2-weighted images shows isointensity, while axial MRI T1-weighted image (E) shows a hypointense mass with an unclear boundary with the right tentorium and brain stem compression (July 10, 2021, before the 3rd operation).

FINAL DIAGNOSIS

The patient was diagnosed with recurrent right CPA PIMM.

TREATMENT

During the third operation, it was observed that the tentorial margin had obviously turned black, and a dark black mass was seen under the petrosal vein. The tumor was solid, soft, tender, black, and rich blood supplied to attach to the dura mater, sparing the parenchyma of the cortex. The facial nerve was pushed outward and upward, and the trochlear and trigeminal nerves were pressed forward and downward. The tumor had a complete and smooth capsule, with a dark coal-like appearance and a black sesame paste-like content (Figure 3). The histopathology examination revealed melanoma (Figures 4A-C) positive for HMB45, Melan A, S-100, SOX-10, and p16. The Ki-67 index was 8% (+) (Figure 4D). Chromosomal locations of positive genes were detected by fluorescence *in situ* hybridization (FISH) in MM: RREB1-6p25/6p11.1-q11.1 (Figure 6 and Table 1). Further examinations included CT scans of the chest, abdomen, and pelvic region as well as PET scans of the whole brain and body, which were all negative. The patient was discharged from the hospital 10 d after GTR with no complications and went on for adjuvant radiotherapy (IMRT, GTV 45 Gy/9 f, CTV 27 Gy/9 f) and chemotherapy with temozolomide as a 5-d oral schedule every 4 wk (administered at 150 mg/m²/d for the first cycle, then 200 mg/m²/d for forward cycles).

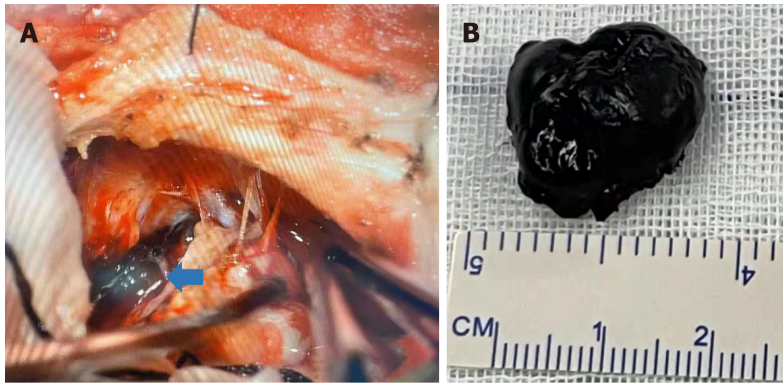
OUTCOME AND FOLLOW-UP

Brain MRI showed that no residual tumor or recurrence was found in the right CPA 3 mo after the 3rd operation (Figure 5). Up to the last follow-up on June 17, 2022, the patient recovered well with no recurrence or related sequelae. His condition was fine without neurological dysfunction, and he resumed his normal life.

Table 1 Malignant melanoma FISH detection

Gene	Chromosomal location	Result
CCND1 signal count/count nuclei	6q23	Negative
MYB signal count/count nuclei	6q25	Negative
RREB1 abnormal cell count/counted cells	6p25/6p11.1-q11.1	Positive
MYB missing cells/counted cells	6p23/6p11.1-q11.1	Negative

Filter set: DAPI, TRITC, FITC, GOLD. Abnormal signal interpretation standard: CCND1 signal count/count nuclei ≥ 2.5 ; MYB signal count/count nuclei ≥ 2.5 ; MYB missing cells/counted cells $\geq 31\%$; RREB1 abnormal cell count/counted cells $\geq 63\%$.



DOI: 10.12998/wjcc.v10.i30.11162 Copyright ©The Author(s) 2022.

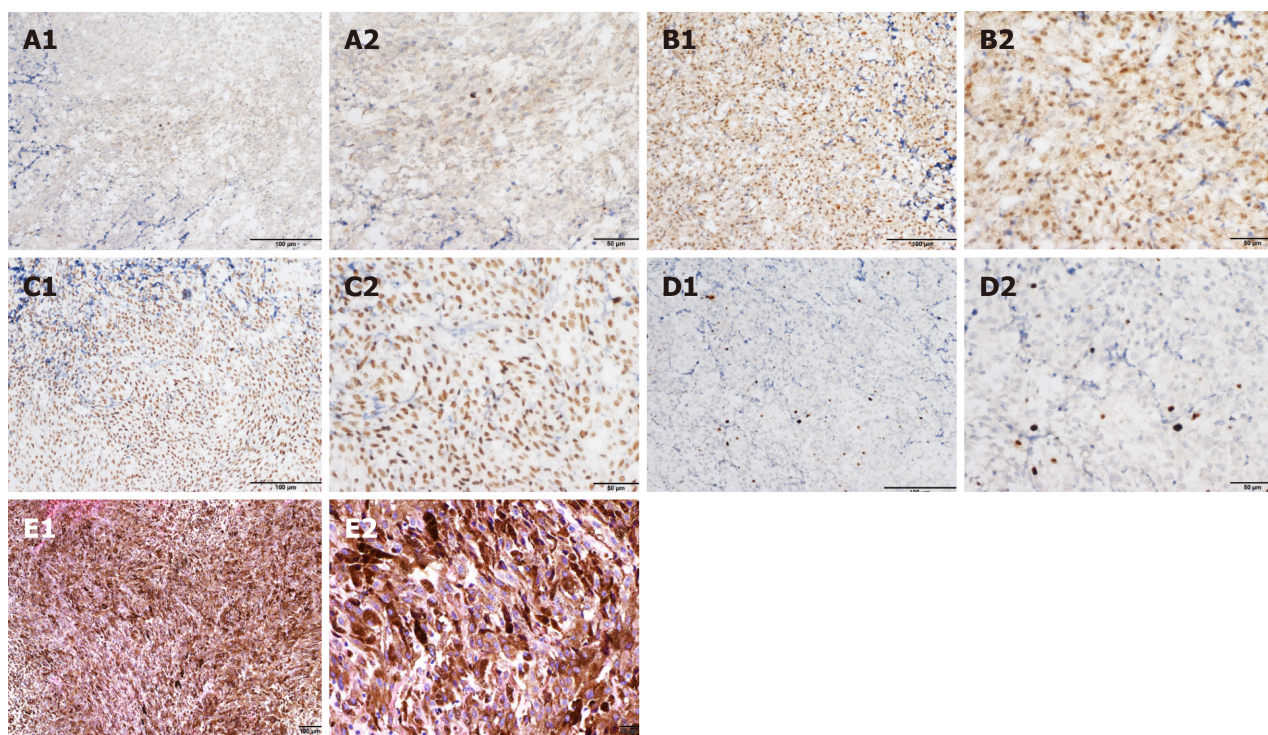
Figure 3 Surgical findings during the 3rd operation. A: Surgical findings showed a dark black semisolid lesion (arrow) was seen under the petrosal vein, the facial nerve was pushed outward and upward, and the trochlear and trigeminal nerves were pressed forward and downward in the right temporal lobe close to the cerebellopontine angle; B: The tumor lesion.

DISCUSSION

The incidence is 0.005/100000 for melanoma. There is a slight female predisposition, with a female-to-male ratio of 1.5:1. The age range of patients with primary nodular melanoma is 15 to 71 years, averaging 43 years. Intracranial melanoma is classified as primary or metastatic, and PIMM accounts for 1% of all melanomas[13]. Primary melanoma derives from leptomeningeal melanocytes. Pedersen *et al* [14] established the first model of melanoma driven by the oncogenic *NRAS* gene and reported two cases of children with melanoma of the CNS that presented mutations in the *NRAS* gene. The CNS melanoma is associated with mutations in the *GNAQ* and *GNA11* genes; however, mutations in the *NRAS* gene are rare in adults[15].

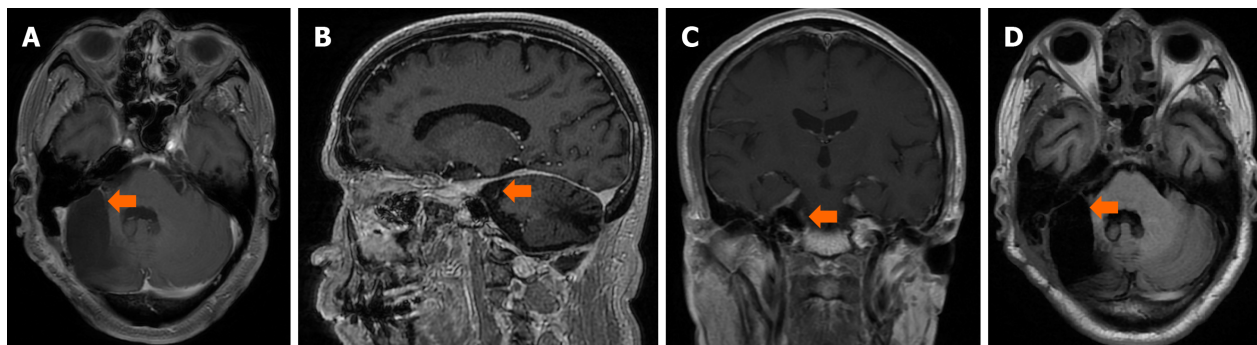
The symptoms and signs are secondary to either the local effects on the CNS parenchyma or hydrocephalus. The rapid progression with increasing intracranial pressure may suggest malignant transformation, which results in irritability, vomiting, lethargy, seizures, and so on. The diagnosis of melanocytic lesions relies on histopathological examination. Most benign and malignant melanocytic lesions display melanin pigment distributed within tumor cells, tumor stroma, and the cytoplasm of tumoral macrophages. Rare melanocytomas and fortuitous primary melanomas do not show melanin pigment, consistent with amelanotic melanoma. Histopathological and immunohistochemical examinations are highly sensitive for amelanotic melanoma.

Isiklar *et al*[16] classified the MRI manifestations into four groups: (1) The melanotic group, with hyperintensity on T1 and hypointensity on T2; (2) The amelanotic group, with iso-/hypointensity on T1 and iso-/hyperintensity on T2; (3) The mixed group, suiting neither of the two criteria; and (4) The hemorrhagic group, with characteristics of intra/peritumoral hemorrhage. There are hematopoietic neoplasms, cystic changes, and necrosis. One of them was suspected to be amelanotic melanoma. In our present case, T1-weighted hyperintense and T2-weighted isointensity signals consistent with the melanotic group were noted (Figure 3). The immunohistochemical analysis showed positive staining for HMB-45, S100, and vimentin. These results are important in the differential diagnosis of melanoma, particularly the positive staining for HMB-45 which is a specific biomarker for melanoma. Actually, the case in the present study also echoes such findings. These new findings reveal that RREB1 functions as both a transcriptional repressor and transcriptional activator for the transcriptional regulation of target genes. RREB1 is believed to function as a diagnostic biomarker or new drug target for melanoma detection.



DOI: 10.12998/wjcc.v10.i30.11162 Copyright ©The Author(s) 2022.

Figure 4 Immunohistochemical and histopathological analysis of confirmed recurrent melanoma at the 3rd operation. A-D: Immunohistochemical staining of tumor cells showed positivity for (A) HMB-45, (B) S-100, (C) SOX-10, and (D) Ki67 (8%) (A1, B1, C1, and D1: $\times 200$; A2, B2, C2, and D2: $\times 400$); E: Hematoxylin-eosin staining showed that the tumor cells were diffusely distributed in flakes, with abundant cytoplasm, pigment granules in some cells, round or oval nuclei, nucleoli, and mitotic figures (3 cells/10 high power fields) (E1: $\times 100$; E2: $\times 400$).

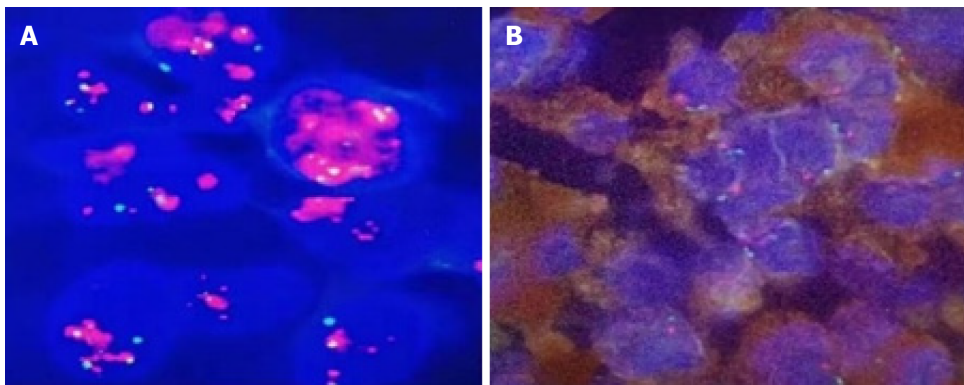


DOI: 10.12998/wjcc.v10.i30.11162 Copyright ©The Author(s) 2022.

Figure 5 Magnetic resonance imaging at last follow-up. A-C: Brain magnetic resonance imaging (MRI) T1-weighted postcontrast image (A) axial, (B) sagittal, (C) transverse; D: Axial MRI T2-weighted image show that no residual tumor or recurrence was found in the right cerebellopontine angle 3 mo after the operation.

Three criteria have been proposed to diagnose primary CNS melanoma: (1) The skin or eyeballs are negative for melanoma; (2) The skin or eyeballs have no history of melanoma resection; and (3) The internal organs are negative for melanoma metastasis. Our presented case had histopathology confirmed MM in the CPA. Whole-body examination ruled out the existence of melanoma outside of the CNS.

MM, which is highly aggressive and chemoradioresistant, has a poor prognosis and easily metastasizes. The prognosis of PIMM lesions appears to be better than that of metastatic examples. It is clear that total resection of tumors should be the key point for treatment[9,10]. For our case of PIMM, gross total resection was achieved; furthermore, excessive removal of invaded adjacent meninges in the 2nd surgery could be one of the important factors resulting in his long-term survival. Immunotherapy has developed rapidly for MM treatment[17]. The prognosis for patients with melanoma brain metastasis (MBM) has also improved, coinciding with the approval of PD-1 immune checkpoint inhibitors and combined BRAF/MEK targeting therapy[18]. However, controversy remains for MM in the CNS; at least, there is little clinical evidence showing efficacy for PIMM[19]. With respect to the



DOI: 10.12998/wjcc.v10.i30.11162 Copyright ©The Author(s) 2022.

Figure 6 MDM2 gene amplification test. A: Positive control; B: Test sample showed negative result of FISH test.

experience of our case, the patient survived for more than 21 years after the comprehensive treatment. Although this patient suffered a relapse after the first surgery, he continued to survive in the following 21 years or more after the second surgery in conjunction with ensuing adjuvant treatment. It remains questionable which of the following could yield effects apart from surgery: Radiotherapy, chemotherapy, and immunotherapy. Based on our analysis, gross total resection should be the key leading to curative effects, while postoperative adjuvant treatments are also important, as used in this case. Franak *et al*[20] reported in 1998 that the survival rate of AJCC (American Joint Committee on Cancer) stage III malignant melanoma patients was 59% 15 years after NDV oncolysate therapy. NDV has been evaluated as an anticancer agent because this virus has been shown to have direct toxic effects on tumor cells as well as indirect effects that appear to be mediated through stimulation of the host immune system[21, 22]. In the case of our patient, we applied NDV-modified tumor vaccine combined with interferon treatment, which could make some contribution; however, this patient received comparatively long-term β -elemene treatment. β -Elemene is a sesquiterpene compound extracted from the herb *Curcuma Rhizoma* and is used to treat several types of cancer including brain cancers such as gliomas[23]. Studies have shown that β -elemene can inhibit cell proliferation, arrest the cell cycle, and induce cell apoptosis. β -Elemene also regulates the expression of several key molecules that are involved in tumor angiogenesis and metastasis[24]. Furthermore, β -elemene has been shown to have regulatory effects on the immune response; for example, β -elemene transforms the polarization of macrophages from M2 to M1, which is considered to be an antitumor phenotype to kill tumor cells directly and stimulate antitumor T cells[25]. Therefore, it is reasonable to speculate that β -elemene treatment should also have helped this patient in combination with NDV-modified tumor vaccine immunotherapy.

CONCLUSION

PIMM is quite rare, and its prognosis is poor. However, comprehensive treatment, including surgical resection followed by appropriate adjuvant treatment strategies, may prolong patient survival. We hope that the PIMM case reported in this paper, which describes a patient whose life was extended by 22 years, can provide useful information for the reference of medical practitioners and patients alike, thereby boosting their confidence in adopting the treatment reported therein.

FOOTNOTES

Author contributions: Chen YS, Hu WM, Lv YC, Huang DC, and Deng ML designed and performed the research content; Wong TF, Zhang XH, and Chen ZP wrote the paper; all authors wrote, read, and approved the final manuscript.

Informed consent statement: Written informed consent was obtained from the patient for the publication of this case report and any accompanying images.

Conflict-of-interest statement: All authors declare no direct conflict of interest for this work.

CARE Checklist (2016) statement: All authors have read the CARE Checklist (2016), and the manuscript was prepared and revised according to the CARE Checklist (2016).

Open-Access: This article is an open-access article that was selected by an in-house editor and fully peer-reviewed by

external reviewers. It is distributed in accordance with the Creative Commons Attribution Non Commercial (CC BY-NC 4.0) license, which permits others to distribute, remix, adapt, build upon this work non-commercially, and license their derivative works on different terms, provided the original work is properly cited and the use is non-commercial. See: <https://creativecommons.org/licenses/by-nc/4.0/>

Country/Territory of origin: China

ORCID number: Tang-Fai Wong [0000-0002-9169-345X](#); Wan-Ming Hu [0000-0002-3632-1258](#); Zhong-Ping Chen [0000-0002-6226-5771](#).

S-Editor: Wang LL

L-Editor: Wang TQ

P-Editor: Wang LL

REFERENCES

- 1 **Sampson JH**, Carter JH Jr, Friedman AH, Seigler HF. Demographics, prognosis, and therapy in 702 patients with brain metastases from malignant melanoma. *J Neurosurg* 1998; **88**: 11-20 [PMID: [9420067](#) DOI: [10.3171/jns.1998.88.1.0011](#)]
- 2 **Puyana C**, Denyer S, Burch T, Bhimani AD, McGuire LS, Patel AS, Mehta AI. Primary Malignant Melanoma of the Brain: A Population-Based Study. *World Neurosurg* 2019; **130**: e1091-e1097 [PMID: [31323401](#) DOI: [10.1016/j.wneu.2019.07.095](#)]
- 3 **Davies MA**, Liu P, McIntyre S, Kim KB, Papadopoulos N, Hwu WJ, Hwu P, Bedikian A. Prognostic factors for survival in melanoma patients with brain metastases. *Cancer* 2011; **117**: 1687-1696 [PMID: [20960525](#) DOI: [10.1002/cncr.25634](#)]
- 4 **Bastian BC**. The molecular pathology of melanoma: an integrated taxonomy of melanocytic neoplasia. *Annu Rev Pathol* 2014; **9**: 239-271 [PMID: [24460190](#) DOI: [10.1146/annurev-pathol-012513-104658](#)]
- 5 **Glitza IC**, Smalley KSM, Brastianos PK, Davies MA, McCutcheon I, Liu JKC, Ahmed KA, Arrington JA, Evernden BR, Smalley I, Eroglu Z, Khushalani N, Margolin K, Kluger H, Atkins MB, Tawbi H, Boire A, Forsyth P. Leptomeningeal disease in melanoma patients: An update to treatment, challenges, and future directions. *Pigment Cell Melanoma Res* 2020; **33**: 527-541 [PMID: [31916400](#) DOI: [10.1111/pcmr.12861](#)]
- 6 **Simonsen TG**, Gaustad JV, Rofstad EK. Bevacizumab treatment of meningeal melanoma metastases. *J Transl Med* 2020; **18**: 13 [PMID: [31915016](#) DOI: [10.1186/s12967-020-02212-3](#)]
- 7 **Gaudy-Marqueste C**, Dussouil AS, Carron R, Troin L, Malissen N, Loundou A, Monestier S, Mallet S, Richard MA, Régis JM, Grob JJ. Survival of melanoma patients treated with targeted therapy and immunotherapy after systematic upfront control of brain metastases by radiosurgery. *Eur J Cancer* 2017; **84**: 44-54 [PMID: [28783540](#) DOI: [10.1016/j.ejca.2017.07.017](#)]
- 8 **Rodriguez y Baena R**, Gaetani P, Danova M, Bosi F, Zappoli F. Primary solitary intracranial melanoma: case report and review of the literature. *Surg Neurol* 1992; **38**: 26-37 [PMID: [1615371](#) DOI: [10.1016/0090-3019\(92\)90208-5](#)]
- 9 **Arai N**, Kagami H, Mine Y, Ishii T, Inaba M. Primary Solitary Intracranial Malignant Melanoma: A Systematic Review of Literature. *World Neurosurg* 2018; **117**: 386-393 [PMID: [29959081](#) DOI: [10.1016/j.wneu.2018.06.138](#)]
- 10 **Nakagawa H**, Hayakawa T, Niiyama K, Nii Y, Yoshimine T, Mori S. Long-term survival after removal of primary intracranial malignant melanoma. Case report. *Acta Neurochir (Wien)* 1989; **101**: 84-88 [PMID: [2603774](#) DOI: [10.1007/bf01410075](#)]
- 11 **Önal C**, Ozyigit G, Akyürek S, Selek U, Ozyar E, Atahan IL. Primary intracranial solitary melanoma: A rare case with long survival. *Turk J Cancer* 2006; **36**: 185-187 [DOI: [10.1016/s0168-1273\(06\)36010-2](#)]
- 12 **Li CB**, Song LR, Li D, Weng JC, Zhang LW, Zhang JT, Wu Z. Primary intracranial malignant melanoma: proposed treatment protocol and overall survival in a single-institution series of 15 cases combined with 100 cases from the literature. *J Neurosurg* 2019; **132**: 902-913 [PMID: [30835686](#) DOI: [10.3171/2018.11.jns.181872](#)]
- 13 **Shah I**, Imran M, Akram R, Rafat S, Zia K, Emaduddin M. Primary intracranial malignant melanoma. *J Coll Physicians Surg Pak* 2013; **23**: 157-159 [PMID: [23374525](#) DOI: [10.29271/jcpsp.2018.06.s123](#)]
- 14 **Pedersen M**, Küsters-Vandeveldt HVN, Viros A, Groenen PJTA, Sanchez-Laorden B, Gilhuis JH, van Engen-van Grunsven IA, Renier W, Schieving J, Niculescu-Duvaz I, Springer CJ, Küsters B, Wesseling P, Blokx WAM, Marais R. Primary melanoma of the CNS in children is driven by congenital expression of oncogenic NRAS in melanocytes. *Cancer Discov* 2013; **3**: 458-469 [PMID: [23303902](#) DOI: [10.1158/2159-8290.cd-12-0464](#)]
- 15 **Murali R**, Wiesner T, Rosenblum MK, Bastian BC. GNAQ and GNA11 mutations in melanocytomas of the central nervous system. *Acta Neuropathol* 2012; **123**: 457-459 [PMID: [22307269](#) DOI: [10.1007/s00401-012-0948-x](#)]
- 16 **Meacham RB**, Townsend RR, Drose JA. Ejaculatory duct obstruction: diagnosis and treatment with transrectal sonography. *AJR Am J Roentgenol* 1995; **165**: 1463-1466 [PMID: [7484587](#) DOI: [10.2214/ajr.165.6.7484597](#)]
- 17 **Luke JJ**, Flaherty KT, Ribas A, Long GV. Targeted agents and immunotherapies: optimizing outcomes in melanoma. *Nat Rev Clin Oncol* 2017; **14**: 463-482 [PMID: [28374786](#) DOI: [10.1038/nrclinonc.2017.43](#)]
- 18 **Bander ED**, Yuan M, Carnevale JA, Reiner AS, Panageas KS, Postow MA, Tabar V, Moss NS. Melanoma brain metastasis presentation, treatment, and outcomes in the age of targeted and immunotherapies. *Cancer* 2021; **127**: 2062-2073 [PMID: [33651913](#) DOI: [10.1002/cncr.33459](#)]
- 19 **Misir Krpan A**, Rakusic Z, Herceg D. Primary leptomeningeal melanomatosis successfully treated with PD-1 inhibitor pembrolizumab: A case report. *Medicine (Baltimore)* 2020; **99**: e22928 [PMID: [33327228](#) DOI: [10.1097/md.00000000000022928](#)]
- 20 **Batliwalla FM**, Bateman BA, Serrano D, Murray D, Macphail S, Maino VC, Ansel JC, Gregersen PK, Armstrong CA. A

- 15-year follow-up of AJCC stage III malignant melanoma patients treated postsurgically with Newcastle disease virus (NDV) oncolysate and determination of alterations in the CD8 T cell repertoire. *Mol Med* 1998; **4**: 783-794 [PMID: 9990864 DOI: [10.1007/bf03401771](https://doi.org/10.1007/bf03401771)]
- 21 Sinkovics J, Horvath J. New developments in the virus therapy of cancer: a historical review. *Intervirology* 1993; **36**: 193-214 [PMID: 8169112 DOI: [10.1159/000150339](https://doi.org/10.1159/000150339)]
 - 22 Takamura-Ishii M, Miura T, Nakaya T, Hagiwara K. Induction of antitumor response to fibrosarcoma by Newcastle disease virus-infected tumor vaccine. *Med Oncol* 2017; **34**: 171 [PMID: 28864944 DOI: [10.1007/s12032-017-1034-y](https://doi.org/10.1007/s12032-017-1034-y)]
 - 23 Zhang X, Chen Y, Yao J, Zhang Y, Li M, Yu B, Wang K. β -elemene combined with temozolomide in treatment of brain glioma. *Biochem Biophys Res Commun* 2021; **28**: 101144 [PMID: 34622038 DOI: [10.1016/j.bbrep.2021.101144](https://doi.org/10.1016/j.bbrep.2021.101144)]
 - 24 Zhai B, Zhang N, Han X, Li Q, Zhang M, Chen X, Li G, Zhang R, Chen P, Wang W, Li C, Xiang Y, Liu S, Duan T, Lou J, Xie T, Sui X. Molecular targets of β -elemene, a herbal extract used in traditional Chinese medicine, and its potential role in cancer therapy: A review. *Biomed Pharmacother* 2019; **114**: 108812 [PMID: 30965237 DOI: [10.1016/j.biopha.2019.108812](https://doi.org/10.1016/j.biopha.2019.108812)]
 - 25 Yu X, Xu M, Li N, Li Z, Li H, Shao S, Zou K, Zou L. β -elemene inhibits tumor-promoting effect of M2 macrophages in lung cancer. *Biochem Biophys Res Commun* 2017; **490**: 514-520 [PMID: 28624450 DOI: [10.1016/j.bbrc.2017.06.071](https://doi.org/10.1016/j.bbrc.2017.06.071)]



Published by **Baishideng Publishing Group Inc**
7041 Koll Center Parkway, Suite 160, Pleasanton, CA 94566, USA

Telephone: +1-925-3991568

E-mail: bpgoffice@wjgnet.com

Help Desk: <https://www.f6publishing.com/helpdesk>

<https://www.wjgnet.com>

