

World Journal of *Clinical Cases*

World J Clin Cases 2022 November 26; 10(33): 12066-12461



Contents

Thrice Monthly Volume 10 Number 33 November 26, 2022

MINIREVIEWS

- 12066** Review of risk factors, clinical manifestations, rapid diagnosis, and emergency treatment of neonatal perioperative pneumothorax
Zhang X, Zhang N, Ren YY

ORIGINAL ARTICLE

Clinical and Translational Research

- 12077** Integrative analysis of platelet-related genes for the prognosis of esophageal cancer
Du QC, Wang XY, Hu CK, Zhou L, Fu Z, Liu S, Wang J, Ma YY, Liu MY, Yu H
- 12089** Comprehensive analysis of the relationship between cuproptosis-related genes and esophageal cancer prognosis
Xu H, Du QC, Wang XY, Zhou L, Wang J, Ma YY, Liu MY, Yu H
- 12104** Molecular mechanisms of Baihedihuang decoction as a treatment for breast cancer related anxiety: A network pharmacology and molecular docking study
Li ZH, Yang GH, Wang F
- 12116** Single-cell RNA-sequencing combined with bulk RNA-sequencing analysis of peripheral blood reveals the characteristics and key immune cell genes of ulcerative colitis
Dai YC, Qiao D, Fang CY, Chen QQ, Que RY, Xiao TG, Zheng L, Wang LJ, Zhang YL

Retrospective Study

- 12136** Diagnosis and treatment of tubal endometriosis in women undergoing laparoscopy: A case series from a single hospital
Jiao HN, Song W, Feng WW, Liu H
- 12146** Different positive end expiratory pressure and tidal volume controls on lung protection and inflammatory factors during surgical anesthesia
Wang Y, Yang Y, Wang DM, Li J, Bao QT, Wang BB, Zhu SJ, Zou L
- 12156** Transarterial chemoembolization combined with radiofrequency ablation in the treatment of large hepatocellular carcinoma with stage C
Sun SS, Li WD, Chen JL
- 12164** Coexistence of anaplastic lymphoma kinase rearrangement in lung adenocarcinoma harbouring epidermal growth factor receptor mutation: A single-center study
Zhong WX, Wei XF

Observational Study

- 12175** Prognostic values of optic nerve sheath diameter for comatose patients with acute stroke: An observational study

Zhu S, Cheng C, Wang LL, Zhao DJ, Zhao YL, Liu XZ

- 12184** Quality of care in patients with inflammatory bowel disease from a public health center in Brazil

Takamune DM, Cury GSA, Ferrás G, Herrerias GSP, Rivera A, Barros JR, Baima JP, Saad-Hossne R, Sasaki LY

- 12200** Comparison of the prevalence of sarcopenia in geriatric patients in Xining based on three different diagnostic criteria

Pan SQ, Li XF, Luo MQ, Li YM

Prospective Study

- 12208** Predictors of bowel damage in the long-term progression of Crohn's disease

Fernández-Clotet A, Panés J, Ricart E, Castro-Pocheiro J, Masamunt MC, Rodríguez S, Caballol B, Ordás I, Rimola J

Randomized Controlled Trial

- 12221** Protective effect of recombinant human brain natriuretic peptide against contrast-induced nephropathy in elderly acute myocardial infarction patients: A randomized controlled trial

Zhang YJ, Yin L, Li J

META-ANALYSIS

- 12230** Prognostic role of pretreatment serum ferritin concentration in lung cancer patients: A meta-analysis

Gao Y, Ge JT

CASE REPORT

- 12240** Non-surgical management of dens invaginatus type IIIB in maxillary lateral incisor with three root canals and 6-year follow-up: A case report and review of literature

Arora S, Gill GS, Saquib SA, Saluja P, Baba SM, Khateeb SU, Abdulla AM, Bavabeedu SS, Ali ABM, Elagib MFA

- 12247** Unusual presentation of Loeys-Dietz syndrome: A case report of clinical findings and treatment challenges

Azrad-Daniel S, Cupa-Galvan C, Farca-Soffer S, Perez-Zincer F, Lopez-Acosta ME

- 12257** Peroral endoscopic myotomy assisted with an elastic ring for achalasia with obvious submucosal fibrosis: A case report

Wang BH, Li RY

- 12261** Subclavian brachial plexus metastasis from breast cancer: A case report

Zeng Z, Lin N, Sun LT, Chen CX

- 12268** Case mistaken for leukemia after mRNA COVID-19 vaccine administration: A case report

Lee SB, Park CY, Park SG, Lee HJ

- 12278** Orthodontic-surgical treatment of an Angle Class II malocclusion patient with mandibular hypoplasia and missing maxillary first molars: A case report

Li GF, Zhang CX, Wen J, Huang ZW, Li H

- 12289** Multiple cranial nerve palsies with small angle exotropia following COVID-19 mRNA vaccination in an adolescent: A case report
Lee H, Byun JC, Kim WJ, Chang MC, Kim S
- 12295** Surgical and nutritional interventions for endometrial receptivity: A case report and review of literature
Hernández-Melchor D, Palafox-Gómez C, Madrazo I, Ortiz G, Padilla-Viveros A, López-Bayghen E
- 12305** Conversion therapy for advanced penile cancer with tislelizumab combined with chemotherapy: A case report and review of literature
Long XY, Zhang S, Tang LS, Li X, Liu JY
- 12313** Endoscopic magnetic compression stricturoplasty for congenital esophageal stenosis: A case report
Liu SQ, Lv Y, Luo RX
- 12319** Novel *hydroxymethylbilane synthase* gene mutation identified and confirmed in a woman with acute intermittent porphyria: A case report
Zhou YQ, Wang XQ, Jiang J, Huang SL, Dai ZJ, Kong QQ
- 12328** Modified fixation for periprosthetic supracondylar femur fractures: Two case reports and review of the literature
Li QW, Wu B, Chen B
- 12337** Erbium-doped yttrium aluminum garnet laser and advanced platelet-rich fibrin+ in periodontal diseases: Two case reports and review of the literature
Tan KS
- 12345** Segmental artery injury during transforaminal percutaneous endoscopic lumbar discectomy: Two case reports
Cho WJ, Kim KW, Park HY, Kim BH, Lee JS
- 12352** Pacemaker electrode rupture causes recurrent syncope: A case report
Zhu XY, Tang XH, Huang WY
- 12358** Hybrid intercalated duct lesion of the parotid: A case report
Stankevicius D, Petroska D, Zaleckas L, Kutanovaite O
- 12365** Clinical features and prognosis of multiple myeloma and orbital extramedullary disease: Seven cases report and review of literature
Hu WL, Song JY, Li X, Pei XJ, Zhang JJ, Shen M, Tang R, Pan ZY, Huang ZX
- 12375** Colon mucosal injury caused by water jet malfunction during a screening colonoscopy: A case report
Patel P, Chen CH
- 12380** Primary malignant pericardial mesothelioma with difficult antemortem diagnosis: A case report
Oka N, Orita Y, Oshita C, Nakayama H, Teragawa H
- 12388** Typical imaging manifestation of neuronal intranuclear inclusion disease in a man with unsteady gait: A case report
Gao X, Shao ZD, Zhu L

- 12395** Multimodality imaging and treatment of paranasal sinuses nuclear protein in testis carcinoma: A case report
Huang WP, Gao G, Qiu YK, Yang Q, Song LL, Chen Z, Gao JB, Kang L
- 12404** T1 rectal mucinous adenocarcinoma with bilateral enlarged lateral lymph nodes and unilateral metastasis: A case report
Liu XW, Zhou B, Wu XY, Yu WB, Zhu RF
- 12410** Influence of enhancing dynamic scapular recognition on shoulder disability, and pain in diabetics with frozen shoulder: A case report
Mohamed AA
- 12416** Acute myocardial necrosis caused by aconitine poisoning: A case report
Liao YP, Shen LH, Cai LH, Chen J, Shao HQ
- 12422** Danggui Sini decoction treatment of refractory allergic cutaneous vasculitis: A case report
Chen XY, Wu ZM, Wang R, Cao YH, Tao YL
- 12430** Phlegmonous gastritis after biloma drainage: A case report and review of the literature
Yang KC, Kuo HY, Kang JW
- 12440** Novel *TINF2* gene mutation in dyskeratosis congenita with extremely short telomeres: A case report
Picos-Cárdenas VJ, Beltrán-Ontiveros SA, Cruz-Ramos JA, Contreras-Gutiérrez JA, Arámbula-Meraz E, Angulo-Rojo C, Guadrón-Llanos AM, Leal-León EA, Cedano-Prieto DM, Meza-Espinoza JP
- 12447** Synchronous early gastric and intestinal mucosa-associated lymphoid tissue lymphoma in a *Helicobacter pylori*-negative patient: A case report
Lu SN, Huang C, Li LL, Di LJ, Yao J, Tuo BG, Xie R

LETTER TO THE EDITOR

- 12455** Diagnostic value of metagenomics next-generation sequencing technology in disseminated strongyloidiasis
Song P, Li X
- 12458** Diagnostic value of imaging examination in autoimmune pancreatitis
Wang F, Peng Y, Xiao B

ABOUT COVER

Editorial Board Member of *World Journal of Clinical Cases*, Cornelia Bala, MD, PhD, Professor, Department of Diabetes and Nutrition Diseases, "Iuliu Hatieganu" University of Medicine and Pharmacy, Cluj-Napoca 400006, Romania. cbala@umfcluj.ro

AIMS AND SCOPE

The primary aim of *World Journal of Clinical Cases* (WJCC, *World J Clin Cases*) is to provide scholars and readers from various fields of clinical medicine with a platform to publish high-quality clinical research articles and communicate their research findings online.

WJCC mainly publishes articles reporting research results and findings obtained in the field of clinical medicine and covering a wide range of topics, including case control studies, retrospective cohort studies, retrospective studies, clinical trials studies, observational studies, prospective studies, randomized controlled trials, randomized clinical trials, systematic reviews, meta-analysis, and case reports.

INDEXING/ABSTRACTING

The WJCC is now abstracted and indexed in Science Citation Index Expanded (SCIE, also known as SciSearch®), Journal Citation Reports/Science Edition, Current Contents®/Clinical Medicine, PubMed, PubMed Central, Scopus, Reference Citation Analysis, China National Knowledge Infrastructure, China Science and Technology Journal Database, and Superstar Journals Database. The 2022 Edition of Journal Citation Reports® cites the 2021 impact factor (IF) for WJCC as 1.534; IF without journal self cites: 1.491; 5-year IF: 1.599; Journal Citation Indicator: 0.28; Ranking: 135 among 172 journals in medicine, general and internal; and Quartile category: Q4. The WJCC's CiteScore for 2021 is 1.2 and Scopus CiteScore rank 2021: General Medicine is 443/826.

RESPONSIBLE EDITORS FOR THIS ISSUE

Production Editor: *Ying-Yi Yuan*; Production Department Director: *Xiang Li*; Editorial Office Director: *Jin-Lei Wang*.

NAME OF JOURNAL

World Journal of Clinical Cases

ISSN

ISSN 2307-8960 (online)

LAUNCH DATE

April 16, 2013

FREQUENCY

Thrice Monthly

EDITORS-IN-CHIEF

Bao-Gan Peng, Jerzy Tadeusz Chudek, George Kontogeorgos, Maurizio Serati, Ja Hyeon Ku

EDITORIAL BOARD MEMBERS

<https://www.wjgnet.com/2307-8960/editorialboard.htm>

PUBLICATION DATE

November 26, 2022

COPYRIGHT

© 2022 Baishideng Publishing Group Inc

INSTRUCTIONS TO AUTHORS

<https://www.wjgnet.com/bpg/gerinfo/204>

GUIDELINES FOR ETHICS DOCUMENTS

<https://www.wjgnet.com/bpg/GerInfo/287>

GUIDELINES FOR NON-NATIVE SPEAKERS OF ENGLISH

<https://www.wjgnet.com/bpg/gerinfo/240>

PUBLICATION ETHICS

<https://www.wjgnet.com/bpg/GerInfo/288>

PUBLICATION MISCONDUCT

<https://www.wjgnet.com/bpg/gerinfo/208>

ARTICLE PROCESSING CHARGE

<https://www.wjgnet.com/bpg/gerinfo/242>

STEPS FOR SUBMITTING MANUSCRIPTS

<https://www.wjgnet.com/bpg/GerInfo/239>

ONLINE SUBMISSION

<https://www.f6publishing.com>



Pacemaker electrode rupture causes recurrent syncope: A case report

Xiao-Yong Zhu, Xin-Hu Tang, Wen-Yin Huang

Specialty type: Cardiac and cardiovascular systems

Provenance and peer review: Unsolicited article; Externally peer reviewed.

Peer-review model: Single blind

Peer-review report's scientific quality classification

Grade A (Excellent): 0
Grade B (Very good): B
Grade C (Good): C, C
Grade D (Fair): 0
Grade E (Poor): E

P-Reviewer: Ghannam WM, Egypt; M.D. HA, Italy; Moussa BS; Salman I, Czech Republic

Received: July 19, 2022

Peer-review started: July 19, 2022

First decision: September 25, 2022

Revised: October 4, 2022

Accepted: October 19, 2022

Article in press: October 19, 2022

Published online: November 26, 2022



Xiao-Yong Zhu, Xin-Hu Tang, Wen-Yin Huang, Department of Cardiology, Jiujiang University Affiliated Hospital, Jiujiang 332000, Jiangxi Province, China

Corresponding author: Xin-Hu Tang, MD, Chief Physician, Doctor, Department of Cardiology, Jiujiang University Affiliated Hospital, No. 57 Road, Xunyang District, Jiujiang 332000, Jiangxi Province, China. 18879292198@163.com

Abstract

BACKGROUND

Currently, the implantation of permanent cardiac pacemakers entails mostly subclavian vein puncture, which is relatively simpler and easier to master. However, due to individual differences, some patients carry a narrow space between the clavicle and the first rib. If the range of activity of the upper limb is increased, the friction between the electrode wire and the bone gap leads to the breakage of the electrode wire, which is manifested by poor pacemaker perception and pacing.

CASE SUMMARY

A 68-year-old woman underwent permanent pacemaker implantation in our hospital because of third-degree atrioventricular block 6 years ago. At that time, the patient was recommended to have a dual-chamber permanent pacemaker implantation, and finally chose a single-chamber permanent pacemaker because she could not afford the cost. The patient has repeatedly lost consciousness for no obvious reason in the past 3 d, and went to our hospital for treatment. The chest X-ray showed that the pacemaker electrode was broken. After the patient was given a pacemaker electrode replacement, the patient did not continue to lose consciousness.

CONCLUSION

Because the electrodes implanted in the subclavian approach are close to the clavicle and the first rib, the pacemaker electrodes may wear out. If the patient loses consciousness again after the pacemaker is implanted, we should consider whether there is a pacemaker. The possibility of electrode breakage, and timely help the patient to replace the new pacemaker electrodes.

Key Words: Syncope; Pacemaker; Lead fracture; Subclavian crush; Case report

©The Author(s) 2022. Published by Baishideng Publishing Group Inc. All rights reserved.

Core Tip: We treated a patient who was implanted with a single-chamber pacemaker 6 years ago. The patient experienced repeated loss of consciousness 3 d ago without obvious incentives. The patient did not continue to lose consciousness after the pacemaker electrodes were replaced.

Citation: Zhu XY, Tang XH, Huang WY. Pacemaker electrode rupture causes recurrent syncope: A case report. *World J Clin Cases* 2022; 10(33): 12352-12357

URL: <https://www.wjgnet.com/2307-8960/full/v10/i33/12352.htm>

DOI: <https://dx.doi.org/10.12998/wjcc.v10.i33.12352>

INTRODUCTION

Permanent pacemaker implantation is an effective treatment for bradyarrhythmia. This treatment method involves relatively simple surgery and is associated with minimal trauma. However, complications can still occur, including mainly hematoma, infection, hemopneumothorax, pacemaker syndrome, and electrode breakage and dislocation. The proportion of electrode fractures is about 1.2% [1]. Early fracture is mostly caused by operator inefficiency, while the late fracture is mostly attributed to small subclavian space and long-term friction between the electrode and the clavicle or rib. We describe a case of abnormal perception and pacing triggered by the rupture of permanent pacemaker electrode, resulting in recurrent syncope. Ultimately, the patient did not experience any loss of consciousness after the pacemaker and electrodes were replaced.

CASE PRESENTATION

Chief complaints

A 68-year-old female, who suffered from repeated loss of consciousness for 3 d went to the Jiujiang University Affiliated Hospital on June 9, 2022.

History of present illness

The patient complained that there was no obvious cause for loss of consciousness 3 d ago, and the family members complained that the patient's consciousness recovered 10 s later, but he did not pay attention to it at that time and did not diagnose and treat it. The patient complained of repeated episodes of loss of consciousness, especially when turning sideways. He went to the emergency department of our hospital for treatment, and the electrocardiogram showed a pacemaker electrocardiogram (Figure 1A). Interestingly, when the patient was sitting on the bed and describing his medical history, she suddenly said that she had amaurosis symptoms, and the bedside electrocardiogram (ECG) monitor showed intermittent poor pacing, which was recorded in time by the ECG (Figure 1B). When the heart resumed full pacing, the patient complained of dizziness and amaurosis symptoms relieved, and the pacemaker programming indicated that the electrode impedance was 323 ohms, and the pacing threshold was 5v.

History of past illness

The patient had a history of hypertension for 10 years. She took amlodipine besylate 5 mg QD regularly to control her blood pressure, noting that the blood pressure level was controlled well. She did not take any other medications. The patient denied history of coronary heart disease, cerebral infarction, diabetes.

Personal and family history

The patient denied smoking, drinking history, and family disease history.

Physical examination

Body temperature, 36.3 °C; breathing, 20 breaths/min; blood pressure, 114/70 mmHg; heart rate, 80 beats/min. Nerve examination and physical examination showed no abnormality

Laboratory examinations

No abnormality is found in blood routine test, liver function, kidney function, electrolyte, thyroid function, blood coagulation function and stool routine test.

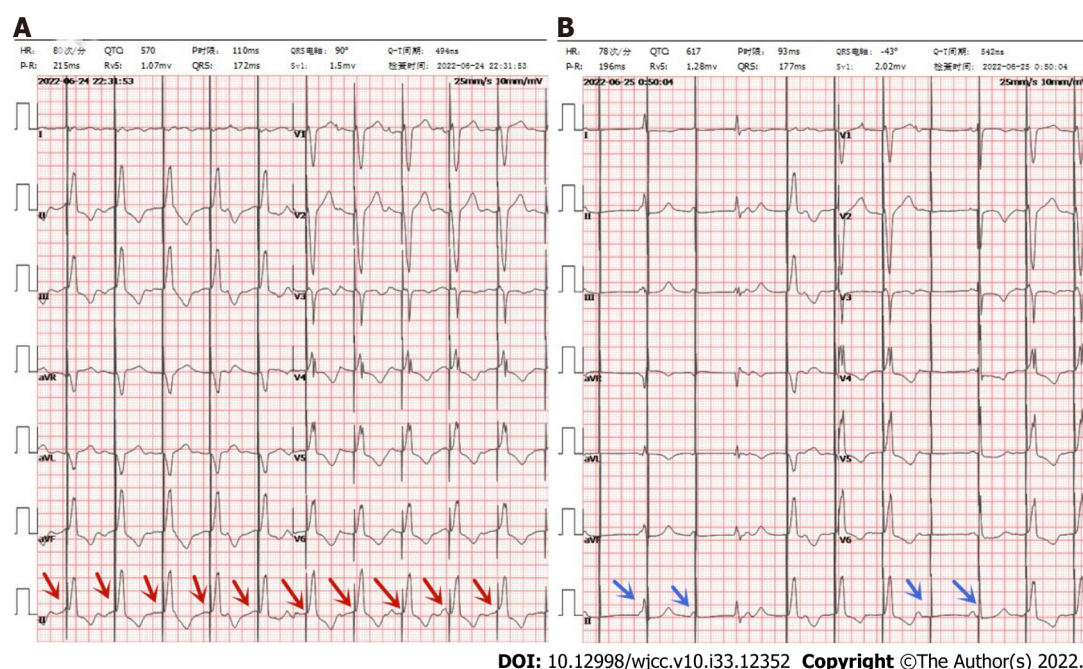


Figure 1 Electrocardiogram. A: Electrocardiogram (ECG) in emergency department: red arrow indicates normal pacing; B: ECG during amaurosis: Blue arrows indicate poor pacing.

Imaging examinations

Brain computed tomography showed no abnormality, Chest X-ray showed a broken electrode line at the junction of the left clavicle and the first rib (Figure 2A and B).

FINAL DIAGNOSIS

Fractured pacemaker electrodes resulted in poor pacing, and the patient experienced repeated loss of consciousness.

TREATMENT

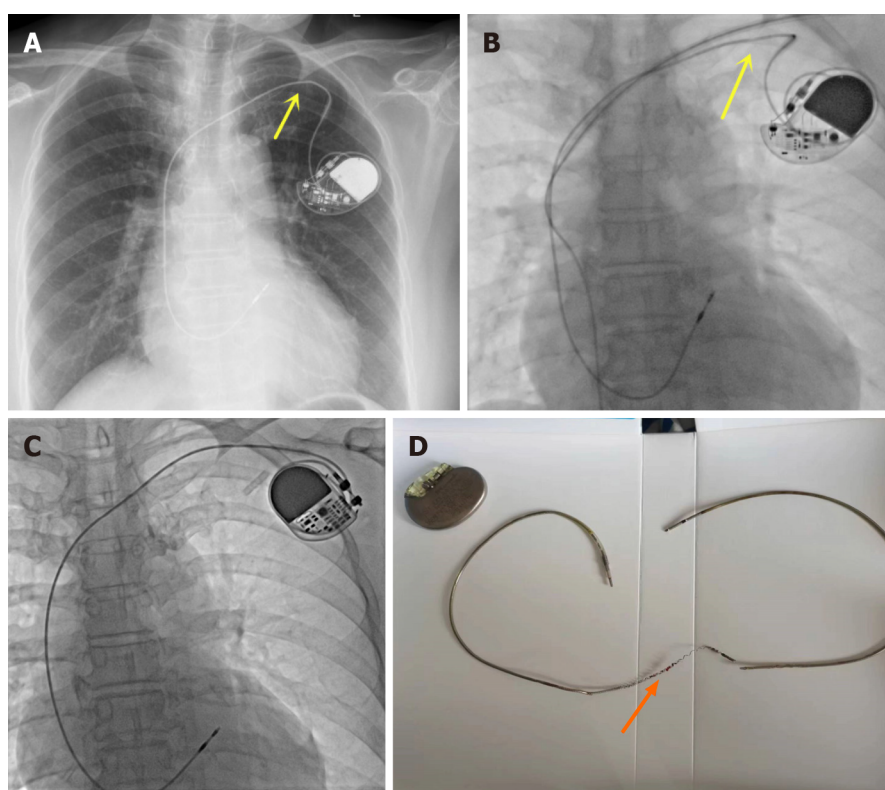
Because the patient's pacemaker was implanted 6 years ago, the pacemaker and electrode replacement surgery were considered after full communication with the patient's family. The vascular puncture site was also adjusted from the subclavian vein to the axillary vein puncture, and the original electrodes were removed. And implanted new electrodes and pacemaker (Figure 2C and D).

OUTCOME AND FOLLOW-UP

The patient had good pacing after surgery, no further loss of consciousness, and was discharged from the hospital on July 7, 2022.

DISCUSSION

Permanent pacemaker plays an important role in the treatment of symptomatic bradyarrhythmia, Syncope can be induced by multiple factors. However, syncope triggered by cardiac causes often indicates poor prognosis and high mortality[2]. The causes of syncope in patients with permanent cardiac pacemakers are mostly neurogenic, hemodynamic instability caused by ventricular tachycardia, pacemaker sensing and pacing dysfunction due to abnormalities associated with pacemaker and lead. Syncope caused by broken pacemaker leads accounts for the least proportion of these cases. Subclavian vein puncture is the preferred method for pacemaker electrode implantation, because of its high success rate, fewer complications, and relative simplicity and user-friendly features. The implantation of



DOI: 10.12998/wjcc.v10.i33.12352 Copyright ©The Author(s) 2022.

Figure 2 Brain computed tomography/electrodes and pacemaker. A and B: The fluoroscopic image shows the lead depression in the subclavian area (yellow arrows); C: Replaced pacemaker and pacemaker electrode; D: Extracted lead shows broken lead (orange arrow).

electrodes from the subclavian vein route is usually done through a narrow space consisting of the clavicle, ribs, muscles and ligaments[3]. The sternoclavicular joint in this area is the joint between the sternal ribs and the scapula, which is involved in the movement of the thoracolumbar region[3]. Because of the relative structural complexity, the pacemaker lead may be clamped, which leads to wear and tear of the pacemaker electrode during hand and shoulder movements, and breakage of the electrode. In some patients, this position can lead to subclavian crush syndrome, resulting in damaged wire. Magney *et al*[4] reported anatomical studies involving cadavers that lead entrapment in the clavicle and first rib rather than friction resulted in lead damage.

In this case, subclavian vein puncture was used. Imaging revealed a medial puncture site and subclavicular electrode fracture site. Considering that the electrode fracture was related to the selection of puncture site, the reduced impedance suggested that the electrode insulation layer was damaged. The subsequent electrode fracture was related to pacemaker extrusion, traction and wear under the clavicle, which was also a disadvantage of subclavian puncture and electrode implantation. Axillary vein or cephalic vein pathway prevents electrode damage induced by subclavian puncture. Compared with the strong medial subclavian vein access, the cephalic or axillary vein puncture significantly reduced this complication[3,5]. Implantation of pacemaker electrodes *via* axillary or cephalic vein incision can significantly reduce the risk of electrode wear[3]. A meta-analysis showed that compared with subclavian puncture, the cephalic incision decreased the risk of electrode wear although the left and right implantations were associated with similar complications. Generally, we select the side toward the non-dominant hand for electrode implantation, that is, For right-handed patients, we place the pacemaker on the left[6]. The annual incidence of pacemaker electrode breakage is about 1.2%[1], which is an underestimate, given the number of undetected and untreated cases. Pacemaker lead breakage is mostly seen in younger individuals (age less than 50 years)[7], patients engaged in intense sports activities, women, and patients with high left ventricular ejection fraction[8]. Symptoms of pacemaker rupture depend on the patient's dependence on pacemaker. These symptoms include dizziness, lethargy, syncope and a syndrome. In the absence of pacemaker dependence, it is hard to identify symptoms associated with a broken pacemaker electrode. ECG indicates poor pacing and it is not easy to detect images of pacemaker fracture. Occasionally, it is necessary to abduct the ipsilateral arm implanted with the pacemaker to detect the electrode fracture on an image. The pacemaker program control indicates a significant elevation in pacemaker electrode impedance (normal range, 300-1000 ohms). The treatment of broken pacemaker electrode is replacement with a new one, based on the advantages and disadvantages, and then decide whether or not to remove the broken pacemaker electrode[2]. In the absence of trauma or intense physical activity, we believe that the broken pacemaker electrode in this

patient was due to repeated friction between the electrode and the clavicle. This patient was fortunate in that the ECG revealed poor pacing after admission, indicating that the syncope was caused by the broken pacemaker wire, which prompted implantation of a new pacemaker electrode, avoiding any further adverse consequences.

CONCLUSION

Electrode breakage after permanent pacemaker implantation can be prevented by the following precautions: (1) The puncture point in subclavian vein puncture should be as close to the outside as possible to reduce the angle between the puncture needle and the skin, and avoid compression and friction of the locking rib triangle on the electrode line, or axillary vein or cephalic vein puncture may be used instead; (2) The range of motion of the upper limb on the operated side should be appropriate to avoid repeated twisting of electrode wires and prevent metal fatigue leading to fracture; and (3) The electrode wire should not be clamped with vascular forceps during the operation to prevent the risk of breakage of the electrode wire caused by human intervention.

FOOTNOTES

Author contributions: Zhu XY reviewed the literature and contributed to manuscript drafting and revising; Zhu XY was the patient's doctors and contributed to collecting the patient's medical data and making a revision to the manuscript; Huang WY Completed surgery and recorded surgical images, Tang XH was responsible for the revision of the manuscript for important intellectual content; all authors issued final approval for the version to be submitted.

Informed consent statement: Informed written consent was obtained from the patient for publication of this report and any accompanying images.

Conflict-of-interest statement: All the authors declare that they have no conflict of interest to disclose.

CARE Checklist (2016) statement: The authors have read the CARE Checklist (2016), and the manuscript was prepared and revised according to the CARE Checklist (2016).

Open-Access: This article is an open-access article that was selected by an in-house editor and fully peer-reviewed by external reviewers. It is distributed in accordance with the Creative Commons Attribution NonCommercial (CC BY-NC 4.0) license, which permits others to distribute, remix, adapt, build upon this work non-commercially, and license their derivative works on different terms, provided the original work is properly cited and the use is non-commercial. See: <https://creativecommons.org/licenses/by-nc/4.0/>

Country/Territory of origin: China

ORCID number: Xiao-Yong Zhu 0000-0003-1103-1227; Xin-Hu Tang 0000-0003-0175-3197; Wen-Yin Huang 0000-0002-5644-030X.

S-Editor: Liu JH

L-Editor: A

P-Editor: Liu JH

REFERENCES

- Alt E, Völker R, Blömer H. Lead fracture in pacemaker patients. *Thorac Cardiovasc Surg* 1987; **35**: 101-104 [PMID: 2440129 DOI: 10.1055/s-2007-1020206]
- Yasa E, Ricci F, Holm H, Persson T, Melander O, Sutton R, Hamrefors V, Fedorowski A. Pacing therapy in the management of unexplained syncope: a tertiary care centre prospective study. *Open Heart* 2019; **6**: e001015 [PMID: 30997138 DOI: 10.1136/openhrt-2019-001015]
- Chan NY, Kwong NP, Cheong AP. Venous access and long-term pacemaker lead failure: comparing contrast-guided axillary vein puncture with subclavian puncture and cephalic cutdown. *Europace* 2017; **19**: 1193-1197 [PMID: 27733455 DOI: 10.1093/europace/euw147]
- Magney JE, Flynn DM, Parsons JA, Staplin DH, Chin-Purcell MV, Milstein S, Hunter DW. Anatomical mechanisms explaining damage to pacemaker leads, defibrillator leads, and failure of central venous catheters adjacent to the sternoclavicular joint. *Pacing Clin Electrophysiol* 1993; **16**: 445-457 [PMID: 7681196 DOI: 10.1111/j.1540-8159.1993.tb01607.x]
- Atti V, Turagam MK, Garg J, Koerber S, Angirekula A, Gopinathannair R, Natale A, Lakkireddy D. Subclavian and Axillary Vein Access Versus Cephalic Vein Cutdown for Cardiac Implantable Electronic Device Implantation: A Meta-Analysis. *JACC Clin Electrophysiol* 2020; **6**: 661-671 [PMID: 32553216 DOI: 10.1016/j.jacep.2020.01.006]

- 6 **Benz AP**, Vamos M, Erath JW, Hohnloser SH. Cephalic vs. subclavian lead implantation in cardiac implantable electronic devices: a systematic review and meta-analysis. *Europace* 2019; **21**: 121-129 [PMID: [30020452](#) DOI: [10.1093/europace/euy165](#)]
- 7 **Morrison TB**, Rea RF, Hodge DO, Crusan D, Koestler C, Asirvatham SJ, Bradley D, Shen WK, Munger TM, Hammill SC, Friedman PA. Risk factors for implantable defibrillator lead fracture in a recalled and a nonrecalled lead. *J Cardiovasc Electrophysiol* 2010; **21**: 671-677 [PMID: [20082653](#) DOI: [10.1111/j.1540-8167.2009.01683.x](#)]
- 8 **Udo EO**, Zuithoff NP, van Hemel NM, de Cock CC, Hendriks T, Doevendans PA, Moons KG. Incidence and predictors of short- and long-term complications in pacemaker therapy: the FOLLOWPACE study. *Heart Rhythm* 2012; **9**: 728-735 [PMID: [22182495](#) DOI: [10.1016/j.hrthm.2011.12.014](#)]



Published by **Baishideng Publishing Group Inc**
7041 Koll Center Parkway, Suite 160, Pleasanton, CA 94566, USA

Telephone: +1-925-3991568

E-mail: bpgoffice@wjgnet.com

Help Desk: <https://www.f6publishing.com/helpdesk>

<https://www.wjgnet.com>

