

# World Journal of *Clinical Cases*

*World J Clin Cases* 2022 December 6; 10(34): 12462-12803



## Contents

Thrice Monthly Volume 10 Number 34 December 6, 2022

### FIELD OF VISION

- 12462** Problematics of neurosurgical service during the COVID-19 pandemic in Slovenia  
*Munda M, Bosnjak R, Velnar T*

### MINIREVIEWS

- 12470** Circulating angiotensin converting enzyme 2 and COVID-19  
*Leowattana W, Leowattana T, Leowattana P*
- 12484** Evaluation of gut dysbiosis using serum and fecal bile acid profiles  
*Monma T, Iwamoto J, Ueda H, Tamamushi M, Kakizaki F, Konishi N, Yara S, Miyazaki T, Hirayama T, Ikegami T, Honda A*
- 12494** Pediatric kidney transplantation during the COVID-19 pandemic  
*Tamura H*

### ORIGINAL ARTICLE

#### Clinical and Translational Research

- 12500** *Coptis*, *Pinellia*, and *Scutellaria* as a promising new drug combination for treatment of *Helicobacter pylori* infection  
*Yu Z, Sheng WD, Yin X, Bin Y*

#### Case Control Study

- 12515** Effects of illness perception on negative emotions and fatigue in chronic rheumatic diseases: Rumination as a possible mediator  
*Lu Y, Jin X, Feng LW, Tang C, Neo M, Ho RC*

#### Retrospective Study

- 12532** Significance of incidental focal fluorine-18 fluorodeoxyglucose uptake in colon/rectum, thyroid, and prostate: With a brief literature review  
*Lee H, Hwang KH*
- 12543** Follow-up study on ThinPrep cytology test-positive patients in tropical regions  
*Chen YC, Liang CN, Wang XF, Wang MF, Huang XN, Hu JD*
- 12551** Effect of teach-back health education combined with structured psychological nursing on adverse emotion and patient cooperation during  $^{99m}\text{Tc}$ -3PRGD2.SPECT/CT  
*Gong WN, Zhang YH, Niu J, Li XB*
- 12559** Nosocomial infection and spread of SARS-CoV-2 infection among hospital staff, patients and caregivers  
*Cheng CC, Fann LY, Chou YC, Liu CC, Hu HY, Chu D*

**Observational Study**

- 12566** Effectiveness and safety of generic and brand direct acting antivirals for treatment of chronic hepatitis C  
*Abdulla M, Al Ghareeb AM, Husain HAHY, Mohammed N, Al Qamish J*

- 12578** Influence of group B *streptococcus* and vaginal cleanliness on the vaginal microbiome of pregnant women  
*Liao Q, Zhang XF, Mi X, Jin F, Sun HM, Wang QX*

**Randomized Controlled Trial**

- 12587** Clinical study on tri-tongue acupuncture combined with low-frequency electrical stimulation for treating post-stroke dysarthria  
*Man B, Li WW, Xu JF, Wang Q*

**META-ANALYSIS**

- 12594** Three-dimensional time-of-flight magnetic resonance angiography combined with high resolution T2-weighted imaging in preoperative evaluation of microvascular decompression  
*Liang C, Yang L, Zhang BB, Guo SW, Li RC*

**CASE REPORT**

- 12605** Acute cytomegalovirus hepatitis in an immunocompetent patient: A case report  
*Wang JP, Lin BZ, Lin CL, Chen KY, Lin TJ*
- 12610** Long-term results of extended Boari flap technique for management of complete ureteral avulsion: A case report  
*Zhong MZ, Huang WN, Huang GX, Zhang EP, Gan L*
- 12617** Amyloid  $\beta$ -related angiitis of the central nervous system occurring after COVID-19 vaccination: A case report  
*Kizawa M, Iwasaki Y*
- 12623** Pseudoileus caused by primary visceral myopathy in a Han Chinese patient with a rare *MYH11* mutation: A case report  
*Li N, Song YM, Zhang XD, Zhao XS, He XY, Yu LF, Zou DW*
- 12631** Emergent use of tube tip in pharynx technique in "cannot intubate cannot oxygenate" situation: A case report  
*Lin TC, Lai YW, Wu SH*
- 12637** Inflammatory myofibroblastic tumor of the central nervous system: A case report  
*Su ZJ, Guo ZS, Wan HT, Hong XY*
- 12648** Atypical aggressive vertebral hemangioma of the sacrum with postoperative recurrence: A case report  
*Wang GX, Chen YQ, Wang Y, Gao CP*
- 12654** Closed reduction of hip dislocation associated with ipsilateral lower extremity fractures: A case report and review of the literature  
*Xu Y, Lv M, Yu SQ, Liu GP*

- 12665** Repair of a large patellar cartilage defect using human umbilical cord blood-derived mesenchymal stem cells: A case report  
*Song JS, Hong KT, Song KJ, Kim SJ*
- 12671** Abdominal bronchogenic cyst: A rare case report  
*Li C, Zhang XW, Zhao CA, Liu M*
- 12678** Malignant fibrous histiocytoma of the axilla with breast cancer: A case report  
*Gao N, Yang AQ, Xu HR, Li L*
- 12684** Rapid hemostasis of the residual inguinal access sites during endovascular procedures: A case report  
*Kim H, Lee K, Cho S, Joh JH*
- 12690** Formation of granulation tissue on bilateral vocal cords after double-lumen endotracheal intubation: A case report  
*Xiong XJ, Wang L, Li T*
- 12696** Giant cellular leiomyoma in the broad ligament of the uterus: A case report  
*Yan J, Li Y, Long XY, Li DC, Li SJ*
- 12703** Pomolidomide for relapsed/refractory light chain amyloidosis after resistance to both bortezomib and daratumumab: A case report  
*Li X, Pan XH, Fang Q, Liang Y*
- 12711** Ureteral- artificial iliac artery fistula: A case report  
*Feng T, Zhao X, Zhu L, Chen W, Gao YL, Wei JL*
- 12717** How to manage isolated tension non-surgical pneumoperitoneum during bronchoscopy? A case report  
*Baima YJ, Shi DD, Shi XY, Yang L, Zhang YT, Xiao BS, Wang HY, He HY*
- 12726** Amiodarone-induced muscle tremor in an elderly patient: A case report  
*Zhu XY, Tang XH, Yu H*
- 12734** Surgical treatment of Pitt-Hopkins syndrome associated with strabismus and early-onset myopia: Two case reports  
*Huang Y, Di Y, Zhang XX, Li XY, Fang WY, Qiao T*
- 12742** Massive low-grade myxoid liposarcoma of the floor of the mouth: A case report and review of literature  
*Kugimoto T, Yamagata Y, Ohsako T, Hirai H, Nishii N, Kayamori K, Ikeda T, Harada H*
- 12750** Gingival enlargement induced by cyclosporine in Medullary aplasia: A case report  
*Victory Rodríguez G, Ruiz Gutiérrez ADC, Gómez Sandoval JR, Lomeli Martínez SM*
- 12761** Compound heterozygous mutations in PMFBP1 cause acephalic spermatozoa syndrome: A case report  
*Deng TQ, Xie YL, Pu JB, Xuan J, Li XM*
- 12768** Colonic tubular duplication combined with congenital megacolon: A case report  
*Zhang ZM, Kong S, Gao XX, Jia XH, Zheng CN*



- 12775** Perforated duodenal ulcer secondary to deferasirox use in a child successfully managed with laparoscopic drainage: A case report  
*Alshehri A, Alsinan TA*
- 12781** Complication after nipple-areolar complex tattooing performed by a non-medical person: A case report  
*Byeon JY, Kim TH, Choi HJ*
- 12787** Interventional urethral balloon dilatation before endoscopic visual internal urethrotomy for post-traumatic bulbous urethral stricture: A case report  
*Ha JY, Lee MS*
- 12793** Regression of gastric endoscopic submucosal dissection induced polypoid nodular scar after *Helicobacter pylori* eradication: A case report  
*Jin BC, Ahn AR, Kim SH, Seo SY*
- 12799** Congenital absence of the right coronary artery: A case report  
*Zhu XY, Tang XH*

**ABOUT COVER**

Editorial Board Member of *World Journal of Clinical Cases*, Giuseppe Lanza, MD, MSc, PhD, Associate Professor, Department of Surgery and Medical-Surgical Specialties, University of Catania, Catania 95123, Italy.  
glanza@oasi.en.it

**AIMS AND SCOPE**

The primary aim of *World Journal of Clinical Cases* (WJCC, *World J Clin Cases*) is to provide scholars and readers from various fields of clinical medicine with a platform to publish high-quality clinical research articles and communicate their research findings online.

WJCC mainly publishes articles reporting research results and findings obtained in the field of clinical medicine and covering a wide range of topics, including case control studies, retrospective cohort studies, retrospective studies, clinical trials studies, observational studies, prospective studies, randomized controlled trials, randomized clinical trials, systematic reviews, meta-analysis, and case reports.

**INDEXING/ABSTRACTING**

The WJCC is now abstracted and indexed in Science Citation Index Expanded (SCIE, also known as SciSearch®), Journal Citation Reports/Science Edition, Current Contents®/Clinical Medicine, PubMed, PubMed Central, Scopus, Reference Citation Analysis, China National Knowledge Infrastructure, China Science and Technology Journal Database, and Superstar Journals Database. The 2022 Edition of Journal Citation Reports® cites the 2021 impact factor (IF) for WJCC as 1.534; IF without journal self cites: 1.491; 5-year IF: 1.599; Journal Citation Indicator: 0.28; Ranking: 135 among 172 journals in medicine, general and internal; and Quartile category: Q4. The WJCC's CiteScore for 2021 is 1.2 and Scopus CiteScore rank 2021: General Medicine is 443/826.

**RESPONSIBLE EDITORS FOR THIS ISSUE**

Production Editor: Si Zhao; Production Department Director: Xu Guo; Editorial Office Director: Jin-Lei Wang.

**NAME OF JOURNAL**

*World Journal of Clinical Cases*

**ISSN**

ISSN 2307-8960 (online)

**LAUNCH DATE**

April 16, 2013

**FREQUENCY**

Thrice Monthly

**EDITORS-IN-CHIEF**

Bao-Gan Peng, Jerzy Tadeusz Chudek, George Kontogeorgos, Maurizio Serati, Ja Hyeon Ku

**EDITORIAL BOARD MEMBERS**

<https://www.wjnet.com/2307-8960/editorialboard.htm>

**PUBLICATION DATE**

December 6, 2022

**COPYRIGHT**

© 2022 Baishideng Publishing Group Inc

**INSTRUCTIONS TO AUTHORS**

<https://www.wjnet.com/bpg/gerinfo/204>

**GUIDELINES FOR ETHICS DOCUMENTS**

<https://www.wjnet.com/bpg/GerInfo/287>

**GUIDELINES FOR NON-NATIVE SPEAKERS OF ENGLISH**

<https://www.wjnet.com/bpg/gerinfo/240>

**PUBLICATION ETHICS**

<https://www.wjnet.com/bpg/GerInfo/288>

**PUBLICATION MISCONDUCT**

<https://www.wjnet.com/bpg/gerinfo/208>

**ARTICLE PROCESSING CHARGE**

<https://www.wjnet.com/bpg/gerinfo/242>

**STEPS FOR SUBMITTING MANUSCRIPTS**

<https://www.wjnet.com/bpg/GerInfo/239>

**ONLINE SUBMISSION**

<https://www.f6publishing.com>



## Formation of granulation tissue on bilateral vocal cords after double-lumen endotracheal intubation: A case report

Xiao-Juan Xiong, Li Wang, Ting Li

**Specialty type:** Medicine, research and experimental

**Provenance and peer review:** Unsolicited article; Externally peer reviewed.

**Peer-review model:** Single blind

**Peer-review report's scientific quality classification**

Grade A (Excellent): 0  
Grade B (Very good): B  
Grade C (Good): C  
Grade D (Fair): 0  
Grade E (Poor): 0

**P-Reviewer:** Jha P, United States; Thongon N, Thailand

**Received:** July 21, 2022

**Peer-review started:** July 21, 2022

**First decision:** October 12, 2022

**Revised:** October 22, 2022

**Accepted:** November 4, 2022

**Article in press:** November 4, 2022

**Published online:** December 6, 2022



**Xiao-Juan Xiong, Li Wang, Ting Li,** Department of Anesthesiology, Army Medical Center of PLA, Daping Hospital, Army Medical University, Chongqing 400042, China

**Corresponding author:** Ting Li, MD, Attending Doctor, Doctor, Department of Anesthesiology, Army Medical Center of PLA, Daping Hospital, Army Medical University, No. 10 Changjiang Zhilu, Yuzhong District, Chongqing 400042, China. [569304104@qq.com](mailto:569304104@qq.com)

### Abstract

#### BACKGROUND

Most case reports on laryngeal granuloma formation have described patients after tracheotomy and single-lumen endotracheal intubation. Few studies have investigated vocal cord granuloma formation after double-lumen endotracheal (DLT) intubation.

#### CASE SUMMARY

We report granulation tissue formation on the bilateral vocal cords after DLT intubation in a 45-year-old, 153-cm-tall female patient. Previous imaging reports showed no formation of vocal cord granuloma before DLT intubation. Therefore, we inferred that DLT intubation may have been the main reason for the postoperative granulation tissue formation on her bilateral vocal cords, based on the patient's history of DLT intubation, persistent hoarseness after thoracic surgery, and fibrolaryngoscopic and pathological reports during 12 mo follow-up.

#### CONCLUSION

Thirty-two Fr DLT tubes should be utilized for thoracic surgery on female patients who are shorter than 153 cm in height.

**Key Words:** DLT; Double-lumen endotracheal; Granulation; Vocal cords; Case report

©The Author(s) 2022. Published by Baishideng Publishing Group Inc. All rights reserved.

**Core Tip:** Most case reports on laryngeal granuloma formation have been reported on patients after tracheotomy and single-lumen endotracheal intubation. Few studies have investigated vocal cord granuloma formation after double-lumen endotracheal (DLT) intubation. We reported a case of a 45-year-old woman with granulation tissue formation of the bilateral vocal cords after lobectomy with DLT. We found that a 32 Fr DLT tube should be selected for thoracic surgery for female patients below 153 cm in height. This study is intended to act as a reference for those seeking to identify people at a high risk of developing airway granulomas and lower the frequency of such complications.

**Citation:** Xiong XJ, Wang L, Li T. Formation of granulation tissue on bilateral vocal cords after double-lumen endotracheal intubation: A case report. *World J Clin Cases* 2022; 10(34): 12690-12695

**URL:** <https://www.wjgnet.com/2307-8960/full/v10/i34/12690.htm>

**DOI:** <https://dx.doi.org/10.12998/wjcc.v10.i34.12690>

## INTRODUCTION

Double-lumen endotracheal (DLT) intubation is now widely applied in thoracic surgery for most cases of lung isolation and perioperative one-lung ventilation. However, compared with single-lumen endotracheal (SLT) intubation, the DLT tube is stiffer. It has a larger external diameter and is more likely to cause postoperative complications[1], such as airway granuloma formation. Previous studies suggested that incidences of granuloma after SLT intubation are rare[2]. Most case reports on laryngeal granuloma formation have been reported on patients after tracheotomy and SLT intubation. There are few case reports on vocal cord granuloma formation after DLT intubation. We report a case of a 45-year-old woman with granulation tissue formation on the bilateral vocal cords after lobectomy with DLT intubation.

## CASE PRESENTATION

### Chief complaints

A 45-year-old woman of a height of 153 cm and weighing 49 kg, who was an employee of the sales industry, was admitted to our department. She complained of nodules in the right upper lobe that had been observed during a routine physical examination 1 mo previously.

### History of present illness

During anesthesia induction, midazolam (2 mg), etomidate (20 mg), sufentanil (25 µg), and cisatracurium (10 mg) were administered intravenously. A left 35 Fr DLT tube (PVC; Wellhead, China) was inserted orally and smoothly with an ordinary laryngoscope. Then, endotracheal intubation was performed by an anesthesiologist with 1 year of experience, and the position of the DLT tube was examined carefully by fiberoptic bronchoscopy. The patient underwent thoracoscopic wedge resection of the right lower lobe without re-positioning the DLT tube.

After surgery, her respiratory signs, muscle strength, and consciousness recovered well, and after 80 min intubation, the DLT tube was removed. The patient experienced hoarseness for 1 mo after discharge but did not seek any medical remediation.

### History of past illness

She denied having a history of hypertension, diabetes, surgery, drug or food allergies, drug use, smoking, alcohol consumption, or a family history of vocal granuloma formation. The patient had no preoperative complaints of sore throat, hoarseness, cough, or gastroesophageal reflux.

### Personal and family history

She denied having a history or a family history of vocal granuloma formation.

### Physical examination

According to the Classification System of the American Society of Anesthesiologists, Mallampati II, her physical status included a normal thyromental distance and a low risk of airway difficulty.

### Laboratory examinations

According to preoperative laboratory examinations, she had no history of syphilis, acquired immune deficiency syndrome, or other infectious diseases.

### Imaging examinations

She underwent fibrolaryngoscopy due to "snoring and dry mouth" 7 mo before the thoracic surgery, and no significant abnormalities were observed (Figure 1A). There was no neoplasm of the glottis on preoperative chest computed tomography (Figure 2). A repeat fibrolaryngoscopy revealed her bilateral vocal cords to be slightly swollen, with a smooth surface, normal motility, poor closure, and granulation tissue protrusions in the bilateral arytenoid region (Figure 1B). Later, her bilateral vocal cords became more swollen under fibrolaryngoscopy. Granulation was observed in the bilateral arytenoid area, and the area of granulation of the right vocal cords (Figure 1C) was larger than that in the previous examination (Figure 1B) and virtually blocked the glottis. On day 105 after thoracic surgery, during follow-up, a fibrolaryngoscopy showed no granulation tissue formation at the glottis (Figure 1D).

## FINAL DIAGNOSIS

Pathological investigation of the resected lesion revealed neoplasms and polyps on both vocal cords and a large amount of granulation tissue (Figure 3).

## TREATMENT

On day 51 after thoracic surgery, she experienced intermittent and recurrent episodes of hoarseness, especially after excessive talking, accompanied by laboured speech and mild dyspnea. However, the symptoms failed to diminish after the patient received medicine for 10 d (montelukast, 10 mg, qd and methoxyphenamine, 25 mg, po tid). She noted worsening hoarseness and dyspnea on postoperative day 73. Therefore, she received resection of the bilateral vocal cord lesion with supporting laryngoscopy on day 75 after thoracic surgery.

## OUTCOME AND FOLLOW-UP

On day 105 after thoracic surgery, during follow-up, a fibrolaryngoscopy showed no granulation tissue formation at the glottis (Figure 1D).

## DISCUSSION

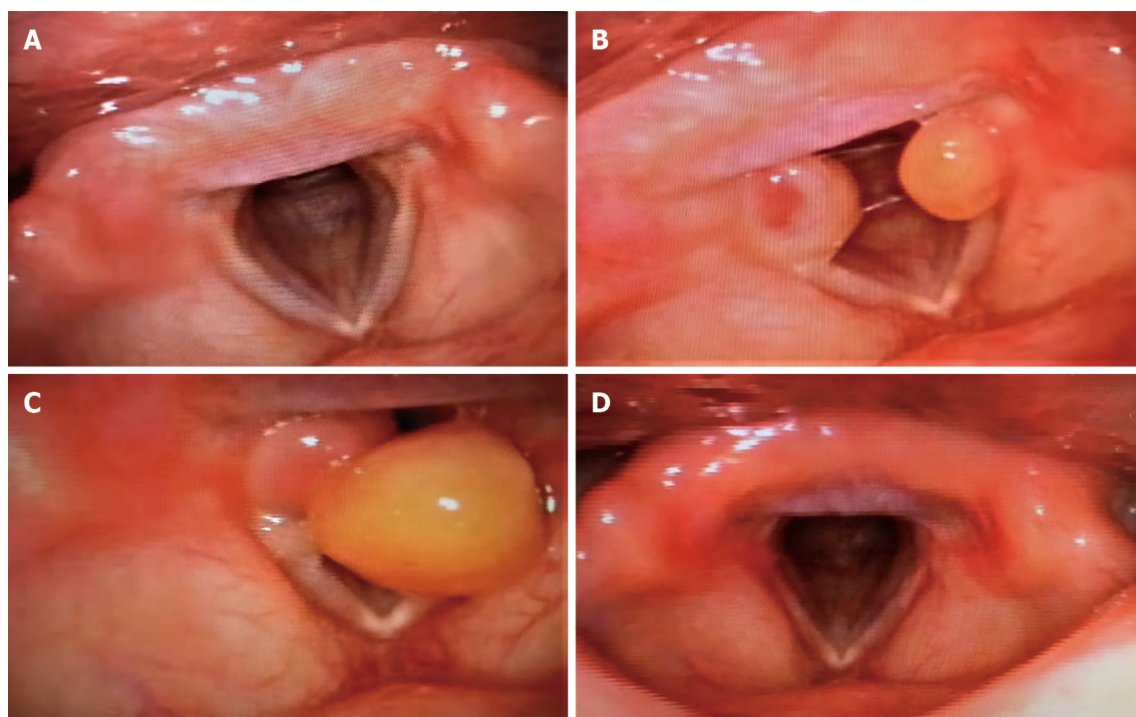
Laryngeal granulomas are benign and nontumorous, and unilateral/bilateral lesions are more likely to develop in the posterior third of the vocal cords, specifically the vocal processes of the arytenoid cartilage, but also occur in the posterior and lateral parts of the cricoid cartilage in the subglottic larynx [3]. According to Poiseuille's law, minor changes to the diameter of the laryngotracheal stem and the length of the narrowed segment result in significant variations in airflow. Hoarseness occurs when the airway size reduces by 30%; dyspnea occurs when the airway shrinks by 80%, and severe airway size reduction can lead to difficulty breathing and swallowing and voice alterations [4]. Treatment of vocal cord granuloma is primarily conservative, either through the amelioration of irritation or the use of medication [3,5]. Surgical excision is rare and only adopted in severe cases [5].

This is the first paper on the granulation tissue formation of vocal cords after DLT intubation, supported by imaging and pathological reports during follow-up. In this case, the causes of postoperative granulation tissue formation on the bilateral vocal cords may be explained as follows.

### DLT

The DLT tube is a curved endobronchial tube that has the potential to cause harm to the patient [5]. DLT tubes are often made of PVC materials with an oblique cut at the end, which increases the risk of touching the vocal cords during intubation and extubation. Laryngeal injury caused by direct pressure from the endotracheal tube can result in mucosal ulceration and inflammation, leading to granuloma formation [5]. In addition, the high pressure applied by balloon cuffs or tubes surpasses the capillary pressure, posing the risk of loss of local blood flow and the inducement of local ischemia or necrosis [6]. The fibrinolytic pathway is thus stimulated, generating a proliferative phase, characterized by angiogenesis, collagen deposition, and granulation tissue formation, followed by a phase of maturation and remodeling with membranous web-like stenosis [6].

One previous study suggested that 32 Fr DLT intubation might only be appropriate for women shorter than 153 cm [7]. However, we selected a 35 Fr left DLT tube for our female patient, who was 153 cm tall. The distance between the trachea and the bronchial cuff was 10.1 cm *vs* 10.3 cm between the glottis and carina. D'Anza *et al* [8] found that, in both men and women, the tracheal cross-sectional area



DOI: 10.12998/wjcc.v10.i34.12690 Copyright ©The Author(s) 2022.

**Figure 1** Fibrolaryngoscopy changes of the glottis before and after thoracic surgery. A: Fibrolaryngoscopy 6 mo before thoracic surgery showed no neoplasm at the glottis; B: Fibrolaryngoscopy 51 d after thoracic surgery revealed granulation tissue in the bilateral arytenoid region of vocal cords; C: Fibrolaryngoscopy 73 d after thoracic surgery revealed granulation tissue in the bilateral arytenoid region of vocal cords; D: Fibrolaryngoscopy 105 d after thoracic surgery revealed no granulation tissue in the bilateral arytenoid region of vocal cords.

increased with height. Gelbard *et al*[9] concluded that the passage of oversized endotracheal tubes through the commonly smaller female trachea might contribute to tracheal injury and subsequent stenosis. At a given depth, the cuff fitted more tightly in the trachea, closer to the vocal cords, and was associated with mucosal tracheal compression over a longer segment[10]. Therefore, the DLT main tracheal cuff was probably positioned at the vocal cords. Once inflated, the cuff could have easily compressed the vocal cords.

### Gender factor

Female patients are prone to developing intubation-related granulomas and account for 75%-90% of all cases[11]. This is because of their narrower and lower glottis and thinner arytenoid cartilage[12] compared to men.

### Vocal cord overuse

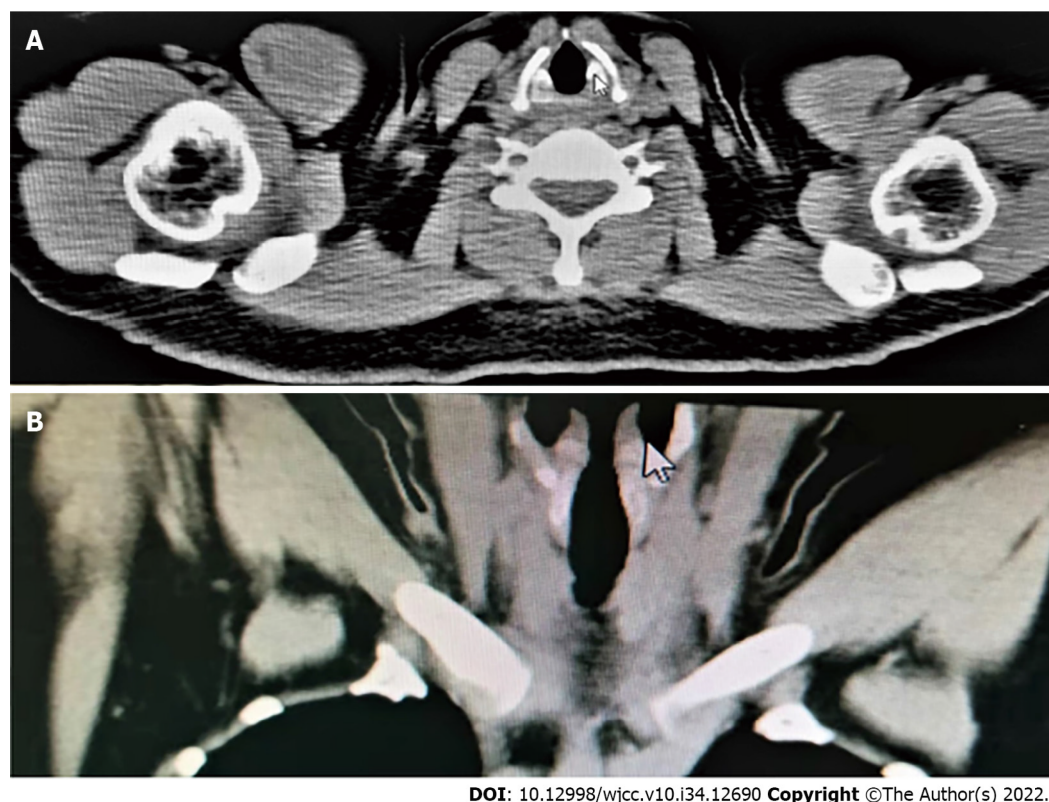
Excessive use of the vocal cords and chronic cough are predisposing factors for forming granulomas after intubation[3]. Traumatic collisions of the vocal cords occur during absurd pronunciation, and a chronic cough can cause stress to the vocal cords after intubation. Therefore, the cricoid cartilage epithelium may be injured, and tissue healing delayed[3,13]. Our patient, a sales woman, might have overused her vocal cords during work after surgery. Unfortunately, she did not receive proper or prompt treatment after experiencing hoarseness.

### Operating factors of endotracheal intubation

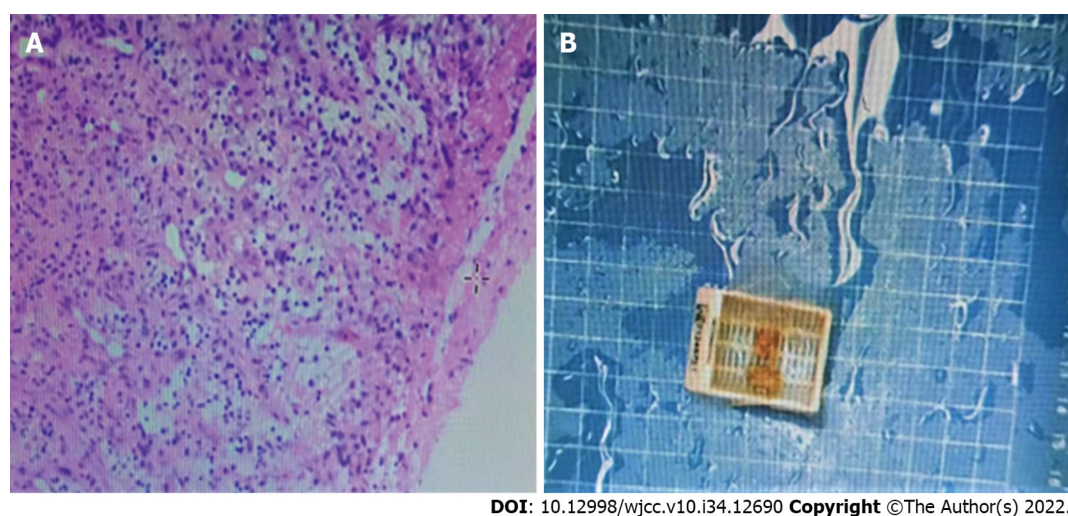
In this case, fibrolaryngoscopy showed that the polyp on the right vocal cord, which almost blocked the glottis, was larger than the polyp on the left. The right vocal cord was at risk of granulation tissue formation when the tube tip injured it. This can be explained by the fact that most endotracheal intubation operators carry the laryngoscope handle in their left hand while using their right hand to perform the intubation procedure[14]. Furthermore, we also suggest that DLT should perform by an anesthesiologist experienced in endotracheal intubation.

During follow-up, the patient admitted that she should have sought medical advice when she experienced persistent hoarseness 1 wk after her thoracic surgery. She was also reminded of her elevated risk of airway granulomas. We noted that a smaller and softer DLT tube should be used in further potential thoracic surgery.





**Figure 2** No neoplasm at the glottis was observed on chest computed tomography during thoracic surgery. A: Cross-section or longitudinal chest computed tomography; B: Longitudinal chest computed tomography.



**Figure 3** Pathological report after vocal cord polypectomy showed bilateral vocal cord polyps with a large amount of granulation tissue in the stroma. A: Pathological section diagram; B: Pathological examination (hematoxylin-eosin staining).

## CONCLUSION

According to our observations and assessment, female patients of a short stature (less than 153 cm) are considered high-risk for the formation of vocal cord granulomas after DLT intubation. Therefore, for female patients shorter than 153 cm, a 32 Fr DLT tube should be selected.

## FOOTNOTES

**Author contributions:** Xiong XJ, Li T and Wang L contributed equally to this work; Xiong XJ, Li T and Wang L

designed the research study; Xiong XJ, Li T and Wang L performed the research; Xiong XJ, Li T and Wang L contributed new reagents and analytic tools; Xiong XJ and Li T analyzed the data and wrote the manuscript; all authors have read and approve the final manuscript.

**Informed consent statement:** Informed written consent was obtained from the patient for publication of this report and any accompanying images.

**Conflict-of-interest statement:** All the authors report no relevant conflicts of interest for this article.

**CARE Checklist (2016) statement:** The authors have read the CARE Checklist (2016), and the manuscript was prepared and revised according to the CARE Checklist (2016).

**Open-Access:** This article is an open-access article that was selected by an in-house editor and fully peer-reviewed by external reviewers. It is distributed in accordance with the Creative Commons Attribution NonCommercial (CC BY-NC 4.0) license, which permits others to distribute, remix, adapt, build upon this work non-commercially, and license their derivative works on different terms, provided the original work is properly cited and the use is non-commercial. See: <https://creativecommons.org/licenses/by-nc/4.0/>

**Country/Territory of origin:** China

**ORCID number:** Xiao-Juan Xiong 0000-0002-5693-0544; Li Wang 0000-0002-7655-8073; Ting Li 0000-0003-3941-9602.

**S-Editor:** Wei ZH

**L-Editor:** A

**P-Editor:** Wei ZH

## REFERENCES

- 1 **Seo JH**, Cho CW, Hong DM, Jeon Y, Bahk JH. The effects of thermal softening of double-lumen endobronchial tubes on postoperative sore throat, hoarseness and vocal cord injuries: a prospective double-blind randomized trial. *Br J Anaesth* 2016; **116**: 282-288 [PMID: 26787799 DOI: 10.1093/bja/aev414]
- 2 **Naito K**, Iwata S, Nishimura T, Takasu A, Kuwauchi T, Yaida M. Nine cases with postintubation granuloma of the larynx. *Auris Nasus Larynx* 1982; **9**: 111-115 [PMID: 7159298 DOI: 10.1016/s0385-8146(82)80008-4]
- 3 **Rimoli CF**, Martins RHG, Catâneo DC, Imamura R, Catâneo AJM. Treatment of post-intubation laryngeal granulomas: systematic review and proportional meta-analysis. *Braz J Otorhinolaryngol* 2018; **84**: 781-789 [PMID: 29699879 DOI: 10.1016/j.bjorl.2018.03.003]
- 4 **Hast MH**. The developmental anatomy of the larynx. *Otolaryngol Clin North Am* 1970; **3**: 413-438 [PMID: 5520248]
- 5 **Knoll H**, Ziegeler S, Schreiber JU, Buchinger H, Bialas P, Semyonov K, Graeter T, Mencke T. Airway injuries after one-lung ventilation: a comparison between double-lumen tube and endobronchial blocker: a randomized, prospective, controlled trial. *Anesthesiology* 2006; **105**: 471-477 [PMID: 16931978 DOI: 10.1097/0000542-200609000-00009]
- 6 **Nikolovski N**, Kopacheva-Barsova G, Pejkovska A. Laryngotracheal Stenosis: A Retrospective Analysis of Their Aetiology, Diagnose and Treatment. *Open Access Maced J Med Sci* 2019; **7**: 1649-1656 [PMID: 31210816 DOI: 10.3889/oamjms.2019.339]
- 7 **Seo JH**, Kwon TK, Jeon Y, Hong DM, Kim HJ, Bahk JH. Comparison of techniques for double-lumen endobronchial intubation: 90° or 180° rotation during advancement through the glottis. *Br J Anaesth* 2013; **111**: 812-817 [PMID: 23794671 DOI: 10.1093/bja/aet203]
- 8 **D'Anza B**, Knight J, Greene JS. Does body mass index predict tracheal airway size? *Laryngoscope* 2015; **125**: 1093-1097 [PMID: 25251641 DOI: 10.1002/lary.24943]
- 9 **Gelbard A**, Francis DO, Sandulache VC, Simmons JC, Donovan DT, Ongkasuwan J. Causes and consequences of adult laryngotracheal stenosis. *Laryngoscope* 2015; **125**: 1137-1143 [PMID: 25290987 DOI: 10.1002/lary.24956]
- 10 **Karmali S**, Rose P. Tracheal tube size in adults undergoing elective surgery - a narrative review. *Anaesthesia* 2020; **75**: 1529-1539 [PMID: 32415788 DOI: 10.1111/anae.15041]
- 11 **Drosnes DL**, Zwillenberg DA. Laryngeal granulomatous polyp after short-term intubation of a child. *Ann Otol Rhinol Laryngol* 1990; **99**: 183-186 [PMID: 2310133]
- 12 **Park SY**, Choi HS, Yoon JY, Kim EJ, Yoon JU, Kim HY, Ahn JH. Fatal vocal cord granuloma after orthognathic surgery. *J Dent Anesth Pain Med* 2018; **18**: 375-378 [PMID: 30637348 DOI: 10.17245/jdpm.2018.18.6.375]
- 13 **Ogawa M**, Hosokawa K, Iwahashi T, Inohara H. The results of Kaplan-Meier and multivariate analyses of etiological factors related to the outcome of combined pharmacological therapy against laryngeal granuloma. *Acta Otolaryngol* 2016; **136**: 1141-1146 [PMID: 27328639 DOI: 10.1080/00016489.2016.1193891]
- 14 **Berry JM**, Harvey S. Laryngoscopic Orotracheal and Nasotracheal Intubation. In Benumof and Hagberg's Airway Management: Third Edition. Elsevier Inc. 2013; 346-358 [DOI: 10.1016/b978-1-4377-2764-7.00017-8]





Published by **Baishideng Publishing Group Inc**  
7041 Koll Center Parkway, Suite 160, Pleasanton, CA 94566, USA

**Telephone:** +1-925-3991568

**E-mail:** [bpgoffice@wjgnet.com](mailto:bpgoffice@wjgnet.com)

**Help Desk:** <https://www.f6publishing.com/helpdesk>

<https://www.wjgnet.com>

