

World Journal of *Clinical Cases*

World J Clin Cases 2022 December 6; 10(34): 12462-12803



Contents

Thrice Monthly Volume 10 Number 34 December 6, 2022

FIELD OF VISION

- 12462** Problematics of neurosurgical service during the COVID-19 pandemic in Slovenia
Munda M, Bosnjak R, Velnar T

MINIREVIEWS

- 12470** Circulating angiotensin converting enzyme 2 and COVID-19
Leowattana W, Leowattana T, Leowattana P
- 12484** Evaluation of gut dysbiosis using serum and fecal bile acid profiles
Monma T, Iwamoto J, Ueda H, Tamamushi M, Kakizaki F, Konishi N, Yara S, Miyazaki T, Hirayama T, Ikegami T, Honda A
- 12494** Pediatric kidney transplantation during the COVID-19 pandemic
Tamura H

ORIGINAL ARTICLE

Clinical and Translational Research

- 12500** *Coptis*, *Pinellia*, and *Scutellaria* as a promising new drug combination for treatment of *Helicobacter pylori* infection
Yu Z, Sheng WD, Yin X, Bin Y

Case Control Study

- 12515** Effects of illness perception on negative emotions and fatigue in chronic rheumatic diseases: Rumination as a possible mediator
Lu Y, Jin X, Feng LW, Tang C, Neo M, Ho RC

Retrospective Study

- 12532** Significance of incidental focal fluorine-18 fluorodeoxyglucose uptake in colon/rectum, thyroid, and prostate: With a brief literature review
Lee H, Hwang KH
- 12543** Follow-up study on ThinPrep cytology test-positive patients in tropical regions
Chen YC, Liang CN, Wang XF, Wang MF, Huang XN, Hu JD
- 12551** Effect of teach-back health education combined with structured psychological nursing on adverse emotion and patient cooperation during ^{99m}Tc -3PRGD2.SPECT/CT
Gong WN, Zhang YH, Niu J, Li XB
- 12559** Nosocomial infection and spread of SARS-CoV-2 infection among hospital staff, patients and caregivers
Cheng CC, Fann LY, Chou YC, Liu CC, Hu HY, Chu D

Observational Study

- 12566** Effectiveness and safety of generic and brand direct acting antivirals for treatment of chronic hepatitis C
Abdulla M, Al Ghareeb AM, Husain HAHY, Mohammed N, Al Qamish J

- 12578** Influence of group B *streptococcus* and vaginal cleanliness on the vaginal microbiome of pregnant women
Liao Q, Zhang XF, Mi X, Jin F, Sun HM, Wang QX

Randomized Controlled Trial

- 12587** Clinical study on tri-tongue acupuncture combined with low-frequency electrical stimulation for treating post-stroke dysarthria
Man B, Li WW, Xu JF, Wang Q

META-ANALYSIS

- 12594** Three-dimensional time-of-flight magnetic resonance angiography combined with high resolution T2-weighted imaging in preoperative evaluation of microvascular decompression
Liang C, Yang L, Zhang BB, Guo SW, Li RC

CASE REPORT

- 12605** Acute cytomegalovirus hepatitis in an immunocompetent patient: A case report
Wang JP, Lin BZ, Lin CL, Chen KY, Lin TJ
- 12610** Long-term results of extended Boari flap technique for management of complete ureteral avulsion: A case report
Zhong MZ, Huang WN, Huang GX, Zhang EP, Gan L
- 12617** Amyloid β -related angiitis of the central nervous system occurring after COVID-19 vaccination: A case report
Kizawa M, Iwasaki Y
- 12623** Pseudoileus caused by primary visceral myopathy in a Han Chinese patient with a rare *MYH11* mutation: A case report
Li N, Song YM, Zhang XD, Zhao XS, He XY, Yu LF, Zou DW
- 12631** Emergent use of tube tip in pharynx technique in "cannot intubate cannot oxygenate" situation: A case report
Lin TC, Lai YW, Wu SH
- 12637** Inflammatory myofibroblastic tumor of the central nervous system: A case report
Su ZJ, Guo ZS, Wan HT, Hong XY
- 12648** Atypical aggressive vertebral hemangioma of the sacrum with postoperative recurrence: A case report
Wang GX, Chen YQ, Wang Y, Gao CP
- 12654** Closed reduction of hip dislocation associated with ipsilateral lower extremity fractures: A case report and review of the literature
Xu Y, Lv M, Yu SQ, Liu GP

- 12665** Repair of a large patellar cartilage defect using human umbilical cord blood-derived mesenchymal stem cells: A case report
Song JS, Hong KT, Song KJ, Kim SJ
- 12671** Abdominal bronchogenic cyst: A rare case report
Li C, Zhang XW, Zhao CA, Liu M
- 12678** Malignant fibrous histiocytoma of the axilla with breast cancer: A case report
Gao N, Yang AQ, Xu HR, Li L
- 12684** Rapid hemostasis of the residual inguinal access sites during endovascular procedures: A case report
Kim H, Lee K, Cho S, Joh JH
- 12690** Formation of granulation tissue on bilateral vocal cords after double-lumen endotracheal intubation: A case report
Xiong XJ, Wang L, Li T
- 12696** Giant cellular leiomyoma in the broad ligament of the uterus: A case report
Yan J, Li Y, Long XY, Li DC, Li SJ
- 12703** Pomolidomide for relapsed/refractory light chain amyloidosis after resistance to both bortezomib and daratumumab: A case report
Li X, Pan XH, Fang Q, Liang Y
- 12711** Ureteral- artificial iliac artery fistula: A case report
Feng T, Zhao X, Zhu L, Chen W, Gao YL, Wei JL
- 12717** How to manage isolated tension non-surgical pneumoperitoneum during bronchoscopy? A case report
Baima YJ, Shi DD, Shi XY, Yang L, Zhang YT, Xiao BS, Wang HY, He HY
- 12726** Amiodarone-induced muscle tremor in an elderly patient: A case report
Zhu XY, Tang XH, Yu H
- 12734** Surgical treatment of Pitt-Hopkins syndrome associated with strabismus and early-onset myopia: Two case reports
Huang Y, Di Y, Zhang XX, Li XY, Fang WY, Qiao T
- 12742** Massive low-grade myxoid liposarcoma of the floor of the mouth: A case report and review of literature
Kugimoto T, Yamagata Y, Ohsako T, Hirai H, Nishii N, Kayamori K, Ikeda T, Harada H
- 12750** Gingival enlargement induced by cyclosporine in Medullary aplasia: A case report
Victory Rodríguez G, Ruiz Gutiérrez ADC, Gómez Sandoval JR, Lomeli Martínez SM
- 12761** Compound heterozygous mutations in PMFBP1 cause acephalic spermatozoa syndrome: A case report
Deng TQ, Xie YL, Pu JB, Xuan J, Li XM
- 12768** Colonic tubular duplication combined with congenital megacolon: A case report
Zhang ZM, Kong S, Gao XX, Jia XH, Zheng CN

- 12775** Perforated duodenal ulcer secondary to deferasirox use in a child successfully managed with laparoscopic drainage: A case report
Alshehri A, Alsinan TA
- 12781** Complication after nipple-areolar complex tattooing performed by a non-medical person: A case report
Byeon JY, Kim TH, Choi HJ
- 12787** Interventional urethral balloon dilatation before endoscopic visual internal urethrotomy for post-traumatic bulbous urethral stricture: A case report
Ha JY, Lee MS
- 12793** Regression of gastric endoscopic submucosal dissection induced polypoid nodular scar after *Helicobacter pylori* eradication: A case report
Jin BC, Ahn AR, Kim SH, Seo SY
- 12799** Congenital absence of the right coronary artery: A case report
Zhu XY, Tang XH

ABOUT COVER

Editorial Board Member of *World Journal of Clinical Cases*, Giuseppe Lanza, MD, MSc, PhD, Associate Professor, Department of Surgery and Medical-Surgical Specialties, University of Catania, Catania 95123, Italy.
glanza@oasi.en.it

AIMS AND SCOPE

The primary aim of *World Journal of Clinical Cases* (WJCC, *World J Clin Cases*) is to provide scholars and readers from various fields of clinical medicine with a platform to publish high-quality clinical research articles and communicate their research findings online.

WJCC mainly publishes articles reporting research results and findings obtained in the field of clinical medicine and covering a wide range of topics, including case control studies, retrospective cohort studies, retrospective studies, clinical trials studies, observational studies, prospective studies, randomized controlled trials, randomized clinical trials, systematic reviews, meta-analysis, and case reports.

INDEXING/ABSTRACTING

The WJCC is now abstracted and indexed in Science Citation Index Expanded (SCIE, also known as SciSearch®), Journal Citation Reports/Science Edition, Current Contents®/Clinical Medicine, PubMed, PubMed Central, Scopus, Reference Citation Analysis, China National Knowledge Infrastructure, China Science and Technology Journal Database, and Superstar Journals Database. The 2022 Edition of Journal Citation Reports® cites the 2021 impact factor (IF) for WJCC as 1.534; IF without journal self cites: 1.491; 5-year IF: 1.599; Journal Citation Indicator: 0.28; Ranking: 135 among 172 journals in medicine, general and internal; and Quartile category: Q4. The WJCC's CiteScore for 2021 is 1.2 and Scopus CiteScore rank 2021: General Medicine is 443/826.

RESPONSIBLE EDITORS FOR THIS ISSUE

Production Editor: Si Zhao; Production Department Director: Xu Guo; Editorial Office Director: Jin-Lei Wang.

NAME OF JOURNAL

World Journal of Clinical Cases

ISSN

ISSN 2307-8960 (online)

LAUNCH DATE

April 16, 2013

FREQUENCY

Thrice Monthly

EDITORS-IN-CHIEF

Bao-Gan Peng, Jerzy Tadeusz Chudek, George Kontogeorgos, Maurizio Serati, Ja Hyeon Ku

EDITORIAL BOARD MEMBERS

<https://www.wjnet.com/2307-8960/editorialboard.htm>

PUBLICATION DATE

December 6, 2022

COPYRIGHT

© 2022 Baishideng Publishing Group Inc

INSTRUCTIONS TO AUTHORS

<https://www.wjnet.com/bpg/gerinfo/204>

GUIDELINES FOR ETHICS DOCUMENTS

<https://www.wjnet.com/bpg/GerInfo/287>

GUIDELINES FOR NON-NATIVE SPEAKERS OF ENGLISH

<https://www.wjnet.com/bpg/gerinfo/240>

PUBLICATION ETHICS

<https://www.wjnet.com/bpg/GerInfo/288>

PUBLICATION MISCONDUCT

<https://www.wjnet.com/bpg/gerinfo/208>

ARTICLE PROCESSING CHARGE

<https://www.wjnet.com/bpg/gerinfo/242>

STEPS FOR SUBMITTING MANUSCRIPTS

<https://www.wjnet.com/bpg/GerInfo/239>

ONLINE SUBMISSION

<https://www.f6publishing.com>



Giant cellular leiomyoma in the broad ligament of the uterus: A case report

Jiao Yan, Yu Li, Xing-Yu Long, Dao-Cheng Li, Si-Jin Li

Specialty type: Surgery

Provenance and peer review:

Unsolicited article; Externally peer reviewed.

Peer-review model: Single blind

Peer-review report's scientific quality classification

Grade A (Excellent): 0

Grade B (Very good): 0

Grade C (Good): C, C

Grade D (Fair): D

Grade E (Poor): 0

P-Reviewer: Gislinge JIP, Denmark; Hegazy AA, Egypt

Received: July 28, 2022

Peer-review started: July 28, 2022

First decision: September 27, 2022

Revised: October 11, 2022

Accepted: November 2, 2022

Article in press: November 2, 2022

Published online: December 6, 2022



Jiao Yan, Xing-Yu Long, The First Clinical Medical College, Guangzhou University of Chinese Medicine, Guangzhou 510000, Guangdong Province, China

Yu Li, The Sixth Clinical Medical College, Guangzhou University of Chinese Medicine, Guangzhou 510000, Guangdong Province, China

Dao-Cheng Li, Si-Jin Li, Department of Obstetrics and Gynecology, The First Affiliated Hospital of Guangzhou University of Chinese Medicine, Guangzhou 510000, Guangdong Province, China

Corresponding author: Dao-Cheng Li, PhD, Doctor, Department of Obstetrics and Gynecology, The First Affiliated Hospital of Guangzhou University of Chinese Medicine, No. 16 Airport Road, Guangzhou 510000, Guangdong Province, China. daochenli@126.com

Abstract

BACKGROUND

The treatment of large pelvic masses in postmenopausal women is a challenge in clinical practice. Although ultrasound or magnetic resonance imaging can be used to determine the size and location of the mass, it is still difficult to achieve a preoperative diagnosis. The majority of cellular leiomyomas are diagnosed by histopathology after surgery. We report the differential diagnosis and surgical management of a rare case of cellular leiomyoma in the broad ligament of the uterus.

CASE SUMMARY

A 52-year-old Chinese woman without sexual history was admitted to the First Affiliated Hospital of Guangzhou University of Chinese Medicine for the first time. The patient had a 1-year history of progressive abdominal enlargement as well as a 2-year history of menopause, and complained of frequent abdominal pain and low-grade fever. Computed tomography of the abdomen showed a solid cystic mass (29.4 cm × 18.8 cm × 37.7 cm) in the pelvis and abdomen. Moreover, routine blood test results indicated a baseline cancer antigen 125 (CA-125) level of 187.7 U/mL and C-reactive protein of 109.58 mg/L. Subsequently, retrograde hysterectomy and bilateral adnexectomy were performed in this patient. On histopathologic examination of the surgical specimen, a rare cellular leiomyoma in the broad ligament was diagnosed.

CONCLUSION

Clinicians need to constantly improve diagnosis and treatment for the challenges

posed during clinical assessment, differential diagnosis, and surgical management.

Key Words: Surgical oncology; Cellular leiomyoma in the broad ligament; Uterine leiomyoma; Retrograde abdominal hysterectomy; Case report

©The Author(s) 2022. Published by Baishideng Publishing Group Inc. All rights reserved.

Core Tip: Initially, a gynecological malignancy was suspected due to an elevated tumor blood index and large abdominal mass of unknown nature in this unmarried, childless middle-aged woman. The importance of differential diagnosis in this case was crucial and removal of the mass was also challenging. We performed an unconventional hysterectomy to ensure a smooth operation, which indicates the importance of surgical choice.

Citation: Yan J, Li Y, Long XY, Li DC, Li SJ. Giant cellular leiomyoma in the broad ligament of the uterus: A case report. *World J Clin Cases* 2022; 10(34): 12696-12702

URL: <https://www.wjgnet.com/2307-8960/full/v10/i34/12696.htm>

DOI: <https://dx.doi.org/10.12998/wjcc.v10.i34.12696>

INTRODUCTION

Cellular leiomyoma arising in the broad ligament of the uterus is extremely rare, with only five cases reported to date. Furthermore, the preoperative diagnosis of cellular leiomyoma poses a great challenge for clinicians. On the one hand, its clinical presentation is similar to that of ovarian cancer, such as enlargement of abdominal masses and increased tumor markers (CA-125) after the menopause[1]. On the other hand, all cellular leiomyomas in the broad ligament were diagnosed by intraoperative observation and postoperative pathology. In our study, the sixth case of giant cellular leiomyoma in the broad ligament with cystic and mucinous lesions is reported.

CASE PRESENTATION

Chief complaints

The patient had recurrent abdominal distension for 1 year, accompanied by left upper abdominal pain for 4 d.

History of present illness

Due to low-grade fever and abdominal pain for 4 d, the woman was admitted to the emergency department of the First Affiliated Hospital of Guangzhou University of Chinese Medicine.

History of past illness

Except for congenital neurofibroma accompanied by local pigmentation throughout the body and prominent skin with scattered small masses, she had no specific previous medical history.

Personal and family history

The patient was a 52-year-old Chinese postmenopausal woman who was unmarried and childless, without a sexual history. She had no drug history or family history. In addition, the patient had no history of smoking or drinking.

Physical examination

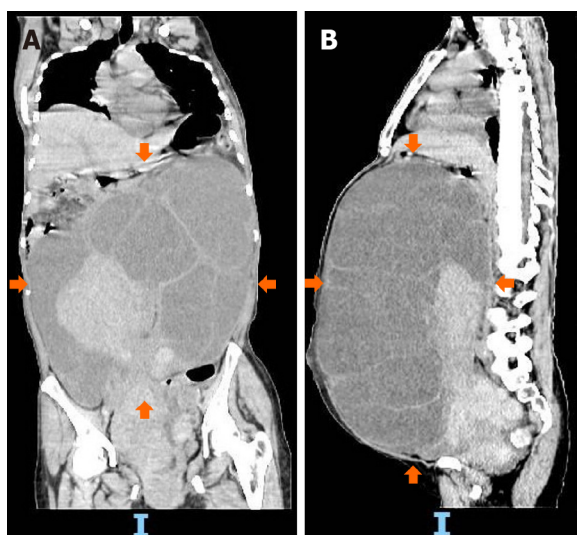
Abdominal examination revealed an abdominal mass corresponding to the abdominal size at 37 wk gestation (located below the xiphoid process). Anal examination revealed a large solid cystic mass with well-defined borders in the pelvic abdomen.

Laboratory examinations

An elevated baseline CA-125 level of 187.7 U/mL was observed.

Imaging examinations

As shown by computed tomography (Figure 1), a solid cystic mass (29.4 cm × 18.8 cm × 37.7 cm) was



DOI: 10.12998/wjcc.v10.i34.12696 Copyright ©The Author(s) 2022.

Figure 1 Preoperative computed tomography images of the patient. A and B: Computed tomography shows a large cystic solid mass in the pelvic and abdominal cavity (orange arrows).

found in the pelvis and abdomen (Figure 2).

FINAL DIAGNOSIS

Right broad ligament uterine leiomyoma.

TREATMENT

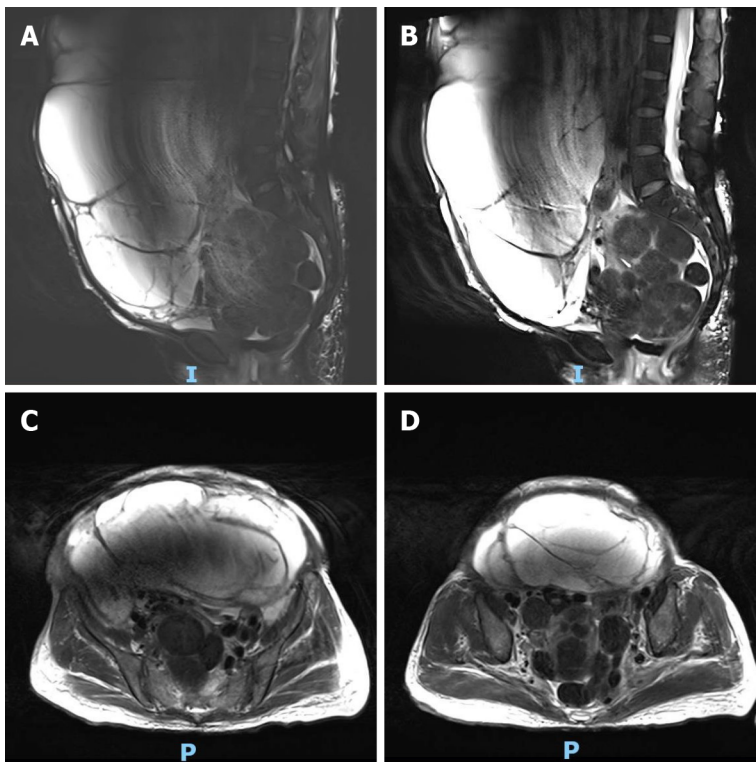
The patient successfully underwent retrograde abdominal hysterectomy and bilateral adnexectomy (Figure 3 and Video).

OUTCOME AND FOLLOW-UP

The surgical samples were sent for histopathological examination, and the results showed that the uterine mass was composed of proliferating smooth muscle cells and arranged in a braided shape; the cell morphology was slightly changed and no abnormalities were observed (Figure 4).

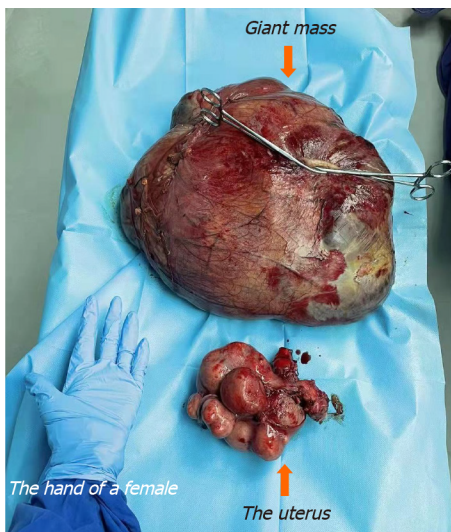
DISCUSSION

Leiomyoma, the most common benign uterine tumor[2], presents no obvious symptoms in many women with fibromas. Only patients who have symptoms affecting the function of the tumor-adjacent organ, such as urinary frequency and urgency, constipation, pain, or cancer-related anemia will opt to visit the clinic. Given the complex pathogenesis of uterine leiomyoma, its etiology is unclear at present. As revealed by clinical observations and laboratory tests, both estrogen and progesterone are involved in regulating the growth of uterine fibroids[3]. In addition, sex hormone level is an essential contributor to uterine fibroids. Several studies have shown that the incidence of hormone-dependent uterine leiomyoma is approximately 70% in women of childbearing age[4] and 80% in 50-year-old women[5]. Uterine fibroids form inside the uterus and are rarely found outside the uterus. In terms of their histomorphological features, uterine fibroids are mainly classified into intramural fibroids, submembranous fibroids, and submucosal fibroids[6]. Of these histopathological forms, cellular leiomyoma in the broad ligament is the least common type of uterine fibroid (< 5%)[7,8]. The broad ligament contains embryonic remnants formed by mesonephric (Wolffian) ducts. Notably, Wolffian ducts give rise to the genital ducts in males, but contract to generate embryonic remnants. These remnants including epithelial and paracellular cells, may spread and form abnormal cysts, or produce some myofibers that can lead to leiomyomas within the broad ligament[9]. To date, only five cases of cellular leiomyoma in



DOI: 10.12998/wjcc.v10.i34.12696 Copyright ©The Author(s) 2022.

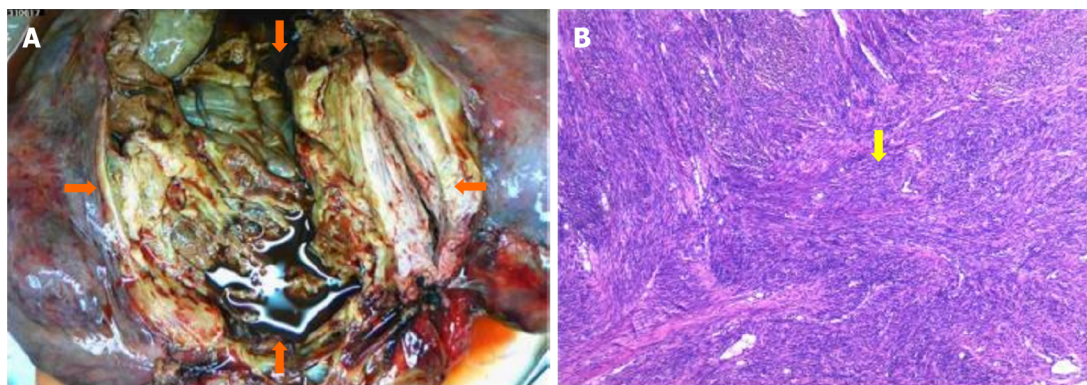
Figure 2 Preoperative magnetic resonance imaging of the mass. A and B: Magnetic resonance imaging of a large cystic solid mass observed in the abdomen and pelvis, approximately 32.0 cm × 21.1 cm × 37.4 cm in size. Slightly longer T1 and slightly shorter T2 signal changes in the solid component, and multiple cystic changes, long T1 and long T2 signal shadow in the cystic component; C and D: Magnetic resonance imaging of the smooth cyst wall of the lesion, and the clear boundary between the lesion and the surrounding tissue structure. The compressed and displaced abdominal and pelvic organs are shown.



DOI: 10.12998/wjcc.v10.i34.12696 Copyright ©The Author(s) 2022.

Figure 3 Postoperative mass and uterus (orange arrows). More than 10 masses were seen on the uterus surface and a large mass was removed from the right broad ligament.

the broad ligament have been reported in the literature[7,10-12]. The comprehensive assessment and diagnosis in these studies were mainly conducted with the aid of tumor markers, ultrasonography and histopathological examination. Nevertheless, little information on cellular leiomyoma in the broad ligament is available due to its rare occurrence. It is easily confused with the diagnosis of ovarian malignancies; therefore, posing a great challenge for clinicians and pathologists to increase the accuracy of preoperative diagnosis of cellular leiomyoma in the broad ligament.



DOI: 10.12998/wjcc.v10.i34.12696 Copyright ©The Author(s) 2022.

Figure 4 The tumor after surgical dissection (orange arrows). A and B: Uterine masses were composed of smooth muscle cells with proliferation and braided arrangement. The cell morphology was slightly changed and no abnormalities were observed (yellow arrow).

Patients with cellular leiomyoma in the broad ligament are diagnosed at an advanced stage, with the main clinical manifestations of an abdominal mass, abdominal distension, and ascites. In line with the findings of previously reported cases, our patient presented with elevated CA-125 levels. However, CA-125 is not a specific marker for cellular leiomyoma in the broad ligament, and is increasingly expressed in endometriosis and serous ovarian tumors, which therefore increases the difficulty of preoperative diagnosis[1]. These findings also imply that all cellular leiomyomas in the broad ligament are currently diagnosed by intraoperative observation and postoperative pathology. Accordingly, it is worth mentioning that exploratory laparotomy is the most effective method for making a diagnosis.

In this case, ring ligation was performed by an attending physician with more than 30 years of clinical surgical experience. Attention should be paid to protecting vital tissues and organs such as the bladder, ureter and major blood vessels during the operation. The tumor was distinctly different from the ovary (Figure 5). Given its complete and clear capsule, the tumor can be preliminarily distinguished from ovarian tumors. Nonetheless, histopathology is the gold standard and should be performed. Postoperative pathological examination of the myometrial wall and bilateral ovaries revealed acute suppurative inflammation, and recurrent low-grade fever in patients may be associated with endogenous fever factors such as tumor growth. In the present case, successful surgical intervention was critical to the patient's prognosis.

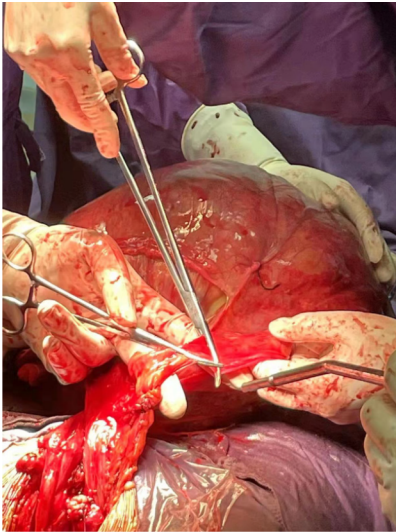
The mass in this patient was so huge that the bladder was moved upward and the boundaries of the interstitial space were unclear. Thus, choosing a conventional hysterectomy had higher risks, such as poor hemostasis and excessive intraoperative bleeding. Collectively, we finally chose retrograde total hysterectomy through the Douglas pouch to inhibit bleeding and effectively dissect the uterovesical space. Specifically, the cervix and vagina were exposed in the posterior fornix; blood flow was blocked in each branch; and the uterus was finally removed after blunt dissection of the uterine space from below to above the level of the bladder triangle.

In addition, hyalinization is the most common secondary phenomenon. With the development of hyaline fibroids, cysts of various sizes are generated after liquefaction and necrosis of muscle cells. This was concluded by reviewing the cases from 2016 and 2020. Thus, large masses were associated with cystic and myxoid lesions. Cystic leiomyomas displayed decreased T1 signal intensity and increased T2 signal intensity (no increase observed in the cystic lesion area) on MRI, while common leiomyomas exhibited lower T2 signal intensity. This provided a method for the clinical differentiation of common leiomyomas and cystic leiomyomas[12].

Cellular leiomyoma, a variant of leiomyoma, is one of the most special types of uterine leiomyoma. In the study conducted by Naz *et al*[13] of 964 female genital leiomyomas, cellular leiomyomas were discovered to be the most common variant of leiomyomas, but they were easily confused with malignancy due to their specificity. Therefore, the application of bioinformatics to predict relevant specific tumor biomarkers is particularly important for preoperative diagnosis and prognosis. In light of the rarity of this disease, it is crucial to address this issue with additional research using animal models in future studies.

CONCLUSION

Giant cellular leiomyoma in the broad ligament is a rare clinical neoplasm. The probability of it being confused with ovarian malignancy is increased by elevated CA-125 levels, as well as cystic and mucinous lesions. Timely and successful surgical intervention is critical for patients indicated for surgery.



DOI: 10.12998/wjcc.v10.i34.12696 Copyright ©The Author(s) 2022.

Figure 5 Intraoperative picture of the operation. The large leiomyoma in the right broad ligament is shown.

FOOTNOTES

Author contributions: Yan J wrote the manuscript; Li Y collected and collated case information; Long XY edited images; Li DC completed the operation as the major surgeon and reviewed the final manuscript; Li SJ followed up the patient as the doctor in charge; all authors have read and approved the final manuscript.

Informed consent statement: The patient provided informed written consent prior to study enrollment.

Conflict-of-interest statement: All the authors declare that they have no known competing financial interests or personal relationships that could influence the work reported in this paper.

CARE Checklist (2016) statement: The authors have read the CARE Checklist (2016), and the manuscript was prepared and revised according to the CARE Checklist (2016).

Open-Access: This article is an open-access article that was selected by an in-house editor and fully peer-reviewed by external reviewers. It is distributed in accordance with the Creative Commons Attribution NonCommercial (CC BY-NC 4.0) license, which permits others to distribute, remix, adapt, build upon this work non-commercially, and license their derivative works on different terms, provided the original work is properly cited and the use is non-commercial. See: <https://creativecommons.org/licenses/by-nc/4.0/>

Country/Territory of origin: China

ORCID number: Jiao Yan 0000-0002-4642-9246; Dao-Cheng Li 0000-0001-7925-6516.

S-Editor: Liu JH

L-Editor: Webster JR

P-Editor: Liu JH

REFERENCES

- 1 Mallick D, Saha M, Chakrabarti S, Chakraborty J. Leiomyoma of broad ligament mimicking ovarian malignancy- report of a unique case. *Kathmandu Univ Med J (KUMJ)* 2014; **12**: 219-221 [PMID: 25855117 DOI: 10.3126/kumj.v12i3.13723]
- 2 Jagtap SV, Khatib WGM, Jagtap SS, Kshirsagar NS. Large leiomyoma of the broad ligament. *Journal of Medical and Allied Sciences* 2013; **3** [DOI: 10.53347/rid-49751]
- 3 The North American Menopause Society (NAMS). NAMS 2018 Utian Translational Science Symposium, October 2018, San Diego, California New therapies for leiomyomas: when surgery may not be the best option. *Menopause* 2019; **26**: 947-957 [PMID: 31453955 DOI: 10.1097/GME.0000000000001402]
- 4 Machado-Lopez A, Simón C, Mas A. Molecular and Cellular Insights into the Development of Uterine Fibroids. *Int J Mol Sci* 2021; **22** [PMID: 34445194 DOI: 10.3390/ijms22168483]
- 5 Lewis TD, Malik M, Britten J, San Pablo AM, Catherino WH. A Comprehensive Review of the Pharmacologic Management of Uterine Leiomyoma. *Biomed Res Int* 2018; **2018**: 2414609 [PMID: 29780819 DOI: 10.1155/2018/2414609]

- 6 **Bajis R**, Eloundou G. Unusual Case of a Torted Mesenteric Fibroid. *Case Rep Obstet Gynecol* 2018; **2018**: 8342127 [PMID: [29977634](#) DOI: [10.1155/2018/8342127](#)]
- 7 **Chmaj-Wierzchowska K**, Buks J, Wierzchowski M, Szymanowski K, Opala T. Leiomyoma cellulare in the broad ligament of the uterus--case report and review of literature. *Ginek Pol* 2012; **83**: 301-304 [PMID: [22712264](#)]
- 8 **Lodhia J**, Gaffur R, Sadiq A, Amsi P, Tsandiraki J, Maro E. Unusual case of broad ligament leiomyoma: A diagnostic and surgical challenge. *Clin Case Rep* 2022; **10**: e6350 [PMID: [36177066](#) DOI: [10.1002/ccr3.6350](#)]
- 9 **Kagan II**. Traditions and peculiarities of clinical anatomy education in Russia. *Clin Anat* 2002; **15**: 152-156 [PMID: [11877796](#) DOI: [10.1002/ca.1112](#)]
- 10 **Sharma P**, Zaheer S, Yadav AK, Mandal AK. Massive Broad Ligament Cellular Leiomyoma with Cystic Change: A Diagnostic Dilemma. *J Clin Diagn Res* 2016; **10**: ED01-ED02 [PMID: [27190813](#) DOI: [10.7860/JCDR/2016/16878.7537](#)]
- 11 **Sikora-Szczęśniak DL**. Leiomyoma cellulare in the broad ligament of the uterus. *Prz Menopauzalny* 2018; **17**: 49-52 [PMID: [29725286](#) DOI: [10.5114/pm.2018.74903](#)]
- 12 **Jha S**, Singh A, Singh S, Murmu S. Huge broad ligament leiomyoma with cystic degeneration: A diagnostic and surgical challenge. *J Obstet Gynaecol Res* 2020; **46**: 791-794 [PMID: [32043297](#) DOI: [10.1111/jog.14213](#)]
- 13 **Naz S**, Rehman A, Riyaz A, Jehangir F, Naeem S, Iqbal T. Leiomyoma: Its Variants And Secondary Changes A Five-Year Study. *J Ayub Med Coll Abbottabad* 2019; **31**: 192-195 [PMID: [31094115](#)]



Published by **Baishideng Publishing Group Inc**
7041 Koll Center Parkway, Suite 160, Pleasanton, CA 94566, USA

Telephone: +1-925-3991568

E-mail: bpgoffice@wjgnet.com

Help Desk: <https://www.f6publishing.com/helpdesk>

<https://www.wjgnet.com>

