

World Journal of *Clinical Cases*

World J Clin Cases 2022 November 16; 10(32): 11665-12065



Contents

Thrice Monthly Volume 10 Number 32 November 16, 2022

OPINION REVIEW

- 11665** Combined use of lactoferrin and vitamin D as a preventive and therapeutic supplement for SARS-CoV-2 infection: Current evidence

Cipriano M, Ruberti E, Tovani-Palone MR

REVIEW

- 11671** Role of adherent invasive *Escherichia coli* in pathogenesis of inflammatory bowel disease
- Zheng L, Duan SL, Dai YC, Wu SC*
- 11690** Emerging potential of ubiquitin-specific proteases and ubiquitin-specific proteases inhibitors in breast cancer treatment

Huang ML, Shen GT, Li NL

MINIREVIEWS

- 11702** Overlap of diabetic ketoacidosis and hyperosmolar hyperglycemic state
- Hassan EM, Mushtaq H, Mahmoud EE, Chhibber S, Saleem S, Issa A, Nitesh J, Jama AB, Khedr A, Boike S, Mir M, Attallah N, Surani S, Khan SA*

ORIGINAL ARTICLE

Case Control Study

- 11712** Comparing the efficacy of different dexamethasone regimens for maintenance treatment of multiple myeloma in standard-risk patients non-eligible for transplantation
- Hu SL, Liu M, Zhang JY*

Retrospective Cohort Study

- 11726** Development and validation of novel nomograms to predict survival of patients with tongue squamous cell carcinoma
- Luo XY, Zhang YM, Zhu RQ, Yang SS, Zhou LF, Zhu HY*

Retrospective Study

- 11743** Non-invasive model for predicting esophageal varices based on liver and spleen volume
- Yang LB, Zhao G, Tantai XX, Xiao CL, Qin SW, Dong L, Chang DY, Jia Y, Li H*

Clinical Trials Study

- 11753** Clinical efficacy of electromagnetic field therapy combined with traditional Chinese pain-reducing paste in myofascial pain syndrome
- Xiao J, Cao BY, Xie Z, Ji YX, Zhao XL, Yang HJ, Zhuang W, Sun HH, Liang WM*

- 11766** Endothelial injury and inflammation in patients with hyperuricemic nephropathy at chronic kidney disease stages 1-2 and 3-4

Xu L, Lu LL, Wang YT, Zhou JB, Wang CX, Xin JD, Gao JD

Observational Study

- 11775** Quality of life and symptom distress after cytoreductive surgery and hyperthermic intraperitoneal chemotherapy

Wang YF, Wang TY, Liao TT, Lin MH, Huang TH, Hsieh MC, Chen VCH, Lee LW, Huang WS, Chen CY

- 11789** Development and validation of a risk assessment model for prediabetes in China national diabetes survey

Yu LP, Dong F, Li YZ, Yang WY, Wu SN, Shan ZY, Teng WP, Zhang B

Case Control Study

- 11804** T-cell immunoglobulin mucin molecule-3, transformation growth factor β , and chemokine-12 and the prognostic status of diffuse large B-cell lymphoma

Wu H, Sun HC, Ouyang GF

META-ANALYSIS

- 11812** Prostate artery embolization on lower urinary tract symptoms related to benign prostatic hyperplasia: A systematic review and meta-analysis

Wang XY, Chai YM, Huang WH, Zhang Y

CASE REPORT

- 11827** Paraneoplastic neurological syndrome caused by cystitis glandularis: A case report and literature review

Zhao DH, Li QJ

- 11835** Neck pain and absence of cranial nerve symptom are clues of cervical myelopathy mimicking stroke: Two case reports

Zhou LL, Zhu SG, Fang Y, Huang SS, Huang JF, Hu ZD, Chen JY, Zhang X, Wang JY

- 11845** Nine-year survival of a 60-year-old woman with locally advanced pancreatic cancer under repeated open approach radiofrequency ablation: A case report

Zhang JY, Ding JM, Zhou Y, Jing X

- 11853** Laparoscopic treatment of inflammatory myofibroblastic tumor in liver: A case report

Li YY, Zang JF, Zhang C

- 11861** Survival of a patient who received extracorporeal membrane oxygenation due to postoperative myocardial infarction: A case report

Wang QQ, Jiang Y, Zhu JG, Zhang LW, Tong HJ, Shen P

- 11869** Triple hit to the kidney-dual pathological crescentic glomerulonephritis and diffuse proliferative immune complex-mediated glomerulonephritis: A case report

Ibrahim D, Brodsky SV, Satoskar AA, Biederman L, Maroz N

- 11877** Successful transcatheter arterial embolization treatment for chest wall haematoma following permanent pacemaker implantation: A case report
Zheng J, Tu XM, Gao ZY
- 11882** Brachiocephalic to left brachial vein thrombotic vasculitis accompanying mediastinal pancreatic fistula: A case report
Kokubo R, Yunaiyama D, Tajima Y, Kugai N, Okubo M, Saito K, Tsuchiya T, Itoi T
- 11889** Long survival after immunotherapy plus paclitaxel in advanced intrahepatic cholangiocarcinoma: A case report and review of literature
He MY, Yan FF, Cen KL, Shen P
- 11898** Successful treatment of pulmonary hypertension in a neonate with bronchopulmonary dysplasia: A case report and literature review
Li J, Zhao J, Yang XY, Shi J, Liu HT
- 11908** Idiopathic tenosynovitis of the wrist with multiple rice bodies: A case report and review of literature
Tian Y, Zhou HB, Yi K, Wang KJ
- 11921** Endoscopic resection of bronchial mucoepidermoid carcinoma in a young adult man: A case report and review of literature
Ding YM, Wang Q
- 11929** Blue rubber bleb nevus syndrome complicated with disseminated intravascular coagulation and intestinal obstruction: A case report
Zhai JH, Li SX, Jin G, Zhang YY, Zhong WL, Chai YF, Wang BM
- 11936** Management of symptomatic cervical facet cyst with cervical interlaminar epidural block: A case report
Hwang SM, Lee MK, Kim S
- 11942** Primary squamous cell carcinoma with sarcomatoid differentiation of the kidney associated with ureteral stone obstruction: A case report
Liu XH, Zou QM, Cao JD, Wang ZC
- 11949** Successful live birth following hysteroscopic adhesiolysis under laparoscopic observation for Asherman's syndrome: A case report
Kakinuma T, Kakinuma K, Matsuda Y, Ohwada M, Yanagida K
- 11955** What is responsible for acute myocardial infarction in combination with aplastic anemia? A case report and literature review
Zhao YN, Chen WW, Yan XY, Liu K, Liu GH, Yang P
- 11967** Repeated ventricular bigeminy by trigeminocardiac reflex despite atropine administration during superficial upper lip surgery: A case report
Cho SY, Jang BH, Jeon HJ, Kim DJ
- 11974** Testis and epididymis-unusual sites of metastatic gastric cancer: A case report and review of the literature
Ji JJ, Guan FJ, Yao Y, Sun LJ, Zhang GM

- 11980** t(4;11) translocation in hyperdiploid *de novo* adult acute myeloid leukemia: A case report
Zhang MY, Zhao Y, Zhang JH
- 11987** Sun-burn induced upper limb lymphedema 11 years following breast cancer surgery: A case report
Li M, Guo J, Zhao R, Gao JN, Li M, Wang LY
- 11993** Minimal change disease caused by polycythemia vera: A case report
Xu L, Lu LL, Gao JD
- 12000** Vitreous amyloidosis caused by a Lys55Asn variant in transthyretin: A case report
Tan Y, Tao Y, Sheng YJ, Zhang CM
- 12007** Endoscopic nasal surgery for mucocoele and pyogenic mucocoele of turbinate: Three case reports
Sun SJ, Chen AP, Wan YZ, Ji HZ
- 12015** Transcatheter arterial embolization for traumatic injury to the pharyngeal branch of the ascending pharyngeal artery: Two case reports
Yunaiyama D, Takara Y, Kobayashi T, Muraki M, Tanaka T, Okubo M, Saguchi T, Nakai M, Saito K, Tsukahara K, Ishii Y, Homma H
- 12022** Retroperitoneal leiomyoma located in the broad ligament: A case report
Zhang XS, Lin SZ, Liu YJ, Zhou L, Chen QD, Wang WQ, Li JY
- 12028** Primary testicular neuroendocrine tumor with liver lymph node metastasis: A case report and review of the literature
Xiao T, Luo LH, Guo LF, Wang LQ, Feng L
- 12036** Endodontic treatment of the maxillary first molar with palatal canal variations: A case report and review of literature
Chen K, Ran X, Wang Y
- 12045** Langerhans cell histiocytosis involving only the thymus in an adult: A case report
Li YF, Han SH, Qie P, Yin QF, Wang HE

LETTER TO THE EDITOR

- 12052** Heart failure with preserved ejection fraction: A distinct heart failure phenotype?
Triposkiadis F, Giamouzis G, Skoularigis J, Xanthopoulos A
- 12056** Insight into appropriate medication prescribing for elderly in the COVID-19 era
Omar AS, Kaddoura R
- 12059** Commentary on "Gallstone associated celiac trunk thromboembolisms complicated with splenic infarction: A case report"
Tokur O, Aydın S, Kantarci M
- 12062** Omicron targets upper airways in pediatrics, elderly and unvaccinated population
Nori W, Ghani Zghair MA

ABOUT COVER

Editorial Board Member of *World Journal of Clinical Cases*, Camelia Cristina Diaconu, FACC, FACP, FESC, MHSc, PhD, Associate Professor, Department of Internal Medicine, "Carol Davila" University of Medicine and Pharmacy, Clinical Emergency Hospital of Bucharest, Bucharest 014461, Romania. drcameliadiaconu@gmail.com

AIMS AND SCOPE

The primary aim of *World Journal of Clinical Cases* (WJCC, *World J Clin Cases*) is to provide scholars and readers from various fields of clinical medicine with a platform to publish high-quality clinical research articles and communicate their research findings online.

WJCC mainly publishes articles reporting research results and findings obtained in the field of clinical medicine and covering a wide range of topics, including case control studies, retrospective cohort studies, retrospective studies, clinical trials studies, observational studies, prospective studies, randomized controlled trials, randomized clinical trials, systematic reviews, meta-analysis, and case reports.

INDEXING/ABSTRACTING

The WJCC is now abstracted and indexed in Science Citation Index Expanded (SCIE, also known as SciSearch®), Journal Citation Reports/Science Edition, Current Contents®/Clinical Medicine, PubMed, PubMed Central, Scopus, Reference Citation Analysis, China National Knowledge Infrastructure, China Science and Technology Journal Database, and Superstar Journals Database. The 2022 Edition of Journal Citation Reports® cites the 2021 impact factor (IF) for WJCC as 1.534; IF without journal self cites: 1.491; 5-year IF: 1.599; Journal Citation Indicator: 0.28; Ranking: 135 among 172 journals in medicine, general and internal; and Quartile category: Q4. The WJCC's CiteScore for 2021 is 1.2 and Scopus CiteScore rank 2021: General Medicine is 443/826.

RESPONSIBLE EDITORS FOR THIS ISSUE

Production Editor: Hua-Ge Yin; Production Department Director: Xu Guo; Editorial Office Director: Jin-Lei Wang.

NAME OF JOURNAL

World Journal of Clinical Cases

ISSN

ISSN 2307-8960 (online)

LAUNCH DATE

April 16, 2013

FREQUENCY

Thrice Monthly

EDITORS-IN-CHIEF

Bao-Gan Peng, Jerzy Tadeusz Chudek, George Kontogeorgos, Maurizio Serati, Ja Hyeon Ku

EDITORIAL BOARD MEMBERS

<https://www.wjgnet.com/2307-8960/editorialboard.htm>

PUBLICATION DATE

November 16, 2022

COPYRIGHT

© 2022 Baishideng Publishing Group Inc

INSTRUCTIONS TO AUTHORS

<https://www.wjgnet.com/bpg/gerinfo/204>

GUIDELINES FOR ETHICS DOCUMENTS

<https://www.wjgnet.com/bpg/GerInfo/287>

GUIDELINES FOR NON-NATIVE SPEAKERS OF ENGLISH

<https://www.wjgnet.com/bpg/gerinfo/240>

PUBLICATION ETHICS

<https://www.wjgnet.com/bpg/GerInfo/288>

PUBLICATION MISCONDUCT

<https://www.wjgnet.com/bpg/gerinfo/208>

ARTICLE PROCESSING CHARGE

<https://www.wjgnet.com/bpg/gerinfo/242>

STEPS FOR SUBMITTING MANUSCRIPTS

<https://www.wjgnet.com/bpg/GerInfo/239>

ONLINE SUBMISSION

<https://www.f6publishing.com>



Minimal change disease caused by polycythemia vera: A case report

Li Xu, Li-Li Lu, Jian-Dong Gao

Specialty type: Hematology

Provenance and peer review:

Unsolicited article; Externally peer reviewed.

Peer-review model: Single blind

Peer-review report's scientific quality classification

Grade A (Excellent): 0
Grade B (Very good): 0
Grade C (Good): C, C
Grade D (Fair): 0
Grade E (Poor): 0

P-Reviewer: Boilard E, Canada;
Tanabe K

Received: August 24, 2022

Peer-review started: August 24, 2022

First decision: September 23, 2022

Revised: September 27, 2022

Accepted: October 19, 2022

Article in press: October 19, 2022

Published online: November 16, 2022



Li Xu, Li-Li Lu, Jian-Dong Gao, Department of Nephrology, Shuguang Hospital Affiliated to the Shanghai University of Traditional Chinese Medicine, TCM Institute of Kidney Disease, Shanghai University of Traditional Chinese Medicine, Key Laboratory of Liver and Kidney Diseases (Shanghai University of Traditional Chinese Medicine), Ministry of Education, Shanghai Key Laboratory of Traditional Chinese Clinical Medicine (20DZ2272200), Shanghai 201203, China

Corresponding author: Jian-Dong Gao, PhD, Professor, Department of Nephrology, Shuguang Hospital Affiliated to the Shanghai University of Traditional Chinese Medicine, TCM Institute of Kidney Disease, Shanghai University of Traditional Chinese Medicine, Key Laboratory of Liver and Kidney Diseases (Shanghai University of Traditional Chinese Medicine), Ministry of Education, Shanghai Key Laboratory of Traditional Chinese Clinical Medicine (20DZ2272200), No. 528 Road ZhangHeng, Shanghai 201203, China.

jiandong.gao@shutcm.edu.cn

Abstract

BACKGROUND

Polycythemia vera (PV), often attributed to the JAK2 V617F mutation, is characterized by enhanced red blood cell counts in the peripheral blood. PV-associated renal disease is clinically rare; to date, there have been reports of other chronic kidney diseases related to PV, but no reports on PV-associated minimal change disease.

CASE SUMMARY

A 37-year-old man presented with proteinuria and high red blood cell count on January 4, 2021. The patient underwent bone marrow and renal biopsies, then was subsequently diagnosed with PV and minimal change in disease. Hydroxyurea was administered and proteinuria remission was achieved. The patient's last visit was on April 14, 2022.

CONCLUSION

We inferred that there may be a causal relationship between PV and minimal change disease.

Key Words: Polycythemia vera; Minimal change disease; Proteinuria; Chronic kidney disease; JAK2 V617F mutation; Case report

©The Author(s) 2022. Published by Baishideng Publishing Group Inc. All rights reserved.

Core Tip: Polycythemia vera (PV) is a myeloproliferative neoplasm that can influence the immune system and affect organs such as the kidneys. This is the first report of PV-associated minimal change disease. In our case, hydroxyurea administration was effective and proteinuria remission was achieved. Therefore, we infer there may be a causal relationship between PV and minimal change disease.

Citation: Xu L, Lu LL, Gao JD. Minimal change disease caused by polycythemia vera: A case report. *World J Clin Cases* 2022; 10(32): 11993-11999

URL: <https://www.wjgnet.com/2307-8960/full/v10/i32/11993.htm>

DOI: <https://dx.doi.org/10.12998/wjcc.v10.i32.11993>

INTRODUCTION

Polycythemia vera (PV)[1], a myeloproliferative neoplasm (MPN), is the ultimate phenotype of the JAK2 V617F mutation, and is characterized by erythrocytosis, leukocytosis, thrombocytosis, splenomegaly, and occasional myelofibrosis. PV-associated renal disease is rare. A literature review[2] referred to cases of PV-associated renal diseases, including immunoglobulin (Ig) A nephropathy, membranoproliferative glomerulonephritis, focal segmental glomerulosclerosis, and rapidly progressive glomerulonephritis. However, to the best of our knowledge, there have been no reports of minimal changes in disease. Here, we report the case of our patient.

CASE PRESENTATION

Chief complaints

A 37-year-old man, a base station engineer, was admitted to the Shuguang Hospital affiliated with the Shanghai University of Traditional Chinese Medicine, Department of Nephrology (Shanghai, China), on January 4, 2021. He complained of proteinuria for approximately one month.

History of present illness

During inpatient care, the patient presented with dizziness, slight weakness, no hematuria, no back pain, good appetite, sound sleep, and normal urine and stool.

History of past illness

The patient claimed no history of past illness.

Personal and family history

The patient claimed no personal or family history.

Physical examination

Physical examination revealed no abnormalities, except for blood pressure, which was 153/106 mmHg.

Laboratory examinations

On December 15, 2020, the patient underwent physical examination, and the report showed positive urine protein (++) , blood routine: white blood cell count, $16.531 \times 10^9/L$; hemoglobin level, 229 g/L; red blood cell $> 7.8 \times 10^{12}/L$; and platelet count, $489 \times 10^9/L$. Biochemistry test: albumin 37 g/L, total albumin 60 g/L, blood uric acid 490 $\mu\text{mol}/L$, triglyceride 3.87 mmol/L, and blood creatinine 88 $\mu\text{mol}/L$.

On December 31, 2020, the 24-hour urine total protein quantitative was 5.08 g/24 h.

On January 7, 2021, routine blood tests showed white blood cells: $21.71 \times 10^9/L$; platelets, $431 \times 10^9/L$; red blood cells, $7.65 \times 10^{12}/L$; and hemoglobin, 216.7 g/L.

On January 11 and 15, the patient underwent bone marrow and renal biopsies, respectively, after providing informed consent. A bone marrow biopsy revealed dense bone and a small amount of bone marrow tissue. The ratio of hematopoietic cells to structural fat in the area available for observation was 85%:15%, and the grain-to-red ratio was approximately 4-5:1. Hematopoietic cells in all stages of the red line could be seen; megakaryocytes were 7-17 per high-power field, distributed in clusters, and the cell bodies were relatively large with more nuclear lobes.

On January 11, 2021, a bone marrow biopsy showed that PV was first considered, and further genetic examination was recommended to clarify the type. IHC2021-0042: CD34 (individual +), CD117 (individual +), CD15 (partial +), MPO (partial +), CD56 (-), CD138 (individual +), CD61 (discrete +), CD71 (part +), Kappa: Lambda (not restricted expression), and special stain results: mesh (-), Periodic

Acid-Schiff stain (+/-), Prussian blue (-).

On January 13, 2021, karyotype analysis showed the following karyotype: 46,XY (Figure 1). Gene test: JAK2 V617F (+). The mutation ratio of JAK2 V617F was 86.60%.

On January 15, 2021, renal biopsy (renal puncture tissue) revealed four glomeruli. The morphology and structure of glomeruli were normal. Some glomeruli showed mild proliferation of mesangial cells and increased matrix. No glomerular sclerosis changes, crescents, or infiltration of inflammatory cells were observed. Protein casts were observed in individual tubules, and some renal tubules showed atrophy and unclear structure. No obvious abnormalities were observed in the renal interstitium or blood vessels. Diagnosis: Minimal change disease (MCD). Fluorescence staining: IgG (-), IgA (-), IgM (-), C3 (-), C4 (-), C1q (-), Fb (+/-). Special staining: PAS (+), silver staining (+), Masson's trichrome (+), Congo red (-). IHC2021-0045: TGF B1 (-) (Figure 2).

Imaging examinations

Abdominal ultrasonography showed splenomegaly.

FINAL DIAGNOSIS

The patient was diagnosed with the following conditions: (1) MCD; (2) PV; and (3) hypertension.

TREATMENT

The patient was given hydroxyurea 0.5 g qd p.o. (total duration of administration: 3 mo), olmesartan 20 mg qd p.o. (till last visit) and has been receiving interferon biweekly since cessation of hydroxyurea.

OUTCOME AND FOLLOW-UP

On March 13, 2021, the patient visited the hospital for a second visit. Routine blood test results revealed the following findings: hemoglobin, 167 g/L; red blood cells: $5.34 \times 10^{12}/L$; white blood cells: $5.5 \times 10^9/L$; and platelets, $170 \times 10^9/L$. On March 18, 2021, the patient's 24 h proteinuria was 1.33 g/24 h. The patient is currently in good condition. Other laboratory data for each visit are shown in Table 1 and Figures 3-5.

DISCUSSION

MCD is a primary cause of idiopathic nephrotic syndrome (NS), which manifests as mass proteinuria, resulting in edema and depletion of intravascular volume[3]. MCD occurs much less frequently in adults than in children[3]. The pathological features of MCD include a lack of visible changes on light microscopy and depletion of foot processes on electron microscopy. Podocyte modifications and immune disorders synergize to change the integrity of the glomerular basement membrane (GBM), thereby determining proteinuria[3]. MCD is primarily associated with extra-glomerular diseases, including neoplastic processes and undesirable reactions to drugs.


MCD has been frequently associated with hematologic malignancies such as Hodgkin's lymphoma [4], and this relationship indicates that MCD is a disease that results from lymphocyte dysfunction. The benefit of immunosuppressants and steroids also implies that the cause of MCD is immune dysregulation. The pathogenesis of PV-associated MCD is likely related to T cell dysfunction. The mechanism is speculated to be a T helper cell class 1 and 2 imbalance in MCD[5,6]. In brief, the main cause of MCD is immune disorders, particularly T cell dysfunction. These T lymphocytes can produce circulating lymphokines which are toxic to GBM, and thus alter their permeability to proteins. In 1974, Shalhoub postulated the existence of a circulating mediator produced by abnormal T-lymphocytes[7]. In our case, T-lymphocyte disorder also induced concurrent MCD with PV. Studies have shown that the immune system is thrown into enormous disruption by myeloproliferative neoplasms (MPNs)[8]. JAK2V617F mutation results in the overexpression of many cytokines and chemokines such as interleukins IL-2, IL-8, as reported in samples from both mice and patients[8,9]. Nephrotic-level proteinuria has been reported in cancer patients treated with IL-2[10]. Evidence indicates that IL-2 is associated with proteinuria[10]. Hermouet *et al*[11] were the first to report that serum IL-8 Levels were elevated in PV patients. Garin *et al*[12] speculated that circulating IL-8 may play a role in MCD.

Our patient's business trip to Chernobyl 8 years ago lasted approximately 4 months. We suspected nuclear contamination, which would have affected the immune system.

Table 1 Laboratory data according to each visit based on timeline

Date	WBC (10 ⁹ /L)	HB (g/L)	RBC (10 ¹² /L)	PLT (10 ⁹ /L)	Hematocrits	UTP (g/24 h)	eGFR (mL × 1.73 m ²)
2019-08-20	12.7	205	7.35	474	0.636	-	-
2021-01-05	16.57	226.1	8.05	435	0.665	8.83	88.33
2021-01-07	21.71	216.7	7.65	431	0.664	-	-
2021-01-10	15.77	218	7.67	500	0.659	-	-
2021-01-12	-	-	-	-	-	-	89.47
2021-01-30	-	-	-	-	-	4.4	-
2022-02-06	2.79	211	7.02	168	0.63	-	-
2022-02-22	3.97	203	6.66	161	0.591	1.81	-
2022-03-13	5.51	167	5.34	170	0.475	-	-
2021-03-18	-	-	-	-	-	1.33	-
2021-04-10	4	141	4.46	263	0.408	1.86	-
2021-05-08	4.53	125	3.76	337	0.362	-	92.69
2021-05-10	-	-	-	-	-	1.83	-
2021-05-24	6.3	128	3.73	450	0.369	-	-
2021-07-03	6.5	156	4.73	525	0.452	0.84	-

WBC: White blood cell; HB, hemoglobin; RBC: Red blood cell; PLT: Platelet; UTP: Urine total protein; eGFR: estimated glomerular filtration rate.

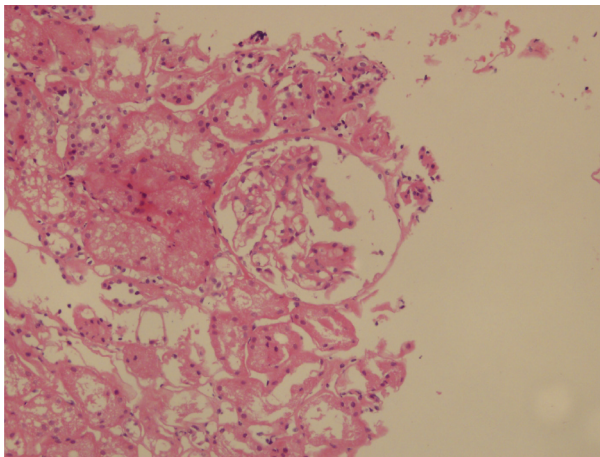


DOI: 10.12998/wjcc.v10.i32.11993 Copyright ©The Author(s) 2022.

Figure 1 Karyotype analysis results.

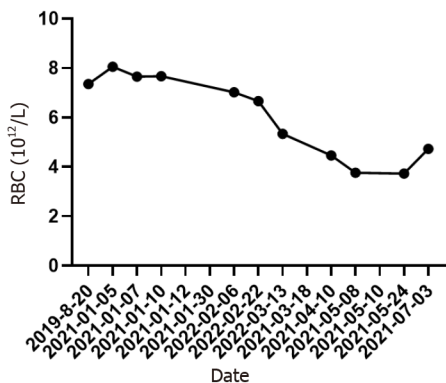
Our question in this case was as follows: Was the occurrence of MCD with PV purely coincidental or was it etiologically linked, either by a common pathogenesis or could the MCD be secondary to the PV? We can see that proteinuria remission was positively associated with treatment with hydroxyurea, so it is reasonable to consider a causal relationship.

However, the exact mechanisms underlying the pathogenesis of MCD associated with PV remain unclear. In addition to immune dysregulation, kidney injury might also be attributed to hyperviscosity, abnormal function, and/or excessive neoplastic blood cell activation and growth factor production[13].



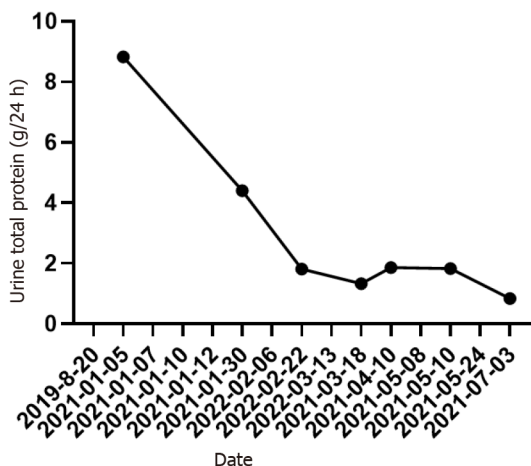
DOI: 10.12998/wjcc.v10.i32.11993 Copyright ©The Author(s) 2022.

Figure 2 Renal biopsy results.



DOI: 10.12998/wjcc.v10.i32.11993 Copyright ©The Author(s) 2022.

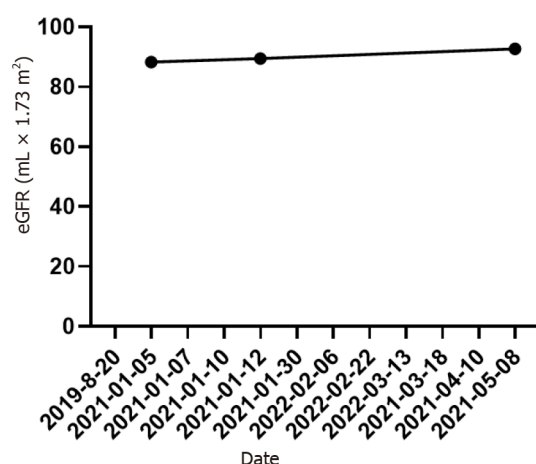
Figure 3 Red blood cell counts at each visit. RBC: Red blood cell.



DOI: 10.12998/wjcc.v10.i32.11993 Copyright ©The Author(s) 2022.

Figure 4 Urine total protein at each visit.

Increased blood viscosity and platelet hypersensitivity can induce microcirculatory disturbances, resulting in endothelial damage. Many cytokines and growth factors such as interferon- γ , IL-6, and platelet-derived growth factor, which have documented in patients with MPNs, can directly elicit endothelial damage. Growth factors can be generated locally by marginating platelets and cells of extramedullary hematopoiesis, accompanied by hyperviscosity, which exacerbates endothelial damage



DOI: 10.12998/wjcc.v10.i32.11993 Copyright ©The Author(s) 2022.

Figure 5 Estimated glomerular filtration rate at each visit. eGFR: Estimated glomerular filtration rate.

[13]. PV can not only result in thrombosis in the main blood vessels[14], but can also induce thrombotic microangiopathy[15]. Glomerular microvasculature is particularly vulnerable to injury due to thrombotic microangiopathy. Therefore, we posit that PV-induced hyperviscosity could be an important factor in the pathogenesis of MCD, except in immune disorders.

Nonetheless, two potential mechanisms, microcirculatory disturbances and immune disorders, may explain the development of MCD in PV patients.

CONCLUSION

Based on our findings, there may be a causal relationship between minimal change in disease and PV. However, this is a clinical inference rather than a critical appraisal of the differences between chance and causal relationships, which would require a study of extensive epidemiological data.

FOOTNOTES

Author contributions: Xu L was responsible for writing the manuscript and data analysis; Lu LL helped with document retrieval; Gao JD was responsible for supervision; all authors agree with the final version of the manuscript.

Supported by the National Natural Science Foundation of China, No. 81874437 and 81904126; Science and Technology Commission of Shanghai Municipality, No. 20Y21901800.

Informed consent statement: Informed written consent was obtained from the patient for the publication of this report and any accompanying images.

Conflict-of-interest statement: The authors declare that they have no conflict of interest.

CARE Checklist (2016) statement: The authors have read the CARE Checklist (2016), and the manuscript was prepared and revised according to the CARE Checklist (2016).

Open-Access: This article is an open-access article that was selected by an in-house editor and fully peer-reviewed by external reviewers. It is distributed in accordance with the Creative Commons Attribution NonCommercial (CC BY-NC 4.0) license, which permits others to distribute, remix, adapt, build upon this work non-commercially, and license their derivative works on different terms, provided the original work is properly cited and the use is non-commercial. See: <https://creativecommons.org/licenses/by-nc/4.0/>

Country/Territory of origin: China

ORCID number: Li Xu 0000-0003-1577-9793; Li-Li Lu 0000-0002-6479-1337; Jian-Dong Gao 0000-0002-1645-837X.

S-Editor: Ma YJ

L-Editor: A

P-Editor: Ma YJ

REFERENCES

- 1 Spivak JL. Polycythemia Vera. *Curr Treat Options Oncol* 2018; **19**: 12 [PMID: 29516275 DOI: 10.1007/s11864-018-0529-x]
- 2 Chen H, Zhang B, Li M, Hu R, Zhou C. Polycythemia vera associated with IgA nephropathy: A case report and literature review. *Exp Ther Med* 2015; **10**: 555-560 [PMID: 26622353 DOI: 10.3892/etm.2015.2572]
- 3 Vivarelli M, Massella L, Ruggiero B, Emma F. Minimal Change Disease. *Clin J Am Soc Nephrol* 2017; **12**: 332-345 [PMID: 27940460 DOI: 10.2215/CJN.05000516]
- 4 Jhaveri KD, Shah HH, Patel C, Kadiyala A, Stokes MB, Radhakrishnan J. Glomerular diseases associated with cancer, chemotherapy, and hematopoietic stem cell transplantation. *Adv Chronic Kidney Dis* 2014; **21**: 48-55 [PMID: 24359986 DOI: 10.1053/j.ackd.2013.08.003]
- 5 Souadjan JV, Enriquez P, Silverstein MN, Pépin JM. The spectrum of diseases associated with thymoma. Coincidence or syndrome? *Arch Intern Med* 1974; **134**: 374-379 [PMID: 4602050 DOI: 10.1001/archinte.1974.00320200184029]
- 6 Bertelli R, Bonanni A, Di Donato A, Cioni M, Ravani P, Ghiggeri GM. Regulatory T cells and minimal change nephropathy: in the midst of a complex network. *Clin Exp Immunol* 2016; **183**: 166-174 [PMID: 26147676 DOI: 10.1111/cei.12675]
- 7 Shalhoub RJ. Pathogenesis of lipid nephrosis: a disorder of T-cell function. *Lancet* 1974; **2**: 556-560 [PMID: 4140273 DOI: 10.1016/s0140-6736(74)91880-7]
- 8 Nasillo V, Riva G, Paolini A, Forghieri F, Roncati L, Lusenti B, Maccaferri M, Messerotti A, Pioli V, Gilioli A, Bettelli F, Giusti D, Barozzi P, Lagreca I, Maffei R, Marasca R, Potenza L, Comoli P, Manfredini R, Maiorana A, Tagliafico E, Luppi M, Trenti T. Inflammatory Microenvironment and Specific T Cells in Myeloproliferative Neoplasms: Immunopathogenesis and Novel Immunotherapies. *Int J Mol Sci* 2021; **22** [PMID: 33672997 DOI: 10.3390/ijms22041906]
- 9 Panteli KE, Hatzimichael EC, Bouranta PK, Katsaraki A, Seferiadis K, Stebbing J, Bourantas KL. Serum interleukin (IL)-1, IL-2, sIL-2Ra, IL-6 and thrombopoietin levels in patients with chronic myeloproliferative diseases. *Br J Haematol* 2005; **130**: 709-715
- 10 Zea AH, Stewart T, Ascani J, Tate DJ, Finkel-Jimenez B, Wilk A, Reiss K, Smoyer WE, Aviles DH. Activation of the IL-2 Receptor in Podocytes: A Potential Mechanism for Podocyte Injury in Idiopathic Nephrotic Syndrome? *PLoS One* 2016; **11**: e0157907 [PMID: 27389192 DOI: 10.1371/journal.pone.0157907]
- 11 Hermouet S, Godard A, Pineau D, Corre I, Raher S, Lippert E, Jacques Y. Abnormal production of interleukin (IL)-11 and IL-8 in polycythemia vera. *Cytokine* 2002; **20**: 178-183 [PMID: 12543083 DOI: 10.1006/cyto.2002.1994]
- 12 Garin EH, West L, Zheng W. Effect of interleukin-8 on glomerular sulfated compounds and albuminuria. *Pediatr Nephrol* 1997; **11**: 274-279 [PMID: 9203172 DOI: 10.1007/s004670050276]
- 13 Büttner-Herold M, Sticht C, Wiech T, Porubsky S. Renal disease associated with myeloproliferative neoplasms and myelodysplastic syndrome/myeloproliferative neoplasms. *Histopathology* 2021; **78**: 738-748 [PMID: 33078472 DOI: 10.1111/his.14282]
- 14 Vannucchi AM, Guglielmelli P. JAK2 mutation-related disease and thrombosis. *Semin Thromb Hemost* 2013; **39**: 496-506 [PMID: 23633193 DOI: 10.1055/s-0033-1343890]
- 15 Eremina V, Jefferson JA, Kowalewska J, Hochster H, Haas M, Weisstuch J, Richardson C, Kopp JB, Kabir MG, Backx PH, Gerber HP, Ferrara N, Barisoni L, Alpers CE, Quaggin SE. VEGF inhibition and renal thrombotic microangiopathy. *N Engl J Med* 2008; **358**: 1129-1136 [PMID: 18337603 DOI: 10.1056/NEJMoa0707330]



Published by **Baishideng Publishing Group Inc**
7041 Koll Center Parkway, Suite 160, Pleasanton, CA 94566, USA

Telephone: +1-925-3991568

E-mail: bpgoffice@wjgnet.com

Help Desk: <https://www.f6publishing.com/helpdesk>

<https://www.wjgnet.com>

