

# World Journal of *Gastroenterology*

*World J Gastroenterol* 2022 November 21; 28(43): 6078-6205



## Contents

Weekly Volume 28 Number 43 November 21, 2022

## EDITORIAL

- 6078 Kyoto classification of gastritis: Advances and future perspectives in endoscopic diagnosis of gastritis  
*Toyoshima O, Nishizawa T*

## OPINION REVIEW

- 6090 Current status of minimally invasive liver surgery for cancers  
*Morise Z*

## MINIREVIEWS

- 6099 Management of non-alcoholic fatty liver disease patients with sleep apnea syndrome  
*Sheng W, Ji G, Zhang L*

## ORIGINAL ARTICLE

## Basic Study

- 6109 Differential analysis of intestinal microbiota and metabolites in mice with dextran sulfate sodium-induced colitis  
*Wang JL, Han X, Li JX, Shi R, Liu LL, Wang K, Liao YT, Jiang H, Zhang Y, Hu JC, Zhang LM, Shi L*
- 6131 *Salvia miltiorrhiza* extract may exert an anti-obesity effect in rats with high-fat diet-induced obesity by modulating gut microbiome and lipid metabolism  
*Ai ZL, Zhang X, Ge W, Zhong YB, Wang HY, Zuo ZY, Liu DY*

## Retrospective Study

- 6157 Upper gastrointestinal endoscopic findings in celiac disease at diagnosis: A multicenter international retrospective study  
*Stefanolo JP, Zingone F, Gizzi C, Marsilio I, Espinet ML, Smecuol EG, Khaouli M, Moreno ML, Pinto-Sánchez MI, Niveloni SI, Verdú EF, Ciacci C, Bai JC*

## SCIENTOMETRICS

- 6168 Integrity of the editing and publishing process is the basis for improving an academic journal's Impact Factor  
*Wang JL, Li X, Fan JR, Yan JP, Gong ZM, Zhao Y, Wang DM, Ma L, Ma N, Guo DM, Ma LS*

## CORRECTION

- 6203 Correction to "MicroRNA-596 acts as a tumor suppressor in gastric cancer and is upregulated by promotor demethylation"  
*Zhang Z, Dai DQ*

**ABOUT COVER**

Editorial Board of *World Journal of Gastroenterology*, Yasuhito Tanaka, MD, PhD, Chief Professor, Department of Gastroenterology and Hepatology, Faculty of Life Sciences, Kumamoto University, 1-1-1 Honjo, Chuo-ku, Kumamoto 860-8556, Japan. [ytanaka@kumamoto-u.ac.jp](mailto:ytanaka@kumamoto-u.ac.jp)

**AIMS AND SCOPE**

The primary aim of *World Journal of Gastroenterology* (WJG, *World J Gastroenterol*) is to provide scholars and readers from various fields of gastroenterology and hepatology with a platform to publish high-quality basic and clinical research articles and communicate their research findings online. WJG mainly publishes articles reporting research results and findings obtained in the field of gastroenterology and hepatology and covering a wide range of topics including gastroenterology, hepatology, gastrointestinal endoscopy, gastrointestinal surgery, gastrointestinal oncology, and pediatric gastroenterology.

**INDEXING/ABSTRACTING**

The WJG is now abstracted and indexed in Science Citation Index Expanded (SCIE, also known as SciSearch®), Current Contents/Clinical Medicine, Journal Citation Reports, Index Medicus, MEDLINE, PubMed, PubMed Central, Scopus, Reference Citation Analysis, China National Knowledge Infrastructure, China Science and Technology Journal Database, and Superstar Journals Database. The 2022 edition of Journal Citation Reports® cites the 2021 impact factor (IF) for WJG as 5.374; IF without journal self cites: 5.187; 5-year IF: 5.715; Journal Citation Indicator: 0.84; Ranking: 31 among 93 journals in gastroenterology and hepatology; and Quartile category: Q2. The WJG's CiteScore for 2021 is 8.1 and Scopus CiteScore rank 2021: Gastroenterology is 18/149.

**RESPONSIBLE EDITORS FOR THIS ISSUE**

Production Editor: *Yi-Xuan Cai*; Production Department Director: *Xiang Li*; Editorial Office Director: *Jia-Ru Fan*.

**NAME OF JOURNAL**

*World Journal of Gastroenterology*

**ISSN**

ISSN 1007-9327 (print) ISSN 2219-2840 (online)

**LAUNCH DATE**

October 1, 1995

**FREQUENCY**

Weekly

**EDITORS-IN-CHIEF**

Andrzej S Tarnawski

**EDITORIAL BOARD MEMBERS**

<http://www.wjgnet.com/1007-9327/editorialboard.htm>

**PUBLICATION DATE**

November 21, 2022

**COPYRIGHT**

© 2022 Baishideng Publishing Group Inc

**INSTRUCTIONS TO AUTHORS**

<https://www.wjgnet.com/bpg/gerinfo/204>

**GUIDELINES FOR ETHICS DOCUMENTS**

<https://www.wjgnet.com/bpg/GerInfo/287>

**GUIDELINES FOR NON-NATIVE SPEAKERS OF ENGLISH**

<https://www.wjgnet.com/bpg/gerinfo/240>

**PUBLICATION ETHICS**

<https://www.wjgnet.com/bpg/GerInfo/288>

**PUBLICATION MISCONDUCT**

<https://www.wjgnet.com/bpg/gerinfo/208>

**ARTICLE PROCESSING CHARGE**

<https://www.wjgnet.com/bpg/gerinfo/242>

**STEPS FOR SUBMITTING MANUSCRIPTS**

<https://www.wjgnet.com/bpg/GerInfo/239>

**ONLINE SUBMISSION**

<https://www.f6publishing.com>



## Retrospective Study

# Upper gastrointestinal endoscopic findings in celiac disease at diagnosis: A multicenter international retrospective study

Juan Pablo Stefanolo, Fabiana Zingone, Carolina Gizzi, Ilaria Marsilio, María Luján Espinet, Edgardo Gustavo Smecuol, Mark Khaouli, María Laura Moreno, María I Pinto-Sánchez, Sonia Isabel Niveloni, Elena F Verdú, Carolina Ciacci, Julio César Bai

**Specialty type:** Gastroenterology and hepatology

**Provenance and peer review:** Invited article; Externally peer reviewed.

**Peer-review model:** Single blind

**Peer-review report's scientific quality classification**

Grade A (Excellent): A  
Grade B (Very good): B  
Grade C (Good): 0  
Grade D (Fair): D  
Grade E (Poor): 0

**P-Reviewer:** Taavela J, Finland; Zhang X, United States; Zhang JW, China

**Received:** August 24, 2022

**Peer-review started:** August 24, 2022

**First decision:** September 8, 2022

**Revised:** September 22, 2022

**Accepted:** November 7, 2022

**Article in press:** November 7, 2022

**Published online:** November 21, 2022



**Juan Pablo Stefanolo, María Luján Espinet, Edgardo Gustavo Smecuol, María Laura Moreno, Sonia Isabel Niveloni, Julio César Bai**, Small Bowel Section, Dr. C. Bonorino Udaondo Gastroenterology Hospital, Buenos Aires 1264, Argentina

**Fabiana Zingone, Ilaria Marsilio**, Department of Surgery, Oncology and Gastroenterology, University of Padua, Padova 35124, Italy

**Fabiana Zingone**, Gastroenterology Unit, Azienda Ospedale Università, Padova 35128, Italy

**Carolina Gizzi, Carolina Ciacci**, Department of Medicine, Surgery, Dentistry, Scuola Medica Salernitana, University of Salerno, Salerno 84081, Italy

**Mark Khaouli, María I Pinto-Sánchez, Elena F Verdú**, Department of Medicine, Farncombe Family Digestive Health Research Institute, McMaster University, Hamilton L8S 4K1, Canada

**Julio César Bai**, Research Institutes, Universidad del Salvador, Buenos Aires 1020, Argentina

**Corresponding author:** Julio César Bai, MD, Academic Research, Emeritus Professor, Small Bowel Section, Dr. C. Bonorino Udaondo Gastroenterology Hospital, Av. Caseros 2061, Buenos Aires 1264, Argentina. [jbai@intramed.net](mailto:jbai@intramed.net)

## Abstract

### BACKGROUND

Gastroduodenal endoscopy and biopsy following positive specific serology is considered the gold standard to diagnose celiac disease (CeD) in adults. Whether upper endoscopy helps detect comorbid conditions is unknown.

### AIM

To investigate the prevalence of non-celiac endoscopic findings in patients in whom endoscopy was performed to confirm CeD diagnosis.

### METHODS

This is an observational, descriptive, multicenter, retrospective study that reports endoscopic findings obtained in adult patients enrolled in local registries from four tertiary centers. We collected data reported on first endoscopy, indicated for investigation of CeD. Diagnosis of CeD was performed by histology ( $\geq$  Marsh 2



type mucosal damage) and specific serology. Two European and one North American center included biopsy-confirmed CeD following positive serology. A fourth center (South America) included symptomatic patients undergoing endoscopy, irrespective of CeD serology. The latter cohort included a non-CeD control group.

## RESULTS

A total of 1328 patients (80% female; 35 years median age) were enrolled, of whom 95.6% had positive specific serology. In 135 patients, endoscopy revealed 163 abnormalities unrelated to CeD (prevalence: 10.1%). Erosive reflux esophagitis (6.4%), gastric erosions (2.0%), and suspicion of esophageal metaplasia (1.2%) were the most common findings. Biopsy-confirmed Barrett's esophagus was infrequent (0.2%). No endoscopic cancer was detected. Older patients ( $\geq 51$  years of age) had a higher prevalence of endoscopic findings than those  $\leq 50$  ( $P < 0.01$ ). Within the South American cohort, CeD was associated with a lower rate (8.2%) of comorbid endoscopic findings compared with controls (29.1%;  $P < 0.001$ ). In the adjusted multivariate analysis of this cohort, having CeD was associated with a 72% reduction in the risk of any endoscopic abnormality ( $P < 0.0001$ ), and having alarm symptoms was associated with a 37% reduction in the risk of finding at least one endoscopic lesion ( $P < 0.02$ ).

## CONCLUSION

In this large multicenter study, young adults with positive CeD serology had few comorbid endoscopic findings. Although patients over 51 years had a high prevalence of non-CeD gastroduodenal mucosal damage, no malignancy or premalignant lesions were found.

**Key Words:** Celiac disease; Upper gastrointestinal endoscopy; Concomitant endoscopic lesions; Malignancies; Multicenter study

©The Author(s) 2022. Published by Baishideng Publishing Group Inc. All rights reserved.

**Core Tip:** We offer novel data on the prevalence of non-celiac endoscopic findings at the time of endoscopy performed to confirm celiac disease (CeD) diagnosis. Based on the very high performance of specific serology tests, the diagnosis of CeD without duodenal biopsy has been proposed in recent years. However, some guidelines do not recommend avoiding endoscopy because relevant comorbid diagnosis can be missed. Our results found that comorbid upper gastrointestinal endoscopic pathology is uncommon in patients with positive CeD serology at the time of diagnostic endoscopy suggesting that a non-biopsy strategy is unlikely to clinically miss significant concomitant endoscopic findings unrelated to CeD.

**Citation:** Stefanolo JP, Zingone F, Gizzi C, Marsilio I, Espinet ML, Smecuol EG, Khaoui M, Moreno ML, Pinto-Sánchez MI, Niveloni SI, Verdú EF, Ciacci C, Bai JC. Upper gastrointestinal endoscopic findings in celiac disease at diagnosis: A multicenter international retrospective study. *World J Gastroenterol* 2022; 28(43): 6157-6167

**URL:** <https://www.wjgnet.com/1007-9327/full/v28/i43/6157.htm>

**DOI:** <https://dx.doi.org/10.3748/wjg.v28.i43.6157>

## INTRODUCTION

Celiac disease (CeD) is one of the most common life-long chronic diseases affecting people with a genetic predisposition conferred by HLA-DQ2 or DQ8[1]. Current recommendations for diagnosing CeD in adult patients involve a combination of specific serology and a duodenal biopsy demonstrating some degree of intestinal atrophy[2,3]. When CeD is clinically suspected, upper gastroduodenal endoscopy with duodenal biopsy confirms diagnosis[4]. Based on the very high specificity and predictive values of specific serology tests[5], the diagnosis of CeD without duodenal biopsy has been proposed in recent years[6-8]. Indeed, European pediatric societies recommend a non-biopsy approach under specific and strict criteria[9,10]. However, other pediatric societies (*e.g.*, the North American Pediatric Gastroenterology Society) do not recommend this, in part because relevant comorbid diagnosis could be missed[11]. This is of particular concern in patients with alarm symptoms such as weight loss, anemia, or abdominal pain[2,12,13]. However, relatively few studies have explored this in-depth, particularly in adult patients undergoing endoscopy to confirm CeD diagnosis[14-16].

Thus, we conducted a multicenter study involving four cohorts of patients diagnosed in three countries to investigate the prevalence of coincidental upper gastrointestinal endoscopic findings in CeD patients at the time of diagnosis. We also compared upper gastrointestinal mucosal injury

diagnoses across centers and age groups. Finally, we studied the pathological findings in patients with a confirmed diagnosis of CeD *vs* those in whom the disease was ruled out.

## MATERIALS AND METHODS

### Design

We conducted a descriptive multicenter retrospective study on endoscopic findings from adult patients who met standard clinical, serological, and histological criteria for CeD. Patients from four different CeD-specialized centers were included. Two European cohorts (Universities of Naples/Salerno and Padua; Italy) and a North American cohort (McMaster University, Hamilton; Canada) recruited consecutive patients enrolled in local registers. CeD was diagnosed by positive serology and confirmed by biopsy. The Naples/Salerno cohort included consecutive patients seen between 1987 and 2021, the Padua cohort between 2017 and 2021, and the Hamilton cohort between 2018 and 2020. A fourth (Small Bowel Section, Dr. C. Bonorino Udaondo Gastroenterology Hospital, Buenos Aires; Argentina) included patients referred for endoscopy and duodenal biopsy due to the presence of symptoms and/or signs compatible with CeD but, irrespective of serology, all of them part of prior research and study[7,15]. Thus, the fourth cohort included CeD and non-CeD participants (controls). **Figure 1** and **Table 1** summarize the demographic characteristics of the cohorts. The Ethics and Research Board of the Dr. C. Bonorino Udaondo Gastroenterology Hospital approved the study because of the prospective design and intervention in the Buenos Aires cohort. Ethics approval was obtained from Hamilton Integrated Research Ethics Board (HiREB# 14460/5415). In Italy, Ethical Committee review was not required for retrospective studies while patient data remained anonymously coded.

### Endoscopic procedures

In all CeD centers, experienced gastroenterologists performed upper gastrointestinal endoscopies and obtained duodenal biopsies *per* shared standard of care protocols. Endoscopic reports were generated using a standard format, and the data were entered into a common database. Duodenal biopsies were sent to each institution's experienced pathologist. A standard number of biopsies were taken when any endoscopic abnormality was detected (*e.g.*, endoscopic evidence of esophageal metaplasia). Endoscopic abnormalities were defined as follows[17]: (1) Erosive esophagitis: Esophageal mucosal damage characterized by one or more mucosal breaks that do not extend across the top of mucosal folds and confluent lesions or ulcers of any size; (2) Suspected esophageal metaplasia: Endoscopically suspected columnar mucosa without histological confirmation of specialized intestinal metaplasia; (3) Barrett's esophagus confirmed by biopsy: Metaplastic columnar epithelium replacing the stratified squamous epithelium in biopsies from suspected metaplasia or presence of intestinal metaplasia; (4) Gastric and duodenal erosions: Presence of erythema and erosions in stomach or duodenum; (5) Esophageal, gastric, or duodenal ulcers extending into the *muscularis propria*; and (6) Esophageal, gastric, or duodenal cancer: Suspected endoscopic lesions were confirmed by specialized pathology.

### CeD diagnosis

CeD was diagnosed based on duodenal histology (Marsh's classification)[1,18]. Inclusion criteria were Marsh 2 enteropathy or higher and positive CeD-specific serology [presence of either anti-TTG immunoglobulin (Ig)A, Anti-EmA IgA, anti-DGP IgA/IgG]. When serology was negative, CeD was diagnosed based on histology and clinical response to the gluten free diet (GFD)[18]. If patients had known exposure to gluten before the endoscopy, intestinal biopsies were taken. As previously stated, the Buenos Aires cohort was part of a research study in which the diagnosis was made first on histological grounds and then confirmed by serology. The standard specific CeD test for all centers was IgA transglutaminase 2[5]. Patients with normal biopsy or minimal inflammation (Marsh 0 or 1) were excluded from the study, regardless of serology or GFD response. In the Hamilton cohort, diagnosis of seronegative CeD patients was based on histology and a clinical and histological response to the GFD.

### Data analysis

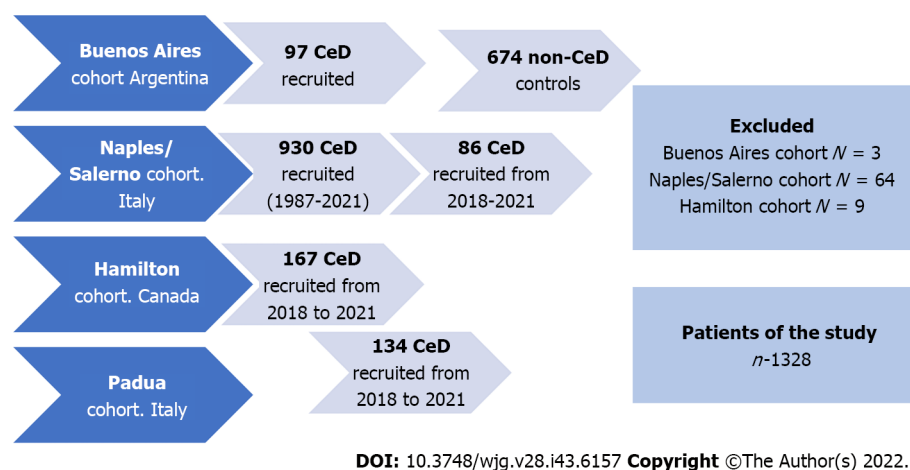
Statistical analysis was carried out using STATA (STATA version 14.0 Corp, College Station, TX, United States). Categorical variables were reported as frequencies and percentages, while continuous variables were reported as mean  $\pm$  SD and/or median and 25%-75% interquartile ranges, according to their distribution. Comparisons of categorical variables between groups were made using the  $\chi^2$  test or Fisher's exact test. *P* values  $< 0.05$  were considered statistically significant. For comparisons of continuous variables the analysis of variance test was used. Logistic regression was used to assess the risk of endoscopic lesions. The model included the report of significant lesions in endoscopy and/or histology reports as a dependent variable and factors such as age, sex, personal history, and signs/symptoms as independent variables.

Given the different recruitment times between centers, a subgroup analysis was performed to compare results in the Naples/Salerno cohort, focusing on cases diagnosed between 2018 and 2021 *vs*

**Table 1** Demography, celiac disease serology, and endoscopic findings by cohorts and the overall population

Demographic data and upper GI endoscopic findings	Naples/Salerno cohort	Buenos Aires cohort	Hamilton cohort	Padua cohort	Overall CeD population
Total population	930 (70.0)	97 (7.3)	167 (12.6)	134 (10.1)	1328
Age in yr	34 (26-42)	35 (27-44)	39 (27-54)	35 (23-46)	35 (26-43)
Female sex	754 (81.1)	88 (90.7)	122 (73.0)	100 (74.6)	1064 (80.1)
Patients with positive serology	899 (96.7)	97 (100)	147 (88.0)	130 (97.0)	1269 (95.6)
Patients with at least one significant endoscopic abnormality	89 (9.6)	8 (8.2)	34 (20.4)	4 (3.0)	135 (10.2)
Reflux esophagitis with erosions	78 (8.4)	1 (1.0)	6 (3.6)	0	85 (6.4)
Esophageal peptic ulcers	0	0	1 (0.6)	0	1 (0.2)
Esophageal malignancy	0	0	0	0	0
Suspicion of esophageal metaplasia	3 (0.3)	0	13 (7.8)	0	16 (1.2)
Biopsy confirmed Barrett's esophagus	2 (0.2)	0	1(0.6)	0	3 (0.2)
Gastric erosions	0	7 (7.2)	16 (9.6)	4 (3.0)	27 (2.0)
Gastric ulcers	1 (0.1)	0	0	0	1 (0.1)
Gastric cancer	0	0	0	0	0
Duodenal erosions	0	0	15 (9.0)	0	15 (1.1)
Duodenal ulcers	8 (0.9)	1 (1.0)	6 (3.6)	0	15 (1.1)
Duodenal cancer	0	0	0	0	0

Data are presented as *n* (%) or median and 25% interquartile range. CeD: Celiac disease; GI: Gastrointestinal; IQR: Interquartile range.

**Figure 1** Flow chart of participants. CeD: Celiac disease.

previous endoscopies, estimating that such analysis could detect differences by using more actualized endoscopic protocols that were temporally concordant with those reported from patients collected in the Padua and Ontario cohorts.

## RESULTS

Overall, 1404 patients were diagnosed with CeD and 1328 of them were included in the study (Figure 1). Patients with slightly positive serology but Marsh 0 or 1 (*n* = 76) were not diagnosed as CeD.

### Demographic and clinical characteristics

The number of participants recruited varied between centers (Tables 1 and 2). The Naples/Salerno cohort contained most (70.0%) of the patients, while the Buenos Aires cohort had the fewest patients (7.3%). The European and North American centers differed in the length of time the celiac centers had been operational. The South American center included patients and controls over a specific time previously enrolled in a different study. There was a female predominance in all groups. There was no difference in the age at which diagnostic endoscopy was performed. There were no differences in baseline demographics across centers. The percentage of patients testing positive for celiac specific antibodies ranged from 88% (Hamilton) to 100% (Buenos Aires).

### Endoscopic findings in CeD patients and age-related damage

Endoscopy revealed 163 distinct abnormalities in 135 patients with CeD (10.1%) (Table 1). The most common finding was erosive reflux esophagitis (6.4%), with the highest prevalence in the Naples/Salerno cohort (8.4%) and the lowest in the Buenos Aires (1%) and Padua (0%) cohorts. Peptic esophageal ulcers were only found in 1 patient within the total cohort. Although Barrett's esophagus was suspected in 1.2% of the patients, it was biopsy confirmed in 0.2% of cases (18.7% of those suspected and subsequently biopsied). The Hamilton cohort had a higher suspicion of metaplasia ( $n = 13$ ), but Barrett's esophagus was confirmed in 1 patient (Table 1). Gastric ulcers were found in 1 patient (0.1%) within the Naples/Salerno cohort, while gastric erosions were found in 2.0% of the total population, with a higher prevalence in the Buenos Aires (7.2%) and the Hamilton (9.6%) cohorts. In the latter, 9.1% of patients with duodenal erosion were documented. Overall, 1.1% of duodenal ulcers were discovered, with a higher frequency encountered in the Hamilton cohort (3.6%). No cancers were reported at any level of the upper gastrointestinal (GI) tract of CeD patients.

Patients under the age of 50 had a lower risk of having at least one abnormality compared with patients over the age of 51 ( $P < 0.01$ ). This indicated a 96.6% increase in lesions found in older patients (8.9% vs 17.5%), which was primarily driven by erosive esophagitis and gastric erosions (Table 2). We performed a subgroup analysis of the Naples/Salerno cohort, including patients diagnosed between 2018 and 2021. Compared with the overall Naples/Salerno cohort, patients diagnosed recently ( $n = 86$ ) had a higher percentage of at least one significant endoscopic abnormality (29.2% vs 9.6%, respectively), owing to a higher proportion of cases with erosive reflux esophagitis (20.0% vs 8.4%) and duodenal ulcers (8.2% vs 0.9%, respectively). These endoscopic features were more common in the Naples/Salerno cohort (after 2018) than in the other cohorts (Padua and Hamilton) ( $P < 0.01$ ). Compared with the Padua cohort, the Salerno cohort had a higher proportion of patients with at least one endoscopic abnormality (29.1% vs 3.0%;  $P < 0.01$ ) (Supplementary Table 1).

### Endoscopic findings in celiac patients and non-celiac controls from the Buenos Aires cohort

We compared CeD patients ( $n = 97$ ) vs non-CeD controls ( $n = 674$ ) (Table 3) using the Buenos Aires cohort. The median age at endoscopy in non-CeD controls was 11 years higher than in patients with CeD, and the percent of females was lower ( $P < 0.01$  for both). Compared with patients with CeD, a higher proportion of controls were under the age of 50 ( $P < 0.001$ ) (Table 3). CeD specific serology was positive in 1.3% of non-CeD controls. IgA transglutaminase positive levels in controls were less than three times the upper limit of normal. Endoscopic findings were more frequent in controls than in CeD patients ( $P < 0.001$ ). In all age groups, gastric erosions were most common. Two control subjects, both older than 51, had a stomach adenocarcinoma and another a duodenal cancer at diagnostic endoscopy. In contrast, no cancers were discovered in CeD patients. Metaplasia was found in 1.0% of controls, with Barrett's esophagus being confirmed after biopsy in two of these cases. Controls over the age of 51 had 12.9% more frequent mucosal damage compared with younger subjects (overall prevalence 31.4% vs 27.8%, respectively).

The crude multivariate analysis based on CeD patients and non-CeD controls found that a CeD diagnosis and presence of alarm symptoms (weight loss, anemia, bleeding, dysphagia, epigastric pain, or history of malignancy) reduced the risk of having at least one lesion by 78.0% and 49.0% ( $P < 0.0001$  for both), respectively. According to the adjusted multivariate analysis, having CeD was associated with a 72% reduction in the risk of any endoscopic lesion ( $P < 0.0001$ ), and having alarm symptoms was associated with a 37% reduction in the risk of having at least one endoscopic lesion ( $P < 0.02$ ; Table 4).

## DISCUSSION

The study's main finding was that upper endoscopy performed concurrently with duodenal biopsies for CeD diagnosis revealed no concomitant damage in 92.0% of cases. Only 1.6% of CeD patients had relevant findings with the potential to progress to severe disease, comprised by esophageal and gastric ulcers and Barrett's esophagus. While 8.9% of patients demonstrated upper GI injury, only 1.3% potentially had dangerous lesions. The low yield of relevant concomitant findings in this study does not support the usefulness of upper endoscopy beyond the need of obtaining biopsies for the diagnosis of CeD.



**Table 2 Demography, celiac disease serology, and endoscopic findings of the overall population and by the age of diagnosis**

Demographic data and upper GI endoscopic findings	Overall CeD population	≤ 50 yr	51-60 yr	≥ 61 yr
Patients	1328	1140 (85.8)	114 (8.6)	74 (5.6)
Age in yr	35 (26-43)	33 (25-39)	55 (53-56)	67 (63-71)
Female sex	1064 (80.1)	931 (81.7)	82 (71.9)	51 (41.0)
Patients with positive serology	1269 (95.6)	1092 (95.8)	109 (95.6)	68 (91.9)
Patients with at least one significant endoscopic abnormalities	135 (10.1)	102 (8.9) <sup>1</sup>	20 (17.5)	13 (17.6)
Reflux esophagitis with erosions	85 (6.4)	69 (6.0)	12 (10.5)	4 (5.4)
Esophageal ulcers	1 (0.2)	1 (0.1)	0	0
Esophageal cancer	0	0	0	0
Suspicion of metaplasia	16 (1.2)	10 (0.9)	3 (2.6)	2 (2.7)
Biopsy confirmed Barrett's esophagus	3 (0.2)	2 (0.2)	0	1 (1.3)
Gastric erosions	27 (2.0)	20 (1.7)	3 (2.6)	4 (5.4)
Gastric ulcers	1 (0.1)	1 (0.1)	0	0
Gastric cancer	0	0	0	0
Duodenal erosions	15 (1.1)	8 (0.7)	3 (2.6)	4 (5.4)
Duodenal ulcers	15 (1.1)	10 (0.9)	4 (3.5)	1 (1.3)
Duodenal cancer	0	0	0	0

<sup>1</sup>≤ 50-years-old *vs* other age categorizations: *vs* patients > 51-years-old: *P* < 0.01. Data are presented as *n* (%) or median and 25% interquartile range.  
CeD: Celiac disease; GI: Gastrointestinal.

The possibility of detecting important or relevant esophageal, gastric, or duodenal pathology during diagnostic endoscopy has been put forward as an added benefit to the confirmation of CeD. Previous findings in CeD patients include reflux esophagitis, esophageal eosinophilia or eosinophilic esophagitis (mostly in children), Barrett's esophagus, *Helicobacter pylori* (*H. pylori*) infection and autoimmune gastritis[14-16]. These were, however, reported in small populations and single center studies. Our study, which included cohorts from the European Union, North America, and South America, gathered the largest sample of patients reported to date. The sample size collectively obtained allowed for subgroup and age category comparisons. The majority of CeD patients were young and female, as expected. The Buenos Aires cohort was prospectively designed to diagnose symptomatic patients suspected of having CeD, which allowed for comparisons between CeD patients and controls biopsy (Marsh's 0 or 1 histology categorization).

Our findings in a large multicenter population confirm recent reports that adult patients with alarm symptoms have a very low prevalence of major endoscopic and histological findings in the upper GI tract other than CeD features at presentation and was comparable to that of patients without alarm symptoms[14,16]. The definition of what constitutes an alarming symptom for CeD at the time of diagnosis appears to be central to this analysis. Weight loss, iron deficiency anemia, pain, or malabsorption symptoms were prevalent among symptomatic patients, which constitutes the vast majority of currently diagnosed CeD patients since a case finding strategy is recommended[19]. However, our findings were limited to the upper GI tract, and the lower GI tract was not explored.

Erosive reflux esophagitis was the most common endoscopic finding at the time of diagnosis (6.4%). Notably, undiagnosed patients with classical or subclinical CeD frequently seek treatment for gastroesophageal reflux symptoms prior to diagnosis, which has been shown to be more common in subjects in whom CeD is ruled out or in those treated with the GFD[20]. We previously reported that up to 30% of newly diagnosed CeD patients perceive moderate to severe reflux symptoms, which does not respond to anti-reflux therapy prior to CeD diagnosis[21,22]. Most of these "non-responsive" patients to anti-reflux therapy will rapidly improve after starting the GFD. Surprisingly, between 2018 and 2021, the Naples/Salerno cohort revealed higher prevalence of overall endoscopic lesions, and specifically of erosive reflux esophagitis, compared with diagnoses made before that time. This could be attributed to the characteristics of the CeD population over time or to differences in the reporting of endoscopic and histology findings.

The possibility of missing severe lesions or potentially dangerous diseases in CeD patients if a diagnostic endoscopy is not performed has been a source of concern in CeD guidelines[2,4]. With respect to Barrett's esophagus or esophageal metaplasia, an Italian study published in 2005 showed

**Table 3 Demography and endoscopic findings in celiac disease patients and non-celiac disease controls of the Buenos Aires cohort**

Demographic data and upper GI endoscopic findings	CeD population	Non-CeD population	≤ 50 yr non-CeD	51-60 yr non-CeD	≥ 61 yr non-CeD
Patients	97 (12.6)	674 (87.4)	435 (64.5)	135 (20.0)	104 (15.4)
Age in yr	35 (27-44)	45 (33-55) <sup>a</sup>	37 (29-44)	55 (53-58)	68 (63-72)
Female sex	88 (90.7)	472 (70.0) <sup>a</sup>	312 (71.7)	92 (68.1)	68 (65.4)
Patients with positive serology	97 (100)	9 (1.3) <sup>a</sup>	6 (1.3)	3 (2.2)	0
Patients with at least one significant endoscopic abnormalities	8 (8.2)	196 (29.1) <sup>b</sup>	121 (27.8)	48 (35.6)	27 (26.0)
Reflux esophagitis with erosions	1 (1.0)	21 (3.1)	11 (2.5)	2 (1.5)	5 (4.8)
Esophageal ulcers	0	0	0	0	0
Esophageal cancer	0	0	0	0	0
Suspicion of metaplasia	0	7 (1.0)	5 (1.1)	2 (1.5)	0
Biopsy confirmed Barrett's esophagus	0	2 (0.3)	2 (0.5)	0	0
Gastric erosions	7 (7.22)	165 (24.5) <sup>a</sup>	103 (23.7)	43 (31.8)	19 (18.3)
Gastric ulcers	0 (0)	11 (1.6)	4(0.9)	2 (1.5)	5 (4.8)
Gastric cancer	0	2 (0.3)	0	1 (0.7)	1 (1.0)
Duodenal erosions	0	10 (1.5)	6 (1.4)	2 (1.5)	2 (1.9)
Duodenal ulcers	1 (1.0)	5 (0.7)	2 (0.5)	2 (1.5)	1 (1.0)
Duodenal cancer	0	1 (0.1)	1 (0.2)	0	0

<sup>a</sup>*P* < 0.01.<sup>b</sup>*P* < 0.001.

Data are presented as *n* (%) or median and 25% interquartile range. Controls were grouped according to age at endoscopy. Comparisons between celiac disease patients *vs* non-celiac disease controls.

CeD: Celiac disease; GI: Gastrointestinal; IQR: Interquartile range.

**Table 4 Crude and adjusted multivariate analysis for the Buenos Aires cohort**

Independent variable	At least one endoscopic lesion <sup>1</sup> (Buenos Aires cohort)			
	OR (95%CI)	<i>P</i> value	Adjusted <sup>2</sup> OR (95%CI)	<i>P</i> value
Male sex	1.19 (0.83-1.69)	0.34	1.03 (0.72-1.48)	0.860
Age	1.01 (1.00-1.02)	0.14	1.00 (0.99-1.01)	0.550
Celiac disease	0.22 (0.10-0.46)	< 0.0001	0.28 (0.13-0.60)	0.001
Alarm symptoms <sup>3</sup>	0.51 (0.35-0.74)	< 0.0001	0.63 (0.43-0.93)	0.020

<sup>1</sup>At least one endoscopic lesion: Erosive esophagitis, esophageal ulcer, esophageal cancer, Barrett's esophagus, gastric erosion, gastric ulcer, gastric cancer, duodenal erosion, duodenal ulcer, duodenal cancer.

<sup>2</sup>Weight loss, anemia, bleeding, dysphagia, epigastric pain, neoplasia history.

<sup>3</sup>Weight loss, iron deficient anemia, malabsorption, chronic diarrhea.

CI: Confidence interval; M: Male; OR: Odds ratio.

metaplasia in 26.6% of CeD patients compared with 10.9% of the control population[23]. This was not confirmed in studies from the United States[24] and South America[15,21] nor by the present study. Reasons for this discrepancy could be related to differences in populations and in the definition of Barrett's esophagus, which required confirmation by biopsy in our study.

In the present study, we did not find mucosal eosinophilic infiltration. A pediatric prospective longitudinal study based on systematic esophageal biopsies found that diagnoses of eosinophilic esophagitis and/or eosinophilia were not clinically relevant, suggesting esophageal biopsy is not necessary in the absence of clinical suspicion[25]. A 2015 cross-sectional population study in the United States based on a national pathology database involving over 88000 CeD patients with both esophageal and duodenal biopsies, reported a slight increase in comorbid eosinophilic esophagitis and CeD[24]. However, no link

between reflux esophagitis or Barrett's esophagus and CeD has been reported. Finally, autoimmune atrophic gastritis was previously modestly associated with CeD[26]. Our study, as well as other population-based studies and systematic reviews, did not confirm the association[27,28].

An earlier prospective study[15] collected consecutive patients and non-CeD controls in a high-risk population for having CeD, and gastric and duodenal biopsies were performed systematically at the time of the diagnostic endoscopy CeD and biopsy. Gastric biopsies from untreated CeD patients also revealed a significantly higher intraepithelial lymphocyte count in the antrum and corpus when compared with controls[15,29,30]. According to an Irish study, 10% of CeD patients have lymphocytic gastritis, which is twice the rate of non-CeD controls[12,14]. These findings are attributed to *H. pylori* infection, autoimmune atrophic gastritis[15,26], or a pan-mucosal gluten-related inflammation[14,15,29,30].

Our study showed only 1 CeD patient had a gastric peptic ulcer. Previous studies found 18.1% of CeD children with gastric ulcers, with a higher prevalence in *H. pylori* negative patients and those with no history of nonsteroidal anti-inflammatory drug use[31,32]. The rate of *H. pylori* infection across centers was not consistently reported here, and this could explain the difference in results. Previous research, however, has shown that high rates of biopsy-confirmed *H. pylori* infection are not associated with an increased risk of malignancy in the long term[27,33]. However, several studies have also shown that when endoscopic appearance is normal, histological evaluation (both in the stomach and the esophagus) is not cost-effective, especially when performed in experienced academic centers[34-36].

There was no diagnosis of gastric adenocarcinoma in CeD. Despite the small number of cases studied, this is consistent with previous findings that the prevalence of other cancers (breast, colon, pulmonary, and gynecological cancers) in CeD appears to be lower than in the general population[27,28]. Small bowel carcinoma is extremely rare in the general population, and CeD patients are three times more likely to develop it[1,28]. However, malignancies in the duodenum are still uncommon at the time of CeD diagnosis, which implies diagnostic CeD endoscopy should not be recommended as surveillance for upper GI cancer[28]. Overall, the current findings, as well as those from previous studies, suggest that a biopsy-avoiding approach in adult patients who meet recommended and strict serological criteria for CeD is possible[12,37-40].

Study strengths included the multicenter design, the large number of patients diagnosed at specialized centers for CeD in whom confirmatory biopsy diagnosis was obtained, as well as the use of standard endoscopic protocols. Despite the small numbers in sub-analyses, the study also provided novel data related to the association of endoscopic findings according to age and time. Study limitations included the observational design, the retrospective collection of endoscopic reports (with potential missing data), the differences in time of enrollment across the four centers, the lack of systematic collection of biopsies from the esophagus and stomach, and the limited number of non-CeD controls. Although the current study suggests that missing potentially serious events is unlikely, this should be confirmed in a larger population.

## CONCLUSION

In conclusion, this multicenter, retrospective study found that comorbid upper GI endoscopic pathology is uncommon in patients with positive CeD serology at the time of diagnostic endoscopy. The risk of severe or premalignant lesions is extremely low, and no malignancies were found in patients who displayed potential warning signs. Our findings suggest that a non-biopsy strategy for diagnosing CeD in adults is unlikely to miss clinically significant concomitant endoscopic findings unrelated to CeD. The results of this study should encourage future population-based or prospective studies in this area.

## ARTICLE HIGHLIGHTS

### Research background

Celiac disease (CeD) is currently diagnosed in adult patients using a combination of specific serology tests and a duodenal biopsy obtained through an upper endoscopy. Upper endoscopy is also considered necessary for CeD diagnosis because non-CeD comorbidities can be missed.

### Research motivation

The prevalence of upper gastrointestinal comorbidities at the time of CeD diagnosis has received little attention.

### Research objectives

To investigate the prevalence of coincidental upper gastrointestinal endoscopic findings at the time of diagnostic endoscopy in four cohorts of patients diagnosed in three different countries.

## Research methods

We conducted a descriptive multicenter retrospective study reporting endoscopic findings from adult patients who met standard criteria for diagnosing CeD.

## Research results

Of 1328 adult patients enrolled, 95.6% had positive specific serology. In 135 patients, endoscopy revealed 163 abnormalities unrelated to CeD (10.1%). Erosive reflux esophagitis (6.4%), gastric erosions (2.0%), and suspicion of esophageal metaplasia (1.2%) were the most common findings. Biopsy-confirmed Barrett's esophagus was infrequent (0.2%). No other neoplastic or malignancies lesions were detected. Patients with alarm symptoms or signs had a lower rate of concomitant findings.

## Research conclusions

Adults with positive CeD serology had few comorbid endoscopic findings when CeD was diagnosed.

## Research perspectives

These findings raise the possibility that adult patients who meet recommended and strict serological criteria for CeD could be diagnosed without undergoing endoscopy and biopsy.

## FOOTNOTES

**Author contributions:** Stefanolo JP, Ciacci C, Zingone F, Gizzi C, Marsilio I, Espinet ML, Pinto-Sánchez MI, and Niveloni SI contributed with data acquisition; Stefanolo JP performed the statistical analysis; Stefanolo JP, Pinto-Sánchez MI, Ciacci C, Zingone F, and Bai JC contributed to study design; Verdú EF, Smecuol EG, Moreno ML contributed to critical analysis; Bai JC, Verdú EF, Ciacci C, Pinto-Sánchez MI and Zingone F contributed to writing and critical review of the manuscript; All authors read and approved the final manuscript.

**Institutional review board statement:** The Ethics and Research Board of the Dr. C. Bonorino Udaondo Gastroenterology Hospital approved the study because of the prospective design and intervention in the Buenos Aires cohort. Ethics approval was obtained from the Hamilton Integrated Research Ethics Board (HiREB# 14460/5415). In Italy, Ethical Committee review was not required for retrospective studies while patient data remained anonymously coded.

**Informed consent statement:** Informed consent was not required by the Ethics and Research Committee of the Hospital de Gastroenterología Dr. C. Bonorino Udaondo (Buenos Aires, Argentina) given the retrospective nature of the study and because this study was categorized as minimal risk by the Committee.

**Conflict-of-interest statement:** All the authors report no relevant conflicts of interest for this article.

**Data sharing statement:** Technical appendix, statistical code, and dataset available from the corresponding author at [jbai@intramed.net](mailto:jbai@intramed.net). Consent was not obtained, but the presented data are anonymized and risk of identification is low.

**Open-Access:** This article is an open-access article that was selected by an in-house editor and fully peer-reviewed by external reviewers. It is distributed in accordance with the Creative Commons Attribution NonCommercial (CC BY-NC 4.0) license, which permits others to distribute, remix, adapt, build upon this work non-commercially, and license their derivative works on different terms, provided the original work is properly cited and the use is non-commercial. See: <https://creativecommons.org/licenses/by-nc/4.0/>

**Country/Territory of origin:** Argentina

**ORCID number:** Juan Pablo Stefanolo 0000-0003-0679-3470; Fabiana Zingone 0000-0003-1133-1502; Edgardo Gustavo Smecuol 0000-0002-4451-819X; María Laura Moreno 0000-0002-0120-8789; María I Pinto-Sánchez 0000-0002-9040-9824; Sonia Isabel Niveloni 0000-0002-1534-1604; Elena F Verdú 0000-0001-6346-2665; Carolina Ciacci 0000-0002-7426-1145; Julio César Bai 0000-0003-4159-0185.

**S-Editor:** Fan JR

**L-Editor:** Filipodia

**P-Editor:** Fan JR

## REFERENCES

- 1 Catassi C, Verdú EF, Bai JC, Lionetti E. Coeliac disease. *Lancet* 2022; **399**: 2413-2426 [PMID: 35691302 DOI: 10.1016/S0140-6736(22)00794-2]



- 2 **Al-Toma A**, Volta U, Auricchio R, Castillejo G, Sanders DS, Cellier C, Mulder CJ, Lundin KEA. European Society for the Study of Coeliac Disease (ESsCD) guideline for coeliac disease and other gluten-related disorders. *United European Gastroenterol J* 2019; **7**: 583-613 [PMID: [31210940](#) DOI: [10.1177/2050640619844125](#)]
- 3 **Lebwohl B**, Sanders DS, Green PHR. Coeliac disease. *Lancet* 2018; **391**: 70-81 [PMID: [28760445](#) DOI: [10.1016/S0140-6736\(17\)31796-8](#)]
- 4 **Lebwohl B**, Rubio-Tapia A, Assiri A, Newland C, Guandalini S. Diagnosis of celiac disease. *Gastrointest Endosc Clin N Am* 2012; **22**: 661-677 [PMID: [23083985](#) DOI: [10.1016/j.giec.2012.07.004](#)]
- 5 **Husby S**, Murray JA. Diagnosing coeliac disease and the potential for serological markers. *Nat Rev Gastroenterol Hepatol* 2014; **11**: 655-663 [PMID: [25266110](#) DOI: [10.1038/nrgastro.2014.162](#)]
- 6 **Valdimarsson T**, Franzen L, Grodzinsky E, Skogh T, Ström M. Is small bowel biopsy necessary in adults with suspected celiac disease and IgA anti-endomysium antibodies? *Dig Dis Sci* 1996; **41**: 83-87 [PMID: [8565771](#) DOI: [10.1007/BF02208588](#)]
- 7 **Kurppa K**, Taavela J, Saavalainen P, Kaukinen K, Lindfors K. Novel diagnostic techniques for celiac disease. *Expert Rev Gastroenterol Hepatol* 2016; **10**: 795-805 [PMID: [26838683](#) DOI: [10.1586/17474124.2016.1148599](#)]
- 8 **Fuchs V**, Kurppa K, Huhtala H, Laurila K, Mäki M, Collin P, Salmi T, Luostarinen L, Saavalainen P, Kaukinen K. Serology-based criteria for adult coeliac disease have excellent accuracy across the range of pre-test probabilities. *Aliment Pharmacol Ther* 2019; **49**: 277-284 [PMID: [30592070](#) DOI: [10.1111/apt.15109](#)]
- 9 **Husby S**, Koletzko S, Korponay-Szabó IR, Mearin ML, Phillips A, Shamir R, Troncone R, Giersiepen K, Branski D, Catassi C, Leigeman M, Mäki M, Ribes-Koninckx C, Ventura A, Zimmer KP; ESPGHAN Working Group on Coeliac Disease Diagnosis; ESPGHAN Gastroenterology Committee; European Society for Pediatric Gastroenterology, Hepatology, and Nutrition. European Society for Pediatric Gastroenterology, Hepatology, and Nutrition guidelines for the diagnosis of coeliac disease. *J Pediatr Gastroenterol Nutr* 2012; **54**: 136-160 [PMID: [22197856](#) DOI: [10.1097/MPG.0b013e31821a23d0](#)]
- 10 **Husby S**, Koletzko S, Korponay-Szabó I, Kurppa K, Mearin ML, Ribes-Koninckx C, Shamir R, Troncone R, Auricchio R, Castillejo G, Christensen R, Dolinsek J, Gillett P, Hróbjartsson A, Koltai T, Maki M, Nielsen SM, Popp A, Størdal K, Werkstetter K, Wessels M. European Society Paediatric Gastroenterology, Hepatology and Nutrition Guidelines for Diagnosing Coeliac Disease 2020. *J Pediatr Gastroenterol Nutr* 2020; **70**: 141-156 [PMID: [31568151](#) DOI: [10.1097/MPG.0000000000002497](#)]
- 11 **Hill ID**, Fasano A, Guandalini S, Hoffenberg E, Levy J, Reilly N, Verma R. NASPGHAN Clinical Report on the Diagnosis and Treatment of Gluten-related Disorders. *J Pediatr Gastroenterol Nutr* 2016; **63**: 156-165 [PMID: [27035374](#) DOI: [10.1097/MPG.0000000000001216](#)]
- 12 **Eftymakis K**, Serio M, Milano A, Laterza F, Bonitatibus A, Di Nicola M, Neri M. Application of the Biopsy-Sparing ESPGHAN Guidelines for Celiac Disease Diagnosis in Adults: A Real-Life Study. *Dig Dis Sci* 2017; **62**: 2433-2439 [PMID: [28717844](#) DOI: [10.1007/s10620-017-4672-1](#)]
- 13 **Husby S**, Murray JA, Katzka DA. AGA Clinical Practice Update on Diagnosis and Monitoring of Celiac Disease—Changing Utility of Serology and Histologic Measures: Expert Review. *Gastroenterology* 2019; **156**: 885-889 [PMID: [30578783](#) DOI: [10.1053/j.gastro.2018.12.010](#)]
- 14 **Feeley KM**, Heneghan MA, Stevens FM, McCarthy CF. Lymphocytic gastritis and coeliac disease: evidence of a positive association. *J Clin Pathol* 1998; **51**: 207-210 [PMID: [9659261](#) DOI: [10.1136/jcp.51.3.207](#)]
- 15 **Diamanti A**, Maino C, Niveloni S, Pedreira S, Vazquez H, Smecuol E, Fiorini A, Cabanne A, Bartellini MA, Kogan Z, Valero J, Mauriño E, Bai JC. Characterization of gastric mucosal lesions in patients with celiac disease: a prospective controlled study. *Am J Gastroenterol* 1999; **94**: 1313-1319 [PMID: [10235212](#) DOI: [10.1111/j.1572-0241.1999.01082.x](#)]
- 16 **Maimaris S**, Schieppatti A, Gabrielli GM, Costetti M, Costa S, Sanders DS, Zingone F, Carroccio A, Ciacci C, Di Sabatino A, Biagi F. Low prevalence of upper endoscopic gastrointestinal findings despite high frequency of alarm symptoms at the time of diagnosis in adult coeliac disease. *Eur J Gastroenterol Hepatol* 2020; **32**: 1447-1451 [PMID: [32675775](#) DOI: [10.1097/MEG.0000000000001829](#)]
- 17 **Aabakken L**, Barkun AN, Cotton PB, Fedorov E, Fujino MA, Ivanova E, Kudo SE, Kuznetsov K, de Lange T, Matsuda K, Moine O, Rembacken B, Rey JF, Romagnuolo J, Rösch T, Sawhney M, Yao K, Wayne JD. Standardized endoscopic reporting. *J Gastroenterol Hepatol* 2014; **29**: 234-240 [PMID: [24329727](#) DOI: [10.1111/jgh.12489](#)]
- 18 **Kelly CP**, Bai JC, Liu E, Leffler DA. Advances in diagnosis and management of celiac disease. *Gastroenterology* 2015; **148**: 1175-1186 [PMID: [25662623](#) DOI: [10.1053/j.gastro.2015.01.044](#)]
- 19 **Tack GJ**, Verbeek WH, Schreurs MW, Mulder CJ. The spectrum of celiac disease: epidemiology, clinical aspects and treatment. *Nat Rev Gastroenterol Hepatol* 2010; **7**: 204-213 [PMID: [20212505](#) DOI: [10.1038/nrgastro.2010.23](#)]
- 20 **Ludvigsson JF**, Aro P, Walker MM, Vieth M, Agréus L, Talley NJ, Murray JA, Ronkainen J. Celiac disease, eosinophilic esophagitis and gastroesophageal reflux disease, an adult population-based study. *Scand J Gastroenterol* 2013; **48**: 808-814 [PMID: [23672638](#) DOI: [10.3109/00365521.2013.792389](#)]
- 21 **Leffler DA**, Kelly CP. Celiac disease and gastroesophageal reflux disease: yet another presentation for a clinical chameleon. *Clin Gastroenterol Hepatol* 2011; **9**: 192-193 [PMID: [21145426](#) DOI: [10.1016/j.cgh.2010.11.039](#)]
- 22 **Reilly NR**, Husby S, Sanders DS, Green PHR. Coeliac disease: to biopsy or not? *Nat Rev Gastroenterol Hepatol* 2018; **15**: 60-66 [PMID: [29018278](#) DOI: [10.1038/nrgastro.2017.121](#)]
- 23 **Maieron R**, Elli L, Marino M, Floriani I, Minerva F, Avellini C, Falconieri G, Pizzolitto S, Zilli M. Celiac disease and intestinal metaplasia of the esophagus (Barrett's esophagus). *Dig Dis Sci* 2005; **50**: 126-129 [PMID: [15712649](#) DOI: [10.1007/s10620-005-1289-6](#)]
- 24 **Jensen ET**, Eluri S, Lebwohl B, Genta RM, Dellon ES. Increased Risk of Esophageal Eosinophilia and Eosinophilic Esophagitis in Patients With Active Celiac Disease on Biopsy. *Clin Gastroenterol Hepatol* 2015; **13**: 1426-1431 [PMID: [25724709](#) DOI: [10.1016/j.cgh.2015.02.018](#)]
- 25 **Cristofori F**, D'Abramo FS, Rutigliano V, Dargenio VN, Castellaneta S, Piscitelli D, De Benedittis D, Indrio F, Raguseo LC, Barone M, Francavilla R. Esophageal Eosinophilia and Eosinophilic Esophagitis in Celiac Children: A Ten Year Prospective Observational Study. *Nutrients* 2021; **13** [PMID: [34836010](#) DOI: [10.3390/nu13113755](#)]

- 26 **Zingone F**, Marsilio I, Fassan M, Pilotto V, Maddalo G, Lorenzon G, Savarino EV, Farinati F. Duodenal Histological Findings and Risk of Coeliac Disease in Subjects with Autoimmune Atrophic Gastritis: A Retrospective Evaluation. *Digestion* 2021; **102**: 615-621 [PMID: [33075781](#) DOI: [10.1159/000510354](#)]
- 27 **Lebwohl B**, Green PHR, Söderling J, Roelstraete B, Ludvigsson JF. Association Between Celiac Disease and Mortality Risk in a Swedish Population. *JAMA* 2020; **323**: 1277-1285 [PMID: [32259229](#) DOI: [10.1001/jama.2020.1943](#)]
- 28 **Pelizzaro F**, Marsilio I, Fassan M, Piazza F, Barberio B, D'Odorico A, Savarino EV, Farinati F, Zingone F. The Risk of Malignancies in Celiac Disease-A Literature Review. *Cancers (Basel)* 2021; **13** [PMID: [34771450](#) DOI: [10.3390/cancers13215288](#)]
- 29 **Lynch DA**, Sobala GM, Dixon MF, Gledhill A, Jackson P, Crabtree JE, Axon AT. Lymphocytic gastritis and associated small bowel disease: a diffuse lymphocytic gastroenteropathy? *J Clin Pathol* 1995; **48**: 939-945 [PMID: [8537495](#) DOI: [10.1136/jcp.48.10.939](#)]
- 30 **Cuoco L**, Cammarota G, Tursi A, Papa A, Certo M, Cianci R, Fedeli G, Gasbarrini G. Disappearance of gastric mucosa-associated lymphoid tissue in coeliac patients after gluten withdrawal. *Scand J Gastroenterol* 1998; **33**: 401-405 [PMID: [9605262](#) DOI: [10.1080/00365529850171035](#)]
- 31 **Levine A**, Domanov S, Sukhotnik I, Zangen T, Shaoul R. Celiac-associated peptic disease at upper endoscopy: how common is it? *Scand J Gastroenterol* 2009; **44**: 1424-1428 [PMID: [19883278](#) DOI: [10.3109/00365520903307987](#)]
- 32 **Tumgor G**, Agin M, Doran F, Cetiner S. Frequency of Celiac Disease in Children with Peptic Ulcers. *Dig Dis Sci* 2018; **63**: 2681-2686 [PMID: [29946872](#) DOI: [10.1007/s10620-018-5174-5](#)]
- 33 **Ciacci C**, Squillante A, Rendina D, Limauro S, Bencivenga C, Labanca F, Romano R, Mazzacca G. Helicobacter pylori infection and peptic disease in coeliac disease. *Eur J Gastroenterol Hepatol* 2000; **12**: 1283-1287 [PMID: [11192316](#) DOI: [10.1097/00042737-200012120-00004](#)]
- 34 **Levy N**, Stermer E, Boss JM. Accuracy of endoscopy in the diagnosis of inflamed gastric and duodenal mucosa. *Isr J Med Sci* 1985; **21**: 564-568 [PMID: [4044216](#)]
- 35 **Dahshan A**, Rabah R. Correlation of endoscopy and histology in the gastroesophageal mucosa in children: are routine biopsies justified? *J Clin Gastroenterol* 2000; **31**: 213-216 [PMID: [11033999](#) DOI: [10.1097/00004836-200010000-00005](#)]
- 36 **Sheiko MA**, Feinstein JA, Capocelli KE, Kramer RE. The concordance of endoscopic and histologic findings of 1000 pediatric EGDs. *Gastrointest Endosc* 2015; **81**: 1385-1391 [PMID: [25440693](#) DOI: [10.1016/j.gie.2014.09.010](#)]
- 37 **Wolf J**, Petroff D, Richter T, Auth MKH, Uhlig HH, Laass MW, Lauenstein P, Krah A, Händel N, de Laffolie J, Hauer AC, Kehler T, Flemming G, Schmidt F, Rodrigues A, Hasenclever D, Mothes T. Validation of Antibody-Based Strategies for Diagnosis of Pediatric Celiac Disease Without Biopsy. *Gastroenterology* 2017; **153**: 410-419.e17 [PMID: [28461188](#) DOI: [10.1053/j.gastro.2017.04.023](#)]
- 38 **Oyaert M**, Vermeersch P, De Hertogh G, Hiele M, Vandeputte N, Hoffman I, Bossuyt X. Combining antibody tests and taking into account antibody levels improves serologic diagnosis of celiac disease. *Clin Chem Lab Med* 2015; **53**: 1537-1546 [PMID: [25719330](#) DOI: [10.1515/ccbm-2013-1099](#)]
- 39 **Penny HA**, Raju SA, Lau MS, Marks LJ, Baggus EM, Bai JC, Bassotti G, Bontkes HJ, Carroccio A, Danciu M, Derakhshan MH, Ensari A, Ganji A, Green PHR, Johnson MW, Ishaq S, Lebwohl B, Levene A, Maxim R, Mohaghegh Shalmani H, Rostami-Nejad M, Rowlands D, Spiridon IA, Srivastava A, Volta U, Villanacci V, Wild G, Cross SS, Rostami K, Sanders DS. Accuracy of a no-biopsy approach for the diagnosis of coeliac disease across different adult cohorts. *Gut* 2021; **70**: 876-883 [PMID: [33139268](#) DOI: [10.1136/gutjnl-2020-320913](#)]
- 40 **Holmes G**, Ciacci C. The serological diagnosis of coeliac disease - a step forward. *Gastroenterol Hepatol Bed Bench* 2018; **11**: 209-215 [PMID: [30013744](#)]



Published by **Baishideng Publishing Group Inc**  
7041 Koll Center Parkway, Suite 160, Pleasanton, CA 94566, USA

**Telephone:** +1-925-3991568

**E-mail:** [bpgoffice@wjgnet.com](mailto:bpgoffice@wjgnet.com)

**Help Desk:** <https://www.f6publishing.com/helpdesk>

<https://www.wjgnet.com>

