

World Journal of *Clinical Cases*

World J Clin Cases 2022 December 6; 10(34): 12462-12803



Contents

Thrice Monthly Volume 10 Number 34 December 6, 2022

FIELD OF VISION

- 12462 Problematics of neurosurgical service during the COVID-19 pandemic in Slovenia
Munda M, Bosnjak R, Velnar T

MINIREVIEWS

- 12470 Circulating angiotensin converting enzyme 2 and COVID-19
Leowattana W, Leowattana T, Leowattana P
- 12484 Evaluation of gut dysbiosis using serum and fecal bile acid profiles
Monma T, Iwamoto J, Ueda H, Tamamushi M, Kakizaki F, Konishi N, Yara S, Miyazaki T, Hirayama T, Ikegami T, Honda A
- 12494 Pediatric kidney transplantation during the COVID-19 pandemic
Tamura H

ORIGINAL ARTICLE

Clinical and Translational Research

- 12500 *Coptis*, *Pinellia*, and *Scutellaria* as a promising new drug combination for treatment of *Helicobacter pylori* infection
Yu Z, Sheng WD, Yin X, Bin Y

Case Control Study

- 12515 Effects of illness perception on negative emotions and fatigue in chronic rheumatic diseases: Rumination as a possible mediator
Lu Y, Jin X, Feng LW, Tang C, Neo M, Ho RC

Retrospective Study

- 12532 Significance of incidental focal fluorine-18 fluorodeoxyglucose uptake in colon/rectum, thyroid, and prostate: With a brief literature review
Lee H, Hwang KH
- 12543 Follow-up study on ThinPrep cytology test-positive patients in tropical regions
Chen YC, Liang CN, Wang XF, Wang MF, Huang XN, Hu JD
- 12551 Effect of teach-back health education combined with structured psychological nursing on adverse emotion and patient cooperation during ^{99m}Tc -3PRGD2.SPECT/CT
Gong WN, Zhang YH, Niu J, Li XB
- 12559 Nosocomial infection and spread of SARS-CoV-2 infection among hospital staff, patients and caregivers
Cheng CC, Fann LY, Chou YC, Liu CC, Hu HY, Chu D

Observational Study

- 12566** Effectiveness and safety of generic and brand direct acting antivirals for treatment of chronic hepatitis C
Abdulla M, Al Ghareeb AM, Husain HAHY, Mohammed N, Al Qamish J
- 12578** Influence of group B *streptococcus* and vaginal cleanliness on the vaginal microbiome of pregnant women
Liao Q, Zhang XF, Mi X, Jin F, Sun HM, Wang QX

Randomized Controlled Trial

- 12587** Clinical study on tri-tongue acupuncture combined with low-frequency electrical stimulation for treating post-stroke dysarthria
Man B, Li WW, Xu JF, Wang Q

META-ANALYSIS

- 12594** Three-dimensional time-of-flight magnetic resonance angiography combined with high resolution T2-weighted imaging in preoperative evaluation of microvascular decompression
Liang C, Yang L, Zhang BB, Guo SW, Li RC

CASE REPORT

- 12605** Acute cytomegalovirus hepatitis in an immunocompetent patient: A case report
Wang JP, Lin BZ, Lin CL, Chen KY, Lin TJ
- 12610** Long-term results of extended Boari flap technique for management of complete ureteral avulsion: A case report
Zhong MZ, Huang WN, Huang GX, Zhang EP, Gan L
- 12617** Amyloid β -related angiitis of the central nervous system occurring after COVID-19 vaccination: A case report
Kizawa M, Iwasaki Y
- 12623** Pseudoileus caused by primary visceral myopathy in a Han Chinese patient with a rare *MYH11* mutation: A case report
Li N, Song YM, Zhang XD, Zhao XS, He XY, Yu LF, Zou DW
- 12631** Emergent use of tube tip in pharynx technique in "cannot intubate cannot oxygenate" situation: A case report
Lin TC, Lai YW, Wu SH
- 12637** Inflammatory myofibroblastic tumor of the central nervous system: A case report
Su ZJ, Guo ZS, Wan HT, Hong XY
- 12648** Atypical aggressive vertebral hemangioma of the sacrum with postoperative recurrence: A case report
Wang GX, Chen YQ, Wang Y, Gao CP
- 12654** Closed reduction of hip dislocation associated with ipsilateral lower extremity fractures: A case report and review of the literature
Xu Y, Lv M, Yu SQ, Liu GP

- 12665** Repair of a large patellar cartilage defect using human umbilical cord blood-derived mesenchymal stem cells: A case report
Song JS, Hong KT, Song KJ, Kim SJ
- 12671** Abdominal bronchogenic cyst: A rare case report
Li C, Zhang XW, Zhao CA, Liu M
- 12678** Malignant fibrous histiocytoma of the axilla with breast cancer: A case report
Gao N, Yang AQ, Xu HR, Li L
- 12684** Rapid hemostasis of the residual inguinal access sites during endovascular procedures: A case report
Kim H, Lee K, Cho S, Joh JH
- 12690** Formation of granulation tissue on bilateral vocal cords after double-lumen endotracheal intubation: A case report
Xiong XJ, Wang L, Li T
- 12696** Giant cellular leiomyoma in the broad ligament of the uterus: A case report
Yan J, Li Y, Long XY, Li DC, Li SJ
- 12703** Pomolidomide for relapsed/refractory light chain amyloidosis after resistance to both bortezomib and daratumumab: A case report
Li X, Pan XH, Fang Q, Liang Y
- 12711** Ureteral- artificial iliac artery fistula: A case report
Feng T, Zhao X, Zhu L, Chen W, Gao YL, Wei JL
- 12717** How to manage isolated tension non-surgical pneumoperitoneum during bronchoscopy? A case report
Baima YJ, Shi DD, Shi XY, Yang L, Zhang YT, Xiao BS, Wang HY, He HY
- 12726** Amiodarone-induced muscle tremor in an elderly patient: A case report
Zhu XY, Tang XH, Yu H
- 12734** Surgical treatment of Pitt-Hopkins syndrome associated with strabismus and early-onset myopia: Two case reports
Huang Y, Di Y, Zhang XX, Li XY, Fang WY, Qiao T
- 12742** Massive low-grade myxoid liposarcoma of the floor of the mouth: A case report and review of literature
Kugimoto T, Yamagata Y, Ohsako T, Hirai H, Nishii N, Kayamori K, Ikeda T, Harada H
- 12750** Gingival enlargement induced by cyclosporine in Medullary aplasia: A case report
Victory Rodríguez G, Ruiz Gutiérrez ADC, Gómez Sandoval JR, Lomeli Martínez SM
- 12761** Compound heterozygous mutations in PMFBP1 cause acephalic spermatozoa syndrome: A case report
Deng TQ, Xie YL, Pu JB, Xuan J, Li XM
- 12768** Colonic tubular duplication combined with congenital megacolon: A case report
Zhang ZM, Kong S, Gao XX, Jia XH, Zheng CN

- 12775** Perforated duodenal ulcer secondary to deferasirox use in a child successfully managed with laparoscopic drainage: A case report
Alshehri A, Alsinan TA
- 12781** Complication after nipple-areolar complex tattooing performed by a non-medical person: A case report
Byeon JY, Kim TH, Choi HJ
- 12787** Interventional urethral balloon dilatation before endoscopic visual internal urethrotomy for post-traumatic bulbous urethral stricture: A case report
Ha JY, Lee MS
- 12793** Regression of gastric endoscopic submucosal dissection induced polypoid nodular scar after *Helicobacter pylori* eradication: A case report
Jin BC, Ahn AR, Kim SH, Seo SY
- 12799** Congenital absence of the right coronary artery: A case report
Zhu XY, Tang XH

ABOUT COVER

Editorial Board Member of *World Journal of Clinical Cases*, Giuseppe Lanza, MD, MSc, PhD, Associate Professor, Department of Surgery and Medical-Surgical Specialties, University of Catania, Catania 95123, Italy.
glanza@oasi.en.it

AIMS AND SCOPE

The primary aim of *World Journal of Clinical Cases* (WJCC, *World J Clin Cases*) is to provide scholars and readers from various fields of clinical medicine with a platform to publish high-quality clinical research articles and communicate their research findings online.

WJCC mainly publishes articles reporting research results and findings obtained in the field of clinical medicine and covering a wide range of topics, including case control studies, retrospective cohort studies, retrospective studies, clinical trials studies, observational studies, prospective studies, randomized controlled trials, randomized clinical trials, systematic reviews, meta-analysis, and case reports.

INDEXING/ABSTRACTING

The WJCC is now abstracted and indexed in Science Citation Index Expanded (SCIE, also known as SciSearch®), Journal Citation Reports/Science Edition, Current Contents®/Clinical Medicine, PubMed, PubMed Central, Scopus, Reference Citation Analysis, China National Knowledge Infrastructure, China Science and Technology Journal Database, and Superstar Journals Database. The 2022 Edition of Journal Citation Reports® cites the 2021 impact factor (IF) for WJCC as 1.534; IF without journal self cites: 1.491; 5-year IF: 1.599; Journal Citation Indicator: 0.28; Ranking: 135 among 172 journals in medicine, general and internal; and Quartile category: Q4. The WJCC's CiteScore for 2021 is 1.2 and Scopus CiteScore rank 2021: General Medicine is 443/826.

RESPONSIBLE EDITORS FOR THIS ISSUE

Production Editor: Si Zhao; Production Department Director: Xu Guo; Editorial Office Director: Jin-Lei Wang.

NAME OF JOURNAL

World Journal of Clinical Cases

ISSN

ISSN 2307-8960 (online)

LAUNCH DATE

April 16, 2013

FREQUENCY

Thrice Monthly

EDITORS-IN-CHIEF

Bao-Gan Peng, Jerzy Tadeusz Chudek, George Kontogeorgos, Maurizio Serati, Ja Hyeon Ku

EDITORIAL BOARD MEMBERS

<https://www.wjnet.com/2307-8960/editorialboard.htm>

PUBLICATION DATE

December 6, 2022

COPYRIGHT

© 2022 Baishideng Publishing Group Inc

INSTRUCTIONS TO AUTHORS

<https://www.wjnet.com/bpg/gerinfo/204>

GUIDELINES FOR ETHICS DOCUMENTS

<https://www.wjnet.com/bpg/GerInfo/287>

GUIDELINES FOR NON-NATIVE SPEAKERS OF ENGLISH

<https://www.wjnet.com/bpg/gerinfo/240>

PUBLICATION ETHICS

<https://www.wjnet.com/bpg/GerInfo/288>

PUBLICATION MISCONDUCT

<https://www.wjnet.com/bpg/gerinfo/208>

ARTICLE PROCESSING CHARGE

<https://www.wjnet.com/bpg/gerinfo/242>

STEPS FOR SUBMITTING MANUSCRIPTS

<https://www.wjnet.com/bpg/GerInfo/239>

ONLINE SUBMISSION

<https://www.f6publishing.com>



Surgical treatment of Pitt-Hopkins syndrome associated with strabismus and early-onset myopia: Two case reports

Ying Huang, Yue Di, Xiao-Xiao Zhang, Xin-Yue Li, Wang-Yi Fang, Tong Qiao

Specialty type: Medicine, research and experimental

Provenance and peer review:

Unsolicited article; Externally peer reviewed.

Peer-review model: Single blind

Peer-review report's scientific quality classification

Grade A (Excellent): 0
Grade B (Very good): B
Grade C (Good): C
Grade D (Fair): 0
Grade E (Poor): 0

P-Reviewer: Atanasova EG, Bulgaria; Tangsuwanaruk T, Thailand

Received: September 5, 2022

Peer-review started: September 5, 2022

First decision: September 26, 2022

Revised: October 10, 2022

Accepted: October 31, 2022

Article in press: October 31, 2022

Published online: December 6, 2022



Ying Huang, Yue Di, Xiao-Xiao Zhang, Xin-Yue Li, Wang-Yi Fang, Tong Qiao, Department of Ophthalmology, Shanghai Children's Hospital, School of Medicine, Shanghai Jiaotong University, Shanghai 200062, China

Corresponding author: Tong Qiao, Doctor, Chief Physician, Department of Ophthalmology, Shanghai Children's Hospital, School of Medicine, Shanghai Jiaotong University, No. 355 Luding Road, Putuo District, Shanghai 200062, China. qiaojoel@126.com

Abstract

BACKGROUND

Pitt-Hopkins syndrome (PTHS; MIM #610954) is a rare genetic neurological disorder. Myopia and strabismus have been reported in approximately 50% of PTHS patients. No studies have reported details about the required surgery for PTHS with strabismus and early-onset myopia. Here, we retrospectively reviewed the surgical management of two patients with PTHS combined with strabismus and/or early-onset myopia.

CASE SUMMARY

A 5-year-old girl presented with congenital esotropia and left eye myopia, and the second girl was a 5-year-old girl who presented with intermittent exotropia. Genetic testing performed on both patients showed a mutation in *transcription factor 4*, which is a diagnostic marker of PTHS. The first girl underwent bilateral medial rectus recession combined with posterior scleral reinforcement (PSR) in the left eye and the second patient underwent bilateral lateral rectus recession strabismus surgery. We made key innovations in surgical timing and strategy, and the results were satisfactory. The combination of strabismus and PSR surgery is an innovative strategy for patients with both strabismus and early-onset myopia.

CONCLUSION

Early treatment of strabismus and myopia positively influence motor development and should be included in rehabilitation programs for patients with PTHS.

Key Words: Pitt-Hopkins syndrome; *Transcription factor 4*; Strabismus; Myopia; Surgery; Case report

©The Author(s) 2022. Published by Baishideng Publishing Group Inc. All rights reserved.

Core Tip: Ophthalmic conditions and surgical outcomes were observed in two children with Pitt-Hopkins syndrome (PTHS). We made key innovations in surgical timing and strategy, and the results were satisfactory. The combination of strabismus and posterior scleral reinforcement surgery is an innovative strategy for patients with both strabismus and early-onset myopia. Furthermore, early diagnosis and treatment of strabismus and myopia positively influence motor development and have, therefore, been included in rehabilitation programs for patients with PTHS. Overall, this study laid the groundwork for future surgical treatment of PTHS associated with strabismus and early-onset myopia.

Citation: Huang Y, Di Y, Zhang XX, Li XY, Fang WY, Qiao T. Surgical treatment of Pitt-Hopkins syndrome associated with strabismus and early-onset myopia: Two case reports. *World J Clin Cases* 2022; 10(34): 12734-12741

URL: <https://www.wjgnet.com/2307-8960/full/v10/i34/12734.htm>

DOI: <https://dx.doi.org/10.12998/wjcc.v10.i34.12734>

INTRODUCTION

Pitt-Hopkins syndrome (PTHS; MIM #610954) is a rare, genetic, neurological disorder first described by Australian physicians Pitt and Hopkins[1] in 1978 and Zollino *et al*[2] in 2019. Prevalence is estimated to be 1:225000–1:300000[2]. The phenotypic presentations most frequently observed in PTHS are developmental delay, intellectual disability, distinctive facial features, breathing pattern abnormalities, and high rates of autism spectrum disorder[3].

PTHS is caused by a mutation in the *transcription factor 4* (TCF4) gene (MIM #602272), a causative gene discovered in 2008[4]. The human TCF4 gene encodes a type I basic helix-loop-helix which binds to E-box DNA sequences. It is located in the 18q21.2 region, containing 41 exons and spanning 437 kb[5]. TCF4 mutations play an essential role in the nervous system and have been linked to autism, schizophrenia, and PTHS in humans[6]. PTHS mutations are spontaneous and do not run in families[7,8].

Myopia and strabismus have been reported in approximately 50% of patients[9]. Myopia is typically severe and usually occurs before 2 years of age[10]. Early-onset myopia is a relevant factor related to later development of high myopia. Hence, once diagnosis of PTHS has been confirmed, children should be referred to an ophthalmologist[2]. Posterior scleral reinforcement (PSR) is recognized as an effective strategy to slow axial length (AL) elongation and prevent high myopic complications[11]. Strabismus surgery is generally performed when conservative treatments are unsuccessful in aligning the eyes[12]. Surgical treatment of strabismus and/or early-onset myopia in patients with PTHS has not been previously described. This report documents our experience in managing two PTHS cases of PTHS with ocular abnormalities.

CASE PRESENTATION

Chief complaints

Case 1: Esodeviation for 5 years and left eye myopia for 2 years.

Case 2: Exodeviation for 1 year.

History of present illness

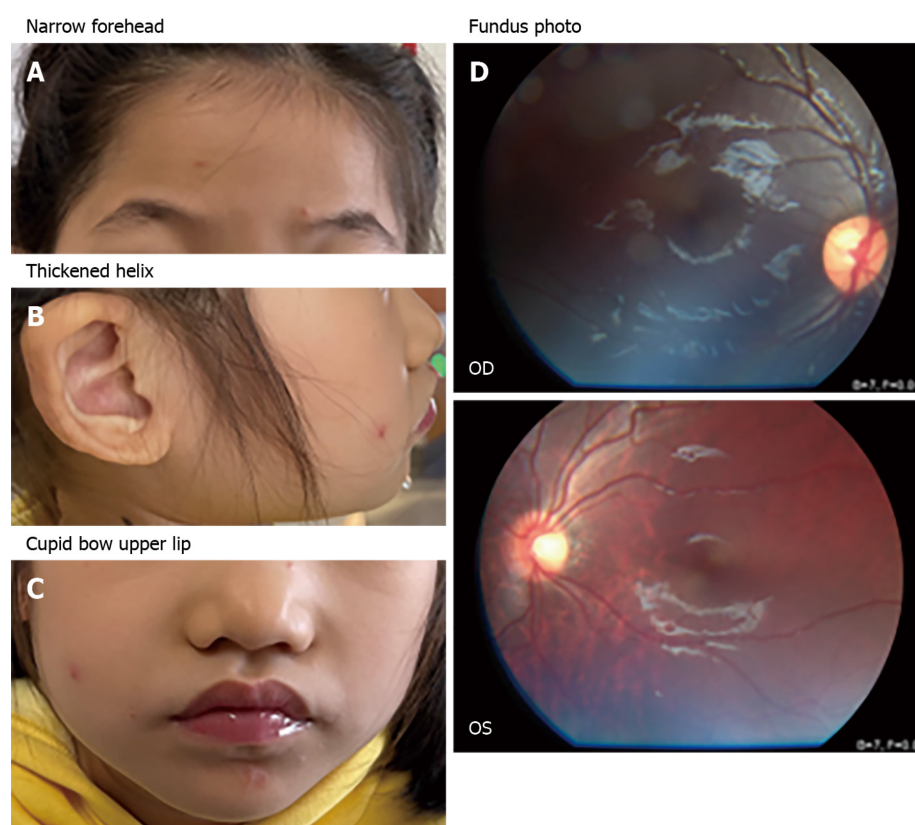
Case 1: The patient presented with distinctive facial features (Figure 1A-C), drooling, stereotypic movements such as hand clapping and hand shaking, and episodic hyperventilation.

Case 2: The patient presented with distinctive facial features, breath-holding while awake, and severe constipation. The patient had intellectual disabilities which were confirmed by a child neurologist.

History of past illness

Case 1: She was born at full term with a birth weight of 3150 g and a length of 49 cm. Apgar score was 10 at one and five minutes. No fetal complications were observed during pregnancy. She was unable to sit until she was 1-year-old. Walking ability was assessed at 4 years of age. Speech development was absent.

Case 2: The child was born at the 38th week (eutopic labor), with a birth weight of 3300 g and a length of 50 cm. Apgar score was 10 at one and five minutes. No fetal complications were observed during pregnancy.



DOI: 10.12998/wjcc.v10.i34.12734 Copyright ©The Author(s) 2022.

Figure 1 Image of patient 1. A-C: Facial abnormalities included narrow forehead, thickened helix, wide mouth and cupid bow upper lip; D: Fundus photos in both eyes of the patient, the left eye (oculus sinister) revealed a slight fundus tessellation. OD: Oculus dexter; OS: Oculus sinister.

Personal and family history

There was no remarkable personal or family history.

Physical examination

Case 1: The patient did not cooperate in visual acuity or stereoacuity examinations. Cycloplegic refraction was +1.75 sph/-1.00 cyl/5° in the right eye and -3.75 sph/-2.25 cyl/5° in the left eye. AL measured with Intraocular Len Master was 23.13 and 25.70 mm in the right and left eyes, respectively. The primary alignment was +40 prism diopter (PD) esotropia with correction. The anterior segments were normal with clear lenses.

Case 2: Visual acuity was 20/40 in both eyes, and near-and distance-stereoacuity was lost. The cycloplegic refraction was +0.25 sph/-1.75 cyl/170° in the right eye and +0.25 sph/-1.75 cyl/15° in the left eye. The AL was 23.42 and 23.39 mm in the right and left eye, respectively. The primary position alignment was -50 PD of exotropia. The intraocular pressure was 17 mmHg in both eyes. The anterior segments were normal with clear lenses.

Laboratory examinations

Case 1: Genetic testing revealed a heterozygous variant (c.1146+3A>G/p.?) in the *TCF4* gene. The patient did not cooperate in visual acuity or stereoacuity examinations.

Case 2: Sequencing results indicated that c.1153C>T of *TCF4* had a nonsense mutation, leading to early termination of protein translation (p. Arg385*), which was confirmed by Sanger sequencing (Figure 2).

Imaging examinations

Case 1: Fundoscopy revealed slight tessellation in the left eye (Figure 1D).

Case 2: There were no abnormalities on fundus examination.

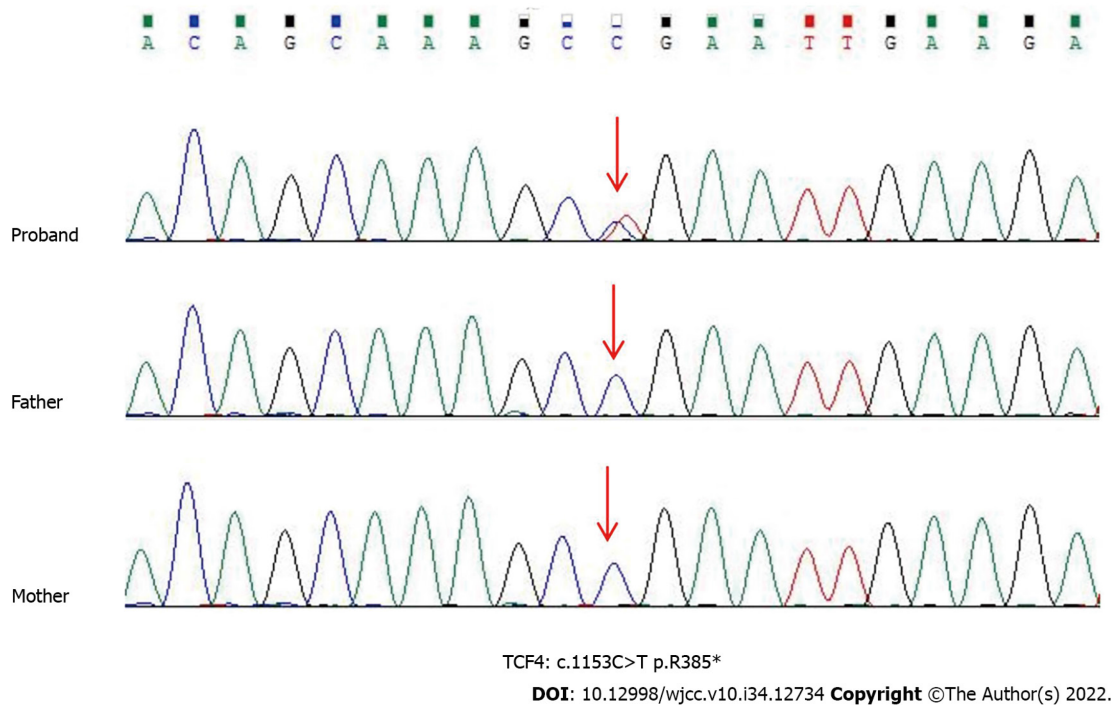


Figure 2 Sanger sequencing showed a heterozygous nonsense mutation (c.1153C>T:p.R385* in exon 15) in the patient 2. Her parents were normal. Red arrows point to the mutant bases. *TCF4*: *Transcription factor 4*.

FINAL DIAGNOSIS

Case 1: PTHS with congenital esotropia and left eye myopia.

Case 2: PTHS with intermittent exotropia.

TREATMENT

Case 1: To repair the strabismus and slow AL elongation to prevent high myopic complications, the patient underwent 5 mm of bilateral medial rectus recession (BMR) combined with PSR in the left eye.

Case 2: The patient underwent 8 mm of bilateral lateral rectus recession (BLR) strabismus surgery to recover visual function and improve her appearance.

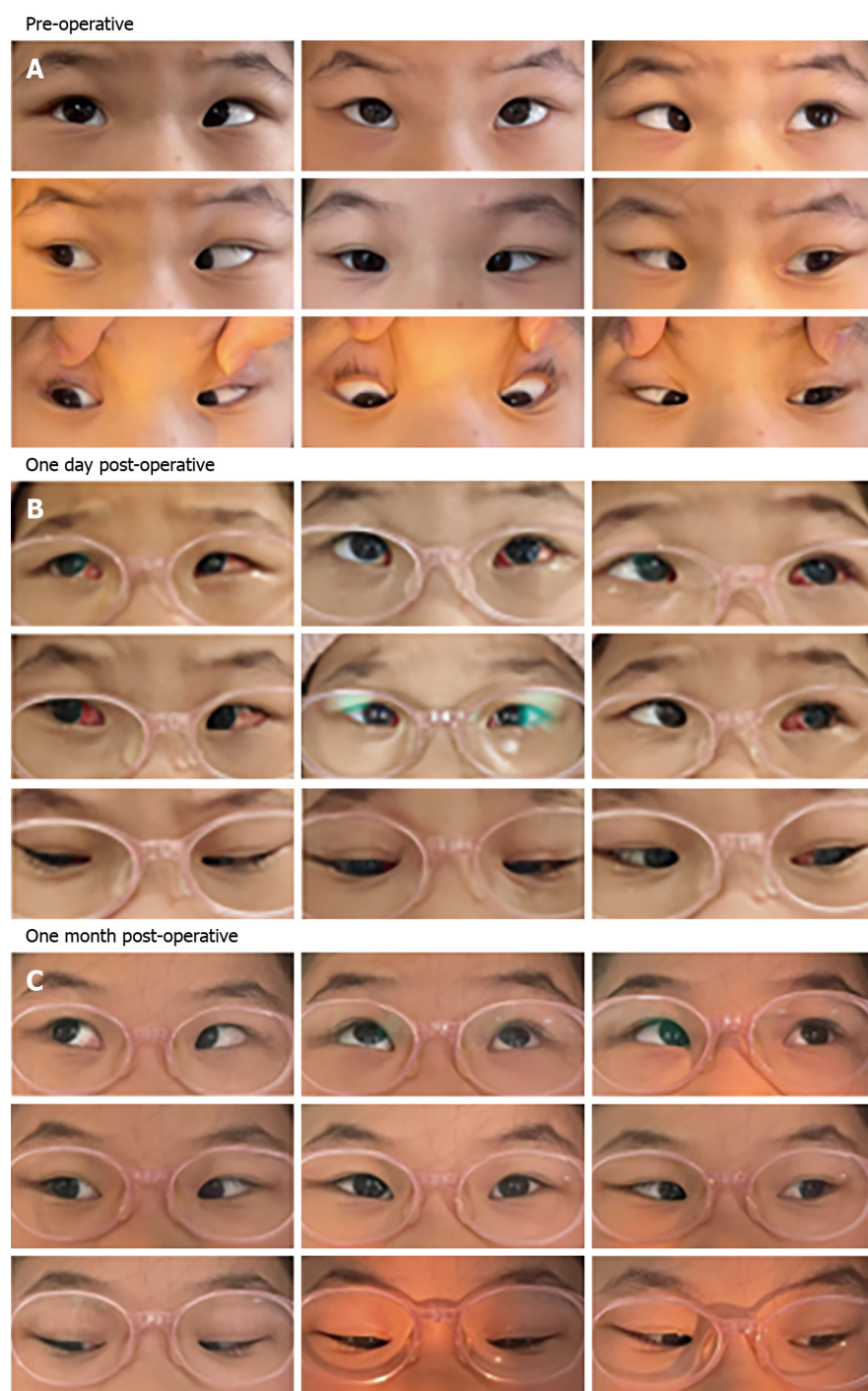OUTCOME AND FOLLOW-UP

Case 1: Esotropia was significantly relieved on the day after surgery. Conjunctival congestion and edema were observed at an early postoperative stage, although both conditions were completely alleviated after 1 mo (Figure 3). No postoperative infection was observed during slit-lamp examination. No postoperative pathological signs were found in either eye during fundus examination performed at the 1 year postoperative follow-up.

Case 2: The patient's exotropia was significantly relieved on the first postoperative day (Figure 4). At the 3 mo postoperative follow-up, her parents noticed that she presented with an improvement in walking and fine motor tasks; she also reported a significant improvement in stereoacuity.

DISCUSSION

Variants of *TCF4* in PTHS usually occur de novo, and empirical recurrence risk can be as high as 2% [2]. Myopia is a supportive feature of the diagnostic criteria for PTHS. In a previous study [2], myopia occurred in 52% of patients with PTHS, and strabismus was present in 44% of patients. One patient (case 1) had early-onset myopia. Consistent with previous literature, which states that strabismus occurs at a very high frequency, case 1 presented with strabismus (congenital esotropia type, unlike case 2,



DOI: 10.12998/wjcc.v10.i34.12734 Copyright ©The Author(s) 2022.

Figure 3 Pre-operative, one day post-operative and one month post-operative alignment of patient 1. A: Case 1 had +40 prism diopter in the primary position before the surgery; B and C: After bilateral medial rectus recession combined with posterior scleral reinforcement surgery, the patient's esotropia was significantly relieved on the secondary day of surgery. Conjunctival congestion and edema were observed in this patient at an early stage, and both conditions were completely alleviated after 1 mo.

which presented with intermittent exotropia). Early-onset myopia may be related to the haploinsufficiency of *TCF4*, causing increased AL, and resulting in myopia combined with rough and partially unpigmented eyes, as demonstrated in zebrafish and drosophila models[13,14]. Interestingly, although refractive errors and strabismus are ubiquitous in PTHS patients, other structural ocular abnormalities, including enophthalmia, small optic nerves, and macular degeneration are uncommon[2].

In this report, case 1 was diagnosed with congenital esotropia and left-eye myopia. Transient visual disturbances during the critical developmental period may be sufficient to impair normal binocular function. Restoring proper ocular alignment as soon as possible can help to improve fine motor development and other visual tasks. Patients with esotropia > 40 PD and a stable or increasing angle on at least two examinations, 2 or more weeks apart following full spectacle correction, are candidates for



Figure 4 Pre-operative and one day post-operative alignment of patient 2. A: Case 2 had -50 prism diopter in the primary position before the surgery; B: After bilateral lateral rectus recession surgery, the patient's exotropia was significantly relieved on the secondary day of surgery.

early surgery[12]. Additionally, case 1 was diagnosed with myopia in the left eye, given that early-onset severe myopia is a frequent clinical manifestation of PTHS, the AL of the patient's left eye was 25.70 mm and much longer than the right, and the left funduscopy revealed slight visibility of the large choroidal vessels. PSR was considered to slow AL elongation and prevent highly myopic complications.

Both strabismus and PSR surgeries require conjunctival incision and extraocular muscle exposure, and they require a similar surgical approach. The surgeon covered the scleral buckle to the posterior pole, which corresponds to the peripheral macula, ensuring the therapeutic effect of the procedure and not affecting the recession or transposition of the extraocular muscle. In case 1, BMR combined with PSR was preferred because it avoided the need for a second surgery for postoperative adhesions, thereby reducing the patient's expenses. It should be noted that acquired esotropia fixus is associated with high myopia[15]; therefore, the amount of recession would be 5–10 PD less than standard surgical numbers. For this child, we performed a 5 mm BMR for a target angle of +40 PD. Intraoperatively, the extraocular muscles were sufficiently exposed and the implanted material covered the posterior pole, which corresponded to the peripheral macula. This patient showed orthotropia in the primary position after combined surgery; therefore, presurgical planning was proven to be correct.

Case 2 was a patient with congenital exotropia, a rare condition that occurs in the first few weeks of life and frequently in stunted children. Typically, stereoscopic vision is preserved when exotropia is well-controlled, and the timing of surgical procedures is based on stereopsis and frequency of exotropia. Nonetheless, for patients with PTHS, we believe that stereopsis and exotropia frequency may not be the most reliable indicators of surgery. Owing to the common comorbidity of severe intellectual disability and speech impairment in children with PTHS, examinations can prove challenging. In these cases, we suggest early surgical interventions after confirming the type of strabismus and the angle of deviation to promote motor coordination ability and balance function recovery.

The two main options for surgical correction include BLR, unilateral lateral rectus recession, and medial rectus resection [16]. However, there is no perfect preoperative plan. Although both PTHS and

Angelman syndrome are muscle tone abnormality disorders, no reports are available on exotropia surgery for PTHS. We selected lateral rectus weakening surgery as the major strategy, and BLR with surgical doses similar to standard exotropia surgery, as in our previous study on Angelman syndrome [17]. Eventually, the patient underwent an 8 mm BLR surgery and achieved stable ocular alignment. A limitation of our study was the small sample size owing to the low incidence rate of PTHS. Another important limitation was the need for further long-term follow-ups of outcomes.

CONCLUSION

Ophthalmic conditions and surgical outcomes were observed in two children with PTHS. To the best of our knowledge, this is the first report of strabismus and PSR surgery in patients with PTHS. We made key innovations in surgical timing and strategy, and the results were satisfactory. The combination of strabismus and PSR surgery is an innovative strategy for patients with both strabismus and early-onset myopia. Furthermore, early diagnosis and treatment of strabismus and myopia positively influence motor development and have, therefore, been included in rehabilitation programs for patients with PTHS. Overall, this study laid the groundwork for future surgical treatment of PTHS associated with strabismus and early-onset myopia.

FOOTNOTES

Author contributions: Huang Y and Di Y contributed equally to this work; Qiao T, Di Y and Huang Y conceived and designed the study; Huang Y, Zhang XX and Li XY collected clinical data; Huang Y and Fang WY analysed the data; Huang Y wrote the manuscript; Qiao T and Di Y gave the critical revision of the manuscript; all authors have read and approve the final manuscript.

Informed consent statement: Informed written consent was obtained from the patient for publication of this report and any accompanying images.

Conflict-of-interest statement: All the authors report no relevant conflicts of interest for this article.

CARE Checklist (2016) statement: The authors have read the CARE Checklist (2016), and the manuscript was prepared and revised according to the CARE Checklist (2016).

Open-Access: This article is an open-access article that was selected by an in-house editor and fully peer-reviewed by external reviewers. It is distributed in accordance with the Creative Commons Attribution NonCommercial (CC BY-NC 4.0) license, which permits others to distribute, remix, adapt, build upon this work non-commercially, and license their derivative works on different terms, provided the original work is properly cited and the use is non-commercial. See: <https://creativecommons.org/licenses/by-nc/4.0/>

Country/Territory of origin: China

ORCID number: Ying Huang 0000-0002-4701-7702; Yue Di 0000-0001-6905-7476; Tong Qiao 0000-0002-3244-4541.

S-Editor: Wei ZH

L-Editor: A

P-Editor: Wei ZH

REFERENCES

- 1 **Pitt D**, Hopkins I. A syndrome of mental retardation, wide mouth and intermittent overbreathing. *Aust Paediatr J* 1978; **14**: 182-184 [PMID: 728011 DOI: 10.1111/jpc.1978.14.3.182]
- 2 **Zollino M**, Zweier C, Van Balkom ID, Sweetser DA, Alaimo J, Bijlsma EK, Cody J, Elsea SH, Giurgea I, Macchiaiolo M, Smigiel R, Thibert RL, Benoist I, Clayton-Smith J, De Winter CF, Deckers S, Gandhi A, Huisman S, Kempink D, Kruisinga F, Lamacchia V, Marangi G, Menke L, Mulder P, Nordgren A, Renieri A, Routledge S, Saunders CJ, Stembalska A, Van Balkom H, Whalen S, Hennekam RC. Diagnosis and management in Pitt-Hopkins syndrome: First international consensus statement. *Clin Genet* 2019; **95**: 462-478 [PMID: 30677142 DOI: 10.1111/cge.13506]
- 3 **Watkins A**, Bissell S, Moss J, Oliver C, Clayton-Smith J, Haye L, Heald M, Welham A. Behavioural and psychological characteristics in Pitt-Hopkins syndrome: a comparison with Angelman and Cornelia de Lange syndromes. *J Neurodev Disord* 2019; **11**: 24 [PMID: 31586495 DOI: 10.1186/s11689-019-9282-0]
- 4 **Zweier C**, Sticht H, Bijlsma EK, Clayton-Smith J, Boonen SE, Fryer A, Grealis MT, Hoffmann L, den Hollander NS, Jongmans M, Kant SG, King MD, Lynch SA, McKee S, Midro AT, Park SM, Ricotti V, Tarantino E, Wessels M, Peippo M, Rauch A. Further delineation of Pitt-Hopkins syndrome: phenotypic and genotypic description of 16 novel patients. *J*

- Med Genet* 2008; **45**: 738-744 [PMID: [18728071](#) DOI: [10.1136/jmg.2008.060129](#)]
- 5 **Sepp M**, Kannike K, Eesmaa A, Urb M, Timmusk T. Functional diversity of human basic helix-loop-helix transcription factor TCF4 isoforms generated by alternative 5' exon usage and splicing. *PLoS One* 2011; **6**: e22138 [PMID: [21789225](#) DOI: [10.1371/journal.pone.0022138](#)]
 - 6 **De Rubeis S**, He X, Goldberg AP, Poultnery CS, Samocha K, Cicek AE, Kou Y, Liu L, Fromer M, Walker S, Singh T, Klei L, Kosmicki J, Shih-Chen F, Aleksic B, Biscaldi M, Bolton PF, Brownfeld JM, Cai J, Campbell NG, Carracedo A, Chahrour MH, Chiocchetti AG, Coon H, Crawford EL, Curran SR, Dawson G, Duketis E, Fernandez BA, Gallagher L, Geller E, Guter SJ, Hill RS, Ionita-Laza J, Jimenez Gonzalez P, Kilpinen H, Klauck SM, Klevzon A, Lee I, Lei I, Lei J, Lehtimäki T, Lin CF, Ma'ayan A, Marshall CR, McInnes AL, Neale B, Owen MJ, Ozaki N, Parellada M, Parr JR, Purcell S, Puura K, Rajagopalan D, Rehnström K, Reichenberg A, Sabo A, Sachse M, Sanders SJ, Schafer C, Schulte-Rüther M, Skuse D, Stevens C, Szatmari P, Tammimies K, Valladares O, Voran A, Li-San W, Weiss LA, Willsey AJ, Yu TW, Yuen RK; DDD Study; Homozygosity Mapping Collaborative for Autism; UK10K Consortium, Cook EH, Freitag CM, Gill M, Hultman CM, Lehner T, Palotie A, Schellenberg GD, Sklar P, State MW, Sutcliffe JS, Walsh CA, Scherer SW, Zwick ME, Barrett JC, Cutler DJ, Roeder K, Devlin B, Daly MJ, Buxbaum JD. Synaptic, transcriptional and chromatin genes disrupted in autism. *Nature* 2014; **515**: 209-215 [PMID: [25363760](#) DOI: [10.1038/nature13772](#)]
 - 7 **Kousoulidou L**, Tanteles G, Moutafi M, Sismani C, Patsalis PC, Anastasiadou V. 263.4 kb deletion within the TCF4 gene consistent with Pitt-Hopkins syndrome, inherited from a mosaic parent with normal phenotype. *Eur J Med Genet* 2013; **56**: 314-318 [PMID: [23528641](#) DOI: [10.1016/j.ejmg.2013.03.005](#)]
 - 8 **Steinbusch CV**, van Roozendaal KE, Tserpelis D, Smeets EE, Kranenburg-de Koning TJ, de Waal KH, Zweier C, Rauch A, Hennekam RC, Blok MJ, Schrander-Stumpel CT. Somatic mosaicism in a mother of two children with Pitt-Hopkins syndrome. *Clin Genet* 2013; **83**: 73-77 [PMID: [22335494](#) DOI: [10.1111/j.1399-0004.2012.01857.x](#)]
 - 9 **de Winter CF**, Baas M, Bijlsma EK, van Heukelingen J, Routledge S, Hennekam RC. Phenotype and natural history in 101 individuals with Pitt-Hopkins syndrome through an internet questionnaire system. *Orphanet J Rare Dis* 2016; **11**: 37 [PMID: [27072915](#) DOI: [10.1186/s13023-016-0422-2](#)]
 - 10 **Giurgea I**, Missirlian C, Cacciagli P, Whalen S, Fredriksen T, Gaillon T, Rankin J, Mathieu-Dramard M, Morin G, Martin-Coignard D, Dubourg C, Chabrol B, Arfi J, Giuliano F, Claude Lambert J, Philip N, Sarda P, Villard L, Goossens M, Moncla A. TCF4 deletions in Pitt-Hopkins Syndrome. *Hum Mutat* 2008; **29**: E242-E251 [PMID: [18781613](#) DOI: [10.1002/humu.20859](#)]
 - 11 **Miao Z**, Li L, Meng X, Guo L, Cao D, Jia Y, He D, Huang L, Wang L. Modified Posterior Scleral Reinforcement as a Treatment for High Myopia in Children and Its Therapeutic Effect. *Biomed Res Int* 2019; **2019**: 5185780 [PMID: [30805365](#) DOI: [10.1155/2019/5185780](#)]
 - 12 **Kanukollu VM**, Sood G. Strabismus. 2022 Feb 17. In: StatPearls [Internet]. Treasure Island (FL): StatPearls Publishing; 2022 Jan- [PMID: [32809617](#)]
 - 13 **Brockschmidt A**, Filippi A, Charbel Issa P, Nelles M, Urbach H, Eter N, Driever W, Weber RG. Neurologic and ocular phenotype in Pitt-Hopkins syndrome and a zebrafish model. *Hum Genet* 2011; **130**: 645-655 [PMID: [21544580](#) DOI: [10.1007/s00439-011-0999-4](#)]
 - 14 **Tamberg L**, Sepp M, Timmusk T, Palgi M. Introducing Pitt-Hopkins syndrome-associated mutations of TCF4 to Drosophila daughterless. *Biol Open* 2015; **4**: 1762-1771 [PMID: [26621827](#) DOI: [10.1242/bio.014696](#)]
 - 15 **Ho TH**, Lin MC, Sheu SJ. Surgical treatment of acquired esotropia in patients with high myopia. *J Chin Med Assoc* 2012; **75**: 416-419 [PMID: [22901728](#) DOI: [10.1016/j.jcma.2012.06.003](#)]
 - 16 **Chougule P**, Kekunnaya R. Surgical management of intermittent exotropia: do we have an answer for all? *BMJ Open Ophthalmol* 2019; **4**: e000243 [PMID: [30997406](#) DOI: [10.1136/bmjophth-2018-000243](#)]
 - 17 **Ye H**, Lan X, Liu Q, Zhang Y, Wang S, Zheng C, Di Y, Qiao T. Ocular findings and strabismus surgery outcomes in Chinese children with Angelman syndrome: Three case reports. *Medicine (Baltimore)* 2019; **98**: e18077 [PMID: [31860958](#) DOI: [10.1097/MD.00000000000018077](#)]



Published by **Baishideng Publishing Group Inc**
7041 Koll Center Parkway, Suite 160, Pleasanton, CA 94566, USA

Telephone: +1-925-3991568

E-mail: bpgoffice@wjgnet.com

Help Desk: <https://www.f6publishing.com/helpdesk>

<https://www.wjgnet.com>

