

World Journal of *Radiology*

World J Radiol 2022 December 28; 14(12): 375-383



ORIGINAL ARTICLE**Retrospective Study**

- 375 Unmasking lower gastrointestinal bleeding under administration of norepinephrine

Werner DJ, Wenzel N, Abusalim N, Kiesslich R, Baar T, Tresch A, Rey JW

ABOUT COVER

Editorial Board Member of *World Journal of Radiology*, Roberto Grassi, MD, Professor, Researcher - University of Campania "Luigi Vanvitelli", Piazza Miraglia, Naples, Italy. roberto.grassi@unicampania.it

AIMS AND SCOPE

The primary aim of *World Journal of Radiology* (*WJR*, *World J Radiol*) is to provide scholars and readers from various fields of radiology with a platform to publish high-quality basic and clinical research articles and communicate their research findings online.

WJR mainly publishes articles reporting research results and findings obtained in the field of radiology and covering a wide range of topics including state of the art information on cardiopulmonary imaging, gastrointestinal imaging, genitourinary imaging, musculoskeletal imaging, neuroradiology/head and neck imaging, nuclear medicine and molecular imaging, pediatric imaging, vascular and interventional radiology, and women's imaging.

INDEXING/ABSTRACTING

The *WJR* is now abstracted and indexed in PubMed, PubMed Central, Emerging Sources Citation Index (Web of Science), Reference Citation Analysis, China National Knowledge Infrastructure, China Science and Technology Journal Database, and Superstar Journals Database. The 2022 edition of Journal Citation Reports® cites the 2021 Journal Citation Indicator (JCI) for *WJR* as 0.48.

RESPONSIBLE EDITORS FOR THIS ISSUE

Production Editor: Si Zhao; Production Department Director: Xu Guo; Editorial Office Director: Jia-Ru Fan.

NAME OF JOURNAL

World Journal of Radiology

ISSN

ISSN 1949-8470 (online)

LAUNCH DATE

January 31, 2009

FREQUENCY

Monthly

EDITORS-IN-CHIEF

Thomas J Vogl

EDITORIAL BOARD MEMBERS

<https://www.wjgnet.com/1949-8470/editorialboard.htm>

PUBLICATION DATE

December 28, 2022

COPYRIGHT

© 2022 Baishideng Publishing Group Inc

INSTRUCTIONS TO AUTHORS

<https://www.wjgnet.com/bpg/gerinfo/204>

GUIDELINES FOR ETHICS DOCUMENTS

<https://www.wjgnet.com/bpg/gerinfo/287>

GUIDELINES FOR NON-NATIVE SPEAKERS OF ENGLISH

<https://www.wjgnet.com/bpg/gerinfo/240>

PUBLICATION ETHICS

<https://www.wjgnet.com/bpg/gerinfo/288>

PUBLICATION MISCONDUCT

<https://www.wjgnet.com/bpg/gerinfo/208>

ARTICLE PROCESSING CHARGE

<https://www.wjgnet.com/bpg/gerinfo/242>

STEPS FOR SUBMITTING MANUSCRIPTS

<https://www.wjgnet.com/bpg/gerinfo/239>

ONLINE SUBMISSION

<https://www.f6publishing.com>



Retrospective Study

Unmasking lower gastrointestinal bleeding under administration of norepinephrine

David John Werner, Nicolai Wenzel, Nael Abusalim, Ralf Kiesslich, Till Baar, Achim Tresch, Johannes Wilhelm Rey

Specialty type: Radiology, nuclear medicine and medical imaging

Provenance and peer review: Unsolicited article; Externally peer reviewed.

Peer-review model: Single blind

Peer-review report's scientific quality classification

Grade A (Excellent): 0
Grade B (Very good): B
Grade C (Good): C, C
Grade D (Fair): 0
Grade E (Poor): 0

P-Reviewer: Farid K, Egypt; Govindarajan KK, India; Liang HL, Taiwan

Received: September 9, 2022

Peer-review started: September 9, 2022

First decision: October 12, 2022

Revised: October 24, 2022

Accepted: December 1, 2022

Article in press: December 1, 2022

Published online: December 28, 2022



David John Werner, Nicolai Wenzel, Nael Abusalim, Department of Radiology, Helios Dr. Horst-Schmidt-Clinic, Wiesbaden 65199, Hessen, Germany

David John Werner, Radiologie Rhein-Nahe, Krankenhaus St. Marienwörth, Bad Kreuznach 55543, Rheinland-Pfalz, Germany

Nael Abusalim, Department of Diagnostic and Interventional Radiology, Medical Center Hanau, Hanau 63450, Hessen, Germany

Ralf Kiesslich, Johannes Wilhelm Rey, Department of Internal Medicine II, Helios Dr. Horst-Schmidt-Clinic, Wiesbaden 65199, Hessen, Germany

Till Baar, Achim Tresch, Institute for Medical Statistics and Computational Biology, Faculty of Medicine, University of Cologne, Cologne 50923, Nordrhein-Westfalen, Germany

Johannes Wilhelm Rey, Department of Gastroenterology and Endoscopy, Medical Center Osnabrueck, Osnabrueck 49076, Niedersachsen, Germany

Corresponding author: Johannes Wilhelm Rey, MD, PhD, Chief Doctor, Department of Gastroenterology and Endoscopy, Medical Center Osnabrueck, Am Finkenhügel 1, Osnabrueck 49076, Niedersachsen, Germany. johannes.wilhelm.rey@t-online.de

Abstract

BACKGROUND

Bleeding in the gastrointestinal tract is common and transarterial embolization enables the clinician to control gastrointestinal bleeding. Contrast extravasation is a prerequisite for successful embolization. Provocative angiography is helpful in the detection of elusive bleeding.

AIM

We performed a retrospective analysis of angiographic treatment in patients with lower gastrointestinal hemorrhage and initially negative angiographies, as well as the role of norepinephrine (NE) in unmasking bleeding.

METHODS

We analyzed 41 patients with lower gastrointestinal bleeding after angiography who had undergone treatment over a period of 10 years. All patients had a

positive shock index and needed intensive care.

RESULTS

In three of four patients, angiography disclosed the site of bleeding when NE was used during the procedure for hemodynamic stabilization.

CONCLUSION

We suggest that angiography performed after the administration of NE in unstable patients with gastrointestinal bleeding and an initially negative angiography has the potential to unmask bleeding sites for successful embolization. However, this statement must be confirmed in prospective studies.

Key Words: Lower gastrointestinal bleeding; Endoscopy; Provocative angiography; Norepinephrine; Radiology; Gastrointestinal bleeding

©The Author(s) 2022. Published by Baishideng Publishing Group Inc. All rights reserved.

Core Tip: Bleeding in the gastrointestinal tract is common in hospital emergency settings. Gastrointestinal endoscopy is currently the undisputed method of choice for achieving hemostasis. Provocative angiography has been reported to help in the detection of elusive bleeding. We performed a retrospective analysis of angiographic management of bleeding in the lower gastrointestinal tract (LGIB). In a small number of patients, hemodynamic stabilization with norepinephrine (NE) disclosed LGIB which had escaped detection until this time. Angiography after administration of NE unmasked bleeding in three of four patients. We saw no complications in two of three patients after embolization. It may be assumed that this method can detect bleeding successfully and help to achieve hemostasis by angiography.

Citation: Werner DJ, Wenzel N, Abusalim N, Kiesslich R, Baar T, Tresch A, Rey JW. Unmasking lower gastrointestinal bleeding under administration of norepinephrine. *World J Radiol* 2022; 14(12): 375-383

URL: <https://www.wjgnet.com/1949-8470/full/v14/i12/375.htm>

DOI: <https://dx.doi.org/10.4329/wjr.v14.i12.375>

INTRODUCTION

Bleeding in the gastrointestinal tract may occur at various sites and is frequently encountered in the preclinical and in-hospital emergency setting. Gastrointestinal endoscopy is currently the undisputed method of choice for achieving hemostasis at the bleeding site in the gastrointestinal tract[1]. Bleeding occurs in the upper gastrointestinal tract four to five times more frequently than it does in the lower gastrointestinal tract (LGIB)[2]. The estimated incidence of LGIB is 25 *per* 100000 adults *per* year[3]. LGIB is strongly dependent on aging; a 200-fold increase was observed between the third and the ninth decade of life[4]. Diverticular bleeding is the most common cause of LGIB. Endoscopy reveals the bleeding site in a mere 20%-30% of cases. Some patients require surgical or angiographic treatment. Although endoscopic hemostasis is effective and the treatment of choice for LGIB, the optimal technique remains to be determined[5,6]. A bleeding site may not be evident in some patients despite endoscopic evaluation. In fact, the bleeding may cease and thus make it difficult to identify the site.

Provocative angiography with vasodilators, anticoagulants or thrombolytics has been reported to help in the detection of elusive bleeding[7-11]. Bloomfeld *et al*[8,12] identified bleeding in 37.5% of their patients using intra-arterial urokinase, tolazoline, and heparin during angiography procedures. In a retrospective analysis of 34 patients, provocative mesenteric angiography using systemic anticoagulation with heparin and selective transcatheter injection of a vasodilator disclosed the bleeding site in 31% of cases. Ten patients received embolization[9]. In a recently published case series of pharmacologic provocation combined with endoscopy, the source of bleeding was discovered in 15 of 27 patients with a regimen of antiplatelet/anticoagulant medication[13]. In 2020, Kokoroskos *et al*[14] described a regimen for stepwise provocation of bleeding with anticoagulants, vasodilators and thrombolytic agents. Twenty-three patients were included in the study; provocation was successful in seven patients, and four of the seven patients were successfully treated by interventional radiological procedures. No complications occurred. The role of vasopressors, such as norepinephrine (NE) in hemorrhagic shock has been reported elsewhere and is well-documented[15-17].

We performed a retrospective analysis of angiographic management of LGIB. In a small number of patients, hemodynamic stabilization with NE disclosed LGIB which had escaped detection until this time. We suspect that, after administering NE, occult bleeding and the concomitant short-term increase

in systolic blood pressure become visible on angiography. We retrospectively identified four patients with LGIB who needed NE in the intensive care setting and whose initial angiography had been negative. To the best of our knowledge, provocative challenges with intravenous NE in unstable patients with LGIB have not been reported so far.

Future prospective studies should address the usefulness of inducing blood pressure peaks in patients on NE treatment during angiography in order to disclose occult gastrointestinal bleeding. It may be assumed that this method, when used in eligible patients, may disclose bleeding successfully and help to achieve hemostasis by angiography. However, this assumption should be confirmed in prospective randomized multicenter studies.

MATERIALS AND METHODS

All patients who had undergone catheter angiography for gastrointestinal bleeding at our maximum-care hospital between 1 January, 2007 and 31 March, 2018 were included in the study[6]. Predictors of complicated angiographic treatment and the role of specific laboratory parameters and scores in predicting the likelihood of a successful intervention were identified. The study protocol conformed to the 1975 Declaration of Helsinki and was approved by the ethics committee of the Regional Medical Society of Hessen (Landesärztekammer Hessen), approval number FF 95/2017, on 31 August 2017. Written informed consent was obtained from each patient. In three of 41 patients, intravenous administration of NE was followed by contrast media extravasation, although the patients had experienced no extravasation during the initial procedure. In one patient, intravenous administration of NE did not disclose the bleeding. The maximal individual dose of NE was 10 µg. A specific time interval was not applied. For the accompanying anesthetists, the application of NE depended on their observations during monitoring and achieving a mean pressure higher than 60 mmHg. The maximum dose *per* patient during an angiography was 40 µg.

From our previous retrospective analysis, we identified a new subgroup of patients with the following common features: LGIB, intensive care, the need for NE, intra-arterial blood pressure measurement, and an intravenous NE bolus of 10-40 µg during angiography (Table 1).

RESULTS

In a retrospective analysis, we studied 41 consecutive patients with LGIB between 2007 and 2018. Twenty-six of 41 patients had diverticular bleeding. The primary endoscopy failed to achieve hemostasis in any patient (Figure 1). Sixteen of 41 patients underwent pre-interventional computed tomography (CT). The mean systolic blood pressure on the day of angiography was 104 mmHg, and the mean shock index was 0.91 (heart rate *per* minute/systolic blood pressure). Twenty-five of 41 patients were monitored by an anesthetist. Of these patients, 16 were intubated. Angiography demonstrated the bleeding in 18 of 41 patients, and 20 patients underwent embolization (2 prophylactic embolizations). The angiography was technically successful in 16/18 cases, and clinically successful in 10/18 cases[6].

Patients who needed catecholamines were documented separately. Three patients presented with severe hematochezia and signs of hemorrhagic shock, and a further patient with chronic sigmoid diverticulitis. Only one patient was female. The mean age was 75.8 years. All patients had a positive shock index, and all had at least one notable comorbid condition. The mean Glasgow-Blatchford bleeding score was 10 or higher in all cases (mean score 12). The mean interval from the time of hospitalization and the endoscopic investigation was 14.1 h. All patients received an emergency colonoscopy. Three of four colonoscopies revealed the stigmata of hemorrhage with no evidence of manageable bleeding. Only one case of diverticular bleeding was classified as active bleeding that could not be managed by endoscopy, and was directly treated by radiological procedures. Two of four patients underwent pre-interventional CT. In patient 1 we performed a triphasic CT scan and found no contrast medium extravasation on the CT, but did observe signs of previous hemorrhage in the colon. Patient 4 also underwent a triphasic CT scan and revealed contrast medium extravasation in the lower gastrointestinal tract as evidence of active bleeding.

The mean period of time until angiography was 3.5 d. The primary angiography failed to reveal active contrast media extravasation in any patient. In three of four cases (75%), the bleeding was seen after the application of noradrenaline for cardiovascular stabilization (Figures 2 and 3). In all cases, microcoils (Tornado® Embolization Coil, Cook Medical) were used for embolization. Superselective embolization failed in one patient; multiple feeding vessels were embolized using a front-door and back-door technique, which resulted in confirmed hemostasis. It should be noted that extended dearterialization caused mesenteric ischemia and necessitated a right-sided hemicolectomy the following day. The mean duration of the hospital stay for patients in the NE population was 18 d.

Table 1 Clinical, endoscopic and angiographic characteristics of patients

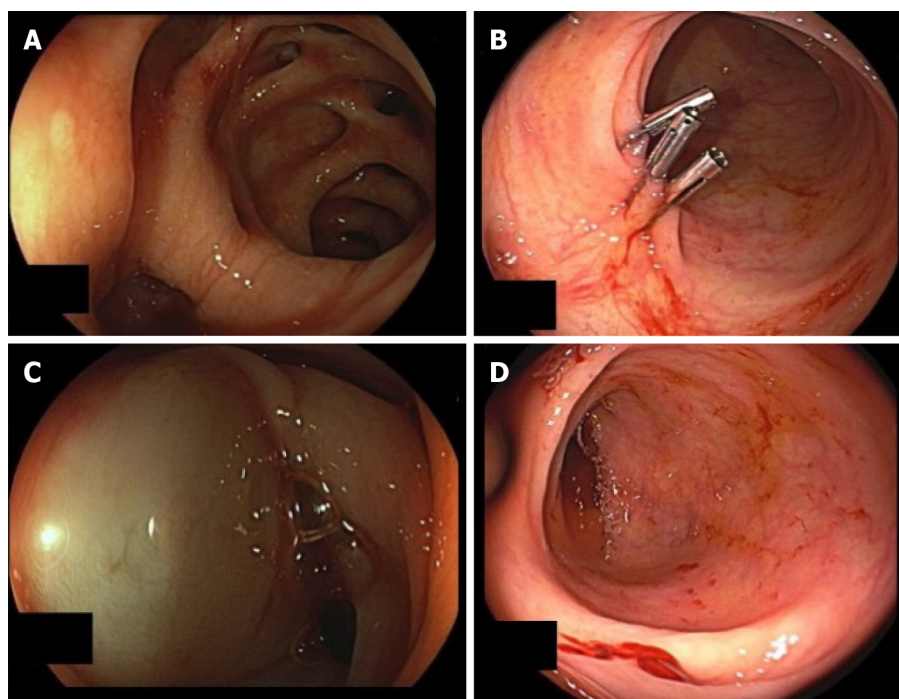
	Case 1	Case 2	Case 3	Case 4
Age (yr)	66	79	94	64
Sex	Male	Male	Female	Male
Reasons for admission	GI bleeding	Amputation	GI bleeding	Inflammatory disease
Shock index > 1	Yes	Yes	Yes	Yes
Heart rate (bpm)	112	106	84	120
Blood pressure (mmHg)	75/50	90/50	80/40	90/60
Comorbidities	PE, AA, Hypertension	DM, Hypertension, PAOD IV	CHD, DM, Hypertension	Hypertension
Glasgow-Blatchford score	12	13	10	13
Packed red cells	17	1	0	2
Time to endoscopy (h)	6.5	6	36	8
Source of bleeding	Diverticular	No bleeding	Diverticular	Diverticular
Location	Cecum	Not located	Sigmoid colon	Cecum
Number of endoscopic interventions	2	0	2	1
Types of intervention	1. Clipping 2. Injection	None	1. Injection 2. Clipping	1. Clipping
Number of endoscopies (Before/After angiography)	7 (6/1)	4 (2/2)	4 (2/2)	3 (3/0)
Time to angiography (d)	6	4	2	2
CTA	Yes	No	No	Yes
Artery with extravasation	A colica dextra	None	AMI	Ileocolic artery
Side of embolization	End arteries	None	Sigmoid artery	Marginal arteries
Material for embolization	Microcoils	-	Microcoils	Microcoils
Type of embolization (mm)	Ø 3/2	-	Ø 10/5	Ø 3/2
Baseline blood pressure (mmHg)	70/40	90/50	80/50	90/60
Dose of norepinephrine	20 µg	20 µg	40 µg	30 µg
Blood pressure (mmHg) at the time the bleeding was identified	155/8	-	170/90	160/90
Bleeding on provocation	Yes	No	Yes	Yes
Early complications	No	No	No	Ischemia
Endoscopy after coiling	Yes	No	No	No
Late complications	No	No	No	No
Duration of hospital stay (d)	18	16	8	30

AA: Aortic aneurysm; AF: Atrial fibrillation; AMI: Inferior mesenteric artery; CHD: Coronary heart disease; CTA: Computed tomography angiography; DM: Diabetes mellitus; Microcoils: Tornado® Embolization Coil, Cook Medical; MM: Malignant melanoma; PAOD: Peripheral arterial occlusive disease; PE: Pulmonary embolism.

DISCUSSION

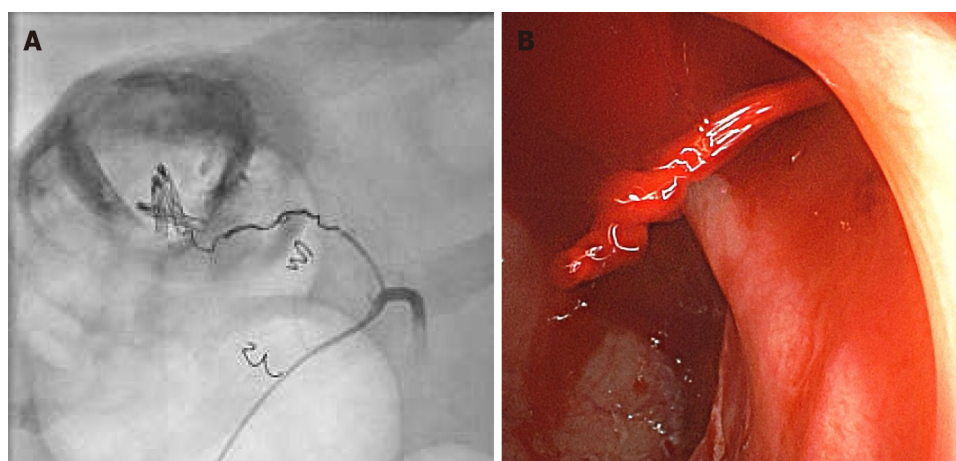
The fact that NE is able to unmask LGIB in unstable patients has not been reported so far in the published literature. The pharmacological basis is alpha1-induced global vasoconstriction with an increase in peripheral vascular resistance and a resulting increase in systolic and mean arterial blood pressure, provoking a morphologically visible contrast media extravasation.

Our case series must be viewed in the context of other scientific investigations on bleeding site provocation in patients with GIB, using established endoscopic or angiographic procedures[6]. Permissive hypotension under sedation is a common phenomenon in patients with GIB and hemorrhagic shock. These conditions are usually treated effectively by intravenous volume substitution



DOI: 10.4329/wjr.v14.i12.375 Copyright ©The Author(s) 2022.

Figure 1 Urgent colonoscopy in case 3. A: Revealed diverticular bleeding in the sigmoid colon; B: The endoscopic procedure was performed with three hemoclips; no further signs of bleeding; C: Injection therapy was used; D: Diverticular bleeding of the right colon was detected in case 4.



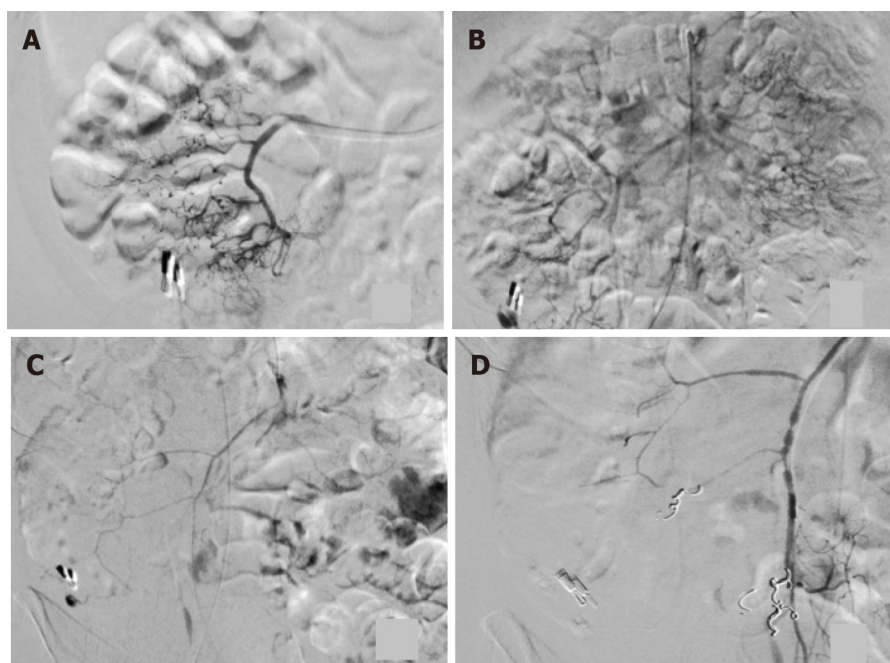
DOI: 10.4329/wjr.v14.i12.375 Copyright ©The Author(s) 2022.

Figure 2 Final colonoscopy in case 1, which revealed a spurt of bleeding at the right colon during norepinephrine treatment of hemorrhagic shock. A: The bleeding site was clip-marked before the patient was transferred for angiographic treatment; B: Superselective view of the right colic artery after norepinephrine application and coiling (the cumulative dose of norepinephrine was 20 µg).

and intravenous NE. In our analysis, this treatment disclosed the source of bleeding in patient 1.

The bleeding site is rarely detected by endoscopy, especially in patients with LGIB[18]. Previously, bleeding provocation procedures were usually performed in conjunction with an intervention in the coagulation system[8,9,11,13]. Although safe and uncomplicated provocation has been reported in all publications, we believe that the use of an anticoagulant as provocation in patients with GIB is a critical measure and is associated with a potential risk of bleeding complications.

All patients were in a state of hemorrhagic shock and had to be treated in an intensive care unit. Blood pressure was measured invasively. The shock index was elevated in 3/4 patients. A previously undetectable extravasation appeared in three of four cases after the administration of a cumulative dose of NE. Two of three patients had no complications after embolization. Nevertheless, the use of NE requires thorough knowledge of its pharmacological properties, especially in unstable patients. NE has a number of potential side effects, such as dizziness, headache, angina, ischemia, necrosis, and vasospasm[17]. Vasospasms occurred in one of our cases (Figure 3).



DOI: 10.4329/wjr.v14.i12.375 Copyright ©The Author(s) 2022.

Figure 3 Angiographic procedure in case 4. A: The ileocolic artery after application of 10 µg of norepinephrine is shown; no sign of extravasation; B: Selective view of the superior mesenteric artery, showing bleeding next to the hemoclip after repeated administration of a cumulative dose of 20 µg of norepinephrine; C: Arterial vasospasm was observed during an ongoing extravasation in the cecum; D: Following extensive embolization, no further bleeding was seen after a cumulative dose of 30 µg of norepinephrine.

In view of the high re-bleeding rates reported under NE, its use as a means of provocation calls for further investigation[19]. Other measures, such as the administration of at least three erythrocyte concentrates, may also improve the detection of bleeding[20]. However, transfusions with concentrates are known to cause side effects, and contrast extravasation after transfusion takes longer than it does after the administration of NE. Liang *et al*[21] used an intra-arterial epinephrine bolus with a small dose of vasopressin to induce vasospasm in the intra-arterial treatment of acute LGIB. The technical success rate in 21 procedures (16 patients) was 100%.

Bowel ischemia is a complication of embolization. In retrospective analyses, 10% of patients who underwent treatment for LGIB required surgical intervention 24 h after the procedure. Long-term survival rates were 70.6% (1 year), 56.6% (3 years) and 50.8% (5 years)[22]. This complication has also been reported in other studies[23-25]. We believe that the case of intestinal ischemia and subsequent hemicolectomy in the present study was not caused by provocation but by unsuccessful superselective embolization. However, this notion cannot be proved conclusively. Bowel ischemia may also have been induced by the administration of NE, which was a clinical necessity.

In view of this ischemic complication, patients with LGIB who have received interventional radiological treatment with provocation must be monitored closely in terms of laboratory parameters as well as follow-up endoscopies, although some authors do not advocate routine colonoscopy after angiography[23]. The need for a standard follow-up colonoscopy and its ideal timing must be investigated further.

We are aware of the crucial importance of patients being monitored by qualified intensive care specialists, including the administration of fluids, as well as the need to monitor other organ functions such as the kidneys, bowel and extremities by specialists and experienced physicians. In the future it may be meaningful to perform an angiography at the time when NE is administered, in order to identify an accidentally provoked contrast media extravasation. In the present investigation, NE was administered for the purpose of cardiovascular stabilization and the extravasation of contrast medium was a positive additional effect.

Limitations: This was a retrospective investigation and was accompanied by the known difficulties incumbent upon a study of this nature. If further investigations show that the suggested approach might be successful, the outcomes will have to be validated prospectively under controlled conditions. Furthermore, the data were not obtained for the purpose of the study and data collection may have been subject to structural inaccuracies. NE is a highly potent substance and should only be used by experienced clinicians. In one of our cases, the complication of bowel ischemia may have been an effect of NE. Further prospective studies are needed to address this problem. The limitations of the previously published study[6] also apply. Many crucial points such as the fluctuating nature of GIB, the time point of endoscopy, the number of endoscopies to be performed, the role of CT diagnosis, and the optimal

time point of angiography have not yet been clearly specified, and must be clarified in future investigations[6].

CONCLUSION

In summary, bleeding was discovered by the administration of NE in three of four patients with LGIB. NE was needed in all cases as a means of cardiovascular support.

Future prospective studies should address the usefulness of inducing blood pressure peaks in patients on NE treatment during angiography in order to disclose occult gastrointestinal bleeding. It may be assumed that this method, when used in eligible patients, may disclose bleeding successfully and help to achieve hemostasis by angiography. However, this assumption should be confirmed in prospective randomized multicenter studies.

ARTICLE HIGHLIGHTS

Research background

Gastrointestinal endoscopy is the undisputed method of choice for achieving hemostasis in the gastrointestinal tract. Provocative angiography has been reported to help in the detection of elusive bleeding.

Research motivation

We discovered contrast extravasation following the application of norepinephrine (NE) in angiographic procedures. Our purpose was to investigate the detection of masked bleeding during NE therapy.

Research objectives

The aim was to describe the procedure for the detection of elusive bleeding under the administration of NE and intensive care therapy.

Research methods

We performed a retrospective analysis of 41 patients with lower gastrointestinal tract bleeding treated by radiological procedures. Four patients received NE during angiography.

Research results

A previously undetected bleed was found in three patients. The bleeding was embolized without complications in two of four patients. In one patient we observed no bleeding after the administration of NE. One patient experienced bowel ischemia and had to be treated surgically.

Research conclusions

Bleeding was discovered in three of four cases. No complications were observed in two of three cases of embolization. Our results suggest that the use of NE may have the potential to improve the angiographic therapy of lower gastrointestinal bleeding in critically ill patients.

Research perspectives

Future studies should be focused on a prospective validation of the procedures described here but with a larger number of patients.

FOOTNOTES

Author contributions: Rey JW and Werner DJ designed the topic and wrote the paper; Wenzel N collected the data and edited the text; Baar T and Tresch A performed data analysis; Kiesslich R performed endoscopy and Abusalim N performed interventional angiography.

Institutional review board statement: The study was reviewed and approved by the Ethik-Kommission bei der Landesärztekammer Hessen Institutional Review Board (Approval No. FF95/2017).

Informed consent statement: Patients were not required to give informed consent to the study as the analysis used anonymous clinical data that were obtained after each patient agreed to treatment by written consent.

Conflict-of-interest statement: All authors declare that they have no conflicts of interest.

Data sharing statement: If there is a need, you can contact the corresponding author to share data at any time.

Open-Access: This article is an open-access article that was selected by an in-house editor and fully peer-reviewed by external reviewers. It is distributed in accordance with the Creative Commons Attribution NonCommercial (CC BY-NC 4.0) license, which permits others to distribute, remix, adapt, build upon this work non-commercially, and license their derivative works on different terms, provided the original work is properly cited and the use is non-commercial. See: <https://creativecommons.org/licenses/by-nc/4.0/>

Country/Territory of origin: Germany

ORCID number: David John Werner 0000-0003-1828-2969; Nicolai Wenzel 0000-0002-8820-2461; Nael Abusalim 0000-0003-3594-6050; Ralf Kiesslich 0000-0003-0199-6412; Till Baar 0000-0002-6744-1463; Achim Tresch 0000-0002-4146-6371; Johannes Wilhelm Rey 0000-0001-9905-4444.

S-Editor: Liu GL

L-Editor: Webster JR

P-Editor: Liu GL

REFERENCES

- 1 **Cook DJ**, Guyatt GH, Salena BJ, Laine LA. Endoscopic therapy for acute nonvariceal upper gastrointestinal hemorrhage: a meta-analysis. *Gastroenterology* 1992; **102**: 139-148 [PMID: 1530782 DOI: 10.1016/0016-5085(92)91793-4]
- 2 **van Leerdam ME**. Epidemiology of acute upper gastrointestinal bleeding. *Best Pract Res Clin Gastroenterol* 2008; **22**: 209-224 [PMID: 18346679 DOI: 10.1016/j.bpg.2007.10.011]
- 3 **Vernava AM 3rd**, Moore BA, Longo WE, Johnson FE. Lower gastrointestinal bleeding. *Dis Colon Rectum* 1997; **40**: 846-858 [PMID: 9221865 DOI: 10.1007/BF02055445]
- 4 **Longstreth GF**. Epidemiology and outcome of patients hospitalized with acute lower gastrointestinal hemorrhage: a population-based study. *Am J Gastroenterol* 1997; **92**: 419-424 [PMID: 9068461]
- 5 **Yamada A**, Niikura R, Yoshida S, Hirata Y, Koike K. Endoscopic management of colonic diverticular bleeding. *Dig Endosc* 2015; **27**: 720-725 [PMID: 26258405 DOI: 10.1111/den.12534]
- 6 **Werner DJ**, Baar T, Kiesslich R, Wenzel N, Abusalim N, Tresch A, Rey JW. Endoscopic hemostasis makes the difference: Angiographic treatment in patients with lower gastrointestinal bleeding. *World J Gastrointest Endosc* 2021; **13**: 221-232 [PMID: 34326943 DOI: 10.4253/wjge.v13.i7.221]
- 7 **ASGE Technology Committee**, DiSario JA, Petersen BT, Tierney WM, Adler DG, Chand B, Conway JD, Coffie JM, Mishkin DS, Shah RJ, Somogyi L, Wong Kee Song LM. Enteroscopes. *Gastrointest Endosc* 2007; **66**: 872-880 [PMID: 17904135 DOI: 10.1016/j.gie.2007.07.032]
- 8 **Bloomfield RS**, Smith TP, Schneider AM, Rockey DC. Provocative angiography in patients with gastrointestinal hemorrhage of obscure origin. *Am J Gastroenterol* 2000; **95**: 2807-2812 [PMID: 11051352 DOI: 10.1111/j.1572-0241.2000.03191.x]
- 9 **Kim CY**, Suhocki PV, Miller MJ Jr, Khan M, Janus G, Smith TP. Provocative mesenteric angiography for lower gastrointestinal hemorrhage: results from a single-institution study. *J Vasc Interv Radiol* 2010; **21**: 477-483 [PMID: 20171902 DOI: 10.1016/j.jvir.2009.11.021]
- 10 **Malden ES**, Hicks ME, Royal HD, Aliperti G, Allen BT, Picus D. Recurrent gastrointestinal bleeding: use of thrombolysis with anticoagulation in diagnosis. *Radiology* 1998; **207**: 147-151 [PMID: 9530310 DOI: 10.1148/radiology.207.1.9530310]
- 11 **Rösch J**, Keller FS, Wawrukiewicz AS, Krippaehne WW, Dotter CT. Pharmacangiography in the diagnosis of recurrent massive lower gastrointestinal bleeding. *Radiology* 1982; **145**: 615-619 [PMID: 6983087 DOI: 10.1148/radiology.145.3.6983087]
- 12 **Bloomfield RS**, Rockey DC, Shetzline MA. Endoscopic therapy of acute diverticular hemorrhage. *Am J Gastroenterol* 2001; **96**: 2367-2372 [PMID: 11513176 DOI: 10.1111/j.1572-0241.2001.04048.x]
- 13 **Raines DL**, Jex KT, Nicaud MJ, Adler DG. Pharmacologic provocation combined with endoscopy in refractory cases of GI bleeding. *Gastrointest Endosc* 2017; **85**: 112-120 [PMID: 27343413 DOI: 10.1016/j.gie.2016.06.030]
- 14 **Kokoroskos N**, Naar L, Peponis T, Martinez M, El Moheb M, El Hechi M, Alser O, Fuentes E, Velmahos G. Provocative Angiography, Followed by Therapeutic Interventions, in the Management of Hard-To-Diagnose Gastrointestinal Bleeding. *World J Surg* 2020; **44**: 2944-2949 [PMID: 32405731 DOI: 10.1007/s00268-020-05545-8]
- 15 **Gupta B**, Garg N, Ramachandran R. Vasopressors: Do they have any role in hemorrhagic shock? *J Anaesthesiol Clin Pharmacol* 2017; **33**: 3-8 [PMID: 28413267 DOI: 10.4103/0970-9185.202185]
- 16 **Meier J**, Pape A, Loniewska D, Lauscher P, Kertscho H, Zwissler B, Habler O. Norepinephrine increases tolerance to acute anemia. *Crit Care Med* 2007; **35**: 1484-1492 [PMID: 17452931 DOI: 10.1097/01.CCM.0000265740.62130.1C]
- 17 **Hoellein L**, Holzgrabe U. Ficts and facts of epinephrine and norepinephrine stability in injectable solutions. *Int J Pharm* 2012; **434**: 468-480 [PMID: 22613065 DOI: 10.1016/j.jpharm.2012.05.017]
- 18 **Rey JW**, Fischbach A, Teubner D, Dieroff M, Heuberger D, Nguyen-Tat M, Manner H, Kiesslich R, Hoffman A. Acute gastrointestinal bleeding - a new approach to clinical and endoscopic management. *Eur J Gastroenterol Hepatol* 2015; **27**: 483-491 [PMID: 25822855 DOI: 10.1097/MEG.0000000000000343]
- 19 **Travis AC**, Wasan SK, Saltzman JR. Model to predict rebleeding following endoscopic therapy for non-variceal upper gastrointestinal hemorrhage. *J Gastroenterol Hepatol* 2008; **23**: 1505-1510 [PMID: 18823441 DOI: 10.1093/ajg/113.10.1505]

- 10.1111/j.1440-1746.2008.05594.x]
- 20 **Koval G**, Benner KG, Rösch J, Kozak BE. Aggressive angiographic diagnosis in acute lower gastrointestinal hemorrhage. *Dig Dis Sci* 1987; **32**: 248-253 [PMID: [3493124](#) DOI: [10.1007/BF01297049](#)]
 - 21 **Liang HL**, Chiang CL, Chen MC, Lin YH, Huang JS, Pan HB. Pharmacologic-induced vasospasm therapy for acute lower gastrointestinal bleeding: a preliminary report. *Eur J Radiol* 2014; **83**: 1811-1815 [PMID: [25043985](#) DOI: [10.1016/j.ejrad.2014.06.032](#)]
 - 22 **Maleux G**, Roeflaer F, Heye S, Vandersmissen J, Vliegen AS, Demedts I, Wilmer A. Long-term outcome of transcatheter embolotherapy for acute lower gastrointestinal hemorrhage. *Am J Gastroenterol* 2009; **104**: 2042-2046 [PMID: [19455109](#) DOI: [10.1038/ajg.2009.186](#)]
 - 23 **Teng HC**, Liang HL, Lin YH, Huang JS, Chen CY, Lee SC, Pan HB. The efficacy and long-term outcome of microcoil embolotherapy for acute lower gastrointestinal bleeding. *Korean J Radiol* 2013; **14**: 259-268 [PMID: [23483780](#) DOI: [10.3348/kjr.2013.14.2.259](#)]
 - 24 **Mejaddam AY**, Cropano CM, Kalva S, Walker TG, Imam AM, Velmahos GC, de Moya MA, King DR. Outcomes following "rescue" superselective angioembolization for gastrointestinal hemorrhage in hemodynamically unstable patients. *J Trauma Acute Care Surg* 2013; **75**: 398-403 [PMID: [23928742](#) DOI: [10.1097/TA.0b013e31829a8b7a](#)]
 - 25 **Werner DJ**, Manner H, Nguyen-Tat M, Kloeckner R, Kiesslich R, Abusalim N, Rey JW. Endoscopic and angiographic management of lower gastrointestinal bleeding: Review of the published literature. *United European Gastroenterol J* 2018; **6**: 337-342 [PMID: [29774146](#) DOI: [10.1177/2050640617746299](#)]



Published by **Baishideng Publishing Group Inc**
7041 Koll Center Parkway, Suite 160, Pleasanton, CA 94566, USA

Telephone: +1-925-3991568

E-mail: bpgoffice@wjgnet.com

Help Desk: <https://www.f6publishing.com/helpdesk>

<https://www.wjgnet.com>

