

# Artificial Intelligence in *Gastroenterology*

*Artif Intell Gastroenterol* 2022 December 28; 3(5): 117-162







# Artificial Intelligence in Gastroenterology

## Contents

Continuous Publication Volume 3 Number 5 December 28, 2022

### REVIEW

- 117 Artificial intelligence in gastroenterology: A narrative review  
*Galati JS, Duve RJ, O'Mara M, Gross SA*
- 142 Artificial intelligence applications in predicting the behavior of gastrointestinal cancers in pathology  
*Yavuz A, Alpsoy A, Gedik EO, Celik MY, Bassorgun CI, Unal B, Elpek GO*



## Contents

*Artificial Intelligence in Gastroenterology*

Continuous Publication Volume 3 Number 5 December 28, 2022

### ABOUT COVER

Editorial Board Member of *Artificial Intelligence in Gastroenterology*, Alina Ioana Tantau, FACE, PhD, Academic Research, Chief Doctor, Professor, Senior Researcher, Department of Internal Medicine and Gastroenterology, "Iuliu Hatieganu" University of Medicine and Pharmacy, 4th Medical Clinic, Cluj-Napoca 400012, Romania. alitantau@gmail.com

### AIMS AND SCOPE

The primary aim of *Artificial Intelligence in Gastroenterology* (AIG, *Artif Intell Gastroenterol*) is to provide scholars and readers from various fields of artificial intelligence in gastroenterology with a platform to publish high-quality basic and clinical research articles and communicate their research findings online.

AIG mainly publishes articles reporting research results obtained in the field of artificial intelligence in gastroenterology and covering a wide range of topics, including artificial intelligence in gastrointestinal cancer, liver cancer, pancreatic cancer, hepatitis B, hepatitis C, nonalcoholic fatty liver disease, inflammatory bowel disease, irritable bowel syndrome, and *Helicobacter pylori* infection.

### INDEXING/ABSTRACTING

The AIG is now abstracted and indexed in Reference Citation Analysis, China Science and Technology Journal Database.

### RESPONSIBLE EDITORS FOR THIS ISSUE

Production Editor: Si Zhao; Production Department Director: Xiang Li; Editorial Office Director: Jin-Lai Wang.

#### NAME OF JOURNAL

*Artificial Intelligence in Gastroenterology*

#### ISSN

ISSN 2644-3236 (online)

#### LAUNCH DATE

July 28, 2020

#### FREQUENCY

Continuous Publication

#### EDITORS-IN-CHIEF

Rajvinder Singh, Ferruccio Bonino

#### EDITORIAL BOARD MEMBERS

<https://www.wjgnet.com/2644-3236/editorialboard.htm>

#### PUBLICATION DATE

December 28, 2022

#### COPYRIGHT

© 2023 Baishideng Publishing Group Inc

#### INSTRUCTIONS TO AUTHORS

<https://www.wjgnet.com/bpg/gerinfo/204>

#### GUIDELINES FOR ETHICS DOCUMENTS

<https://www.wjgnet.com/bpg/GerInfo/287>

#### GUIDELINES FOR NON-NATIVE SPEAKERS OF ENGLISH

<https://www.wjgnet.com/bpg/gerinfo/240>

#### PUBLICATION ETHICS

<https://www.wjgnet.com/bpg/GerInfo/288>

#### PUBLICATION MISCONDUCT

<https://www.wjgnet.com/bpg/gerinfo/208>

#### ARTICLE PROCESSING CHARGE

<https://www.wjgnet.com/bpg/gerinfo/242>

#### STEPS FOR SUBMITTING MANUSCRIPTS

<https://www.wjgnet.com/bpg/GerInfo/239>

#### ONLINE SUBMISSION

<https://www.f6publishing.com>

© 2022 Baishideng Publishing Group Inc. All rights reserved. 7041 Koll Center Parkway, Suite 160, Pleasanton, CA 94566, USA

E-mail: [bpgoffice@wjgnet.com](mailto:bpgoffice@wjgnet.com) <https://www.wjgnet.com>



## Artificial intelligence in gastroenterology: A narrative review

Jonathan S Galati, Robert J Duve, Matthew O'Mara, Seth A Gross

**Specialty type:** Gastroenterology and hepatology

**Provenance and peer review:** Invited article; Externally peer reviewed.

**Peer-review model:** Single blind

**Peer-review report's scientific quality classification**

Grade A (Excellent): 0  
Grade B (Very good): B  
Grade C (Good): C  
Grade D (Fair): D  
Grade E (Poor): 0

**P-Reviewer:** Liu XQ, China; Qi XS, China

**Received:** October 9, 2022

**Peer-review started:** October 9, 2022

**First decision:** October 29, 2022

**Revised:** November 21, 2022

**Accepted:** December 21, 2022

**Article in press:** December 21, 2022

**Published online:** December 28, 2022



**Jonathan S Galati**, Department of Medicine, NYU Langone Health, New York, NY 10016, United States

**Robert J Duve**, Department of Internal Medicine, Jacobs School of Medicine and Biomedical Sciences, University at Buffalo, Buffalo, NY 14203, United States

**Matthew O'Mara, Seth A Gross**, Division of Gastroenterology, NYU Langone Health, New York, NY 10016, United States

**Corresponding author:** Jonathan S Galati, MD, Department of Medicine, NYU Langone Health, 550 First Avenue, New York, NY 10016, United States. [jonathan.galati@nyulangone.org](mailto:jonathan.galati@nyulangone.org)

### Abstract

Artificial intelligence (AI) is a complex concept, broadly defined in medicine as the development of computer systems to perform tasks that require human intelligence. It has the capacity to revolutionize medicine by increasing efficiency, expediting data and image analysis and identifying patterns, trends and associations in large datasets. Within gastroenterology, recent research efforts have focused on using AI in esophagogastroduodenoscopy, wireless capsule endoscopy (WCE) and colonoscopy to assist in diagnosis, disease monitoring, lesion detection and therapeutic intervention. The main objective of this narrative review is to provide a comprehensive overview of the research being performed within gastroenterology on AI in esophagogastroduodenoscopy, WCE and colonoscopy.

**Key Words:** Artificial intelligence; Colonoscopy; Computer-aided detection; Deep learning; Endoscopy; Machine learning

©The Author(s) 2022. Published by Baishideng Publishing Group Inc. All rights reserved.

**Core Tip:** Artificial intelligence (AI) is a complex concept that has the capacity to revolutionize medicine. Within gastroenterology, recent research efforts have focused on using AI in esophagogastroduodenoscopy, wireless capsule endoscopy (WCE) and colonoscopy to assist in diagnosis, disease monitoring, lesion detection and therapeutic intervention. This narrative review provides a comprehensive overview of the research being performed within gastroenterology on AI in esophagogastroduodenoscopy, WCE and colonoscopy.



**Citation:** Galati JS, Duve RJ, O'Mara M, Gross SA. Artificial intelligence in gastroenterology: A narrative review. *Artif Intell Gastroenterol* 2022; 3(5): 117-141

**URL:** <https://www.wjgnet.com/2644-3236/full/v3/i5/117.htm>

**DOI:** <https://dx.doi.org/10.35712/aig.v3.i5.117>

## INTRODUCTION

Artificial intelligence (AI) is a complex concept, broadly defined in medicine as the development of computer systems to perform tasks that require human intelligence[1]. Since its inception in the 1950s, the field of AI has grown considerably (Figure 1)[2]. Often AI is accompanied by the terms machine learning (ML) and deep learning (DL), techniques used within the field of AI to develop systems that can learn and adapt without explicit instructions. Machine learning uses self-learning algorithms that derive knowledge from data to predict outcomes[1]. There are two main categories within ML: Supervised and unsupervised learning. In supervised learning, the AI is trained on a dataset in which human intervention has previously assigned a hierarchy of features which allows the algorithm to understand differences between data inputs and classify or predict outcomes[3]. In unsupervised learning, the system is provided a dataset that has not been categorized by human intervention. The algorithm then analyzes the data with the goal of identifying labels or patterns[3].

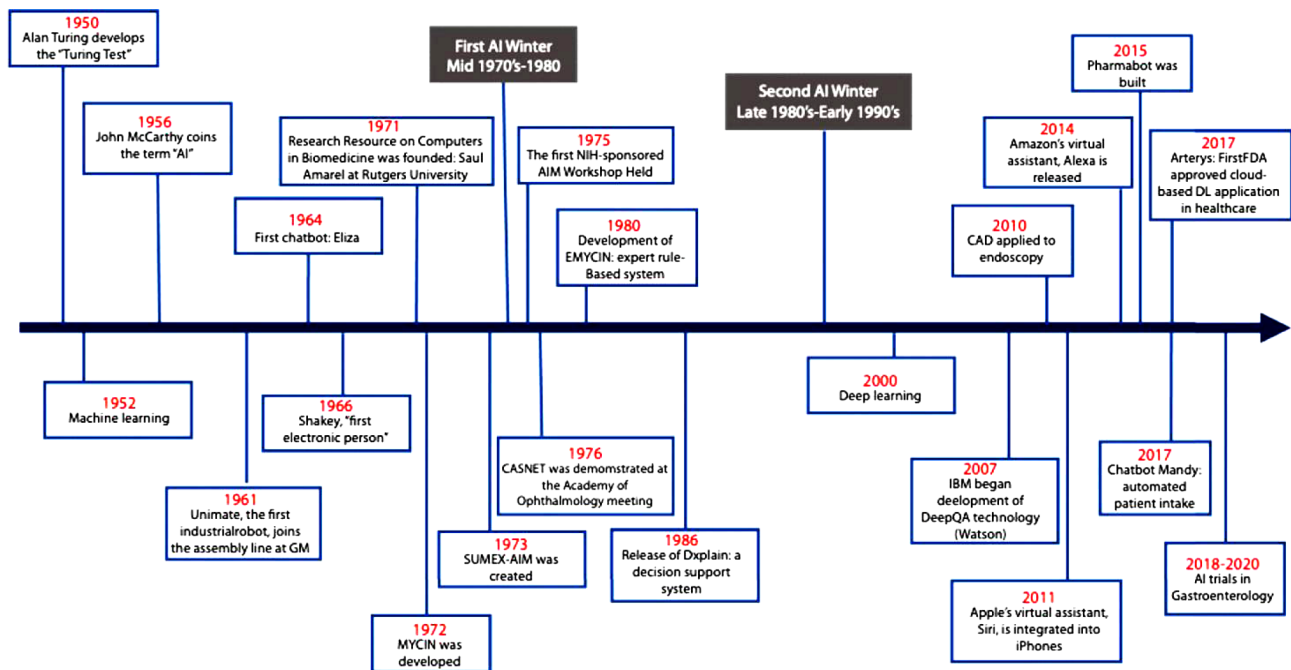
Deep learning is a subfield of ML that utilizes artificial neural networks (ANN) to analyze data. In DL, the system is able to analyze raw data and determine features that distinguish between data inputs. ANN systems are composed of interconnected nodes in a layered structure similar to how neurons are organized in the human brain. The weight of the connections between each node influences how the system can recognize, classify, and describe objects within data[3,4]. ANNs with multiple layers of nodes are classified as deep neural networks which form the backbone of deep learning.

Artificial intelligence has the capacity to revolutionize medicine. It can be used to increase efficiency by aiding in appointment scheduling, reviewing insurance eligibility, or tracking patient history. AI can also expedite data and image analysis and detect patterns, trends and associations[5]. Within gastroenterology, AI's prominence stems from its utility in image analysis[5,6]. Many gastrointestinal diseases rely on endoscopic evaluation for diagnosis, disease monitoring, lesion detection and therapeutic intervention. However, endoscopic evaluation is heavily operator dependent and thus subject to operator bias and human error. As such, recent efforts have focused on using AI in esophagogastroduodenoscopy, wireless capsule endoscopy (WCE) and colonoscopy to mitigate these issues, serving as an additional objective observer of the intestinal tract. The main objective of this narrative review is to provide a comprehensive overview of the research being performed within gastroenterology on artificial intelligence in esophagogastroduodenoscopy, WCE and colonoscopy. While other narrative reviews have been published regarding the use of artificial intelligence in esophagogastroduodenoscopy, WCE and colonoscopy, this narrative review goes a step further by providing a granular and more technical assessment of the literature. As such, this narrative review is intended for medical providers and researchers who are familiar with the use of artificial intelligence in esophagogastroduodenoscopy, WCE and colonoscopy and are interested in obtaining an in-depth review in a specific area.

## LITERATURE REVIEW

Electronic databases Embase, Ovid Medicine, and PubMed were searched from inception to September 2022 using multiple search queries. Combinations of the terms "artificial intelligence", "AI", "computer aided", "computer aided detection", "CADE", "convolutional neural network", "deep learning", "DCNN", "machine learning", "colonoscopy", "endoscopy", "wireless capsule endoscopy", "capsule endoscopy", "WCE", "esophageal cancer", esophageal adenocarcinoma", "esophageal squamous cell carcinoma", "gastric cancer", "gastric neoplasia", "gastric lesions", "Barrett's esophagus", "celiac disease", "Helicobacter pylori", "Helicobacter pylori infection", "H pylori", "H pylori infection", "gastric ulcers", "duodenal ulcers", "inflammatory bowel disease", "IBD", "ulcerative colitis", "Crohn's disease", "parasitic infections", "hookworms", "bleeding", "gastrointestinal bleeding", "vascular lesions", "angioectasias", "polyp", "polyp detection", "tumor", "gastrointestinal tumor", "small bowel tumor", "bowel preparation", "Boston bowel preparation scale", "BBPS", "adenoma", "adenoma detection", "adenoma detection rate", "sessile serrated lesion", and "sessile serrated lesion rate" were used. We subsequently narrowed the results to clinical trials in human published within the last 10 years.





**Figure 1** Timeline of the development and use of artificial intelligence in medicine. AI: Artificial intelligence; DL: Deep learning; FDA: U.S. Food and Drug Administration; CAD: Computer-aided diagnosis. Reprinted with permission from Elsevier Science & Technology Journals[2].

## ESOPHAGOGASTRODUODENOSCOPY

### *Barrett's esophagus and esophageal adenocarcinoma*

Barrett's esophagus (BE) is a premalignant condition associated with esophageal adenocarcinoma (EAC) [7-9]. It is caused by chronic inflammation and tissue injury of the lower esophagus as a result of gastric reflux [7-9]. Early detection and diagnosis can prevent the progression of BE to EAC [7-9]. Patients with BE should undergo routine surveillance endoscopies to monitor for progression. However, even with surveillance, dysplastic changes can be easily missed [7]. To improve the detection of dysplastic changes in BE, researchers have focused on developing AI systems to assist with the identification of dysplasia and early neoplasia during endoscopic evaluation.

Since 2016, a group of researchers from the Netherlands have developed numerous AI systems to identify neoplastic lesions in BE [10-16]. Their first publication detailed their experience using a support vector machine (SVM), a ML method, to identify early neoplastic lesions from white light endoscopy (WLE) images [10]. Their SVM achieved a sensitivity and specificity of 83% with respect to per-image detection and sensitivity of 86% and specificity of 87% with respect to per-patient detection [10]. In their next study, the group trialed several different feature extraction and ML methods using volumetric laser endomicroscopy (VLE) images [11]. They received the best results with the feature extraction module "layering and signal decay statistics", achieving high sensitivity (90%) and specificity (93%) with area under the curve (AUC) 0.95 for neoplastic lesion detection [11]. Following this, they conducted a second study again using ML in VLE to identify neoplastic lesions in BE, however, they used a multiframe analysis approach, including frames neighboring the region of interest in the analysis [12]. With this approach, they found that multiframe analysis resulted in a significantly higher median AUC when compared to single frame analysis (0.91 *vs* 0.83;  $P < 0.001$ ) [12]. Continuing to use ML methods, the group published their finding from the ARGOS project – a consortium of three international tertiary referral centers for Barrett's neoplasia [13]. In this study, de Groof *et al* [13] created a computer-aided detection (CADE) system that used SVM to classify images. The group tested the CADE with 60 images – 40 images from patients with a neoplastic lesion, 20 images from patients with non-dysplastic Barrett's esophagus. The CADE achieved an AUC of 0.92 and a sensitivity, specificity and accuracy of 95%, 85% and 92% respectively for detecting neoplastic lesions [13].

Following their successes creating ML systems for neoplastic lesion detection, the group of researchers from the Netherlands shifted their focus to DL methods. In their first foray into DL, they developed a hybrid CADE system using architecture from ResNet and U-Net models. The CADE was trained with 494364 labeled endoscopic images and subsequently refined with a data set comprised of 1247 WLE images. It was finally tested on a set of 297 images (129 images with early neoplasia, 168 with non-dysplastic BE) where the hybrid CADE system attained a sensitivity of 87.6%, specificity of 88.6% and accuracy of 88.2% for identifying early neoplasia [14]. The system was also tested in two external validation sets where it achieved similar results. A secondary outcome of the study was to see if within the images classified as having neoplasia if the CADE could delineate the neoplasia and recommend a



site for biopsy. The ground truth was determined by expert endoscopists. In two external data sets (external validation data set 4 and 5), the CADe identified the optimal biopsy site in 97.2% of cases and 91.9% of cases respectively[14]. Using a similar hybrid CADe, the group performed a pilot study testing the CADe during live endoscopic procedures[15]. Overall, the CADe achieved a sensitivity of 75.8%, specificity of 86.5% and accuracy of 84% in per-image analyses[15]. Their most recent study again used their hybrid ResNet and U-Net CADe to identify neoplastic lesions in narrow-band imaging (NBI)[16]. With respect to NBI images, the CADe was found to have sensitivity of 88% (95%CI 86%-94%), specificity of 78% (95%CI 72%-84%), and accuracy of 84% (95%CI 81%-88%) for identifying BE neoplasia [16]. In per frame and per video analyses, the CADe achieved sensitivities of 75% and 85%, specificities of 90% and 83% and accuracies of 85% and 83% respectively[16].

Outside of this group from the Netherlands, several other researchers have created DL systems for the detection of BE neoplasia[17-21]. Hong *et al*[17] created a CNN that could distinguish between intestinal metaplasia, gastric metaplasia and neoplasia from images obtained by endomicroscopy in patients with Barrett's esophagus with accuracy of 80.8%. Ebigo *et al*[18] created a DL-CADe capable of detecting BE neoplasia with sensitivity 83.7%, specificity of 100.0% and accuracy of 89.9%. Two other groups achieved similar results to Ebigo *et al*[18]: Hashimoto *et al*'s CNN detected early neoplasia with sensitivity of 96.4%, specificity of 94.2%, and accuracy of 95.4% and Hussein *et al*'s CNN detected early neoplasia with sensitivity 91%, specificity 79%, area under the receiver operating characteristic (AUROC) of 93%[19,20]. An overview of these studies is provided in Table 1.

In addition to neoplasia detection, some groups started to use AI to grade BE and predict submucosal invasion of lesions. Ali *et al*[22] recently published the results from a pilot study using a DL system to quantitatively assess BE area (BEA), circumference and maximal length (C&M). They tested their DL system on 3D printed phantom esophagus models with different BE patterns and 194 videos from 131 patients with BE. In the phantom esophagus models, the DL system achieved an accuracy of 98.4% for BEA and 97.2% for C&M[22]. In the patient videos, the DL system differed from expert endoscopists by 8% and 7% for C&M respectively[22]. Ebigo *et al*[23], building upon their earlier success using a DL CADe to detect neoplasia, performed a pilot study using a 101-layer CNN to differentiate T1a (mucosal) and T1b (submucosal) BE related cancers. Using 230 WLE images obtained from three tertiary care centers in Germany, their CNN was capable of discerning T1a lesions from T1b lesions with sensitivity, specificity and accuracy of 77%, 64% and 71% respectively, comparable to the expert endoscopists enrolled in the study[23].

Despite BE's potential progression to EAC if left unmanaged, few studies have explicitly looked at using AI to detect EAC. Ghatwary *et al*[24] tested several DL models on 100 WLE images (50 featuring EAC, 50 featuring normal mucosa) to determine which was best at identifying EAC. They found that the Single-Shot Multibox Detector (SSD) method achieved the best results, attaining a sensitivity of 96% and specificity of 92%[24]. In 2021, Iwagami *et al*[25] focused on developing an AI system to identify esophagogastric junctional adenocarcinomas. They used SSD for their CNN, achieving a sensitivity, specificity and accuracy of 94%, 42% and 66% for detecting esophagogastric junctional adenocarcinomas. Their CNN performed similarly to endoscopists enrolled in the study (sensitivity 88%, specificity 43%, accuracy 66%)[25].

### Esophageal squamous cell carcinoma

Esophageal squamous cell carcinoma (ESCC) is the most common histologic type of esophageal cancer in the world[26]. While certain imaging modalities such as Lugol's chromoendoscopy and confocal microendoscopy are effective at improving the accuracy, sensitivity and specificity of targeted biopsies, they are expensive and not universally available[27]. In recent years, efforts have focused on developing AI systems to support lower cost imaging modalities in order to improve their ability to detect ESCC.

Shin *et al*[27] and Quang *et al*[28] created ML algorithms which they tested on high-resolution microendoscope images, obtaining comparable sensitivities for the detection of ESCC (98% and 95% respectively). Following these studies, several groups created DL systems to detect ESCC[29-38]. In Cai *et al*'s study, their deep neural network-CADe was tested on 187 images obtained from WLE. The system obtained good sensitivity (97.8%), specificity (85.4%) and accuracy (91.4%) for identifying ESCC [29]. Similar findings occurred in three separate studies that used deep convolutional neural networks (DCNNs) to detect ESCC in WLE[30-32]. Using NBI, Guo *et al*[33] created a CADe that achieved high sensitivity (98.0%), specificity (95.0%) and an AUC of 0.99 for detecting ESCC in still images. Similar results were obtained in Li *et al*'s study[35]. For detecting ESCC in NBI video clips, Fukuda *et al*[34] obtained different results, finding similar sensitivity (91%) to Guo *et al*[33] however substantially lower specificity (51%). Three studies compared a DL-CADe with WLE to DL-CADe with NBI for the detection of ESCC[32,35,36]. The results from these three studies were quite discordant and as such a statement regarding whether a DL-CADe with WLE or DL-CADe with NBI is better for the detection of ESCC cannot be made at this time.

Interestingly, several studies used DL algorithms to assess ESCC invasion depth[39,40]. Everson *et al* [39] and Zhao *et al*[40] created CNNs to detect intrapapillary capillary loops, a feature of ESCC that correlates with invasion depth, in images obtained from magnification endoscopy with NBI. They achieved similar findings with Everson *et al*'s CNN achieving an accuracy of 93.7% and Zhao *et al*'s achieving an accuracy of 89.2%[39,40]. Using DL, two groups created DCNNs to directly detect ESCC



**Table 1 Overview of findings from studies evaluating the detection accuracy of computer-aided detection for Barrett's esophagus-related neoplasia**

Ref.	Country	Study design	AI Classifier	Lesions	Training dataset	Test dataset	Sensitivity (%)	Specificity (%)	Accuracy (%)	AUROC
Swager <i>et al</i> [11], 2017	Netherlands	Retrospective	ML <sup>2</sup> methods	NPL	-	60 VLE images	90	93	-	0.95
van der Sommen <i>et al</i> [10], 2016	Netherlands	Retrospective	SVM	NPL	-	100 WLE images	83	83	-	-
Hong <i>et al</i> [17], 2017	South Korea	Retrospective	CNN	NPL, IM, GM	236 endomicroscopy images	26 endomicroscopy images	-	-	80.77	-
de Groof <i>et al</i> [13], 2019	Netherlands, Germany, Belgium	Prospective	SVM	NPL	-	60 WLE images	95	85	91.7	0.92
Ebigbo <i>et al</i> [21], 2019	Germany, Brazil	Retrospective	CNN	EAC	Augsburg dataset: 148 WLE images and NBI; MICCAI dataset: 100 WLE images		97; 94 <sup>a</sup> ; 92	88; 80 <sup>a</sup> ; 100	-	-
Ghatwary <i>et al</i> [24], 2019	England, Egypt	Retrospective	Multiple CNNs	EAC	Images from 21 patients	Images from 9 patients	96	92	-	-
de Groof <i>et al</i> [14], 2020	Netherlands, France, Sweden, Germany, Belgium, Australia	Ambispective	CNN	NPL	Dataset 1: 494364 images; Dataset 2: 1; 247 images; Dataset 3: 297 images	Dataset 3: 297 images; Dataset 4: 80 images; Dataset 5: 80 images	90 <sup>b</sup>	87.5 <sup>b</sup>	88.8 <sup>b</sup>	-
de Groof <i>et al</i> [15], 2020	Netherlands, Belgium	Prospective	CNN	NPL	495611 images	20 patients; 144 WLE images	75.8	86.5	84	-
Ebigbo <i>et al</i> [18], 2020	Germany, Brazil	Prospective	CNN	EAC	129 images	62 images	83.7	100	89.9	-
Hashimoto <i>et al</i> [19], 2020	United States	Retrospective	CNN	NPL	1374 images	458 images	96.4	94.2	95.4	-
Struyvenberg <i>et al</i> [12], 2020	Netherlands	Prospective	ML <sup>2</sup> methods	NPL	-	3060 VLE frames	-	-	-	0.91
Iwagami <i>et al</i> [25], 2021	Japan	Retrospective	CNN	EJC	3443 images	232 images	94	42	66	-
Struyvenberg <i>et al</i> [16], 2021	Netherlands, Sweden, Belgium	Retrospective	CNN	NPL	495611 images	157 NBI zoom videos; 30021 frames	85 <sup>1</sup> ; 75	83 <sup>1</sup> ; 90	83 <sup>1</sup> ; 85	-
Hussein <i>et al</i> [20], 2022	England, Spain, Belgium, Austria	Prospective	CNN	DPL	148936 frames	264 <i>iscan-1</i> images	91	79	-	0.93

<sup>a</sup>Sensitivity and specificity reported by white light endoscopy images from the Augsburg dataset, narrow band images from the Augsburg dataset, and from the MICCAI dataset respectively.

<sup>b</sup>Results found from convolutional neural network analyzing dataset 4.

<sup>1</sup>Sensitivity, specificity and accuracy obtained from per-video analysis and from per-frame analysis respectively.

<sup>2</sup>Multiple machine learning (ML) methods tested. Results from best performing ML method reported.

AI: Artificial intelligence; AUROC: Area under the receiver operating characteristic; CNN: Convolutional neural network; DPL: Dysplasia; EAC: Esophageal adenocarcinoma; EJC: Esophagogastric junctional adenocarcinoma; GM: Gastric metaplasia; IM: Intestinal metaplasia; ML: Machine learning; NBI: Narrow band images; NPL: Neoplasia; SVM: Support vector machine; VLE: Volumetric laser endomicroscopy; WLE: White light endoscopy.

invasion depth[41-43]. One group from Osaka International Cancer Institute conducted two studies using SSD to create their DCNNs[41,42]. The DCNNs were made to classify images as EP-SM1 or EP-SM2-3 as this distinction in ESCC bares clinical significance. The studies (Nakagawa *et al*[41] and Shimamoto *et al*[42]) attained similar accuracies and specificities, however had substantially different sensitivities (90.1% *vs* 50% and 71%)[41,42]. The third study, Tokai *et al*[43], used SSD as well for their DCNN and also programed the DCNN to classify images as EP-SM1 or EP-SM2-3. Their observed sensitivity, specificity and accuracy were lower than those found by Nakagawa *et al*[41] (84.1%, 73.3% and 80.9% respectively).



### Gastric cancer

Gastric cancer is the third leading cause of cancer-related mortality in the world[44,45]. Early detection of precancerous lesions or early gastric cancer with endoscopy can prevent progression to advanced disease[46]. However, a substantial number of upper gastrointestinal cancers are missed placing patients at risk for interval development[45]. To mitigate this risk, AI systems are being developed to assist with lesion detection.

In 2013, Miyaki *et al*[47] used a bag-of-features framework with densely sampled scale-invariant feature transform descriptors to classify still images obtained from magnifying endoscopy with flexible spectral imaging color enhancement as having or not having gastric cancer. Their system, a rudimentary version of ML, obtained good sensitivity (84.8%), specificity (87.0%) and accuracy (85.9%) for identifying gastric cancer[47]. Using SVM, Kanesaka *et al*[48] found higher sensitivity (96.7%), specificity (95%) and accuracy (96.3%).

Following these successes, several groups began using CNNs for the identification of gastric cancer [44-46,49-59]. In 2018, Hirasawa *et al*[44] published one of the first papers to use a CNN (SSD) to detect gastric cancer. In a test set of 2296 images, the CNN had a sensitivity of 92.2% for identifying gastric cancer lesions[44]. In a larger study, Tang *et al*[49] created a DCNN to detect gastric cancer in a test set of 9417 images and 26 endoscopy videos. With respect to their test set, the DCNN performed well, achieving a sensitivity of 95.5% (95%CI 94.8%-96.1%), specificity of 81.7% (95%CI 80.7%-82.8%), accuracy of 87.8% (95%CI 87.1%-88.5%) and AUC 0.94[49]. The DCNN continued to perform well in external validation sets, achieving sensitivity of 85.9%-92.1%, specificity of 84.4%-90.3%, accuracy of 85.1%-91.2% and AUC 0.89-0.93[49]. Compared to expert endoscopists, the DCNN attained higher sensitivity, specificity and accuracy. In the video set, the DCNN achieved a sensitivity of 88.5% (95%CI 71.0%-96.0%)[49]. Several studies using DCNN to detect gastric cancer in endoscopy images obtained similar sensitivities, specificities and accuracies to Tang *et al*[49]. While one study reported a sensitivity of 58.4% for detecting gastric cancer, the sensitivity for the study's 67 endoscopists was 31.9%[55].

Recently, several groups from China and Japan have published studies using CNNs with magnified endoscopy with NBI (ME-NBI) in an effort to improve early gastric cancer detection[56-59]. Using a 22-layer CNN, Horiuchi *et al*[56] achieved a sensitivity, specificity and accuracy of 95.4%, 71.0% and 85.3% respectively for identifying early gastric cancer from a set of 258 ME-NBI images (151 gastric cancer, 107 gastritis). The same group published a similar study the following year however using ME-NBI videos instead of still images[57]. They obtained similar results: sensitivity of 87.4% (95%CI 78.8%-92.8%), specificity of 82.8% (95%CI 73.5%-89.3%) and accuracy of 85.1% (95%CI 79.0%-89.6%)[57]. Hu *et al*[58] and Ueyama *et al*[59] in their studies using CNN to identify gastric cancer in ME-NBI achieved similar sensitivities, specificities and accuracies as Horiuchi *et al*[56]. An overview of these studies is provided in Table 2.

Of increasing interest to researchers within this field is predicting invasion depth of gastric cancer using AI. Few studies have used CNNs to predict invasion depth[60-63]. Yoon *et al*[60] created a CNN to predict gastric cancer lesion depth from standard endoscopy images. The CNN achieved good sensitivity (79.2%) and specificity (77.8%) for differentiating T1a (mucosal) from T1b (submucosal) gastric cancers (AUC 0.851)[60]. Also using standard endoscopy images, Zhu *et al*[61] attained similar results. They trained their CNN to identify P0 (restricted to the mucosa or < 0.5 mm within the muscularis mucosae) vs P1 (≥ 0.5 mm deep into the muscularis mucosae) lesions. The CNN achieved a sensitivity of 76.6%, specificity of 95.6%, accuracy of 89.2% and AUROC 0.94 (95%CI 0.90-0.97). Cho *et al* [62] using DenseNet-161 as their CNN and Nagao *et al*[62] using ResNet50 as their CNN obtained comparable results to Zhu *et al*[61] for predicting gastric cancer invasion depth from endoscopy images.

### Gastric ulcers

Within recent years, numerous studies have been published regarding the use of AI to assist with the detection and classification of gastric lesions. Few of these studies explicitly used AI systems to detect duodenal and gastric ulcers, however they report data pertaining to ulcer detection.

Using YOLOv5, a deep learning object detection model, Ku *et al*[64] created a CADe system capable of detecting multiple gastric lesions with good precision (98%) and sensitivity (89%). Also using YOLO for their DCNN, Yuan *et al*[53] achieved an overall system accuracy of 85.7% for gastric lesion identification. With respect to peptic ulcer detection, their system achieved an accuracy of 95.4% (93.5%-97.2%), sensitivity of 86.2% (77.5%-94.8%) and specificity of 96.8% (95.1%-98.4%)[53]. Guo *et al*[54] used ResNet50 to construct their CADe designed to detect gastric lesions. Their CADe achieved lower sensitivity 71.4% (95%CI 69.5-73.2%) and specificity 70.9% (95%CI 70.3-71.4%) than Yuan *et al*'s DCNN [53], however Guo *et al*[54] combined erosions and ulcers into one category for analysis. With their primary outcome being classifying gastric cancers and ulcers, Namikawa *et al*[52] developed a CNN capable of identifying gastric ulcers with high sensitivity (93.3%; 95%CI 87.3%-97.1%) and specificity (99.0%; 95%CI 94.6%-100%).

### Helicobacter pylori infection

As a risk factor for future development of gastric cancer, early detection and eradication of *Helicobacter pylori* (*H. pylori*) in infected individuals is important. Endoscopic evaluation for *H. pylori* is highly



Table 2 Overview of findings from studies evaluating the detection accuracy of computer-aided detection for gastric cancer

Ref.	Country	Study design	AI classifier	Lesions	Training dataset	Test dataset	Sensitivity (%)	Specificity (%)	Accuracy (%)	AUROC
Miyaki <i>et al</i> [47], 2013	Japan	Prospective <sup>a</sup>	SVM	Gastric cancer	493 FICE-derived magnifying endoscopic images	92 FICE-derived magnifying endoscopic images	84.8	97	85.9	-
Kanesaka <i>et al</i> [48], 2018	Japan, Taiwan	Retrospective	SVM	EGC	126 M-NBI images	81 M-NBI images	96.7	95	96.3	-
Wu <i>et al</i> [50], 2019	China	Retrospective	CNN	EGC	9151 images	200 images	94	91	92.5	-
Cho <i>et al</i> [51], 2019	South Korea	Ambispective	CNN	Advanced gastric cancer, EGC, high grade dysplasia, low grade dysplasia, non-neoplasm	4205 WLE images	812 WLE images; 200 WLE images	-	-	86.6 <sup>b</sup> ; 76.4	0.877 <sup>b</sup>
Tang <i>et al</i> [49], 2020	China	Retrospective	CNN	EGC	35823 WLE images	Internal: 9417 WLE images; External: 1514 WLE images <sup>1</sup>	95.5 <sup>1</sup> ; 85.9-92.1	81.7 <sup>1</sup> ; 84.4-90.3	87.8 <sup>1</sup> ; 85.1-91.2	0.94 <sup>1</sup> ; 0.887-0.925
Namikawa <i>et al</i> [52], 2020	Japan	Retrospective	CNN	Gastric cancer	18410 images	1459 images	99	93.3	99	-
Horiuchi <i>et al</i> [56], 2020	Japan	Retrospective	CNN	EGC	2570 M-NBI images	258 M-NBI images	95.4	71	85.3	0.852
Horiuchi <i>et al</i> [57], 2020	Japan	Retrospective	CNN	EGC	2570 M-NBI images	174 videos	87.4	82.8	85.1	0.8684
Guo <i>et al</i> [54], 2021	China	Retrospective	CNN	Gastric cancer, erosions/ulcers, polyps, varices	293162 WLE images	33959 WLE images	67.5 <sup>2</sup> ; 85.1	70.9 <sup>2</sup> ; 90.3	-	-
Ikenoyama <i>et al</i> [55], 2021	Japan	Retrospective	CNN	EGC	13584 WLE and NBI images	2940 WLE and NBI images	58.4	87.3	-	-
Hu <i>et al</i> [58], 2021	China	Retrospective	CNN	EGC	M-NBI images from 170 patients	Internal: M-NBI from 73 patients External: M-NBI images from 52 patients	79.2 <sup>3</sup> ; 78.2	74.5 <sup>3</sup> ; 74.1	77 <sup>3</sup> ; 76.3	0.808 <sup>3</sup> ; 0.813
Ueyama <i>et al</i> [59], 2021	Japan	Retrospective	CNN	EGC	5574 M-NBI images	2300 M-NBI	98	100	98.7	-
Yuan <i>et al</i> [53], 2022	China	Retrospective	CNN	EGC, advanced gastric cancer, submucosal tumor, polyp, peptic ulcer, erosion, and lesion-free gastric mucosa	29809 WLE images	1579 WLE images	59.2 <sup>4</sup> ; 100	99.3 <sup>4</sup> ; 98.1	93.5 <sup>4</sup> ; 98.4	-

<sup>a</sup>Presumed prospective based on manuscript.

<sup>b</sup>Accuracy of convolutional neural network (CNN) for detecting the five different lesions and detecting gastric cancer respectively. Area under the receiver operating characteristic (AUROC) pertains to detecting gastric cancer.

<sup>1</sup>The external dataset was comprised of images from 3 external sites. Sensitivity, specificity, accuracy and AUROC for the internal dataset and external dataset respectively.

<sup>2</sup>Sensitivity and specificity of CNN for detecting gastric cancers in a dataset comprised of images without annotations and for detecting gastric cancers in a dataset comprised of annotated images respectively.

<sup>3</sup>Sensitivity, specificity, accuracy and AUROC for the internal dataset and external dataset respectively.

<sup>4</sup>Sensitivity, specificity and accuracy for detecting early gastric cancer and for detecting advanced gastric cancer respectively.

"Internal" and "External" refer to internal and external datasets respectively.

CNN: Convolutional neural network; AUROC: Area under the receiver operating characteristic; EGC: Early gastric cancer; FICE: Flexible spectral imaging



color enhancement; M-NBI: Magnifying endoscopy with narrow band imaging; NBI: Narrow band imaging; SVM: Support vector machine; WLE: White light endoscopy.

operator dependent[65]. Pairing artificial intelligence with endoscopy for the detection of *H. pylori* could possibly reduce false results.

Shichijo *et al*[66] used GoogLeNet, a DCNN consisting of 22 layers, to evaluate 11481 images obtained from 397 patients (72 *H. pylori* positive, 325 negative) for the presence or absence of *H. pylori* infection. GoogLeNet attained a sensitivity of 81.9% (95%CI 71.1%-90.0%), specificity of 83.4% (95%CI 78.9%-87.3%) and accuracy of 83.1% (95%CI 79.1%-86.7%) with AUROC 0.89 for detecting *H. Pylori* infection [66]. When compared to endoscopists enrolled in the study, the sensitivity, specificity and accuracy attained by GoogLeNet was comparable to those attained by the endoscopists[66]. This same group published a second study in 2019 again using GoogLeNet for their DCNN[67]. However, a different optimization technique was used to prepare GoogLeNet. The DCNN was tasked with classifying images as *H. pylori* positive, negative or eradicated. In a set of 23699 images, the DCNN attained an accuracy of 80% for *H. pylori* negative, 84% for *H. pylori* eradicated, and 48% for *H. pylori* positive[67]. Also using GoogLeNet, Itoh *et al*[68] obtained similar results to Shichijo *et al*'s 2017 study with respect to sensitivity (86.7%) and specificity (86.7%)[66]. Using ResNet-50 as their architectural unit for their DCNN, Zheng *et al*[69] were successful in classifying images as *H. pylori* positive or negative, achieving a sensitivity, specificity, accuracy and AUC of 81.4% (95%CI 79.8%-82.9%), 90.1% (95%CI 88.4%-91.7%), 84.5% (95%CI 83.3%-85.7%) and 0.93 (95%CI 0.92-0.94) respectively.

Taking a different approach, Yasuda *et al*[70] used linked color imaging (LCI) with SVM to identify *H. pylori* infection. The LCI images were classified into high-hue and low-hue images based on redness and classified by SVM as *H. pylori* positive or negative. This method attained a sensitivity, specificity and accuracy of 90.4%, 85.7% and 87.6% respectively[70]. Combining LCI with a deep learning CADE system, Nakashima *et al*[71] achieved a sensitivity, specificity and accuracy of 92.5%, 80.0%, 84.2% for identifying *H. pylori* negative images, 62.5%, 92.5%, 82.5% for *H pylori* positive images, 65%, 86.2%, 79.2% for *H. pylori* post-eradication images respectively.

### Celiac disease

While immunological tests can support the diagnosis of celiac disease, definitive diagnosis requires histological assessment of duodenal biopsies[72]. As such being able to identify changes in the duodenal mucosa consistent with celiac disease is important. However, these changes can be subtle and difficult to appreciate. Few studies have been published using a CADE system to detect or diagnose celiac disease.

In 2016, Gadermayr *et al*[73] created a system that combined expert knowledge acquisition with feature extraction to classify duodenal images obtained from 290 children as Marsh-0 (normal mucosa) or Marsh-3 (villous atrophy). Expert knowledge acquisition was achieved by having one of three study endoscopists assign a Marsh grade of 0 or 3 to an image. Feature extraction was accomplished using one of three methods: (1) multi-resolution local binary patterns; (2) multi-fractal spectrum; and (3) improved Fisher vectors. From expert knowledge acquisition and feature extraction, their classification algorithm identified images as Marsh-0 or Marsh-3. With optimal settings, the classification algorithm achieved an accuracy of 95.6%-99.6%[73]. In 2016, Wimmer *et al*[74] used CNN to detect celiac disease in a set of 1661 images (986 images of normal mucosa, 675 images of celiac disease) with varying convolutional blocks. Their CNN achieved the best overall classification rate (90.3%) with 4 convolutional blocks[74]. Taking their CNN a step further, they combined the CNN with 4 convolutional blocks with SVM which increased overall classification rate by 6.7%[74]. While interesting, Gadermayr *et al*'s method requires human intervention and the paper's methodology is quite complicated[73], largely in part to the extensive number of systems tested. Wimmer *et al*[74] provided a simpler method that attained a good overall classification rate.

---

## WIRELESS CAPSULE ENDOSCOPY

---

### Celiac disease

Few studies have assessed the utility of AI in the detection of celiac disease using WCE. In 2017, Zhou *et al*[75] trained GoogLeNet, a DCNN, to identify celiac disease using clips obtained during WCE. Their DCCN achieved a sensitivity and specificity of 100% for identifying patients with celiac disease from 10 WCE videos (5 from patients with celiac disease, 5 from healthy controls)[75]. Similarly, Wang *et al*[76] used DL to diagnose celiac disease from WCE videos, however their CNN utilized a block-wise channel squeeze and excitations attenuation module, a newer architectural unit thought to better mimic human visual perception[76]. Their system attained an accuracy of 95.9%, sensitivity of 97.2% and specificity of 95.6% for diagnosing celiac disease.



### Inflammatory bowel disease

WCE is often used in patients with inflammatory bowel disease (IBD) to detect small bowel ulcers and erosions. While computed tomography enterography and MRI have been used to detect areas of disease activity and inflammation along the gastrointestinal tract in patients with IBD, these imaging modalities can miss early or small lesions. While WCE can directly visualize lesions, endoscopists reviewing the video may miss lesions or mistakenly identify imaging artifacts as lesions. AI systems could help reduce these errors. Several studies have been published using AI in WCE to detect intestinal changes consistent with Crohn's disease[77-83].

To discriminate ulcers from normal mucosa in Crohn's disease, Charisis *et al*[78] proposed combining bidimensional ensemble empirical mode decomposition and differential lacunarity to pre-process images followed by classification using several ML algorithms and a multilayer neural network. Using a dataset consisting of 87 ulcer and 87 normal mucosa images, their CADE achieved accuracy 89.0%-95.4%, sensitivity 88.2%-98.8%, and specificity 84.2%-96.6%[78]. Subsequently, Charisis and Hadjileontiadis published a paper in 2016 combining hybrid adaptive filtering and differential lacunarity (HAF-DLac) to process images followed by SVM to detect Crohn's disease related lesions in WCE[79]. In a set of 800 WCE images, the HAF-DLac system achieved a sensitivity, specificity and accuracy of 95.2%, 92.4% and 93.8% respectively for detecting lesions[79]. Using a similar approach to Charisis *et al*[78], Kumar *et al*[80] used MPEG-7 edge, color and texture features to pre-process images followed by image classification using SVM to detect and classify lesions in patients with Crohn's disease. Their system, tested against 533 images (212 normal mucosa, 321 images with lesions), obtained an accuracy of 93.0%-93.8% for detecting lesions and an accuracy of 78.5% for classifying them based on severity.

With respect to deep learning, few groups have used deep learning algorithms in WCE to identify Crohn's disease related lesions. Recently, Ferreira *et al*[82] used a DCNN to identify erosions and ulcers in patients with Crohn's disease. Their DCNN achieved a sensitivity of 98.0%, specificity of 99.0%, accuracy of 98.8% and AUROC of 1.00. Interestingly, Klang *et al*[83] developed a DCNN to detect intestinal strictures. Overall, their DCNN achieved an accuracy of 93.5%  $\pm$  6.7% and AUC of 0.989 for detecting strictures.

### Hookworm infections

Three studies have used artificial intelligence to detect hookworms using WCE. The first to publish on this topic was Wu *et al*[84] in 2016. Using SVM, they were able to create a system that achieved a specificity of 99.0% and accuracy of 98.4% for detecting hookworms in WCE[84]. However, the system's sensitivity was 11.1%. He *et al*[85] created a DCNN using a novel deep hookworm detection framework that modeled the tubular appearance of hookworms. Their DCNN had an accuracy of 88.5% for identifying hookworm[85]. Gan *et al*[86] performed a similar study, finding an AUC of 0.97 (95%CI 0.967-0.978), sensitivity of 92.2%, specificity of 91.1% and accuracy of 91.2%. The concordant findings of these three studies suggest a possible utility of using AI to diagnose hookworm infections.

### Intestinal bleeding

One of the most common reasons to perform WCE is to evaluate for gastrointestinal bleeding after prior endoscopic attempts have failed to localize a source. Since the implementation of WCE in clinical practice, many methods, notably AI, have been employed to improve the detection of gastrointestinal sources of bleeding.

Several studies have looked at using supervised learning to identify bleeding in WCE. In 2014, Sainju *et al*[87] used an ML algorithm to interpret color quantization images and determine if bleeding was present. One of their models achieved a sensitivity, specificity and accuracy of 96%, 90% and 93%, respectively[87]. Using SVM, Usman *et al*[88] achieved similar results - sensitivity, specificity and accuracy of 94%, 91% and 92% respectively.

More recently, several groups have created DCNNs to identify bleeding and sources of bleeding in WCE. In 2021, Ghosh *et al*[89] used a system comprised of two CNN systems (CNN-1, CNN-2) to classify WCE images as bleeding or non-bleeding and subsequently to identify sources of bleeding within the bleeding images. For classifying images as bleeding or non-bleeding, CNN-1 had a sensitivity, specificity, accuracy and AUC of 97.5%, 99.9%, 99.4% and 0.99[89]. For identifying sources of bleeding within the bleeding images, CNN-2 had an accuracy of 94.4% and intersection over union (IoU) of 90.7%[89].

In 2020, Tsuboi *et al*[90] published the first study to use DCNN to detect small bowel angioectasias from WCE images. In their test set which included 488 images of small bowel angioectasias and 10000 images of normal small bowel mucosa, their DCNN achieved an AUC of 0.99 with sensitivity and specificity of 98.8% and 98.4%[90]. Similarly, in 2021 Ribeiro *et al*[91] developed a DCNN to identify vascular lesions, categorizing them by bleeding risk according to Saurin's classification: P0 - no hemorrhagic potential, P1 - uncertain/intermediate hemorrhagic potential and red spots, and P2 - high hemorrhagic potential (angioectasias, varices). In their validation set, the DCNN had a sensitivity, specificity, accuracy and AUROC of 91.7%, 95.3%, 94.1% and 0.97 respectively for identifying P1 lesions[91]. Regarding P2 lesions, the network had a sensitivity, specificity, accuracy and AUROC of 94.1%, 95.1%, 94.8% and 0.98 respectively[91]. This group published a similar study in 2022 however now using



their DCNN to detect and differentiate mucosal erosions and ulcers based on bleeding potential[92]. Saurin's classification was again used to classify lesions, additionally labeling P1 lesions as mucosal erosions or small ulcers and P2 lesions as large ulcers (> 2 cm)[92]. The DCNN achieved an overall sensitivity of  $90.8\% \pm 4.7\%$ , specificity of  $97.1\% \pm 1.7\%$ , and accuracy of  $93.4\% \pm 3.3\%$  in their test set of 1226 images[92]. For the detection of mucosal erosions (P1), their DCNN achieved a sensitivity of 87.2%, specificity of 95.0% and accuracy of 93.3% with AUROC of 0.98 (95%CI 0.97-0.99)[92]. With respect to small ulcers (P1), their DCNN achieved a sensitivity of 86.4%, specificity of 96.9% and accuracy of 94.5% with AUROC of 0.99 (95%CI 0.97-1.00)[92]. Finally, with respect to large ulcers (P2), their DCNN achieved a sensitivity of 95.3%, specificity of 99.2% and AUROC of 1.00 (95%CI 0.98-1.00)[92]. A third study published by this group aimed to develop a DCNN to identify colonic lesions and luminal blood/hematic vestiges had similar findings. In their training set of 1801 images, the DCNN achieved an overall sensitivity, specificity and accuracy of 96.3%, 98.2%, and 97.6% respectively[93]. For detecting mucosal lesions, the DCNN achieved a sensitivity of 92.0%, specificity of 98.5% and AUROC of 0.99 (95%CI 0.98-1.00)[93]. For luminal blood/hematic vestiges, the DCNN achieved a sensitivity of 99.5%, specificity of 99.8% and AUROC of 1.00 (95%CI 0.99-1.00)[93].

### **Polyp and tumor detection**

Gastrointestinal tumors can be difficult to discern from normal mucosa and thus pose a higher degree of diagnostic difficulty compared to other lesions on traditional WCE[94]. As such, developing an AI system to aid with the detection of these easy to miss lesions could be beneficial.

Several groups have developed ML systems to aid with detection. Using SVM, Li *et al*[95] were able to develop a system capable of detecting small bowel tumors with sensitivity, specificity and accuracy of 88.6%, 96.2% and 92.4%. Similarly, Liu *et al*[96] and Faghih Dinevari *et al*[97] used SVM to identify tumors in WCE, however they used different image pre-processing algorithms. Liu *et al*[96] used discrete curvelet transform to pre-process images prior to being classified by SVM. Their ML system achieved a sensitivity of  $97.8\% \pm 0.5$ , specificity of  $96.7\% \pm 0.4$  and accuracy of  $97.3\% \pm 0.5$  for identifying small bowel tumors[96]. Faghih Dinevari *et al*[97] relied on discrete wavelet transform and singular value decomposition for image pre-processing prior to classification by SVM. Their system achieved a sensitivity of 94.0%, specificity of 93.0% and accuracy of 93.5% for identifying small bowel tumors[97]. Sundaram and Santhiyakumari built upon these methodologies, using a region of interest-based color histogram to enhance WCE images prior to being classified by two SVM algorithms: SVM1 and SVM2 [98]. SVM1 classified the WCE image as normal or abnormal. If SVM1 classified the image as abnormal, it was further classified by SVM2 as benign, malignant or normal[98]. The system attained an overall sensitivity of 96.0%, specificity of 95.4% and accuracy of 95.7% for small bowel tumor detection and classification[98].

With respect to DL methods, Blanes-Vidal *et al*[99] created a DCNN to autonomously detect and localize colorectal polyps. Their study included 255 patients who underwent WCE and standard colonoscopy for positive fecal immunochemical tests. Of the 255 patients, 131 had at least 1 polyp. The DCNN obtained a sensitivity of 97.1%, specificity of 93.3% and accuracy of 96.4% for detecting polyps in WCE[99]. Saraiva *et al*[100] and Mascarenhas *et al*[101] similarly used DCNNs to detect colonic polyps in WCE and obtained similar results to Blanes-Vidal *et al*[99-101]. Using an ANN, Constantinescu *et al*[102] created a DL system able to detect small bowel polyps with sensitivity of 93.6% and specificity of 91.4%. For gastric polyps and tumors, Xia *et al*[103] created a novel CNN – a region-based convolutional neural network (RCNN) – to evaluate magnetically controlled capsule endoscopy (MCE) images. Tested on 201365 MCE images obtained from 100 patients, the RCNN detected gastric polyps with sensitivity of 96.5%, specificity of 94.8%, accuracy of 94.9% and AUC of 0.898 (95%CI 0.84-0.96)[103]. For submucosal tumors, the RCNN achieved a sensitivity of 87.2%, specificity of 95.3%, accuracy of 95.2% and AUC of 0.88 (95%CI 0.81-0.96)[103]. Taking a different approach, Yuan and Meng used a novel deep learning method – stacked sparse autoencoder image manifold constraint – to identify intestinal polyps on WCE, finding an accuracy of 98.00% for polyp detection[104]. However, sensitivity, specificity and AUC analyses were not reported.

---

## **COLONOSCOPY**

---

### **Bowel preparation assessment**

Inadequate bowel preparation, present in 15% to 35% of colonoscopies, is associated with lower rates of cecal intubation, lower adenoma detection rate (ADR), and higher rates of procedure-related adverse events[105,106]. For patients with inadequate bowel preparation, the United States Multi-Society Task Force of Colorectal Cancer (MSTF) which represents the American College of Gastroenterology, the American Gastroenterological Association and the American Society for Gastrointestinal Endoscopy (ASGE), and the European Society of Gastrointestinal Endoscopy recommend repeating a colonoscopy within 1 year[105,107-109]. In addition, the MSTF and ASGE recommend that endoscopists document bowel preparation quality at time of colonoscopy[108,109].



Despite these recommendations and variety of bowel preparation rating scales available, documentation of bowel preparation quality remains variable with studies reporting appropriate documentation in 20% to 88% of colonoscopies[110-112]. Few studies have been published regarding the use of DCNN to assist in the objective assessment of bowel preparation. The first group to do so, Zhou *et al*[113] in 2019, found that their DCNN (ENDOANGEL) was more accurate (93.3%) at grading the bowel preparation quality of still images than novice (< 1 year of experience performing colonoscopies; 75.91%), senior (1-3 years of experience performing colonoscopies; 74.36%) and expert (> 3 years of experience performing colonoscopies; 55.11%) endoscopists. When tested on colonoscopy videos, ENDOANGEL remained accurate at grading bowel preparation quality (89.04%)[113].

Building upon their experience with ENDOANGEL, Zhou *et al*[114] created a new system using two DCNNs: DCNN1 filtered unqualified frames while DCNN2 classified images by Boston Bowel Preparation Scale (BBPS) scores. The BBPS is a validated rating scale for assessing bowel preparation quality[115]. Colonic segments are assigned scores on a scale from 0 to 3. Colonic segments unable to be evaluated due to the presence of solid, unremovable stool are assigned a score of 0 whereas colonic segments that are able to be easily evaluated and contain minimal to no stool are assigned a score of 3 [115]. Zhou *et al*'s DCNN2 classified images into two categories: well-prepared (BBPS score 2-3) and poorly prepared (BBPS score 0-1)[114]. There was no difference between the dual DCNN system and study endoscopists when calculating the unqualified image portion (28.35% *vs* 29.58%,  $P = 0.285$ ) and e-BBPS scores (7.81% *vs* 8.74%,  $P = 0.088$ ). In addition, a strong inverse relationship between e-BBPS and ADR ( $\rho = -0.976$ ,  $P = 0.022$ ) was found.

Two other groups developed similar dual DCNN systems as Zhou *et al*[114] to calculate BBPS and obtained concordant findings[116,117]. Lee *et al*[116] tested their system on colonoscopy videos and found the system had an accuracy of 85.3% and AUC of 0.918 for detecting adequate bowel preparation. Using still images, Low *et al*'s system was able to accurately determine bowel preparation adequacy (98%) and subclassify by BBPS (91%)[117].

Using a different approach, Wang *et al*[118] used U-Net to create a DCNN to perform automatic segmentation of fecal matter from still images. Compared to images segmented by endoscopists, U-Net achieved an accuracy of 94.7%.

### Inflammatory bowel disease

Colonoscopy is essential for the assessment of IBD as it allows for real-time evaluation of colonic inflammation[119,120]. Despite there being endoscopic scoring systems available to quantify disease activity, assessment is operator-dependent resulting in high interobserver variability[119-121]. Recent efforts have focused on using artificial intelligence to objectively grade colonic inflammation[121,122].

Several studies have investigated using DCNNs to classify images obtained from patients with ulcerative colitis (UC) by endoscopic inflammation scoring systems. The most commonly used endoscopic scoring system in these studies is the Mayo Endoscopic Score (MES). Physicians assign scores on a scale from 0 to 3 based on the absence or presence of erythema, friability, erosions, ulceration and bleeding[123]. A score of 0 indicates normal or inactive mucosa whereas a score of 3 indicates severe disease activity[123]. In 2018, Ozawa *et al*[121] published the first study to use a DCNN to classify still images obtained from patients with UC into MES 0 *vs* MES 1-3 and MES 0-1 *vs* MES 2-3. Their DCNN had an AUROC of 0.86 (95%CI 0.84-0.87) and AUROC 0.98 (95%CI 0.97-0.98) when differentiating MES 0 *vs* MES 1-3 and MES 0-1 *vs* MES 2-3 respectively[121]. Stidham *et al*[122] performed a similar study and found an AUROC of 0.966 (95%CI 0.967-0.972) for differentiating still images into MES 0-1 *vs* MES 2-3. Using a combined deep learning and machine learning system, Huang *et al*[124] were able to achieve an AUC of 0.938 with accuracy of 94.5% for identifying MES 0-1 *vs* MES 2-3 from still images. While the binary classification used in the aforementioned studies can differentiate remission/mucosal healing (MES 0-1) and active inflammation (MES 2-3), knowing exact MESs also has clinical significance[125,126]. Bhambhani and Zamora created a DCNN to assign individual MESs to still images. The model achieved an AUC of 0.89, 0.86 and 0.96 for classifying images into MES 1, MES 2 and MES 3 respectively and achieved an average specificity of 85.7%, average sensitivity of 72.4% and overall accuracy of 77.2%[127].

In order to simulate how MES is performed in practice, several groups developed systems using DL to predict MES from colonoscopy videos. Yao *et al*'s DCNN had good agreement with MES scoring performed by gastroenterologists in their internal video test set ( $k = 0.84$ ; 95%CI 0.75-0.92), however their DCCN did not perform as well in the external video test set ( $k = 0.59$ ; 95%CI 0.46-0.71)[128]. Gottlieb *et al*[129] reported similar findings to Yao *et al*[128], finding that their DCNN had good agreement with MES scoring performed by gastroenterologists (quadratic weighted kappa of 0.844; 95%CI 0.787-0.901). Gutierrez Becker *et al*[130] created a DL system designed to perform multiple binary tasks: discriminating MES < 1 *vs* MES  $\geq 1$ , MES < 2 *vs* MES  $\geq 2$ , and MES < 3 *vs* MES  $\geq 3$ . For these tasks, their DL system attained an AUROC of 0.84, 0.85, and 0.85 respectively.

A group from Japan published several studies using AI on endoscopic images to predict histologic activity in patients with UC[131-134]. Their first study in 2016 used machine learning to predict persistent histologic inflammation[131]. Their system attained a sensitivity of 74% (95%CI 65%-81%), specificity of 97% (95%CI 95%-99%) and accuracy of 91% (95%CI 83%-95%) for predicting persistent histologic inflammation in still images[131]. Their following studies used a deep neural network labeled



DNUC (deep neural network for evaluation of UC) to identify endoscopic remission and histologic remission[132,134]. In still images, DNUC had a sensitivity of 93.3% (95%CI 92.2%–94.3%), specificity of 87.8% (95%CI 87.0%–88.4%) and diagnostic accuracy of 90.1% (95%CI 89.2%–90.9%) for determining endoscopic remission[132]. With respect to histologic remission, DNUC had a sensitivity of 92.4% (95%CI 91.5%–93.2%), specificity of 93.5% (95%CI 92.6%–94.3%) and diagnostic accuracy of 90.1% (92.9%; 95%CI 92.1%–93.7%)[132]. In colonoscopy videos, DNUC showed a sensitivity of 81.5% (95%CI 78.5%–83.9%) and specificity of 94.7% (95%CI 92.5%–96.4%) for endoscopic remission[134]. For histologic remission, DNUC had a sensitivity of 97.9% (95%CI 97.0%–98.5%) and specificity of 94.6% (95%CI 91.1%–96.9%) in colonoscopy videos[134].

To date, only one study has been published using an AI system to distinguish normal from inflamed colonic mucosa in Crohn's disease[135]. The group paired a DCNN with a long short-term memory (LSTM), a type of neural network that uses previous findings to interpret its current input, and confocal laser endomicroscopy. Their DCNN-LSTM system attained an accuracy of 95.3% and AUC of 0.98 for differentiating normal from inflamed mucosa[135].

### Polyp detection

Colorectal cancer is the third most common malignancy and second leading cause of cancer-related mortality in the world[136]. While colonoscopy is the gold standard for detection and treatment of premalignant and malignant lesions, a substantial number of adenomas are missed[137,138]. As such, efforts have focused on using AI to improve ADR and decrease adenoma miss rate (AMR).

At present, numerous pilot, validation and prospective studies[139–161], randomized controlled studies[162–174], and systematic reviews and meta-analyses[175–183] have been published regarding the use of AI for the detection of colonic polyps. Furthermore, there are commercially available AI systems for both polyp detection and interpretation. With respect to the systematic reviews and meta-analyses published on this topic, AI-assisted colonoscopy has consistently been shown to have higher ADR, polyp detection rate (PDR) and adenoma per colonoscopy (APC) compared to standard colonoscopy [175–183]. Recently, several large, randomized controlled trials have been published supporting these findings. Shaukat *et al*[162] published their findings from their multicenter, randomized controlled trial comparing CADe colonoscopy to standard colonoscopy. Their study included 1359 patients: 677 randomized to standard colonoscopy, 682 to CADe colonoscopy. They found an increase in ADR (47.8% *vs* 43.9%;  $P = 0.065$ ) and APC (1.05 *vs* 0.83;  $P = 0.002$ ) in the CADe colonoscopy group. However, they also found a decrease in the overall sessile serrated lesions per colonoscopy rate (0.20 *vs* 0.28;  $P = 0.042$ ) and sessile serrated lesion detection rate (12.6% *vs* 16.0%;  $P = 0.092$ ) in the CADe colonoscopy group [162]. Brown *et al*[163] in their CADeT-CS Trial which was a multicenter, single-blind randomized tandem colonoscopy study comparing CADe colonoscopy to high-definition white light colonoscopy found similar increases in ADR (50.44% *vs* 43.64%;  $P = 0.3091$ ) and APC (1.19 *vs* 0.90;  $P = 0.0323$ ) in their patients who underwent CADe colonoscopy first[163]. Additionally, polyp miss rate (PMR) (20.70% *vs* 33.71%;  $P = 0.0007$ ), AMR (20.12% *vs* 31.25%;  $P = 0.0247$ ), and sessile serrated lesion miss rate (7.14% *vs* 42.11%;  $P = 0.0482$ ) were lower in the CADe colonoscopy first group. In a similarly designed study to Brown *et al*[163], Kamba *et al*'s multicenter, randomized tandem colonoscopy study comparing CADe colonoscopy to standard colonoscopy found lower AMR (13.8% *vs* 26.7%;  $P < 0.0001$ ), PMR (14.2% *vs* 40.6%;  $P < 0.0001$ ), and sessile serrated lesion miss rate (13.0% *vs* 38.5%  $P = 0.03$ ) and higher ADR (64.5% *vs* 53.6%;  $P = 0.036$ ) and PDR (69.8% *vs* 60.9%;  $P = 0.084$ ) in patients who underwent CADe colonoscopy first[164]. Similar to Shaukat *et al*[162], the sessile serrated lesion detection rate was lower in the CADe colonoscopy first group compared to standard colonoscopy first (7.6% *vs* 8.1%;  $P = 0.866$ ) [164]. Similar increases in ADR, APC and PDR were appreciated in randomized controlled trials by Xu *et al*[172], Liu *et al*[173], Repici *et al*[170], Gong *et al*[166], Wang *et al*[167], and Su *et al*[169] as well[166–172].

The majority of AI-assisted colonoscopy studies focus on adenoma detection. While these studies report sessile serrated lesion rates, it is often a secondary outcome despite sessile serrated lesions being the precursors of 15%–30% of all colorectal cancers[184]. Few studies have created AI systems optimized for dedicating sessile serrated lesions. Recently, Yoon *et al*[184] used a generative adversarial network (GAN) to generate endoscopic images of sessile serrated lesions which were used to train their DCNN with the hope of improving sessile serrated lesion detection. In the validation set which was comprised of 1141 images of polyps and 1000 normal images, their best performing GAN-DCNN model, GAN-aug2, achieved a sensitivity of 95.44% (95%CI 93.71%–97.17%), specificity of 90.10% (95%CI 88.38%–91.77%), accuracy of 92.95% (95%CI 91.86%–94.04%) and AUROC of 0.96 (95%CI 0.9547–0.9709)[184]. In a type-separated polyp validation dataset, the GAN-aug2 achieved a sensitivity of 95.24%, 19.1% higher than the DCNN without augmentation[184]. Given the small number of sessile serrate lesions present in the initial set, Yoon *et al*[184] collected an additional 130 images depicting 133 sessile serrated lesions to create an additional validation set titled SSL temporal validation dataset[184]. The GAN-aug2 continued to outperform the DCNN without augmentation (sensitivity 93.98% *vs* 84.21%). Nemoto *et al*[185] created a DCNN to differentiate (1) tubular adenomas from serrated lesions; and (2) serrated lesions from hyperplastic polyps. In their 215-image training set, the DCNN was able to differentiate tubular adenomas from sessile serrated lesions with sensitivity of 72% (95%CI 62%–81%), specificity 89% (95%CI 82%–94%), accuracy 82% (95%CI 77%–87%) and AUC 0.86 (95%CI 0.80–0.91). For differentiating sessile serrated lesions from hyperplastic polyps, the DCNN achieved a sensitivity of 17% (95%CI 7%–32%),



specificity 85% (95%CI 76%-92%), accuracy 63% (95%CI 54%-72%) and AUC 0.55 (95%CI 0.44-0.66)[185]. An overview of studies investigating the detection accuracy of CADe is provided in Table 3. An overview of studies investigating ADR and PDR using CADe is provided in Table 4.

## FUTURE DIRECTIONS

Artificial intelligence is in its early stages for medicine, especially in gastroenterology and endoscopy. AI will help in the areas of “augmentation” and “automation”. Augmentation like what is happening with polyp detection and interpretation. Automation by eliminating electronic paperwork, such as the use of natural language processing for procedure documentation. Artificial intelligence systems have repeatedly been shown to be effective at identifying gastrointestinal lesions with high sensitivity, specificity and accuracy. While lesion detection is important, this is only the beginning of AI’s utility in esophagogastroduodenoscopy, WCE and colonoscopy.

After refining their AI systems for lesion detection, several groups discussed in this narrative review were able to add additional functions to their AI systems. In BE, ESCC and gastric cancer, several AI systems were capable of predicting tumor invasion depth. Within IBD, AI systems were able to generate endoscopic disease severity scores. One group was able to train their CADe to recommend neoplasia biopsy sites in BE[14]. Additional efforts should be dedicated to developing these functions, testing them in real-time and having the AI system provide management recommendations when clinically appropriate.

Additional areas in need of future research are using AI systems to make histologic predictions, to assist with positioning of the endoscopic ultrasound (EUS) transducer and interpretation of EUS images, to detect biliary diseases and make therapeutic recommendations in endoscopic retrograde cholangiopancreatography (ERCP), and, in combination with endoscopic mechanical attachments, to improve colorectal cancer screening and surveillance. While endoscopists may perform optical biopsies of gastrointestinal lesions to predict histology and make real-time management decisions, these predictions are highly operator-dependent and often require expensive equipment that is not readily available. Thus, developing an AI system capable of performing objective optical biopsies, especially in WLE, would preserve the quality of histologic predictions, be cost effective, and avoid the risks associated with endoscopic biopsy and resection.

Similarly, EUS is highly operator-dependent, requiring endoscopists to place the transducer in specific positions to obtain adequate views of the hepatopancreatobiliary system. Research should focus on using AI systems to assist with appropriate transducer positioning and perform real-time EUS image analysis[186-194].

Presently, several clinical studies are actively recruiting patients to evaluate the utility of AI systems in ERCP. Of particular interest is the diagnosis and management of biliary diseases. Some groups are planning to use AI to classify bile duct lesions and provide biopsy site recommendations[195]. One group is planning to use an AI system in patients requiring biliary stents to assist with biliary stent choice and stent placement[196]. It will be interesting to see how AI performs in these tasks as successes could pave the way for future studies investigating the utility of AI systems to make real-time management recommendations.

While this narrative review focused on the use of AI in colonoscopy, of growing interest is the use of endoscopic mechanical attachments in colonoscopy to assist with polyp detection in colorectal cancer screening and surveillance. Independently, AI systems and endoscopic mechanical attachments are known to increase ADR and PDR. Few studies have investigated how combining AI with endoscopic mechanical attachments impacts ADR and PDR. Future research should examine the impact that combining these modalities has on ADR and PDR.

## LIMITATIONS

While substantial advances have been made in AI, it is important to note that AI is not without limitations. In many of the studies discussed in this narrative review, the authors trained their AI systems using internally obtained images labeled by a single endoscopist. Thus, the AI is subject to the same operator biases and human error as the labeling endoscopist[1,197]. In addition, by using internally obtained data, several of these training sets may have inherent institutional or geographic biases resulting in AI systems that are biased and nongeneralizable[197]. As AI continues to progress, large datasets comprised of high-quality images should be created and used for training AI systems to reduce these biases[1].

With the implementation of AI in clinical practice, medical error accountability must also be addressed. While many of the AI systems discussed in this narrative review boast high detection accuracies, none are perfect. It is undeniable that errors in detection and diagnosis will arise when using these technologies. Regulatory bodies are needed to continually supervise these AI systems and oversee problems as they arise[198].



**Table 3 Overview of findings from studies evaluating the detection accuracy of computer-aided detection for colonic polyps**

Ref.	Country	Study design	Lesions	Training dataset	Test dataset	Sensitivity (%)	Specificity (%)	Accuracy (%)	AUROC
Komeda <i>et al</i> [139], 2017	Japan	Retrospective	Adenomas	1200 images	10 images	80	60	70	-
Misawa <i>et al</i> [140], 2018	Japan	Retrospective	Polyps	411 video clips	135 video clips	90	63.3	76.5	0.87
Wang <i>et al</i> [149], 2018	China, United States	Retrospective	Polyps	4495 images	Dataset A: 27113 images; Dataset C: 138 video clips; Dataset D: 54 full-length videos	Dataset A: 94.38; Dataset C: 91.64	Dataset A: 95.92; Dataset D: 95.4	-	Dataset A: 0.984
Horiuchi <i>et al</i> [154], 2019	Japan	Prospective	Diminutive polyps	-	<sup>a</sup>	80	95.3	91.5	-
Hassan <i>et al</i> [141], 2020	Italy, United States	Retrospective	Polyps	-	338 video clips	99.7	-	-	-
Guo <i>et al</i> [142], 2021	Japan	Retrospective	Polyps	1991 images	100 video clips; 15 full videos	87 <sup>b</sup>	98.3 <sup>b</sup>	-	-
Neumann <i>et al</i> [143], 2021	Germany	Retrospective	Polyps	> 500 videos	240 polyps within full-length videos	100	0	-	-
Li <i>et al</i> [144], 2021	Singapore	Retrospective	Polyps	6038 images	2571 images	74.1	85.1	-	-
Livovsky <i>et al</i> [151], 2021	Israel	Ambispective	Polyps	3611 h of videos	1393 h of videos	97.1	0	-	-
Pfeifer <i>et al</i> [158], 2021	Germany, Italy, Netherlands	Retrospective	Polyps	10467 images	45 videos	90	80	-	0.92
Ahmad <i>et al</i> [145], 2022 <sup>2</sup>	England	Prospective	Polyps	Dataset A: 58849 frames; Dataset B: 10993 videos and still images	Dataset C: 110985 frames; Dataset D: 8950 frames; Dataset E: 542484 frames	Dataset C: 100, 84.1; Dataset D&E: 98.9, 85.2	Dataset C: 79.6; Dataset D&E: 79.3%	-	-
Hori <i>et al</i> [146], 2022	Japan	Prospective	Polyps	1456 images	600 images	97	97.7	97.3	-
Pacal <i>et al</i> [152], 2022	Turkey	Retrospective	Polyps	Used images from 3 publicly available datasets (SUN, PICCOLO, Etis-Larib) to create training and test datasets		91.04	-	-	-
Yoon <i>et al</i> [184], 2022	South Korea	Retrospective	SSL	4397 images	Validation Set 2106; SSL Temporal Validation set 133	95.44; 93.89	90.1	92.95	0.96
Nemoto <i>et al</i> [185], 2022	Japan	Retrospective	TA, SSL	1849 images	400 images	72	89	82	0.86
Lux <i>et al</i> [148], 2022	Germany	Retrospective	Polyps	506338 images	41 full-length videos	-	-	95.3	-

<sup>a</sup>Tested CAdE in a cohort of 95 patients.<sup>b</sup>Per-frame analysis from full-length video dataset.<sup>1</sup>Presumed retrospective based on manuscript.<sup>2</sup>Sensitivity is reported as per-polyp and per-frame respectively. Specificity is reported as per-frame.

AUROC: Area under the receiver operating characteristic; SSL: Sessile serrate lesion; TA: Tubular adenoma. All studies used a convolutional neural network to classify images.



## CONCLUSION

In this narrative review, we provide an objective overview of the AI-related research being performed within esophagogastroduodenoscopy, WCE and colonoscopy. We attempted to be comprehensive by using several electronic databases including Embase, Ovid Medicine, and PubMed. However, it is possible that some publications pertinent to our narrative review were missed.

Undoubtedly, AI within esophagogastroduodenoscopy, WCE and colonoscopy is rapidly evolving, moving from retrospectively tested supervised learning algorithms to large, multicenter clinical trials using completely autonomous systems within the span of 10 years. The systems developed by these researchers show promise for detecting lesions, diagnosing conditions, and monitoring diseases. In fact, two of the computer aided detection systems discussed in this narrative review designed to aid with colorectal polyp detection were approved by the United States Food and Drug Administration in 2021 [171,199]. Thus, the question is no longer if but when will AI become integrated with clinical practice. Medical providers at all levels of training should prepare to incorporate artificial intelligence systems into routine practice.

**Table 4 Overview of findings from studies evaluating computer-aided detection for adenoma detection rate and polyp detection rate**

Ref.	Country	Study design	Patients (n)		PDR (%)			ADR (%)		
			CADe	SC	CADe	SC	P value	CADe	SC	P value
Wang <i>et al</i> [168], 2019	China, United States	Randomized	522	536	45.02	29.1	< 0.001	29.12	20.34	< 0.001
Becq <i>et al</i> [155], 2020	United States, Turkey, Costa Rica	Prospective	50 <sup>b</sup>		82	62	Not reported	-	-	-
Gong <i>et al</i> [166], 2020	China	Randomized	355	349	47	34	0.0016	16	8	0.001
Liu <i>et al</i> [171], 2020	China, United States	Randomized	393	397	47.07	33.25	< 0.001	29.01	20.91	0.009
Liu <i>et al</i> [173], 2020	China	Prospective	508	518	43.65	27.81	< 0.001	39.1	23.89	< 0.001
Repici <i>et al</i> [170], 2020	Italy, Kuwait, United States, Germany	Randomized	341	344	-	-	-	54.8	40.4	< 0.001
Su <i>et al</i> [169], 2020	China	Randomized	308	315	38.3	25.4	0.001	28.9	16.5	< 0.001
Wang <i>et al</i> [156], 2020	China, United States	Prospective, Tandem <sup>1</sup>	184	185	65.59	55.14	0.099	42.39	35.68	0.186
Wang <i>et al</i> [167], 2020	China, United States	Randomized	484	478	52	37	< 0.0001	34	28	0.03
Kamba <i>et al</i> [164], 2021	Japan	Randomized, Tandem <sup>2</sup>	172	174	69.8	60.9	0.084	64.5	53.6	0.036
Luo <i>et al</i> [174], 2021	China	Randomized, Tandem <sup>1</sup>	72	78	38.7	34	< 0.001	-	-	-
Pfeifer <i>et al</i> [158], 2021	Germany, Italy, Netherlands	Prospective, Tandem <sup>1</sup>	42 <sup>b</sup>		50	38	0.023	36	26	0.044
Shaukat <i>et al</i> [157], 2021	United States, England	Prospective	83	283	-	-	-	54.2	40.6	0.028
Shen <i>et al</i> [150], 2021	China	Ambispective	64	64	78.1	56.3	0.008	53.1	29.7	0.007
Xu <i>et al</i> [172], 2021	China	Randomized	1177	1175	38.8	36.2	0.183	-	-	-
Glissen Brown <i>et al</i> [163], 2022	China, United States	Randomized, Tandem <sup>2</sup>	113	110	70.8	65.45	0.3923	50.44	43.64	0.3091
Ishiyama <i>et al</i> [159], 2022	Japan, Norway	Prospective	918	918	59	52.1	0.003	26.4	19.9	0.001
Lux <i>et al</i> [148], 2022	Germany	Retrospective	41	-	-	-	-	-	41.5	-



Quan <i>et al</i> [153], 2022	United States	Prospective	300	300	-	-	-	43.7 <sup>a</sup> ; 66.7	37.8 <sup>a</sup> ; 59.72	0.37 <sup>a</sup> ; 0.35
Repici <i>et al</i> [165], 2022	Italy, Switzerland, United States, Germany	Randomized	330	330	-	-	-	53.3	44.5	0.017
Shaukat <i>et al</i> [162], 2022	United States	Randomized	682	677	64.4	61.2	0.242	47.8	43.9	0.065
Zippelius <i>et al</i> [160], 2022	Germany, United States	Prospective	150 <sup>b</sup>		-	-	-	50.7	52	0.5

<sup>a</sup>Quan *et al* [153] reported results by indication, screening and surveillance respectively.

<sup>b</sup>The same patients were used to compare CAdE versus standard colonoscopy; Becq *et al* [155] recorded 50 colonoscopy videos that were analyzed by CAdE and reviewed by endoscopists separately; Pfeifer *et al* [158] performed standard colonoscopy followed by CAdE-assisted colonoscopy in all 42 patients; Zippelius *et al* [160] had their CAdE analyze their patients while the endoscopists performed their colonoscopies.

<sup>1</sup>Performed analyses using data obtained from whole process.

<sup>2</sup>Performed analyses using data obtained from first pass.

ADR: Adenoma detection rate; CAdE: Computer-aided detection; PDR: Polyp detection rate; SC: Standard colonoscopy. All studies used a convolutional neural network to classify images.

## FOOTNOTES

**Author contributions:** Galati JS, Gross SA contributed to manuscript concept and design; Galati JS, Duve RJ, O'Mara M contributed to obtaining and interpreting literary sources, drafting of manuscript; Galati JS, Duve RJ, O'Mara M, Gross SA contributed to revision of manuscript; All authors read and approved the final version of the manuscript.

**Conflict-of-interest statement:** All the authors declare that they have no conflict of interest.

**Open-Access:** This article is an open-access article that was selected by an in-house editor and fully peer-reviewed by external reviewers. It is distributed in accordance with the Creative Commons Attribution NonCommercial (CC BY-NC 4.0) license, which permits others to distribute, remix, adapt, build upon this work non-commercially, and license their derivative works on different terms, provided the original work is properly cited and the use is non-commercial. See: <https://creativecommons.org/licenses/by-nc/4.0/>

**Country/Territory of origin:** United States

**ORCID number:** Jonathan S Galati 0000-0001-8075-3376; Seth A Gross 0000-0001-8942-865X.

**S-Editor:** Liu JH

**L-Editor:** A

**P-Editor:** Liu JH

## REFERENCES

- Kröner PT, Engels MM, Glicksberg BS, Johnson KW, Mzaik O, van Hooft JE, Wallace MB, El-Serag HB, Krittanawong C. Artificial intelligence in gastroenterology: A state-of-the-art review. *World J Gastroenterol* 2021; **27**: 6794-6824 [PMID: 34790008 DOI: 10.3748/wjg.v27.i40.6794]
- Kaul V, Enslin S, Gross SA. History of artificial intelligence in medicine. *Gastrointest Endosc* 2020; **92**: 807-812 [PMID: 32565184 DOI: 10.1016/j.gie.2020.06.040]
- Deo RC. Machine Learning in Medicine. *Circulation* 2015; **132**: 1920-1930 [PMID: 26572668 DOI: 10.1161/CIRCULATIONAHA.115.001593]
- Le Berre C, Sandborn WJ, Aridhi S, Devignes MD, Fournier L, Smaïl-Tabbone M, Danese S, Peyrin-Biroulet L. Application of Artificial Intelligence to Gastroenterology and Hepatology. *Gastroenterology* 2020; **158**: 76-94.e2 [PMID: 31593701 DOI: 10.1053/j.gastro.2019.08.058]
- Christou CD, Tsoulfas G. Challenges and opportunities in the application of artificial intelligence in gastroenterology and hepatology. *World J Gastroenterol* 2021; **27**: 6191-6223 [PMID: 34712027 DOI: 10.3748/wjg.v27.i37.6191]
- Pannala R, Krishnan K, Melson J, Parsi MA, Schulman AR, Sullivan S, Trikudanathan G, Trindade AJ, Watson RR, Maple JT, Lichtenstein DR. Artificial intelligence in gastrointestinal endoscopy. *VideoGIE* 2020; **5**: 598-613 [PMID: 33319126 DOI: 10.1016/j.vgie.2020.08.013]
- Hussein M, González-Bueno Puyal J, Mountney P, Lovat LB, Haidry R. Role of artificial intelligence in the diagnosis of oesophageal neoplasia: 2020 an endoscopic odyssey. *World J Gastroenterol* 2020; **26**: 5784-5796 [PMID: 33132634 DOI: 10.3748/wjg.v26.i38.5784]
- Sharma P. Barrett Esophagus: A Review. *JAMA* 2022; **328**: 663-671 [PMID: 35972481 DOI: 10.1001/jama.2022.13298]
- Bujanda DE, Hachem C. Barrett's Esophagus. *Mo Med* 2018; **115**: 211-213 [PMID: 30228724]
- van der Sommen F, Zinger S, Curvers WL, Bisschops R, Pech O, Weusten BL, Bergman JJ, de With PH, Schoon EJ.



- Computer-aided detection of early neoplastic lesions in Barrett's esophagus. *Endoscopy* 2016; **48**: 617-624 [PMID: 27100718 DOI: 10.1055/s-0042-105284]
- 11 **Swager AF**, van der Sommen F, Klomp SR, Zinger S, Meijer SL, Schoon EJ, Bergman JJGHM, de With PH, Curvers WL. Computer-aided detection of early Barrett's neoplasia using volumetric laser endomicroscopy. *Gastrointest Endosc* 2017; **86**: 839-846 [PMID: 28322771 DOI: 10.1016/j.gie.2017.03.011]
  - 12 **Struyvenberg MR**, van der Sommen F, Swager AF, de Groof AJ, Rikos A, Schoon EJ, Bergman JJ, de With PHN, Curvers WL. Improved Barrett's neoplasia detection using computer-assisted multiframe analysis of volumetric laser endomicroscopy. *Dis Esophagus* 2020; **33** [PMID: 31364700 DOI: 10.1093/dote/doz065]
  - 13 **de Groof J**, van der Sommen F, van der Putten J, Struyvenberg MR, Zinger S, Curvers WL, Pech O, Meining A, Neuhaus H, Bisschops R, Schoon EJ, de With PH, Bergman JJ. The Argos project: The development of a computer-aided detection system to improve detection of Barrett's neoplasia on white light endoscopy. *United European Gastroenterol J* 2019; **7**: 538-547 [PMID: 31065371 DOI: 10.1177/2050640619837443]
  - 14 **de Groof AJ**, Struyvenberg MR, van der Putten J, van der Sommen F, Fockens KN, Curvers WL, Zinger S, Pouw RE, Coron E, Baldaque-Silva F, Pech O, Weusten B, Meining A, Neuhaus H, Bisschops R, Dent J, Schoon EJ, de With PH, Bergman JJ. Deep-Learning System Detects Neoplasia in Patients With Barrett's Esophagus With Higher Accuracy Than Endoscopists in a Multistep Training and Validation Study With Benchmarking. *Gastroenterology* 2020; **158**: 915-929.e4 [PMID: 31759929 DOI: 10.1053/j.gastro.2019.11.030]
  - 15 **de Groof AJ**, Struyvenberg MR, Fockens KN, van der Putten J, van der Sommen F, Boers TG, Zinger S, Bisschops R, de With PH, Pouw RE, Curvers WL, Schoon EJ, Bergman JJGHM. Deep learning algorithm detection of Barrett's neoplasia with high accuracy during live endoscopic procedures: a pilot study (with video). *Gastrointest Endosc* 2020; **91**: 1242-1250 [PMID: 31926965 DOI: 10.1016/j.gie.2019.12.048]
  - 16 **Struyvenberg MR**, de Groof AJ, van der Putten J, van der Sommen F, Baldaque-Silva F, Omae M, Pouw R, Bisschops R, Vieth M, Schoon EJ, Curvers WL, de With PH, Bergman JJ. A computer-assisted algorithm for narrow-band imaging-based tissue characterization in Barrett's esophagus. *Gastrointest Endosc* 2021; **93**: 89-98 [PMID: 32504696 DOI: 10.1016/j.gie.2020.05.050]
  - 17 **Jisu Hong**, Bo-Yong Park, Hyunjin Park. Convolutional neural network classifier for distinguishing Barrett's esophagus and neoplasia endomicroscopy images. *Annu Int Conf IEEE Eng Med Biol Soc* 2017; **2017**: 2892-2895 [PMID: 29060502 DOI: 10.1109/EMBC.2017.8037461]
  - 18 **Ebigbo A**, Mendel R, Probst A, Manzeneder J, Prinz F, de Souza LA Jr, Papa J, Palm C, Messmann H. Real-time use of artificial intelligence in the evaluation of cancer in Barrett's oesophagus. *Gut* 2020; **69**: 615-616 [PMID: 31541004 DOI: 10.1136/gutjnl-2019-319460]
  - 19 **Hashimoto R**, Requa J, Dao T, Ninh A, Tran E, Mai D, Lugo M, El-Hage Chehade N, Chang KJ, Karnes WE, Samarasena JB. Artificial intelligence using convolutional neural networks for real-time detection of early esophageal neoplasia in Barrett's esophagus (with video). *Gastrointest Endosc* 2020; **91**: 1264-1271.e1 [PMID: 31930967 DOI: 10.1016/j.gie.2019.12.049]
  - 20 **Hussein M**, González-Bueno Puyal J, Lines D, Sehgal V, Toth D, Ahmad OF, Kader R, Everson M, Lipman G, Fernandez-Sordo JO, Ragunath K, Esteban JM, Bisschops R, Banks M, Haefner M, Mountney P, Stoyanov D, Lovat LB, Haidry R. A new artificial intelligence system successfully detects and localises early neoplasia in Barrett's esophagus by using convolutional neural networks. *United European Gastroenterol J* 2022; **10**: 528-537 [PMID: 35521666 DOI: 10.1002/ueg2.12233]
  - 21 **Ebigbo A**, Mendel R, Probst A, Manzeneder J, Souza LA Jr, Papa JP, Palm C, Messmann H. Computer-aided diagnosis using deep learning in the evaluation of early oesophageal adenocarcinoma. *Gut* 2019; **68**: 1143-1145 [PMID: 30510110 DOI: 10.1136/gutjnl-2018-317573]
  - 22 **Ali S**, Bailey A, Ash S, Haghighat M; TGU Investigators, Leedham SJ, Lu X, East JE, Rittscher J, Braden B. A Pilot Study on Automatic Three-Dimensional Quantification of Barrett's Esophagus for Risk Stratification and Therapy Monitoring. *Gastroenterology* 2021; **161**: 865-878.e8 [PMID: 34116029 DOI: 10.1053/j.gastro.2021.05.059]
  - 23 **Ebigbo A**, Mendel R, Rückert T, Schuster L, Probst A, Manzeneder J, Prinz F, Mende M, Steinbrück I, Faiss S, Rauber D, de Souza LA Jr, Papa JP, Deprez PH, Oyama T, Takahashi A, Seewald S, Sharma P, Byrne MF, Palm C, Messmann H. Endoscopic prediction of submucosal invasion in Barrett's cancer with the use of artificial intelligence: a pilot study. *Endoscopy* 2021; **53**: 878-883 [PMID: 33197942 DOI: 10.1055/a-1311-8570]
  - 24 **Ghatwary N**, Zolgharni M, Ye X. Early esophageal adenocarcinoma detection using deep learning methods. *Int J Comput Assist Radiol Surg* 2019; **14**: 611-621 [PMID: 30666547 DOI: 10.1007/s11548-019-01914-4]
  - 25 **Iwagami H**, Ishihara R, Aoyama K, Fukuda H, Shimamoto Y, Kono M, Nakahira H, Matsuura N, Shichijo S, Kanesaka T, Kanzaki H, Ishii T, Nakatani Y, Tada T. Artificial intelligence for the detection of esophageal and esophagogastric junctional adenocarcinoma. *J Gastroenterol Hepatol* 2021; **36**: 131-136 [PMID: 32511793 DOI: 10.1111/jgh.15136]
  - 26 **Zhang Y**. Epidemiology of esophageal cancer. *World J Gastroenterol* 2013; **19**: 5598-5606 [PMID: 24039351 DOI: 10.3748/wjg.v19.i34.5598]
  - 27 **Shin D**, Protano MA, Polydorides AD, Dawsey SM, Pierce MC, Kim MK, Schwarz RA, Quang T, Parikh N, Bhutani MS, Zhang F, Wang G, Xue L, Wang X, Xu H, Anandasabapathy S, Richards-Kortum RR. Quantitative analysis of high-resolution microendoscopic images for diagnosis of esophageal squamous cell carcinoma. *Clin Gastroenterol Hepatol* 2015; **13**: 272-279.e2 [PMID: 25066838 DOI: 10.1016/j.cgh.2014.07.030]
  - 28 **Quang T**, Schwarz RA, Dawsey SM, Tan MC, Patel K, Yu X, Wang G, Zhang F, Xu H, Anandasabapathy S, Richards-Kortum R. A tablet-interfaced high-resolution microendoscope with automated image interpretation for real-time evaluation of esophageal squamous cell neoplasia. *Gastrointest Endosc* 2016; **84**: 834-841 [PMID: 27036635 DOI: 10.1016/j.gie.2016.03.1472]
  - 29 **Cai SL**, Li B, Tan WM, Niu XJ, Yu HH, Yao LQ, Zhou PH, Yan B, Zhong YS. Using a deep learning system in endoscopy for screening of early esophageal squamous cell carcinoma (with video). *Gastrointest Endosc* 2019; **90**: 745-753.e2 [PMID: 31302091 DOI: 10.1016/j.gie.2019.06.044]
  - 30 **Liu G**, Hua J, Wu Z, Meng T, Sun M, Huang P, He X, Sun W, Li X, Chen Y. Automatic classification of esophageal



- lesions in endoscopic images using a convolutional neural network. *Ann Transl Med* 2020; **8**: 486 [PMID: [32395530](#) DOI: [10.21037/atm.2020.03.24](#)]
- 31 **Liu W**, Yuan X, Guo L, Pan F, Wu C, Sun Z, Tian F, Yuan C, Zhang W, Bai S, Feng J, Hu Y, Hu B. Artificial Intelligence for Detecting and Delineating Margins of Early ESCC Under WLI Endoscopy. *Clin Transl Gastroenterol* 2022; **13**: e00433 [PMID: [35130184](#) DOI: [10.14309/ctg.0000000000000433](#)]
  - 32 **Ohmori M**, Ishihara R, Aoyama K, Nakagawa K, Iwagami H, Matsuura N, Shichijo S, Yamamoto K, Nagaike K, Nakahara M, Inoue T, Aoi K, Okada H, Tada T. Endoscopic detection and differentiation of esophageal lesions using a deep neural network. *Gastrointest Endosc* 2020; **91**: 301-309.e1 [PMID: [31585124](#) DOI: [10.1016/j.gie.2019.09.034](#)]
  - 33 **Guo L**, Xiao X, Wu C, Zeng X, Zhang Y, Du J, Bai S, Xie J, Zhang Z, Li Y, Wang X, Cheung O, Sharma M, Liu J, Hu B. Real-time automated diagnosis of precancerous lesions and early esophageal squamous cell carcinoma using a deep learning model (with videos). *Gastrointest Endosc* 2020; **91**: 41-51 [PMID: [31445040](#) DOI: [10.1016/j.gie.2019.08.018](#)]
  - 34 **Fukuda H**, Ishihara R, Kato Y, Matsunaga T, Nishida T, Yamada T, Ogiyama H, Horie M, Kinoshita K, Tada T. Comparison of performances of artificial intelligence versus expert endoscopists for real-time assisted diagnosis of esophageal squamous cell carcinoma (with video). *Gastrointest Endosc* 2020; **92**: 848-855 [PMID: [32505685](#) DOI: [10.1016/j.gie.2020.05.043](#)]
  - 35 **Li B**, Cai SL, Tan WM, Li JC, Yalikong A, Feng XS, Yu HH, Lu PX, Feng Z, Yao LQ, Zhou PH, Yan B, Zhong YS. Comparative study on artificial intelligence systems for detecting early esophageal squamous cell carcinoma between narrow-band and white-light imaging. *World J Gastroenterol* 2021; **27**: 281-293 [PMID: [33519142](#) DOI: [10.3748/wjg.v27.i3.281](#)]
  - 36 **Shiroma S**, Yoshio T, Kato Y, Horie Y, Namikawa K, Tokai Y, Yoshimizu S, Yoshizawa N, Horiuchi Y, Ishiyama A, Hirasawa T, Tsuchida T, Akazawa N, Akiyama J, Tada T, Fujisaki J. Ability of artificial intelligence to detect T1 esophageal squamous cell carcinoma from endoscopic videos and the effects of real-time assistance. *Sci Rep* 2021; **11**: 7759 [PMID: [33833355](#) DOI: [10.1038/s41598-021-87405-6](#)]
  - 37 **Horie Y**, Yoshio T, Aoyama K, Yoshimizu S, Horiuchi Y, Ishiyama A, Hirasawa T, Tsuchida T, Ozawa T, Ishihara S, Kumagai Y, Fujishiro M, Maetani I, Fujisaki J, Tada T. Diagnostic outcomes of esophageal cancer by artificial intelligence using convolutional neural networks. *Gastrointest Endosc* 2019; **89**: 25-32 [PMID: [30120958](#) DOI: [10.1016/j.gie.2018.07.037](#)]
  - 38 **Kumagai Y**, Takubo K, Kawada K, Aoyama K, Endo Y, Ozawa T, Hirasawa T, Yoshio T, Ishihara S, Fujishiro M, Tamaru JI, Mochiki E, Ishida H, Tada T. Diagnosis using deep-learning artificial intelligence based on the endocytoscopic observation of the esophagus. *Esophagus* 2019; **16**: 180-187 [PMID: [30547352](#) DOI: [10.1007/s10388-018-0651-7](#)]
  - 39 **Everson M**, Herrera L, Li W, Luengo IM, Ahmad O, Banks M, Magee C, Alzoubaidi D, Hsu HM, Graham D, Vercauteren T, Lovat L, Ourselin S, Kashin S, Wang HP, Wang WL, Haidry RJ. Artificial intelligence for the real-time classification of intrapapillary capillary loop patterns in the endoscopic diagnosis of early oesophageal squamous cell carcinoma: A proof-of-concept study. *United European Gastroenterol J* 2019; **7**: 297-306 [PMID: [31080614](#) DOI: [10.1177/2050640618821800](#)]
  - 40 **Zhao YY**, Xue DX, Wang YL, Zhang R, Sun B, Cai YP, Feng H, Cai Y, Xu JM. Computer-assisted diagnosis of early esophageal squamous cell carcinoma using narrow-band imaging magnifying endoscopy. *Endoscopy* 2019; **51**: 333-341 [PMID: [30469155](#) DOI: [10.1055/a-0756-8754](#)]
  - 41 **Nakagawa K**, Ishihara R, Aoyama K, Ohmori M, Nakahira H, Matsuura N, Shichijo S, Nishida T, Yamada T, Yamaguchi S, Ogiyama H, Egawa S, Kishida O, Tada T. Classification for invasion depth of esophageal squamous cell carcinoma using a deep neural network compared with experienced endoscopists. *Gastrointest Endosc* 2019; **90**: 407-414 [PMID: [31077698](#) DOI: [10.1016/j.gie.2019.04.245](#)]
  - 42 **Shimamoto Y**, Ishihara R, Kato Y, Shoji A, Inoue T, Matsueda K, Miyake M, Waki K, Kono M, Fukuda H, Matsuura N, Nagaike K, Aoi K, Yamamoto K, Nakahara M, Nishihara A, Tada T. Real-time assessment of video images for esophageal squamous cell carcinoma invasion depth using artificial intelligence. *J Gastroenterol* 2020; **55**: 1037-1045 [PMID: [32778959](#) DOI: [10.1007/s00535-020-01716-5](#)]
  - 43 **Tokai Y**, Yoshio T, Aoyama K, Horie Y, Yoshimizu S, Horiuchi Y, Ishiyama A, Tsuchida T, Hirasawa T, Sakakibara Y, Yamada T, Yamaguchi S, Fujisaki J, Tada T. Application of artificial intelligence using convolutional neural networks in determining the invasion depth of esophageal squamous cell carcinoma. *Esophagus* 2020; **17**: 250-256 [PMID: [31980977](#) DOI: [10.1007/s10388-020-00716-x](#)]
  - 44 **Hirasawa T**, Aoyama K, Tanimoto T, Ishihara S, Shichijo S, Ozawa T, Ohnishi T, Fujishiro M, Matsuo K, Fujisaki J, Tada T. Application of artificial intelligence using a convolutional neural network for detecting gastric cancer in endoscopic images. *Gastric Cancer* 2018; **21**: 653-660 [PMID: [29335825](#) DOI: [10.1007/s10120-018-0793-2](#)]
  - 45 **Lee JH**, Kim YJ, Kim YW, Park S, Choi YI, Park DK, Kim KG, Chung JW. Spotting malignancies from gastric endoscopic images using deep learning. *Surg Endosc* 2019; **33**: 3790-3797 [PMID: [30719560](#) DOI: [10.1007/s00464-019-06677-2](#)]
  - 46 **Li L**, Chen Y, Shen Z, Zhang X, Sang J, Ding Y, Yang X, Li J, Chen M, Jin C, Chen C, Yu C. Convolutional neural network for the diagnosis of early gastric cancer based on magnifying narrow band imaging. *Gastric Cancer* 2020; **23**: 126-132 [PMID: [31332619](#) DOI: [10.1007/s10120-019-00992-2](#)]
  - 47 **Miyaki R**, Yoshida S, Tanaka S, Kominami Y, Sanomura Y, Matsuo T, Oka S, Raytchev B, Tamaki T, Koide T, Kaneda K, Yoshihara M, Chayama K. Quantitative identification of mucosal gastric cancer under magnifying endoscopy with flexible spectral imaging color enhancement. *J Gastroenterol Hepatol* 2013; **28**: 841-847 [PMID: [23424994](#) DOI: [10.1111/jgh.12149](#)]
  - 48 **Kanesaka T**, Lee TC, Uedo N, Lin KP, Chen HZ, Lee JY, Wang HP, Chang HT. Computer-aided diagnosis for identifying and delineating early gastric cancers in magnifying narrow-band imaging. *Gastrointest Endosc* 2018; **87**: 1339-1344 [PMID: [29225083](#) DOI: [10.1016/j.gie.2017.11.029](#)]
  - 49 **Tang D**, Wang L, Ling T, Lv Y, Ni M, Zhan Q, Fu Y, Zhuang D, Guo H, Dou X, Zhang W, Xu G, Zou X. Development and validation of a real-time artificial intelligence-assisted system for detecting early gastric cancer: A multicentre retrospective diagnostic study. *EBioMedicine* 2020; **62**: 103146 [PMID: [33254026](#) DOI: [10.1016/j.ebiom.2020.103146](#)]



- 50 **Wu L**, Zhou W, Wan X, Zhang J, Shen L, Hu S, Ding Q, Mu G, Yin A, Huang X, Liu J, Jiang X, Wang Z, Deng Y, Liu M, Lin R, Ling T, Li P, Wu Q, Jin P, Chen J, Yu H. A deep neural network improves endoscopic detection of early gastric cancer without blind spots. *Endoscopy* 2019; **51**: 522-531 [PMID: [30861533](#) DOI: [10.1055/a-0855-3532](#)]
- 51 **Cho BJ**, Bang CS, Park SW, Yang YJ, Seo SI, Lim H, Shin WG, Hong JT, Yoo YT, Hong SH, Choi JH, Lee JJ, Baik GH. Automated classification of gastric neoplasms in endoscopic images using a convolutional neural network. *Endoscopy* 2019; **51**: 1121-1129 [PMID: [31443108](#) DOI: [10.1055/a-0981-6133](#)]
- 52 **Namikawa K**, Hirasawa T, Nakano K, Ikenoyama Y, Ishioka M, Shiroma S, Tokai Y, Yoshimizu S, Horiuchi Y, Ishiyama A, Yoshio T, Tsuchida T, Fujisaki J, Tada T. Artificial intelligence-based diagnostic system classifying gastric cancers and ulcers: comparison between the original and newly developed systems. *Endoscopy* 2020; **52**: 1077-1083 [PMID: [32503056](#) DOI: [10.1055/a-1194-8771](#)]
- 53 **Yuan XL**, Zhou Y, Liu W, Luo Q, Zeng XH, Yi Z, Hu B. Artificial intelligence for diagnosing gastric lesions under white-light endoscopy. *Surg Endosc* 2022; **36**: 9444-9453 [PMID: [35879572](#) DOI: [10.1007/s00464-022-09420-6](#)]
- 54 **Guo L**, Gong H, Wang Q, Zhang Q, Tong H, Li J, Lei X, Xiao X, Li C, Jiang J, Hu B, Song J, Tang C, Huang Z. Detection of multiple lesions of gastrointestinal tract for endoscopy using artificial intelligence model: a pilot study. *Surg Endosc* 2021; **35**: 6532-6538 [PMID: [33185766](#) DOI: [10.1007/s00464-020-08150-x](#)]
- 55 **Ikenoyama Y**, Hirasawa T, Ishioka M, Namikawa K, Yoshimizu S, Horiuchi Y, Ishiyama A, Yoshio T, Tsuchida T, Takeuchi Y, Shichijo S, Katayama N, Fujisaki J, Tada T. Detecting early gastric cancer: Comparison between the diagnostic ability of convolutional neural networks and endoscopists. *Dig Endosc* 2021; **33**: 141-150 [PMID: [32282110](#) DOI: [10.1111/den.13688](#)]
- 56 **Horiuchi Y**, Aoyama K, Tokai Y, Hirasawa T, Yoshimizu S, Ishiyama A, Yoshio T, Tsuchida T, Fujisaki J, Tada T. Convolutional Neural Network for Differentiating Gastric Cancer from Gastritis Using Magnified Endoscopy with Narrow Band Imaging. *Dig Dis Sci* 2020; **65**: 1355-1363 [PMID: [31584138](#) DOI: [10.1007/s10620-019-05862-6](#)]
- 57 **Horiuchi Y**, Hirasawa T, Ishizuka N, Tokai Y, Namikawa K, Yoshimizu S, Ishiyama A, Yoshio T, Tsuchida T, Fujisaki J, Tada T. Performance of a computer-aided diagnosis system in diagnosing early gastric cancer using magnifying endoscopy videos with narrow-band imaging (with videos). *Gastrointest Endosc* 2020; **92**: 856-865.e1 [PMID: [32422155](#) DOI: [10.1016/j.gie.2020.04.079](#)]
- 58 **Hu H**, Gong L, Dong D, Zhu L, Wang M, He J, Shu L, Cai Y, Cai S, Su W, Zhong Y, Li C, Zhu Y, Fang M, Zhong L, Yang X, Zhou P, Tian J. Identifying early gastric cancer under magnifying narrow-band images with deep learning: a multicenter study. *Gastrointest Endosc* 2021; **93**: 1333-1341.e3 [PMID: [33248070](#) DOI: [10.1016/j.gie.2020.11.014](#)]
- 59 **Ueyama H**, Kato Y, Akazawa Y, Yatagai N, Komori H, Takeda T, Matsumoto K, Ueda K, Hojo M, Yao T, Nagahara A, Tada T. Application of artificial intelligence using a convolutional neural network for diagnosis of early gastric cancer based on magnifying endoscopy with narrow-band imaging. *J Gastroenterol Hepatol* 2021; **36**: 482-489 [PMID: [32681536](#) DOI: [10.1111/jgh.15190](#)]
- 60 **Yoon HJ**, Kim S, Kim JH, Keum JS, Oh SI, Jo J, Chun J, Youn YH, Park H, Kwon IG, Choi SH, Noh SH. A Lesion-Based Convolutional Neural Network Improves Endoscopic Detection and Depth Prediction of Early Gastric Cancer. *J Clin Med* 2019; **8** [PMID: [31454949](#) DOI: [10.3390/jcm8091310](#)]
- 61 **Zhu Y**, Wang QC, Xu MD, Zhang Z, Cheng J, Zhong YS, Zhang YQ, Chen WF, Yao LQ, Zhou PH, Li QL. Application of convolutional neural network in the diagnosis of the invasion depth of gastric cancer based on conventional endoscopy. *Gastrointest Endosc* 2019; **89**: 806-815.e1 [PMID: [30452913](#) DOI: [10.1016/j.gie.2018.11.011](#)]
- 62 **Cho BJ**, Bang CS, Lee JJ, Seo CW, Kim JH. Prediction of Submucosal Invasion for Gastric Neoplasms in Endoscopic Images Using Deep-Learning. *J Clin Med* 2020; **9** [PMID: [32549190](#) DOI: [10.3390/jcm9061858](#)]
- 63 **Nagao S**, Tsuji Y, Sakaguchi Y, Takahashi Y, Minatsuki C, Niimi K, Yamashita H, Yamamichi N, Seto Y, Tada T, Koike K. Highly accurate artificial intelligence systems to predict the invasion depth of gastric cancer: efficacy of conventional white-light imaging, nonmagnifying narrow-band imaging, and indigo-carmin dye contrast imaging. *Gastrointest Endosc* 2020; **92**: 866-873.e1 [PMID: [32592776](#) DOI: [10.1016/j.gie.2020.06.047](#)]
- 64 **Ku Y**, Ding H, Wang G. Efficient Synchronous Real-Time CAde for Multicategory Lesions in Gastroscopy by Using Multiclass Detection Model. *Biomed Res Int* 2022; **2022**: 8504149 [PMID: [36093395](#) DOI: [10.1155/2022/8504149](#)]
- 65 **Watanabe K**, Nagata N, Shimbo T, Nakashima R, Furuhashi E, Sakurai T, Akazawa N, Yokoi C, Kobayakawa M, Akiyama J, Mizokami M, Uemura N. Accuracy of endoscopic diagnosis of Helicobacter pylori infection according to level of endoscopic experience and the effect of training. *BMC Gastroenterol* 2013; **13**: 128 [PMID: [23947684](#) DOI: [10.1186/1471-230X-13-128](#)]
- 66 **Shichijo S**, Nomura S, Aoyama K, Nishikawa Y, Miura M, Shinagawa T, Takiyama H, Tanimoto T, Ishihara S, Matsuo K, Tada T. Application of Convolutional Neural Networks in the Diagnosis of Helicobacter pylori Infection Based on Endoscopic Images. *EBioMedicine* 2017; **25**: 106-111 [PMID: [29056541](#) DOI: [10.1016/j.ebiom.2017.10.014](#)]
- 67 **Shichijo S**, Endo Y, Aoyama K, Takeuchi Y, Ozawa T, Takiyama H, Matsuo K, Fujishiro M, Ishihara S, Ishihara R, Tada T. Application of convolutional neural networks for evaluating Helicobacter pylori infection status on the basis of endoscopic images. *Scand J Gastroenterol* 2019; **54**: 158-163 [PMID: [30879352](#) DOI: [10.1080/00365521.2019.1577486](#)]
- 68 **Itoh T**, Kawahira H, Nakashima H, Yata N. Deep learning analyzes Helicobacter pylori infection by upper gastrointestinal endoscopy images. *Endosc Int Open* 2018; **6**: E139-E144 [PMID: [29399610](#) DOI: [10.1055/s-0043-120830](#)]
- 69 **Zheng W**, Zhang X, Kim JJ, Zhu X, Ye G, Ye B, Wang J, Luo S, Li J, Yu T, Liu J, Hu W, Si J. High Accuracy of Convolutional Neural Network for Evaluation of Helicobacter pylori Infection Based on Endoscopic Images: Preliminary Experience. *Clin Transl Gastroenterol* 2019; **10**: e00109 [PMID: [31833862](#) DOI: [10.14309/ctg.000000000000109](#)]
- 70 **Yasuda T**, Hiroyasu T, Hiwa S, Okada Y, Hayashi S, Nakahata Y, Yasuda Y, Omatsu T, Obora A, Kojima T, Ichikawa H, Yagi N. Potential of automatic diagnosis system with linked color imaging for diagnosis of Helicobacter pylori infection. *Dig Endosc* 2020; **32**: 373-381 [PMID: [31398276](#) DOI: [10.1111/den.13509](#)]
- 71 **Nakashima H**, Kawahira H, Kawachi H, Sakaki N. Endoscopic three-categorical diagnosis of Helicobacter pylori infection using linked color imaging and deep learning: a single-center prospective study (with video). *Gastric Cancer* 2020; **23**: 1033-1040 [PMID: [32382973](#) DOI: [10.1007/s10120-020-01077-1](#)]



- 72 **Stoleru CA**, Dulf EH, Ciobanu L. Automated detection of celiac disease using Machine Learning Algorithms. *Sci Rep* 2022; **12**: 4071 [PMID: [35260574](#) DOI: [10.1038/s41598-022-07199-z](#)]
- 73 **Gadermayr M**, Kogler H, Karla M, Merhof D, Uhl A, Vécsei A. Computer-aided texture analysis combined with experts' knowledge: Improving endoscopic celiac disease diagnosis. *World J Gastroenterol* 2016; **22**: 7124-7134 [PMID: [27610022](#) DOI: [10.3748/wjg.v22.i31.7124](#)]
- 74 **Wimmer G**, Hegenbart S, Vecsei A, Uhl A. Convolutional Neural Network Architectures for the Automated Diagnosis of Celiac Disease. Presented at: International Workshop on Computer-Assisted and Robotic Endoscopy. CARE 2016; 104–113 [DOI: [10.1007/978-3-319-54057-3\\_10](#)]
- 75 **Zhou T**, Han G, Li BN, Lin Z, Ciaccio EJ, Green PH, Qin J. Quantitative analysis of patients with celiac disease by video capsule endoscopy: A deep learning method. *Comput Biol Med* 2017; **85**: 1-6 [PMID: [28412572](#) DOI: [10.1016/j.compbiomed.2017.03.031](#)]
- 76 **Wang X**, Qian H, Ciaccio EJ, Lewis SK, Bhagat G, Green PH, Xu S, Huang L, Gao R, Liu Y. Celiac disease diagnosis from videocapsule endoscopy images with residual learning and deep feature extraction. *Comput Methods Programs Biomed* 2020; **187**: 105236 [PMID: [31786452](#) DOI: [10.1016/j.cmpb.2019.105236](#)]
- 77 **Yogapriya J**, Chandran V, Sumithra MG, Anitha P, Jenopaul P, Suresh Gnana Dhas C. Gastrointestinal Tract Disease Classification from Wireless Endoscopy Images Using Pretrained Deep Learning Model. *Comput Math Methods Med* 2021; **2021**: 5940433 [PMID: [34545292](#) DOI: [10.1155/2021/5940433](#)]
- 78 **Charisis VS**, Hadjileontiadis LJ, Liatsos CN, Mavrogiannis CC, Sergiadis GD. Capsule endoscopy image analysis using texture information from various colour models. *Comput Methods Programs Biomed* 2012; **107**: 61-74 [PMID: [22056811](#) DOI: [10.1016/j.cmpb.2011.10.004](#)]
- 79 **Charisis VS**, Hadjileontiadis LJ. Potential of hybrid adaptive filtering in inflammatory lesion detection from capsule endoscopy images. *World J Gastroenterol* 2016; **22**: 8641-8657 [PMID: [27818583](#) DOI: [10.3748/wjg.v22.i39.8641](#)]
- 80 **Kumar R**, Zhao Q, Seshamani S, Mullin G, Hager G, Dassopoulos T. Assessment of Crohn's disease lesions in wireless capsule endoscopy images. *IEEE Trans Biomed Eng* 2012; **59**: 355-362 [PMID: [22020661](#) DOI: [10.1109/TBME.2011.2172438](#)]
- 81 **Wei Z**, Wang W, Bradfield J, Li J, Cardinale C, Frackelton E, Kim C, Mentch F, Van Steen K, Visscher PM, Baldassano RN, Hakonarson H; International IBD Genetics Consortium. Large sample size, wide variant spectrum, and advanced machine-learning technique boost risk prediction for inflammatory bowel disease. *Am J Hum Genet* 2013; **92**: 1008-1012 [PMID: [23731541](#) DOI: [10.1016/j.ajhg.2013.05.002](#)]
- 82 **Ferreira JPS**, de Mascarenhas Saraiva MJDQEC, Afonso JPL, Ribeiro TFC, Cardoso HMC, Ribeiro Andrade AP, de Mascarenhas Saraiva MNG, Parente MPL, Natal Jorge R, Lopes SIO, de Macedo GMG. Identification of Ulcers and Erosions by the Novel Pillcam™ Crohn's Capsule Using a Convolutional Neural Network: A Multicentre Pilot Study. *J Crohns Colitis* 2022; **16**: 169-172 [PMID: [34228113](#) DOI: [10.1093/ecco-jcc/jjab117](#)]
- 83 **Klang E**, Grinman A, Soffer S, Margalit Yehuda R, Barzilay O, Amitai MM, Konen E, Ben-Horin S, Eliakim R, Barash Y, Kopylov U. Automated Detection of Crohn's Disease Intestinal Strictures on Capsule Endoscopy Images Using Deep Neural Networks. *J Crohns Colitis* 2021; **15**: 749-756 [PMID: [33216853](#) DOI: [10.1093/ecco-jcc/jjaa234](#)]
- 84 **Wu X**, Chen H, Gan T, Chen J, Ngo CW, Peng Q. Automatic Hookworm Detection in Wireless Capsule Endoscopy Images. *IEEE Trans Med Imaging* 2016; **35**: 1741-1752 [PMID: [26886971](#) DOI: [10.1109/TMI.2016.2527736](#)]
- 85 **He JY**, Wu X, Jiang YG, Peng Q, Jain R. Hookworm Detection in Wireless Capsule Endoscopy Images With Deep Learning. *IEEE Trans Image Process* 2018; **27**: 2379-2392 [PMID: [29470172](#) DOI: [10.1109/TIP.2018.2801119](#)]
- 86 **Gan T**, Yang Y, Liu S, Zeng B, Yang J, Deng K, Wu J, Yang L. Automatic Detection of Small Intestinal Hookworms in Capsule Endoscopy Images Based on a Convolutional Neural Network. *Gastroenterol Res Pract* 2021; **2021**: 5682288 [PMID: [34868306](#) DOI: [10.1155/2021/5682288](#)]
- 87 **Sainju S**, Bui FM, Wahid KA. Automated bleeding detection in capsule endoscopy videos using statistical features and region growing. *J Med Syst* 2014; **38**: 25 [PMID: [24696394](#) DOI: [10.1007/s10916-014-0025-1](#)]
- 88 **Usman MA**, Satrya GB, Usman MR, Shin SY. Detection of small colon bleeding in wireless capsule endoscopy videos. *Comput Med Imaging Graph* 2016; **54**: 16-26 [PMID: [27793502](#) DOI: [10.1016/j.compmedimag.2016.09.005](#)]
- 89 **Ghosh T**, Chakareski J. Deep Transfer Learning for Automated Intestinal Bleeding Detection in Capsule Endoscopy Imaging. *J Digit Imaging* 2021; **34**: 404-417 [PMID: [33728563](#) DOI: [10.1007/s10278-021-00428-3](#)]
- 90 **Tsuboi A**, Oka S, Aoyama K, Saito H, Aoki T, Yamada A, Matsuda T, Fujishiro M, Ishihara S, Nakahori M, Koike K, Tanaka S, Tada T. Artificial intelligence using a convolutional neural network for automatic detection of small-bowel angioectasia in capsule endoscopy images. *Dig Endosc* 2020; **32**: 382-390 [PMID: [31392767](#) DOI: [10.1111/den.13507](#)]
- 91 **Ribeiro T**, Saraiva MM, Ferreira JPS, Cardoso H, Afonso J, Andrade P, Parente M, Jorge RN, Macedo G. Artificial intelligence and capsule endoscopy: automatic detection of vascular lesions using a convolutional neural network. *Ann Gastroenterol* 2021; **34**: 820-828 [PMID: [34815648](#) DOI: [10.20524/aog.2021.0653](#)]
- 92 **Afonso J**, Saraiva MM, Ferreira JPS, Cardoso H, Ribeiro T, Andrade P, Parente M, Jorge RN, Macedo G. Automated detection of ulcers and erosions in capsule endoscopy images using a convolutional neural network. *Med Biol Eng Comput* 2022; **60**: 719-725 [PMID: [35038118](#) DOI: [10.1007/s11517-021-02486-9](#)]
- 93 **Mascarenhas M**, Ribeiro T, Afonso J, Ferreira JPS, Cardoso H, Andrade P, Parente MPL, Jorge RN, Mascarenhas Saraiva M, Macedo G. Deep learning and colon capsule endoscopy: automatic detection of blood and colonic mucosal lesions using a convolutional neural network. *Endosc Int Open* 2022; **10**: E171-E177 [PMID: [35186665](#) DOI: [10.1055/a-1675-1941](#)]
- 94 **Lewis BS**, Eisen GM, Friedman S. A pooled analysis to evaluate results of capsule endoscopy trials. *Endoscopy* 2005; **37**: 960-965 [PMID: [16189768](#) DOI: [10.1055/s-2005-870353](#)]
- 95 **Li B**, Meng MQ. Tumor recognition in wireless capsule endoscopy images using textural features and SVM-based feature selection. *IEEE Trans Inf Technol Biomed* 2012; **16**: 323-329 [PMID: [22287246](#) DOI: [10.1109/TITB.2012.2185807](#)]
- 96 **Liu G**, Yan G, Kuang S, Wang Y. Detection of small bowel tumor based on multi-scale curvelet analysis and fractal technology in capsule endoscopy. *Comput Biol Med* 2016; **70**: 131-138 [PMID: [26829705](#) DOI: [10.1016/j.compbiomed.2016.01.021](#)]



- 97 **Faghih Dinevari V**, Karimian Khosroshahi G, Zolfy Lighvan M. Singular Value Decomposition Based Features for Automatic Tumor Detection in Wireless Capsule Endoscopy Images. *Appl Bionics Biomech* 2016; **2016**: 3678913 [PMID: 27478364 DOI: 10.1155/2016/3678913]
- 98 **Shanmuga Sundaram P**, Santhiyakumari N. An Enhancement of Computer Aided Approach for Colon Cancer Detection in WCE Images Using ROI Based Color Histogram and SVM2. *J Med Syst* 2019; **43**: 29 [PMID: 30612188 DOI: 10.1007/s10916-018-1153-9]
- 99 **Blanes-Vidal V**, Baatrup G, Nadimi ES. Addressing priority challenges in the detection and assessment of colorectal polyps from capsule endoscopy and colonoscopy in colorectal cancer screening using machine learning. *Acta Oncol* 2019; **58**: S29-S36 [PMID: 30836800 DOI: 10.1080/0284186X.2019.1584404]
- 100 **Saraiva MM**, Ferreira JPS, Cardoso H, Afonso J, Ribeiro T, Andrade P, Parente MPL, Jorge RN, Macedo G. Artificial intelligence and colon capsule endoscopy: development of an automated diagnostic system of protruding lesions in colon capsule endoscopy. *Tech Coloproctol* 2021; **25**: 1243-1248 [PMID: 34499277 DOI: 10.1007/s10151-021-02517-5]
- 101 **Mascarenhas M**, Afonso J, Ribeiro T, Cardoso H, Andrade P, Ferreira JPS, Saraiva MM, Macedo G. Performance of a Deep Learning System for Automatic Diagnosis of Protruding Lesions in Colon Capsule Endoscopy. *Diagnostics (Basel)* 2022; **12** [PMID: 35741255 DOI: 10.3390/diagnostics12061445]
- 102 **Constantinescu AF**, Ionescu M, Iovănescu VF, Ciurea ME, Ionescu AG, Streba CT, Bunesu MG, Rogoveanu I, Vere CC. A computer-aided diagnostic system for intestinal polyps identified by wireless capsule endoscopy. *Rom J Morphol Embryol* 2016; **57**: 979-984 [PMID: 28002513]
- 103 **Xia J**, Xia T, Pan J, Gao F, Wang S, Qian YY, Wang H, Zhao J, Jiang X, Zou WB, Wang YC, Zhou W, Li ZS, Liao Z. Use of artificial intelligence for detection of gastric lesions by magnetically controlled capsule endoscopy. *Gastrointest Endosc* 2021; **93**: 133-139.e4 [PMID: 32470426 DOI: 10.1016/j.gie.2020.05.027]
- 104 **Yuan Y**, Meng MQ. Deep learning for polyp recognition in wireless capsule endoscopy images. *Med Phys* 2017; **44**: 1379-1389 [PMID: 28160514 DOI: 10.1002/mp.12147]
- 105 **Sharma P**, Burke CA, Johnson DA, Cash BD. The importance of colonoscopy bowel preparation for the detection of colorectal lesions and colorectal cancer prevention. *Endosc Int Open* 2020; **8**: E673-E683 [PMID: 32355887 DOI: 10.1055/a-1127-3144]
- 106 **Ahmad OF**. Deep learning for automated bowel preparation assessment during colonoscopy: time to embrace a new approach? *Lancet Digit Health* 2021; **3**: e685-e686 [PMID: 34538737 DOI: 10.1016/S2589-7500(21)00143-6]
- 107 **Hassan C**, East J, Radaelli F, Spada C, Benamouzig R, Bisschops R, Bretthauer M, Dekker E, Dinis-Ribeiro M, Ferlitsch H, Fuccio L, Awadie H, Gralnek I, Jover R, Kaminski MF, Pellisé M, Triantafyllou K, Vanella G, Mangas-Sanjuan C, Frazzoni L, Van Hooft JE, Dumonceau JM. Bowel preparation for colonoscopy: European Society of Gastrointestinal Endoscopy (ESGE) Guideline - Update 2019. *Endoscopy* 2019; **51**: 775-794 [PMID: 31295746 DOI: 10.1055/a-0959-0505]
- 108 **Rex DK**, Boland CR, Dominitz JA, Giardiello FM, Johnson DA, Kaltenbach T, Levin TR, Lieberman D, Robertson DJ. Colorectal Cancer Screening: Recommendations for Physicians and Patients from the U.S. Multi-Society Task Force on Colorectal Cancer. *Am J Gastroenterol* 2017; **112**: 1016-1030 [PMID: 28555630 DOI: 10.1038/ajg.2017.174]
- 109 **ASGE Standards of Practice Committee**, Saltzman JR, Cash BD, Pasha SF, Early DS, Muthusamy VR, Khashab MA, Chathadi KV, Fanelli RD, Chandrasekhara V, Lightdale JR, Fonkalsrud L, Shergill AK, Hwang JH, Decker GA, Jue TL, Sharaf R, Fisher DA, Evans JA, Foley K, Shaikat A, Eloubeidi MA, Faulx AL, Wang A, Acosta RD. Bowel preparation before colonoscopy. *Gastrointest Endosc* 2015; **81**: 781-794 [PMID: 25595062 DOI: 10.1016/j.gie.2014.09.048]
- 110 **Hadlock SD**, Liu N, Bernstein M, Gould M, Rabeneck L, Ruco A, Sutradhar R, Tinmouth JM. The Quality of Colonoscopy Reporting in Usual Practice: Are Endoscopists Reporting Key Data Elements? *Can J Gastroenterol Hepatol* 2016; **2016**: 1929361 [PMID: 27579299 DOI: 10.1155/2016/1929361]
- 111 **Gavin DR**, Valori RM, Anderson JT, Donnelly MT, Williams JG, Swarbrick ET. The national colonoscopy audit: a nationwide assessment of the quality and safety of colonoscopy in the UK. *Gut* 2013; **62**: 242-249 [PMID: 22661458 DOI: 10.1136/gutjnl-2011-301848]
- 112 **Coe SG**, Panjala C, Heckman MG, Patel M, Qumseya BJ, Wang YR, Dalton B, Tran P, Palmer W, Diehl N, Wallace MB, Raimondo M. Quality in colonoscopy reporting: an assessment of compliance and performance improvement. *Dig Liver Dis* 2012; **44**: 660-664 [PMID: 22579446 DOI: 10.1016/j.dld.2012.03.022]
- 113 **Zhou J**, Wu L, Wan X, Shen L, Liu J, Zhang J, Jiang X, Wang Z, Yu S, Kang J, Li M, Hu S, Hu X, Gong D, Chen D, Yao L, Zhu Y, Yu H. A novel artificial intelligence system for the assessment of bowel preparation (with video). *Gastrointest Endosc* 2020; **91**: 428-435.e2 [PMID: 31783029 DOI: 10.1016/j.gie.2019.11.026]
- 114 **Zhou W**, Yao L, Wu H, Zheng B, Hu S, Zhang L, Li X, He C, Wang Z, Li Y, Huang C, Guo M, Zhang X, Zhu Q, Wu L, Deng Y, Zhang J, Tan W, Li C, Zhang C, Gong R, Du H, Zhou J, Sharma P, Yu H. Multi-step validation of a deep learning-based system for the quantification of bowel preparation: a prospective, observational study. *Lancet Digit Health* 2021; **3**: e697-e706 [PMID: 34538736 DOI: 10.1016/S2589-7500(21)00109-6]
- 115 **Lai EJ**, Calderwood AH, Doros G, Fix OK, Jacobson BC. The Boston bowel preparation scale: a valid and reliable instrument for colonoscopy-oriented research. *Gastrointest Endosc* 2009; **69**: 620-625 [PMID: 19136102 DOI: 10.1016/j.gie.2008.05.057]
- 116 **Lee JY**, Calderwood AH, Karnes W, Requa J, Jacobson BC, Wallace MB. Artificial intelligence for the assessment of bowel preparation. *Gastrointest Endosc* 2022; **95**: 512-518.e1 [PMID: 34896100 DOI: 10.1016/j.gie.2021.11.041]
- 117 **Low DJ**, Hong Z, Jugnundan S, Mukherjee A, Grover SC. Automated Detection of Bowel Preparation Scoring and Adequacy With Deep Convolutional Neural Networks. *JCAG* 2022; **XX**: 1-5 [DOI: 10.1093/jcag/gwac013]
- 118 **Wang YP**, Jheng YC, Sung KY, Lin HE, Hsin IF, Chen PH, Chu YC, Lu D, Wang YJ, Hou MC, Lee FY, Lu CL. Use of U-Net Convolutional Neural Networks for Automated Segmentation of Fecal Material for Objective Evaluation of Bowel Preparation Quality in Colonoscopy. *Diagnostics (Basel)* 2022; **12** [PMID: 35328166 DOI: 10.3390/diagnostics12030613]
- 119 **Kohli A**, Holzwanger EA, Levy AN. Emerging use of artificial intelligence in inflammatory bowel disease. *World J Gastroenterol* 2020; **26**: 6923-6928 [PMID: 33311940 DOI: 10.3748/wjg.v26.i44.6923]
- 120 **Cohen-Mekelburg S**, Berry S, Stidham RW, Zhu J, Waljee AK. Clinical applications of artificial intelligence and



- machine learning-based methods in inflammatory bowel disease. *J Gastroenterol Hepatol* 2021; **36**: 279-285 [PMID: 33624888 DOI: 10.1111/jgh.15405]
- 221 **Ozawa T**, Ishihara S, Fujishiro M, Saito H, Kumagai Y, Shichijo S, Aoyama K, Tada T. Novel computer-assisted diagnosis system for endoscopic disease activity in patients with ulcerative colitis. *Gastrointest Endosc* 2019; **89**: 416-421.e1 [PMID: 30367878 DOI: 10.1016/j.gie.2018.10.020]
  - 222 **Stidham RW**, Liu W, Bishu S, Rice MD, Higgins PDR, Zhu J, Nallamotheu BK, Waljee AK. Performance of a Deep Learning Model vs Human Reviewers in Grading Endoscopic Disease Severity of Patients With Ulcerative Colitis. *JAMA Netw Open* 2019; **2**: e193963 [PMID: 31099869 DOI: 10.1001/jamanetworkopen.2019.3963]
  - 223 **Dave M**, Loftus EV Jr. Mucosal healing in inflammatory bowel disease-a true paradigm of success? *Gastroenterol Hepatol (N Y)* 2012; **8**: 29-38 [PMID: 22347830]
  - 224 **Huang TY**, Zhan SQ, Chen PJ, Yang CW, Lu HH. Accurate diagnosis of endoscopic mucosal healing in ulcerative colitis using deep learning and machine learning. *J Chin Med Assoc* 2021; **84**: 678-681 [PMID: 34050105 DOI: 10.1097/JCMA.0000000000000559]
  - 225 **Barreiro-de Acosta M**, Vallejo N, de la Iglesia D, Uribarri L, Bastón I, Ferreiro-Iglesias R, Lorenzo A, Domínguez-Muñoz JE. Evaluation of the Risk of Relapse in Ulcerative Colitis According to the Degree of Mucosal Healing (Mayo 0 vs 1): A Longitudinal Cohort Study. *J Crohns Colitis* 2016; **10**: 13-19 [PMID: 26351390 DOI: 10.1093/ecco-jcc/jjv158]
  - 226 **Osterman MT**, Scott FI, Fogt FF, Gilroy ED, Parrott S, Galanko J, Cross R, Moss A, Herfarth HH, Higgins PDR. Endoscopic and Histological Assessment, Correlation, and Relapse in Clinically Quiescent Ulcerative Colitis (MARQUEE). *Inflamm Bowel Dis* 2021; **27**: 207-214 [PMID: 32170946 DOI: 10.1093/ibd/izaa048]
  - 227 **Bhambhani HP**, Zamora A. Deep learning enabled classification of Mayo endoscopic subscore in patients with ulcerative colitis. *Eur J Gastroenterol Hepatol* 2021; **33**: 645-649 [PMID: 33079775 DOI: 10.1097/MEG.0000000000001952]
  - 228 **Yao H**, Najarian K, Gryak J, Bishu S, Rice MD, Waljee AK, Wilkins HJ, Stidham RW. Fully automated endoscopic disease activity assessment in ulcerative colitis. *Gastrointest Endosc* 2021; **93**: 728-736.e1 [PMID: 32810479 DOI: 10.1016/j.gie.2020.08.011]
  - 229 **Gottlieb K**, Requa J, Karnes W, Chandra Gudivada R, Shen J, Rael E, Arora V, Dao T, Ninh A, McGill J. Central Reading of Ulcerative Colitis Clinical Trial Videos Using Neural Networks. *Gastroenterology* 2021; **160**: 710-719.e2 [PMID: 33098883 DOI: 10.1053/j.gastro.2020.10.024]
  - 230 **Gutierrez Becker B**, Arcadu F, Thalhammer A, Gamez Serna C, Feehan O, Drawnel F, Oh YS, Prunotto M. Training and applying a deep learning model for endoscopic severity grading in ulcerative colitis using multicenter clinical trial data. *Ther Adv Gastrointest Endosc* 2021; **14**: 2631774521990623 [PMID: 33718871 DOI: 10.1177/2631774521990623]
  - 231 **Maeda Y**, Kudo SE, Mori Y, Misawa M, Ogata N, Sasanuma S, Wakamura K, Oda M, Mori K, Ohtsuka K. Fully automated diagnostic system with artificial intelligence using endocytoscopy to identify the presence of histologic inflammation associated with ulcerative colitis (with video). *Gastrointest Endosc* 2019; **89**: 408-415 [PMID: 30268542 DOI: 10.1016/j.gie.2018.09.024]
  - 232 **Takenaka K**, Ohtsuka K, Fujii T, Negi M, Suzuki K, Shimizu H, Oshima S, Akiyama S, Motobayashi M, Nagahori M, Saito E, Matsuoka K, Watanabe M. Development and Validation of a Deep Neural Network for Accurate Evaluation of Endoscopic Images From Patients With Ulcerative Colitis. *Gastroenterology* 2020; **158**: 2150-2157 [PMID: 32060000 DOI: 10.1053/j.gastro.2020.02.012]
  - 233 **Takenaka K**, Ohtsuka K, Fujii T, Oshima S, Okamoto R, Watanabe M. Deep Neural Network Accurately Predicts Prognosis of Ulcerative Colitis Using Endoscopic Images. *Gastroenterology* 2021; **160**: 2175-2177.e3 [PMID: 33485853 DOI: 10.1053/j.gastro.2021.01.210]
  - 234 **Takenaka K**, Fujii T, Kawamoto A, Suzuki K, Shimizu H, Maeyashiki C, Yamaji O, Motobayashi M, Igarashi A, Hanazawa R, Hibiya S, Nagahori M, Saito E, Okamoto R, Ohtsuka K, Watanabe M. Deep neural network for video colonoscopy of ulcerative colitis: a cross-sectional study. *Lancet Gastroenterol Hepatol* 2022; **7**: 230-237 [PMID: 34856196 DOI: 10.1016/S2468-1253(21)00372-1]
  - 235 **Udrisoiu AL**, Stefanescu D, Gruionu G, Gruionu LG, Iacob AV, Karstensen JG, Vilman P, Saftoiu A. Deep Learning Algorithm for the Confirmation of Mucosal Healing in Crohn's Disease, Based on Confocal Laser Endomicroscopy Images. *J Gastrointest Liver Dis* 2021; **30**: 59-65 [PMID: 33723558 DOI: 10.15403/jgld-3212]
  - 236 **Xi Y**, Xu P. Global colorectal cancer burden in 2020 and projections to 2040. *Transl Oncol* 2021; **14**: 101174 [PMID: 34243011 DOI: 10.1016/j.tranon.2021.101174]
  - 237 **Roselló S**, Simón S, Cervantes A. Programmed colorectal cancer screening decreases incidence and mortality. *Transl Gastroenterol Hepatol* 2019; **4**: 84 [PMID: 32039289 DOI: 10.21037/tgh.2019.12.13]
  - 238 **Ahn SB**, Han DS, Bae JH, Byun TJ, Kim JP, Eun CS. The Miss Rate for Colorectal Adenoma Determined by Quality-Adjusted, Back-to-Back Colonoscopies. *Gut Liver* 2012; **6**: 64-70 [PMID: 22375173 DOI: 10.5009/gnl.2012.6.1.64]
  - 239 **Komeda Y**, Handa H, Watanabe T, Nomura T, Kitahashi M, Sakurai T, Okamoto A, Minami T, Kono M, Arizumi T, Takenaka M, Hagiwara S, Matsui S, Nishida N, Kashida H, Kudo M. Computer-Aided Diagnosis Based on Convolutional Neural Network System for Colorectal Polyp Classification: Preliminary Experience. *Oncology* 2017; **93** Suppl 1: 30-34 [PMID: 29258081 DOI: 10.1159/000481227]
  - 240 **Misawa M**, Kudo SE, Mori Y, Cho T, Kataoka S, Yamauchi A, Ogawa Y, Maeda Y, Takeda K, Ichimasa K, Nakamura H, Yagawa Y, Toyoshima N, Ogata N, Kudo T, Hisayuki T, Hayashi T, Wakamura K, Baba T, Ishida F, Itoh H, Roth H, Oda M, Mori K. Artificial Intelligence-Assisted Polyp Detection for Colonoscopy: Initial Experience. *Gastroenterology* 2018; **154**: 2027-2029.e3 [PMID: 29653147 DOI: 10.1053/j.gastro.2018.04.003]
  - 241 **Hassan C**, Wallace MB, Sharma P, Maselli R, Craviotto V, Spadaccini M, Repici A. New artificial intelligence system: first validation study versus experienced endoscopists for colorectal polyp detection. *Gut* 2020; **69**: 799-800 [PMID: 31615835 DOI: 10.1136/gutjnl-2019-319914]
  - 242 **Guo Z**, Nemoto D, Zhu X, Li Q, Aizawa M, Utano K, Isohata N, Endo S, Kawarai Lefor A, Togashi K. Polyp detection algorithm can detect small polyps: Ex vivo reading test compared with endoscopists. *Dig Endosc* 2021; **33**: 162-169 [PMID: 32173917 DOI: 10.1111/den.13670]



- 143 **Neumann H**, Kreft A, Sivanathan V, Rahman F, Galle PR. Evaluation of novel LCI CAD EYE system for real time detection of colon polyps. *PLoS One* 2021; **16**: e0255955 [PMID: [34437563](#) DOI: [10.1371/journal.pone.0255955](#)]
- 144 **Li JW**, Chia T, Fock KM, Chong KW, Wong YJ, Ang TL. Artificial intelligence and polyp detection in colonoscopy: Use of a single neural network to achieve rapid polyp localization for clinical use. *J Gastroenterol Hepatol* 2021; **36**: 3298-3307 [PMID: [34327729](#) DOI: [10.1111/jgh.15642](#)]
- 145 **Ahmad OF**, González-Bueno Puyal J, Brandao P, Kader R, Abbasi F, Hussein M, Haidry RJ, Toth D, Mountney P, Seward E, Vega R, Stoyanov D, Lovat LB. Performance of artificial intelligence for detection of subtle and advanced colorectal neoplasia. *Dig Endosc* 2022; **34**: 862-869 [PMID: [34748665](#) DOI: [10.1111/den.14187](#)]
- 146 **Hori K**, Ikematsu H, Yamamoto Y, Matsuzaki H, Takeshita N, Shinmura K, Yoda Y, Kiuchi T, Takemoto S, Yokota H, Yano T. Detecting colon polyps in endoscopic images using artificial intelligence constructed with automated collection of annotated images from an endoscopy reporting system. *Dig Endosc* 2022; **34**: 1021-1029 [PMID: [34748658](#) DOI: [10.1111/den.14185](#)]
- 147 **Brand M**, Troya J, Krenzer A, Saßmannshausen Z, Zoller WG, Meining A, Lux TJ, Hann A. Development and evaluation of a deep learning model to improve the usability of polyp detection systems during interventions. *United European Gastroenterol J* 2022; **10**: 477-484 [PMID: [35511456](#) DOI: [10.1002/ueg2.12235](#)]
- 148 **Lux TJ**, Banck M, Saßmannshausen Z, Troya J, Krenzer A, Fitting D, Sudarevic B, Zoller WG, Puppe F, Meining A, Hann A. Pilot study of a new freely available computer-aided polyp detection system in clinical practice. *Int J Colorectal Dis* 2022; **37**: 1349-1354 [PMID: [35543874](#) DOI: [10.1007/s00384-022-04178-8](#)]
- 149 **Wang P**, Xiao X, Glissen Brown JR, Berzin TM, Tu M, Xiong F, Hu X, Liu P, Song Y, Zhang D, Yang X, Li L, He J, Yi X, Liu J, Liu X. Development and validation of a deep-learning algorithm for the detection of polyps during colonoscopy. *Nat Biomed Eng* 2018; **2**: 741-748 [PMID: [31015647](#) DOI: [10.1038/s41551-018-0301-3](#)]
- 150 **Shen P**, Li WZ, Li JX, Pei ZC, Luo YX, Mu JB, Li W, Wang XM. Real-time use of a computer-aided system for polyp detection during colonoscopy, an ambispective study. *J Dig Dis* 2021; **22**: 256-262 [PMID: [33742774](#) DOI: [10.1111/1751-2980.12985](#)]
- 151 **Livovsky DM**, Veikherman D, Golany T, Aides A, Dashinsky V, Rabani N, Ben Shimol D, Blau Y, Katzir L, Shimshoni I, Liu Y, Segol O, Goldin E, Corrado G, Lachter J, Matias Y, Rivlin E, Freedman D. Detection of elusive polyps using a large-scale artificial intelligence system (with videos). *Gastrointest Endosc* 2021; **94**: 1099-1109.e10 [PMID: [34216598](#) DOI: [10.1016/j.gie.2021.06.021](#)]
- 152 **Pacal I**, Karaman A, Karaboga D, Akay B, Basturk A, Nalbantoglu U, Coskun S. An efficient real-time colonic polyp detection with YOLO algorithms trained by using negative samples and large datasets. *Comput Biol Med* 2022; **141**: 105031 [PMID: [34802713](#) DOI: [10.1016/j.compbiomed.2021.105031](#)]
- 153 **Quan SY**, Wei MT, Lee J, Mohi-Ud-Din R, Mostaghim R, Sachdev R, Siegel D, Friedlander Y, Friedland S. Clinical evaluation of a real-time artificial intelligence-based polyp detection system: a US multi-center pilot study. *Sci Rep* 2022; **12**: 6598 [PMID: [35449442](#) DOI: [10.1038/s41598-022-10597-y](#)]
- 154 **Horiuchi H**, Tamai N, Kamba S, Inomata H, Ohya TR, Sumiyama K. Real-time computer-aided diagnosis of diminutive rectosigmoid polyps using an auto-fluorescence imaging system and novel color intensity analysis software. *Scand J Gastroenterol* 2019; **54**: 800-805 [PMID: [31195905](#) DOI: [10.1080/00365521.2019.1627407](#)]
- 155 **Becq A**, Chandnani M, Bharadwaj S, Baran B, Ernest-Suarez K, Gabr M, Glissen-Brown J, Sawhney M, Pleskow DK, Berzin TM. Effectiveness of a Deep-learning Polyp Detection System in Prospectively Collected Colonoscopy Videos With Variable Bowel Preparation Quality. *J Clin Gastroenterol* 2020; **54**: 554-557 [PMID: [31789758](#) DOI: [10.1097/MCG.0000000000001272](#)]
- 156 **Wang P**, Liu P, Glissen Brown JR, Berzin TM, Zhou G, Lei S, Liu X, Li L, Xiao X. Lower Adenoma Miss Rate of Computer-Aided Detection-Assisted Colonoscopy vs Routine White-Light Colonoscopy in a Prospective Tandem Study. *Gastroenterology* 2020; **159**: 1252-1261.e5 [PMID: [32562721](#) DOI: [10.1053/j.gastro.2020.06.023](#)]
- 157 **Shaukat A**, Colucci D, Erisson L, Phillips S, Ng J, Iglesias JE, Saltzman JR, Somers S, Brugge W. Improvement in adenoma detection using a novel artificial intelligence-aided polyp detection device. *Endosc Int Open* 2021; **9**: E263-E270 [PMID: [33553591](#) DOI: [10.1055/a-1321-1317](#)]
- 158 **Pfeifer L**, Neufert C, Leppkes M, Waldner MJ, Häfner M, Beyer A, Hoffman A, Siersema PD, Neurath MF, Rath T. Computer-aided detection of colorectal polyps using a newly generated deep convolutional neural network: from development to first clinical experience. *Eur J Gastroenterol Hepatol* 2021; **33**: e662-e669 [PMID: [34034272](#) DOI: [10.1097/MEG.0000000000002209](#)]
- 159 **Ishiyama M**, Kudo SE, Misawa M, Mori Y, Maeda Y, Ichimasa K, Kudo T, Hayashi T, Wakamura K, Miyachi H, Ishida F, Itoh H, Oda M, Mori K. Impact of the clinical use of artificial intelligence-assisted neoplasia detection for colonoscopy: a large-scale prospective, propensity score-matched study (with video). *Gastrointest Endosc* 2022; **95**: 155-163 [PMID: [34352255](#) DOI: [10.1016/j.gie.2021.07.022](#)]
- 160 **Zippelius C**, Alqahtani SA, Schedel J, Brookman-Amissah D, Muehlenberg K, Federle C, Salzberger A, Schorr W, Pech O. Diagnostic accuracy of a novel artificial intelligence system for adenoma detection in daily practice: a prospective nonrandomized comparative study. *Endoscopy* 2022; **54**: 465-472 [PMID: [34293812](#) DOI: [10.1055/a-1556-5984](#)]
- 161 **Wu L**, Zhang J, Zhou W, An P, Shen L, Liu J, Jiang X, Huang X, Mu G, Wan X, Lv X, Gao J, Cui N, Hu S, Chen Y, Hu X, Li J, Chen D, Gong D, He X, Ding Q, Zhu X, Li S, Wei X, Li X, Wang X, Zhou J, Zhang M, Yu HG. Randomised controlled trial of WISENSE, a real-time quality improving system for monitoring blind spots during esophagogastroduodenoscopy. *Gut* 2019; **68**: 2161-2169 [PMID: [30858305](#) DOI: [10.1136/gutjnl-2018-317366](#)]
- 162 **Shaukat A**, Lichtenstein DR, Somers SC, Chung DC, Perdue DG, Gopal M, Colucci DR, Phillips SA, Marka NA, Church TR, Brugge WR; SKOUT™ Registration Study Team. Computer-Aided Detection Improves Adenomas per Colonoscopy for Screening and Surveillance Colonoscopy: A Randomized Trial. *Gastroenterology* 2022; **163**: 732-741 [PMID: [35643173](#) DOI: [10.1053/j.gastro.2022.05.028](#)]
- 163 **Glissen Brown JR**, Mansour NM, Wang P, Chuchuca MA, Minchenberg SB, Chandnani M, Liu L, Gross SA, Sengupta N, Berzin TM. Deep Learning Computer-aided Polyp Detection Reduces Adenoma Miss Rate: A United States Multi-center Randomized Tandem Colonoscopy Study (CADEt-CS Trial). *Clin Gastroenterol Hepatol* 2022; **20**: 1499-1507.e4



- [PMID: 34530161 DOI: 10.1016/j.cgh.2021.09.009]
- 164 **Kamba S**, Tamai N, Saitoh I, Matsui H, Horiuchi H, Kobayashi M, Sakamoto T, Ego M, Fukuda A, Tonouchi A, Shimahara Y, Nishikawa M, Nishino H, Saito Y, Sumiyama K. Reducing adenoma miss rate of colonoscopy assisted by artificial intelligence: a multicenter randomized controlled trial. *J Gastroenterol* 2021; **56**: 746-757 [PMID: 34218329 DOI: 10.1007/s00535-021-01808-w]
  - 165 **Repici A**, Spadaccini M, Antonelli G, Correale L, Maselli R, Galtieri PA, Pellegatta G, Capogreco A, Milluzzo SM, Lollo G, Di Paolo D, Badalamenti M, Ferrara E, Fugazza A, Carrara S, Anderloni A, Rondonotti E, Amato A, De Gottardi A, Spada C, Radaelli F, Savevski V, Wallace MB, Sharma P, Rösch T, Hassan C. Artificial intelligence and colonoscopy experience: lessons from two randomised trials. *Gut* 2022; **71**: 757-765 [PMID: 34187845 DOI: 10.1136/gutjnl-2021-324471]
  - 166 **Gong D**, Wu L, Zhang J, Mu G, Shen L, Liu J, Wang Z, Zhou W, An P, Huang X, Jiang X, Li Y, Wan X, Hu S, Chen Y, Hu X, Xu Y, Zhu X, Li S, Yao L, He X, Chen D, Huang L, Wei X, Wang X, Yu H. Detection of colorectal adenomas with a real-time computer-aided system (ENDOANGEL): a randomised controlled study. *Lancet Gastroenterol Hepatol* 2020; **5**: 352-361 [PMID: 31981518 DOI: 10.1016/S2468-1253(19)30413-3]
  - 167 **Wang P**, Liu X, Berzin TM, Glissen Brown JR, Liu P, Zhou C, Lei L, Li L, Guo Z, Lei S, Xiong F, Wang H, Song Y, Pan Y, Zhou G. Effect of a deep-learning computer-aided detection system on adenoma detection during colonoscopy (CADE-DB trial): a double-blind randomised study. *Lancet Gastroenterol Hepatol* 2020; **5**: 343-351 [PMID: 31981517 DOI: 10.1016/S2468-1253(19)30411-X]
  - 168 **Wang P**, Berzin TM, Glissen Brown JR, Bharadwaj S, Becq A, Xiao X, Liu P, Li L, Song Y, Zhang D, Li Y, Xu G, Tu M, Liu X. Real-time automatic detection system increases colonoscopic polyp and adenoma detection rates: a prospective randomised controlled study. *Gut* 2019; **68**: 1813-1819 [PMID: 30814121 DOI: 10.1136/gutjnl-2018-317500]
  - 169 **Su JR**, Li Z, Shao XJ, Ji CR, Ji R, Zhou RC, Li GC, Liu GQ, He YS, Zuo XL, Li YQ. Impact of a real-time automatic quality control system on colorectal polyp and adenoma detection: a prospective randomized controlled study (with videos). *Gastrointest Endosc* 2020; **91**: 415-424.e4 [PMID: 31454493 DOI: 10.1016/j.gie.2019.08.026]
  - 170 **Repici A**, Badalamenti M, Maselli R, Correale L, Radaelli F, Rondonotti E, Ferrara E, Spadaccini M, Alkandari A, Fugazza A, Anderloni A, Galtieri PA, Pellegatta G, Carrara S, Di Leo M, Craviotto V, Lamonaca L, Lorenzetti R, Andrealli A, Antonelli G, Wallace M, Sharma P, Rosch T, Hassan C. Efficacy of Real-Time Computer-Aided Detection of Colorectal Neoplasia in a Randomized Trial. *Gastroenterology* 2020; **159**: 512-520.e7 [PMID: 32371116 DOI: 10.1053/j.gastro.2020.04.062]
  - 171 **Liu P**, Wang P, Glissen Brown JR, Berzin TM, Zhou G, Liu W, Xiao X, Chen Z, Zhang Z, Zhou C, Lei L, Xiong F, Li L, Liu X. The single-monitor trial: an embedded CADE system increased adenoma detection during colonoscopy: a prospective randomized study. *Therap Adv Gastroenterol* 2020; **13**: 1756284820979165 [PMID: 33403003 DOI: 10.1177/1756284820979165]
  - 172 **Xu L**, He X, Zhou J, Zhang J, Mao X, Ye G, Chen Q, Xu F, Sang J, Wang J, Ding Y, Li Y, Yu C. Artificial intelligence-assisted colonoscopy: A prospective, multicenter, randomized controlled trial of polyp detection. *Cancer Med* 2021; **10**: 7184-7193 [PMID: 34477306 DOI: 10.1002/cam4.4261]
  - 173 **Liu WN**, Zhang YY, Bian XQ, Wang LJ, Yang Q, Zhang XD, Huang J. Study on detection rate of polyps and adenomas in artificial-intelligence-aided colonoscopy. *Saudi J Gastroenterol* 2020; **26**: 13-19 [PMID: 31898644 DOI: 10.4103/sjg.SJG\_377\_19]
  - 174 **Luo Y**, Zhang Y, Liu M, Lai Y, Liu P, Wang Z, Xing T, Huang Y, Li Y, Li A, Wang Y, Luo X, Liu S, Han Z. Artificial Intelligence-Assisted Colonoscopy for Detection of Colon Polyps: a Prospective, Randomized Cohort Study. *J Gastrointest Surg* 2021; **25**: 2011-2018 [PMID: 32968933 DOI: 10.1007/s11605-020-04802-4]
  - 175 **Barua I**, Vinsard DG, Jodal HC, Løberg M, Kalager M, Holme Ø, Misawa M, Bretthauer M, Mori Y. Artificial intelligence for polyp detection during colonoscopy: a systematic review and meta-analysis. *Endoscopy* 2021; **53**: 277-284 [PMID: 32557490 DOI: 10.1055/a-1201-7165]
  - 176 **Aziz M**, Fatima R, Dong C, Lee-Smith W, Nawras A. The impact of deep convolutional neural network-based artificial intelligence on colonoscopy outcomes: A systematic review with meta-analysis. *J Gastroenterol Hepatol* 2020; **35**: 1676-1683 [PMID: 32267558 DOI: 10.1111/jgh.15070]
  - 177 **Hassan C**, Spadaccini M, Iannone A, Maselli R, Jovani M, Chandrasekar VT, Antonelli G, Yu H, Areia M, Dinis-Ribeiro M, Bhandari P, Sharma P, Rex DK, Rösch T, Wallace M, Repici A. Performance of artificial intelligence in colonoscopy for adenoma and polyp detection: a systematic review and meta-analysis. *Gastrointest Endosc* 2021; **93**: 77-85.e6 [PMID: 32598963 DOI: 10.1016/j.gie.2020.06.059]
  - 178 **Li J**, Lu J, Yan J, Tan Y, Liu D. Artificial intelligence can increase the detection rate of colorectal polyps and adenomas: a systematic review and meta-analysis. *Eur J Gastroenterol Hepatol* 2021; **33**: 1041-1048 [PMID: 32804846 DOI: 10.1097/MEG.0000000000001906]
  - 179 **Zhang Y**, Zhang X, Wu Q, Gu C, Wang Z. Artificial Intelligence-Aided Colonoscopy for Polyp Detection: A Systematic Review and Meta-Analysis of Randomized Clinical Trials. *J Laparoendosc Adv Surg Tech A* 2021; **31**: 1143-1149 [PMID: 33524298 DOI: 10.1089/lap.2020.0777]
  - 180 **Deliwala SS**, Hamid K, Barbarawi M, Lakshman H, Zayed Y, Kandel P, Malladi S, Singh A, Bachuwa G, Gurvits GE, Chawla S. Artificial intelligence (AI) real-time detection vs. routine colonoscopy for colorectal neoplasia: a meta-analysis and trial sequential analysis. *Int J Colorectal Dis* 2021; **36**: 2291-2303 [PMID: 33934173 DOI: 10.1007/s00384-021-03929-3]
  - 181 **Nazarian S**, Glover B, Ashrafian H, Darzi A, Teare J. Diagnostic Accuracy of Artificial Intelligence and Computer-Aided Diagnosis for the Detection and Characterization of Colorectal Polyps: Systematic Review and Meta-analysis. *J Med Internet Res* 2021; **23**: e27370 [PMID: 34259645 DOI: 10.2196/27370]
  - 182 **Xu Y**, Ding W, Wang Y, Tan Y, Xi C, Ye N, Wu D, Xu X. Comparison of diagnostic performance between convolutional neural networks and human endoscopists for diagnosis of colorectal polyp: A systematic review and meta-analysis. *PLoS One* 2021; **16**: e0246892 [PMID: 33592048 DOI: 10.1371/journal.pone.0246892]
  - 183 **Bang CS**, Lee JJ, Baik GH. Computer-Aided Diagnosis of Diminutive Colorectal Polyps in Endoscopic Images:



- Systematic Review and Meta-analysis of Diagnostic Test Accuracy. *J Med Internet Res* 2021; **23**: e29682 [PMID: 34432643 DOI: 10.2196/29682]
- 184 **Yoon D**, Kong HJ, Kim BS, Cho WS, Lee JC, Cho M, Lim MH, Yang SY, Lim SH, Lee J, Song JH, Chung GE, Choi JM, Kang HY, Bae JH, Kim S. Colonoscopic image synthesis with generative adversarial network for enhanced detection of sessile serrated lesions using convolutional neural network. *Sci Rep* 2022; **12**: 261 [PMID: 34997124 DOI: 10.1038/s41598-021-04247-y]
  - 185 **Nemoto D**, Guo Z, Peng B, Zhang R, Nakajima Y, Hayashi Y, Yamashina T, Aizawa M, Utano K, Lefor AK, Zhu X, Togashi K. Computer-aided diagnosis of serrated colorectal lesions using non-magnified white-light endoscopic images. *Int J Colorectal Dis* 2022; **37**: 1875-1884 [PMID: 35861862 DOI: 10.1007/s00384-022-04210-x]
  - 186 **Yao L**, Zhang J, Liu J, Zhu L, Ding X, Chen D, Wu H, Lu Z, Zhou W, Zhang L, Xu B, Hu S, Zheng B, Yang Y, Yu H. A deep learning-based system for bile duct annotation and station recognition in linear endoscopic ultrasound. *EBioMedicine* 2021; **65**: 103238 [PMID: 33639404 DOI: 10.1016/j.ebiom.2021.103238]
  - 187 **Săftoiu A**, Vilman P, Gorunescu F, Janssen J, Hocke M, Larsen M, Iglesias-Garcia J, Arcidiacono P, Will U, Giovannini M, Dietrich CF, Havre R, Gheorghe C, McKay C, Gheonea DI, Ciurea T; European EUS Elastography Multicentric Study Group. Efficacy of an artificial neural network-based approach to endoscopic ultrasound elastography in diagnosis of focal pancreatic masses. *Clin Gastroenterol Hepatol* 2012; **10**: 84-90.e1 [PMID: 21963957 DOI: 10.1016/j.cgh.2011.09.014]
  - 188 **Kuwahara T**, Hara K, Mizuno N, Okuno N, Matsumoto S, Obata M, Kurita Y, Koda H, Toriyama K, Onishi S, Ishihara M, Tanaka T, Tajika M, Niwa Y. Usefulness of Deep Learning Analysis for the Diagnosis of Malignancy in Intraductal Papillary Mucinous Neoplasms of the Pancreas. *Clin Transl Gastroenterol* 2019; **10**: 1-8 [PMID: 31117111 DOI: 10.14309/ctg.0000000000000045]
  - 189 **Goyal H**, Sherazi SAA, Gupta S, Perisetti A, Achebe I, Ali A, Tharian B, Thosani N, Sharma NR. Application of artificial intelligence in diagnosis of pancreatic malignancies by endoscopic ultrasound: a systemic review. *Therap Adv Gastroenterol* 2022; **15**: 17562848221093873 [PMID: 35509425 DOI: 10.1177/17562848221093873]
  - 190 **Dumitrescu EA**, Ungureanu BS, Cazacu IM, Florescu LM, Streba L, Croitoru VM, Sur D, Croitoru A, Turcu-Stiolica A, Lungulescu CV. Diagnostic Value of Artificial Intelligence-Assisted Endoscopic Ultrasound for Pancreatic Cancer: A Systematic Review and Meta-Analysis. *Diagnostics (Basel)* 2022; **12** [PMID: 35204400 DOI: 10.3390/diagnostics12020309]
  - 191 **Minoda Y**, Ihara E, Komori K, Ogino H, Otsuka Y, Chinen T, Tsuda Y, Ando K, Yamamoto H, Ogawa Y. Efficacy of endoscopic ultrasound with artificial intelligence for the diagnosis of gastrointestinal stromal tumors. *J Gastroenterol* 2020; **55**: 1119-1126 [PMID: 32918102 DOI: 10.1007/s00535-020-01725-4]
  - 192 **Jang SI**, Kim YJ, Kim EJ, Kang H, Shon SJ, Seol YJ, Lee DK, Kim KG, Cho JH. Diagnostic performance of endoscopic ultrasound-artificial intelligence using deep learning analysis of gallbladder polypoid lesions. *J Gastroenterol Hepatol* 2021; **36**: 3548-3555 [PMID: 34431545 DOI: 10.1111/jgh.15673]
  - 193 **Zhang B**, Zhu F, Li P, Zhu J. Artificial intelligence-assisted endoscopic ultrasound in the diagnosis of gastrointestinal stromal tumors: a meta-analysis. *Surg Endosc* 2022 [PMID: 36100781 DOI: 10.1007/s00464-022-09597-w]
  - 194 **Ye XH**, Zhao LL, Wang L. Diagnostic accuracy of endoscopic ultrasound with artificial intelligence for gastrointestinal stromal tumors: A meta-analysis. *J Dig Dis* 2022; **23**: 253-261 [PMID: 35793389 DOI: 10.1111/1751-2980.13110]
  - 195 **Marya NB**, Powers PD, Petersen BT, Law R, Storm A, Abusaleh RR, Rau P, Stead C, Levy MJ, Martin J, Vargas EJ, Abu Dayyeh BK, Chandrasekhara V. Identification of patients with malignant biliary strictures using a cholangioscopy-based deep learning artificial intelligence (with video). *Gastrointest Endosc* 2022 [PMID: 36007584 DOI: 10.1016/j.gie.2022.08.021]
  - 196 **Huang L**, Lu X, Huang X, Zou X, Wu L, Zhou Z, Wu D, Tang D, Chen D, Wan X, Zhu Z, Deng T, Shen L, Liu J, Zhu Y, Gong D, Zhong Y, Liu F, Yu H. Intelligent difficulty scoring and assistance system for endoscopic extraction of common bile duct stones based on deep learning: multicenter study. *Endoscopy* 2021; **53**: 491-498 [PMID: 32838430 DOI: 10.1055/a-1244-5698]
  - 197 **Uche-Anyia E**, Anyane-Yeboa A, Berzin TM, Ghassemi M, May FP. Artificial intelligence in gastroenterology and hepatology: how to advance clinical practice while ensuring health equity. *Gut* 2022; **71**: 1909-1915 [PMID: 35688612 DOI: 10.1136/gutjnl-2021-326271]
  - 198 **Stidham RW**. Artificial Intelligence for Understanding Imaging, Text, and Data in Gastroenterology. *Gastroenterol Hepatol (N Y)* 2020; **16**: 341-349 [PMID: 34035738]
  - 199 **Spadaccini M**, Marco A, Franchellucci G, Sharma P, Hassan C, Repici A. Discovering the first US FDA-approved computer-aided polyp detection system. *Future Oncol* 2022; **18**: 1405-1412 [PMID: 35081745 DOI: 10.2217/fon-2021-1135]





Published by **Baishideng Publishing Group Inc**  
7041 Koll Center Parkway, Suite 160, Pleasanton, CA 94566, USA

**Telephone:** +1-925-3991568

**E-mail:** [bpgoffice@wjgnet.com](mailto:bpgoffice@wjgnet.com)

**Help Desk:** <https://www.f6publishing.com/helpdesk>

<https://www.wjgnet.com>

