

World Journal of *Clinical Cases*

World J Clin Cases 2023 March 6; 11(7): 1434-1668



Contents

Thrice Monthly Volume 11 Number 7 March 6, 2023

OPINION REVIEW

- 1434 Reconstruction surgery in head and neck cancer patients amidst the COVID-19 pandemic: Current practice and lessons for the future

Lizambri D, Giacalone A, Shah PA, Tovani-Palone MR

REVIEW

- 1442 Risk factors and digital interventions for anxiety disorders in college students: Stakeholder perspectives

Liu XQ, Guo YX, Xu Y

MINIREVIEWS

- 1458 Immune-related adverse events induced by programmed death protein-1 inhibitors from the perspective of lymphoma immunotherapy

Hou YZ, Zhang Q, Bai H, Wu T, Chen YJ

ORIGINAL ARTICLE

Clinical and Translational Research

- 1467 Analysis of differentially expressed genes related to cerebral ischaemia in young rats based on the Gene Expression Omnibus database

Xia Y, Liu H, Zhu R

Retrospective Study

- 1477 Deep learning-assisted diagnosis of femoral trochlear dysplasia based on magnetic resonance imaging measurements

Xu SM, Dong D, Li W, Bai T, Zhu MZ, Gu GS

- 1488 Facial basal cell carcinoma: A retrospective study of 67 cases

Khalil AA, Enezei HH, Aldelaimi TN, Al-Ani RM

CASE REPORT

- 1498 Successful multidisciplinary therapy for a patient with liver metastasis from ascending colon adenocarcinoma: A case report and review of literature

Tan XR, Li J, Chen HW, Luo W, Jiang N, Wang ZB, Wang S

- 1506 Accessory renal arteries - a source of hypertension: A case report

Calinoiu A, Guluta EC, Rusu A, Minca A, Minca D, Tomescu L, Gheorghita V, Minca DG, Negreanu L

- 1513 Synchronous multiple primary malignant neoplasms in breast, kidney, and bilateral thyroid: A case report

Jia MM, Yang B, Ding C, Yao YR, Guo J, Yang HB

- 1521** Invasive breast carcinoma with osteoclast-like stromal giant cells: A case report
Wang YJ, Huang CP, Hong ZJ, Liao GS, Yu JC
- 1528** Retroperitoneal and abdominal bleeding in anticoagulated COVID-19 hospitalized patients: Case series and brief literature review
Evrev D, Sekulovski M, Gulinac M, Dobrev H, Velikova T, Hadjidekov G
- 1549** Hyperthyroidism and severe bradycardia: Report of three cases and review of the literature
He YL, Xu WX, Fang TY, Zeng M
- 1560** Isolated cerebral mucormycosis that looks like stroke and brain abscess: A case report and review of the literature
Chen CH, Chen JN, Du HG, Guo DL
- 1569** Gastric ectopic pancreas combined with synchronous multiple early gastric cancer: A rare case report
Zhao ZY, Lai YX, Xu P
- 1576** Manifestation of the malignant progression of glioma following initial intracerebral hemorrhage: A case report
Xu EX, Lu SY, Chen B, Ma XD, Sun EY
- 1586** Four kinds of antibody positive paraneoplastic limbic encephalitis: A rare case report
Huang P, Xu M
- 1593** Spontaneous fracture of a titanium mesh cranioplasty implant in a child: A case report
Zhang R, Gao Z, Zhu YJ, Wang XF, Wang G, He JP
- 1600** Rheumatic valvular heart disease treated with traditional Chinese medicine: A case report
Chen WH, Tan Y, Wang YL, Wang X, Liu ZH
- 1607** Mucosa-associated lymphoid tissue lymphoma of the trachea treated with radiotherapy: A case report
Zhen CJ, Zhang P, Bai WW, Song YZ, Liang JL, Qiao XY, Zhou ZG
- 1615** Bow-and-arrow sign on point-of-care ultrasound for diagnosis of pacemaker lead-induced heart perforation: A case report and literature review
Chen N, Miao GX, Peng LQ, Li YH, Gu J, He Y, Chen T, Fu XY, Xing ZX
- 1627** Prostate lymphoma with renal obstruction; reflections on diagnosis and treatment: Two case reports
Chen TF, Lin WL, Liu WY, Gu CM
- 1634** Pulmonary nocardiosis with bloodstream infection diagnosed by metagenomic next-generation sequencing in a kidney transplant recipient: A case report
Deng ZF, Tang YJ, Yan CY, Qin ZQ, Yu N, Zhong XB
- 1642** Primary yolk sac tumor in the abdominal wall in a 20-year-old woman: A case report
Wang Y, Yang J

- 1650** Misdiagnosis of food-borne foreign bodies outside of the digestive tract on magnetic resonance imaging: Two case reports

Ji D, Lu JD, Zhang ZG, Mao XP

- 1656** IgG4-related kidney disease complicated with retroperitoneal fibrosis: A case report

He PH, Liu LC, Zhou XF, Xu JJ, Hong WH, Wang LC, Liu SJ, Zeng JH

LETTER TO THE EDITOR

- 1666** Commentary on a case report and literature review of acute carotid stent thrombosis

Willman M, Lucke-Wold B

ABOUT COVER

Editorial Board Member of *World Journal of Clinical Cases*, Baharudin Ibrahim, BPharm, PhD, Associate Professor, Pharmacist, Department of Clinical Pharmacy and Pharmacy Practice, Faculty of Pharmacy, Universiti Malaya, Kuala Lumpur 50603, Malaysia. baharudin.ibrahim@um.edu.my

AIMS AND SCOPE

The primary aim of *World Journal of Clinical Cases* (WJCC, *World J Clin Cases*) is to provide scholars and readers from various fields of clinical medicine with a platform to publish high-quality clinical research articles and communicate their research findings online.

WJCC mainly publishes articles reporting research results and findings obtained in the field of clinical medicine and covering a wide range of topics, including case control studies, retrospective cohort studies, retrospective studies, clinical trials studies, observational studies, prospective studies, randomized controlled trials, randomized clinical trials, systematic reviews, meta-analysis, and case reports.

INDEXING/ABSTRACTING

The WJCC is now abstracted and indexed in Science Citation Index Expanded (SCIE, also known as SciSearch®), Journal Citation Reports/Science Edition, Current Contents®/Clinical Medicine, PubMed, PubMed Central, Scopus, Reference Citation Analysis, China National Knowledge Infrastructure, China Science and Technology Journal Database, and Superstar Journals Database. The 2022 Edition of Journal Citation Reports® cites the 2021 impact factor (IF) for WJCC as 1.534; IF without journal self cites: 1.491; 5-year IF: 1.599; Journal Citation Indicator: 0.28; Ranking: 135 among 172 journals in medicine, general and internal; and Quartile category: Q4. The WJCC's CiteScore for 2021 is 1.2 and Scopus CiteScore rank 2021: General Medicine is 443/826.

RESPONSIBLE EDITORS FOR THIS ISSUE

Production Editor: Si Zhao; Production Department Director: Xiang Li; Editorial Office Director: Jin-Lei Wang.

NAME OF JOURNAL

World Journal of Clinical Cases

ISSN

ISSN 2307-8960 (online)

LAUNCH DATE

April 16, 2013

FREQUENCY

Thrice Monthly

EDITORS-IN-CHIEF

Bao-Gan Peng, Jerzy Tadeusz Chudek, George Kontogeorgos, Maurizio Serati, Ja Hyeon Ku

EDITORIAL BOARD MEMBERS

<https://www.wjgnet.com/2307-8960/editorialboard.htm>

PUBLICATION DATE

March 6, 2023

COPYRIGHT

© 2023 Baishideng Publishing Group Inc

INSTRUCTIONS TO AUTHORS

<https://www.wjgnet.com/bpg/gerinfo/204>

GUIDELINES FOR ETHICS DOCUMENTS

<https://www.wjgnet.com/bpg/GerInfo/287>

GUIDELINES FOR NON-NATIVE SPEAKERS OF ENGLISH

<https://www.wjgnet.com/bpg/gerinfo/240>

PUBLICATION ETHICS

<https://www.wjgnet.com/bpg/GerInfo/288>

PUBLICATION MISCONDUCT

<https://www.wjgnet.com/bpg/gerinfo/208>

ARTICLE PROCESSING CHARGE

<https://www.wjgnet.com/bpg/gerinfo/242>

STEPS FOR SUBMITTING MANUSCRIPTS

<https://www.wjgnet.com/bpg/GerInfo/239>

ONLINE SUBMISSION

<https://www.f6publishing.com>

Hyperthyroidism and severe bradycardia: Report of three cases and review of the literature

Yang-Li He, Wen-Xing Xu, Tuan-Yu Fang, Min Zeng

Specialty type: Endocrinology and metabolism

Provenance and peer review: Unsolicited article; Externally peer reviewed.

Peer-review model: Single blind

Peer-review report's scientific quality classification

Grade A (Excellent): A
Grade B (Very good): 0
Grade C (Good): 0
Grade D (Fair): D
Grade E (Poor): 0

P-Reviewer: Junior JMA, Brazil;
Ong H, Malaysia

Received: October 19, 2022

Peer-review started: October 19, 2022

First decision: December 26, 2022

Revised: January 13, 2023

Accepted: February 15, 2023

Article in press: February 15, 2023

Published online: March 6, 2023



Yang-Li He, Wen-Xing Xu, Min Zeng, Center of Geriatrics, Hainan General Hospital, Haikou 570311, Hainan Province, China

Yang-Li He, Wen-Xing Xu, Min Zeng, Hainan Clinical Research Center for Cardiovascular Disease, Hainan General Hospital, Haikou 570311, Hainan Province, China

Yang-Li He, Min Zeng, Center of Geriatrics, Hainan Affiliated Hospital of Hainan Medical University, Haikou 570311, Hainan Province, China

Tuan-Yu Fang, Department of Endocrine, Hainan General Hospital, Haikou 570311, Hainan Province, China

Corresponding author: Min Zeng, PhD, Chief Doctor, Professor, Center of Geriatrics, Hainan General Hospital, No. 19 Xiuhua Road, Haikou 570311, Hainan Province, China. hndzm6@126.com

Abstract

BACKGROUND

Hyperthyroidism often leads to tachycardia, but there are also sporadic reports of hyperthyroidism with severe bradycardia, such as sick sinus syndrome (SSS) and atrioventricular block. These disorders are a challenge for clinicians.

CASE SUMMARY

We describe three cases of hyperthyroidism with SSS and found 31 similar cases in a PubMed literature search. Through the analysis of these 34 cases, we found 21 cases of atrioventricular block and 13 cases of SSS, with 67.6% of the patients experiencing bradycardia symptoms. After drug treatment, temporary pacemaker implantation, or anti-hyperthyroidism treatment, the bradycardia of 27 patients (79.4%) was relieved, and the median recovery time was 5.5 (2-8) d. Only 7 cases (20.6%) needed permanent pacemaker implantation.

CONCLUSION

Patients with hyperthyroidism should be aware of the risk of severe bradycardia. In most cases, drug treatment or temporary pacemaker placement is recommended for initial treatment. If the bradycardia does not improve after 1 wk, a permanent pacemaker should be implanted.

Key Words: Hyperthyroidism; Bradycardia; Sick sinus syndrome; Atrioventricular block; Pacemaker; Case report

Core Tip: Severe bradycardia, such as sick sinus syndrome and atrioventricular block, can occasionally be encountered in patients with hyperthyroidism. These pose a challenge for physicians. We report three cases of hyperthyroidism with severe bradycardia and identified an additional 31 cases indexed in PubMed. We found that hyperthyroidism with severe bradycardia may require 1 wk of observation before deciding whether to implant a permanent pacemaker. The use of drugs (*e.g.*, atropine, isoproterenol, and/or anti-hyperthyroidism treatment), implantation of temporary pacemakers, and correcting the electrolyte disorder are recommended before permanent pacemaker implantation.

Citation: He YL, Xu WX, Fang TY, Zeng M. Hyperthyroidism and severe bradycardia: Report of three cases and review of the literature. *World J Clin Cases* 2023; 11(7): 1549-1559

URL: <https://www.wjgnet.com/2307-8960/full/v11/i7/1549.htm>

DOI: <https://dx.doi.org/10.12998/wjcc.v11.i7.1549>

INTRODUCTION

Hyperthyroidism refers to a group of clinical syndromes characterized by increased excitability and hypermetabolism of the nervous, circulatory, and digestive systems caused by excessive serum thyroid hormone levels[1]. Hyperthyroidism is a common disease. In the United States, the prevalence is estimated to be 1.20%[2]. In China, the prevalence of overt hyperthyroidism is 0.78% and that of subclinical hyperthyroidism is 0.44%[3].

Hyperthyroidism affects the heart in the following ways[4,5]: (1) It increases the sensitivity of heart β -receptors to catecholamine; (2) it directly acts on myocardial contractile protein and enhances the positive inotropic effect of the myocardium; and (3) it leads to the expansion of peripheral blood vessels, an increase in the resistance of peripheral blood vessels, and a subsequent compensatory increase in cardiac output. Therefore, patients with hyperthyroidism often develop tachycardia (such as sinus tachycardia and rapid atrial fibrillation). However, severe bradycardia, such as sick sinus syndrome (SSS) and atrioventricular block, are occasionally encountered in patients with hyperthyroidism, which pose a challenge for physicians.

It is unclear whether anti-hyperthyroidism treatment will reduce the patient's heart rate. Hyperthyroidism is also known to induce rapid atrial fibrillation, but the treatment of rapid atrial fibrillation along with bradycardia is also unclear. Specifically, it is unknown whether patients with hyperthyroidism and bradycardia need permanent pacemakers and when such pacemakers should be placed. In the present report, we share our experience with three patients with hyperthyroidism combined with severe bradycardia who were treated at our hospital since 2019. We also review similar cases published in PubMed and summarize the features and treatment strategies. These findings will be useful for the diagnosis and treatment of hyperthyroidism with severe bradycardia in the future.

CASE 1

Chief complaints

A 63-year-old woman suffered from hunger and weight loss for 15 years. Her condition worsened and was accompanied by palpitations and syncope in the 4 mo prior to presentation.

History of present illness

In 2004, the patient was diagnosed with hyperthyroidism based on frequent hunger and weight loss and was prescribed medication for hyperthyroidism (information about the treatment was not available). She adhered to the drug regimen for more than 1 year, but she later discontinued the treatment and started self-treatment with Chinese herbal medicines (the drugs are unknown). She experienced some symptom relief from the alternative treatment. However, since December 2018, her symptoms reappeared, and she repeatedly experienced palpitations and syncope.

History of past illness

The patient had no previous medical history.

Personal and family history

The patient was a housewife and denied any relevant family history.

Physical examination

On physical examination, the patient's blood pressure was 143/71 mmHg. Slight protrusion of the eyeballs (bilateral) was observed, and the thyroid gland showed degree II swelling and moved with swallowing. The heart rate was 99 beats/min and regular, and no noise was heard during auscultation. Her hands trembled slightly.

Laboratory examinations

Triiodothyronine (TT3) level was 5.39 nmol/L (normal range: 0.88-2.44 nmol/L). Thyroxine (TT4) was > 308.88 nmol/L (normal range: 62.68-150.80 nmol/L). Free triiodothyronine (FT3) was > 46.08 pmol/L (normal range: 2.63-5.70 pmol/L). Free thyroxine (FT4) was 58.59 pmol/L (normal range: 9.01-19.05 pmol/L). Thyroid-stimulating hormone (TSH) was < 0.0025 mIU/L (normal range: 0.35-4.94 mIU/L). Thyrotrophin receptor antibody (TRAb) was 39.56 U/L (normal level, \leq 1.75 U/L). Thyroid peroxidase antibody (TPOAb) was 69.52 IU/L (normal level, < 5.61 IU/L). Blood potassium, troponin, brain natriuretic peptide, routine blood parameters, transaminase, and creatinine levels were normal.

Imaging examinations

Echocardiography showed no abnormality. Continuous electrocardiogram (ECG) monitoring showed paroxysmal atrial fibrillation that was automatically converted into a sinus rhythm. During rhythm conversion, sinus arrest for 4 s was observed.

Final diagnosis

The patient was diagnosed as hyperthyroidism and SSS.

Treatment

The day after hospitalization, the patient experienced palpitations. Her heart rate was 130-140 beats/min and irregular. ECG revealed atrial fibrillation. She was intravenously administered with 0.2 mg of cedilanide. After 4 h, the patient felt her heart stop beating, and this was accompanied by dizziness and fatigue. Her blood pressure was 140/80 mmHg, and she had arrhythmia, with her heart rate fluctuating between 50 beats/min and 160 beats/min. She was transferred to the cardiology intensive care unit.

Continuous ECG monitoring showed that her heart rate fluctuated between 70 beats/min and 180 beats/min, and it was accompanied by paroxysmal atrial fibrillation that was automatically converted into a sinus rhythm. During rhythm conversion, sinus arrest for 4 s occurred, and the patient had syncope again. A temporary pacemaker was implanted.

She was diagnosed with hyperthyroidism and was treated with propylthiouracil (100 mg tid). She was also given metoprolol (25 mg bid) for paroxysmal rapid atrial fibrillation.

After 10 d of observation, a second laboratory examination showed that her thyroid hormone levels were normal (TT3 = 2.86 nmol/L, TT4 = 129.76 nmol/L, FT3 = 5.81 pmol/L, FT4 = 7.87 pmol/L, and TSH = 0.02 mIU/L). However, rapid atrial fibrillation, sinus rhythm, and pacing rhythm still occurred alternately according to the findings of ECG monitoring. A permanent dual-chamber pacemaker was implanted, and she continued treatment with propylthiouracil (300 mg/d) and metoprolol sustained-release tablets (95 mg/d).

Outcome and follow-up

No syncope occurred during the 2-year follow-up.

CASE 2**Chief complaints**

A 76-year-old woman suffered from repeated episodes of palpitations and syncope for more than 6 mo.

History of present illness

Since March 2019, the patient had been experiencing repeated episodes of dizziness, palpitations, and syncope. In August 2019, she was diagnosed with SSS at a local hospital, and a temporary pacemaker was implanted. After 1 wk, her symptoms improved and the temporary pacemaker was removed. However, 3 d prior to admission to our hospital, she experienced syncope again.

History of past illness

The patient was diagnosed with hyperthyroidism in 1999 and was treated with methimazole. She had a history of hypertension for more than 7 years and was treated with amlodipine. However, she did not

monitor it regularly.

Personal and family history

The patient was previously employed and retired 18 years prior. She denied any relevant family history.

Physical examination

On physical examination, the patient's blood pressure was 178/80 mmHg. Her heart rate was 84 beats/min. Auscultation revealed regular and normal sounds. No goiter, exophthalmos, or tremor of the hands was observed.

Laboratory examinations

TT3 level was 1.35 nmol/L (normal range: 0.88-2.44 nmol/L). TT4 was 107.75 nmol/L (normal range: 62.68-150.80 nmol/L). FT3 was 3.38 pmol/L (normal range: 2.63-5.70 pmol/L). FT4 was 14.32 pmol/L (normal range: 9.01-19.05 pmol/L). TSH was < 0.0025 mIU/L (normal range: 0.35-4.94 mIU/L). TRAb was 9.18 IU/L (normal level \leq 1.75 IU/L). TPOAb was 899.86 IU/L (normal level: < 5.61 IU/L).

Imaging examinations

Cardiac ultrasound showed local calcification and mild regurgitation in the posterior mitral valve, as well as mild regurgitation of the tricuspid valve and aortic valve. Holter ECG revealed sinus arrest, and the longest RR interval was 3.77 s.

Final diagnosis

The patient was diagnosed as SSS and subclinical hyperthyroidism.

Treatment

A permanent pacemaker was implanted, and treatment with methimazole (10 mg/d) was continued.

Outcome and follow-up

No dizziness or syncope occurred after implantation of the pacemaker during the 2-year follow-up.

CASE 3

Chief complaints

A 60-year-old man was admitted because he had been experiencing palpitations for 6 mo and dizziness for 2 mo.

History of present illness

The patient reported that he had started experiencing repeated episodes of palpitations and chest tightness in the past 6 mo. ECG showed paroxysmal atrial fibrillation, and he was treated with metoprolol (25 mg bid) intermittently. Two months prior to presentation, the patient had recurrent dizziness accompanied by amaurosis that resolved spontaneously within a few seconds. The patient had discontinued metoprolol 1 mo prior. However, repeated episodes of dizziness and palpitations occurred. Since the onset of the disease, his body weight had decreased by 10 kg.

History of past illness

The patient had a history of hypertension for more than 1 year, but he did not take any medicine.

Personal and family history

The patient had just retired from administrative work and denied any relevant family history.

Physical examination

At the time of admission to our hospital, his blood pressure was 150/80 mmHg. The heart rate was 55 beats/min, and regular sounds were heard during auscultation. His hands trembled slightly, but no goiter or exophthalmos was observed.

Laboratory examinations

TT3 Level was 4.12 nmol/L (normal range: 0.88-2.44 nmol/L). TT4 was 208.65 nmol/L (normal range: 62.68-150.80 nmol/L). FT3 was 15.34 pmol/L (normal range: 2.63-5.70 pmol/L). FT4 was 29.00 pmol/L (normal range: 9.01-19.05 pmol/L). TSH was < 0.0025 mIU/L (normal range: 0.35-4.94 mIU/L). TRAb was 9.28 IU/L (normal level: \leq 1.75 IU/L). TPOAb was 4.02 IU/L (normal level: < 5.61 IU/L).

Imaging examinations

Cardiac ultrasound showed mild regurgitation of the tricuspid valve, mitral valve, and aortic valve and mild pulmonary hypertension (estimated pulmonary artery systolic pressure, 40 mmHg). Twelve-lead ECG taken at admission indicated sinus bradycardia with a heart rate of 55 beats/min. However, Holter ECG indicated atrial fibrillation, and the fastest heart rate was 200 beats/min, accompanied by sinus arrest (Figure 1). Sinus arrest for more than 3 s was observed 16 times, and the longest arrest time was 8.1 s.

Final diagnosis

The patient was diagnosed as Hyperthyroidism and SSS.

Treatment

A permanent dual-chamber pacemaker was implanted, and treatment with methimazole (10 mg bid) was started.

Outcome and follow-up

The patient recovered well and did not have any episodes of syncope during the 1-year follow-up.

DISCUSSION

We searched PubMed for similar cases. The search query was (hyperthyroidism OR hyperthyroid OR Graves OR Basedow) AND (bradycardia OR sick sinus syndrome OR atrioventricular block). This search retrieved 31 similar cases. With the three cases that we report here, we analyze 34 cases in total.

The features of all 34 cases are summarized in Table 1. The age of the patients ranged from 10 to 76 years. In 22 cases, the patients were less than 60 years of age, and in 12 cases, the patients were ≥ 60 years. With regard to sex distribution, 24 (70.6%) patients were female, and 10 (29.4%) were male. It appeared that hyperthyroidism combined with bradycardia was more likely to occur in patients under 60 years of age and in females. Among the 34 patients, 21 (61.8%) had atrioventricular block and 13 (38.2%) had SSS.

Table 2 summarizes the clinical presentation. Except for two cases not mentioned, five cases (14.7%) were hospitalized for bradycardia first, and hyperthyroidism was detected after a clinical workup. Nine cases (26.4%) had hyperthyroidism and bradycardia simultaneously. Eighteen cases (52.9%) were diagnosed with hyperthyroidism first, and bradycardia was found during hyperthyroidism treatment. These data showed that bradycardia may be either the first symptom of hyperthyroidism or may appear at any stage during the hyperthyroidism treatment. In 8 of 34 patients, β -receptor blocker or digitalis was used to control tachycardia caused by hyperthyroidism before bradycardia was detected. In terms of symptoms, 67.6% had symptoms related to bradycardia. The most common bradycardia symptom was syncope. Other symptoms of bradycardia were fatigue, palpitations, and dizziness. For the accompanying conditions, two patients had fever, two had hypokalemia, and one had acute renal insufficiency with hyperkalemia.

Table 3 shows the treatment and outcome of the 34 cases. In 11 cases (32.3%), bradycardia was treated with atropine, isoproterenol, or glucocorticoid. In 11 cases (32.3%), the patients were implanted with a temporary pacemaker. Most of the patients were given anti-hyperthyroidism treatment at the same time. Twenty-seven patients (79.4%) recovered or their condition significantly improved through treatment of their accompanying conditions (such as fever and electrolyte disorder) or implantation of a temporary pacemaker and hyperthyroidism treatment. The recovery time of bradycardia was reported in 16 cases. The median recovery time was 5.5 (2-8) d. Permanent pacemakers were implanted in 7 cases (20.6%), and the majority (85.7%) occurred in elderly patients.

The exact mechanism of hyperthyroidism combined with bradycardia is unclear. Studies on the possible causes are primarily focused on the direct impact of hyperthyroidism on the conduction system [31], inflammation [32,33], and hypokalemia [22,25,29]. The molecular mechanism may involve the effect of T3 on phospholamban/sarco(endo)plasma reticulum Ca ATPase type 2A (SERCA2a). The regulation of Ca^{2+} is closely related to phospholamban and SERCA2a. SERCA2a is a Ca^{2+} enzyme that transfers Ca^{2+} from the cytoplasm of cells to the sarcoplasmic reticulum [34]. When SERCA2a activity decreases and the intracellular Ca^{2+} level increases, the pacing activity of the sinoatrial node is inhibited. This results in bradycardia [35]. Phospholamban is an allosteric inhibitor of the SERCA2a pump that reduces the affinity of the SERCA2a pump for Ca^{2+} [36]. However, the expression of phospholamban can be inhibited by T3 [37,38]. Therefore, during the treatment of hyperthyroidism, even a slight decrease in T3 Levels may affect phospholamban/SERCA2a and lead to bradycardia [39]. This may partly explain why some patients developed bradycardia after treatment for hyperthyroidism.

β -receptor blockers are also commonly used in the treatment of hyperthyroidism. However, only seven cases were treated with β -receptor blockers before bradycardia occurred (Table 2). It is possible that β -receptor blockers are involved in the occurrence of bradycardia, but they may not be the main

Table 1 Features of 34 cases of hyperthyroidism and severe bradycardia

Number	Reference	Year	Age in yr	Sex	Bradycardia type
1	[6]	1970	22	F	Complete AVB
2	[7]	1980	55	F	2 nd degree AVB
3	[8]	1985	55	F	Complete AVB
4	[9]	1985	54	F	Complete AVB
5	[10]	1990	29	M	Complete AVB
6	[11]	1998	16	F	Complete AVB
7	[12]	2001	60	F	Complete AVB
8	[12]	2001	30	F	Complete AVB
9	[13]	2005	50	M	Complete AVB
10	[13]	2005	68	F	Complete AVB
11	[14]	2006	67	M	Complete AVB
12	[15]	2007	40	M	Complete AVB
13	[16]	2008	59	M	Complete AVB
14	[17]	2009	28	F	Complete AVB
15	[18]	2011	55	F	Complete AVB
16	[19]	2012	37	F	Complete AVB
17	[20]	2012	71	F	2 nd degree AVB
18	[21]	2014	75	F	2 nd degree AVB
19	[22]	2015	30	M	2 nd degree AVB
20	[23]	2017	10	F	2 nd degree AVB
21	[24]	2020	28	F	Complete AVB
22	[25]	1972	21	F	SSS
23	[25]	1972	26	M	SSS
24	[25]	1972	63	F	SSS
25	[26]	1990	65	F	SSS
26	[27]	1995	50	F	SSS
27	[28]	1999	22	M	SSS
28	[29]	2006	36	M	SSS
29	[30]	2017	48	F	SSS
30	[30]	2017	63	F	SSS
31	[30]	2017	66	F	SSS
32	This report	2019	63	F	SSS
33	This report	2019	76	F	SSS
34	This report	2020	60	M	SSS

AVB: Atrioventricular block; F: Female, M: Male; SSS: Sick sinus syndrome.

cause of bradycardia.

As there are only a few reported cases of hyperthyroidism combined with severe bradycardia, large-scale evidence-based research on the disease course and treatment is difficult. In the clinical setting, it is unclear for physicians whether a patient should receive a permanent pacemaker and when a permanent pacemaker should ideally be implanted. Unfortunately, the findings from the cases reported so far are still inconsistent.

Table 2 Clinical presentation of 34 cases of hyperthyroidism and severe bradycardia

Number	Symptoms of bradycardia	Sequence of occurrence of hyperthyroidism and bradycardia	Use of anti-arrhythmic drugs before onset of bradycardia	Accompanying conditions
1	-	Hyperthyroidism first	-	-
2	Syncope	Hyperthyroidism first	Propranolol	-
3	Syncope	Hyperthyroidism first	Digoxin and propranolol	-
4	Syncope	Hyperthyroidism first	-	-
5	-	-	-	Fever
6	-	-	-	Fever
7	Syncope	Hyperthyroidism first	-	-
8	Presyncope	Simultaneous	-	-
9	Syncope	Hyperthyroidism first	Propranolol	-
10	-	Bradycardia first	-	-
11	Near syncope	Bradycardia first	Carvedilol	-
12	Syncope	Bradycardia first	-	-
13	-	Simultaneous	-	Jaundice and febrile, creatinine 250 $\mu\text{mol/L}$
14	Syncope	Hyperthyroidism first	-	-
15	Syncope	Hyperthyroidism first	-	-
16	Syncope	Hyperthyroidism first	-	-
17	Syncope	Simultaneous	-	-
18	-	Simultaneous	-	-
19	-	Hyperthyroidism first	-	-
20	Dizziness	Hyperthyroidism first	Atenolol	-
21	Syncope	Bradycardia first	-	-
22	Syncope	Hyperthyroidism first	-	-
23	-	Simultaneous	-	Periodic paralysis
24	Syncope	Hyperthyroidism first	-	-
25	Syncope	Hyperthyroidism first	Propranolol, diltiazem	-
26	Fatigue	Bradycardia first	-	-
27	-	Simultaneous	-	-
28	Syncope	Simultaneous	-	Blood potassium 2.3 mmol/L
29	Palpitation	Hyperthyroidism first	Metoprolol	-
30	-	Simultaneous	-	-
31	-	Hyperthyroidism first	-	-
32	Syncope	Hyperthyroidism first	Cedilanide	-
33	Syncope	Hyperthyroidism first	-	-
34	Syncope	Simultaneous	-	-

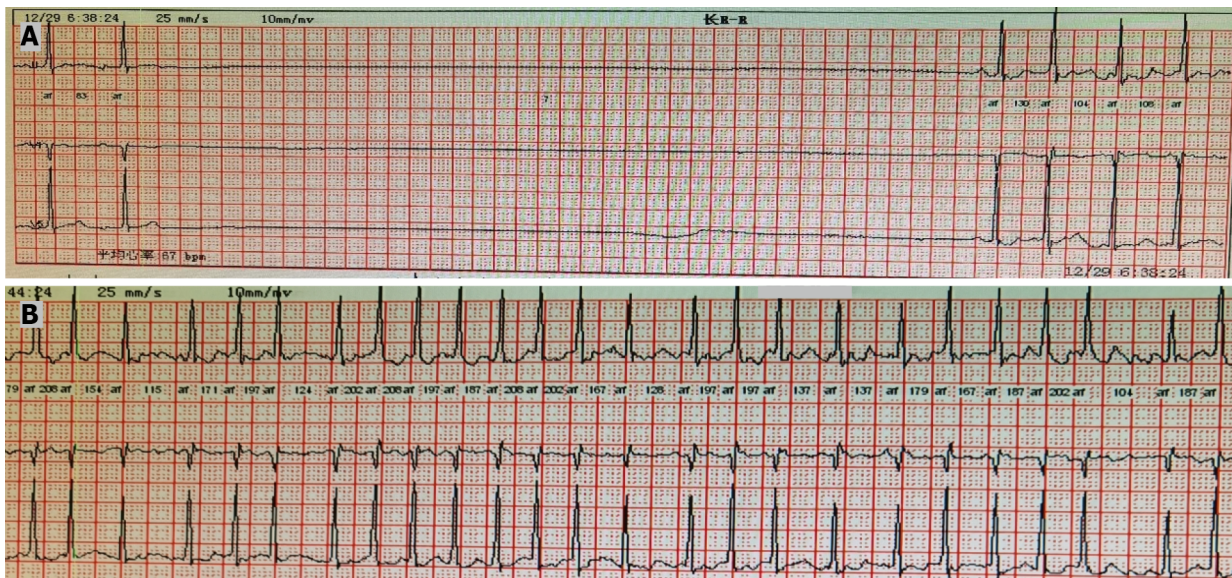
-. No or information not available.

Most scholars believe that pacemaker implantation to treat severe bradycardia combined with hyperthyroidism should be delayed as much as possible. The need for a permanent pacemaker should be determined only after thyroid function stabilizes[7]. However, Ozcan *et al*[40] reported a series of 21 patients with hyperthyroidism (including subclinical hyperthyroidism) complicated with atrioventricular block. After hyperthyroidism treatment and follow-up, only three cases (14%) of

Table 3 Treatment and outcome of 34 cases of hyperthyroidism and severe bradycardia

Number	Hyperthyroidism treatment	Bradycardia drug treatment	Temporary pacemaker	ECG changes after treatment ¹	Bradycardia recovery time in d	Permanent pacemaker
1	Propylthiouracil	Isoproterenol, atropine, prednisone,	Yes	1 st degree AVB	7	No
2	Methimazole	Atropine	Yes	1 st degree AVB	8	No
3	Propylthiouracil, iodine-131	Atropine, isoprenaline	No	Returned to normal	-	No
4	Methimazole	Prednisolone	Yes	Returned to normal	1	No
5	-	-	-	Returned to normal	-	-
6	Carbimazole, intravenous iodide a	Dexamethasone	No	Returned to normal	-	No
7	Methimazole	-	No	No recovery	No recovery	Yes
8	-	Prednisone	No	No recovery	No recovery	Yes
9	Propylthiouracil	-	No	1 st degree AVB	-	No
10	Propylthiouracil	-	No	Returned to normal	-	No
11	Methimazole	Atropine	Yes	No recovery	No recovery	Yes
12	Propylthiouracil	-	No	Returned to normal	3	No
13	Carbimazole	-	Yes	Returned to normal	21	No
14	Propylthiouracil	-	No	Returned to normal	8	No
15	Propylthiouracil, subtotal thyroidectomy	-	No	Returned to normal	7	No
16	Propylthiouracil	Steroid	No	1 st degree AVB	7	No
17	Radioactive iodine	-	No	Returned to normal	-	No
18	-	-	No	Returned to normal	-	No
19	-	-	No	Returned to normal	2	No
20	Carbimazole	-	No	1 st degree AVB	2	No
21	Propylthiouracil	-	Yes	Normal	8	No
22	Carbimazole	Atropine	Yes	Sinus bradycardia	2	No
23	-	-	No	Returned to normal	-	No
24	Carbimazole	Atropine	Yes	Returned to normal	4	No
25	Propylthiouracil and potassium iodine	-	No	Returned to normal	10	No
26	Methylmercaptoimidazole	Atropine	Yes	Returned to normal	2	No
27	Subtotal thyroidectomy	-	No	Returned to normal	-	No
28	Carbimazole	-	No	Returned to normal	2	No
29	Methimazole, surgical treatment	-	No	Returned to normal	-	No
30	Methimazole	-	No	No recovery	No recovery	Yes
31	Methimazole	-	No	Arrhythmias were fewer and shorter	-	No
32	Propylthiouracil	-	Yes	No recovery	No recovery	Yes
33	Methimazole	-	Yes	No recovery	No recovery	Yes
34	Propylthiouracil	-	No	/	/	Yes

¹Treatment included drugs or temporary pacemaker. -: Information not available; /: Did not occur. AVB: Atrioventricular block; ECG: Electrocardiogram.



DOI: 10.12998/wjcc.v11.i7.1549 Copyright ©The Author(s) 2023.

Figure 1 Holter electrocardiogram. A: Holter electrocardiogram (ECG) showed sinus arrest with atrial fibrillation. The sinus arrest lasted 8.1 s; B: Holter ECG showed atrial fibrillation. The fastest heart rate was 200 beats/min.

bradycardia were found to be caused by hyperthyroidism. Based on their findings, they concluded that patients with thyroid dysfunction combined with second- or third-degree atrioventricular block almost always require permanent pacemaker implantation, even after the thyroid state returns to normal. However, based on our analysis of the 34 reported cases, we observed that most cases of hyperthyroidism combined with severe bradycardia did not require permanent pacemaker treatment. We found that in 27 cases (79.4%), bradycardia was resolved by correction of combined electrolyte disorder and infection, with the treatment of atropine, isoproterenol, or glucocorticoids, temporary pacemaker implantation, and/or hyperthyroidism treatment. The median recovery time was 5.5 (2-8) d.

We hypothesize that most elderly patients with hyperthyroidism and severe bradycardia may need permanent pacemaker implantation. Our analysis revealed that 6 of the 12 elderly patients required permanent pacemaker implantation. Elderly patients accounted for 85.7% (6/7) of all reported permanent pacemaker implantations. Elderly patients are more likely to need a permanent pacemaker because the cardiac conduction system undergoes a series of changes with age, such as a decrease in the number of pacing cells, an increase in fibrous tissue, and fat infiltration in the sinoatrial node. These events cause difficulty for the elderly to recover.

We directly implanted a permanent pacemaker without waiting for 1 wk in Case 3. The patient exhibited obvious alternation between rapid atrial fibrillation and sinus arrest within a day, and cardiac ultrasound showed changes in cardiac structure. In this case, we did not know if hyperthyroidism was the only reason for bradycardia. Therefore, we were unsure if treatment of hyperthyroidism would relieve the severe bradycardia or how long it would take. We do know that acute unstable bradycardia can lead to cardiac arrest, and this patient had multiple sinus arrests that could last for 8.1 s. By not directly treating bradycardia and treating hyperthyroidism instead, his risk of cardiac arrest would be higher. Therefore, his family chose to have a permanent pacemaker implanted immediately. He recovered well and did not have any episodes of syncope during the 1-year follow-up.

In most cases, hyperthyroidism with severe bradycardia may require 1 wk of observation before deciding whether to implant a permanent pacemaker. Using drugs, such as atropine and isoproterenol and/or anti-hyperthyroidism treatment, or implantation of temporary pacemakers to increase heart rate and assessment of blood potassium levels need to be completed before permanent pacemaker implantation. Moreover, we must remember that the probability of recovery of the elderly will decrease. Therefore, in special cases, such as elderly patients, an immediate permanent pacemaker implantation may be chosen.

CONCLUSION

Patients with hyperthyroidism carry a risk of severe bradycardia. For patients with hyperthyroidism accompanied by severe bradycardia, treatment with drugs or a temporary pacemaker for 1 wk is recommended before implantation of a permanent pacemaker. However, in special cases where the patient's safety is at stake or in elderly patients who are at risk, permanent pacemaker implantation can

be carried out immediately with the patient's consent.

FOOTNOTES

Author contributions: He YL and Zeng M contributed to manuscript writing and editing, and data collection; Xu WX and Fang TY contributed to data analysis; all authors have read and approved the final manuscript.

Supported by the Clinical Medical Research Center Project of Hainan Province, China, No. LCYX202207; and Key R&D Plan Project of Hainan Province, China, No. ZDYF2020118.

Informed consent statement: Informed written consent was obtained from the patients for publication of this report and any accompanying images.

Conflict-of-interest statement: The authors declare that they have no conflict of interest.

CARE Checklist (2016) statement: The authors have read the CARE Checklist (2016), and the manuscript was prepared and revised according to the CARE Checklist (2016).

Open-Access: This article is an open-access article that was selected by an in-house editor and fully peer-reviewed by external reviewers. It is distributed in accordance with the Creative Commons Attribution NonCommercial (CC BY-NC 4.0) license, which permits others to distribute, remix, adapt, build upon this work non-commercially, and license their derivative works on different terms, provided the original work is properly cited and the use is non-commercial. See: <https://creativecommons.org/licenses/by-nc/4.0/>

Country/Territory of origin: China

ORCID number: Yang-Li He 0000-0002-3875-7573; Wen-Xing Xu 0000-0003-0095-6400; Tuan-Yu Fang 0000-0002-0359-6394; Min Zeng 0000-0001-6472-1980.

S-Editor: Chen YL

L-Editor: Wang TQ

P-Editor: Chen YL

REFERENCES

- 1 De Leo S, Lee SY, Braverman LE. Hyperthyroidism. *Lancet* 2016; **388**: 906-918 [PMID: 27038492 DOI: 10.1016/S0140-6736(16)00278-6]
- 2 Doubleday AR, Sippel RS. Hyperthyroidism. *Gland Surg* 2020; **9**: 124-135 [PMID: 32206604 DOI: 10.21037/gs.2019.11.01]
- 3 Li Y, Teng D, Ba J, Chen B, Du J, He L, Lai X, Teng X, Shi X, Li Y, Chi H, Liao E, Liu C, Liu L, Qin G, Qin Y, Quan H, Shi B, Sun H, Tang X, Tong N, Wang G, Zhang JA, Wang Y, Xue Y, Yan L, Yang J, Yang L, Yao Y, Ye Z, Zhang Q, Zhang L, Zhu J, Zhu M, Ning G, Mu Y, Zhao J, Shan Z, Teng W. Efficacy and Safety of Long-Term Universal Salt Iodization on Thyroid Disorders: Epidemiological Evidence from 31 Provinces of Mainland China. *Thyroid* 2020; **30**: 568-579 [PMID: 32075540 DOI: 10.1089/thy.2019.0067]
- 4 Polikar R, Burger AG, Scherrer U, Nicod P. The thyroid and the heart. *Circulation* 1993; **87**: 1435-1441 [PMID: 8490997 DOI: 10.1161/01.cir.87.5.1435]
- 5 Klein I, Ojamaa K. Thyroid hormone and the cardiovascular system. *N Engl J Med* 2001; **344**: 501-509 [PMID: 11172193 DOI: 10.1056/NEJM200102153440707]
- 6 Muggia AL, Stjernholm M, Houle T. Complete heart block with thyrotoxic myocarditis. Report of a case. *N Engl J Med* 1970; **283**: 1099-1100 [PMID: 5470854 DOI: 10.1056/NEJM19701122832010]
- 7 Miller RH, Corcoran FH, Baker WP. Second and third degree atrioventricular block with Graves' disease: a case report and review of the literature. *Pacing Clin Electrophysiol* 1980; **3**: 702-711 [PMID: 6161353 DOI: 10.1111/j.1540-8159.1980.tb05575.x]
- 8 Kramer MR, Shilo S, Herskovic C. Atrioventricular and sinoatrial block in thyrotoxic crisis. *Br Heart J* 1985; **54**: 600-602 [PMID: 4074593 DOI: 10.1136/hrt.54.6.600]
- 9 Nakagawa S, Higa A, Kondoh H, Koiwaya Y, Tanaka K. Cyclic sinus node dysfunction in a patient with hyperthyroidism. *Arch Intern Med* 1985; **145**: 2126-2127 [PMID: 4062469 DOI: 10.1001/archinte.1985.00360110202043]
- 10 Sriussadaporn S, Vannasaeng S, Trisukosol D, Nitiyanant W, Piraphatdist T, Vichayanrat A. Complete heart block complicating hyperthyroidism: a case report. *J Med Assoc Thai* 1990; **73**: 53-57 [PMID: 2345328]
- 11 Ho SC, Eng PH, Ding ZP, Fok AC, Khoo DH. Thyroid storm presenting as jaundice and complete heart block. *Ann Acad Med Singap* 1998; **27**: 748-751 [PMID: 9919355]
- 12 Vassiliou V. Thyrotoxicosis with heart block. *J R Soc Med* 2001; **94**: 552-553 [PMID: 11581359 DOI: 10.1177/014107680109401030]
- 13 Topaloglu S, Topaloglu OY, Ozdemir O, Soylu M, Demir AD, Korkmaz S. Hyperthyroidism and complete atrioventricular block--a report of 2 cases with electrophysiologic assessment. *Angiology* 2005; **56**: 217-220 [PMID: 15793611 DOI: 10.1177/0141076805270001]

- 10.1177/000331970505600212]
- 14 **Kuo YC**, Tseng YT, Lee TI, Hsieh MH. Chronic bifascicular block with intermittent complete atrioventricular block induced by hyperthyroidism. *Int J Cardiol* 2006; **110**: 407-410 [PMID: 16300844 DOI: 10.1016/j.ijcard.2005.08.042]
 - 15 **Ozaydin M**, Türker Y, Doğan A, Varol E, Aslan SM, Altınbaş A. An unusual cause of syncope: hyperthyroidism. *Anadolu Kardiyol Derg* 2007; **7**: 453-454 [PMID: 18065353]
 - 16 **Krishnamoorthy S**, Narain R, Creamer J. Unusual presentation of thyrotoxicosis as complete heart block and renal failure: a case report. *J Med Case Rep* 2009; **3**: 9303 [PMID: 20062792 DOI: 10.1186/1752-1947-3-9303]
 - 17 **Karakas CY**, Topaloglu C, Canbolant E, Seyfeli E, Akgül F. Hyperthyroidism as a rare cause of complete AV block. *Anadolu Kardiyol Derg* 2009; **9**: 67-68 [PMID: 19196581]
 - 18 **Aritürk Y**, Islamoglu E, Tekbas. An unusual presentation of hyperthyroidism: atrioventricular complete heart block. *Acta Endocrinologica (Buc)* 2011; **7**: 405-409 [DOI: 10.4183/aeb.2011.405]
 - 19 **Al Bannay R**, Husain A, Khalaf S. Complete heart block in thyrotoxicosis, is it a manifestation of thyroid storm? *Case Rep Endocrinol* 2012; **2012**: 318398 [PMID: 22934200 DOI: 10.1155/2012/318398]
 - 20 **Kausel A**, Korniyenko A, Sandhu G. Bradyarrhythmia as a presenting feature of subclinical hyperthyroidism. *QJM* 2012; **105**: 461-462 [PMID: 21459807 DOI: 10.1093/qjmed/hcr049]
 - 21 **illogo GR**, Konaté L, Samandoulougou A. Transient atrioventricular block in multinodular goiter: report of a case. *Pan Afr Med J* 2014; **19**: 53 [DOI: 10.13070/rs.en.1.897]
 - 22 **Upta A**, Arora S. Atrioventricular Heart Blocks in Thyrotoxicosis. *JACC* 2015; **65**: A738 [DOI: 10.1016/s0735-1097(15)60738-0]
 - 23 **Adesokan A**, Vigneswaran T, Ajzensztejn M, Mathur S. Atrioventricular block: an unusual complication of Graves' disease. *BMJ Case Rep* 2017; **2017** [PMID: 28473357 DOI: 10.1136/bcr-2016-218273]
 - 24 **Eom YS**, Oh PC. Graves' Disease Presenting with Complete Atrioventricular Block. *Case Rep Endocrinol* 2020; **2020**: 6656875 [PMID: 33381328 DOI: 10.1155/2020/6656875]
 - 25 **Wan SH**, Lee GS, Toh CC. The sick sinus syndrome. A study of 15 cases. *Br Heart J* 1972; **34**: 942-952 [PMID: 4263048 DOI: 10.1136/hrt.34.9.942]
 - 26 **Lubitz RM**, Acker JJ. Thyrotoxicosis induced sick sinus syndrome: medical therapy may avoid permanent pacing. *Pacing Clin Electrophysiol* 1990; **13**: 700-702 [PMID: 1695346 DOI: 10.1111/j.1540-8159.1990.tb02092.x]
 - 27 **Namura M**, Kanaya H, Ikeda M, Shibayama S, Ohka T. Hyperthyroidism complicated with sick sinus syndrome. *Jpn Circ J* 1995; **59**: 824-828 [PMID: 8788374 DOI: 10.1253/jcj.59.824]
 - 28 **Moustaghfir A**, Kharchafi A, Mahassin F, Chaari J, Ghafir D, Ohayon V, Archane MI. [Sinus dysfunction in Basedow's disease. A case report]. *Rev Med Interne* 1999; **20**: 804-805 [PMID: 10522303 DOI: 10.1016/s0248-8663(00)88688-9]
 - 29 **Lee G**, McGavigan AD, Hillock RJ, Roberts-Thomson KC, Stevenson IH, Mond HG. A grave case of bradycardia. *Pacing Clin Electrophysiol* 2006; **29**: 788-790 [PMID: 16884518 DOI: 10.1111/j.1540-8159.2006.00436.x]
 - 30 **Tudoran M**, Tudoran C. Hyperthyroidism and sick sinus syndrome, a rare but challenging association: A study of three cases. *Niger J Clin Pract* 2017; **20**: 1046-1048 [PMID: 28891553 DOI: 10.4103/njcp.njcp_288_16]
 - 31 **Talwar KK**, Gupta V, Kaul U, Ahuja MM, Bhatia ML. Electrophysiological studies in thyrotoxicosis with and without associated sick sinus syndrome. *Clin Cardiol* 1987; **10**: 249-254 [PMID: 3581536 DOI: 10.1002/clc.4960100408]
 - 32 **Ortmann C**, Pfeiffer H, Du Chesne A, Brinkmann B. Inflammation of the cardiac conduction system in a case of hyperthyroidism. *Int J Legal Med* 1999; **112**: 271-274 [PMID: 10433039 DOI: 10.1007/s004140050248]
 - 33 **Biondi B**, Kahaly GJ. Cardiovascular involvement in patients with different causes of hyperthyroidism. *Nat Rev Endocrinol* 2010; **6**: 431-443 [PMID: 20585347 DOI: 10.1038/nrendo.2010.105]
 - 34 **Chen PS**, Joung B, Shinohara T, Das M, Chen Z, Lin SF. The initiation of the heart beat. *Circ J* 2010; **74**: 221-225 [PMID: 20019407 DOI: 10.1253/circj.cj-09-0712]
 - 35 **Wang Q**, Wang D, Yan G, Qiao Y, Sun L, Zhu B, Wang X, Tang C. SERCA2a was serotonylated and may regulate sinoatrial node pacemaker activity. *Biochem Biophys Res Commun* 2016; **480**: 492-497 [PMID: 27780728 DOI: 10.1016/j.bbrc.2016.10.082]
 - 36 . Retraction. ATP consumption by sarcoplasmic reticulum Ca²⁺ pumps accounts for 50% of resting metabolic rate in mouse fast and slow twitch skeletal muscle. *Am J Physiol Cell Physiol*. 2010 Mar;298(3):C521-9. doi: 10.1152/ajpcell.00479.2009. *Am J Physiol Cell Physiol* 2012; **303**: C1000 [PMID: 23124948 DOI: 10.1152/ajpcell.zh0-7108-retr.2012]
 - 37 **Holt E**, Sjaastad I, Lunde PK, Christensen G, Sejersted OM. Thyroid hormone control of contraction and the Ca(2+)-ATPase/phospholamban complex in adult rat ventricular myocytes. *J Mol Cell Cardiol* 1999; **31**: 645-656 [PMID: 10198194 DOI: 10.1006/jmcc.1998.0900]
 - 38 **Kimura Y**, Otsu K, Nishida K, Kuzuya T, Tada M. Thyroid hormone enhances Ca²⁺ pumping activity of the cardiac sarcoplasmic reticulum by increasing Ca²⁺ ATPase and decreasing phospholamban expression. *J Mol Cell Cardiol* 1994; **26**: 1145-1154 [PMID: 7815458 DOI: 10.1006/jmcc.1994.1133]
 - 39 **Hoefig CS**, Harder L, Oelkrug R, Meusel M, Vennström B, Brabant G, Mittag J. Thermoregulatory and Cardiovascular Consequences of a Transient Thyrotoxicosis and Recovery in Male Mice. *Endocrinology* 2016; **157**: 2957-2967 [PMID: 27145010 DOI: 10.1210/en.2016-1095]
 - 40 **Ozcan KS**, Osmonov D, Erdinler I, Altay S, Yildirim E, Turkkan C, Hasdemir H, Cakmak N, Alper AT, Satilmis S, Gurkan K. Atrioventricular block in patients with thyroid dysfunction: prognosis after treatment with hormone supplementation or antithyroid medication. *J Cardiol* 2012; **60**: 327-332 [PMID: 22738687 DOI: 10.1016/j.jjcc.2012.05.012]



Published by **Baishideng Publishing Group Inc**
7041 Koll Center Parkway, Suite 160, Pleasanton, CA 94566, USA

Telephone: +1-925-3991568

E-mail: bpgoffice@wjgnet.com

Help Desk: <https://www.f6publishing.com/helpdesk>

<https://www.wjgnet.com>

