

World Journal of *Clinical Cases*

World J Clin Cases 2023 April 16; 11(11): 2363-2581



Contents

Thrice Monthly Volume 11 Number 11 April 16, 2023

REVIEW

- 2363 Presbyphagia: Dysphagia in the elderly
Feng HY, Zhang PP, Wang XW

MINIREVIEWS

- 2374 Narrative minireview of the spatial epidemiology of substance use disorder in the United States: Who is at risk and where?
Cuadros DF, Branscum AJ, Moreno CM, MacKinnon NJ
- 2386 Pyroptosis and its role in cancer
Liu SW, Song WJ, Ma GK, Wang H, Yang L
- 2396 Platelet rich fibrin is not a barrier membrane! Or is it?
Agrawal AA
- 2405 Advances in translational therapy for locally advanced gastric cancer
Zhao K, Na Y, Xu HM

ORIGINAL ARTICLE

Retrospective Study

- 2412 Study of pathogenic genes in a pedigree with familial dilated cardiomyopathy
Zhang XR, Ren H, Yao F, Liu Y, Song CL
- 2423 Classification of hepatobiliary scintigraphy patterns in segmented gallbladder according to anatomical discordance
Lee YC, Jung WS, Lee CH, Kim SH, Lee SO
- 2435 Optimal laboratory testing protocol for patients with acne taking oral isotretinoin
Park YJ, Shin HY, Choi WK, Lee AY, Lee SH, Hong JS

Observational Study

- 2443 Etiology analysis for term newborns with severe hyperbilirubinemia in eastern Guangdong of China
Xu JX, Lin F, Wu YH, Chen ZK, Ma YB, Yang LY

CASE REPORT

- 2452 Aicardi-Goutières syndrome type 7 in a Chinese child: A case report
Lin SZ, Yang JJ, Xie TL, Li JY, Ma JQ, Wu S, Wang N, Wang YJ

- 2457** Allergic bronchopulmonary aspergillosis with marked peripheral blood eosinophilia and pulmonary eosinophilia: A case report
Zhang XX, Zhou R, Liu C, Yang J, Pan ZH, Wu CC, Li QY
- 2464** Late presentation of dural tears: Two case reports and review of literature
Xu C, Dong RP, Cheng XL, Zhao JW
- 2474** Difficult-to-treat rheumatoid arthritis treated with Abatacept combined with Baricitinib: A case report
Qi JP, Jiang H, Wu T, Zhang Y, Huang W, Li YX, Wang J, Zhang J, Ying ZH
- 2482** Anesthesia management in a pediatric patient with complicatedly difficult airway: A case report
Chen JX, Shi XL, Liang CS, Ma XG, Xu L
- 2489** Intracranial large artery embolism due to carotid thrombosis caused by a neck massager: A case report
Pan J, Wang JW, Cai XF, Lu KF, Wang ZZ, Guo SY
- 2496** Intraductal papillary mucinous neoplasm originating from a jejunal heterotopic pancreas: A case report
Huang JH, Guo W, Liu Z
- 2502** Application of endoscopic retrograde cholangiopancreatography for treatment of obstructive jaundice after hepatoblastoma surgery: A case report
Shu J, Yang H, Yang J, Bian HQ, Wang X
- 2510** Total removal of a large esophageal schwannoma by submucosal tunneling endoscopic resection: A case report and review of literature
Mu YZ, Zhang Q, Zhao J, Liu Y, Kong LW, Ding ZX
- 2521** SMARCA4-deficient undifferentiated thoracic tumor: A case report
Kwon HJ, Jang MH
- 2528** Prostate-specific antigen reduction after capecitabine plus oxaliplatin chemotherapy: A case report
Zou Q, Shen RL, Guo X, Tang CY
- 2535** Bilateral carpal tunnel syndrome and motor dysfunction caused by gout and type 2 diabetes: A case report
Zhang GF, Rong CM, Li W, Wei BL, Han MT, Han QL
- 2541** Pregnancy complicated by juxtaglomerular cell tumor of the kidney: A case report
Fu X, Deng G, Wang K, Shao C, Xie LP
- 2549** Successful treatment of lichen amyloidosis coexisting with atopic dermatitis by dupilumab: Four case reports
Zhu Q, Gao BQ, Zhang JF, Shi LP, Zhang GQ
- 2559** Successful treatment of breast metastasis from primary transverse colon cancer: A case report
Jiao X, Xing FZ, Zhai MM, Sun P

- 2567** Different endodontic treatments induced root development of two nonvital immature teeth in the same patient: A case report
Chai R, Yang X, Zhang AS
- 2576** Autoimmune encephalitis after surgery for appendiceal cancer: A case report
Mao YH, Li L, Wen LM, Qin JM, Yang YL, Wang L, Wang FR, Zhao YZ

ABOUT COVER

Editorial Board Member of *World Journal of Clinical Cases*, Farooq Shahzad, FACS, MBBS, MS, Assistant Professor, Plastic Surgery Service, Department of Surgery, Memorial Sloan-Kettering Cancer Center, New York, NY 10065, United States. fooqs@hotmail.com

AIMS AND SCOPE

The primary aim of *World Journal of Clinical Cases* (WJCC, *World J Clin Cases*) is to provide scholars and readers from various fields of clinical medicine with a platform to publish high-quality clinical research articles and communicate their research findings online.

WJCC mainly publishes articles reporting research results and findings obtained in the field of clinical medicine and covering a wide range of topics, including case control studies, retrospective cohort studies, retrospective studies, clinical trials studies, observational studies, prospective studies, randomized controlled trials, randomized clinical trials, systematic reviews, meta-analysis, and case reports.

INDEXING/ABSTRACTING

The WJCC is now abstracted and indexed in Science Citation Index Expanded (SCIE, also known as SciSearch®), Journal Citation Reports/Science Edition, Current Contents®/Clinical Medicine, PubMed, PubMed Central, Scopus, Reference Citation Analysis, China National Knowledge Infrastructure, China Science and Technology Journal Database, and Superstar Journals Database. The 2022 Edition of Journal Citation Reports® cites the 2021 impact factor (IF) for WJCC as 1.534; IF without journal self cites: 1.491; 5-year IF: 1.599; Journal Citation Indicator: 0.28; Ranking: 135 among 172 journals in medicine, general and internal; and Quartile category: Q4. The WJCC's CiteScore for 2021 is 1.2 and Scopus CiteScore rank 2021: General Medicine is 443/826.

RESPONSIBLE EDITORS FOR THIS ISSUE

Production Editor: Hua-Ge Yin; Production Department Director: Xiang Li; Editorial Office Director: Jin-Lei Wang.

NAME OF JOURNAL

World Journal of Clinical Cases

ISSN

ISSN 2307-8960 (online)

LAUNCH DATE

April 16, 2013

FREQUENCY

Thrice Monthly

EDITORS-IN-CHIEF

Bao-Gan Peng, Jerzy Tadeusz Chudek, George Kontogeorgos, Maurizio Serati, Ja Hyeon Ku

EDITORIAL BOARD MEMBERS

<https://www.wjgnet.com/2307-8960/editorialboard.htm>

PUBLICATION DATE

April 16, 2023

COPYRIGHT

© 2023 Baishideng Publishing Group Inc

INSTRUCTIONS TO AUTHORS

<https://www.wjgnet.com/bpg/gerinfo/204>

GUIDELINES FOR ETHICS DOCUMENTS

<https://www.wjgnet.com/bpg/GerInfo/287>

GUIDELINES FOR NON-NATIVE SPEAKERS OF ENGLISH

<https://www.wjgnet.com/bpg/gerinfo/240>

PUBLICATION ETHICS

<https://www.wjgnet.com/bpg/GerInfo/288>

PUBLICATION MISCONDUCT

<https://www.wjgnet.com/bpg/gerinfo/208>

ARTICLE PROCESSING CHARGE

<https://www.wjgnet.com/bpg/gerinfo/242>

STEPS FOR SUBMITTING MANUSCRIPTS

<https://www.wjgnet.com/bpg/GerInfo/239>

ONLINE SUBMISSION

<https://www.f6publishing.com>



Application of endoscopic retrograde cholangiopancreatography for treatment of obstructive jaundice after hepatoblastoma surgery: A case report

Jun Shu, Hu Yang, Jun Yang, Hong-Qiang Bian, Xin Wang

Specialty type: Medicine, research and experimental

Provenance and peer review:

Unsolicited article; Externally peer reviewed.

Peer-review model: Single blind

Peer-review report's scientific quality classification

Grade A (Excellent): 0
Grade B (Very good): 0
Grade C (Good): 0
Grade D (Fair): 0
Grade E (Poor): 0

P-Reviewer: Amornyotin S, Thailand; Rashid R, Bangladesh

Received: December 2, 2022

Peer-review started: December 2, 2022

First decision: January 5, 2023

Revised: January 14, 2023

Accepted: March 21, 2023

Article in press: March 21, 2023

Published online: April 16, 2023



Jun Shu, Hu Yang, Jun Yang, Hong-Qiang Bian, Xin Wang, Department of General Surgery, Wuhan Children' Hospital, Tongji Medical College, Huazhong University of Science and Technology, Wuhan 430000, Hubei Province, China

Corresponding author: Xin Wang, MD, Surgeon, Department of General Surgery, Wuhan Children' Hospital, Tongji Medical College, Huazhong University of Science and Technology, No. 100 Hong Kong Road, Wuhan 430000, Hubei Province, China.

wangxin20150710@163.com

Abstract

BACKGROUND

We aimed to investigate the effectiveness of endoscopic retrograde cholangiopancreatography (ERCP) for treating obstructive jaundice (OJ) post hepatoblastoma (HB) surgery (post-HB OJ) by analyzing the data of a case and performing a literature review.

CASE SUMMARY

Clinical data of one patient with post-HB OJ treated by ERCP were retrospectively analyzed. Furthermore, clinical characteristics and insights into the diagnosis and treatment of post-HB OJ in children were summarized *via* searching various databases and platforms, such as China National Knowledge Infrastructure, Wanfang database, CQVIP database, PubMed, Ringer Link, and Google Scholar. The patient reported herein underwent five chemotherapy sessions after the diagnosis of HB and right hemihepatectomy after tumor size reduction; these were followed by two postoperative chemotherapy sessions. Three months postoperatively, the patient developed icteric sclera, strong tea-colored urine, and clay-like stools, and showed signs of skin itchiness; blood analysis showed significantly an increased conjugated bilirubin (CB) level (200.3 $\mu\text{mol/L}$). Following the poor efficacy of anti-jaundice and hepatoprotective treatments, the patient underwent ERCP. Intraoperative imaging showed a dilated bile duct in the porta hepatis with significant distal stenosis. A 5 Fr nasopancreatic tube was placed in the dilated area through the stricture for external drainage, and the patient was extubated on postoperative day 6. Postoperatively, the patient's stool turned yellow, and the CB level decreased to 78.2 $\mu\text{mol/L}$. Fifteen days later, ERCP was repeated due to unrelieved jaundice symptoms, wherein a 7 Fr nasobiliary drainage tube was successfully placed. Three months post-ERCP, the

jaundice symptoms resolved, and the CB level was reduced to 33.2 $\mu\text{mol/L}$. A follow-up examination one year postoperatively revealed no jaundice symptoms and normal CB level.

CONCLUSION

Post-HB OJ is rare. Compared to biliary tract reconstruction, ERCP is less invasive and has a better therapeutic effect.

Key Words: Endoscopic retrograde cholangiopancreatography; Hepatoblastoma; Pediatric patients; Obstructive jaundice; Case report

©The Author(s) 2023. Published by Baishideng Publishing Group Inc. All rights reserved.

Core Tip: This study aimed to investigate the effectiveness of endoscopic retrograde cholangiopancreatography (ERCP) in the treatment of obstructive jaundice following hepatoblastoma surgery by analyzing the data of a case and performing a literature review. We found that ERCP is less invasive and has a better therapeutic effect compared to biliary tract reconstruction.

Citation: Shu J, Yang H, Yang J, Bian HQ, Wang X. Application of endoscopic retrograde cholangiopancreatography for treatment of obstructive jaundice after hepatoblastoma surgery: A case report. *World J Clin Cases* 2023; 11(11): 2502-2509

URL: <https://www.wjgnet.com/2307-8960/full/v11/i11/2502.htm>

DOI: <https://dx.doi.org/10.12998/wjcc.v11.i11.2502>

INTRODUCTION

Hepatoblastoma (HB) is a common malignant, solid tumor that affects children's livers and accounts for approximately two-thirds of all liver malignancies; it has an overall survival rate of 70% to 80% [1]. Presently, a surgery-based multidisciplinary management strategy with chemotherapy is the standard treatment modality for HB. HB-related postoperative complications include obstructive jaundice (OJ), which is rare. OJ is manifested clinically as generalized yellowing of the skin and sclera, skin pruritus, yellow urine, and clay-like stools. Furthermore, perioperative liver function impairment, biliary tract infection, and liver failure are also observed, and they critically affect the patient's postoperative recovery [2]. The effectiveness and safety of endoscopic retrograde cholangiopancreatography (ERCP) in the management of adult biliary and pancreatic diseases are well known; however, its application in children is scarce due to the low incidence of biliopancreatic diseases in children, lack of relevant pediatric instruments, special characteristics associated with pediatric cases, and operational difficulties. This paper reports a case of post-HB surgery OJ (post-HB OJ) treated by ERCP. Moreover, effective diagnosis and treatment methods are explored based on a literature review.

CASE PRESENTATION

Chief complaints

A one-year-old female child presented to a local hospital with an abdominal mass.

History of present illness

The patient presented with icteric sclera and symptoms of itchy skin at 3 mo after a right hemihepatectomy.

History of past illness

The patient was examined and diagnosed with HB for which she underwent five chemotherapy sessions and a right hemihepatectomy after tumor size reduction. These were followed by two postoperative chemotherapy sessions. These were followed by two postoperative chemotherapy sessions.

Physical examination

Strong tea-colored urine and clay-like stools were reported. Blood examinations revealed significantly increased conjugated bilirubin (CB) (200.3 $\mu\text{mol/L}$) and total bilirubin (293.6 $\mu\text{mol/L}$) levels.

Laboratory examinations

The patient's gamma-glutamyl transpeptidase (1834 U/L), alanine transaminase (104 U/L), and aspartate aminotransferase (210 U/L) levels were elevated. However, atomolam, inosine, intravenous ornithine aspartate drip, oral ursodeoxycholic acid, and compound glycyrrhizin tablet administered at the local hospital proved ineffective.

Imaging examinations

Magnetic resonance cholangiopancreatography (MRCP) showed a dilated bile duct in the porta hepatis (widest diameter, approximately 12 mm) (Figure 1).

FINAL DIAGNOSIS

The patient underwent ERCP under general anesthesia in our hospital. After routine intubation, MRCP showed a slender common bile duct (2 mm) and contrast agent accumulation in the porta hepatis, and the intrahepatic bile duct and the middle and lower common bile ducts could not be visualized (Figure 2). Pressurized contrast imaging demonstrated a dilated bile duct in the porta hepatis with significant stenosis at its distal terminal. The difficult passage at this site caused the guidewire to bend, leading to a filling defect (Figure 3).

TREATMENT

A 7 Fr nasobiliary drainage tube could not pass through the stricture (Figure 4A), and with great difficulty, a 6 Fr nasobiliary drainage tube was passed through. Subsequently, on postoperative day 6, a 5 Fr nasopancreatic tube was placed at the dilatation through the stricture for external drainage (Figure 4B) and the patient was extubated. During this time, the patient's stools turned yellow, and the CB level decreased to 78.2 $\mu\text{mol/L}$. Fifteen days later, ERCP was repeated due to unalleviated jaundice symptoms. Although the imaging results still suggested bile duct dilatation in the porta hepatis, the intrahepatic bile duct, and the lower and middle common bile ducts could not be visualized (Figure 4C), along with balloon dilatation of the stenosis. Finally, a 7 Fr nasobiliary drainage tube was successfully inserted (Figure 4D).

OUTCOME AND FOLLOW-UP

Three months after the second ERCP, the patient's jaundice symptoms mostly resolved; furthermore, the patient's CB level decreased to 33.2 $\mu\text{mol/L}$. A one-year follow-up revealed that the jaundice symptoms had disappeared and the patient had normal bilirubin level.

China National Knowledge Infrastructure, Wanfang database, CQVIP database, PubMed, Ringer Link, and Google Scholar were searched until April 2022 with the keywords hepatoblastoma, obstructive jaundice, and biliary obstruction. The inclusion criteria for the studies were as follows: (1) Patients with a diagnosis of HB with surgical treatment; (2) Those with postoperative OJ; and (3) Those who underwent treatment of OJ *via* surgical methods, including biliary tract reconstruction and ERCP. Duplicate cases reported by the same author, institute, hospital, and database were excluded.

Five studies that met the requirements were included in the review; two studies were written in English and three in Chinese. A total of six cases were analyzed, of which five met the inclusion criteria. One patient with HB developed post-HB OJ and died of liver failure without surgical treatment and was excluded from the review. Finally, five patients from the retrieved studies and the patients in this case report were included (Table 1). All children presented with post-HB OJ within 14 d to 4 mo postoperatively. Five patients developed OJ due to intraoperative biliary injury; whereas, one patient developed OJ and elevated liver stiffness which was attributed to biliary injury-related bile leakage[3]. Furthermore, one patient developed biliary obstruction due to a postoperatively regenerated liver that compressed the bile duct[4]. Four patients underwent biliary tract reconstruction[3-6] and recovered well postoperatively. One patient developed severe malnutrition post percutaneous transhepatic cholangial drainage (PTCD); however, subsequent biliary tract reconstruction facilitated good recovery [7]. As mentioned previously, the patient in this report was treated by ERCP and recovered well after surgery.

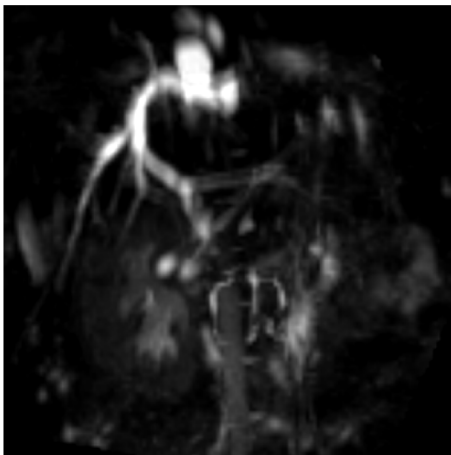
DISCUSSION

Post-HB OJ is a rare complication and is associated with injury or compression of trunk ducts, such as

Table 1 Clinical data of six children with obstructive jaundice after hepatoblastoma operation

Ref.	Case	Age (mo)	Sex	Surgery	Time of postoperative obstructive jaundice	Reason	Solution	Prognosis
Canty[4], 1991	2	6	Male	Right hemihepatectomy	4 mo	Postoperative liver regeneration caused biliary obstruction	Biliary tract reconstruction operation	Good
		2	Male	Right hemihepatectomy	14 d	Postoperative liver regeneration caused biliary obstruction	-	Died of jaundice and liver failure 4 mo after surgery
Murphy <i>et al</i> [7], 2012	1	12	Female	Right hemihepatectomy	2.5 mo	Left hepatic duct injury	PTCD failed followed by biliary tract reconstruction operation	Good
Liu <i>et al</i> [5], 2015	1	1	—	—	—	Right hepatic duct injury	Biliary tract reconstruction operation	Good
Yao <i>et al</i> [6], 2018	1	11	Male	Left hemihepatectomy and VII/VIII section resection	16 d	Right hepatic duct injury	Biliary tract reconstruction operation	Good
Feng <i>et al</i> [3], 2020	1	—	—	—	—	Biliary tract injury forms biliary leakage	Biliary tract reconstruction operation	Good
This Study	1	12	Female	Right hemihepatectomy	3 mo	Hepatic duct injury	ERCP	Good

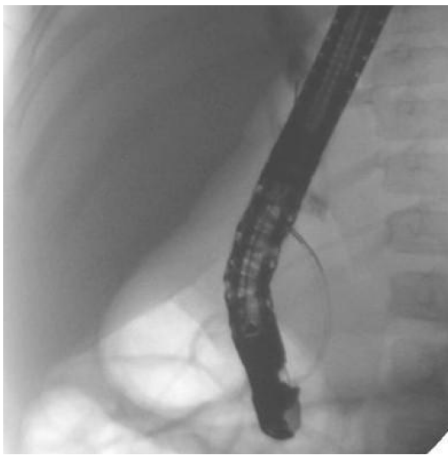ERCP: Endoscopic retrograde cholangiopancreatography; PTCD: Percutaneous transhepatic cholangial drainage.



DOI: 10.12998/wjcc.v11.i11.2502 Copyright ©The Author(s) 2023.

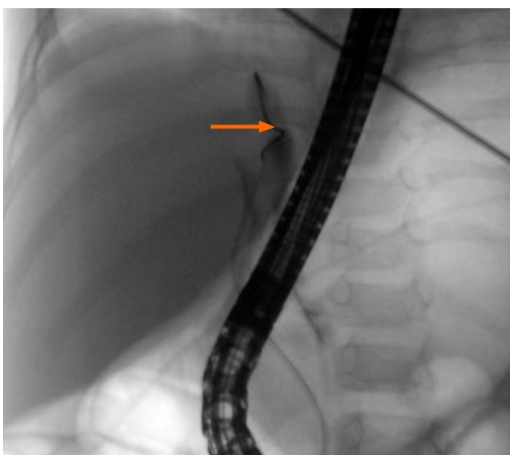
Figure 1 Magnetic resonance cholangiopancreatography examination demonstrating dilatation of the common bile duct in the porta hepatis with the widest diameter of approximately 12 mm.

the right or left hepatic ducts. Incomplete ligation of small bile ducts in the hepatectomy section dislodged ligatures, and necrosis are responsible for bile leakage. In five of the six children included in this review, OJ developed due to injury to the main hepatic duct. Moreover, a rare case of OJ due to postoperative liver regeneration was also noted[4]. Remarkable liver regeneration is observed post hepatectomy, which is typically initiated within a few days postoperatively and is completed within a few months. Rapid macronodular regeneration of the liver leads to stretching, compression, and eventual ischemic fibrosis of the extrahepatic biliary system, resulting in OJ. One child in this review developed postoperative bile leakage due to damage to the main hepatic duct. However, the bile leakage did not resolve after drainage, and local infection and encapsulated effusion were observed. Long-term conservative treatment led to inflammatory scar formation and tissue fragility around the bile leakage site, leading to OJ and increased liver stiffness[3]. However, damage to the main hepatic



DOI: 10.12998/wjcc.v11.i11.2502 Copyright ©The Author(s) 2023.

Figure 2 Aggregation of contrast in the porta hepatis and non-visualization of the intrahepatic bile duct and the middle and lower common bile ducts.



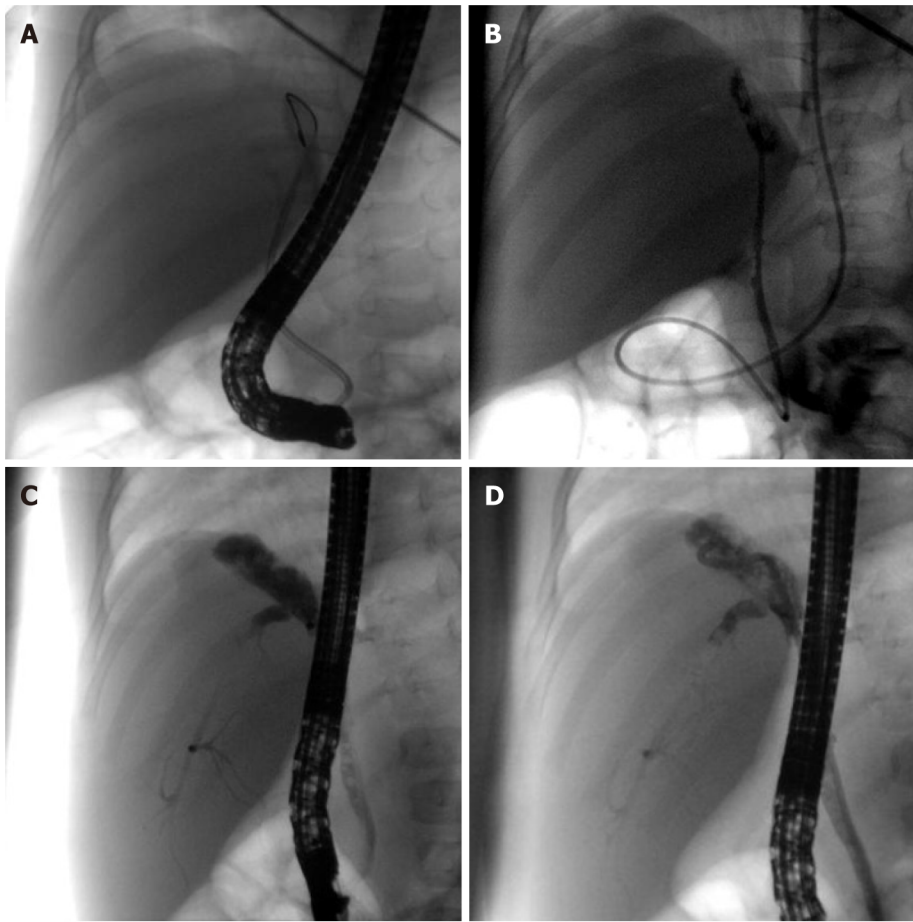
DOI: 10.12998/wjcc.v11.i11.2502 Copyright ©The Author(s) 2023.

Figure 3 Dilated bile duct in the porta hepatis with significant distal stenosis (arrow), as observed via pressurized contrast imaging.

duct does not consistently lead to bile leakage. In one child, the left hepatic duct was ligated extremely close to the common hepatic duct, resulting in a slight angle at the convergence of the right hepatic duct into the common hepatic duct and causing OJ due to poor bile flow[6].

Children with biliary tract infections present with abdominal pain. In addition, children who develop OJ after bile leakage may present with intestinal obstruction, localized and systemic infections, and liver stiffness due to severe abdominal infection. In such cases, hematological tests may demonstrate elevated total bilirubin levels, especially CB levels, with increased transaminases. Ultrasound is the preferred diagnostic modality for biliary obstruction because it is noninvasive, simple, efficient, and economical. However, computed tomography (CT), MPCP, and ERCP are required for confirming the diagnosis. Enhanced CT can demonstrate the tumor's recurrence post-HB surgery, locate the bile duct obstruction site, and determine the degree of bile duct dilatation. Additionally, it can also characterize the morphology and thickness of the bile duct wall. The diagnostic value of MRCP for pancreaticobiliary duct disease is well recognized as it clearly shows the pancreatic-bile duct structure; however, it is not ideal for diagnosing microscopic stones or lesions when pancreaticobiliary duct obstruction and dilatation are not apparent, especially when combined with ascites.

Effective treatments for post-HB OJ include biliary tract reconstruction, PTCD, and ERCP, of which biliary tract reconstruction is the most commonly used method. Despite its definite efficiency, its drawbacks are apparent, including the need for re-laparotomy for choledochojejunostomy and major surgical strikes. PTCD puncture requires a skilled surgeon with expertise in X-ray or ultrasound-guided puncture, and the continuous flow of bile into the abdominal cavity after failed catheterizing leads to acute peritonitis, requiring emergency surgery in severe cases[8]. PTCD is more effective for bile drainage; however, it is prone to complications, such as drainage tube blockage, infection, dislodgement, and bile loss, which cause an imbalance in the internal homeostasis of the body.



DOI: 10.12998/wjcc.v11.i11.2502 Copyright ©The Author(s) 2023.

Figure 4 Treatment of the patient. A: Inability and difficulty in passing the stenosis using a 7 Fr nasobiliary drainage tube; B: Smooth passage of a 5 Fr nasopancreatic tube through the stenosis; C: Dilatation of the bile ducts in the porta hepatis with visualization of the intrahepatic bile duct and the middle and lower common bile ducts; D: Smooth placement of a 7 Fr nasobiliary drainage tube.

Furthermore, pediatric care is highly demanding. Despite managing jaundice by external drainage with PTCD, one child developed severe malnutrition; however, the final biliary tract reconstruction facilitated spontaneous recovery[7]. Compared to ERCP, placement of inner support *via* PTCD is a highly traumatic procedure with the formation of a dead zone and is prone to migration into the duodenum, thus possibly triggering intestinal perforation[9].

Biliary stricture is a common complication observed post-liver transplantation and biliary surgery in adults. Its incidence after liver transplantation and due to direct injury during cholecystectomy is approximately 10%-40% and 0.5%, respectively[10,11]. Placement of balloon-dilated stents *via* the ERCP route for biliary strictures is safe, effective, minimally invasive, and the first-line treatment option for benign biliary strictures[12]. ERCP is the preferred treatment modality for simple anastomotic stenosis combined with bile duct calculi and can remarkably improve a patient's clinical symptoms and quality of life; however, patients undergoing ERCP require multiple removals and replacements of plastic stents with poor biocompatibility. Biodegradable biliary stents and tectorial self-expanding metal stents are used clinically and have a longer drainage time and reduce the frequency of stent replacements in a short period. ERCP has a low cure rate in patients with non-anastomotic strictures, especially diffuse strictures combined with calculus; nevertheless, it can provide short-term relief by alleviating the patient's clinical symptoms and improving the general condition. Thus, ERCP can be used as a transitional treatment modality. Moreover, failures of ERCP or poor treatment outcomes do not aggravate the patients' clinical conditions, and PTCD or surgical treatment is still feasible.

The lower frequency of ERCP use as a treatment modality in children compared to adults may be attributed to the relatively low probability of ERCP use in childhood, lack of physicians with extensive relevant experience, and lack of specialized equipment for children[13]. Recent years has witnessed increased use of ERCP for the treatment of pediatric pancreaticobiliary diseases, including congenital pancreaticobiliary diseases, biliary calculi, biliary strictures, pancreas divisum, and acute and chronic pancreatitis in children. This can be attributed to the advancements of duodenoscopic techniques in children and the involvement of adult endoscopists. Although MRCP has become a routine imaging modality for biliary obstructive disease, ERCP remains the gold standard for the diagnosis of biliary obstructive diseases since it allows for simultaneous examination and treatment[14]. The goal of biliary

obstruction treatment is long-term bile duct decompression and maintenance of bile duct patency, and endoscopic balloon dilation followed by placement of stents is one of the primary treatment modalities. Jaundice symptoms of our case disappeared 6 mo after the placement of a 7 Fr nasobiliary drainage tube *via* ERCP, and normal bilirubin levels were observed. In addition, the patient lived normally after extubation. Based on the results of a subsequent follow-up examination of the child, a 9 Fr biliary stent can be considered feasible for dilation and drainage when necessary. Despite the good efficacy of external nasobiliary drainage under ERCP, the tube had to be placed for a long period, remarkably influencing her and her family members. Therefore, placement of a biliary stent under ERCP for internal drainage may be a more optimal option for the treatment of biliary obstruction[15].

We recommend patients who meet the following indications to apply ERCP procedure: (1) Patients who are 10 kg or over or 1 year old or over; (2) A history of hepatectomy which may cause iatrogenic biliary stricture during surgery; and (3) Postoperative clinical findings, laboratory examination, and imaging examination results suggested biliary obstruction.

The effectiveness of ERCP in treating these cases is also affected by the following factors: (1) Scope of the first surgical resection and the degree of bile duct injury; (2) The patient's own ability to repair and regenerate the biliary tract; (3) The patient's degree of adaptation to biliary balloon dilatation; (4) The unobstructed time of the bile stent; and (5) Biliary tract infection and systemic infection of the patient. And the need of multiple ERCP operations is also the limitation of the therapy.

CONCLUSION

In summary, post-HB OJ is rare. ERCP aids in avoiding unnecessary surgical procedures, is less invasive, and shows better treatment outcomes than biliary tract reconstruction.

FOOTNOTES

Author contributions: Wang X and Shu J designed the research study; Wang X and Yang H performed the research; Wang X, Yang J, and Bian HQ analyzed the data and wrote the manuscript; All authors have read and approved the final manuscript.

Informed consent statement: The study received the patient's consent and approval from the hospital's ethics committee.

Conflict-of-interest statement: All the authors report no relevant conflicts of interest for this article.

CARE Checklist (2016) statement: The authors have read CARE Checklist (2016), and the manuscript was prepared and revised according to CARE Checklist (2016).

Open-Access: This article is an open-access article that was selected by an in-house editor and fully peer-reviewed by external reviewers. It is distributed in accordance with the Creative Commons Attribution NonCommercial (CC BY-NC 4.0) license, which permits others to distribute, remix, adapt, build upon this work non-commercially, and license their derivative works on different terms, provided the original work is properly cited and the use is non-commercial. See: <https://creativecommons.org/licenses/by-nc/4.0/>

Country/Territory of origin: China

ORCID number: Xin Wang 0000-0002-0153-953X.

S-Editor: Li L

L-Editor: Wang TQ

P-Editor: Li L

REFERENCES

- 1 Hiyama E, Hishiki T, Watanabe K, Ida K, Yano M, Oue T, Iehara T, Hoshino K, Koh K, Tanaka Y, Kurihara S, Ueda Y, Onitake Y. Mortality and morbidity in primarily resected hepatoblastomas in Japan: Experience of the JPLT (Japanese Study Group for Pediatric Liver Tumor) trials. *J Pediatr Surg* 2015; **50**: 2098-2101 [PMID: 26388131 DOI: 10.1016/j.jpedsurg.2015.08.035]
- 2 Saxena P, Kumbhari V, Zein ME, Khashab MA. Preoperative biliary drainage. *Dig Endosc* 2015; **27**: 265-277 [PMID: 25293587 DOI: 10.1111/den.12394]
- 3 Feng J, Wang HM, Qin H, Yang W, Han W, Cheng HY, Chang XF, Zhu ZY, Han JY. [Diagnosis and treatment of postoperative biliary fistula in children with hepatoblastoma]. *Zhonghua Xiaoer Waik Zazhi* 2020; **19**: 794-799 [DOI: 10.1111/den.12394]

- 10.3969/j.issn.1671-6353.2020.09.007]
- 4 **Canty TG Sr.** Biliary obstruction from hepatic regeneration following extended right hepatectomy for tumor. *J Pediatr Surg* 1991; **26**: 830-833 [PMID: 1654407 DOI: 10.1016/0022-3468(91)90149-n]
 - 5 **Liu GB, Liu BH, Ma YY, Li K, Dong KR.** [Neonatal hepatoblastoma: a report of 8 cases with a literature review]. *Zhonghua Xiaer Waik Zazhi* 2015; **36**: 269-272 [DOI: 10.3760/cma.j.issn.0253-3006.2015.04.007]
 - 6 **Yao W, Dong KR, Xiao XM, Zheng JC, Li Km, Liu XQ, Liu BH, Zheng S.** [Associating liver partition and portal vein ligation for staged hepatectomy for hepatoblastoma: a report of one case]. *Zhonghua Xiaer Waik Zazhi* 2018; **39**: 597-603 [DOI: 10.3760/cma.j.issn.0253-3006.2018.08.009]
 - 7 **Murphy AJ, Rauth TP, Lovvorn HN 3rd.** Chronic biloma after right hepatectomy for stage IV hepatoblastoma managed with Roux-en-Y biliary cystenterostomy. *J Pediatr Surg* 2012; **47**: e5-e9 [PMID: 23164033 DOI: 10.1016/j.jpedsurg.2012.06.007]
 - 8 **Du CX, Li JX, Li DR, Su MB, Ya XQ, Wang WB, Liu JH.** [A study comparing PTCD with ENBD on jaundiced patients before laparoscopic pancreaticoduodenectomy]. *Zhonghua Gandan Waik Zazhi* 2022; **28**: 4 [DOI: 10.3760/cma.j.cn113884-20210621-00201]
 - 9 **Sun D, Liu YG, Yang JQ, Liu S, Zhu GQ.** [Therapeutic effect of PTCD in combination with ERCP on malignant obstructive jaundice]. *Zhonghua Gandan Waik Zazhi* 2010; **(4)**: 308-309 [DOI: 10.3760/cma.j.issn.1007-8118.2010.04.023]
 - 10 **Hildebrand T, Pannicke N, Dechene A, Gotthardt DN, Kirchner G, Reiter FP, Sterneck M, Herzer K, Lenzen H, Rupp C, Barg-Hock H, de Leuw P, Teufel A, Zimmer V, Lammert F, Sarrazin C, Spengler U, Rust C, Manns MP, Strassburg CP, Schramm C, Weismüller TJ; German PSC Study Group.** Biliary strictures and recurrence after liver transplantation for primary sclerosing cholangitis: A retrospective multicenter analysis. *Liver Transpl* 2016; **22**: 42-52 [PMID: 26438008 DOI: 10.1002/lt.24350]
 - 11 **Grönroos JM.** Endoscopic management of postcholecystectomy bile duct strictures. *J Am Coll Surg* 2008; **207**: 786-7; author reply 787 [PMID: 18954798 DOI: 10.1016/j.jamcollsurg.2008.08.001]
 - 12 **Kuroda Y, Tsuyuguchi T, Sakai Y, K C S, Ishihara T, Yamaguchi T, Saisho H, Yokosuka O.** Long-term follow-up evaluation for more than 10 years after endoscopic treatment for postoperative bile duct strictures. *Surg Endosc* 2010; **24**: 834-840 [PMID: 19730951 DOI: 10.1007/s00464-009-0673-2]
 - 13 **Jang JY, Yoon CH, Kim KM.** Endoscopic retrograde cholangiopancreatography in pancreatic and biliary tract disease in Korean children. *World J Gastroenterol* 2010; **16**: 490-495 [PMID: 20101777 DOI: 10.3748/wjg.v16.i4.490]
 - 14 **Park ET.** Endoscopic Retrograde Cholangiopancreatography in Bilioenteric Anastomosis. *Clin Endosc* 2016; **49**: 510-514 [PMID: 27838918 DOI: 10.5946/ce.2016.138]
 - 15 **Sun B, Yu D, Chen J, Tang Y, Wu H.** Endoscopic biliary drainage management for children with serious cholangitis caused by congenital biliary dilatation. *Pediatr Surg Int* 2018; **34**: 897-901 [PMID: 29872885 DOI: 10.1007/s00383-018-4296-3]



Published by **Baishideng Publishing Group Inc**
7041 Koll Center Parkway, Suite 160, Pleasanton, CA 94566, USA

Telephone: +1-925-3991568

E-mail: bpgoffice@wjgnet.com

Help Desk: <https://www.f6publishing.com/helpdesk>

<https://www.wjgnet.com>

