

World Journal of *Clinical Cases*

World J Clin Cases 2023 April 6; 11(10): 2123-2362



Contents

Thrice Monthly Volume 11 Number 10 April 6, 2023

EVIDENCE REVIEW

- 2123** Fractional flow reserve and non-hyperemic indices: Essential tools for percutaneous coronary interventions

Boutaleb AM, Ghafari C, Ungureanu C, Carlier S

REVIEW

- 2140** Diagnosis, treatment protocols, and outcomes of liver transplant recipients infected with COVID-19

Hashem M, El-Kassas M

MINIREVIEWS

- 2160** Treatment of stellate ganglion block in diseases: Its role and application prospect

Deng JJ, Zhang CL, Liu DW, Huang T, Xu J, Liu QY, Zhang YN

- 2168** Clinical application of SARS-CoV-2 antibody detection and monoclonal antibody therapies against COVID-19

Sun J, Yang ZD, Xie X, Li L, Zeng HS, Gong B, Xu JQ, Wu JH, Qu BB, Song GW

- 2181** Cheesy material on macroscopic on-site evaluation after endoscopic ultrasound-guided fine-needle biopsy: Don't miss the tuberculosis

Delsa H, Bellahammou K, Okasha HH, Ghalim F

- 2189** Liver manifestations in COVID-19 patients: A review article

Helou M, Nasr J, El Osta N, Jabbour E, Husni R

- 2201** Breast reconstruction: Review of current autologous and implant-based techniques and long-term oncologic outcome

Malekpour M, Malekpour F, Wang HTH

- 2213** Update on the current management of persistent and recurrent primary hyperparathyroidism after parathyroidectomy

Pavlidis ET, Pavlidis TE

ORIGINAL ARTICLE

Retrospective Study

- 2226** Hepatobiliary system and intestinal injury in new coronavirus infection (COVID-19): A retrospective study

Kozlov KV, Zhdanov KV, Ratnikova AK, Ratnikov VA, Tishkov AV, Grinevich V, Kravchuk YA, Miklush PI, Nikiforova PO, Gordienko VV, Popov AF, Andryukov BG

- 2237** Impact of lockdown policies during the COVID-19 outbreak on a trauma center of a tertiary hospital in China

Shen BS, Cheng WY, Liang ZR, Tang Q, Li KY

Observational Study

- 2246** Interaction between the left ventricular ejection fraction and left ventricular strain and its relationship with coronary stenosis
Gui HY, Liu SW, Zhu DF

CASE REPORT

- 2254** Neonatal hyperinsulinism with an *ABCC8* mutation: A case report
Liu MT, Yang HX
- 2260** Unilateral contrast-induced encephalopathy with contrast medium exudation: A case report
Zhang ZY, Lv H, Wang PJ, Zhao DY, Zhang LY, Wang JY, Hao JH
- 2267** Diagnosis and treatment of primary seminoma of the prostate: A case report and review of literature
Cao ZL, Lian BJ, Chen WY, Fang XD, Jin HY, Zhang K, Qi XP
- 2276** Primary intra-abdominal paraganglioma: A case report
Guo W, Li WW, Chen MJ, Hu LY, Wang XG
- 2282** Successful surgical treatment of bronchopleural fistula caused by severe pulmonary tuberculosis: A case report and review of literature
Shen L, Jiang YH, Dai XY
- 2290** Clinical and genetic features of Kenny-Caffey syndrome type 2 with multiple electrolyte disturbances: A case report
Yuan N, Lu L, Xing XP, Wang O, Jiang Y, Wu J, He MH, Wang XJ, Cao LW
- 2301** Dupilumab for treatment of severe atopic dermatitis accompanied by lichenoid amyloidosis in adults: Two case reports
Zhao XQ, Zhu WJ, Mou Y, Xu M, Xia JX
- 2308** Reabsorption of intervertebral disc prolapse after conservative treatment with traditional Chinese medicine: A case report
Wang CA, Zhao HF, Ju J, Kong L, Sun CJ, Zheng YK, Zhang F, Hou GJ, Guo CC, Cao SN, Wang DD, Shi B
- 2315** Development of subdural empyema from subdural effusion after suppurative encephalitis: A case report
Yang RX, Chen B, Zhang Y, Yang Y, Xie S, He L, Shi J
- 2321** Treatment of periprosthetic knee infection and coexistent periprosthetic fracture: A case report and literature review
Hao LJ, Wen PF, Zhang YM, Song W, Chen J, Ma T
- 2329** Formation of a rare curve-shaped thoracolith documented on serial chest computed tomography images: A case report
Hsu FC, Huang TW, Pu TW
- 2336** Neurofibromatosis type 1 with multiple gastrointestinal stromal tumors: A case report
Yao MQ, Jiang YP, Yi BH, Yang Y, Sun DZ, Fan JX

- 2343** Coexisting cytomegalovirus colitis in an immunocompetent patient with *Clostridioides difficile* colitis: A case report
Kim JH, Kim HS, Jeong HW
- 2349** Paradoxical vocal fold motion masquerading as post-anesthetic respiratory distress: A case report
Baek J, Jee DL, Choi YS, Kim SW, Choi EK
- 2355** Full neurological recovery from severe nonexertional heat stroke with multiple organ dysfunction: A case report
Du F, Zheng JW, Zhao YB, Yang K, Li HN

ABOUT COVER

Editorial Board Member of *World Journal of Clinical Cases*, Abdullah Gul, MD, PhD, Associate Professor, Department of Urology, University of Health Sciences Turkey, Bursa Yuksek Ihtisas Training and Research Hospital, Bursa 16310, Turkey. dr_abdullahgul@hotmail.com

AIMS AND SCOPE

The primary aim of *World Journal of Clinical Cases* (WJCC, *World J Clin Cases*) is to provide scholars and readers from various fields of clinical medicine with a platform to publish high-quality clinical research articles and communicate their research findings online.

WJCC mainly publishes articles reporting research results and findings obtained in the field of clinical medicine and covering a wide range of topics, including case control studies, retrospective cohort studies, retrospective studies, clinical trials studies, observational studies, prospective studies, randomized controlled trials, randomized clinical trials, systematic reviews, meta-analysis, and case reports.

INDEXING/ABSTRACTING

The WJCC is now abstracted and indexed in Science Citation Index Expanded (SCIE, also known as SciSearch®), Journal Citation Reports/Science Edition, Current Contents®/Clinical Medicine, PubMed, PubMed Central, Scopus, Reference Citation Analysis, China National Knowledge Infrastructure, China Science and Technology Journal Database, and Superstar Journals Database. The 2022 Edition of Journal Citation Reports® cites the 2021 impact factor (IF) for WJCC as 1.534; IF without journal self cites: 1.491; 5-year IF: 1.599; Journal Citation Indicator: 0.28; Ranking: 135 among 172 journals in medicine, general and internal; and Quartile category: Q4. The WJCC's CiteScore for 2021 is 1.2 and Scopus CiteScore rank 2021: General Medicine is 443/826.

RESPONSIBLE EDITORS FOR THIS ISSUE

Production Editor: *Xu Guo*; Production Department Director: *Xiang Li*; Editorial Office Director: *Jin-Lei Wang*.

NAME OF JOURNAL

World Journal of Clinical Cases

ISSN

ISSN 2307-8960 (online)

LAUNCH DATE

April 16, 2013

FREQUENCY

Thrice Monthly

EDITORS-IN-CHIEF

Bao-Gan Peng, Jerzy Tadeusz Chudek, George Kontogeorgos, Maurizio Serati, Ja Hyeon Ku

EDITORIAL BOARD MEMBERS

<https://www.wjgnet.com/2307-8960/editorialboard.htm>

PUBLICATION DATE

April 6, 2023

COPYRIGHT

© 2023 Baishideng Publishing Group Inc

INSTRUCTIONS TO AUTHORS

<https://www.wjgnet.com/bpg/gerinfo/204>

GUIDELINES FOR ETHICS DOCUMENTS

<https://www.wjgnet.com/bpg/GerInfo/287>

GUIDELINES FOR NON-NATIVE SPEAKERS OF ENGLISH

<https://www.wjgnet.com/bpg/gerinfo/240>

PUBLICATION ETHICS

<https://www.wjgnet.com/bpg/GerInfo/288>

PUBLICATION MISCONDUCT

<https://www.wjgnet.com/bpg/gerinfo/208>

ARTICLE PROCESSING CHARGE

<https://www.wjgnet.com/bpg/gerinfo/242>

STEPS FOR SUBMITTING MANUSCRIPTS

<https://www.wjgnet.com/bpg/GerInfo/239>

ONLINE SUBMISSION

<https://www.f6publishing.com>

Dupilumab for treatment of severe atopic dermatitis accompanied by lichenoid amyloidosis in adults: Two case reports

Xue-Qi Zhao, Wen-Jing Zhu, Yan Mou, Meng Xu, Jian-Xin Xia

Specialty type: Medicine, research and experimental

Provenance and peer review: Unsolicited article; Externally peer reviewed.

Peer-review model: Single blind

Peer-review report's scientific quality classification

Grade A (Excellent): 0
Grade B (Very good): B
Grade C (Good): C
Grade D (Fair): 0
Grade E (Poor): 0

P-Reviewer: Rolla G, Italy;
Teragawa H, Japan

Received: December 4, 2022

Peer-review started: December 4, 2022

First decision: February 7, 2023

Revised: February 18, 2023

Accepted: March 14, 2023

Article in press: March 14, 2023

Published online: April 6, 2023



Xue-Qi Zhao, Wen-Jing Zhu, Yan Mou, Meng Xu, Jian-Xin Xia, Department of Dermatology, The Second Hospital of Jilin University, Changchun 130041, Jilin Province, China

Corresponding author: Jian-Xin Xia, MD, PhD, Professor, Department of Dermatology, The Second Hospital of Jilin University, No. 218 Ziqiang Street, Nangan District, Changchun 130041, Jilin Province, China. 911469806@qq.com

Abstract

BACKGROUND

Lichenoid amyloidosis (LA) is a subtype of primary cutaneous amyloidosis characterized by persistent multiple groups of hyperkeratotic papules, usually on the lower leg, back, forearm, or thigh. LA may be associated with several skin diseases, including atopic dermatitis (AD). The treatment of LA is considered to be difficult. However, as there is some overlap in the etiopathogenesis of LA and AD, AD treatment may also be effective for LA.

CASE SUMMARY

Case 1: A 70-year-old man was diagnosed with severe AD with LA based on large dark erythema and papules on the trunk and buttocks and dense hemispherical millet-shaped papules with pruritus on the extensor side of the lower limbs. He had a long history of the disease (8 years), with repeated and polymorphic skin lesions. Given the poor efficacy of traditional treatments, this patient was recommended to receive dupilumab treatment. At the initial stage, 300 mg was injected subcutaneously every 2 wk. After 28 wk, the drug interval was extended to 1 mo due to the pandemic. Follow-up observations revealed that the patient reached an Eczema Area Severity Index of 90 (skin lesions improved by 90% compared with the baseline) by the end of the study. Moreover, Investigator's Global Assessment score was 1, and scoring atopic dermatitis index and numeric rating scale improved by 97.7% and 87.5% compared with the baseline, respectively, with LA skin lesions having largely subsided. Case 2: A 30-year-old woman was diagnosed with severe AD with LA, due to dense and substantial papules on the dorsal hands similar to changes in cutaneous amyloidosis, and erythema and papules scattered on limbs and trunk with pruritus, present for 25 years. After 16 wk of dupilumab treatment, she stopped, and skin lesions completely subsided, without recurrence since the last follow-up.

CONCLUSION

Dupilumab shows rational efficacy and safety in the treatment of severe AD with

LA, in addition to benefits in the quality of life of the patients.

Key Words: Atopic dermatitis; Lichenoid amyloidosis; Dupilumab; Treatment; Case report

©The Author(s) 2023. Published by Baishideng Publishing Group Inc. All rights reserved.

Core Tip: Although cases of atopic dermatitis (AD) with lichenoid amyloidosis (LA) are not uncommon, there are few reports on the use of AD treatment for LA. In this paper, two adult patients with severe AD and LA are described. Treatment with dupilumab significantly improved the AD and LA skin lesions with no adverse reactions, confirming the efficacy and safety of dupilumab in the treatment of AD with LA, and providing a reference for clinically similar diseases.

Citation: Zhao XQ, Zhu WJ, Mou Y, Xu M, Xia JX. Dupilumab for treatment of severe atopic dermatitis accompanied by lichenoid amyloidosis in adults: Two case reports. *World J Clin Cases* 2023; 11(10): 2301-2307

URL: <https://www.wjgnet.com/2307-8960/full/v11/i10/2301.htm>

DOI: <https://dx.doi.org/10.12998/wjcc.v11.i10.2301>

INTRODUCTION

Atopic dermatitis (AD), a chronic recurrent disease driven by type-2 inflammation, is clinically characterized as chronic eczematoid manifestations[1]. Lichenoid amyloidosis (LA) is a subtype of primary cutaneous amyloidosis, which is characterized by persistent multiple groups of hyperkeratotic papules, usually in the lower leg, back, forearm, or thigh[2]. It has been demonstrated that primary cutaneous amyloidosis is associated with AD, with an elusive mechanism[3-5]. Dupilumab, a human monoclonal antibody targeting for interleukin (IL)-4/13 receptor α chain, can inhibit the development of type-2 inflammation, and has shown promising efficacy and safety in the treatment of medium and severe AD [6,7]. Currently, there are cases reported that dupilumab may hold promise in the treatment of AD-related LA, but with minor cases, and few studies focused on the changes of skin lesions after drug withdrawal and the efficacy and safety of the long-term application. This paper reports two cases of severe AD with LA in adults. The patients were treated with subcutaneous dupilumab injection after ineffective traditional treatment. In case 1, the skin lesions of AD and LA virtually disappeared after long-term application of dupilumab, with promising efficacy and safety. In case 2, the skin lesions of AD and LA skin lesions disappeared after dupilumab treatment, without recurrence after discontinuation.

CASE PRESENTATION

Chief complaints

Case 1: On August 12, 2021, a 70-year-old man was admitted to our department due to the appearance of large dark erythematous papules on his trunk and buttocks, together with dense hemispherical millet granular miliary papules with itching on the extensor sides of his lower limbs.

Case 2: On December 21, 2020, a 30-year-old woman was admitted to our department due to substantial dense papules on the back of her hands and scattered erythema, papules, and itching on her limbs and torso.

History of present illness

Case 1: A 70-year-old man developed erythema and papules on his lower limbs 8 years ago, and pruritus. He was diagnosed with chronic eczema at a local hospital and treated with a Chinese medicine decoction. He stopped taking this medicine after most skin lesions subsided. The patient subsequently complained of mildly symptomatic recurrent skin lesions following the cessation of treatment. The patient did not seek further treatment at this time. Three years ago, he was diagnosed with AD at the Dermatology Department of the Second Hospital of Jilin University. Treatment with a topical glucocorticoid and oral levocetirizine controlled the skin lesions and prevented recurrence. However, two years ago, the skin lesions became aggravated without obvious inducement and spread to the entire body. Dense, hemispherical, millet-shaped papules appeared on the extensor surfaces of both lower limbs. The patient's condition did not improve despite self-medication with traditional Chinese medicine and a topical glucocorticoid and the patient experienced expanded skin lesions and sleep severely affected by

pruritus. In August 2021, he visited our department for further treatment.

Case 2: A 30-year-old woman developed several coin-sized erythema lesions and papules on her hips and both lower limbs along with pruritus without obvious inducement 25 years ago. She was diagnosed with chronic eczema at a local hospital and was treated with a topical glucocorticoid and oral loratadine. Following treatment, the skin lesions partially subsided, with occasional recurrence. Two years ago, the patient developed dense erythema and papules covered by small scales, keratosis, and chapped skin on the dorsal side of both hands. After self-medication with antihistamines and a topical glucocorticoid, the skin lesions showed no improvement and gradually progressed to the elbows and trunk. Concomitantly, her pruritus severely affected her sleep. In December 2020, she visited our department for further treatment.

History of past illness

Case 1: The patient's past history was unremarkable.

Case 2: The patient had a history of allergic rhinitis for 5 years, which aggravated in autumn every year. Oral loratadine or levocetirizine was required to relieve the allergic rhinitis.

Personal and family history

Case 1: There was no family history of similar disease.

Case 2: The patient's grandfather and aunt suffered from allergic rhinitis.

Physical examination

Case 1: Systemic examination revealed no obvious abnormalities. The dermatological conditions included dryness of the skin over the whole body, while the trunk and buttocks showed extensive dark erythema and papules. The skin lesions were thickened, lichenized, and pruritic. Similarly, dense hemispherical millet-shaped papules were observed on the lateral sides of both lower legs, with scattered erythema and papules on both feet (Figure 1A and B). The scoring atopic dermatitis index (SCORAD), Eczema Area Severity Index (EASI), numeric rating scale (NRS), and Investigator's Global Assessment (IGA) scores were 60.8, 13.5, 8, and 4, respectively.

Case 2: Systemic examination revealed no obvious abnormalities. Dermatological conditions included dry skin affecting the entire body, chapping erythema covered by a few scales affecting the palms of both hands, densely filled millet grain-to-sorghum grain-sized papules on the dorsal surface of both hands with keratinized surfaces reminiscent of cutaneous amyloidosis, thick and lichenized lesions on both elbows and feet, erythema and papules scattered on the trunk, and scratches and blood scabs on the buttocks (Figure 2A and B). SCORAD, EASI, NRS, and IGA scores were 53.1, 13.1, 7, and 4, respectively.

Laboratory examinations

Case 1: Routine blood analysis showed an eosinophil count of $1.96 \times 10^9/L$.

Case 2: Allergen-specific immunoglobulin E: Artemisia > 100 IU/mL, positive value: 6.0; ragweed: 9.4 IU/mL, positive value: 3.4.

Imaging examinations

Case 1: Histopathology of dense papules on the extensor surface of the lower leg showed amorphous amyloid lump deposition with mild eosinophilic staining in the dermal papillary layer, which was consistent with amyloidosis (Figure 3).

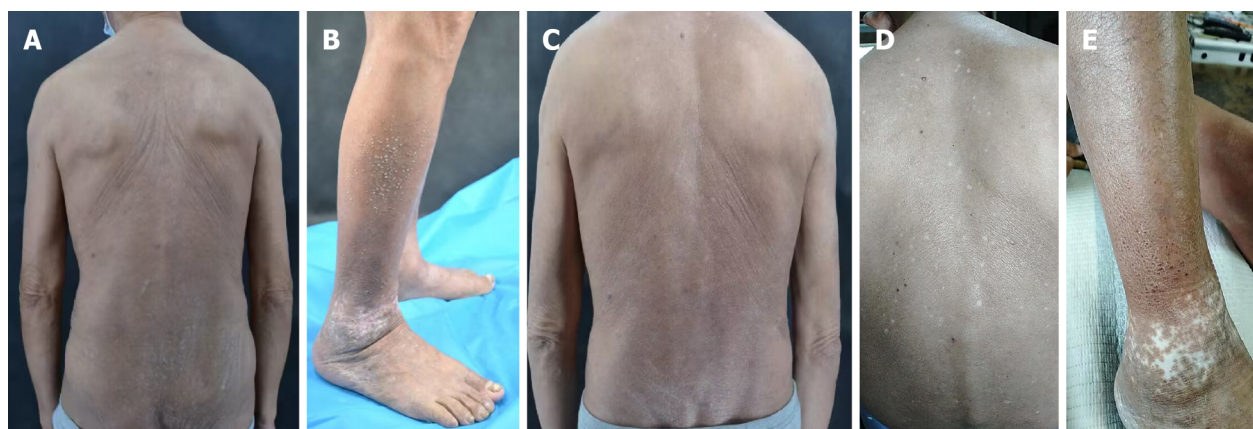Case 2: No histological examination was performed because the patient refused invasive examination.

FINAL DIAGNOSIS

Severe AD accompanied by LA.

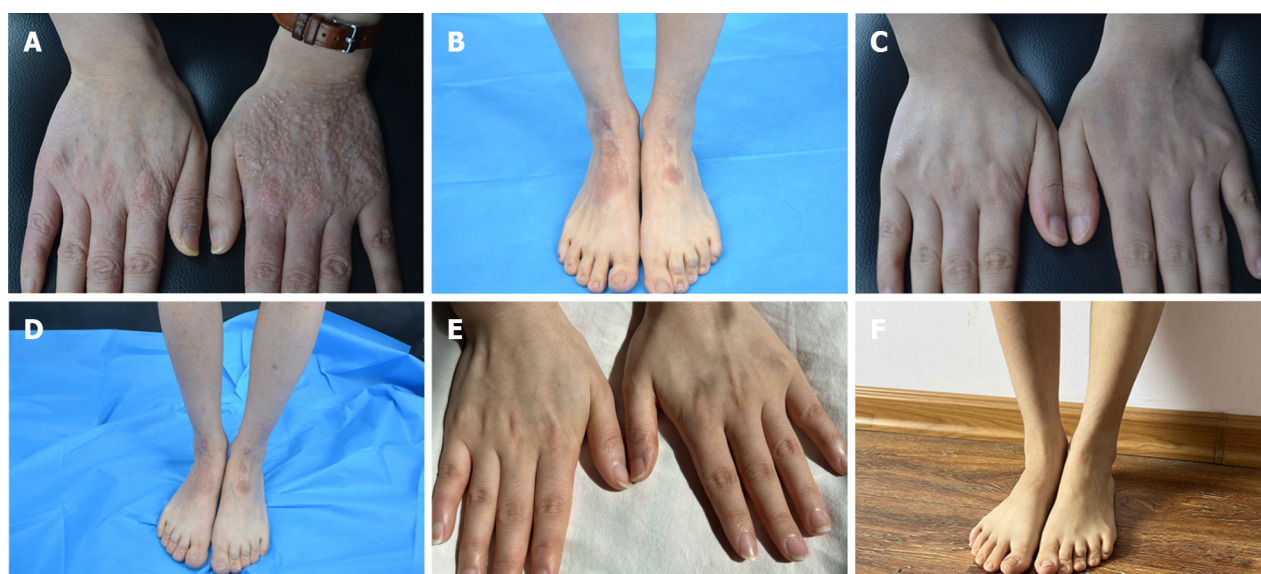
TREATMENT

A designated staff assigned to cases 1 and 2 independently collected the basic information, clinical features, medical history, drug allergy history, and family history of the patients and established personal AD files. Both patients received an initial subcutaneous injection of 600 mg dupilumab followed by 300 mg every 2 wk. During the treatment period, the patients were followed regularly,



DOI: 10.12998/wjcc.v11.i10.2301 Copyright ©The Author(s) 2023.

Figure 1 Skin lesions at various follow-up time points of patient 1 after the application of dupilumab to the lesions. A: Skin lesions on the back before the treatment of dupilumab; B: Skin lesions on both lower limbs before the treatment of dupilumab; C: Posterior trunk at 16-wk follow-up; D: Back at 55-wk follow-up; E: Skin lesions on both lower limbs at 55-wk follow-up.



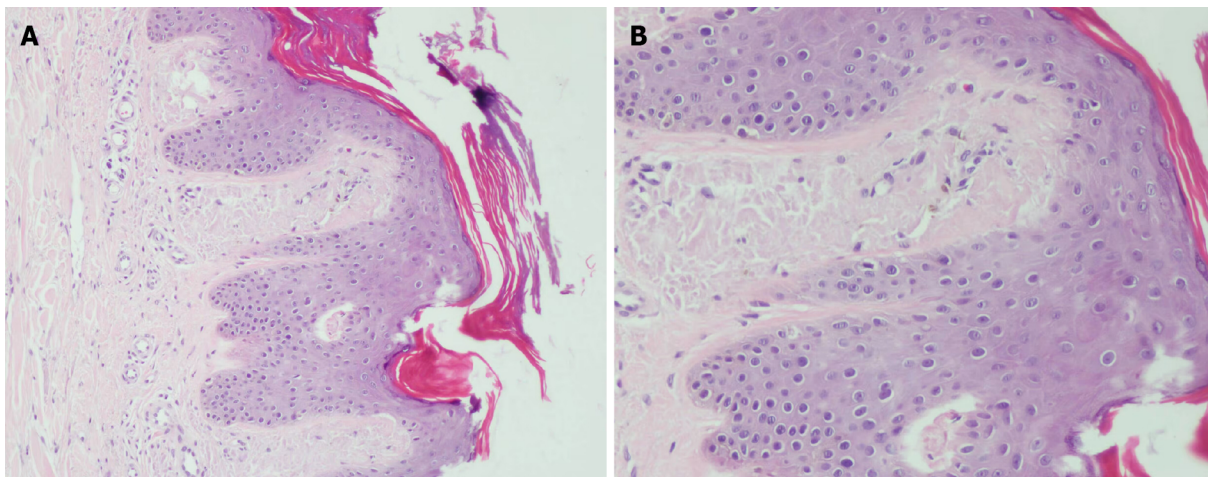
DOI: 10.12998/wjcc.v11.i10.2301 Copyright ©The Author(s) 2023.

Figure 2 Skin lesions at various follow-up time points of patient 2 after application of dupilumab to the lesions. A: Skin lesions of hands before the treatment of dupilumab; B: Skin lesions of both lower limbs before the treatment of dupilumab; C: 16-wk follow-up; D: 16-wk follow-up; E: Hands 1.5 year post-treatment follow-up; F: Lower limbs 1.5 years post-treatment follow-up.

during which the skin lesions were photographed, SCORAD, EASI, NRS, and IGA were recorded, and the incidence of any adverse reactions was noted.

OUTCOME AND FOLLOW-UP

Case 1: The patient was first treated with dupilumab on August 21, 2021. The pruritus was relieved after 1 wk and the skin lesions improved after 4 wk. During the treatment, all scores continued to decline, without adverse reactions. After 16 wk of treatment, most skin lesions had improved, and papules on both legs had partially flattened. In the 28th week (February 8, 2022), most of the skin lesions had subsided with some pigmentation remaining on the trunk and buttocks, without recurrence. The skin over the entire body was still dry, and the patient was advised to use external moisturizing emollients regularly. SCORAD, EASI, NRS, and IGA scores were 7.1, 2.3, 2, and 1, respectively (Figure 1C). Due to the access limitations associated with the COVID-19 pandemic, the subcutaneous injection of dupilumab was adjusted to 300 mg every month. The patient was treated with dupilumab for a total of 55 wk, after which the skin lesions of the whole body had largely subsided, without adverse reactions during the



DOI: 10.12998/wjcc.v11.i10.2301 Copyright ©The Author(s) 2023.

Figure 3 Skin histopathology. A: Amorphous amyloid lump deposition with mild eosinophilic staining in the dermal papillary layer, consistent with amyloidosis (hematoxylin-eosin staining, 100 ×); B: Amorphous amyloid lump deposition with mild eosinophilic staining in the dermal papillary layer, consistent with amyloidosis (hematoxylin-eosin staining, 400 ×).

treatment (Figure 1D and E). SCORAD, EASI, NRS, and IGA scores were 1.4, 1.2, 1, and 1, respectively, reaching EASI90 (skin lesions improved by 90% from baseline). Notably, SCORAD and NRS scores improved by 97.7% and 87.5% from baseline, respectively.

Case 2: The patient was first treated with dupilumab on December 21, 2020. The pruritus was relieved after 1 wk, and the skin lesions improved after 2 wk of treatment. During the treatment, all scores continued to decline, without adverse reactions. The final injection was administered on April 9, 2021, by which the patient had received a total of eight dupilumab injections. At this point, the skin lesions had completely subsided and with each score reaching 0 (Figure 2C and D). The last follow-up was done 1.5 years since the termination of drug treatment, and no recurrence of skin lesions was observed. The symptoms of allergic rhinitis were also significantly improved, and no further medical treatment was deemed necessary (Figure 2E and F).

DISCUSSION

AD, a chronic recurrent disease driven by type-2 inflammation, is clinically characterized by chronic eczematoid manifestations with pruritus, which can be diagnosed according to the previously reported clinical criteria[1,8]. In addition to eczematoid manifestations, the skin lesions of the two patients in this study exhibited lichen amyloidosis, a subtype of primary cutaneous amyloidosis which manifested as numerous persistent groups of hyperkeratotic papules, usually on the lower leg, back, forearm or thigh [2]. It was first proposed by Shanon *et al*[9] in 1970 that cutaneous amyloidosis was related to atopic disease. Currently, studies have found that AD is related to primary cutaneous amyloidosis; however, the exact mechanism remains elusive[3-5]. Primary cutaneous amyloidosis can be caused by the deposition of skin amyloid protein through the "itching-scratching" cycle. Since AD patients generally have pruritus, it is currently believed that the destruction of the skin barrier in AD through chronic scratching and friction can lead to the damage and death of keratinocytes and the subsequent deposition of amyloid protein, resulting in amyloidosis[10,11]. The treatment of AD is typically individualized and different treatment methods are selected according to the severity of the disease. Moderate and severe AD patients can be treated with topical drugs, systemic drugs, and immunosuppressants[12]. In our study, two patients with a long history of repeated dermatological illness were selected and treated with dupilumab based on the inefficacies of the traditional medicines that had been trialed in these patients previously. Dupilumab is a human monoclonal antibody that targets the receptor for Th2 cytokines IL-4/13 (IL-4 receptor α chain), thereby inhibiting type-2 inflammation by blocking the pro-inflammatory effects of IL-4/13[6]. It has been demonstrated that dupilumab effectively inhibits type-2 pathway genes as early as the 4th week of treatment, and significantly improves the clinical efficacy indexes of AD in the 16th week of treatment[13].

Currently, several treatments exist for primary cutaneous amyloidosis associated with AD, including oral antihistamines, CO₂ laser, cyclosporine, and acitretin. However, it is proven difficult to achieve complete skin lesion regression through these methods[14-17]. Primary cutaneous amyloidosis is related to pruritus, and IL-4 and IL-13 have been shown to promote pruritus *via* their role in the type-2 inflammation pathway. Thus, dupilumab may relieve pruritus and inhibit the development of amyloidosis by

blocking the effects of IL-4 and IL-13[18]. However, the specific mechanism of dupilumab in the treatment of primary cutaneous amyloidosis has not been clarified. Previous studies have detected increased expression of IL-31 in the skin lesions of patients with familial primary cutaneous amyloidosis. IL-31 is also one of the pro-pruritus factors secreted by Th2 cells. Dupilumab can indirectly inhibit the secretion of IL-31 by Th2 cells by inhibiting type-2 inflammation, and therefore may exert beneficial effects in primary cutaneous amyloidosis through this mechanism[19,20]. To date, there is one case where remission of AD-related lichen amyloidosis skin lesions was achieved after treatment with dupilumab, indicating that dupilumab can have a therapeutic benefit in AD-related amyloidosis[11]. In this study, case 1 experienced reduced pruritus after one week of dupilumab. To date, the skin lesions of lichen amyloidosis have largely subsided in this patient, without adverse reactions, demonstrating that dupilumab has a rational efficacy against AD-related lichen amyloidosis, and long-term treatment can achieve skin lesion control with high safety. In case 2, the skin lesions of lichen amyloidosis completely subsided 16 wk after dupilumab was applied, and have not recurred since the termination of treatment, indicating that dupilumab may inhibit the recurrence of AD-related lichen amyloidosis on the basis of its therapeutic effect.

CONCLUSION

In this study, the treatment of AD with dupilumab substantially reduced the appearance of skin lesions in two patients with lichen amyloidosis. Long-term treatment of dupilumab for AD and lichen amyloidosis in case 1 was deemed effective and safe. In case 2, there was no recurrence of skin lesions of AD and lichen amyloidosis following termination of treatment. Moreover, compared to the previous traditional treatments, dupilumab was more effective and deemed safe in the treatment of AD and its associated amyloidosis. The above two cases further indicate that the treatments indicated for AD may also have rational efficacy against AD-related lichen amyloidosis.

ACKNOWLEDGEMENTS

We thank the patients and their family members for their support.

FOOTNOTES

Author contributions: Zhao XQ and Xia JX contributed to study conception and design, and data collection and analysis; Zhu WJ contributed to study conception and design, and data collection; Mou Y and Xu M contributed to data collection and analysis; all authors issued final approval for the version to be submitted.

Supported by National Natural Science Foundation of China, No. 81803160; and Scientific Development Program of Jilin Province, No. 20200801078GH.

Informed consent statement: Informed consent was obtained from the patients for publication of this report and any accompanying images.

Conflict-of-interest statement: All the authors report no relevant conflicts of interest for this article.

CARE Checklist (2016) statement: The authors have read the CARE Checklist (2016), and the manuscript was prepared and revised according to the CARE Checklist (2016).

Open-Access: This article is an open-access article that was selected by an in-house editor and fully peer-reviewed by external reviewers. It is distributed in accordance with the Creative Commons Attribution NonCommercial (CC BY-NC 4.0) license, which permits others to distribute, remix, adapt, build upon this work non-commercially, and license their derivative works on different terms, provided the original work is properly cited and the use is non-commercial. See: <https://creativecommons.org/licenses/by-nc/4.0/>

Country/Territory of origin: China

ORCID number: Xue-Qi Zhao 0000-0003-2174-5936; Wen-Jing Zhu 0000-0003-1253-0503; Yan Mou 0000-0002-9152-6301; Meng Xu 0000-0001-7131-4320; Jian-Xin Xia 0000-0002-0067-2910.

Corresponding Author's Membership in Professional Societies: Dermatopathology Group, Pathology Branch of Chinese Medical Association.

S-Editor: Fan JR

L-Editor: Wang TQ

P-Editor: Fan JR

REFERENCES

- 1 Ständer S. Atopic Dermatitis. *N Engl J Med* 2021; **384**: 1136-1143 [PMID: 33761208 DOI: 10.1056/NEJMra2023911]
- 2 Hamie L, Haddad I, Nasser N, Kurban M, Abbas O. Primary Localized Cutaneous Amyloidosis of Keratinocyte Origin: An Update with Emphasis on Atypical Clinical Variants. *Am J Clin Dermatol* 2021; **22**: 667-680 [PMID: 34286474 DOI: 10.1007/s40257-021-00620-9]
- 3 Lee DD, Huang CK, Ko PC, Chang YT, Sun WZ, Oyang YJ. Association of primary cutaneous amyloidosis with atopic dermatitis: a nationwide population-based study in Taiwan. *Br J Dermatol* 2011; **164**: 148-153 [PMID: 21070198 DOI: 10.1111/j.1365-2133.2010.10024.x]
- 4 Chia B, Tan A, Tey HL. Primary localized cutaneous amyloidosis: association with atopic dermatitis. *J Eur Acad Dermatol Venereol* 2014; **28**: 810-813 [PMID: 23489336 DOI: 10.1111/jdv.12144]
- 5 Akar A, Taştan HB, Demiriz M, Erbil H. Lack of effect of cyclosporine in lichen amyloidosis associated with atopic dermatitis. *Eur J Dermatol* 2002; **12**: 612-614 [PMID: 12459544]
- 6 Gooderham MJ, Hong HC, Eshtiaghi P, Papp KA. Dupilumab: A review of its use in the treatment of atopic dermatitis. *J Am Acad Dermatol* 2018; **78**: S28-S36 [PMID: 29471919 DOI: 10.1016/j.jaad.2017.12.022]
- 7 Halling AS, Loft N, Silverberg JI, Guttman-Yassky E, Thyssen JP. Real-world evidence of dupilumab efficacy and risk of adverse events: A systematic review and meta-analysis. *J Am Acad Dermatol* 2021; **84**: 139-147 [PMID: 32822798 DOI: 10.1016/j.jaad.2020.08.051]
- 8 Liu P, Zhao Y, Mu ZL, Lu QJ, Zhang L, Yao X, Zheng M, Tang YW, Lu XX, Xia XJ, Lin YK, Li YZ, Tu CX, Yao ZR, Xu JH, Li W, Lai W, Yang HM, Xie HF, Han XP, Xie ZQ, Nong X, Guo ZP, Deng DQ, Shi TX, Zhang JZ. Clinical Features of Adult/Adolescent Atopic Dermatitis and Chinese Criteria for Atopic Dermatitis. *Chin Med J (Engl)* 2016; **129**: 757-762 [PMID: 26996468 DOI: 10.4103/0366-6999.178960]
- 9 Shanon J. Cutaneous amyloidosis associated with atopic disorders. *Dermatologica* 1970; **141**: 297-302 [PMID: 5487488 DOI: 10.1159/000252484]
- 10 Fujisawa T, Shu E, Ikeda T, Seishima M. Primary localized cutaneous nodular amyloidosis that appeared in a patient with severe atopic dermatitis. *J Dermatol* 2012; **39**: 312-313 [PMID: 21767295 DOI: 10.1111/j.1346-8138.2011.01247.x]
- 11 Aoki K, Ohyama M, Mizukawa Y. A case of lichen amyloidosis associated with atopic dermatitis successfully treated with dupilumab: A case report and literature review. *Dermatol Ther* 2021; **34**: e15005 [PMID: 34037298 DOI: 10.1111/dth.15005]
- 12 Goh MS, Yun JS, Su JC. Management of atopic dermatitis: a narrative review. *Med J Aust* 2022; **216**: 587-593 [PMID: 35644531 DOI: 10.5694/mja2.51560]
- 13 Guttman-Yassky E, Bissonnette R, Ungar B, Suárez-Fariñas M, Ardeleanu M, Esaki H, Suprun M, Estrada Y, Xu H, Peng X, Silverberg JI, Menter A, Krueger JG, Zhang R, Chaudhry U, Swanson B, Graham NMH, Pirozzi G, Yancopoulos GD, D Hamilton JD. Dupilumab progressively improves systemic and cutaneous abnormalities in patients with atopic dermatitis. *J Allergy Clin Immunol* 2019; **143**: 155-172 [PMID: 30194992 DOI: 10.1016/j.jaci.2018.08.022]
- 14 Kang MJ, Kim HS, Kim HO, Park YM. A case of atopic dermatitis-associated lichen amyloidosis successfully treated with oral cyclosporine and narrow band UVB therapy in succession. *J Dermatolog Treat* 2009; **20**: 368-370 [PMID: 19954395 DOI: 10.3109/09546630802691325]
- 15 Koh WS, Oh EH, Kim JE, Ro YS. Alitretinoin treatment of lichen amyloidosis. *Dermatol Ther* 2017; **30** [PMID: 28906049 DOI: 10.1111/dth.12537]
- 16 Chu H, Shin JU, Lee J, Park CO, Lee KH. Successful treatment of lichen amyloidosis accompanied by atopic dermatitis by fractional CO(2) laser. *J Cosmet Laser Ther* 2017; **19**: 345-346 [PMID: 28535110 DOI: 10.1080/14764172.2017.1326612]
- 17 Oiso N, Yudate T, Kawara S, Kawada A. Successful treatment of lichen amyloidosis associated with atopic dermatitis using a combination of narrowband ultraviolet B phototherapy, topical corticosteroids and an antihistamine. *Clin Exp Dermatol* 2009; **34**: e833-e836 [PMID: 20055846 DOI: 10.1111/j.1365-2230.2009.03574.x]
- 18 Moniaga CS, Tominaga M, Takamori K. The Pathology of Type 2 Inflammation-Associated Itch in Atopic Dermatitis. *Diagnostics (Basel)* 2021; **11** [PMID: 34829437 DOI: 10.3390/diagnostics11112090]
- 19 Schreml S. Is targeting interleukin-31 a cure for the itch? *Br J Dermatol* 2016; **174**: 1192-1193 [PMID: 27317285 DOI: 10.1111/bjd.14491]
- 20 Garcovich S, Maurelli M, Gisondi P, Peris K, Yosipovitch G, Girolomoni G. Pruritus as a Distinctive Feature of Type 2 Inflammation. *Vaccines (Basel)* 2021; **9** [PMID: 33807098 DOI: 10.3390/vaccines9030303]



Published by **Baishideng Publishing Group Inc**
7041 Koll Center Parkway, Suite 160, Pleasanton, CA 94566, USA

Telephone: +1-925-3991568

E-mail: bpgoffice@wjgnet.com

Help Desk: <https://www.f6publishing.com/helpdesk>

<https://www.wjgnet.com>

