

World Journal of *Immunology*

World J Immunol 2023 May 31; 13(1): 1-10



CASE REPORT

- 1 Challenges to associate early onset epilepsy with COVID-19 autoimmune encephalitis: A case report

Zouari Mallouli S, Jallouli O, Bouchaala W, Ben Nsir S, Kamoun Feki F, Charfi Triki C

ABOUT COVER

Editorial Board Member of *World Journal of Immunology*, Hakim Rahmoune, MD, Assistant Professor, Lecturer, Research Assistant Professor, Pediatrics, Setif University Hospital, Setif-1 University, Setif 19000, Setif, Algeria. rahmounehakim@gmail.com

AIMS AND SCOPE

The primary aim of *World Journal of Immunology* (WJI, *World J Immunol*) is to provide scholars and readers from various fields of immunology with a platform to publish high-quality basic and clinical research articles and communicate their research findings online.

WJI mainly publishes articles reporting research results and findings obtained in the field of immunology and covering a wide range of topics including allergy and asthma, and other hypersensitivities, antigen processing and presentation, antigen recognition and signal transduction, apoptosis, etc.

INDEXING/ABSTRACTING

The WJI is now abstracted and indexed in Reference Citation Analysis, China National Knowledge Infrastructure, China Science and Technology Journal Database, and Superstar Journals Database.

RESPONSIBLE EDITORS FOR THIS ISSUE

Production Editor: Mai-Xin Ji; Production Department Director: Xu Guo; Editorial Office Director: Li-Li Wang.

NAME OF JOURNAL

World Journal of Immunology

ISSN

ISSN 2219-2824 (online)

LAUNCH DATE

December 27, 2011

FREQUENCY

Continuous Publication

EDITORS-IN-CHIEF

Seung-Yong Seong, Hui-Ying Wang

EDITORIAL BOARD MEMBERS

<https://www.wjgnet.com/2219-2824/editorialboard.htm>

PUBLICATION DATE

May 31, 2023

COPYRIGHT

© 2023 Baishideng Publishing Group Inc

INSTRUCTIONS TO AUTHORS

<https://www.wjgnet.com/bpg/gerinfo/204>

GUIDELINES FOR ETHICS DOCUMENTS

<https://www.wjgnet.com/bpg/GerInfo/287>

GUIDELINES FOR NON-NATIVE SPEAKERS OF ENGLISH

<https://www.wjgnet.com/bpg/gerinfo/240>

PUBLICATION ETHICS

<https://www.wjgnet.com/bpg/GerInfo/288>

PUBLICATION MISCONDUCT

<https://www.wjgnet.com/bpg/gerinfo/208>

ARTICLE PROCESSING CHARGE

<https://www.wjgnet.com/bpg/gerinfo/242>

STEPS FOR SUBMITTING MANUSCRIPTS

<https://www.wjgnet.com/bpg/GerInfo/239>

ONLINE SUBMISSION

<https://www.f6publishing.com>



Challenges to associate early onset epilepsy with COVID-19 autoimmune encephalitis: A case report

Salma Zouari Mallouli, Olfa Jallouli, Wafa Bouchaala, Sihem Ben Nsir, Fatma Kamoun Feki, Chahnez Charfi Triki

Specialty type: Neurosciences

Provenance and peer review:

Unsolicited article; Externally peer reviewed.

Peer-review model: Single blind

Peer-review report's scientific quality classification

Grade A (Excellent): 0
Grade B (Very good): B, B
Grade C (Good): 0
Grade D (Fair): 0
Grade E (Poor): 0

P-Reviewer: Dey J, India; El Sayed S, Egypt

Received: December 11, 2022

Peer-review started: December 11, 2022

First decision: January 3, 2023

Revised: January 14, 2023

Accepted: February 2, 2023

Article in press: February 2, 2023

Published online: May 31, 2023



Salma Zouari Mallouli, Olfa Jallouli, Wafa Bouchaala, Sihem Ben Nsir, Fatma Kamoun Feki, Chahnez Charfi Triki, Department of Child Neurology, Hedi Chaker Sfax University Hospital and Research Laboratory LR19ES15-University of Sfax, Tunisia, Sfax 3029, Tunisia

Corresponding author: Salma Zouari Mallouli, Doctor, Medical Assistant, Department of Child Neurology, Hedi Chaker Sfax University Hospital and Research Laboratory LR19ES15-University of Sfax, El Ain Street Km 0.5, 3029 Sfax, Tunisia. mallouli.salma26@gmail.com

Abstract

BACKGROUND

Diagnosis of coronavirus disease 2019 (COVID-19)-related neurological events in the pediatric population is challenging. Overlapping clinical picture of children with altered neurological state and inborn errors of metabolism, in addition to the frequency of asymptomatic COVID-19 cases, pose the main challenges for diagnosis. Diagnostic approaches to the onset post-COVID 19 subacute encephalopathy are still troublesome as seronegative autoimmune encephalitis (AIE) is reported.

CASE SUMMARY

A 27-mo-old boy was admitted for stormy refractory seizure of polymorphic semiology and altered mental status followed by various neuropsychiatric features that were suggestive of AIE. Brain magnetic resonance imaging and cerebrospinal fluid analysis were normal. Neither the immunological assessment, including viral serologies, antinuclear antibodies, autoimmune antibodies (NMDA, AMPA, CASPR2, LG11, GABARB, Hu, Yo, Ri, CV2, PNMA2, SOX1, Titin, amphiphysin, Recoverin), nor the metabolic assessment for lactate and pyruvate showed significant anomaly. Both positive history of COVID-19 infection and the findings of characteristic repetitive extreme delta brush played a key role in the diagnosis of COVID-19-related AIE. A remarkable improvement in the state of the child was noted after two pulse doses of intravenous Veinoglobulin and high dose of intravenous Corticosteroid.

CONCLUSION

Diagnostic biomarkers for AIE might aid effective treatment.

Key Words: Post-COVID-19; Auto-immune encephalitis; Diagnosis biomarkers; Pediatric population; Delta brush sign; Autoimmune antibodies

Core Tip: Overlapping epileptic syndromes and etiologies in infancy constitute a real challenge to the diagnostic and therapeutic approach to autoimmune epilepsy related to post-coronavirus disease 2019 (COVID-19) autoimmune encephalitis (AIE). Indeed, epileptic seizures could entail the onset of seronegative form of post-COVID-19 AIE. Adequate seizure management and control might be hampered by potential misdiagnosis. Defining clinical and paraclinical biomarkers of seronegative form of post-COVID-19 AIE would enable early diagnosis and management, and better prognosis.

Citation: Zouari Mallouli S, Jallouli O, Bouchaala W, Ben Nsir S, Kamoun Feki F, Charfi Triki C. Challenges to associate early onset epilepsy with COVID-19 autoimmune encephalitis: A case report. *World J Immunol* 2023; 13(1): 1-10

URL: <https://www.wjgnet.com/2219-2824/full/v13/i1/1.htm>

DOI: <https://dx.doi.org/10.5411/wji.v13.i1.1>

INTRODUCTION

Since the outbreak of novel coronavirus 2 (SARS-CoV-2) in China in late December 2019, several acute and post-acute neurological events have been reported with the increasing number of infections[1]. These disorders were believed to arise either out of direct viral cytopathogenic effect in the acute phase or an indirect immune-mediated and vascular process in the post-acute phase. Recent literature on coronavirus disease 2019 (COVID-19)-related well-defined immune-mediated neurological conditions included central nervous system (CNS) disorders such as post-infectious immune encephalitis, CNS vasculitis, and myelitis as well as peripheral nervous system injury, mainly Guillain-Barre syndrome [2]. Although seizures occurred in conjunction with SARS-CoV-2 as acute symptomatic seizures or post-acute period due to brain immune response, little interest was given to seizure features and their underlying pathogenic mechanisms[3].

We here report an infant initially admitted for refractory seizures. Diagnosis and subsequent management of COVID-19-related AIE were delayed. Due to insufficient clinical and paraclinical biomarkers, it took a long time to establish the diagnostic criteria for a sero-negative form of autoimmune encephalitis (AIE). Data of similar cases were collected in order to establish clinical and para-clinical biomarkers for post-COVID-19 AIE diagnosis. Key words such as “COVID-19 related”, “neurological disorders”, neurological events”, “seizure”, “autoimmune encephalitis” were used to collect the data.

Despite the huge number of reports of different neurological disorders, data about the delayed development of neurological events after the onset of SARS-CoV-2 infection, and pathognomonic features of COVID-19-related features remain scarce. The causal link between COVID-19 and specific neurological manifestations has not been established yet. In addition, various factors should be considered before ascertaining the triggering role of COVID-19. Indeed, neurological symptoms may be due to COVID-19 systemic dysfunction including hypoxia, hypotension, electrolytic homeostasis disturbances, or even iatrogenic origin. Some COVID-19 patients seemed to be more prone to develop neurological events due to unknown genetic, demographic and/or environmental factors. Associating COVID-19 with neurological events is even more challenging in the pediatric population, especially those with prior disabling condition. Future studies on these factors would strengthen our understanding of neurological sequelae of COVID-19.

CASE PRESENTATION

Chief complaints

Epileptic seizures.

History of present illness

A 24-mo-old boy was admitted to our department for stormy onset of multifocal motor seizures.

History of past illness

Multifocal motor seizures occurred 2 wk after the child was infected with mild form of COVID-19 with flu-like syndrome.

Personal and family history

Medical and family histories were unremarkable.

Physical examination

On neurological examination, the child showed some behavioral changes with unsteadiness and over-activity. No further neurological focal signs were noted. There was no fever or headache. On video filmed seizure during hospitalization, the child often yielded focal elementary semiology with machining, slow eye and head deviation associated with autonomic changes such as pallor, labial cyanosis, and hyperventilation. The motor component was made of clonic movements. Electroencephalography (EEG) showed slowed background activity without inter-ictal epileptiform abnormalities (IEA) with a recording of a tonic-clonic focal motor seizure synchronous to frontal discharges. Another EEG performed in the setting of altered mental status and fluctuating awareness showed irregular anterior high amplitude slow waves alternating with short periods of low-voltage activity in favor of non-motor epileptic seizure (Figure 1A and E). Diagnosed with early onset of severe epilepsy, the child was kept on valproate (VPA; 30 mg/kg/d) and clonazepam (CLZ; 0.05 mg/kg/d).

Laboratory examinations

Repetitive peripheral blood biochemistry, C-reactive protein and blood cell count were found normal. Antinuclear antibodies and autoimmune antibodies serologies were negative. Cerebrospinal fluid (CSF) analysis was also normal. COVID-19 serology was positive.

Imaging examinations

Brain magnetic resonance imaging (MRI) showed no abnormalities.

MULTIDISCIPLINARY EXPERT CONSULTATION

After a seizure-free period of 2 wk, the child was readmitted for recurrent cluster seizures. Clinical seizure activity continued for several days despite anti-seizure medication (ASM) dose adjustment. Ultimately, the child developed a generalized motor status epilepticus requiring intensive care. Later, seizure control was maintained for one week with a higher dose of VPA (40 mg/kg/d). Then, the child exhibited another seizure storm with motor seizures of a tonic, clonic and myoclonic nature. At this stage, three standard EEGs found a global slowing of the background activity with Delta-brush activity. Abnormally extended and widespread spindles were also noticed (Figure 1A and F). Seizures were often accompanied by a slight increase in body temperature (38.5°C) without perceptible infectious site or biological inflammatory syndrome. Concurrently, the child showed restless sleep. Even on Levetiracetam (LVT; 20 mg/kg/d), the child ended up with a second refractory status epilepticus.

FINAL DIAGNOSIS

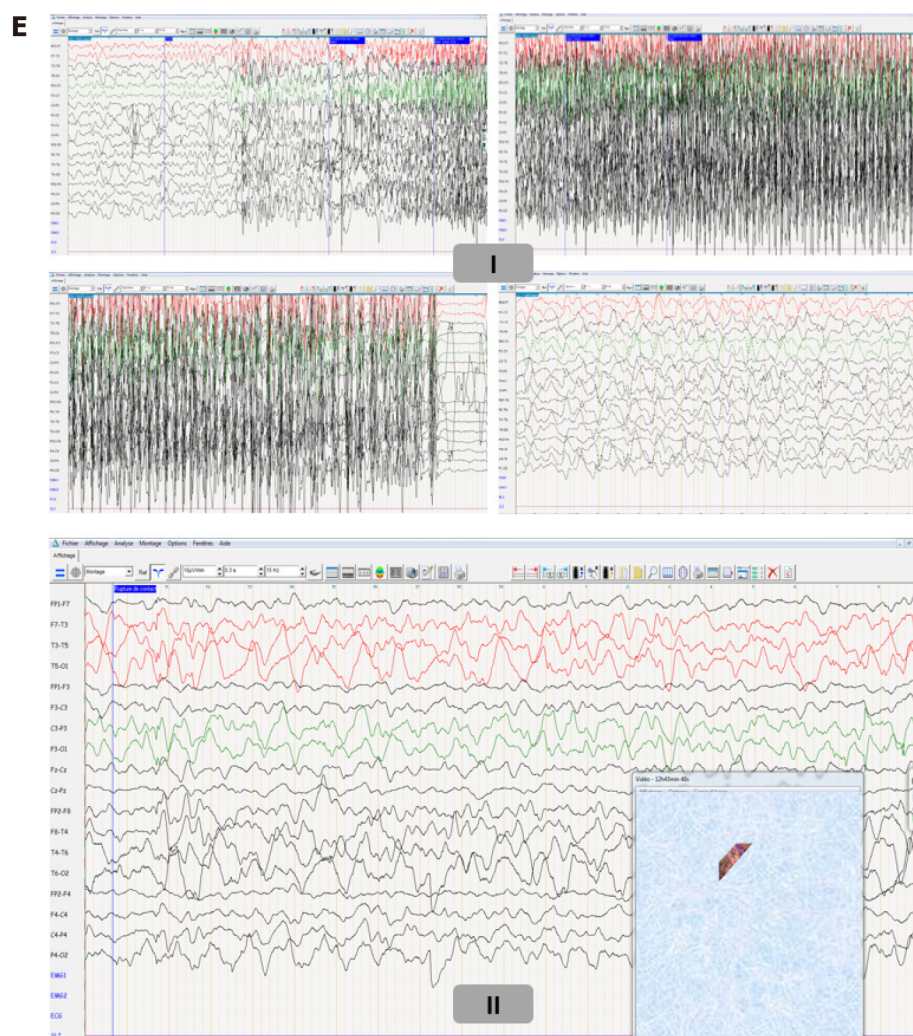
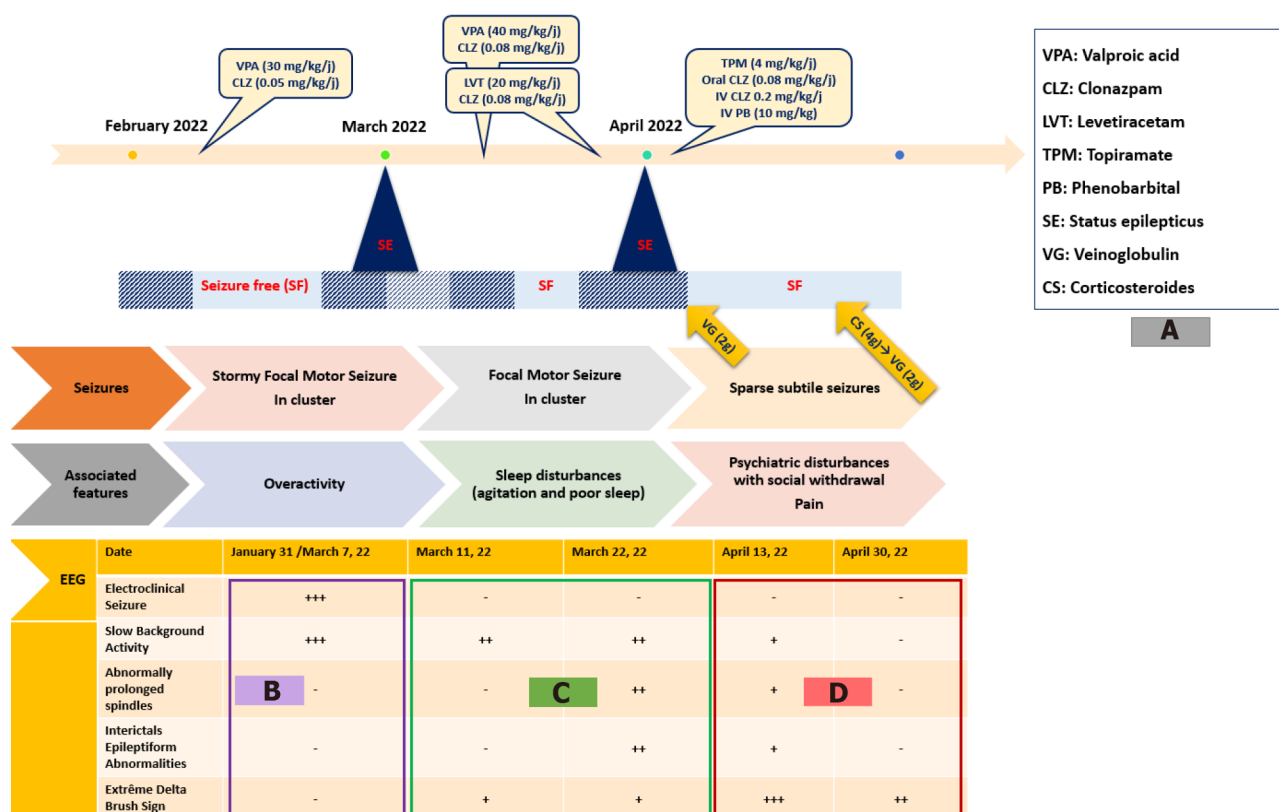
The child was diagnosed with autoimmune epilepsy due to post-COVID-19 AIE.


TREATMENT

Disease-modifying treatment with intravenous immunoglobulin (2 g/kg) was started in addition to switching to Topiramate with a good seizure control outcome. Over the monitoring period, social withdrawal and sleep moaning were noted. EEG recording at that time showed better awake and sleep background activity organization but higher load of IEA and the classic aspect of "extreme delta brush" (EDB) (Figure 1A and G). Thus, three weeks later, the child received a second immunoglobulin pulse (0.4/kg/d for 5 d) after administration of high-dose intravenous methylprednisolone (30 mg/kg/d for 4 d) relayed by oral corticosteroids. Second-line treatment such as Rituximab and cyclophosphamide has been avoided because it has no AMM in children. Several new therapies including proteasome inhibitors (bortezomib), (IL)-6 inhibitors (tocilizumab), IL-2 at low dose and anti-CD20 antibodies (Ocrelizumab) are still under test.

OUTCOME AND FOLLOW-UP

During hospitalization, the child still had some subtle and brief seizures with ataxic gait. At outpatient follow-up visit 6 mo later, gait was back to normal. According to his mother, sleep disturbances and behavioral problems had disappeared. However, the child uttered no more than single words. Follow-





DOI: 10.5411/wji.v13.i1.1 Copyright ©The Author(s) 2023.

Figure 1 Electroencephalography during and between epileptic seizures. A: The three-stage clinical disease course; B: electroencephalographic (EEG) disturbances during the first disease course; C: EEG disturbances during the second disease course; D: EEG disturbances during the third disease course; E: (I) Ictal EEG shows tonic-clonic focal motor seizure with synchronous rapid recruiting activity of left frontal origin which gradually increases in amplitude and frequency and diffuses to ipsilateral then contralateral cortex; (II) EEG during non-motor epileptic seizure shows irregular anterior high amplitude slow waves discharges alternating with short periods of low-voltage activity; F: EEG shows global slowing of the background activity with sparse surimposed delta brush activity (blue arrows) and

abnormally extended and widespread spindles (red box) during sleep; G: EEG shows high load of interictal epileptiform abnormalities (green box) and extreme delta brush sign (blue arrows) and better sleep organization with K complex followed by well-structured spindles (red box).

up EEG recorded electroclinical seizures made of tonic spasms.

DISCUSSION

Here we report the case of a child with refractory seizure who was later diagnosed with seronegative post-COVID 19 AIE. Clinical and para-clinical red flags that led to this diagnosis were highlighted.

Since the COVID-19 outbreak, few researches have been carried out on pediatric population [4-7]. Thus, there is insufficient data to establish specific recommendations in this regard [4]. By mid-November 2021, the spread of the SARS-CoV-2 Omicron variant was associated with a notable increase in COVID-19 pediatric cases [8,9]. Until late 2021, Alpha and Delta variants, which infected mainly adults, had been the most investigated COVID-19 cases [10]. Therefore, the clinical picture of adult COVID-19 patients with neurological manifestation was by far superior to reports on pediatric population. By 2022, the emergence of Omicron variant was a pivotal event. It prompted an insight on the neurological clinical picture of children with increasing pediatric COVID-19 cases. A wide spectrum of neurological symptoms has been reported. Among these, infant seizures were deemed as an inaugural sign of onset COVID-19 infection and later in the para-infectious period [1,11]. It is particularly challenging to establish a direct and unique cause-effect link between COVID-19 disease and seizure in this age range due to the already higher frequency of such neurological feature. The spectrum of SARS-CoV-2-related neurological features includes headache, intracranial hypertension, meningismus, altered mental status, stroke, seizure, brainstem and cerebellar signs, as well peripheral nervous system involvement. Neurological symptoms develop at some points of the disease course and may even constitute a part of the onset initial presentation [1,12,13]. A paper on Omicron variant in South Africa reported convulsions as a major reason for the hospitalization of pediatric COVID-19 patients [8]. However, seizure types and EEG features were not reported. The present report addresses diagnostic pitfalls of COVID-19 autoimmune encephalitis with inaugural seizures and three-stage electro-clinical disease course (Figure 1A-D). In the present case, delta brush sign on EEG and the response to immunomodulatory treatment were key elements for a definitive diagnosis of AIE.

Despite the growing association between COVID-19 and various neurological features, the causal link between the novel virus and onset neurological presentation has not been established with sufficient certainty. So far, there are no clear criteria, risk scores and definite biomarkers that sustain the plausible link. This seems an imminent need notably faced with onset seizure at early childhood, a life-period known for its higher frequency of certain epileptic syndromes and encephalopathies. A recent paper linked seizures at onset COVID-19 infection with fever or hypoxia due to upper respiratory distress falling into the umbrella of febrile or provoked seizures. However, the authors stressed a probable predisposition of male sex and some ethnic groups to onset COVID-19-related febrile seizures which had the peculiarity to occur outside the typical age range for febrile seizures [11]. Altogether seizures were not attributed to the direct effect of the virus but rather to the preexistent potential in some individuals to develop seizure, a condition mandatory for epilepsy definition [14]. As for seizures occurring after a delay from onset COVID-19 infection, AIE was the major underlying cause. According data from six papers reporting 14 pediatric SARS-CoV-2-related AIE cases, seven patients (4 girls and 3 boys) presented seizures. Two of these children had a history of chronic neurological condition including migraine and developmental disorders with autism and intellectual disability. About 42.8% of patients had seizures as their main presenting symptom. The others developed seizures in the course of the disease. Seizure types included cluster generalized tonic-clonic seizures (28.5%), migraine aura triggered seizures (14.2%) and status epilepticus (14.2%). Associated neurological features included mainly cognitive impairment (42.8%) followed by movement disorders (35.7%). Fever, altered mental status, behavioral changes and motor deficit were present in 28.5% children. Other features were in decreasing order of frequency - headache and ataxia (21.4%), psychiatric symptoms and sleep disturbances (14.2%) (Table 1; Figure 2A) [15-20]. Most reports focused on describing clinical picture whilst little interest was given to disease course. The three-stage disease course with alternate period of initial response and resistance to ASM found in this case was previously reported in a child with migraine-aura triggered seizure inaugurating a seronegative AIE [20]. Hence, it is still unclear whether such evolution arises only from underlying pathogenic process or a probable interaction between ASM and autoantibodies' target [21]. Previous studies on pediatric post-COVID-19 AIE reported a delay of diagnosis in three children. The delay was due to initial long-lasting mono-symptomatic presentation limited to epileptic seizures or isolated psychiatric features with transient improvement under brain-tropic molecules (LVT, Topiramate, atypical neuroleptic) as well as the failure of immunological assessment and neuroimaging to provide additional support elements [17,20]. The key diagnosis proof in the present report of post-COVID-19 seronegative AIE was evidenced by responsiveness to

Table 1 Clinical and paraclinical data reported in pediatric cases diagnosed as post-coronavirus disease 2019 auto-immune encephalitis

		Patient number
Clinical features	Epileptic seizures	7/14
	Cognitive impairment	6/14
	Motor deficit	4/14
	Movement disorders	5/14
	Ataxia	3/14
	Pain/Headache	4/14
	Behavioral changes	4/14
	Psychiatric features	2/14
Laboratory analysis	Cell blood count changes	6/14
	High C-reactive protein level	5/14
	High sedimentation velocity rate	3/14
	CSF analysis: Pleiocytosis	6/14
	High protein level	5/14
	High IgG index	1/14
	Auto-antibodies	8/14
Neuroimaging	Cortex involvement	4/14
	Basal ganglia involvement	2/14
	White matter involvement	6/14

CSF: Cerebrospinal fluid; IgG: Immunoglobulin G.

immunomodulatory treatment. The other less pronounced signs which gradually enrich the clinical picture can be attributed to a postictal state or an entry mode in an epileptic encephalopathy in a child with frequent and drug-resistant seizures. Later appearance of EDB sign sustained the diagnosis. While the stormy seizure period was associated with diffuse slow background activity, the occurrence of EDB sign was correlated with lower seizure activity and greater psychiatric problems. This finding is inconsistent with previous reports in which various EEG phenotypes were associated with anti-NMDA AIE. Among these, excessive beta activity and EDB are more likely to occur along with seizure and psychiatric symptoms, anxiety and cognitive impairment[22]. According to the literature, para-clinical biomarkers mostly include anterior cortex and subcortical white matter involvement on brain MRI (28.5%), lymphocytes rates changes (28.5%), lymphocytes pleiocytosis and high protein level on cerebrospinal fluid analysis (35.7%) and positive auto-immune antibodies mainly anti-NMDA (35.7%) (Table 1; Figure 2B). Although such biomarkers are not specific to post-COVID-19 AIE, response to immunomodulatory treatment was a hallmark of disease outcome in all reported cases, with complete recovery in 42.8% of patients, gradual improvement of one patient and incomplete recovery in 50% of patients. Residual symptoms included memory deficits (3/7), asomatognosia (1/7), psychiatric problems, ataxia, dysarthria and visual impairment (1/7)[15-20].

CONCLUSION

The diagnosis of seronegative AIE in the setting of onset first seizure especially after COVID-19 with long-lasting mono-symptomatic presentation is still challenging. Nevertheless, this case report supports previous studies which suggest the following biomarkers. Clinical biomarkers: Febrile seizure outside the typical age range for febrile convulsions; Stormy, in cluster refractory seizure of various types; Transient response to ASM. EEG biomarkers: Interictal focal or diffuse slowing; Abnormally extended and widespread sleep spindles; Delta brush sign. Biological biomarkers: Lymphocyte count changes; Lymphocytic pleiocytosis, high protein and immunoglobulin G level in CSF analysis. Neuroimaging biomarkers: Predominant involvement of anterior (frontal, temporal and parietal) cortex and basal ganglia.

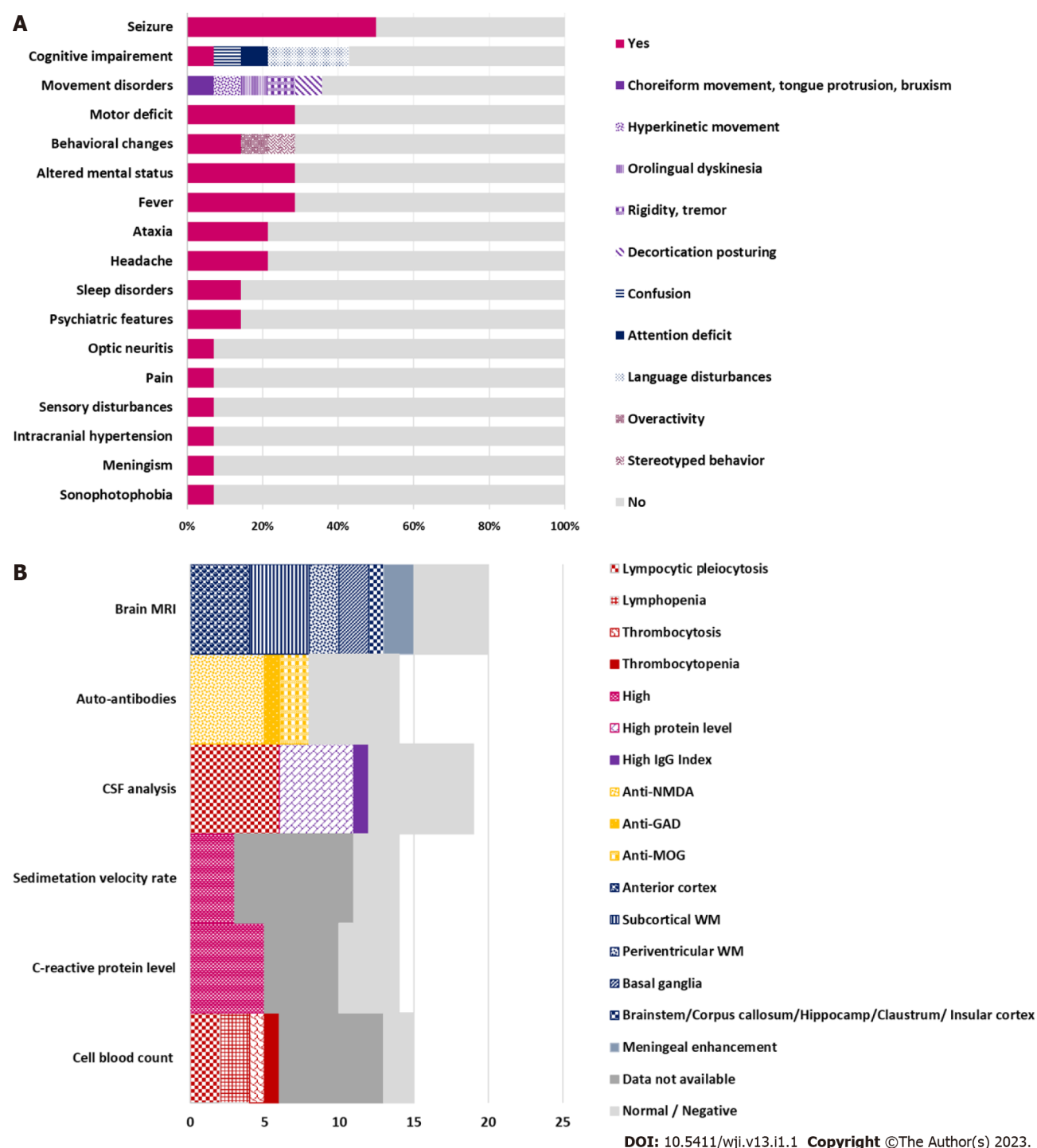

Figure 2 Neurological features and para-clinical biomarkers. A: The percentages of neurological features associated with coronavirus disease 2019 (COVID-19)-related AIE according to previous reports; B: The percentages of support para-clinical biomarkers for post-COVID-19 autoimmune encephalitis diagnosis according to literature data[15-20].

FOOTNOTES

Author contributions: Zouari Mallouli S contributed to manuscript writing and editing, and bibliography; Jallouli O, Bouchaala W, Ben Nsir S contributed to bibliography; Kamoun Feki F, Charfi Triki C contributed to editing and supervision; all authors have read and approved the final manuscript.

Informed consent statement: The patients' legal guardian provided informed written consent prior to study enrollment.

Conflict-of-interest statement: All the authors declare that they have no conflict of interest to disclose.

CARE Checklist (2016) statement: The authors have read the CARE Checklist (2016), and the manuscript was

prepared and revised according to the CARE Checklist (2016).

Open-Access: This article is an open-access article that was selected by an in-house editor and fully peer-reviewed by external reviewers. It is distributed in accordance with the Creative Commons Attribution NonCommercial (CC BY-NC 4.0) license, which permits others to distribute, remix, adapt, build upon this work non-commercially, and license their derivative works on different terms, provided the original work is properly cited and the use is non-commercial. See: <https://creativecommons.org/licenses/by-nc/4.0/>

Country/Territory of origin: Tunisia

ORCID number: Salma Zouari Mallouli 0000-0002-2298-3613; Olfa Jallouli 0000-0001-6972-0936; Wafa Bouchaala 0000-0002-4228-1002; Sihem Ben Nsir 0000-0002-5016-3241; Fatma Kamoun Feki 0000-0002-5058-7693; Chahnez Charfi Triki 0000-0003-2918-3819.

S-Editor: Liu JH

L-Editor: Ma JY

P-Editor: Liu JH

REFERENCES

- 1 Aljomah L, Almedlej S, Baarmah D, Altwaijri W, Alrumayyan A, Alrifai MT, Almuqbil M, Alshalaan M. Pediatrics COVID-19 and neurological manifestations: Single tertiary centre experience. *eNeurologicalSci* 2021; **24**: 100355 [PMID: 34307923 DOI: 10.1016/j.ensci.2021.100355]
- 2 Beghi E, Giussani G, Westenberg E, Allegri R, Garcia-Azorin D, Guekht A, Frontera J, Kivipelto M, Mangialasche F, Mukaetova-Ladinska EB, Prasad K, Chowdhary N, Winkler AS. Acute and post-acute neurological manifestations of COVID-19: present findings, critical appraisal, and future directions. *J Neurol* 2022; **269**: 2265-2274 [PMID: 34674005 DOI: 10.1007/s00415-021-10848-4]
- 3 Westman G, Zelano J. Epilepsy diagnosis after Covid-19: A population-wide study. *Seizure* 2022; **101**: 11-14 [PMID: 35842976 DOI: 10.1016/j.seizure.2022.07.005]
- 4 Garcia-Azorin D, Seeher KM, Newton CR, Okubadejo NU, Pilotto A, Saylor D, Winkler AS, Charfi Triki C, Leonardi M. Disruptions of neurological services, its causes and mitigation strategies during COVID-19: a global review. *J Neurol* 2021; **268**: 3947-3960 [PMID: 34021772 DOI: 10.1007/s00415-021-10588-5]
- 5 Triki CC, Leonardi M, Mallouli SZ, Cacciatore M, Karlshoej KC, Magnani FG, Newton CR, Pilotto A, Saylor D, Westenberg E, Walsh D, Winkler AS, Thakur KT, Okubadejo NU, Garcia-Azorin D. Global survey on disruption and mitigation of neurological services during COVID-19: the perspective of global international neurological patients and scientific associations. *J Neurol* 2022; **269**: 26-38 [PMID: 34117527 DOI: 10.1007/s00415-021-10641-3]
- 6 von Oertzen TJ, Macerollo A, Leone MA, Beghi E, Crean M, Oztuk S, Bassetti C, Twardzik A, Bereczki D, Di Liberto G, Helbok R, Oreja-Guevara C, Pisani A, Sauerbier A, Sellner J, Soffietti R, Zedde M, Bianchi E, Bodini B, Cavallieri F, Campiglio L, Maia LF, Priori A, Rakusa M, Taba P, Moro E, Jenkins TM; EANcore COVID-19 task force. EAN consensus statement for management of patients with neurological diseases during the COVID-19 pandemic. *Eur J Neurol* 2021; **28**: 7-14 [PMID: 33058321 DOI: 10.1111/ene.14521]
- 7 Direction Qualité des Soins et Sécurité des Patients. Guide parcours du patient suspect ou confirme COVID-19 réponse rapide. Septembre 2020. Available from: https://www.ineas.tn/sites/default/files/gps_covid-19.pdf
- 8 Cloete J, Kruger A, Masha M, du Plessis NM, Mawela D, Tshukudu M, Tabea Manyane, Komane L, Venter M, Jassat W, Goga A, Feucht U. Rapid rise in paediatric COVID-19 hospitalisations during the early stages of the Omicron wave, Tshwane District, South Africa. *medRxiv* [DOI: 10.1101/2021.12.21.21268108]
- 9 Cloete J, Kruger A, Masha M, du Plessis NM, Mawela D, Tshukudu M, Manyane T, Komane L, Venter M, Jassat W, Goga A, Feucht U. Paediatric hospitalisations due to COVID-19 during the first SARS-CoV-2 omicron (B.1.1.529) variant wave in South Africa: a multicentre observational study. *Lancet Child Adolesc Health* 2022; **6**: 294-302 [PMID: 35189083 DOI: 10.1016/S2352-4642(22)00027-X]
- 10 Réseau de Veille et de Riposte « EPICOV-TUN ». Bulletin de veille SARS-CoV-2-Tunisie. Octobre 2021. Available from: <https://www.onmne.tn/wp-content/uploads/2021/10/Bulletin-de-veille-SARS-CoV-2-10102021-VFC.pdf>
- 11 Ludvigsson JF. Convulsions in children with COVID-19 during the Omicron wave. *Acta Paediatr* 2022; **111**: 1023-1026 [PMID: 35098577 DOI: 10.1111/apa.16276]
- 12 Abdel-Mannan O, Eyre M, Löbel U, Bamford A, Eltze C, Hameed B, Hemingway C, Hachohen Y. Neurologic and Radiographic Findings Associated With COVID-19 Infection in Children. *JAMA Neurol* 2020; **77**: 1440-1445 [PMID: 32609336 DOI: 10.1001/jamaneurol.2020.2687]
- 13 Chen TH. Neurological involvement associated with COVID-19 infection in children. *J Neurol Sci* 2020; **418**: 117096 [PMID: 32823135 DOI: 10.1016/j.jns.2020.117096]
- 14 Falco-Walter JJ, Scheffer IE, Fisher RS. The new definition and classification of seizures and epilepsy. *Epilepsy Res* 2018; **139**: 73-79 [PMID: 29197668 DOI: 10.1016/j.epilepsyres.2017.11.015]
- 15 Payus AO, Jeffree MS, Ohn MH, Tan HJ, Ibrahim A, Chia YK, Raymond AA. Immune-mediated neurological syndrome in SARS-CoV-2 infection: a review of literature on autoimmune encephalitis in COVID-19. *Neurol Sci* 2022; **43**: 1533-1547 [PMID: 34853897 DOI: 10.1007/s10072-021-05785-z]
- 16 Stoian A, Stoian M, Bajko Z, Maier S, Andone S, Cioflinc RA, Motaitianu A, Barcutan L, Balasa R. Autoimmune

- Encephalitis in COVID-19 Infection: Our Experience and Systematic Review of the Literature. *Biomedicines* 2022; **10** [PMID: 35453524 DOI: 10.3390/biomedicines10040774]
- 17 **Nabizadeh F**, Balabandian M, Sodeifian F, Rezaei N, Rostami MR, Naser Moghadasi A. Autoimmune encephalitis associated with COVID-19: A systematic review. *Mult Scler Relat Disord* 2022; **62**: 103795 [PMID: 35472834 DOI: 10.1016/j.msard.2022.103795]
- 18 **Sarigecili E**, Arslan I, Ucar HK, Celik U. Pediatric anti-NMDA receptor encephalitis associated with COVID-19. *Childs Nerv Syst* 2021; **37**: 3919-3922 [PMID: 33852058 DOI: 10.1007/s00381-021-05155-2]
- 19 **Sánchez-Morales AE**, Urrutia-Osorio M, Camacho-Mendoza E, Rosales-Pedraza G, Dávila-Maldonado L, González-Duarte A, Herrera-Mora P, Ruiz-García M. Neurological manifestations temporally associated with SARS-CoV-2 infection in pediatric patients in Mexico. *Childs Nerv Syst* 2021; **37**: 2305-2312 [PMID: 33751228 DOI: 10.1007/s00381-021-05104-z]
- 20 **Hilado M**, Banh M, Homans J, Partikian A. Pediatric Autoimmune Encephalitis Following COVID-19 Infection. *J Child Neurol* 2022; **37**: 268-272 [PMID: 35014889 DOI: 10.1177/08830738211069814]
- 21 **Jang Y**, Kim DW, Yang KI, Byun JI, Seo JG, No YJ, Kang KW, Kim D, Kim KT, Cho YW, Lee ST; Drug Committee of Korean Epilepsy Society. Clinical Approach to Autoimmune Epilepsy. *J Clin Neurol* 2020; **16**: 519-529 [PMID: 33029957 DOI: 10.3988/jcn.2020.16.4.519]
- 22 **Huang Q**, Liao Y, Ma M, Wu Y. Delta brush variant: A novel ictal EEG pattern in anti-NMDAR encephalitis. *Epilepsia Open* 2020; **5**: 507-513 [PMID: 32913959 DOI: 10.1002/epi4.12423]



Published by **Baishideng Publishing Group Inc**
7041 Koll Center Parkway, Suite 160, Pleasanton, CA 94566, USA

Telephone: +1-925-3991568

E-mail: bpgoffice@wjgnet.com

Help Desk: <https://www.f6publishing.com/helpdesk>

<https://www.wjgnet.com>

