

# World Journal of *Clinical Cases*

*World J Clin Cases* 2023 April 6; 11(10): 2123-2362



## Contents

Thrice Monthly Volume 11 Number 10 April 6, 2023

## EVIDENCE REVIEW

- 2123** Fractional flow reserve and non-hyperemic indices: Essential tools for percutaneous coronary interventions

*Boutaleb AM, Ghafari C, Ungureanu C, Carlier S*

## REVIEW

- 2140** Diagnosis, treatment protocols, and outcomes of liver transplant recipients infected with COVID-19

*Hashem M, El-Kassas M*

## MINIREVIEWS

- 2160** Treatment of stellate ganglion block in diseases: Its role and application prospect

*Deng JJ, Zhang CL, Liu DW, Huang T, Xu J, Liu QY, Zhang YN*

- 2168** Clinical application of SARS-CoV-2 antibody detection and monoclonal antibody therapies against COVID-19

*Sun J, Yang ZD, Xie X, Li L, Zeng HS, Gong B, Xu JQ, Wu JH, Qu BB, Song GW*

- 2181** Cheesy material on macroscopic on-site evaluation after endoscopic ultrasound-guided fine-needle biopsy: Don't miss the tuberculosis

*Delsa H, Bellahammou K, Okasha HH, Ghalim F*

- 2189** Liver manifestations in COVID-19 patients: A review article

*Helou M, Nasr J, El Osta N, Jabbour E, Husni R*

- 2201** Breast reconstruction: Review of current autologous and implant-based techniques and long-term oncologic outcome

*Malekpour M, Malekpour F, Wang HTH*

- 2213** Update on the current management of persistent and recurrent primary hyperparathyroidism after parathyroidectomy

*Pavlidis ET, Pavlidis TE*

## ORIGINAL ARTICLE

## Retrospective Study

- 2226** Hepatobiliary system and intestinal injury in new coronavirus infection (COVID-19): A retrospective study

*Kozlov KV, Zhdanov KV, Ratnikova AK, Ratnikov VA, Tishkov AV, Grinevich V, Kravchuk YA, Miklush PI, Nikiforova PO, Gordienko VV, Popov AF, Andryukov BG*

- 2237** Impact of lockdown policies during the COVID-19 outbreak on a trauma center of a tertiary hospital in China

*Shen BS, Cheng WY, Liang ZR, Tang Q, Li KY*

**Observational Study**

- 2246** Interaction between the left ventricular ejection fraction and left ventricular strain and its relationship with coronary stenosis  
*Gui HY, Liu SW, Zhu DF*

**CASE REPORT**

- 2254** Neonatal hyperinsulinism with an *ABCC8* mutation: A case report  
*Liu MT, Yang HX*
- 2260** Unilateral contrast-induced encephalopathy with contrast medium exudation: A case report  
*Zhang ZY, Lv H, Wang PJ, Zhao DY, Zhang LY, Wang JY, Hao JH*
- 2267** Diagnosis and treatment of primary seminoma of the prostate: A case report and review of literature  
*Cao ZL, Lian BJ, Chen WY, Fang XD, Jin HY, Zhang K, Qi XP*
- 2276** Primary intra-abdominal paraganglioma: A case report  
*Guo W, Li WW, Chen MJ, Hu LY, Wang XG*
- 2282** Successful surgical treatment of bronchopleural fistula caused by severe pulmonary tuberculosis: A case report and review of literature  
*Shen L, Jiang YH, Dai XY*
- 2290** Clinical and genetic features of Kenny-Caffey syndrome type 2 with multiple electrolyte disturbances: A case report  
*Yuan N, Lu L, Xing XP, Wang O, Jiang Y, Wu J, He MH, Wang XJ, Cao LW*
- 2301** Dupilumab for treatment of severe atopic dermatitis accompanied by lichenoid amyloidosis in adults: Two case reports  
*Zhao XQ, Zhu WJ, Mou Y, Xu M, Xia JX*
- 2308** Reabsorption of intervertebral disc prolapse after conservative treatment with traditional Chinese medicine: A case report  
*Wang CA, Zhao HF, Ju J, Kong L, Sun CJ, Zheng YK, Zhang F, Hou GJ, Guo CC, Cao SN, Wang DD, Shi B*
- 2315** Development of subdural empyema from subdural effusion after suppurative encephalitis: A case report  
*Yang RX, Chen B, Zhang Y, Yang Y, Xie S, He L, Shi J*
- 2321** Treatment of periprosthetic knee infection and coexistent periprosthetic fracture: A case report and literature review  
*Hao LJ, Wen PF, Zhang YM, Song W, Chen J, Ma T*
- 2329** Formation of a rare curve-shaped thoracolith documented on serial chest computed tomography images: A case report  
*Hsu FC, Huang TW, Pu TW*
- 2336** Neurofibromatosis type 1 with multiple gastrointestinal stromal tumors: A case report  
*Yao MQ, Jiang YP, Yi BH, Yang Y, Sun DZ, Fan JX*

- 2343** Coexisting cytomegalovirus colitis in an immunocompetent patient with *Clostridioides difficile* colitis: A case report  
*Kim JH, Kim HS, Jeong HW*
- 2349** Paradoxical vocal fold motion masquerading as post-anesthetic respiratory distress: A case report  
*Baek J, Jee DL, Choi YS, Kim SW, Choi EK*
- 2355** Full neurological recovery from severe nonexertional heat stroke with multiple organ dysfunction: A case report  
*Du F, Zheng JW, Zhao YB, Yang K, Li HN*

**ABOUT COVER**

Editorial Board Member of *World Journal of Clinical Cases*, Abdullah Gul, MD, PhD, Associate Professor, Department of Urology, University of Health Sciences Turkey, Bursa Yuksek Ihtisas Training and Research Hospital, Bursa 16310, Turkey. dr\_abdullahgul@hotmail.com

**AIMS AND SCOPE**

The primary aim of *World Journal of Clinical Cases (WJCC, World J Clin Cases)* is to provide scholars and readers from various fields of clinical medicine with a platform to publish high-quality clinical research articles and communicate their research findings online.

*WJCC* mainly publishes articles reporting research results and findings obtained in the field of clinical medicine and covering a wide range of topics, including case control studies, retrospective cohort studies, retrospective studies, clinical trials studies, observational studies, prospective studies, randomized controlled trials, randomized clinical trials, systematic reviews, meta-analysis, and case reports.

**INDEXING/ABSTRACTING**

The *WJCC* is now abstracted and indexed in Science Citation Index Expanded (SCIE, also known as SciSearch®), Journal Citation Reports/Science Edition, Current Contents®/Clinical Medicine, PubMed, PubMed Central, Scopus, Reference Citation Analysis, China National Knowledge Infrastructure, China Science and Technology Journal Database, and Superstar Journals Database. The 2022 Edition of Journal Citation Reports® cites the 2021 impact factor (IF) for *WJCC* as 1.534; IF without journal self cites: 1.491; 5-year IF: 1.599; Journal Citation Indicator: 0.28; Ranking: 135 among 172 journals in medicine, general and internal; and Quartile category: Q4. The *WJCC*'s CiteScore for 2021 is 1.2 and Scopus CiteScore rank 2021: General Medicine is 443/826.

**RESPONSIBLE EDITORS FOR THIS ISSUE**

Production Editor: *Xu Guo*; Production Department Director: *Xiang Li*; Editorial Office Director: *Jin-Lei Wang*.

**NAME OF JOURNAL**

*World Journal of Clinical Cases*

**ISSN**

ISSN 2307-8960 (online)

**LAUNCH DATE**

April 16, 2013

**FREQUENCY**

Thrice Monthly

**EDITORS-IN-CHIEF**

Bao-Gan Peng, Jerzy Tadeusz Chudek, George Kontogeorgos, Maurizio Serati, Ja Hyeon Ku

**EDITORIAL BOARD MEMBERS**

<https://www.wjgnet.com/2307-8960/editorialboard.htm>

**PUBLICATION DATE**

April 6, 2023

**COPYRIGHT**

© 2023 Baishideng Publishing Group Inc

**INSTRUCTIONS TO AUTHORS**

<https://www.wjgnet.com/bpg/gerinfo/204>

**GUIDELINES FOR ETHICS DOCUMENTS**

<https://www.wjgnet.com/bpg/GerInfo/287>

**GUIDELINES FOR NON-NATIVE SPEAKERS OF ENGLISH**

<https://www.wjgnet.com/bpg/gerinfo/240>

**PUBLICATION ETHICS**

<https://www.wjgnet.com/bpg/GerInfo/288>

**PUBLICATION MISCONDUCT**

<https://www.wjgnet.com/bpg/gerinfo/208>

**ARTICLE PROCESSING CHARGE**

<https://www.wjgnet.com/bpg/gerinfo/242>

**STEPS FOR SUBMITTING MANUSCRIPTS**

<https://www.wjgnet.com/bpg/GerInfo/239>

**ONLINE SUBMISSION**

<https://www.f6publishing.com>



## Coexisting cytomegalovirus colitis in an immunocompetent patient with *Clostridioides difficile* colitis: A case report

Jun Hyoung Kim, Hee-Sung Kim, Hye Won Jeong

**Specialty type:** Medicine, research and experimental

**Provenance and peer review:** Unsolicited article; Externally peer reviewed.

**Peer-review model:** Single blind

**Peer-review report's scientific quality classification**

Grade A (Excellent): 0  
Grade B (Very good): 0  
Grade C (Good): C, C, C  
Grade D (Fair): 0  
Grade E (Poor): 0

**P-Reviewer:** Faraji N, Iran; Gao C, China

**Received:** December 21, 2022

**Peer-review started:** December 21, 2022

**First decision:** January 5, 2023

**Revised:** January 12, 2023

**Accepted:** March 6, 2023

**Article in press:** March 6, 2023

**Published online:** April 6, 2023



**Jun Hyoung Kim, Hee-Sung Kim, Hye Won Jeong**, Department of Internal Medicine, Chungbuk National University Hospital, Cheongju 28644, Chungbuk, South Korea

**Hee-Sung Kim, Hye Won Jeong**, Department of Internal Medicine, Chungbuk National University College of Medicine, Cheongju 28644, Chungbuk, South Korea

**Corresponding author:** Hye Won Jeong, MD, PhD, Professor, Department of Internal Medicine, Chungbuk National University College of Medicine, No. 1 Chungdae-ro, Seowon-gu, Cheongju 28644, Chungbuk, South Korea. [hwjeong@chungbuk.ac.kr](mailto:hwjeong@chungbuk.ac.kr)

### Abstract

#### BACKGROUND

*Clostridioides difficile* (*C. difficile*) colitis is one of the most common infections in hospitalized patients, characterized by fever and diarrhea. It usually improves after appropriate antibiotic treatment; if not, comorbidities should be considered. Cytomegalovirus (CMV) colitis is a possible co-existing diagnosis in patients with *C. difficile* infection with poor treatment response. However, compared with immunocompromised patients, CMV colitis in immunocompetent patients is not well studied.

#### CASE SUMMARY

We present an unusual case of co-existing CMV colitis in an immunocompetent patient with *C. difficile* infection. An 80-year-old female patient was referred to the infectious disease department due to diarrhea, abdominal discomfort, and fever for 1 wk during her hospitalization for surgery. *C. difficile* toxin B polymerase chain reaction on stool samples was positive. After *C. difficile* infection was diagnosed, oral vancomycin treatment was administered. Her symptoms including diarrhea, fever and abdominal discomfort improved for ten days. Unfortunately, the symptoms worsened again with bloody diarrhea and fever. Therefore, a sigmoidoscopy was performed for evaluation, showing a longitudinal ulcer on the sigmoid colon. Endoscopic biopsy confirmed CMV colitis, and the clinical symptoms improved after using ganciclovir.

#### CONCLUSION

Co-existing CMV colitis should be considered in patients with aggravated *C. difficile* infection on appropriate treatment, even in immunocompetent hosts.

**Key Words:** Cytomegalovirus; *Clostridioides difficile*; Coinfection; Colitis;

Immunocompetent; Case report

©The Author(s) 2023. Published by Baishideng Publishing Group Inc. All rights reserved.

**Core Tip:** Cytomegalovirus (CMV) colitis is rare in immunocompetent patients, but colitis is the main clinical manifestation. The *Clostridioides difficile* (*C. difficile*) infection and CMV colitis symptoms might be indistinguishable clinically. Therefore, it is difficult to consider their co-existence in patients suspected of *C. difficile* infection. If a patient treated with *C. difficile* infection does not show clinical improvement, the possibility of co-existing CMV colitis should be considered as one of the differential diagnoses. Sigmoidoscopy with biopsy is crucial in diagnosing co-existing CMV and *C. difficile* infection colitis.

**Citation:** Kim JH, Kim HS, Jeong HW. Coexisting cytomegalovirus colitis in an immunocompetent patient with *Clostridioides difficile* colitis: A case report. *World J Clin Cases* 2023; 11(10): 2343-2348

**URL:** <https://www.wjgnet.com/2307-8960/full/v11/i10/2343.htm>

**DOI:** <https://dx.doi.org/10.12998/wjcc.v11.i10.2343>

## INTRODUCTION

Cytomegalovirus (CMV) is a member of the herpesvirus family and forms latent infection after the resolution of the primary infection[1]. CMV primary infection can cause mononucleosis-like symptoms in immunocompetent adults[1]. After the primary CMV infection, CMV remains in host cells and CMV replication is controlled by the immune system in immunocompetent patients[1]. Immunodeficiency is the leading risk factor for invasive CMV diseases[2]. Invasive CMV diseases can occur in immunocompromised patients, including transplant recipients or patients with HIV, by primary infection or reactivation and could have significant morbidity and mortality[3]. This mostly affects the gastrointestinal tract, comprising 30% of tissue-invasive CMV diseases in immunocompromised patients[4]. Clinical manifestation of CMV colitis in immunocompromised patients varies and depends on the site of involvement which could cause odynophagia, abdominal pain, hematochezia, and fever[4].

CMV colitis in immunocompetent patients was previously considered very rare. However, there has been an increasing number of case reports in immunocompetent patients[5,6]. The symptoms of CMV colitis in immunocompetent patients also present odynophagia, abdominal pain, hematochezia, and fever[5,6]. However, its epidemiology, clinical features, and outcomes in immunocompetent patients are not completely understood[4-8].

*Clostridioides difficile* (*C. difficile*) colitis is a cause of diarrhea in hospitalized patients and is one of the most common causes of nosocomial infections[9]. *C. difficile* infection is usually suspected when hospitalized patients develop diarrhea and fever[9]. CMV colitis symptoms are clinically indistinguishable from those of *C. difficile* infection. Therefore, if the immunocompromised status of patients who develop *C. difficile* infection does not improve even with appropriate treatment, accompanying CMV colitis should be considered. However, this may not be considered in immunocompromised patients because cases of co-existing *C. difficile* infection and CMV colitis are rare in immunocompetent patients. We report an unusual case of CMV colitis in an immunocompetent *C. difficile* infection patient with literature review.

## CASE PRESENTATION

### Chief complaints

An 80-year-old female patient was referred for an infectious disease (ID) consult due to diarrhea, abdominal discomfort, and fever for 1 wk during her rehabilitation treatment after spinal stenosis surgery.

### History of present illness

She underwent spinal stenosis surgery three weeks ago for back pain. She took methylprednisolone 250 mg per day for a week from the time of surgery due to paralysis of the lower extremities associated with spinal stenosis. She was treated with piperacillin/tazobactam for 7 d and cefixime for 4 d for a urinary tract infection before ID consultation. She had diarrhea, abdominal discomfort, and fever for 1 wk. *C. difficile* toxin A, B polymerase chain reaction (PCR) tests were performed on stool samples. *C. difficile* toxin B PCR was positive. Computed tomography (CT) of the abdomen/pelvis showed diffuse wall thickening in the rectum with mild perirectal infiltration in the upstream colon. The patient was treated

with oral vancomycin 250 mg every 6 h for 10 d, after which fever and diarrhea improved for ten days. However, the symptoms worsened again with bloody diarrhea and fever.

### History of past illness

She had a medical history of hypertension and diabetes.

### Personal and family history

The patient had no family history.

### Physical examination

Vital signs were a temperature of 37.8 °C, blood pressure of 110/60 mmHg, pulse rate of 84 beats/min, respiratory rate of 18 breaths/min on the consultation day. The patient's Glasgow Coma Scale score was 15. She had hyperactive bowel sounds, no tenderness or rebound tenderness, no abdominal distension.

### Laboratory examinations

On the consultation day, laboratory evaluation revealed anemia (Hb = 9.5 g/dL), an increased level of C-reactive protein (7.3 mg/dL), and an increased erythrocyte sedimentation rate (61 mm/h) with a normal white blood cell counts of 9730 cell/mm<sup>3</sup> (neutrophils = 80%, lymphocyte = 15%). Stool culture for *Salmonella* spp., *Shigella* spp., *Campylobacter* spp., and *Escherichia coli* O-157:H7 was negative. In routine stool examination, there is no helminth or protozoa, and stool white blood cell counts are 1-5 cell/high power field.

### Imaging examinations

Flexible sigmoidoscopy showed a longitudinal ulcer from the anal verge (AV) to 12 cm above the AV (Figure 1). The biopsy was performed on the ulcer site. Cells with basophilic intranuclear inclusion body surrounded by a clear halo on hematoxylin and eosin stain and positive immunohistochemistry for CMV (Figure 2).

---

## FINAL DIAGNOSIS

---

Co-existing CMV colitis with *C. difficile* colitis.

---

## TREATMENT

---

Antiviral treatment with intravenous ganciclovir (10 mg/kg/day) was initiated. Fever and bloody diarrhea improved after 5 d of using ganciclovir, and the treatment was continued for 3 wk.

---

## OUTCOME AND FOLLOW-UP

---

A sigmoidoscopy performed after the treatment showed an improvement in the ulcer lesion, and a biopsy performed 1 mo after the treatment showed negative findings. The patient was discharged to a nursing home after successful treatment with improved symptoms.

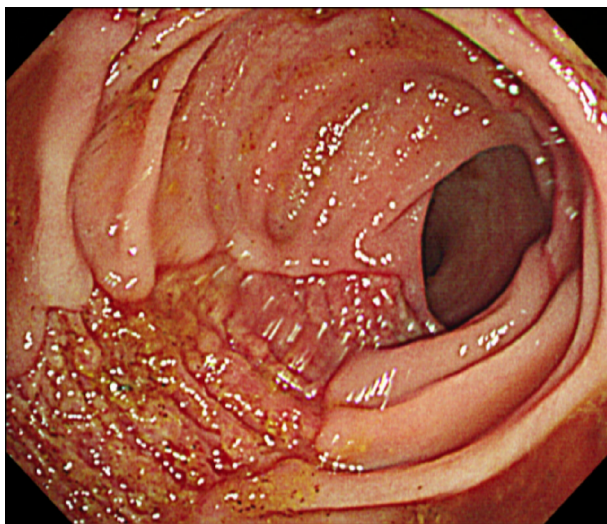
---

## DISCUSSION

---

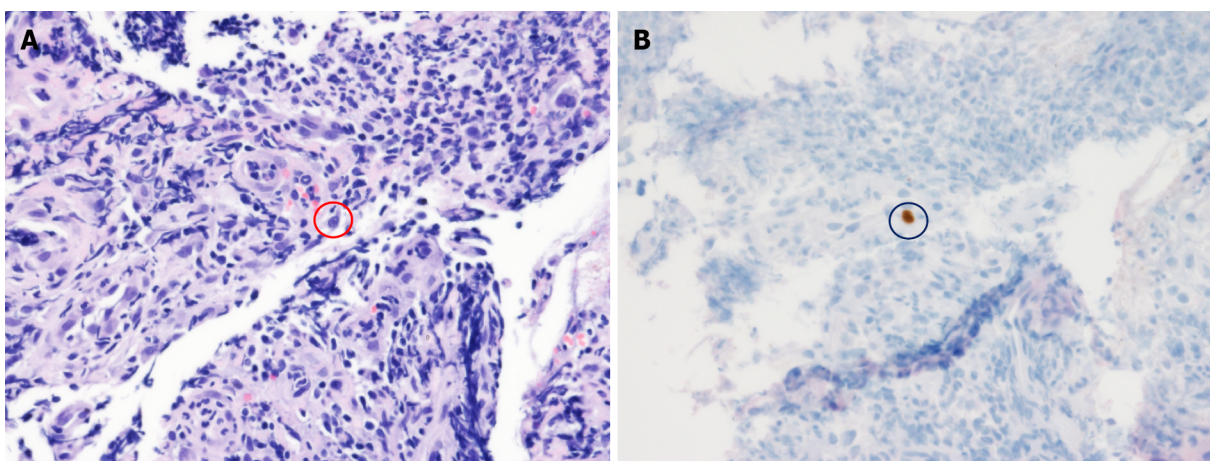
Although CMV infection in immunocompetent hosts has been considered rare, one review article retrieved 89 articles reporting on severe CMV infection in immunocompetent adults from 1950 to 2007 [10]. They were mainly gastrointestinal and central nervous system diseases. Symptoms of CMV infection in immunocompetent patients are not well documented; however, severe life-threatening CMV infections in immunocompetent hosts might not be such a rare condition as was previously thought [10]. Currently, a rapidly rising number of literature cases worldwide indicate that CMV infections can also be observed in immunocompetent patients with altered immune status such as steroid use [8,11]. A total of 51 immunocompetent patients were diagnosed with CMV colitis between January 1995 and February 2014 at a tertiary care university hospital in South Korea, with 36 cases diagnosed after 2008, suggesting the growing number of immunocompetent CMV patients [8]. Similarly, 42 immunocompetent patients were diagnosed between April 2002 and December 2016 at a hospital in Taiwan [11]. Ko *et al* [8] reported that risk factors of CMV colitis in immunocompetent patients were steroid use and RBC transfusion within 1 mo. Our patient also received steroid treatment, and this could be the risk factor of CMV colitis. Wetwittayakhang *et al* [5] compared clinical features and endoscopic findings of





DOI: 10.12998/wjcc.v11.i10.2343 Copyright ©The Author(s) 2023.

**Figure 1 Sigmoidoscopy image.** Sigmoidoscopy image shows presenting a longitudinal ulcer from the anal verge (AV) to 12 cm above the AV.



DOI: 10.12998/wjcc.v11.i10.2343 Copyright ©The Author(s) 2023.

**Figure 2 Pathology findings.** A: Red circle shows a cell with a basophilic intranuclear inclusion body surrounded by a clear halo (hematoxylin and eosin stain, 400 ×); B: Black circle shows positive immunohistochemistry for cytomegalovirus (immunohistochemical stain, 400 ×).

gastrointestinal CMV diseases between immunocompetent and immunocompromised patients and found that immunocompetent patients were older and had more GI bleeding and shorter symptom period than immunocompromised patients[5]. Small bowel involvement was more frequent in the immunocompetent group[5]. Chaemsupaphan *et al*[6] also reported that most immunocompetent patients presented with gastrointestinal bleeding compared to immunocompromised patients[6]. In another study by Yoon *et al*[7], CMV gastroenterocolitis of immunocompetent patients occurred in older patients with comorbidities and had various endoscopic features such as discrete ulcer type and diffuse edematous type with no association with clinical outcomes[7].

*C. difficile* infection is a common cause of colitis in hospitalized patients. Although there are variations according to region and year by year, *C. difficile* infection occurs in approximately 10 cases per 1000 hospitalization days[12]. Clinical manifestations of *C. difficile* infection vary from mild diarrhea to life-threatening conditions such as toxic megacolon and bowel perforation[12]. Patients with mild *C. difficile* infection often recovered 5 to 10 d after stopping antibiotics[13]. However, fulminant *C. difficile* infection could occur in approximately 1% to 3% of patients[13]. Generally, patients with *C. difficile* infection are known to recover after 10-14 d of treatment[13,14]. Currently, the diagnosis of *C. difficile* infection is based on detection of *C. difficile* toxins and glutamate dehydrogenase with enzyme immunoassay or nucleic acid amplification test[13]. Endoscopy is not recommended in patients with typical *C. difficile* infection confirmed by laboratory tests and clinical features[13]. However, endoscopic evaluation is recommended if diagnostic problems occur such as clinically suspected *C. difficile* infection with negative laboratory test, if there was no response to treatment, or when an alternative diagnosis is

suspected[13]. Our patient underwent endoscopy because of worsening symptoms gained after the *C. difficile* infection treatment for 10 d. As *C. difficile* infection and CMV colitis have similar symptoms, it is difficult to differentiate them simply based on the symptoms. However, severe watery diarrhea is more characteristic of *C. difficile* infection and bloody diarrhea or sometimes massive bleeding in CMV colitis [15]. In our case, the patient developed worsening bloody diarrhea with fever; we performed endoscopy and the biopsy confirmed CMV colitis.

## CONCLUSION

Clinicians should be aware of the possibility of co-existing CMV colitis in patients with *C. difficile* infection, even in those with immunocompetent status, especially if patients do not respond to the *C. difficile* infection treatment. Early endoscopy could help diagnose the possible co-existing CMV colitis in patients with refractory *C. difficile* infection.

## FOOTNOTES

**Author contributions:** Kim JH contributed to manuscript writing and editing; Kim HS and Jeong HW supervised the study; Jeong HW conceived the study; all authors have read and approved the final manuscript.

**Informed consent statement:** Informed written consent was obtained from the patient and her family for publication of this report and any accompanying images.

**Conflict-of-interest statement:** All the authors report no relevant conflicts of interest for this article.

**CARE Checklist (2016) statement:** The authors have read the CARE Checklist (2016), and the manuscript was prepared and revised according to the CARE Checklist (2016).

**Open-Access:** This article is an open-access article that was selected by an in-house editor and fully peer-reviewed by external reviewers. It is distributed in accordance with the Creative Commons Attribution NonCommercial (CC BY-NC 4.0) license, which permits others to distribute, remix, adapt, build upon this work non-commercially, and license their derivative works on different terms, provided the original work is properly cited and the use is non-commercial. See: <https://creativecommons.org/licenses/by-nc/4.0/>

**Country/Territory of origin:** South Korea

**ORCID number:** Jun Hyoun Kim 0000-0002-0595-2110; Hee-Sung Kim 0000-0001-7559-4438; Hye Won Jeong 0000-0002-1063-8476.

**S-Editor:** Fan JR

**L-Editor:** A

**P-Editor:** Fan JR

## REFERENCES

- 1 Picarda G, Benedict CA. Cytomegalovirus: Shape-Shifting the Immune System. *J Immunol* 2018; **200**: 3881-3889 [PMID: 29866770 DOI: 10.4049/jimmunol.1800171]
- 2 Yerushalmy-Feler A, Padlipsky J, Cohen S. Diagnosis and Management of CMV Colitis. *Curr Infect Dis Rep* 2019; **21**: 5 [PMID: 30771028 DOI: 10.1007/s11908-019-0664-y]
- 3 Griffiths P, Reeves M. Pathogenesis of human cytomegalovirus in the immunocompromised host. *Nat Rev Microbiol* 2021; **19**: 759-773 [PMID: 34168328 DOI: 10.1038/s41579-021-00582-z]
- 4 Fakhreddine AY, Frenette CT, Konijeti GG. A Practical Review of Cytomegalovirus in Gastroenterology and Hepatology. *Gastroenterol Res Pract* 2019; **2019**: 6156581 [PMID: 30984257 DOI: 10.1155/2019/6156581]
- 5 Wetwittayakhlang P, Rujeerapaiboon N, Wetwittayakhlang P, Sripongpun P, Pruphetkaew N, Jandee S, Chamroonkul N, Piratvisuth T. Clinical Features, Endoscopic Findings, and Predictive Factors for Mortality in Tissue-Invasive Gastrointestinal Cytomegalovirus Disease between Immunocompetent and Immunocompromised Patients. *Gastroenterol Res Pract* 2021; **2021**: 8886525 [PMID: 33897776 DOI: 10.1155/2021/8886525]
- 6 Chaemsupaphan T, Limsrivilai J, Thongdee C, Sudcharoen A, Pongpaibul A, Pausawasdi N, Charatcharoenwitthaya P. Patient characteristics, clinical manifestations, prognosis, and factors associated with gastrointestinal cytomegalovirus infection in immunocompetent patients. *BMC Gastroenterol* 2020; **20**: 22 [PMID: 32000707 DOI: 10.1186/s12876-020-1174-y]
- 7 Yoon J, Lee J, Kim DS, Lee JW, Hong SW, Hwang HW, Hwang SW, Park SH, Yang DH, Ye BD, Myung SJ, Jung HY, Yang SK, Byeon JS. Endoscopic features and clinical outcomes of cytomegalovirus gastroenterocolitis in

- immunocompetent patients. *Sci Rep* 2021; **11**: 6284 [PMID: [33737711](#) DOI: [10.1038/s41598-021-85845-8](#)]
- 8 **Ko JH**, Peck KR, Lee WJ, Lee JY, Cho SY, Ha YE, Kang CI, Chung DR, Kim YH, Lee NY, Kim KM, Song JH. Clinical presentation and risk factors for cytomegalovirus colitis in immunocompetent adult patients. *Clin Infect Dis* 2015; **60**: e20-e26 [PMID: [25452594](#) DOI: [10.1093/cid/ciu969](#)]
- 9 **Balsells E**, Shi T, Leese C, Lyell I, Burrows J, Wiuff C, Campbell H, Kyaw MH, Nair H. Global burden of *Clostridium difficile* infections: a systematic review and meta-analysis. *J Glob Health* 2019; **9**: 010407 [PMID: [30603078](#) DOI: [10.7189/jogh.09.010407](#)]
- 10 **Rafailidis PI**, Mourtzoukou EG, Varbobitis IC, Falagas ME. Severe cytomegalovirus infection in apparently immunocompetent patients: a systematic review. *Virol J* 2008; **5**: 47 [PMID: [18371229](#) DOI: [10.1186/1743-422X-5-47](#)]
- 11 **Chan KS**, Yang CC, Chen CM, Yang HH, Lee CC, Chuang YC, Yu WL. Cytomegalovirus colitis in intensive care unit patients: difficulties in clinical diagnosis. *J Crit Care* 2014; **29**: 474.e1-474.e6 [PMID: [24556151](#) DOI: [10.1016/j.jcrc.2014.01.003](#)]
- 12 **Turner NA**, Grambow SC, Woods CW, Fowler VG Jr, Moehring RW, Anderson DJ, Lewis SS. Epidemiologic Trends in *Clostridioides difficile* Infections in a Regional Community Hospital Network. *JAMA Netw Open* 2019; **2**: e1914149 [PMID: [31664443](#) DOI: [10.1001/jamanetworkopen.2019.14149](#)]
- 13 **Czepiel J**, Drózd M, Pituch H, Kuijper EJ, Perucki W, Mielimonka A, Goldman S, Wultańska D, Garlicki A, Biesiada G. *Clostridium difficile* infection: review. *Eur J Clin Microbiol Infect Dis* 2019; **38**: 1211-1221 [PMID: [30945014](#) DOI: [10.1007/s10096-019-03539-6](#)]
- 14 **Guery B**, Galperine T, Barbut F. *Clostridioides difficile*: diagnosis and treatments. *BMJ* 2019; **366**: 14609 [PMID: [31431428](#) DOI: [10.1136/bmj.14609](#)]
- 15 **Chan KS**, Lee WY, Yu WL. Coexisting cytomegalovirus infection in immunocompetent patients with *Clostridium difficile* colitis. *J Microbiol Immunol Infect* 2016; **49**: 829-836 [PMID: [26850320](#) DOI: [10.1016/j.jmii.2015.12.007](#)]



Published by **Baishideng Publishing Group Inc**  
7041 Koll Center Parkway, Suite 160, Pleasanton, CA 94566, USA

**Telephone:** +1-925-3991568

**E-mail:** [bpgoffice@wjgnet.com](mailto:bpgoffice@wjgnet.com)

**Help Desk:** <https://www.f6publishing.com/helpdesk>

<https://www.wjgnet.com>

