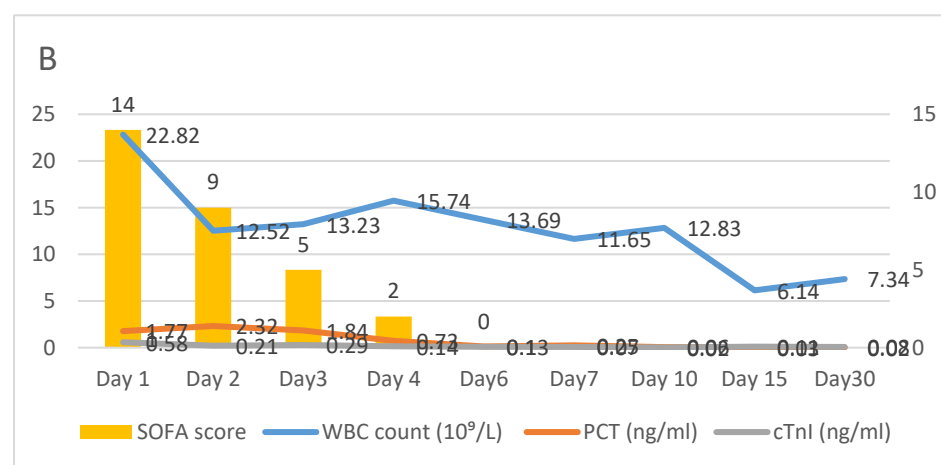


Dear professor:

Thanks for your review. Detailed answers about this case report are as follows:

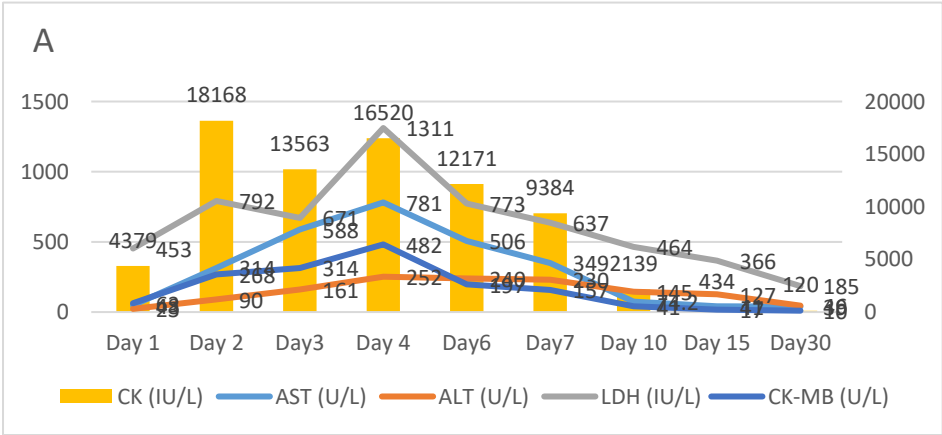
1. The term targeted temperature management (TTM) is used instead of therapeutic hypothermia in the revised manuscript.
2. Rising global temperatures owing to excessive carbon dioxide emissions or heat island effect caused by urbanization have been endangering human health worldwide. In addition, our city has continuous high temperature and humidity this summer (up to 41°C), especially in mid to late august. A 67-year-old woman was exposure to high environmental temperatures (Her family members said that she went out to picked up litters and scraps for money) for a long time and lying prone on the road 12:00 at noon on a summer day in august.
3. The SOFA score was added in the revised manuscript.



4. Similar cases have been reported in the literature. Sagisaka *et al.*<sup>[24]</sup> described a rare case of full neurological recovery from severe heatstroke in a 77-year-old woman while taking a bedrock bath, this case demonstrated that the prognosis of patients with heatstroke may be unrelated to poor EEG findings, laboratory data, unknown causes of sympathetic hyperactivity, or poor state of consciousness. Prompt cooling is the cornerstone of treatment and it seems to be the most important prognostic measure<sup>[16]</sup>. Rapid cooling to reduce core temperatures as quickly as possible is the primary and most

effective treatment, as it has been shown that the major determinant of outcome in heatstroke is the degree and duration of hyperthermia<sup>[2]</sup>. Some studies (Carvalho AS, BMJ Case Rep. 2016; Heled Y, Mil Med. 2004) have shown that, if temperature is reduced to less than 40.0°C within 30 min after the loss of consciousness, the mortality rate is negligible. Sagisaka *et al.*<sup>[24]</sup> initiated immediate cooling and intensive care after detailed examination. In the present case, although the duration of exposure to hyperthermia in the elderly woman was not established, but was undertaken rapid cooling, in the EICU, her rectal core temperature was 37.8°C. Therefore, the patient recovered under our comprehensive management (TTM, combination therapy with hemodialysis and hemoperfusion, hyperbaric oxygen therapy).

5. I have added a new figure as a supplement figure.



6. I have used a similar abbreviation and checked other abbreviations in the table.

7. We recognize the limitations of our study. The primary limitation was whether our TTM process could be improved (maintenance phase longer than 24 h and goal temperature lower than 34 °C). This requires more clinical research.

Thanks again!

If you have any questions, please don't hesitate to contact me!  
1217209787@qq.com