

World Journal of *Clinical Cases*

World J Clin Cases 2023 June 6; 11(16): 3664-3931



Contents

Thrice Monthly Volume 11 Number 16 June 6, 2023

REVIEW

- 3664 Kikuchi-Fujimoto disease: A comprehensive review
Mahajan VK, Sharma V, Sharma N, Rani R
- 3680 Current diagnostic tools and treatment modalities for rectal prolapse
Oruc M, Erol T

MINIREVIEWS

- 3694 Application of laparoscopic surgery in gallbladder carcinoma
Wu X, Li BL, Zheng CJ
- 3706 Current research of idiopathic normal pressure hydrocephalus: Pathogenesis, diagnosis and treatment
Ishida T, Murayama T, Kobayashi S
- 3714 *Helicobacter pylori* plays a key role in gastric adenocarcinoma induced by spasmolytic polypeptide-expressing metaplasia
Li ML, Hong XX, Zhang WJ, Liang YZ, Cai TT, Xu YF, Pan HF, Kang JY, Guo SJ, Li HW
- 3725 Review of deep learning and artificial intelligence models in fetal brain magnetic resonance imaging
Vahedifard F, Adepoju JO, Supanich M, Ai HA, Liu X, Kocak M, Marathu KK, Byrd SE
- 3736 Diabetes more than retinopathy, it's effect on the anterior segment of eye
Morya AK, Ramesh PV, Kaur K, Gurnani B, Heda A, Bhatia K, Sinha A

ORIGINAL ARTICLE

Retrospective Cohort Study

- 3750 Long term outcomes of Cohen's cross trigonal reimplantation for primary vesicoureteral reflux in poorly functioning kidney
Ansari MS, Banthia R, Jain S, Kaushik VN, Danish N, Yadav P

Retrospective Study

- 3756 Dexmedetomidine-induced anesthesia in elderly patients undergoing hip replacement surgery
Li JQ, Yuan H, Wang XQ, Yang M

Observational Study

- 3765 Hypoperfusion context as a predictor of 28-d all-cause mortality in septic shock patients: A comparative observational study
Kataria S, Singh O, Juneja D, Goel A, Bhide M, Yadav D

- 3780** Psychological review of hemodialysis patients and kidney transplant recipients during the COVID-19 pandemic

Gundogmus AG, Oguz EG, Guler-Cimen S, Kocyigit Y, Dogan AE, Ayli MD

- 3791** Incidence and peri-operative risk factors for development of acute kidney injury in patients after cardiac surgery: A prospective observational study

Dimopoulos S, Zagkotsis G, Kinti C, Rouvali N, Georgopoulou M, Mavraki M, Tasouli A, Lyberopoulou E, Roussakis A, Vasileiadis I, Nanas S, Karabinis A

Randomized Controlled Trial

- 3802** Coaxial radiography guided puncture technique for percutaneous transforaminal endoscopic lumbar discectomy: A randomized control trial

Chen LP, Wen BS, Xu H, Lu Z, Yan LJ, Deng H, Fu HB, Yuan HJ, Hu PP

CASE REPORT

- 3813** Blood typing and transfusion therapy in a patient with A2 subtype acute myeloid leukemia M2: A case report

Kuang XC, Zhang SH, Cen YJ, Zhang JB, Liu YS

- 3822** Valve repair after infective endocarditis secondary to perforation caused by *Streptococcus gordonii*: A case report

Qu YF, Yang J, Wang JY, Wei B, Ye XH, Li YX, Han SL

- 3830** *Prevotella oris*-caused meningitis and spinal canal infection: A case report

Zhang WW, Ai C, Mao CT, Liu DK, Guo Y

- 3837** Severe liver trauma with complex portal and common bile duct avulsion: A case report and review of the literature

Mitricof B, Kraft A, Anton F, Barcu A, Barzan D, Haiducu C, Brasoveanu V, Popescu I, Moldovan CA, Botea F

- 3847** TACC diagnosed by transoesophageal endoscopic ultrasonography: A case report

Pu XX, Xu QW, Liu BY

- 3852** Ruptured teratoma mimicking a pelvic inflammatory disease and ovarian malignancy: A case report

Lai PH, Ding DC

- 3858** Purpura annularis telangiectodes of Majocchi: A case report

Pu YJ, Jiang HJ, Zhang L

- 3864** Giant cyst in heterotopic pregnancy: A case report

Kong YY, Chanda K, Ying XY

- 3870** High doses of dextromethorphan induced shock and convulsions in a 19-year-old female: A case report

Shimozawa S, Usuda D, Sasaki T, Tsuge S, Sakurai R, Kawai K, Matsubara S, Tanaka R, Suzuki M, Hotchi Y, Tokunaga S, Osugi I, Katou R, Ito S, Asako S, Mishima K, Kondo A, Mizuno K, Takami H, Komatsu T, Oba J, Nomura T, Sugita M

- 3877** Postpartum ovarian vein thrombosis after cesarean section and vaginal delivery: Two case reports

Zhu HD, Shen W, Wu HL, Sang X, Chen Y, Geng LS, Zhou T

- 3885** Traumatic pancreatic ductal injury treated by endoscopic stenting in a 9-year-old boy: A case report
Kwon HJ, Jung MK, Park J
- 3891** Novel mutation c.2090_2091del in neurodevelopmental-craniofacial syndrome with variable renal and cardiac abnormalities in an 18.5-mo-old boy: A case report
Li Y, Zhou Z, Xu Y, Wang ZR
- 3899** Reading impairment after neonatal hypoglycemia with parieto-temporo-occipital injury without cortical blindness: A case report
Kurahashi N, Ogaya S, Maki Y, Nonobe N, Kumai S, Hosokawa Y, Ogawa C, Yamada K, Maruyama K, Miura K, Nakamura M
- 3907** Unusual clinical presentation of oral pyogenic granuloma with severe alveolar bone loss: A case report and review of literature
Lomeli Martínez SM, Bocanegra Morando D, Mercado González AE, Gómez Sandoval JR
- 3915** Intraoperative photodynamic therapy for tracheal mass in non-small cell lung cancer: A case report
Jung HS, Kim HJ, Kim KW
- 3921** Coexistence of urinary tuberculosis and urothelial carcinoma: A case report
Tsai YC, Li CC, Chen BT, Wang CY

LETTER TO THE EDITOR

- 3929** Symmetric DWI hyperintensities in CMT1X patients after SARS-CoV-2 vaccination should not be classified as stroke-like lesions
Finsterer J

ABOUT COVER

Editorial Board Member of *World Journal of Clinical Cases*, Ashraf F Hefny, MD, MSc, Associate Professor, Surgeon, Department of Surgery, College of Medicine and Health Sciences, UAE University, Al Ain 00000, United Arab Emirates. ahefny@uaeu.ac.ae

AIMS AND SCOPE

The primary aim of *World Journal of Clinical Cases* (WJCC, *World J Clin Cases*) is to provide scholars and readers from various fields of clinical medicine with a platform to publish high-quality clinical research articles and communicate their research findings online.

WJCC mainly publishes articles reporting research results and findings obtained in the field of clinical medicine and covering a wide range of topics, including case control studies, retrospective cohort studies, retrospective studies, clinical trials studies, observational studies, prospective studies, randomized controlled trials, randomized clinical trials, systematic reviews, meta-analysis, and case reports.

INDEXING/ABSTRACTING

The WJCC is now abstracted and indexed in Science Citation Index Expanded (SCIE, also known as SciSearch®), Journal Citation Reports/Science Edition, Current Contents®/Clinical Medicine, PubMed, PubMed Central, Scopus, Reference Citation Analysis, China National Knowledge Infrastructure, China Science and Technology Journal Database, and Superstar Journals Database. The 2022 Edition of Journal Citation Reports® cites the 2021 impact factor (IF) for WJCC as 1.534; IF without journal self cites: 1.491; 5-year IF: 1.599; Journal Citation Indicator: 0.28; Ranking: 135 among 172 journals in medicine, general and internal; and Quartile category: Q4. The WJCC's CiteScore for 2021 is 1.2 and Scopus CiteScore rank 2021: General Medicine is 443/826.

RESPONSIBLE EDITORS FOR THIS ISSUE

Production Editor: Si Zhao; Production Department Director: Xu Guo; Editorial Office Director: Jin-Lei Wang.

NAME OF JOURNAL

World Journal of Clinical Cases

ISSN

ISSN 2307-8960 (online)

LAUNCH DATE

April 16, 2013

FREQUENCY

Thrice Monthly

EDITORS-IN-CHIEF

Bao-Gan Peng, Jerzy Tadeusz Chudek, George Kontogeorgos, Maurizio Serati, Ja Hyeon Ku

EDITORIAL BOARD MEMBERS

<https://www.wjgnet.com/2307-8960/editorialboard.htm>

PUBLICATION DATE

June 6, 2023

COPYRIGHT

© 2023 Baishideng Publishing Group Inc

INSTRUCTIONS TO AUTHORS

<https://www.wjgnet.com/bpg/gerinfo/204>

GUIDELINES FOR ETHICS DOCUMENTS

<https://www.wjgnet.com/bpg/GerInfo/287>

GUIDELINES FOR NON-NATIVE SPEAKERS OF ENGLISH

<https://www.wjgnet.com/bpg/gerinfo/240>

PUBLICATION ETHICS

<https://www.wjgnet.com/bpg/GerInfo/288>

PUBLICATION MISCONDUCT

<https://www.wjgnet.com/bpg/gerinfo/208>

ARTICLE PROCESSING CHARGE

<https://www.wjgnet.com/bpg/gerinfo/242>

STEPS FOR SUBMITTING MANUSCRIPTS

<https://www.wjgnet.com/bpg/GerInfo/239>

ONLINE SUBMISSION

<https://www.f6publishing.com>

Prevotella oris-caused meningitis and spinal canal infection: A case report

Wei-Wei Zhang, Chao Ai, Chien-Tai Mao, Dong-Kang Liu, Yi Guo

Specialty type: Medicine, research and experimental

Provenance and peer review: Unsolicited article; Externally peer reviewed.

Peer-review model: Single blind

Peer-review report's scientific quality classification

Grade A (Excellent): A
Grade B (Very good): B
Grade C (Good): 0
Grade D (Fair): 0
Grade E (Poor): 0

P-Reviewer: Beran RG, Australia; Mora DJ, Brazil;

Received: January 7, 2023

Peer-review started: January 7, 2023

First decision: March 10, 2023

Revised: March 16, 2023

Accepted: April 12, 2023

Article in press: April 12, 2023

Published online: June 6, 2023



Wei-Wei Zhang, Chao Ai, Chien-Tai Mao, Department of Clinical Pharmacy, Beijing Tsinghua Changgung Hospital, School of Medicine, Tsinghua University, Beijing 102218, China

Dong-Kang Liu, Yi Guo, Department of Neurosurgery, Beijing Tsinghua Changgung Hospital, School of Medicine, Tsinghua University, Beijing 102218, China

Corresponding author: Yi Guo, MD, Doctor, Department of Neurosurgery, Beijing Tsinghua Changgung Hospital, School of Medicine, Tsinghua University, No. 168 Litang Road, Changping District, Beijing 102218, China. gya01246@btch.edu.cn

Abstract

BACKGROUND

Prevotella oris-induced meningitis and *Prevotella oris*-induced meningitis concomitant with spinal canal infection are extremely rare. To the best of our knowledge, only 1 case of *Prevotella oris*-induced central system infection has been reported. This is the second report on meningitis combined with spinal canal infection due to *Prevotella oris*.

CASE SUMMARY

We report a case of a 9-year-old boy suffering from meningitis and spinal canal infection. The patient presented to the neurosurgery department with lumbosacral pain for 1 mo and headache and vomiting for 1 d. He had been treated with cephalosporin and nonsteroidal anti-inflammatory drugs for fever, otalgia and pharyngalgia in a local hospital 2 mo prior to this admission. During hospitalization, magnetic resonance imaging suggested meningitis and L3-S1 lumbosacral dural sac infection. The cerebrospinal fluid and blood cultures were negative, but the cerebrospinal fluid specimen indicated the presence of *Prevotella oris* by metagenomic next-generation sequencing. Previous cases of *Prevotella oris* infection were retrieved from PubMed to characterize the clinicopathological features and identify the prognostic factors and related antimicrobial treatment of infection due to *Prevotella oris*.

CONCLUSION

This report shed light on the characteristics of *Prevotella oris* infection and highlighted the role of metagenomic next-generation sequencing in pathogen detection.

Key Words: *Prevotella oris*; Meningitis; Spinal canal infection; Metagenomic next-

generation sequencing; Central nervous system infection; Case report

©The Author(s) 2023. Published by Baishideng Publishing Group Inc. All rights reserved.

Core Tip: *Prevotella oris* is an anaerobic, Gram-negative, nonpigmented bacterium that rarely results in central nervous system infection. To date, only 1 case has been reported of *Prevotella oris* causing central nervous system infection. We report a patient who suffered from meningitis and spinal canal infection due to *Prevotella oris*. Metagenomic next-generation sequencing identified the pathogen, although the cerebrospinal fluid and blood cultures were negative. Early detection of pathogens is crucial for patient survival and prognosis. We analyzed the characteristics of *Prevotella oris*-induced infection and found that all patients were male; the most commonly used antimicrobial agent was metronidazole.

Citation: Zhang WW, Ai C, Mao CT, Liu DK, Guo Y. *Prevotella oris*-caused meningitis and spinal canal infection: A case report. *World J Clin Cases* 2023; 11(16): 3830-3836

URL: <https://www.wjgnet.com/2307-8960/full/v11/i16/3830.htm>

DOI: <https://dx.doi.org/10.12998/wjcc.v11.i16.3830>

INTRODUCTION

Bacterial meningitis and spinal canal infection are not common but can be deadly. They may result in permanent disabilities such as cognitive impairment and learning disabilities, which pose a threat to public health[1,2]. The leading pathogens of bacterial meningitis and spinal canal infection are mainly *Streptococcus pneumoniae* and *Neisseria meningitidis*[3]. *Prevotella oris* is rarely the cause of meningitis and spinal canal infections. There was only one documented case of cervical spinal epidural abscess and meningitis caused by *Prevotella oris* and *Peptostreptococcus micros*[4]. More references are warranted to understand the characteristics of *Prevotella oris*-induced central nervous system (CNS) infection. We presented a case of a 9-year-old male with *Prevotella oris*-induced meningitis and spinal canal infection whose symptoms were relieved significantly after targeted antimicrobial therapy.

CASE PRESENTATION

Chief complaints

A 9-year-old Chinese male presented to the neurosurgery clinic with a complaint of headache and vomiting for 1 d.

History of present illness

The patient had lumbosacral pain for 1 mo prior to this presentation.

History of past illness

Three months prior to admission, the patient presented with fever, otalgia and pharyngalgia and was admitted to a local hospital with a diagnosis of otitis media. He was treated with cephalosporin and nonsteroidal anti-inflammatory drugs (the specific agents and dosages are unknown), and the symptoms were alleviated temporarily. One month later, he had a fever and bilateral muscle pain in the thighs. The pain spread to the whole lumbosacral region. He began to vomit and experienced a progressive headache.

Personal and family history

The patient's personal and family history were not significant.

Physical examination

Physical examination showed that his body temperature was 38 °C, pulse rate was 110 beats per min, respiratory rate was 19 breaths per min and blood pressure was 120/62 mmHg. His consciousness was clear but exhibited despondency. Neurological examinations revealed that his meningeal irritation sign was negative and other functions were normal.

Laboratory examinations

A routine blood examination revealed 12990 leukocytes/ μ L (79% neutrophils) and procalcitonin was

0.099 ng/mL. The cerebral spinal fluid (CSF) was colorless and clear, and the leukocyte count was 985 cells/ μ L with 89% polymorphonuclear leukocytes. The CSF glucose was 2.33 mmol/L, the CSF chloride was 114 mmol/L, and the total protein was 962 mg/L. The CSF and blood cultures were negative.

Imaging examinations

Brain magnetic resonance imaging (MRI) revealed hydrocephalus, and there were multiple intracranial meningeal thickening areas and mastoiditis on the left side (Figure 1). In addition, spinal MRI showed that the dura in the thoracolumbosacral spinal canal (mainly in the lumbar segment) was unevenly thickened, and there were scattered small nodular hypointense foci in the spinal canal at the level of the L3-S1 vertebral body, with the largest being approximately 5 mm (Figure 2).

FURTHER DIAGNOSTIC WORK-UP

To investigate the pathogenic microorganisms, a CSF specimen was tested using metagenomic next-generation sequencing (mNGS). The results showed the presence of *Prevotella oris* with a sequence number of 630 copies and a relative abundance of 1.81%.

FINAL DIAGNOSIS

The patient was diagnosed with meningitis and L3-S1 lumbosacral dural sac infection.

TREATMENT

Initially, the patient was empirically treated with intravenous vancomycin (40 mg/kg/d in two divided doses) and meropenem (40 mg/kg every 8 h). He also underwent a puncture and external drainage of the right ventricle and was given intracranial pressure-decreasing agents and systemic nutritional support. His symptoms did not improve. After the mNGS results indicated the presence of *Prevotella oris*, antibiotic therapy was changed to intravenous metronidazole (15 mg/kg every 6 h) and meropenem (40 mg/kg every 8 h) for 2 wk, followed by meropenem (40 mg/kg every 8 h) for another 2 mo due to the patient experiencing a metronidazole-induced gastrointestinal reaction.

OUTCOME AND FOLLOW-UP

The patient's temperature returned to normal, and his symptoms improved significantly with targeted antimicrobial therapy. After 1 mo of treatment, the routine blood examination showed that the leukocyte count and the percentage of neutrophil granulocytes returned to normal. The leukocyte count in the CSF was 66 cells/ μ L with 33% polymorphonuclear leukocytes. The CSF glucose was 3.11 mmol/L, the CSF chloride was 117 mmol/L, and the total protein was 560 mg/L. Brain and spinal MRI showed that the thickening of the intracranial and lumbosacral dura mater was greatly resolved. The ventricular drainage catheter was pulled out. The patient was continuously treated for another month and followed up for 2 mo without recurrence.

DISCUSSION

CNS infections are potentially devastating and disabling infectious diseases worldwide. They include meningitis, encephalitis, spinal and cranial abscesses, discitis and other complications. It is estimated that the global incidence of CNS infections was 389/100000 between 1990 and 2016[5]. Although CNS infections are not common in developed countries, they remain a public health problem in developing countries[5,6]. Bacterial infections are one type of CNS infection and can be frequently caused by *Haemophilus influenzae*, *Streptococcus pneumoniae*, *Neisseria meningitidis*, Group B strep and *Listeria monocytogenes* in children[7].

Prevotella oris, a nonpigmented, anaerobic, Gram-negative, rod-shaped bacterium, is a periodontopathogen and frequently detected in periodontal diseases[8]. We retrieved and reviewed previous cases of *Prevotella oris* causing extraoral infection from the PubMed database (Table 1). *Prevotella oris* was reported as a pathogen in pleural infection, bacteremia, hepatic abscess, pericarditis, mediastinitis, sepsis and empyema. Only 1 case reported cervical spinal epidural abscess and meningitis due to *Prevotella oris* and *Peptostreptococcus micros* after retropharyngeal surgery in 2004[4]. Upon review, we found that the patients all reported cases were male, and 2 of the 7 cases were initially diagnosed as a

Table 1 Characteristics of infections caused by *Prevotella oris*

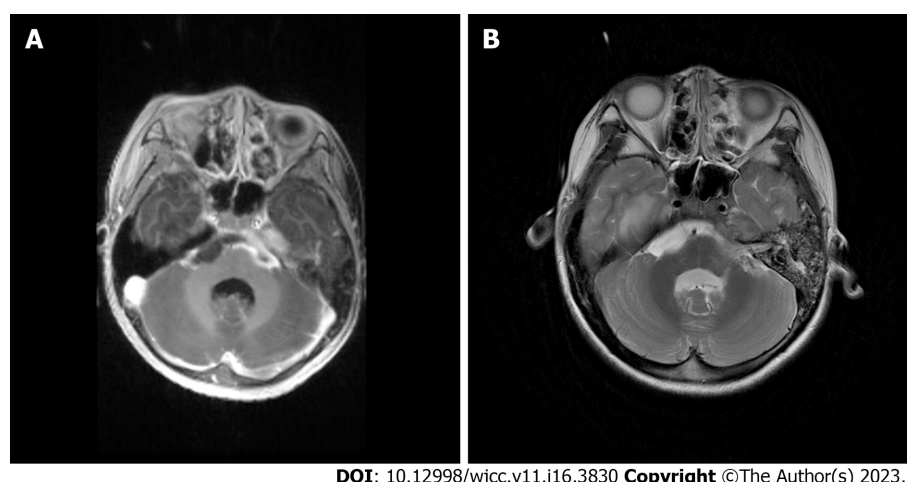
Ref.	Age/Sex	Initial symptoms	Infection site	Pathogens	Initial diagnosis	Final diagnosis	Antimicrobial treatment	Outcome
Viswanath et al[14], 2022	51/M	Right-sided chest pain	Pleura	<i>Prevotella oris</i>	Pulmonary tuberculosis	Pleural infection	Metronidazole (500 mg) IV twice a day initially and then continued for 5 d	Improved
Cobo et al [15], 2022	70/M	Fever, dyspnea and general malaise	Blood and liver	<i>Prevotella oris</i>	COVID-19 infection	Bacteremia, hepatic abscess	Initially, piperacillin-tazobactam (1 g/8 h/IV) and levofloxacin (500 mg/12 h/IV); subsequently, piperacillin-tazobactam (1 g/8 h/IV) and metronidazole (500 mg/8 h/IV) for 10 d	Recovered
Carmack et al[16], 2021	34/M	Cough, fever and night sweats	Pericardium	<i>Prevotella oris</i> and <i>Fusobacterium nucleatum</i>	Tuberculosis pericarditis	Pericarditis secondary to <i>Prevotella oris</i> and <i>Fusobacterium nucleatum</i>	Initially, rifampin, isoniazid, pyrazinamide, ethambutol (RIPE) and prednisone, then ceftriaxone and doxycycline; subsequently, ampicillin/sulbactam 3 g every 6 h	Improved
Duan et al [17], 2021	64/M	Unconsciousness, dyspnea and swelling in the mandible and neck	Mediastinum	<i>Prevotella oris</i> ; <i>Prevotella denticola</i> ; <i>Streptococcus anginosus</i> ; <i>Peptostreptococcus stomatis</i> ; <i>Fusobacterium nucleatum</i> ; <i>Alloprevotella tannerae</i>	Acute purulent mediastinitis	Descending necrotizing mediastinitis	Initially, vancomycin, imipenem; subsequently, piperacillin/tazobactam and tinidazole; finally, levaquin and piperacillin/tazobactam	Improved
Bein et al [18], 2003	NA	Acute unconsciousness due to spontaneous intracerebral bleeding in the cerebellar region	Blood	<i>Prevotella oris</i>	Spontaneous intracerebral bleeding	Bacteremia and sepsis due to <i>Prevotella oris</i> from dentoalveolar abscesses	Initially, imipenem via central venous catheter; subsequently, metronidazole IV	Improved
Abufaied et al[19], 2020	42/M	Left-sided pleuritic chest pain and acute onset of left upper limb weakness	Chest	<i>Prevotella oris</i>	Empyema necessitans	Empyema necessitans	14 d of IV ertapenem and later 14 d of oral ciprofloxacin 500 mg two times daily and amoxicillin/clavulanic acid 625 mg three times daily at the time of discharge	Improved
Frat et al[4], 2004	61/M	Right hemiparesis and bilateral Babinski's sign	Cervical spinal epidural space and meninges	<i>Prevotella oris</i> and <i>Peptostreptococcus micros</i>	Meningoencephalitis	Cervical spinal epidural abscess and meningitis	Initially, ceftriaxone, amoxicillin and cotrimoxazole; subsequently, fosfomycin, ceftriaxone and metronidazole for 3 wk, followed by 8 wk of oral metronidazole	Improved

COVID-19: Coronavirus disease 2019; IV: Intravenous; NA: Not available; M: Male.

tuberculosis infection, which indicated that the symptoms of *Prevotella oris*-induced infection may not be specific and may be similar to tuberculosis infection.

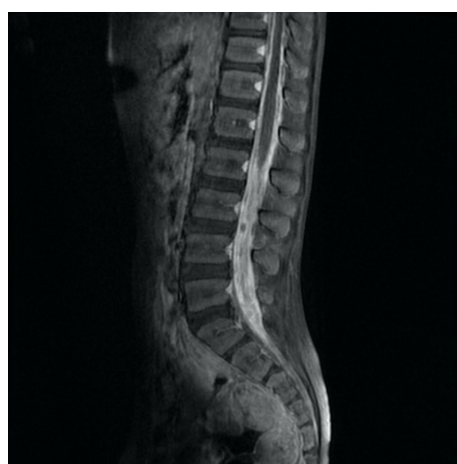
In this case, the patient did not show significant meningitis or spinal infection symptoms. His meningeal irritation sign was negative, and the glucose level of the CSF was in the normal range. Both his blood and CSF cultures were negative. All these factors make pathogen identification more difficult. To investigate the pathogen, we used mNGS, a promising and clinically validated test for CNS infections[9].

Traditional blood and CSF bacterial cultures are essential laboratory tests in meningitis and spinal canal infection. They rarely detect pathogens effectively and in a timely manner under certain circumstances, such as infections caused by oral flora[10]. Compared to traditional methods, mNGS can improve the detection of pathogens to aid clinicians with a timely diagnosis. Some researchers have



DOI: 10.12998/wjcc.v11.i16.3830 Copyright ©The Author(s) 2023.

Figure 1 Brain magnetic resonance imaging sequences of the patient. A: Contrast-enhanced T1-weighted imaging; and B: T2-weighted imaging.



DOI: 10.12998/wjcc.v11.i16.3830 Copyright ©The Author(s) 2023.

Figure 2 Spinal magnetic resonance imaging sequences of contrast-enhanced T1-weighted imaging of the patient.

validated the effects of mNGS in CNS infections[11,12]. It can also provide guidance for clinicians in choosing appropriate antimicrobial regimens.

To date, antimicrobial treatment recommendations have been lacking for *Prevotella oris*-induced nervous system infection. By reviewing previous case reports, we found that the most commonly used antibiotic for treating *Prevotella oris*-induced infection was metronidazole, while other antibiotics included piperacillin-tazobactam, ampicillin/sulbactam, levofloxacin, ertapenem, ciprofloxacin and ceftriaxone. For the documented *Prevotella oris*-induced and *Peptostreptococcus micros*-induced cervical spinal epidural abscess and meningitis cases, fosfomycin, ceftriaxone and metronidazole were used for targeted therapy (Table 1). According to the European Committee of Antimicrobial Susceptibility Testing guidelines, *Prevotella oris* was susceptible to metronidazole, imipenem, chloramphenicol and cefoxitin discs[13]. For this patient, we used metronidazole and meropenem to treat the infection after we found that the effect of empirical antimicrobial therapy was unsatisfactory. The infection was controlled in a timely and effective manner.

CONCLUSION

To the best of our knowledge, this is the second report of meningitis combined with spinal canal infection due to *Prevotella oris*. Despite its rareness, *Prevotella oris* may cause meningitis and spinal canal infection. The symptoms of this kind of infection may not be typical, and conventional culture tests have difficulty detecting pathogens. mNGS is a promising technique to identify pathogens under such circumstances. Clinicians should be aware of this possibility and treat it with rapid imaging, neurosurgical intervention and targeted antibiotics.

FOOTNOTES

Author contributions: Zhang WW contributed to manuscript writing and editing; Ai C, Liu DK and Mao CT contributed to data collection and analysis; Guo Y contributed to conceptualization and supervision; All authors read and approved the final manuscript.

Informed consent statement: The patient's legal guardian provided informed written consent to publish this case report and any accompanying images.

Conflict-of-interest statement: All authors report no having relevant conflicts of interest for this article.

CARE Checklist (2016) statement: The authors have read the CARE Checklist (2016), and the manuscript was prepared and revised according to the CARE Checklist (2016).

Open-Access: This article is an open-access article that was selected by an in-house editor and fully peer-reviewed by external reviewers. It is distributed in accordance with the Creative Commons Attribution NonCommercial (CC BY-NC 4.0) license, which permits others to distribute, remix, adapt, build upon this work non-commercially, and license their derivative works on different terms, provided the original work is properly cited and the use is non-commercial. See: <https://creativecommons.org/licenses/by-nc/4.0/>

Country/Territory of origin: China

ORCID number: Wei-Wei Zhang 0000-0003-1647-166X; Yi Guo 0000-0001-9985-2585.

S-Editor: Liu XF

L-Editor: Filipodia

P-Editor: Zhang YL

REFERENCES

- 1 Sunwoo JS, Shin HR, Lee HS, Moon J, Lee ST, Jung KH, Park KI, Jung KY, Kim M, Lee SK, Chu K. A hospital-based study on etiology and prognosis of bacterial meningitis in adults. *Sci Rep* 2021; **11**: 6028 [PMID: 33727651 DOI: 10.1038/s41598-021-85382-4]
- 2 van de Beek D, de Gans J, Spanjaard L, Weisfelt M, Reitsma JB, Vermeulen M. Clinical features and prognostic factors in adults with bacterial meningitis. *N Engl J Med* 2004; **351**: 1849-1859 [PMID: 15509818 DOI: 10.1056/NEJMoa040845]
- 3 Oordt-Speets AM, Bolijn R, van Hoorn RC, Bhavsar A, Kyaw MH. Global etiology of bacterial meningitis: A systematic review and meta-analysis. *PLoS One* 2018; **13**: e0198772 [PMID: 29889859 DOI: 10.1371/journal.pone.0198772]
- 4 Frat JP, Godet C, Grollier G, Blanc JL, Robert R. Cervical spinal epidural abscess and meningitis due to *Prevotella oris* and *Peptostreptococcus micros* after retropharyngeal surgery. *Intensive Care Med* 2004; **30**: 1695 [PMID: 15034651 DOI: 10.1007/s00134-004-2265-x]
- 5 Robertson FC, Lepard JR, Mekary RA, Davis MC, Yunusa I, Gormley WB, Baticulon RE, Mahmud MR, Misra BK, Rattani A, Dewan MC, Park KB. Epidemiology of central nervous system infectious diseases: a meta-analysis and systematic review with implications for neurosurgeons worldwide. *J Neurosurg* 2018; 1-20 [PMID: 29905514 DOI: 10.3171/2017.10.JNS17359]
- 6 Sarrazin J-L, Bonneville F, Martin-Blondel G. Infections cérébrales. *Journal de Radiologie Diagnostique et Interventionnelle* 2012; **93**: 503-20 [DOI: 10.1016/j.jradio.2012.03.003]
- 7 Alamarat Z, Hasbun R. Management of Acute Bacterial Meningitis in Children. *Infect Drug Resist* 2020; **13**: 4077-4089 [PMID: 33204125 DOI: 10.2147/IDR.S240162]
- 8 Yousefi-Mashouf R, Duerden B, Eley A, Rawlinson A, Goodwin L. Incidence and distribution of non-pigmented *Prevotella* species in periodontal pockets before and after periodontal therapy. *Microb Ecol Health Dis* 1993; **6**: 35-42 [DOI: 10.3109/08910609309141560]
- 9 Ramachandran PS, Wilson MR. Metagenomics for neurological infections - expanding our imagination. *Nat Rev Neurol* 2020; **16**: 547-556 [PMID: 32661342 DOI: 10.1038/s41582-020-0374-y]
- 10 Xue H, Wang XH, Shi L, Wei Q, Zhang YM, Yang HF. Dental focal infection-induced ventricular and spinal canal empyema: A case report. *World J Clin Cases* 2020; **8**: 3114-3121 [PMID: 32775394 DOI: 10.12998/wjcc.v8.i14.3114]
- 11 Lan ZW, Xiao MJ, Guan YL, Zhan YJ, Tang XQ. Detection of *Listeria monocytogenes* in a patient with meningoencephalitis using next-generation sequencing: a case report. *BMC Infect Dis* 2020; **20**: 721 [PMID: 33004020 DOI: 10.1186/s12879-020-05447-z]
- 12 Ramchandar N, Coufal NG, Warden AS, Briggs B, Schwarz T, Stinnett R, Xie H, Schlager R, Foley J, Clarke C, Waldeman B, Enriquez C, Osborne S, Arrieta A, Salyakina D, Janvier M, Sendi P, Totapally BR, Dimmock D, Farnaes L. Metagenomic Next-Generation Sequencing for Pathogen Detection and Transcriptomic Analysis in Pediatric Central Nervous System Infections. *Open Forum Infect Dis* 2021; **8**: ofab104 [PMID: 34104666 DOI: 10.1093/ofid/ofab104]
- 13 Nagy E, Justesen US, Eitel Z, Urbán E; ESCMID Study Group on Anaerobic Infection. Development of EUCAST disk diffusion method for susceptibility testing of the *Bacteroides fragilis* group isolates. *Anaerobe* 2015; **31**: 65-71 [PMID: 25464140 DOI: 10.1016/j.anaerobe.2014.10.008]
- 14 Viswanath LS, Gunalan A, Jamir I, S B, S A, K A, Biswas R. *Prevotella oris*: A lesser known etiological agent of pleural

- effusion. *Anaerobe* 2022; **78**: 102644 [PMID: [36116686](#) DOI: [10.1016/j.anaerobe.2022.102644](#)]
- 15 **Cobo F**, Pérez-Carrasco V, Pérez-Rosillo MÁ, García-Salcedo JA, Navarro-Marí JM. Bacteremia due to *Prevotella oris* of probable hepatic origin. *Anaerobe* 2022; **76**: 102586 [PMID: [35598874](#) DOI: [10.1016/j.anaerobe.2022.102586](#)]
- 16 **Carmack AE**, LaRocco AM, Mathew M, Goldberg HV, Patel DM, Saleeb PG. Subacute Polymicrobial Bacterial Pericarditis Mimicking Tuberculous Pericarditis: A Case Report. *Am J Case Rep* 2021; **22**: e933684 [PMID: [34782592](#) DOI: [10.12659/AJCR.933684](#)]
- 17 **Duan J**, Zhang C, Che X, Fu J, Pang F, Zhao Q, You Z. Detection of aerobe-anaerobe mixed infection by metagenomic next-generation sequencing in an adult suffering from descending necrotizing mediastinitis. *BMC Infect Dis* 2021; **21**: 905 [PMID: [34479479](#) DOI: [10.1186/s12879-021-06624-4](#)]
- 18 **Bein T**, Brem J, Schlüsselbauer T. Bacteremia and sepsis due to *Prevotella oris* from dentoalveolar abscesses. *Intensive Care Med* 2003; **29**: 856 [PMID: [12664220](#) DOI: [10.1007/s00134-003-1697-z](#)]
- 19 **Abufaied M**, Iqbal P, Yassin MA. A Rare and Challenging Presentation of Empyema Necessitans/Necessitasis Leading to Brachial Plexopathy. *Cureus* 2020; **12**: e8267 [PMID: [32596084](#) DOI: [10.7759/cureus.8267](#)]



Published by **Baishideng Publishing Group Inc**
7041 Koll Center Parkway, Suite 160, Pleasanton, CA 94566, USA

Telephone: +1-925-3991568

E-mail: bpgoffice@wjgnet.com

Help Desk: <https://www.f6publishing.com/helpdesk>

<https://www.wjgnet.com>

