

Round 1

Dear Reviewers,

We have received the review suggestions and have read them carefully. We are extending our sincere thanks to both experts for their careful review, as well as special thanks to the experts for their valuable suggestions. We have revised the manuscript article by article according to the suggestions of the two experts, and have revised and improved the manuscript in light of these comments. We look forward to your valuable suggestions on our comprehensive revision.

Sincerely,

Huan-Shuang Pei, MD

Department of Anesthesiology

The Fourth Hospital of Hebei Medical University

No. 12 Jian-Kang Road

Chang'an District, Shijiazhuang City, Hebei Province, China

Email: wxhmz99999@163.com

I WILL RESPOND TO EACH OF THE REVIEW SUGGESTIONS, PLEASE REVIEW THEM

Reviewer #1:

Scientific Quality: Grade C (Good)

Language Quality: Grade B (Minor language polishing)

Conclusion: Minor revision

Specific Comments to Authors: We present a case of secondary hepatocellular in which the circulation stability and recovery quality of the patient were not affected by severe hyperlactemia during the convalescence period.

1. In the conclusion section of the abstract, you have repeated your case. One should point directly to this conclusion.

Thank you for this valuable suggestion. In this case, hyperlactatemia did not affect circulatory stability or the quality of awakening. We considered that active intraoperative rehydration avoided serious harm to the organism caused by

hyperlactatemia due to insufficient tissue perfusion, while hyperlactatemia caused by decreased lactate clearance due to impaired liver function associated with surgical resection had a mild effect on the function of important organs. Strengthening body temperature protection could improve lactate circulation.

2. The authors should explain how their findings make a difference to the readers of the World Journal of Clinical Cases?

Thank you for this valuable comment. I have revised the content as suggested and have summarized these findings in Table 3.

3. It is better introduce your suggested management as a flow char or graph

Thank you for this suggestion. Please see table below for your consideration:

Table 3 Etiology, treatment, and prognosis of hyperlactatemia associated with resection of secondary hepatic metastatic carcinoma.

Causes of disease			Treatment		Prognosis	
Excessive lactic acid production	Insufficient volume leading to	Aggressive fluid replacement to improve	Severe hyperlactatemia is			
	inadequate tissue perfusion	tissue perfusion	associated with failure of all			
	Longer hepatic portal block,	Rehydration, potassium replacement,	vital organs and is difficult to			
	traumatic injury leading to ischemic	correction of acidosis	reverse with a poor prognosis			
	reperfusion injury					
	Hypothermia	Insulation therapy				
Decreased lactate clearance	Blockage of blood flow to the liver	Minimize hepatic portal block time,	Severe hyperlactatemia is			
	leading to a decrease in the liver's	temperature protection	associated with cardiac			
	ability to remove lactic acid		surgery, epilepsy and other			
	Impaired liver function associated	Hepatoprotective therapy	conditions where the primary			
	with surgical resection		condition can be reversed, and			
	Impaired kidney function	Maintain circulatory stability and	has a mild impact on patients			
		rehydration	with a good prognosis			

Reviewer #2:

Scientific Quality: Grade D (Fair)

Language Quality: Grade C (A great deal of language polishing)

Conclusion: Major revision

Specific Comments to Authors: It is interesting that the manuscript entitled "Hyperlactemia associated with secondary hepatocellular carcinoma resection did not affect circulation stability and quality of recovery : A case report" reported a case of hyperlactemia during postoperative resection of liver metastases following chemotherapy for sigmoid cancer, which did not affect circulatory stability or quality of recovery. The remainder of this paper is structured as follows. However, the paper is too lengthy, and the written English needs improvement. Rigorous revision of this manuscript is indispensable. My comments are below:

1. Language: Written English needs improvement. The manuscript was reviewed by a native English speaker.

Thank you for this valuable suggestion. I have revised the manuscript and made linguistic modifications throughout.

2. This section is lengthy, and the content of the conclusion is halved.

Thanks. I have revised the Conclusion section and made deletions accordingly.

Thank you for this comment. In this case, hyperlactatemia did not affect circulatory stability or the quality of awakening. We considered that active intraoperative rehydration avoided serious harm to the organism caused by hyperlactatemia due to insufficient tissue perfusion, while hyperlactatemia caused by decreased lactate clearance due to impaired liver function associated with surgical resection had a mild effect on the function of important organs. Strengthening body temperature protection could improve lactate circulation.

3. CASE PRESENTATION

- 3.1 This part is too lengthy, please simplify, the timeline of case presentation can be summarized on a table

Thank you for this suggestion. The content has been simplified and the timeline of the

case presentation has been summarized in a table.

Table 4 Case report timeline.

Item	Timeline
Preoperative	1 Ten months after diagnosis of sigmoid colon cancer, 4 months after postoperative chemotherapy for liver metastasis.
	2 History of “cerebral infarction” for more than six months without special treatment.
	3 Abdominal CT scan suggestive of liver metastasis.
	4 The operation was performed under general anesthesia.
Perioperative	5 Invasive blood pressure was monitored and arterial blood gas analysis was conducted.
	6 BIS was monitored.
	7 Induction of conventional anesthesia with tracheal intubation.
	8 CVC after general anesthesia. Ultrasound-guided transversus abdominis block was performed.
	9 Maintenance of anesthesia was performed using static inhalation compound general anesthesia.
	10 The operation was performed using Pringle's method to block the hepatic metastases, and arterial blood gases were monitored dynamically intraoperatively. Hyperlactatemia was detected and treated aggressively with fluid replacement and other treatments. However, the patient's vital signs were stable.
	11 The surgery was successfully completed.
Postoperative	12 After the operation, the patient was transferred to the PACU. There was still hyperlactatemia detected. However, the patient's vital signs were stable.
	13 Treatments such as temperature protection as well as arterial blood gas testing were implemented, 5 although hyperlactatemia was present, vital signs were stable and awakening was satisfactory. The patient returned to

the ward after surgery.

14 The patient was discharged six days after surgery.

15 The patient was followed up two months after the operation

BIS, bispectral index; CT, computed tomography; CVC, central venous catheter; PACU, post-anesthesia care unit

3.2 Correct “His” to “Her” on the second line of the physical examination section

Thank you for this suggestion. We modified the text to indicate that the patient’s height was 156 cm and her weight was 60 kg.

3.3 The follow-up time is short, the patient needs to be followed up during post-discharge

Thank you for noting this. We have indicated that the patient's vital signs were stable at the two-month postoperative follow-up.

3.4 Images were lacking, please add the abdominal CT and pathological images

Thank you for this valuable suggestion. We have indicated that abdominal CT tomography suggested liver metastases (Figure 1) and a pathological diagnosis of hypofractionated adenocarcinoma (Figure 2).

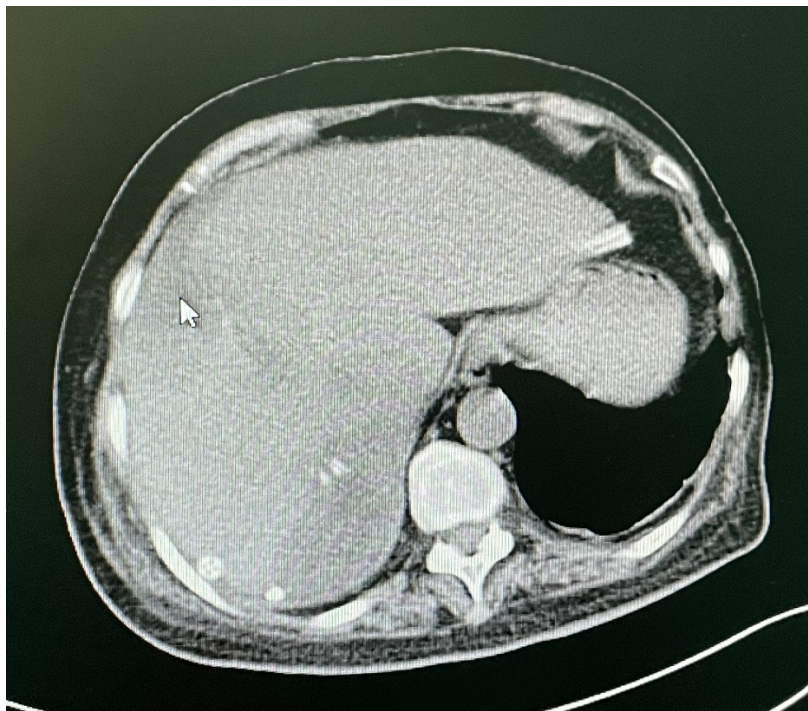


Figure 1 Abdominal computed tomography (CT) findings suggestive of liver metastases.

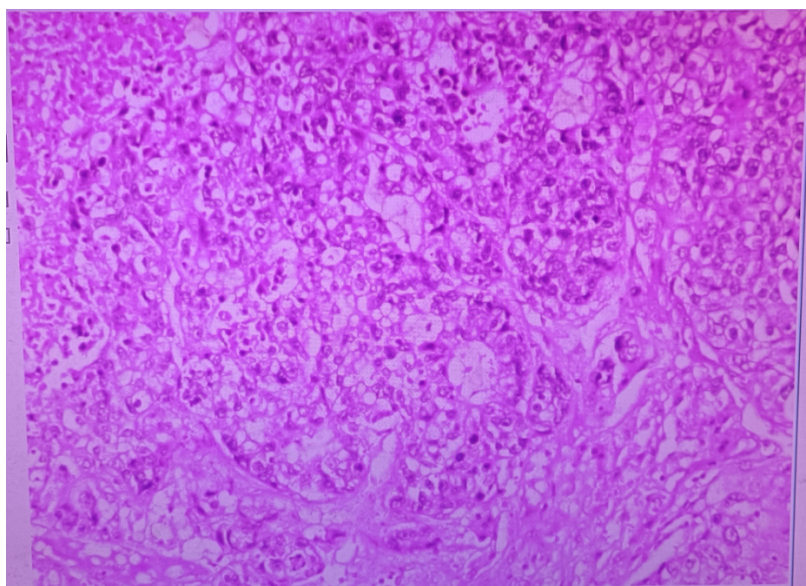


Figure 2 Imaging depicting the pathological diagnosis of hypofractionated adenocarcinoma.

4 DISCUSSION

4.1. This part is too lengthy; please simplify the manuscript accordingly. The background narrative is too lengthy, and there is no need to introduce the lactic acid metabolic pathway in cells or the mechanism of liver lactic acid metabolism.

Thank you for this valuable insight. We have modified the manuscript as follows:

“Approximately 57% of secondary liver cancers are caused by hematogenous metastasis of pancreatic, gastric, and colorectal cancers, whereas lung, cervical, breast, and ovarian cancers commonly metastasize to the liver via hematogenous metastasis. Secondary liver cancer is insensitive to radiotherapy and chemotherapy. Therefore, early surgical resection is the single most effective treatment.

Since the liver is rich in blood flow and liver tissue is fragile, the risk of intraoperative hemorrhage is high. Therefore, a key goal of surgery is to effectively control liver bleeding. To reduce bleeding, resection is often performed after hilar block. Both Pringle's method and the hemihilar block are common clinical methods for blocking hepatic blood flow. The Pringle method is advantageous in reducing bleeding. At the same time, the anesthesiologist needs to pay close attention to the bleeding volume and rate during tumor resection, the status of the operative field, and the dynamic changes of the patient's blood pressure and pulse rate as well as other indicators. While actively administering fluids and transfusing blood, it is necessary

to pay extra attention to changes in electrolytes and metabolic indices to avoid serious metabolic disorders such as hyperlactatemia, which may affect the function of vital organs.”

4.2. Please review the literature on the causes, corresponding treatments, and prognoses of hyperlactemia associated with secondary hepatocellular carcinoma resection and summarize them in a table.

Thank you for this comment. We have revised as suggested and have summarized the literature in Table 3.

Table 3 Etiology, treatment, and prognosis of hyperlactatemia associated with resection of secondary hepatic metastatic carcinoma.

Causes of disease			Treatment		Prognosis	
Excessive lactic acid production	Insufficient volume leading to	Aggressive fluid replacement to improve	Severe hyperlactatemia is			
	inadequate tissue perfusion	tissue perfusion	associated with failure of all			
	Longer hepatic portal block,Rehydration, potassium replacement,vital organs and is difficult to	traumatic injury leading to ischemiccorrection of acidosis	reverse with a poor prognosis			
	reperfusion injury					
	Hypothermia	Insulation therapy				
Decreased lactate clearance	Blockage of blood flow to the liver	Minimize hepatic portal block time,	Severe hyperlactatemia is			
	leading to a decrease in the liver'stemperature protection		associated with cardiac			
	ability to remove lactic acid		surgery, epilepsy and other			
	Impaired liver function associated	Hepatoprotective therapy	conditions where the primary			
	with surgical resection		condition can be reversed, and			
	Impaired kidney function	Maintain circulatory stability and	has a mild impact on patients			
		rehydration	with a good prognosis			

4.3 Limitation and future scope are missing

Thank you for this valuable suggestion. We have revised accordingly, stating that this was a case study, and that clinical trials are needed for further study.

5 REFERENCES

There are relatively few references. Please add the references.

Thank you for this valuable suggestion. We have modified the reference section as follows:

REFERENCES

- 1 **Kraut JA**, Madias NE. Lactic acidosis. *N Engl J Med* 2014; 371: 2309-2319 [PMID: 25494270 DOI: 10.1056/NEJMra1309483]
- 2 **Haas SA**, Lange T, Saugel B, Petzoldt M, Fuhrmann V, Metschke M, Kluge S. Severe hyperlactatemia, lactate clearance and mortality in unselected critically ill patients. *Intensive Care Med* 2016; 42: 202-210 [PMID: 26556617 DOI: 10.1007/s00134-015-4127-0]
- 3 **Bian L-Y**, Yu K, Long C. Hyperlactatemia in cardiac surgery. *Med Rev* 2010; 16: 3281-3283
- 4 **Theodoraki K**, Arkadopoulos N, Fragulidis G, Voros D, Karapanos K, Markatou M, Kostopanagiotou G, Smyrniotis V. Transhepatic lactate gradient in relation to liver ischemia/reperfusion injury during major hepatectomies. *Liver Transpl* 2006; 12: 1825-1831 [PMID: 17031827 DOI: 10.1002/lt.20911]
- 5 **Su WL**, Zhu TH. Research progress on the etiology and treatment of hyperlactatemia. *J Doubtful Dis* 2017; 8: 848-851
- 6 **Hu BJ**, Bo LL, Deng S, *et al.* Advances in research related to lactic acidosis. *China Pharm Herald* 2018; 15: 22-25
- 7 **Liu Y**, Liu YL, Cheng W, Yin XM, Jiang B. The expression of SIRT3 in primary hepatocellular carcinoma and the mechanism of its tumor suppressing effects. *Eur Rev Med Pharmacol Sci* 2017; 21: 978-998 [PMID: 28338198]
- 8 **Li CX**, Zhang Q, Ma LB, *et al.* Effect of multimodal insulation on postoperative regression and fee-for-service in patients undergoing radical hepatocellular carcinoma surgery. *Chin J Anesthesiol* 2017; 37: 1304-1307

- 9 **Zhou H**, Jia WD, Qiao XF, Liu FP, Chen L, Hu CL. Clinical values of multimodal preventive analgesia in patients with partial hepatectomy for liver cancer. *Zhonghua Wai Ke Za Zhi* 2017; 55: 141-145 [PMID: 28162215 DOI: 10.3760/cma.j.issn.0529-5815.2017.02.013]
- 10 **Cheung TT**, Chok KS, Chan AC, Tsang SH, Dai WC, Yau TC, Kwong A, Lo CM. Survival analysis of breast cancer liver metastasis treated by hepatectomy: a propensity score analysis for Chinese women in Hong Kong. *Hepatobiliary Pancreat Dis Int* 2019; 18: 452-457 [PMID: 31474444 DOI: 10.1016/j.hbpd.2019.08.001]

Round 2

Reviewer# 06395944: The manuscript entitled "Hyperlactemia associated with secondary hepatocellular carcinoma resection in relation to circulation stability and quality of recovery: A case report" reported a case of hyperlactemia during postoperative resection of liver metastases following chemotherapy for sigmoid cancer, which did not affect circulatory stability or quality of recovery. The paper is well structured. The authors had well completed the "Answering reviewers". I find the article potentially acceptable for publication after minor revision, my comment is below: 1. The revised manuscript includes both Chinese and English, I guess the author may have uploaded the wrong file.

Answer: We apologize for any inconvenience caused. There was a small problem when I uploaded the revised version, which showed both Chinese and English. We have corrected this issue in the whole manuscript.