

World Journal of *Orthopedics*

World J Orthop 2023 May 18; 14(5): 268-368



EVIDENCE REVIEW

- 268 Unhappy triad of the knee: What are the current concepts and opinions?
Hoveidaei AH, Sattarpour R, Dadgostar H, Razi S, Razi M

REVIEW

- 275 Tuberculosis of the spine
Leowattana W, Leowattana P, Leowattana T

MINIREVIEWS

- 294 Implications of obesity in patients with foot and ankle pathology
Ubillus HA, Samsonov AP, Azam MT, Forney MP, Jimenez Mosquea TR, Walls RJ
- 302 Surgical strategy of the treatment of atypical femoral fractures
Shim BJ, Won H, Kim SY, Baek SH
- 312 Amputation in diabetic foot ulcer: A treatment dilemma
Primadhi RA, Septrina R, Hapsari P, Kusumawati M

ORIGINAL ARTICLE**Basic Study**

- 319 Rotator cuff repair with an interposition polypropylene mesh: A biomechanical ovine study
Lim WSR, Yew AKS, Lie H, Chou SM, Lie DTT

Retrospective Study

- 328 Mid-term results of sub-trochanteric valgus osteotomy for symptomatic late stages Legg-Calvé-Perthes disease
Emara KM, Diab RA, Emara AK, Eissa M, Gemeah M, Mahmoud SA

- 340 Spinal fusion is an aerosol generating procedure
Langner JL, Pham NS, Richey A, Oquendo Y, Mehta S, Vorhies JS

Clinical Trials Study

- 348 Does orthotics use improve comfort, speed, and injury rate during running? A randomised control trial
Fortune AE, Sims JMG, Ampat G

CASE REPORT

- 362 Intra-abdominal myositis ossificans - a clinically challenging disease: A case report
Carbone G, Andreasi V, De Nardi P

ABOUT COVER

Editorial Board Member of *World Journal of Orthopedics*, Biju Benjamin, MBBS, MCh, MS, Surgeon, Department of Orthopaedic surgery, Forth Valley Royal Hospital, Larbert FK5 4WR, Scotland, United Kingdom.
bijuben@yahoo.com

AIMS AND SCOPE

The primary aim of *World Journal of Orthopedics* (*WJO*, *World J Orthop*) is to provide scholars and readers from various fields of orthopedics with a platform to publish high-quality basic and clinical research articles and communicate their research findings online.

WJO mainly publishes articles reporting research results and findings obtained in the field of orthopedics and covering a wide range of topics including arthroscopy, bone trauma, bone tumors, hand and foot surgery, joint surgery, orthopedic trauma, osteoarthropathy, osteoporosis, pediatric orthopedics, spinal diseases, spine surgery, and sports medicine.

INDEXING/ABSTRACTING

WJO is now abstracted and indexed in PubMed, PubMed Central, Emerging Sources Citation Index (Web of Science), Scopus, Reference Citation Analysis, China National Knowledge Infrastructure, China Science and Technology Journal Database, and Superstar Journals Database. The 2022 edition of Journal Citation Reports® cites the 2021 Journal Citation Indicator (JCI) for *WJO* as 0.62. The *WJO*'s CiteScore for 2021 is 2.4 and Scopus CiteScore rank 2021: Orthopedics and Sports Medicine is 139/284.

RESPONSIBLE EDITORS FOR THIS ISSUE

Production Editor: *Ying-Yi Yuan*, Production Department Director: *Xiang Li*, Editorial Office Director: *Jin-Lai Wang*.

NAME OF JOURNAL

World Journal of Orthopedics

ISSN

ISSN 2218-5836 (online)

LAUNCH DATE

November 18, 2010

FREQUENCY

Monthly

EDITORS-IN-CHIEF

Massimiliano Leigheb

EDITORIAL BOARD MEMBERS

<http://www.wjgnet.com/2218-5836/editorialboard.htm>

PUBLICATION DATE

May 18, 2023

COPYRIGHT

© 2023 Baishideng Publishing Group Inc

INSTRUCTIONS TO AUTHORS

<https://www.wjgnet.com/bpg/gerinfo/204>

GUIDELINES FOR ETHICS DOCUMENTS

<https://www.wjgnet.com/bpg/GerInfo/287>

GUIDELINES FOR NON-NATIVE SPEAKERS OF ENGLISH

<https://www.wjgnet.com/bpg/gerinfo/240>

PUBLICATION ETHICS

<https://www.wjgnet.com/bpg/GerInfo/288>

PUBLICATION MISCONDUCT

<https://www.wjgnet.com/bpg/gerinfo/208>

ARTICLE PROCESSING CHARGE

<https://www.wjgnet.com/bpg/gerinfo/242>

STEPS FOR SUBMITTING MANUSCRIPTS

<https://www.wjgnet.com/bpg/GerInfo/239>

ONLINE SUBMISSION

<https://www.f6publishing.com>



Intra-abdominal myositis ossificans - a clinically challenging disease: A case report

Gabriele Carbone, Valentina Andreasi, Paola De Nardi

Specialty type: Medicine, research and experimental

Provenance and peer review: Unsolicited article; Externally peer reviewed.

Peer-review model: Single blind

Peer-review report's scientific quality classification

Grade A (Excellent): 0
Grade B (Very good): B, B
Grade C (Good): C, C
Grade D (Fair): 0
Grade E (Poor): 0

P-Reviewer: Bottari A, Italy; Freund O, Israel; Kai K, Japan

Received: January 16, 2023

Peer-review started: January 16, 2023

First decision: January 31, 2023

Revised: February 25, 2023

Accepted: March 29, 2023

Article in press: March 29, 2023

Published online: May 18, 2023



Gabriele Carbone, Valentina Andreasi, Paola De Nardi, Department of Gastrointestinal Surgery, IRCCS San Raffaele Hospital, Milan 20132, Italy

Corresponding author: Paola De Nardi, FASCRS, MD, Staff Physician, Surgeon, Department of Gastrointestinal Surgery, IRCCS San Raffaele Hospital, Via Olgettina 60, Milan 20132, Italy. denardi.paola@hsr.it

Abstract

BACKGROUND

Myositis ossificans (MO) is an uncommon disorder characterized by heterotopic ossification within soft tissues. Only a few cases of intra-abdominal MO (IMO) have been described in the literature. Histology could be difficult to understand and a wrong diagnosis could lead to an improper cure.

CASE SUMMARY

We herein report the case of IMO in a healthy 69-year-old man. The patient presented with an abdominal mass in the left lower quadrant. A computed tomography scan showed an inhomogeneous mass with multiple calcifications. The patient underwent radical excision of the mass. Histopathological findings were compatible with MO. Five months later the patient showed a recurrence causing hemorrhagic shock due to intractable intralesional bleeding. The patients eventually died within three months since recurrence.

CONCLUSION

The case described could be classified as post-traumatic MO that developed close to the previously fractured iliac bone. The subsequent surgical procedure was ineffective and the disease rapidly recurred. The misleading intraoperative diagnosis led to improper surgical treatment with a dramatic evolution.

Key Words: Myositis ossificans; Post-traumatic; Diagnosis; Surgical treatment; Prognosis; Case report

©The Author(s) 2023. Published by Baishideng Publishing Group Inc. All rights reserved.

Core Tip: Myositis ossificans (MO) is a rare condition of heterotopic bone formation within muscle or soft tissues. Intra-abdominal MO is even rarer usually arousing following abdominal surgery or trauma. Its presentation is non-specific and physical examination is usually unremarkable until the mass reaches large dimensions. Laboratory examinations are within normal limits. Computed tomography scan is essential for the diagnosis, since it can show the typical “zonal patterns” of the calcifications. Histopathology can differentiate MO from infections and malignancies. However, histology could be misinterpreted for fibromatosis or sarcoma, thus leading to improper cure. The treatment may be complex and should be based on patients’ symptoms. Most patients can be treated conservatively and surgical procedures should be reserved for selected patients since repetitive surgery promotes further and more aggressive calcifications.

Citation: Carbone G, Andreasi V, De Nardi P. Intra-abdominal myositis ossificans - a clinically challenging disease: A case report. *World J Orthop* 2023; 14(5): 362-368

URL: <https://www.wjgnet.com/2218-5836/full/v14/i5/362.htm>

DOI: <https://dx.doi.org/10.5312/wjo.v14.i5.362>

INTRODUCTION

Myositis ossificans (MO) is a rare and benign connective tissue disorder characterized by non-neoplastic heterotopic ossification in the context of soft tissues. MO tends to be secondary to trauma. It is mostly found in adolescents or young adults and the lesions are predominantly located in the large skeletal muscles of the arms and thighs. This form, also known as post-traumatic MO (PTMO), is usually self-limiting thus not requiring specific surgical treatment. However, the clinical, radiological, and histological presentation of MO is often non-specific and can mimic a soft tissue malignancy, resulting in misdiagnosis and inappropriate management. We herein report a very rare case of intra-abdominal MO (IMO) and review the main features of this rarely encountered, but clinically demanding condition.

CASE PRESENTATION

Chief complaints

A 69-year-old man presented at the surgical clinic with a painless abdominal lump, located in the left iliac fossa. The patient did not refer any systemic symptom.

History of present illness

The mass had slowly increased in size over the last couple of months.

History of past illness

His past medical history included an appendectomy during his childhood. Four years earlier a car accident occurred resulting in abdominal trauma and left iliac bone fracture.

Personal and family history

The patient denied any family or personal history of malignancies.

Physical examination

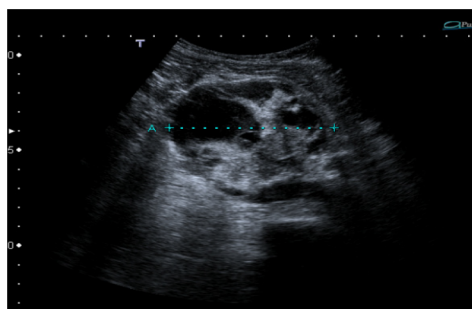
Clinical examination revealed a non-tender, firm, oval-shaped abdominal mass with smooth surface in the left lower quadrant.

Laboratory examinations

Laboratory findings were within normal range.

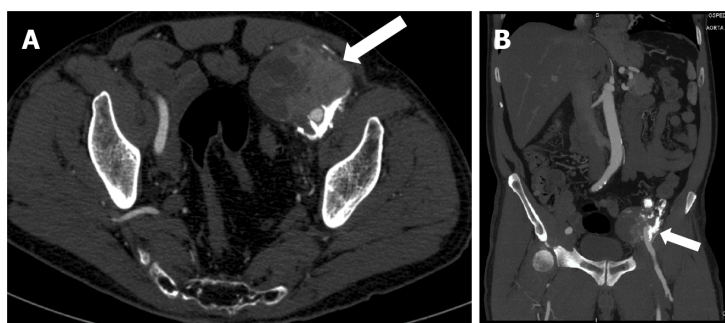
Imaging examinations

An abdominal ultrasound showed a 7-cm ovoidal lesion with a mixed echo structure, diffuse calcifications and increased vascular density at the color-Doppler control (Figure 1). A computed tomography (CT) scan was obtained with evidence of an 8 cm × 6.5 cm × 7 cm, highly inhomogeneous mass composed by multiple calcifications at the periphery (Figure 2).



DOI: 10.5312/wjo.v14.i5.362 Copyright ©The Author(s) 2023.

Figure 1 Abdominal ultrasound showed a 7-cm ovoidal lesion with a mixed echo pattern. It was possible to distinguish fluid and solid components (including diffuse calcifications).



DOI: 10.5312/wjo.v14.i5.362 Copyright ©The Author(s) 2023.

Figure 2 Computed tomography image revealed an 8 cm × 6.5 cm × 7 cm, highly inhomogeneous mass composed by multiple calcifications at the periphery. A: Axial view; B: Sagittal view.

FINAL DIAGNOSIS

The imaging features were strongly suspicious for a malignancy originating from mesenchymal cells. Based on these findings, a surgical exploration was performed.

TREATMENT

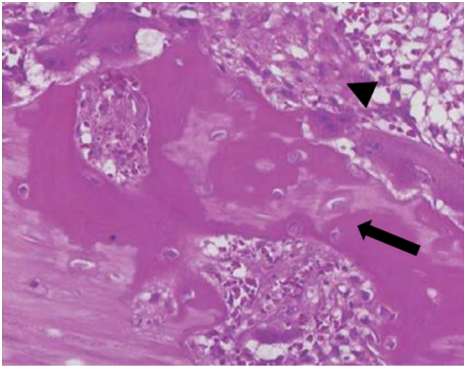
A bulky tumor with dense adhesions to the left iliac bone was found and the intraoperative histological examination was consistent with osteosarcoma. A radical excision of the mass was then carried out.

Gross examination of the surgical specimen revealed a partially capsulated, 8.5 cm × 8 cm × 6 cm mass with hemorrhagic and calcified areas. The lesion presented trabecular architecture characterized by a central area consisting of fiber cells and by a peripheral area consisting of osteoblasts, producing osteoid and bone matrix. Histopathological findings were compatible with IMO (Figure 3).

OUTCOME AND FOLLOW-UP

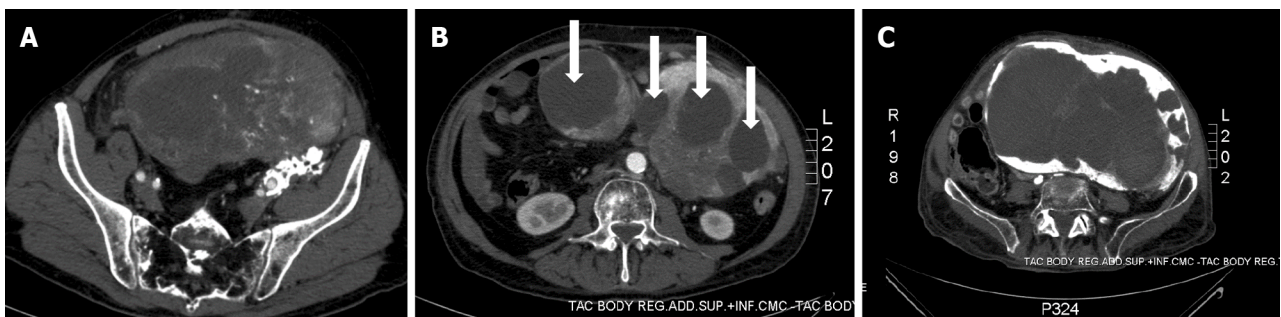
The post-operative course was complicated by a chylous fistula that was managed conservatively. Additionally, a complete thrombosis of the left femoral vein was diagnosed. The patient was then discharged with anticoagulant therapy.

Five months later, the patient returned to the Emergency Department complaining rapidly worsening abdominal pain, nausea, and vomiting. The radiological examinations showed disease recurrence with an inhomogeneous pelvic mass measuring approximately 20 cm in diameter and causing compression of the sigmoid colon (Figures 4A and 5). Because of the bowel obstruction, an explorative laparotomy was planned. At surgery, a hard, hyper vascular lesion strongly adherent to the anterior abdominal wall and to the deep posterior planes was found. Thus, due to the high risk of bleeding, only a biopsy of the mass was performed and the histopathological diagnosis confirmed an IMO. During the postoperative course the patient developed a hemorrhagic shock caused by multiple intralesional bleedings (Figure 4B). An angiography, with embolization of vessels originating from the left iliac artery, was performed with cessation of the bleeding. The lesion, however, continued to grow rapidly, infiltrating



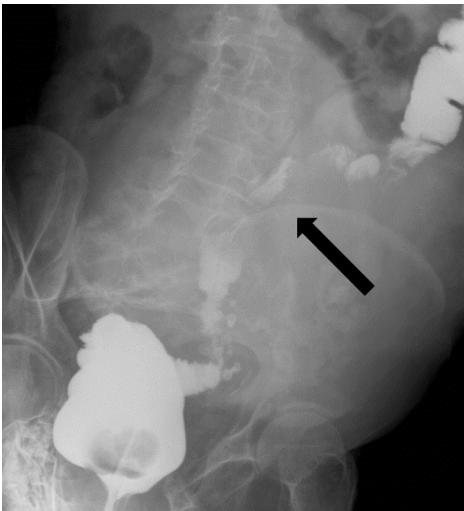
DOI: 10.5312/wjo.v14.i5.362 Copyright ©The Author(s) 2023.

Figure 3 Microscopic findings of myositis ossificans. Haematoxylin and eosin staining showing a mature lamellar bone neo-formation (arrow) and fibroblasts with elongated nuclei (arrowhead) arranged in short irregular fascicles with the typical "zonation pattern" placed in loose myxoid or collagenous stroma. Occasional mitoses can be observed, in the absence of cellular atypia.



DOI: 10.5312/wjo.v14.i5.362 Copyright ©The Author(s) 2023.

Figure 4 The computed tomography scan. A: An inhomogeneous pelvic mass measuring almost 20 cm in diameter; B: A mass with multiple haemorrhagic areas (arrows); C: A huge mass filling almost all the abdominal cavity and infiltrating the aortic plane and both ureters.



DOI: 10.5312/wjo.v14.i5.362 Copyright ©The Author(s) 2023.

Figure 5 Barium enema showing compression of the sigmoid colon (arrow).

the aortic plane and both ureters (Figure 4C). Eventually, the patient dramatically died eight months after the first diagnosis.

DISCUSSION

MO is an infrequent and non-malignant disease distinguished by abnormal heterotopic bone formation within soft tissues[1]. Two different clinical entities of MO have been reported in the literature: Progressive or genetic MO and acquired MO[2,3].

Progressive MO (PMO), also known as Munchmeyer disease, is a rare genetic autosomic dominant disorder characterized by congenital malformation of big toes and progressive heterotopic ossification of connective tissue. It usually begins in the spine and proceeds in a proximal to distal, cranial to caudal or axial to appendicular direction[4]. PMO normally develops in the first decade of life and the evidence of malformed great toes may lead to the correct diagnosis[5].

Acquired MO can be classified into neurogenic (associated with paraplegia) and non-neurogenic; the latter group can be divided into post-traumatic and idiopathic/pseudo malignant[2,3]. The case described in our report was reasonably a PTMO and, in the present article, we will discuss this clinical entity, which represents the most frequent form of MO, accounting for almost 70% of cases[6].

PTMO usually presents within the second and third decade of life, but lesions can arise at any age, as showed in our patient. PTMO typically originates in the context of the large skeletal muscles of the limbs. Quadriceps and brachialis muscles are the two most affected regions because of the high risk of traumas and injuries. However, PTMO can occur in almost every site of the body and even cases of PTMO in the hand have been described in the literature[7].

Abdominal PTMO mostly arises from a midline surgical incision or a trauma site[8], while IMO is an extremely rare condition associated with neoplasms of gastrointestinal tract or previous intra-abdominal surgery[9]. In the few IMO cases reported in literature[10,11], lesions developed inside the mesentery or the omentum after a surgical procedure and tended to grow rapidly, often resulting in bowel obstruction. Interestingly, in our patient the IMO lesion was located next to the previously fractured iliac bone and the mechanical trauma was likely the *primum movens* for the development of the lesion. The following surgical stress was probably responsible for disease recurrence and especially for the rapid growth evolution.

The clinical presentation of PTMO is highly variable, depending also on the site of origin. In case of PTMO of the limbs, it may range from an incidental finding to a rapidly enlarging painful mass with reduced range of movement. Otherwise, as mentioned before, patients with IMO can present with bowel obstruction. In some cases, clinical symptoms can mimic those of an aggressive malignant sarcoma, representing a diagnostic challenge[12,13].

The diagnosis of PTMO depends strictly on radiological and histological features since symptoms can be vague and clinical history is often silent (the only relevant element may be a trauma in the affected area). CT is the preferred imaging technique for PTMO as it best demonstrates the typical “zonal pattern”. This feature is represented by a low-attenuating center with a well-circumscribed, high-attenuating, peripheral rim of calcification. CT may also show the classical “string sign”, a thin radiolucent cleft which separates MO from adjacent bone. In our case, imaging revealed an inhomogeneous and hyper vascularized lesion with calcifications located only in one third of the circumference. These features were highly suspicious for a malignant lesion[14,15].

The “zone phenomenon” is also observed on histological tissue samples with a well-organized mature lamellar bone at the periphery, an intermediate osteoid region, and a central immature non-ossified fibroblastic focus[16]. The evidence of that histological feature makes MO diagnosis certain, since malignant neoplasms as osteosarcomas usually have a disorderly growth with a “reverse zoning effect”. However, in some cases, a biopsy from the central zone that represents the least organized portion can be histologically suggestive of malignancies, leading to incorrect diagnoses[17]. This is what happened in our case, with an intraoperative histological exam positive for osteosarcoma that led to a surgical excision. Immunohistochemistry is not strictly essential for a correct diagnosis, but it helps to differentiate MO from malignant lesions, especially in atypical cases. MO samples generally include a large number of osteoblasts, which are positive for the marker SATB2. On other hand, osteosarcomas may be characterized by MDM2 and CDK4 overexpression[18,19]. The surgical specimen of our patient demonstrated organized mature lamellar bone at the periphery of the lesion, with a great amount of SATB2 positive cells, thus confirming MO diagnosis.

The management of PTMO is controversial and depends on the severity of patient's symptoms. PTMO is generally self-limiting and lesions often decreases in volume within two years. For this reason, most patients can be treated conservatively with nonsteroidal anti-inflammatory drugs, acetic acid therapy, iontophoresis treatment, magnesium therapy, and etidronate disodium[20,21]. In case of severe and persistent symptoms, surgery is the definitive treatment even if it is associated with local recurrence [22,23]. Particularly, IMO tends to recur and, since this condition is clearly exacerbated by surgery, surgical procedures should be reserved for selected patient[11]. The highest risk of recurrence is reached when surgical excision is performed within 6 mo of previous trauma. Therefore, it is preferable to perform a surgical procedure at least six months after the trauma when the lesion is completely mature and ossified[24]. As discussed before, we decided to proceed with a surgical excision based on pre-operative and intra-operative data and the disease recurrence was dramatically extraordinary in term of growing time. To the best of our knowledge, such aggressive behavior was only described in the literature for genetic forms of MO[25] that usually present in the first decade of life and have a life

expectancy of forty years[26].

CONCLUSION

MO is an uncommon and benign condition that can develop in any part of the body. The diagnosis may be difficult even with multiple imaging modalities, especially when MO develops in atypical locations. Biopsy is the gold standard, but in some case it can be misleading. Surgical treatment should be reserved for symptomatic patients because of the risk of recurrence. The present case emphasizes the challenges and pitfalls a clinician has to face to ensure a correct diagnosis and an appropriate management of this disease.

FOOTNOTES

Author contributions: Carbone G and De Nardi P contributed to manuscript writing and editing, and data collection; Andreasi V contributed to data collection and conceptualization; all authors have read and approved the final manuscript.

Informed consent statement: The patient provided informed written consent for the use of his data.

Conflict-of-interest statement: All the authors report no relevant conflicts of interest for this article.

CARE Checklist (2016) statement: The authors have read the CARE Checklist (2016), and the manuscript was prepared and revised according to the CARE Checklist (2016).

Open-Access: This article is an open-access article that was selected by an in-house editor and fully peer-reviewed by external reviewers. It is distributed in accordance with the Creative Commons Attribution NonCommercial (CC BY-NC 4.0) license, which permits others to distribute, remix, adapt, build upon this work non-commercially, and license their derivative works on different terms, provided the original work is properly cited and the use is non-commercial. See: <https://creativecommons.org/licenses/by-nc/4.0/>

Country/Territory of origin: Italy

ORCID number: Gabriele Carbone 0000-0002-2084-7407; Valentina Andreasi 0000-0002-3793-2982; Paola De Nardi 0000-0002-9337-6765.

S-Editor: Zhao S

L-Editor: A

P-Editor: Zhao S

REFERENCES

- 1 McCarthy EF, Sundaram M. Heterotopic ossification: a review. *Skeletal Radiol* 2005; **34**: 609-619 [PMID: 16132978 DOI: 10.1007/s00256-005-0958-z]
- 2 Edwards DS, Clasper JC. Heterotopic ossification: a systematic review. *J R Army Med Corps* 2015; **161**: 315-321 [PMID: 25015927 DOI: 10.1136/jramc-2014-000277]
- 3 Meyers C, Lisiecki J, Miller S, Levin A, Fayad L, Ding C, Sono T, McCarthy E, Levi B, James AW. Heterotopic Ossification: A Comprehensive Review. *JBM R Plus* 2019; **3**: e10172 [PMID: 31044187 DOI: 10.1002/jbm4.10172]
- 4 Sheth SB, Santhosh Kumar SN, Sabhlok S, Singh M. Munchmeyer's disease-a rare case report and review of literature. *Dentomaxillofac Radiol* 2014; **43**: 20140022 [PMID: 24773627 DOI: 10.1259/dmfr.20140022]
- 5 Kartal-Kaess M, Shore EM, Xu M, Schwering L, Uhl M, Korinthenberg R, Niemeyer C, Kaplan FS, Lauten M. Fibrodysplasia ossificans progressiva (FOP): watch the great toes! *Eur J Pediatr* 2010; **169**: 1417-1421 [PMID: 20577760 DOI: 10.1007/s00431-010-1232-5]
- 6 Saad A, Azzopardi C, Patel A, Davies AM, Botchu R. Myositis ossificans revisited - The largest reported case series. *J Clin Orthop Trauma* 2021; **17**: 123-127 [PMID: 33816108 DOI: 10.1016/j.jcot.2021.03.005]
- 7 Al-Qattan MM, Al-Fahdil L, Al-Shammari HM, Joarder AI. Management of Myositis Ossificans of the Hand: A Case Report and a Review of the Literature. *J Hand Surg Am* 2017; **42**: 576.e1-576.e4 [PMID: 28385291 DOI: 10.1016/j.jhsa.2017.03.007]
- 8 Jung EJ, Lee YJ, Park ST, Ha WS, Choi SK, Hong SC, Jeong CY, Joo YT, Na JB, Ko GH. Myositis ossificans of the abdominal rectus muscle: report of a case. *Surg Today* 2006; **36**: 619-622 [PMID: 16794797 DOI: 10.1007/s00595-006-3208-7]
- 9 Bovo G, Romano F, Perego E, Franciosi C, Buffa R, Uggeri F. Heterotopic mesenteric ossification ("intraabdominal myositis ossificans"): a case report. *Int J Surg Pathol* 2004; **12**: 407-409 [PMID: 15494869 DOI: 10.1177/106689690401200416]

- 10 **Zamolyi RQ**, Souza P, Nascimento AG, Unni KK. Intraabdominal myositis ossificans: a report of 9 new cases. *Int J Surg Pathol* 2006; **14**: 37-41 [PMID: [16501833](#) DOI: [10.1177/106689690601400107](#)]
- 11 **Wilson JD**, Montague CJ, Salcuni P, Bordi C, Rosai J. Heterotopic mesenteric ossification ('intraabdominal myositis ossificans'): report of five cases. *Am J Surg Pathol* 1999; **23**: 1464-1470 [PMID: [10584699](#) DOI: [10.1097/00000478-199912000-00003](#)]
- 12 **Cortellazzo Wiel L**, Trevisan M, Murru FM, Rabusin M, Barbi E. Myositis ossificans mimicking sarcoma: a not so rare bioptic diagnostic pitfall. *Ital J Pediatr* 2020; **46**: 110 [PMID: [32736643](#) DOI: [10.1186/s13052-020-00874-9](#)]
- 13 **Ragunathan N**, Sugavanam C. Pseudomalignant myositis ossificans mimicking osteosarcoma: a case report. *J Orthop Surg (Hong Kong)* 2006; **14**: 219-221 [PMID: [16914794](#) DOI: [10.1177/230949900601400224](#)]
- 14 **Parikh J**, Hyare H, Saifuddin A. The imaging features of post-traumatic myositis ossificans, with emphasis on MRI. *Clin Radiol* 2002; **57**: 1058-1066 [PMID: [12475528](#) DOI: [10.1053/crad.2002.1120](#)]
- 15 **Tyler P**, Saifuddin A. The imaging of myositis ossificans. *Semin Musculoskelet Radiol* 2010; **14**: 201-216 [PMID: [20486028](#) DOI: [10.1055/s-0030-1253161](#)]
- 16 **Cocks M**, Mohan A, Meyers CA, Ding C, Levi B, McCarthy E, James AW. Vascular patterning in human heterotopic ossification. *Hum Pathol* 2017; **63**: 165-170 [PMID: [28315426](#) DOI: [10.1016/j.humpath.2017.03.005](#)]
- 17 **Luczyńska E**, Kasperkiewicz H, Domalik A, Cwierz A, Bobek-Billewicz B. Myositis ossificans mimicking sarcoma, the importance of diagnostic imaging - case report. *Pol J Radiol* 2014; **79**: 228-232 [PMID: [25077008](#) DOI: [10.12659/PJR.890209](#)]
- 18 **Yoshida A**, Ushiku T, Motoi T, Shibata T, Beppu Y, Fukayama M, Tsuda H. Immunohistochemical analysis of MDM2 and CDK4 distinguishes low-grade osteosarcoma from benign mimics. *Mod Pathol* 2010; **23**: 1279-1288 [PMID: [20601938](#) DOI: [10.1038/modpathol.2010.124](#)]
- 19 **Savvidou O**, Papakonstantinou O, Lakiotaki E, Melissaridou D, Korkolopoulou P, Papagelopoulos PJ. Post-traumatic myositis ossificans: a benign lesion that simulates malignant bone and soft tissue tumours. *EFORT Open Rev* 2021; **6**: 572-583 [PMID: [34377549](#) DOI: [10.1302/2058-5241.6.210002](#)]
- 20 **Moore KD**, Goss K, Anglen JO. Indomethacin versus radiation therapy for prophylaxis against heterotopic ossification in acetabular fractures: a randomised, prospective study. *J Bone Joint Surg Br* 1998; **80**: 259-263 [PMID: [9546456](#) DOI: [10.1302/0301-620x.80b2.8157](#)]
- 21 **Wieder DL**. Treatment of traumatic myositis ossificans with acetic acid iontophoresis. *Phys Ther* 1992; **72**: 133-137 [PMID: [1549634](#) DOI: [10.1093/ptj/72.2.133](#)]
- 22 **Orava S**, Sinikumpu JJ, Sarimo J, Lempainen L, Mann G, Hetsroni I. Surgical excision of symptomatic mature posttraumatic myositis ossificans: characteristics and outcomes in 32 athletes. *Knee Surg Sports Traumatol Arthrosc* 2017; **25**: 3961-3968 [PMID: [28780628](#) DOI: [10.1007/s00167-017-4667-7](#)]
- 23 **Pavey GJ**, Polfer EM, Nappo KE, Tintle SM, Forsberg JA, Potter BK. What Risk Factors Predict Recurrence of Heterotopic Ossification After Excision in Combat-related Amputations? *Clin Orthop Relat Res* 2015; **473**: 2814-2824 [PMID: [25832006](#) DOI: [10.1007/s11999-015-4266-1](#)]
- 24 **Conner GA**, Duffy M. Myositis ossificans: a case report of multiple recurrences following third molar extractions and review of the literature. *J Oral Maxillofac Surg* 2009; **67**: 920-926 [PMID: [19304059](#) DOI: [10.1016/j.joms.2008.06.106](#)]
- 25 **de Ruiter RD**, Smilde BJ, Pals G, Bravenboer N, Knaus P, Schoenmaker T, Botman E, Sánchez-Duffhues G, Pacifici M, Pignolo RJ, Shore EM, van Egmond M, Van Oosterwyck H, Kaplan FS, Hsiao EC, Yu PB, Boccardi R, De Cunto CL, Longo Ribeiro Delai P, de Vries TJ, Hilderbrandt S, Jaspers RT, Keen R, Koolwijk P, Morhart R, Netelenbos JC, Rustemeyer T, Scott C, Stockklauser C, Ten Dijke P, Triffit J, Ventura F, Ravazzolo R, Micha D, Eekhoff EMW. Fibrodysplasia Ossificans Progressiva: What Have We Achieved and Where Are We Now? *Front Endocrinol (Lausanne)* 2021; **12**: 732728 [PMID: [34858325](#) DOI: [10.3389/fendo.2021.732728](#)]
- 26 **Kaplan FS**, Zasloff MA, Kitterman JA, Shore EM, Hong CC, Rocke DM. Early mortality and cardiorespiratory failure in patients with fibrodysplasia ossificans progressiva. *J Bone Joint Surg Am* 2010; **92**: 686-691 [PMID: [20194327](#) DOI: [10.2106/JBJS.I.00705](#)]



Published by **Baishideng Publishing Group Inc**
7041 Koll Center Parkway, Suite 160, Pleasanton, CA 94566, USA

Telephone: +1-925-3991568

E-mail: bpgoffice@wjgnet.com

Help Desk: <https://www.f6publishing.com/helpdesk>

<https://www.wjgnet.com>

