

# World Journal of *Clinical Cases*

*World J Clin Cases* 2023 April 16; 11(11): 2363-2581



## Contents

Thrice Monthly Volume 11 Number 11 April 16, 2023

## REVIEW

- 2363 Presbyphagia: Dysphagia in the elderly  
*Feng HY, Zhang PP, Wang XW*

## MINIREVIEWS

- 2374 Narrative minireview of the spatial epidemiology of substance use disorder in the United States: Who is at risk and where?  
*Cuadros DF, Branscum AJ, Moreno CM, MacKinnon NJ*
- 2386 Pyroptosis and its role in cancer  
*Liu SW, Song WJ, Ma GK, Wang H, Yang L*
- 2396 Platelet rich fibrin is not a barrier membrane! Or is it?  
*Agrawal AA*
- 2405 Advances in translational therapy for locally advanced gastric cancer  
*Zhao K, Na Y, Xu HM*

## ORIGINAL ARTICLE

## Retrospective Study

- 2412 Study of pathogenic genes in a pedigree with familial dilated cardiomyopathy  
*Zhang XR, Ren H, Yao F, Liu Y, Song CL*
- 2423 Classification of hepatobiliary scintigraphy patterns in segmented gallbladder according to anatomical discordance  
*Lee YC, Jung WS, Lee CH, Kim SH, Lee SO*
- 2435 Optimal laboratory testing protocol for patients with acne taking oral isotretinoin  
*Park YJ, Shin HY, Choi WK, Lee AY, Lee SH, Hong JS*

## Observational Study

- 2443 Etiology analysis for term newborns with severe hyperbilirubinemia in eastern Guangdong of China  
*Xu JX, Lin F, Wu YH, Chen ZK, Ma YB, Yang LY*

## CASE REPORT

- 2452 Aicardi-Goutières syndrome type 7 in a Chinese child: A case report  
*Lin SZ, Yang JJ, Xie TL, Li JY, Ma JQ, Wu S, Wang N, Wang YJ*

- 2457** Allergic bronchopulmonary aspergillosis with marked peripheral blood eosinophilia and pulmonary eosinophilia: A case report  
*Zhang XX, Zhou R, Liu C, Yang J, Pan ZH, Wu CC, Li QY*
- 2464** Late presentation of dural tears: Two case reports and review of literature  
*Xu C, Dong RP, Cheng XL, Zhao JW*
- 2474** Difficult-to-treat rheumatoid arthritis treated with Abatacept combined with Baricitinib: A case report  
*Qi JP, Jiang H, Wu T, Zhang Y, Huang W, Li YX, Wang J, Zhang J, Ying ZH*
- 2482** Anesthesia management in a pediatric patient with complicatedly difficult airway: A case report  
*Chen JX, Shi XL, Liang CS, Ma XG, Xu L*
- 2489** Intracranial large artery embolism due to carotid thrombosis caused by a neck massager: A case report  
*Pan J, Wang JW, Cai XF, Lu KF, Wang ZZ, Guo SY*
- 2496** Intraductal papillary mucinous neoplasm originating from a jejunal heterotopic pancreas: A case report  
*Huang JH, Guo W, Liu Z*
- 2502** Application of endoscopic retrograde cholangiopancreatography for treatment of obstructive jaundice after hepatoblastoma surgery: A case report  
*Shu J, Yang H, Yang J, Bian HQ, Wang X*
- 2510** Total removal of a large esophageal schwannoma by submucosal tunneling endoscopic resection: A case report and review of literature  
*Mu YZ, Zhang Q, Zhao J, Liu Y, Kong LW, Ding ZX*
- 2521** SMARCA4-deficient undifferentiated thoracic tumor: A case report  
*Kwon HJ, Jang MH*
- 2528** Prostate-specific antigen reduction after capecitabine plus oxaliplatin chemotherapy: A case report  
*Zou Q, Shen RL, Guo X, Tang CY*
- 2535** Bilateral carpal tunnel syndrome and motor dysfunction caused by gout and type 2 diabetes: A case report  
*Zhang GF, Rong CM, Li W, Wei BL, Han MT, Han QL*
- 2541** Pregnancy complicated by juxtaglomerular cell tumor of the kidney: A case report  
*Fu X, Deng G, Wang K, Shao C, Xie LP*
- 2549** Successful treatment of lichen amyloidosis coexisting with atopic dermatitis by dupilumab: Four case reports  
*Zhu Q, Gao BQ, Zhang JF, Shi LP, Zhang GQ*
- 2559** Successful treatment of breast metastasis from primary transverse colon cancer: A case report  
*Jiao X, Xing FZ, Zhai MM, Sun P*

- 2567** Different endodontic treatments induced root development of two nonvital immature teeth in the same patient: A case report  
*Chai R, Yang X, Zhang AS*
- 2576** Autoimmune encephalitis after surgery for appendiceal cancer: A case report  
*Mao YH, Li L, Wen LM, Qin JM, Yang YL, Wang L, Wang FR, Zhao YZ*



**ABOUT COVER**

Editorial Board Member of *World Journal of Clinical Cases*, Farooq Shahzad, FACS, MBBS, MS, Assistant Professor, Plastic Surgery Service, Department of Surgery, Memorial Sloan-Kettering Cancer Center, New York, NY 10065, United States. fooqs@hotmail.com

**AIMS AND SCOPE**

The primary aim of *World Journal of Clinical Cases* (WJCC, *World J Clin Cases*) is to provide scholars and readers from various fields of clinical medicine with a platform to publish high-quality clinical research articles and communicate their research findings online.

WJCC mainly publishes articles reporting research results and findings obtained in the field of clinical medicine and covering a wide range of topics, including case control studies, retrospective cohort studies, retrospective studies, clinical trials studies, observational studies, prospective studies, randomized controlled trials, randomized clinical trials, systematic reviews, meta-analysis, and case reports.

**INDEXING/ABSTRACTING**

The WJCC is now abstracted and indexed in Science Citation Index Expanded (SCIE, also known as SciSearch®), Journal Citation Reports/Science Edition, Current Contents®/Clinical Medicine, PubMed, PubMed Central, Scopus, Reference Citation Analysis, China National Knowledge Infrastructure, China Science and Technology Journal Database, and Superstar Journals Database. The 2022 Edition of Journal Citation Reports® cites the 2021 impact factor (IF) for WJCC as 1.534; IF without journal self cites: 1.491; 5-year IF: 1.599; Journal Citation Indicator: 0.28; Ranking: 135 among 172 journals in medicine, general and internal; and Quartile category: Q4. The WJCC's CiteScore for 2021 is 1.2 and Scopus CiteScore rank 2021: General Medicine is 443/826.

**RESPONSIBLE EDITORS FOR THIS ISSUE**

Production Editor: Hua-Ge Yin; Production Department Director: Xiang Li; Editorial Office Director: Jin-Lei Wang.

**NAME OF JOURNAL**

*World Journal of Clinical Cases*

**ISSN**

ISSN 2307-8960 (online)

**LAUNCH DATE**

April 16, 2013

**FREQUENCY**

Thrice Monthly

**EDITORS-IN-CHIEF**

Bao-Gan Peng, Jerzy Tadeusz Chudek, George Kontogeorgos, Maurizio Serati, Ja Hyeon Ku

**EDITORIAL BOARD MEMBERS**

<https://www.wjgnet.com/2307-8960/editorialboard.htm>

**PUBLICATION DATE**

April 16, 2023

**COPYRIGHT**

© 2023 Baishideng Publishing Group Inc

**INSTRUCTIONS TO AUTHORS**

<https://www.wjgnet.com/bpg/gerinfo/204>

**GUIDELINES FOR ETHICS DOCUMENTS**

<https://www.wjgnet.com/bpg/GerInfo/287>

**GUIDELINES FOR NON-NATIVE SPEAKERS OF ENGLISH**

<https://www.wjgnet.com/bpg/gerinfo/240>

**PUBLICATION ETHICS**

<https://www.wjgnet.com/bpg/GerInfo/288>

**PUBLICATION MISCONDUCT**

<https://www.wjgnet.com/bpg/gerinfo/208>

**ARTICLE PROCESSING CHARGE**

<https://www.wjgnet.com/bpg/gerinfo/242>

**STEPS FOR SUBMITTING MANUSCRIPTS**

<https://www.wjgnet.com/bpg/GerInfo/239>

**ONLINE SUBMISSION**

<https://www.f6publishing.com>



## Successful treatment of breast metastasis from primary transverse colon cancer: A case report

Xin Jiao, Fang-Zhou Xing, Mi-Mi Zhai, Peng Sun

**Specialty type:** Medicine, research and experimental

**Provenance and peer review:** Unsolicited article; Externally peer reviewed.

**Peer-review model:** Single blind

**Peer-review report's scientific quality classification**

Grade A (Excellent): 0  
Grade B (Very good): 0  
Grade C (Good): C, C  
Grade D (Fair): D, D, D  
Grade E (Poor): 0

**P-Reviewer:** Dambraszkas Z, Lithuania; Faraji N, Iran; Pattarajierapan S, Thailand

**Received:** January 18, 2023

**Peer-review started:** January 18, 2023

**First decision:** February 7, 2023

**Revised:** February 13, 2023

**Accepted:** March 23, 2023

**Article in press:** March 23, 2023

**Published online:** April 16, 2023



**Xin Jiao, Fang-Zhou Xing, Peng Sun,** Department of Gastrointestinal Surgery, Affiliated Hospital of Weifang Medical University, Weifang 261041, Shandong Province, China

**Mi-Mi Zhai,** Department of Digestive System, Weifang People's Hospital, Weifang 261041, Shandong Province, China

**Corresponding author:** Peng Sun, PhD, Doctor, Department of Gastrointestinal Surgery, Affiliated Hospital of Weifang Medical University, No. 2428 Yuhe Road, Kuiwen District, Weifang 261041, Shandong Province, China. [1105031456@qq.com](mailto:1105031456@qq.com)

### Abstract

#### BACKGROUND

The incidence of colon cancer is increasing worldwide. Treatments for colon cancer include surgery and surgery combined with chemotherapy and radiotherapy, but the median survival rate is still poor. Colon cancer most commonly metastasizes to the lymph nodes, lungs, liver, peritoneum, and brain, but breast metastasis is rare. There is no agreement on its treatment.

#### CASE SUMMARY

A 23-year-old woman was admitted to our hospital for further treatment with a history of acute abdominal pain, nausea, and vomiting. Her physical examination and computed tomography scan revealed an abdominal tumor. Transverse colectomy was successfully performed. Histopathological examination revealed that the tumor was a mucosecretory adenocarcinoma with signet ring cells. The patient inadvertently found a mass in the outer upper quadrant of the right breast after four cycles of XELOX chemotherapy [oxaliplatin 130 mg/m<sup>2</sup>, d1, intravenous (iv) drip for 2 h; capecitabine 1000 mg/m<sup>2</sup>, po, bid, d1-d14]. After discussion with the patient, we performed a lumpectomy and frozen biopsy. The latter revealed that the breast tumor was intestinal metastasis. Genetic testing showed wild-type RAS and BRAF. So we replaced the original chemotherapy with FOLFIRI [irinotecan 180 mg/m<sup>2</sup>, d1, iv drip for 3-90 min; leucovorin 400 mg/m<sup>2</sup>, d1, iv drip for 2 h; 5-fluorouracil (5-FU) 400 mg/m<sup>2</sup>, d1 and 5-FU 1200 mg/m<sup>2</sup> d × 2 d, continuous iv drip for 46-48 h] + cetuximab (500 mg/m<sup>2</sup>, d1, iv drip for 2 h). Serum levels of tumor markers returned to normal after several treatment cycles, and there was no evidence of tumor recurrence or metastasis.

#### CONCLUSION

Breast metastasis from colon cancer is rare. Radical breast surgery should be avoided unless needed for palliation. Chemotherapy combined with targeted

therapy should be the first choice.

**Key Words:** Colon cancer; Breast metastasis; Tumor markers; FOLFIRI; Cetuximab; Prognosis; Case report

©The Author(s) 2023. Published by Baishideng Publishing Group Inc. All rights reserved.

**Core Tip:** Breast metastasis from colon cancer is rare. The prognosis is poor and conservative treatment is mainly adopted. We present a rare case of breast metastasis from colon cancer in a young patient who received chemotherapy (FOLFIRI) combined with targeted therapy (cetuximab) after undergoing transverse colectomy and lumpectomy. There was no recurrence or metastasis during the 16-mo follow-up after lumpectomy, and the treatment effect was good.

**Citation:** Jiao X, Xing FZ, Zhai MM, Sun P. Successful treatment of breast metastasis from primary transverse colon cancer: A case report. *World J Clin Cases* 2023; 11(11): 2559-2566

**URL:** <https://www.wjgnet.com/2307-8960/full/v11/i11/2559.htm>

**DOI:** <https://dx.doi.org/10.12998/wjcc.v11.i11.2559>

## INTRODUCTION

Colon cancer is the third most common type of cancer worldwide and the fourth leading cause of cancer mortality[1]. Approximately 25% of patients with colon cancer have been diagnosed as having stage IV cancer, and the five-year survival rate for patients with stage IV tumors is less than 10%[2]. The metastatic pathways of colon cancer are similar to those of other malignancies, and include lymphatic, hematogenous, and distant metastases. Breast metastasis is rare, with an incidence of 0.5%-3%[3], and is especially rare from colon carcinoma. Since the first case reported in 1976[4], only no more than 30 cases have been reported[5,6]. Hsieh and Hsu[7] summarized 45 cases that were previously reported, and we found that about 60 studies have reported this rare case so far by searching the literature in the *Reference Citation Analysis* (<https://www.referencecitationanalysis.com/>) database, PubMed, and Embase. Prognosis is poor because it is usually indicative of disseminated disease. It is important to distinguish breast metastasis from primary breast carcinoma in order to plan the most suitable treatment[8]. Treatment experience is uncomfortable due to the rarity of the metastatic pattern. We report a new case of breast metastasis from colon carcinoma.

## CASE PRESENTATION

### Chief complaints

A 23-year-old woman was admitted to our hospital in February 2021 for further treatment with a history of acute abdominal pain, nausea, and vomiting.

### History of present illness

The patient suddenly suffered from abdominal pain, nausea, and vomiting, without fever, chills, fatigue, melena, haematemesis, hematochezia, or other discomforts.

### History of past illness

The patient had no previous medical history.

### Personal and family history

There was no personal or family history of acute or chronic disease. There was no family history of tumors.

### Physical examination

Physical examination revealed abdominal tension, pressing pain, and rebound pain. There was a large abdominal mass with hard texture, unclear boundary, and uncertain size, and tenderness of the left abdomen.

### Laboratory examinations

Laboratory examination showed a significant increase in serum levels of tumor markers: Carcinoem-

bryonic antigen (CEA), 697.90 ng/mL (normal range: 0–10 ng/mL); carbohydrate antigen (CA)125, 104.20 U/mL (normal range: 0–35 U/mL); and CA72-4, > 300.0 U/mL (normal range: 0–6.9 U/mL). The level of CA19-9 (3.49 U/mL) was normal (normal range: 0–27 U/mL).

### Imaging examinations

Computed tomography (CT) and abdominal enhanced CT showed that the abdominal tumor measured 7.5 cm × 10.9 cm, with uneven density, and unclear boundary between the tumor and surrounding tissues (Figure 1A). There were swollen lymph nodes in the mesentery. Abdominal enhanced CT was highly suspicious for gastrointestinal stromal tumors, and abdominal and retroperitoneal lymph nodes were swollen. Preoperative chest CT showed no abnormalities.

### Surgical exploration and pathological diagnosis

We performed exploratory laparotomy. A tumor with hard texture was located in the middle of the transverse colon, causing peritonitis because of perforation. The diameter of the tumor was approximately 10 cm. Transverse colectomy was successfully performed. The lymph nodes around the transverse colon were cleared, but the retroperitoneal lymph nodes could not be removed. The favorable recovery period for the patient was approximately 2 wk. Immunohistochemistry was negative for CD20 and CD117, but positive for CK20, caudal-related homeobox transcription factor 2 (CDX-2) (Figure 2A), mucin 2 (Figure 2B), villin (Figure 2C), delay of germination 1, leukocyte common antigen, and CD3. Histopathological examination revealed that the tumor was a mucosecretory adenocarcinoma with signet ring cells (Figure 2D and E). Lymph node metastasis was evident (of the 24 detected lymph nodes, 23 were metastatic lymph nodes), but no distant metastasis was detected. The pathological stage was IIIC.

### Disease evolution

The patient received chemotherapy according to the National Comprehensive Cancer Network guidelines for colorectal cancer. We retested the serum tumor markers after surgery in March 2021, which revealed significant changes: CEA, 44.65 ng/mL (normal range: 0–10 ng/mL); CA125, 7.33 U/mL (normal range: 0–35 U/mL); and CA72-4, 68.0 U/mL (normal range: 0–6.9 U/mL). The level of CA19-9 was normal (< 0.6 U/mL; normal range: 0–27 U/mL). The effect of tumor resection was remarkable. The patient inadvertently found a mass in the outer upper quadrant of the right breast after receiving four cycles of chemotherapy (XELOX: Oxaliplatin 130 mg/m<sup>2</sup>, d1, iv drip for 2 h; capecitabine 1000 mg/m<sup>2</sup>, po, bid, d1–d14). Physical examination revealed that the breast mass was 1.5 cm × 2 cm in size, with hard texture, and clear boundary between the mass and surrounding tissues. Further examination was performed. Breast ultrasound showed a tumor of 2.1 cm × 1.5 cm × 1.3 cm, with unclear boundary and echo heterogeneity. Color Doppler flow imaging showed blood flow signal (Figure 1B). Axillary lymph nodes were normal. It was not clear whether the breast tumor was a primary cancer or metastasis from colon cancer. There were slight elevations in serum tumor markers: CEA, 76.7 ng/mL (normal range: 0–10 ng/mL); CA125, 7.66 U/mL (normal range: 0–35 U/mL); and CA72-4, 43.20 U/mL (normal range: 0–6.9 U/mL). The level of CA19-9 (8.83 U/mL; normal range: 0–27 U/mL) was still normal. After discussion with the patient, we decided to perform a lumpectomy and frozen biopsy in June 2021. Frozen biopsy revealed that the breast tumor was intestinal metastasis. Routine hematoxylin and eosin staining of the breast tumor revealed breast metastasis from mucosecretory adenocarcinoma possibly of colonic origin (Figure 2F and G). The tumor was negative for estrogen receptor, progesterone receptor, GATA binding protein-3 (GATA3) (Figure 2H), gross cystic disease fluid protein, human epidermal-growth factor receptor-2, and CK7, but positive for CDX-2, villin, and special AT-rich binding protein (SATB). GATA3 is an important indicator of primary breast cancer; however, CDX-2, villin, and SATB are important indicators of enterogenous breast cancer. The disease was considered to be disseminated.

## FINAL DIAGNOSIS

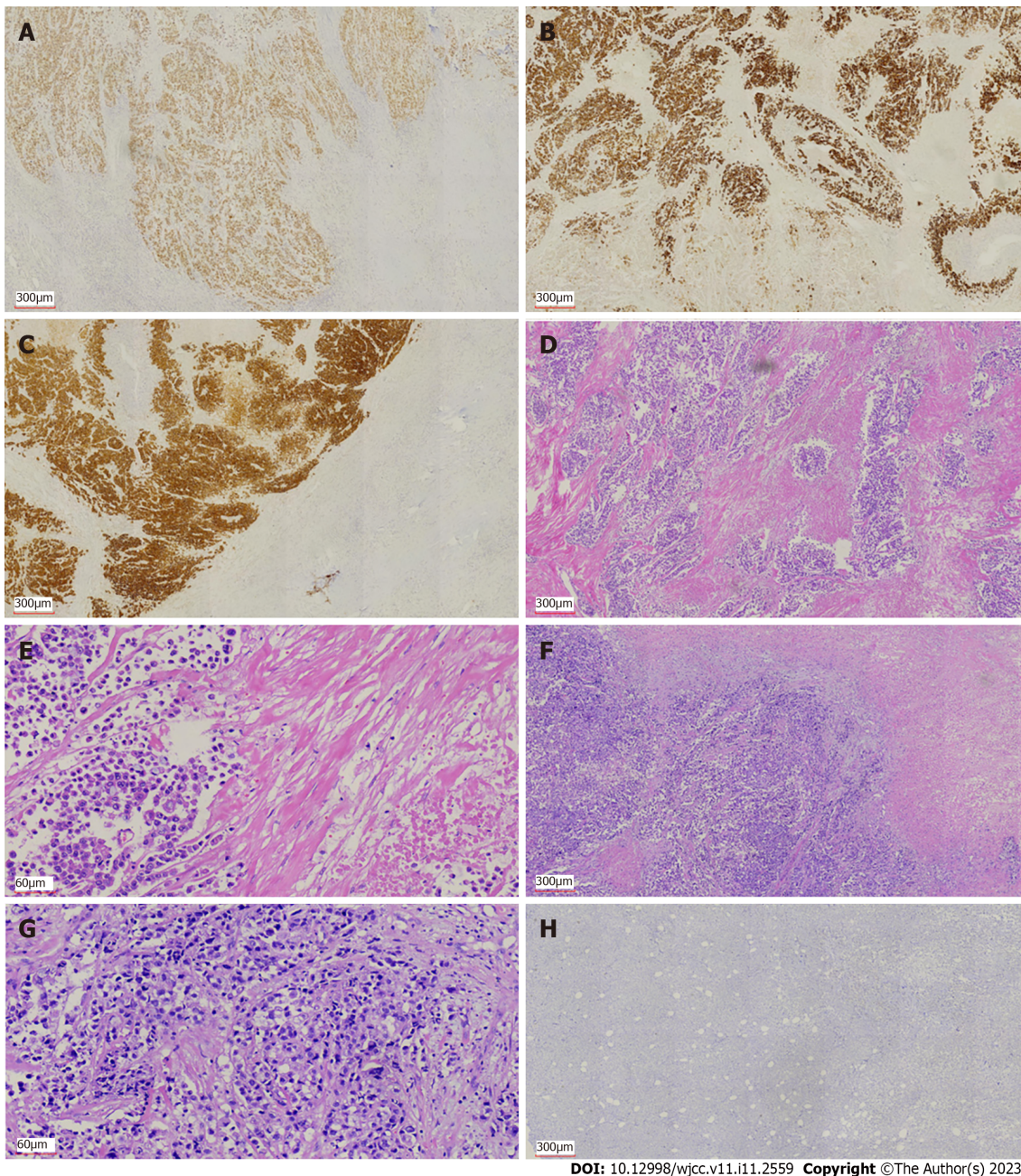
Based on the pathological findings and clinical results, the final diagnosis was breast metastasis from transverse colon carcinoma.

## TREATMENT

Genetic testing showed that *RAS* and *BRAF* were wild type. According to the treatment guidelines for distant metastasis of colon cancer, we replaced the original chemotherapy with FOLFIRI + cetuximab [irinotecan 180 mg/m<sup>2</sup>, d1, iv drip for 30–90 min; leucovorin 400 mg/m<sup>2</sup>, d1, iv drip for 2 h; 5-fluorouracil (5-FU) 400 mg/m<sup>2</sup>, d1 and 5-FU 1200 mg/(m<sup>2</sup> d) × 2 d, continuous iv drip for 46–48 h; cetuximab 500 mg/m<sup>2</sup>, d1, iv drip for 2 h]. The serum levels of tumor markers were significantly reduced in July 2021 after one treatment cycle: CEA, 26.20 ng/mL (normal range: 0–10 ng/mL); CA125,



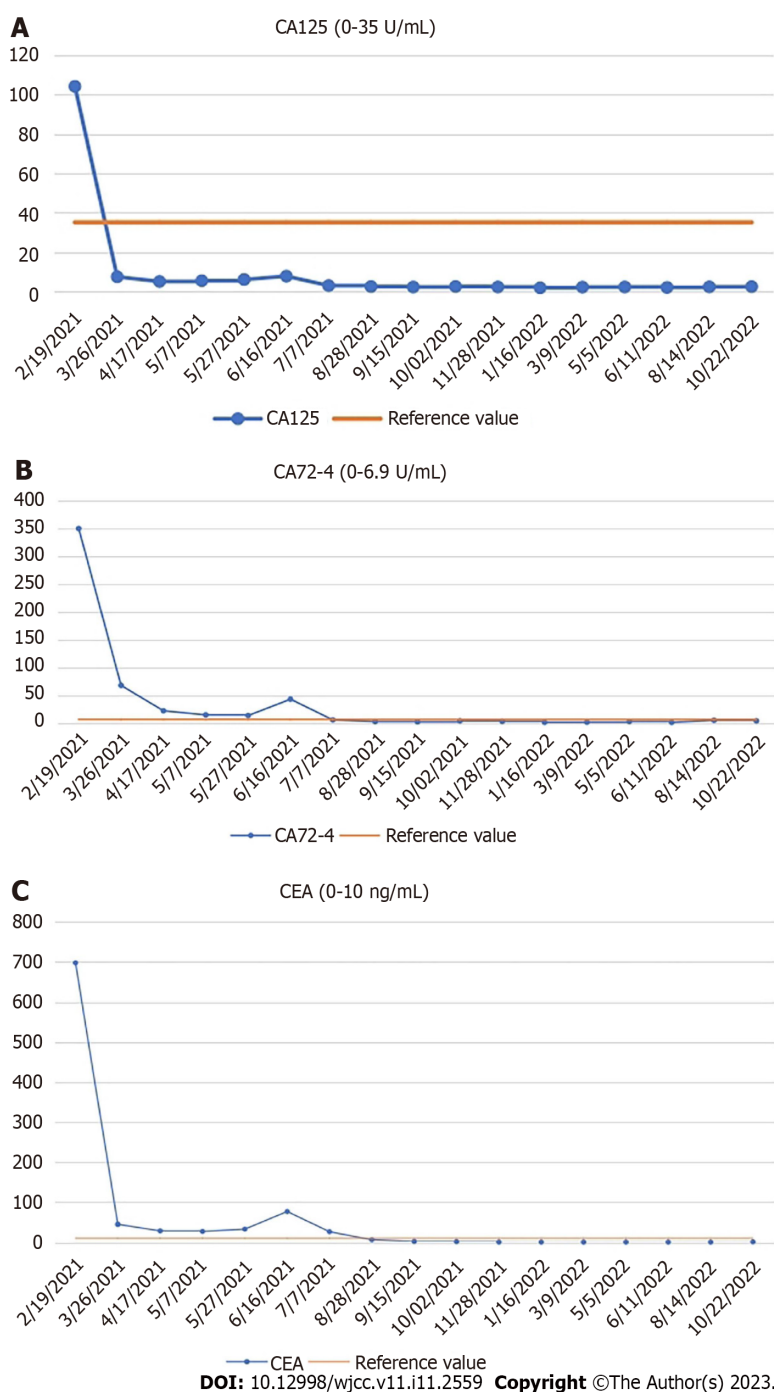




DOI: 10.12998/wjcc.v11.i11.2559 Copyright ©The Author(s) 2023.

**Figure 2 Immunohistochemical and histological features of the primary colon cancer and breast metastasis from colon cancer.** A-C: Immunohistochemical staining showed expression of caudal-related homeobox transcription factor 2 (A), mucin-2 (B), and villin (C) in colon cancer; D and E: Hematoxylin and eosin (H&E) staining showed intracellular mucus in colon cancer (D, 40 ×; E, 200 ×); F: H&E staining showed breast metastasis from colon cancer (40 ×); G: H&E staining showed adenocarcinoma cells in the breast metastasis (200 ×); H: Immunohistochemical staining showed negative expression of GATA binding protein-3 in breast metastasis from colon cancer.

Because of early diagnosis and new therapeutic methods, the overall incidence and mortality of colorectal cancer have declined significantly[12,13]. However, metastasis remains a significant challenge in prolonging survival. In particular, we have no experience in the treatment of breast metastasis from colon cancer, and there is no clear statement in the relevant guidelines. For the treatment of metastatic colorectal cancer, *KRAS*, *NRAS*, *RAS*, and *BRAF* should be tested first by genetic testing, which is the basis for treatment with cetuximab or bevacizumab. We selected cetuximab according to the results of genetic testing (wild-type *KRAS*, *NRAS*, *RAS*, and *BRAF*). After we replaced FOLFIRI + cetuximab with XELOX, the serum levels of CEA, CA125, and CA72-4 decreased dramatically. According to the treatment guidelines for distant metastasis of colon cancer, there is no mistake in giving chemotherapy and targeted treatment. Diagnosis of breast metastasis from colon cancer has been reported, but there are few reports on treatment and metastasis route[14,15]. The prognosis of such patients is poor. Barthelmes reported a case of breast metastasis from colon cancer who died 4 mo later from advanced intra-abdominal carcinomatosis[5]. In our case, the patient survived for 16 mo after receiving lumpectomy, which was due to the application of chemotherapeutic and targeted drugs, especially



**Figure 3** Changes in serum levels of carcinoembryonic antigen, carbohydrate antigen 72-4, and carbohydrate antigen 125. A: Carbohydrate antigen (CA) 125 (0-35 U/mL); B: CA72-4 (0-6.9 U/mL); C: Carcinoembryonic antigen (0-10 ng/mL). CA: Carbohydrate antigen; CEA: Carcinoembryonic antigen.

cetuximab. Cetuximab is used for the treatment of metastatic colorectal cancer with overexpression of epidermal growth factor (EGF) receptor and resistance to irinotecan-based chemotherapy. Cetuximab is an immunoglobulin G1 monoclonal antibody against EGF receptor. After specific binding, the two antibodies block the intracellular signal transduction pathway by inhibiting the binding of ligands to EGF receptor, resulting in inhibition of proliferation of cancer cells, inducing apoptosis of cancer cells, and reducing the production of matrix metalloproteinase and vascular endothelial growth factor[16]. Wang *et al*[6] performed treatment with XELOX chemotherapy regimen in combination with bevacizumab in a patient with breast metastasis from colon cancer for 8 cycles, increasing successful treatment experience for patients with this rare metastasis. This is similar to our research. In addition, most of the other reports only reported the diagnosis of this rare metastasis. The average survival time is 14.9 mo according to the literature[6]. Only one case had a more than 5-year overall survival with colon cancer metastasis to the breast[6]. The patient had a 16-mo disease-free survival in our case, which has exceeded the average level, indicating that our treatment is effective.



Our patient received chemotherapy and targeted therapy after surgery. At the same time, the patient was regularly reviewed, including chest and abdominal CT, and gastrointestinal tumor markers. The dramatic decrease in tumor markers (CEA, CA125, and CA72-4) was due to the removal of colon tumor after transverse colectomy. When breast metastasis occurs, tumor markers begin to increase. However, in our case, the levels of tumor markers (CEA, CA125, and CA72-4) decreased and remained within the normal range after treatment with FOLFIRI + cetuximab. CEA is usually highly expressed in digestive system tumors, especially in some patients with advanced gastric cancer and colorectal cancer[17]. As a specific tumor marker, CA72-4 is used to monitor the recurrence and prognosis of gastric cancer. CA125 is a sensitive marker for ovarian cancer[18], and is also elevated in gastrointestinal tumors. CA125 seems to be a better tumor marker than CEA for predicting progressive disease in colorectal cancer in both men and women[19]. The changes of CEA, CA125, and CA72-4 reflected disease progression and effect of treatment in our patient. These three tumor markers play an important role in evaluating disease status, tumor recurrence, tumor metastasis, and prognosis of gastrointestinal cancer patients. They also indicate postoperative follow-up of patients with gastrointestinal tumors. We will continue to evaluate the condition of the patient by monitoring the levels of tumor markers and CT changes, which are beneficial for treatment planning.

Breast metastasis from colon cancer is a manifestation of advanced cancer. There are a variety of treatment methods, but they are complex and difficult. In addition to chemotherapy and targeted therapy, immunotherapy may also become a new choice, which needs further clinical research. For this patient, we will continue to observe the effect of treatment by follow-up and decide whether to give further treatment according to the review results.

## CONCLUSION

Breast metastasis from colon cancer is rare. Typically, it has a poor prognosis because it is associated with disseminated metastatic disease. Radical breast surgery should be avoided unless needed for palliation. The surgical treatment of a metastatic breast tumor should be both diagnostic and palliative. Chemotherapy combined with targeted therapy should be the first choice. The mechanism of metastasis and better treatment need to be studied.

## FOOTNOTES

**Author contributions:** Jiao X reviewed the literature and contributed to manuscript drafting; Xing FZ was the patient's primary doctor and substantially contributed to the conception and design of the study and acquisition of the data; Zhai MM substantially contributed to the data acquisition; Sun P was responsible for the revision of the manuscript for important intellectual content.

**Informed consent statement:** Informed written consent was obtained from the patient for the publication of this case report.

**Conflict-of-interest statement:** All the authors report no relevant conflicts of interest for this article.

**CARE Checklist (2016) statement:** The authors have read the CARE Checklist (2016), and the manuscript was prepared and revised according to the CARE Checklist (2016).

**Open-Access:** This article is an open-access article that was selected by an in-house editor and fully peer-reviewed by external reviewers. It is distributed in accordance with the Creative Commons Attribution NonCommercial (CC BY-NC 4.0) license, which permits others to distribute, remix, adapt, build upon this work non-commercially, and license their derivative works on different terms, provided the original work is properly cited and the use is non-commercial. See: <https://creativecommons.org/licenses/by-nc/4.0/>

**Country/Territory of origin:** China

**ORCID number:** Xin Jiao 0000-0002-4153-7870; Fang-Zhou Xing 0000-0002-0451-416X; Mi-Mi Zhai 0000-0002-6909-9685; Peng Sun 0000-0002-7276-7724.

**S-Editor:** Zhao S

**L-Editor:** Wang TQ

**P-Editor:** Zhao S

## REFERENCES

- 1 **Taieb J**, Karoui M, Basile D. How I treat stage II colon cancer patients. *ESMO Open* 2021; **6**: 100184 [PMID: [34237612](#) DOI: [10.1016/j.esmoop.2021.100184](#)]
- 2 **Wang Z**, Song J, Azami NLB, Sun M. Identification of a Novel Immune Landscape Signature for Predicting Prognosis and Response of Colon Cancer to Immunotherapy. *Front Immunol* 2022; **13**: 802665 [PMID: [35572595](#) DOI: [10.3389/fimmu.2022.802665](#)]
- 3 **Tsung SH**. Metastasis of Colon Cancer to the Breast. *Case Rep Oncol* 2017; **10**: 77-80 [PMID: [28203167](#) DOI: [10.1159/000455225](#)]
- 4 **McIntosh IH**, Hooper AA, Millis RR, Greening WP. Metastatic carcinoma within the breast. *Clin Oncol* 1976; **2**: 393-401 [PMID: [1024766](#)]
- 5 **Arnaout K**, Hawa N, Agha S, Kadoura L, Aloulou M, Ayoub K. A case report of multiple bilateral breast metastases after colorectal cancer. *Int J Surg Case Rep* 2021; **81**: 105759 [PMID: [33743246](#) DOI: [10.1016/j.ijscr.2021.105759](#)]
- 6 **Wang X**, Zhang H, Lu Y. Breast metastasis of signet ring cell carcinoma from the colon: a case report. *World J Surg Oncol* 2022; **20**: 376 [PMID: [36451153](#) DOI: [10.1186/s12957-022-02840-7](#)]
- 7 **Hsieh TC**, Hsu CW. Breast metastasis from colorectal cancer treated by multimodal therapy: Case report and literature review. *Medicine (Baltimore)* 2019; **98**: e18016 [PMID: [31860952](#) DOI: [10.1097/MD.00000000000018016](#)]
- 8 **Fernández de Bobadilla L**, García Villanueva A, Collado M, de Juan A, Rojo R, Pérez J, Lisa E, Aguilera A, Mena A, González-Palacios F. Breast metastasis of primary colon cancer. *Rev Esp Enferm Dig* 2004; **96**: 415-7; 418 [PMID: [15230671](#) DOI: [10.4321/s1130-01082004000600007](#)]
- 9 **Taccogna S**, Gozzi E, Rossi L, Caruso D, Conte D, Trenta P, Leoni V, Tomao S, Raimondi L, Angelini F. Colorectal cancer metastatic to the breast: A case report. *World J Gastrointest Oncol* 2020; **12**: 1073-1079 [PMID: [33005300](#) DOI: [10.4251/wjgo.v12.i9.1073](#)]
- 10 **Gallagher DJ**, Kemeny N. Metastatic colorectal cancer: from improved survival to potential cure. *Oncology* 2010; **78**: 237-248 [PMID: [20523084](#) DOI: [10.1159/000315730](#)]
- 11 **Lane K**, Worsley D, McKenzie D. Exercise and the lymphatic system: implications for breast-cancer survivors. *Sports Med* 2005; **35**: 461-471 [PMID: [15974632](#) DOI: [10.2165/00007256-200535060-00001](#)]
- 12 **Siegel RL**, Miller KD, Jemal A. Cancer statistics, 2015. *CA Cancer J Clin* 2015; **65**: 5-29 [PMID: [25559415](#) DOI: [10.3322/caac.21254](#)]
- 13 **Zhao L**, Xu J, Liang F, Li A, Zhang Y, Sun J. Effect of Chronic Psychological Stress on Liver Metastasis of Colon Cancer in Mice. *PLoS One* 2015; **10**: e0139978 [PMID: [26444281](#) DOI: [10.1371/journal.pone.0139978](#)]
- 14 **Mihai R**, Christie-Brown J, Bristol J. Breast metastases from colorectal carcinoma. *Breast* 2004; **13**: 155-158 [PMID: [15019699](#) DOI: [10.1016/S0960-9776\(03\)00125-5](#)]
- 15 **Wakeham NR**, Satchithananda K, Svensson WE, Barrett NK, Comitis S, Zaman N, Ralleigh G, Sinnett D, Shousha S, Lim AK. Colorectal breast metastases presenting with atypical imaging features. *Br J Radiol* 2008; **81**: e149-e153 [PMID: [18440938](#) DOI: [10.1259/bjr/62391254](#)]
- 16 **Kopetz S**, Guthrie KA, Morris VK, Lenz HJ, Magliocco AM, Maru D, Yan Y, Lanman R, Manyam G, Hong DS, Sorokin A, Atreya CE, Diaz LA, Allegra C, Raghav KP, Wang SE, Lieu CH, McDonough SL, Philip PA, Hochster HS. Randomized Trial of Irinotecan and Cetuximab With or Without Vemurafenib in BRAF-Mutant Metastatic Colorectal Cancer (SWOG S1406). *J Clin Oncol* 2021; **39**: 285-294 [PMID: [33356422](#) DOI: [10.1200/JCO.20.01994](#)]
- 17 **Zheng TH**, Zhao JL, Guleng B. Advances in Molecular Biomarkers for Gastric Cancer. *Crit Rev Eukaryot Gene Expr* 2015; **25**: 299-305 [PMID: [26559090](#) DOI: [10.1615/critrevukaryotgeneexpr.2015014360](#)]
- 18 **Bast RC Jr**, Feeney M, Lazarus H, Nadler LM, Colvin RB, Knapp RC. Reactivity of a monoclonal antibody with human ovarian carcinoma. *J Clin Invest* 1981; **68**: 1331-1337 [PMID: [7028788](#) DOI: [10.1172/jci110380](#)]
- 19 **Huang CJ**, Jiang JK, Chang SC, Lin JK, Yang SH. Serum CA125 concentration as a predictor of peritoneal dissemination of colorectal cancer in men and women. *Medicine (Baltimore)* 2016; **95**: e5177 [PMID: [27893659](#) DOI: [10.1097/MD.00000000000005177](#)]



Published by **Baishideng Publishing Group Inc**  
7041 Koll Center Parkway, Suite 160, Pleasanton, CA 94566, USA

**Telephone:** +1-925-3991568

**E-mail:** [bpgoffice@wjgnet.com](mailto:bpgoffice@wjgnet.com)

**Help Desk:** <https://www.f6publishing.com/helpdesk>

<https://www.wjgnet.com>

