

# World Journal of *Clinical Cases*

*World J Clin Cases* 2023 May 16; 11(14): 3114-3368



## Contents

Thrice Monthly Volume 11 Number 14 May 16, 2023

## OPINION REVIEW

- 3114 Modernising autism spectrum disorder model engineering and treatment *via* CRISPR-Cas9: A gene reprogramming approach

*Sandhu A, Kumar A, Rawat K, Gautam V, Sharma A, Saha L*

## REVIEW

- 3128 Burden of disability in type 2 diabetes mellitus and the moderating effects of physical activity

*Oyewole OO, Ale AO, Ogunlana MO, Gurayah T*

## MINIREVIEWS

- 3140 Postoperative hypoxemia for patients undergoing Stanford type A aortic dissection

*Liu HY, Zhang SP, Zhang CX, Gao QY, Liu YY, Ge SL*

## ORIGINAL ARTICLE

## Case Control Study

- 3148 Impact of extended nursing model after multi-disciplinary treatment on young patient with post-stroke

*Xu XY, Pang ZJ, Li MH, Wang K, Song J, Cao Y, Fang M*

- 3158 Changes and significance of serum ubiquitin carboxyl-terminal hydrolase L1 and glial fibrillary acidic protein in patients with glioma

*Zhu QH, Wu JK, Hou GL*

## Retrospective Study

- 3167 Multitrack and multianchor point screw technique combined with the Wiltse approach for lesion debridement for lumbar tuberculosis

*Yuan YF, Ren ZX, Zhang C, Li GJ, Liu BZ, Li XD, Miao J, Li JF*

- 3176 Clinical features and prognostic factors in 49 patients with follicular lymphoma at a single center: A retrospective analysis

*Wu H, Sun HC, Ouyang GF*

- 3187 Value of optical coherence tomography measurement of macular thickness and optic disc parameters for glaucoma screening in patients with high myopia

*Mu H, Li RS, Yin Z, Feng ZL*

## Observational Study

- 3195 Comparative study of the clinical efficacy of all-inside and traditional techniques in anterior cruciate ligament reconstruction

*An BJ, Wang YT, Zhao Z, Wang MX, Xing GY*

- 3204** Positioning and design by computed tomography imaging in neuroendoscopic surgery of patients with chronic subdural hematoma

*Wang XJ, Yin YH, Zhang LY, Wang ZF, Sun C, Cui ZM*

- 3211** Evaluation of chronic idiopathic tinnitus and its psychosocial triggers

*Hamed SA, Attiah FA, Fawzy M, Azzam M*

- 3224** Intestinal complications in patients with Crohn's disease in the Brazilian public healthcare system between 2011 and 2020

*Sasaki LY, Martins AL, Galhardi-Gasparini R, Saad-Hossne R, Ritter AMV, Barreto TB, Marcolino T, Balula B, Yang-Santos C*

### Randomized Controlled Trial

- 3238** Effect of non-pharmacological treatment on the full recovery of social functioning in patients with attention deficit hyperactivity disorder

*Lv YB, Cheng W, Wang MH, Wang XM, Hu YL, Lv LQ*

### CASE REPORT

- 3248** Diagnosis of tuberculous uveitis by the macrogenome of intraocular fluid: A case report and review of the literature

*Zhang YK, Guan Y, Zhao J, Wang LF*

- 3256** Intragastric fish bones migrate into the liver: A case report

*Dai MG, Zheng JJ, Yang J, Ye B*

- 3261** Primary seminal vesicle adenocarcinoma with a history of seminal vesicle cyst: A case report and review of literature

*Yao Y, Liu S, He YL, Luo L, Zhang GM*

- 3267** Immune checkpoint inhibitor therapy-induced autoimmune polyendocrine syndrome type II and Crohn's disease: A case report

*Gao MJ, Xu Y, Wang WB*

- 3275** Late-onset mitochondrial encephalomyopathy with lactic acidosis and stroke-like episodes syndrome with mitochondrial DNA 3243A>G mutation masquerading as autoimmune encephalitis: A case report

*Wang JW, Yuan XB, Chen HF*

- 3282** Metastatic gastric cancer from breast carcinoma presenting with paraneoplastic rheumatic syndrome: A case report

*Rech MB, da-Cruz ER, Salgado K, Balbinot RA, Balbinot SS, Soldera J*

- 3288** Novel mutation of SPG4 gene in a Chinese family with hereditary spastic paraplegia: A case report

*Wang J, Bu WT, Zhu MJ, Tang JY, Liu XM*

- 3295** Chronic pulmonary mucormycosis caused by rhizopus microsporus mimics lung carcinoma in an immunocompetent adult: A case report

*Guo XZ, Gong LH, Wang WX, Yang DS, Zhang BH, Zhou ZT, Yu XH*

- 3304** Idiopathic sclerosing mesenteritis presenting with small bowel volvulus in a patient with antiphospholipid syndrome: A case report  
*Chennavasini P, Gururatsakul M*
- 3311** *Neisseria mucosa* - A rare cause of peritoneal dialysis-related peritonitis: A case report  
*Ren JM, Zhang XY, Liu SY*
- 3317** Rectal prolapse in a 30-year-old bladder stone male patient: A case report  
*Ding HX, Huang JG, Feng C, Tai SC*
- 3323** Successful treatment of veno-arterial extracorporeal membrane oxygenation complicated with left ventricular thrombus by intravenous thrombolysis: A case report  
*Wang YD, Lin JF, Huang XY, Han XD*
- 3330** Successful remimazolam sedation-epidural block in an older patient with severe chronic obstructive pulmonary disease: A case report  
*Yu JJ, Pei HS, Meng Y*
- 3340** *De novo* mutation of NAXE (APOAIBP)-related early-onset progressive encephalopathy with brain edema and/or leukoencephalopathy-1: A case report  
*Ding L, Huang TT, Ying GH, Wang SY, Xu HF, Qian H, Rahman F, Lu XP, Guo H, Zheng G, Zhang G*
- 3351** Iatrogenic atlantoaxial rotatory subluxation after thyroidectomy in a pediatric patient: A case report  
*Hong WJ, Lee JK, Hong JH, Han MS, Lee SS*
- 3356** Bladder metastasis from epidermal growth factor receptor mutant lung cancer: A case report  
*Jin CB, Yang L*
- 3362** Primary rectal mucosa-associated lymphoid tissue lymphoma treated with only endoscopic submucosal dissection: A case report  
*Lee WS, Noh MG, Joo YE*

**ABOUT COVER**

Editorial Board Member of *World Journal of Clinical Cases*, Jaw-Yuan Wang, MD, PhD, Professor, Surgical Oncologist, Department of Surgery, Kaohsiung Medical University Hospital, Kaohsiung Medical University, Kaohsiung 807, Taiwan. jawyuanwang@gmail.com

**AIMS AND SCOPE**

The primary aim of *World Journal of Clinical Cases* (WJCC, *World J Clin Cases*) is to provide scholars and readers from various fields of clinical medicine with a platform to publish high-quality clinical research articles and communicate their research findings online.

WJCC mainly publishes articles reporting research results and findings obtained in the field of clinical medicine and covering a wide range of topics, including case control studies, retrospective cohort studies, retrospective studies, clinical trials studies, observational studies, prospective studies, randomized controlled trials, randomized clinical trials, systematic reviews, meta-analysis, and case reports.

**INDEXING/ABSTRACTING**

The WJCC is now abstracted and indexed in Science Citation Index Expanded (SCIE, also known as SciSearch®), Journal Citation Reports/Science Edition, Current Contents®/Clinical Medicine, PubMed, PubMed Central, Scopus, Reference Citation Analysis, China National Knowledge Infrastructure, China Science and Technology Journal Database, and Superstar Journals Database. The 2022 Edition of Journal Citation Reports® cites the 2021 impact factor (IF) for WJCC as 1.534; IF without journal self cites: 1.491; 5-year IF: 1.599; Journal Citation Indicator: 0.28; Ranking: 135 among 172 journals in medicine, general and internal; and Quartile category: Q4. The WJCC's CiteScore for 2021 is 1.2 and Scopus CiteScore rank 2021: General Medicine is 443/826.

**RESPONSIBLE EDITORS FOR THIS ISSUE**

Production Editor: Hua-Ge Yin; Production Department Director: Xu Guo; Editorial Office Director: Jin-Lei Wang.

**NAME OF JOURNAL**

*World Journal of Clinical Cases*

**ISSN**

ISSN 2307-8960 (online)

**LAUNCH DATE**

April 16, 2013

**FREQUENCY**

Thrice Monthly

**EDITORS-IN-CHIEF**

Bao-Gan Peng, Jerzy Tadeusz Chudek, George Kontogeorgos, Maurizio Serati, Ja Hyeon Ku

**EDITORIAL BOARD MEMBERS**

<https://www.wjgnet.com/2307-8960/editorialboard.htm>

**PUBLICATION DATE**

May 16, 2023

**COPYRIGHT**

© 2023 Baishideng Publishing Group Inc

**INSTRUCTIONS TO AUTHORS**

<https://www.wjgnet.com/bpg/gerinfo/204>

**GUIDELINES FOR ETHICS DOCUMENTS**

<https://www.wjgnet.com/bpg/GerInfo/287>

**GUIDELINES FOR NON-NATIVE SPEAKERS OF ENGLISH**

<https://www.wjgnet.com/bpg/gerinfo/240>

**PUBLICATION ETHICS**

<https://www.wjgnet.com/bpg/GerInfo/288>

**PUBLICATION MISCONDUCT**

<https://www.wjgnet.com/bpg/gerinfo/208>

**ARTICLE PROCESSING CHARGE**

<https://www.wjgnet.com/bpg/gerinfo/242>

**STEPS FOR SUBMITTING MANUSCRIPTS**

<https://www.wjgnet.com/bpg/GerInfo/239>

**ONLINE SUBMISSION**

<https://www.f6publishing.com>





## Rectal prolapse in a 30-year-old bladder stone male patient: A case report

Hong-Xiang Ding, Jia-Guo Huang, Chao Feng, Sheng-Cheng Tai

**Specialty type:** Medicine, research and experimental

**Provenance and peer review:** Unsolicited article; Externally peer reviewed.

**Peer-review model:** Single blind

**Peer-review report's scientific quality classification**

Grade A (Excellent): 0  
Grade B (Very good): 0  
Grade C (Good): C, C  
Grade D (Fair): 0  
Grade E (Poor): 0

**P-Reviewer:** Cassell III AK, Liberia; Pietroletti R, Italy

**Received:** February 4, 2023

**Peer-review started:** February 4, 2023

**First decision:** March 24, 2023

**Revised:** March 31, 2023

**Accepted:** April 12, 2023

**Article in press:** April 12, 2023

**Published online:** May 16, 2023



**Hong-Xiang Ding, Jia-Guo Huang, Sheng-Cheng Tai,** Department of Urology, Affiliated Xiaoshan Hospital, Hangzhou Normal University, Hangzhou 310000, Zhejiang Province, China

**Chao Feng,** School of Medicine, Hangzhou Normal University, Hangzhou 310000, Zhejiang Province, China

**Corresponding author:** Sheng-Cheng Tai, MM, Surgeon, Department of Urology, Affiliated Xiaoshan Hospital, Hangzhou Normal University, No. 728 North Yucai Road, Xiaoshan District, Hangzhou 311200, Zhejiang Province, China. [tsc13516811191@126.com](mailto:tsc13516811191@126.com)

### Abstract

#### BACKGROUND

Rectal prolapse occurs most commonly in children and middle-aged and elderly women and is relatively rare in young men and is occasionally caused by bladder stones. Severe rectal prolapse, bilateral hydronephrosis, and renal insufficiency caused by bladder stones are rare in a 30-year-old man.

#### CASE SUMMARY

We report the case of a 30-year-old male patient with cerebral palsy who presented with a large bladder stone that resulted in severe rectal prolapse, bilateral hydronephrosis, and renal insufficiency. Following a definitive diagnosis, the bladder stone was successfully removed, and his kidney function returned to normal. We assessed the patient's nutritional status and stone composition and concluded that the main cause was malnutrition.

#### CONCLUSION

Rectal prolapse is a rare clinical manifestation of bladder stones, particularly in young adults. Cerebral palsy patients are a vulnerable group in society because of their intellectual disabilities and communicative impairments. Accordingly, besides taking care of their daily diet, abnormal signs in their bodies should receive the doctors' attention in a timely manner.

**Key Words:** Bladder stone; Rectal prolapse; Cerebral palsy; Malnutrition; Case report

©The Author(s) 2023. Published by Baishideng Publishing Group Inc. All rights reserved.

**Core Tip:** Bladder stones are generally observed in elderly males and children but are rarely found in young adults. Similarly, rectal prolapse is extremely rare in young men. Clinically, the most common symptoms of bladder stones are urinary frequency, interrupted urine flow, typically terminal hematuria, dysuria, or suprapubic pain, which are worst at the end of urination. Rectal prolapse is a rare clinical manifestation of bladder stones. We report an unusual case of a young man with cerebral palsy who presented with rectal prolapse and finally confirmed a diagnosis of bladder stone. Patients with cerebral palsy are unable to accurately describe physical discomfort due to intellectual disability and communication disabilities. Therefore, the abnormal signs in their body should be given timely attention by doctors, and early diagnosis and provision of appropriate active treatment positively impact on the prognosis of patients.

**Citation:** Ding HX, Huang JG, Feng C, Tai SC. Rectal prolapse in a 30-year-old bladder stone male patient: A case report. *World J Clin Cases* 2023; 11(14): 3317-3322

**URL:** <https://www.wjgnet.com/2307-8960/full/v11/i14/3317.htm>

**DOI:** <https://dx.doi.org/10.12998/wjcc.v11.i14.3317>

## INTRODUCTION

Bladder stones constitute approximately 5% of all urinary tract stones[1]. They are generally observed in elderly males and children and are rarely found in young adults[2-4]. The most common symptoms of bladder stones are urinary frequency, interrupted urine flow, typically terminal hematuria, dysuria, or suprapubic pain, which are worst at the end of urination. These symptoms may be exacerbated following sudden movement and exercise[5,6]. In addition to dysuria, children may experience pulling of the penis, urinary retention, enuresis, or rectal prolapse. Bladder stones are incidental findings in 10% of cases[7,8]. Bladder stone presentations are often due to interrupted urination, dysuria, or gross hematuria. Rectal prolapse is an extremely rare reason for a doctor's visit for bladder stones in young adults. Here, we report the case of a 30-year-old male patient.

## CASE PRESENTATION

### Chief complaints

A 30-year-old male patient with cerebral palsy presented to the emergency department with a history of recurrent rectal prolapse for one year and a six-hour failed manual reduction procedure.

### History of present illness

The symptoms started one year before presentation with recurrent rectal prolapse. When rectal prolapse had occurred, the patient had shown obvious irritability and painful expressions. The obvious irritability and painful expressions could be relieved after manual reduction. Six hours before admission, the patient developed rectal prolapse. Because of a failed manual reduction procedure, he was brought to the emergency department of our hospital, accompanied by a doctor of his welfare home.

### History of past illness

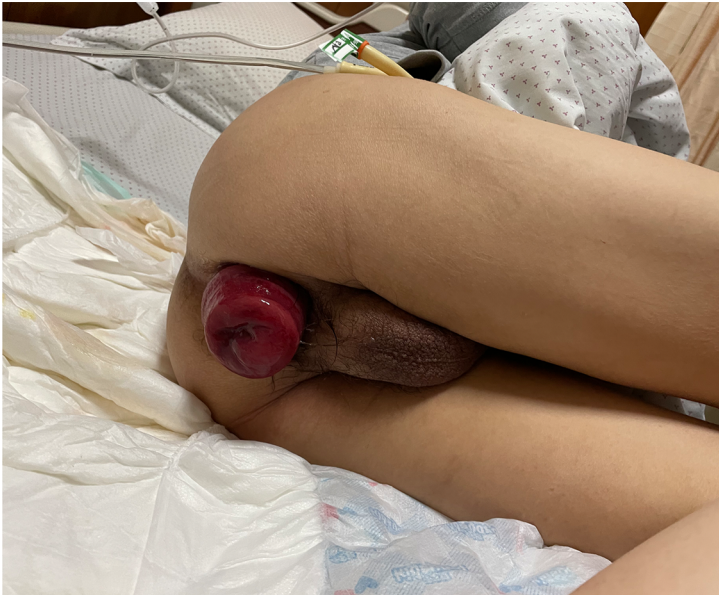The patient had typical clinical manifestations of cerebral palsy, including central motor disorders, abnormal posture, intellectual disability, communicative impairments, and abnormal mental behavior. He could walk only short distances, spent most of his time sitting or resting in bed, and his emotional changes could only be guessed through facial expressions.

### Personal and family history

The patient's family history was unknown because he was abandoned in an orphanage after being diagnosed with cerebral palsy in infancy.

### Physical examination

On physical examination, his body mass index (BMI), calculated from 145 cm of height and 35 kg of weight, was 16.6 kg/m<sup>2</sup>. A palpable mass in the bladder area of the lower abdomen demonstrated marked tenderness, and the rectum was prolapsed approximately 10 cm from the anus (Figure 1).



DOI: 10.12998/wjcc.v11.i14.3317 Copyright ©The Author(s) 2023.

Figure 1 Rectal prolapse.

#### Laboratory examinations

Blood biochemical analysis indicated a potassium level of 2.443 mmol/L, creatinine levels of 381  $\mu$ mol/L, and blood urea nitrogen of 11.53 mmol/L.

#### Imaging examinations

Abdominal computed tomography revealed a large bladder stone, bilateral hydronephrosis, and thickening of the bladder wall (Figure 2).

### FINAL DIAGNOSIS

Bladder stone, rectal prolapse.

### TREATMENT

The anorectal surgeon manually reset the prolapsed rectum, and the patient was referred to the urology department for treatment. After the patient's hypokalemia was corrected and nutritional support was provided, we performed a cystotomy and excised the bladder stone. We analyzed the components of the bladder stone and found that the main components were ammonium uric acid and calcium oxalate.

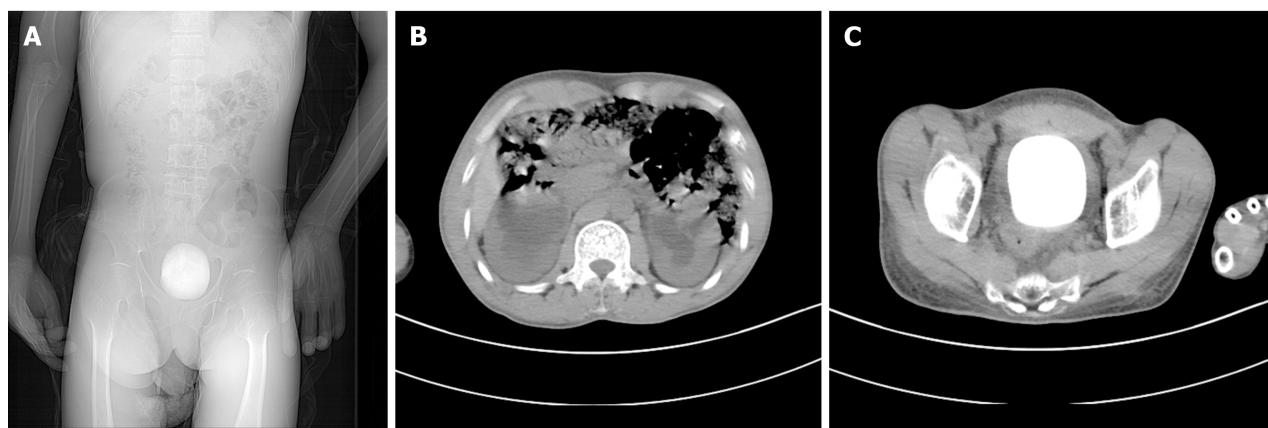
### OUTCOME AND FOLLOW-UP

One week after the operation, the patient's catheter was removed, and he returned to normal urination. The renal function and serum potassium were normal upon reexamination. The patient with rectal prolapse underwent surgery in the proctology department.

### DISCUSSION

Bladder stones are rare causes of rectal prolapse. In the past few decades, only four papers have reported rectal prolapse caused by bladder stones. Among them, three cases were of primary bladder stones in infants and young children[9-11], and one case was of secondary bladder stones caused by foreign bodies in an adult's bladder[12]. There have been no reports of bladder stones as the primary cause of rectal prolapse in adults. This study reports a patient aged 30 years without prior history of benign prostatic hyperplasia, whose large bladder stone led to severe rectal prolapse, bilateral





DOI: 10.12998/wjcc.v11.i14.3317 Copyright ©The Author(s) 2023.

**Figure 2** Preoperative abdominal computed tomography findings. A: A large bladder stone; B: Bilateral hydronephrosis; and C: A large bladder stone and thickening of the bladder wall.

hydronephrosis, and renal insufficiency.

Rectal prolapse mostly occurs in children, middle-aged, and elderly women and is generally related to an increase in abdominal pressure (such as constipation), chronic cough, difficulty in urinating, or multiple deliveries, which often leads to increased abdominal pressure and pushes the rectum to prolapse downward[13]. Rectal prolapse is rarer in men than it is in women. Some theories suggest that the prostate is a powerful anchor for the pelvic organ and may also be associated with low-frequency constipation[14]. In this patient, dysuria due to bladder stones was a probable cause, accompanied by a persistent increase in the abdominal pressure required to urinate, ultimately leading to rectal prolapse. Additionally, the prolapsed rectum, pulling the floor of the bladder may have caused chronic, incomplete bladder emptying, favoring urine residue and stone formation. They affect each other, leading to a vicious circle.

In recent decades, the incidence of bladder stones has decreased annually[15]. Bladder stones are usually multi-factorial in etiology[3] and are classified as primary, secondary, or migratory[16]. Primary or endemic bladder stones are usually observed in children in areas with poor hydration, recurrent diarrhea, and a diet deficient in animal protein without any other urinary tract pathology[7]. Secondary bladder stones are most commonly caused by bladder outlet obstruction in adults, accounting for 45%–79% of bladder stones. They are also associated with neurogenic bladder dysfunction, chronic bacteriuria, foreign bodies, catheters, bladder diverticula, bladder augmentation, and urinary diversion [3,5,6,17,18]. The term “migratory” refers to stones that have left the upper urinary tract after forming and may serve as a site for bladder stone growth once they have passed[19]. It was necessary to analyze the etiology of the patient’s bladder stone; its composition was mainly ammonium acid urate and calcium oxalate, which is consistent with research findings on bladder stones caused by malnutrition [20]. Furthermore, the patient’s BMI of 16.6 indicated a poor nutritional state. Thus, the stone formation in the patient was due to malnutrition and low water intake but was also aggravated by secondary urinary tract infection after stone formation.

It is also likely that rectal prolapse and bladder stones are two separate pathologies. The patient had cerebral palsy and could have been prone to chronic constipation as an underlying risk factor for rectal prolapse. However, the outcome of the disease is often not caused by a single factor; therefore it is necessary to consider whether there is an interaction between pathogenic factors when studying the pathogenic mechanism.

The patient was diagnosed with cerebral palsy and was unable to live independently. Residing in a welfare home, he could not express his physical discomfort clearly. In the early stage of rectal prolapse, the patient had abnormal physical signs, but the doctors did not notice them promptly, and he did not receive treatment until severe rectal prolapse occurred one year later. It is possible that the doctors in the welfare home did not conduct a comprehensive evaluation of the patient, which may have accounted for the delayed diagnosis and treatment. However, patients with cerebral palsy are a vulnerable group in society and deserve special attention.

## CONCLUSION

Bladder stones are a rare cause of rectal prolapse, particularly in young adults. In this case, the diagnosis and treatment were delayed because of the patient’s cerebral palsy, intellectual disability, and communication impairment. Patients with cerebral palsy are a vulnerable group in society and deserve particular attention. Accordingly, besides taking care of their daily diet, clinicians should be keenly

aware of any abnormal signs in the patient's body and make timely diagnoses and treatments.

## ACKNOWLEDGEMENTS

We acknowledge the contribution of the participants. We thank Home for Researchers editorial team ([www.home-for-researchers.com](http://www.home-for-researchers.com)) for language editing service.

## FOOTNOTES

**Author contributions:** Tai SC contributed to conceptualization, supervision, writing-review and editing; Ding HX contributed to investigation, writing-original draft; Huang JG contributed to investigation; Feng C contributed to case collection, and all authors have read and approved the final manuscript.

**Supported by** Bureau of Science and Technology in Xiaoshan District, Hangzhou, China, NO. 2020210.

**Informed consent statement:** Informed consent was obtained from the patients' guardian for publication of this case report details.

**Conflict-of-interest statement:** All the authors report no relevant conflicts of interest for this article.

**CARE Checklist (2016) statement:** The authors have read the CARE Checklist (2016), and the manuscript was prepared and revised according to the CARE Checklist (2016).

**Open-Access:** This article is an open-access article that was selected by an in-house editor and fully peer-reviewed by external reviewers. It is distributed in accordance with the Creative Commons Attribution NonCommercial (CC BY-NC 4.0) license, which permits others to distribute, remix, adapt, build upon this work non-commercially, and license their derivative works on different terms, provided the original work is properly cited and the use is non-commercial. See: <https://creativecommons.org/licenses/by-nc/4.0/>

**Country/Territory of origin:** China

**ORCID number:** Sheng-Cheng Tai [0000-0002-4014-3159](https://orcid.org/0000-0002-4014-3159).

**S-Editor:** Liu XF

**L-Editor:** A

**P-Editor:** Cai YX

## REFERENCES

- Aydogdu O, Telli O, Burgu B, Beduk Y. Infravesical obstruction results as giant bladder calculi. *Can Urol Assoc J* 2011; **5**: E77-E78 [PMID: [21806900](https://pubmed.ncbi.nlm.nih.gov/21806900/) DOI: [10.5489/cuaj.10130](https://doi.org/10.5489/cuaj.10130)]
- Halstead SB. Epidemiology of bladder stone of children: precipitating events. *Urolithiasis* 2016; **44**: 101-108 [PMID: [26559057](https://pubmed.ncbi.nlm.nih.gov/26559057/) DOI: [10.1007/s00240-015-0835-8](https://doi.org/10.1007/s00240-015-0835-8)]
- Takasaki E, Suzuki T, Honda M, Imai T, Maeda S, Hosoya Y. Chemical compositions of 300 Lower urinary tract calculi and associated disorders in the urinary tract. *Urol Int* 1995; **54**: 89-94 [PMID: [7538235](https://pubmed.ncbi.nlm.nih.gov/7538235/) DOI: [10.1159/000282696](https://doi.org/10.1159/000282696)]
- Naqvi SA, Rizvi SA, Shahjehan S. Bladder stone disease in children: clinical studies. *J Pak Med Assoc* 1984; **34**: 94-101 [PMID: [6429380](https://pubmed.ncbi.nlm.nih.gov/6429380/)]
- Smith JM, O'Flynn JD. Vesical stone: The clinical features of 652 cases. *Ir Med J* 1975; **68**: 85-89 [PMID: [1112692](https://pubmed.ncbi.nlm.nih.gov/1112692/)]
- Millán-Rodríguez F, Errando-Smet C, Rousaud-Barón F, Izquierdo-Latorre F, Rousaud-Barón A, Villavicencio-Mavrich H. Urodynamic findings before and after noninvasive management of bladder calculi. *BJU Int* 2004; **93**: 1267-1270 [PMID: [15180620](https://pubmed.ncbi.nlm.nih.gov/15180620/) DOI: [10.1111/j.1464-410X.2004.04815.x](https://doi.org/10.1111/j.1464-410X.2004.04815.x)]
- Lal B, Paryani JP, Memon SU. Childhood bladder stones-an endemic disease of developing countries. *J Ayub Med Coll Abbottabad* 2015; **27**: 17-21 [PMID: [26182729](https://pubmed.ncbi.nlm.nih.gov/26182729/)]
- Al-Marhoon MS, Sarhan OM, Awad BA, Helmy T, Ghali A, Dawaba MS. Comparison of endourological and open cystolithotomy in the management of bladder stones in children. *J Urol* 2009; **181**: 2684-7; discussion 2687 [PMID: [19375100](https://pubmed.ncbi.nlm.nih.gov/19375100/) DOI: [10.1016/j.juro.2009.02.040](https://doi.org/10.1016/j.juro.2009.02.040)]
- Liu J. One Case Report of Bladder Stone Complicated with Prolapse of Anus in Children. *Jiangxi Medical Journal* 1982; **6**: 64-64
- Munns J, Amawi F. A large urinary bladder stone: an unusual cause of rectal prolapse. *Arch Dis Child* 2010; **95**: 1026 [PMID: [20870623](https://pubmed.ncbi.nlm.nih.gov/20870623/) DOI: [10.1136/adc.2010.198440](https://doi.org/10.1136/adc.2010.198440)]
- Lauschke H. Large urinary bladder stones associated with prolapse of the rectum in children: case report. *Trop Doct* 1989; **19**: 65-66 [PMID: [2734839](https://pubmed.ncbi.nlm.nih.gov/2734839/) DOI: [10.1177/004947558901900207](https://doi.org/10.1177/004947558901900207)]

- 12 **Chi J**, Guo Z. [A case report of rectal prolapse caused by bladder stones]. *Gong Qi Yi Kan* 1995; 2: 87-87
- 13 **Goldstein SD**, Maxwell PJ 4th. Rectal prolapse. *Clin Colon Rectal Surg* 2011; **24**: 39-45 [PMID: [22379404](#) DOI: [10.1055/s-0031-1272822](#)]
- 14 **Church J**. Rectal Prolapse: Diagnosis and Clinical Management. *Gastroenterology* 2009; 136: 1456-1457 [DOI: [10.1053/j.gastro.2009.02.031](#)]
- 15 **Ye Z**, Zeng G, Yang H, Li J, Tang K, Wang G, Wang S, Yu Y, Wang Y, Zhang T, Long Y, Li W, Wang C, Wang W, Gao S, Shan Y, Huang X, Bai Z, Lin X, Cheng Y, Wang Q, Xu Z, Xie L, Yuan J, Ren S, Fan Y, Pan T, Wang J, Li X, Chen X, Gu X, Sun Z, Xiao K, Jia J, Zhang Q, Sun T, Xu C, Shi G, He J, Song L, Sun G, Wang D, Liu Y, Han Y, Liang P, Wang Z, He W, Chen Z, Xing J, Xu H. The status and characteristics of urinary stone composition in China. *BJU Int* 2020; **125**: 801-809 [PMID: [30958622](#) DOI: [10.1111/bju.14765](#)]
- 16 **Philippou P**, Moraitis K, Masood J, Junaid I, Buchholz N. The management of bladder lithiasis in the modern era of endourology. *Urology* 2012; **79**: 980-986 [PMID: [22119259](#) DOI: [10.1016/j.urology.2011.09.014](#)]
- 17 **Douenias R**, Rich M, Badlani G, Mazor D, Smith A. Predisposing factors in bladder calculi. Review of 100 cases. *Urology* 1991; **37**: 240-243 [PMID: [2000681](#) DOI: [10.1016/0090-4295\(91\)80293-g](#)]
- 18 **Yang X**, Wang K, Zhao J, Yu W, Li L. The value of respective urodynamic parameters for evaluating the occurrence of complications linked to benign prostatic enlargement. *Int Urol Nephrol* 2014; **46**: 1761-1768 [PMID: [24811567](#) DOI: [10.1007/s11255-014-0722-1](#)]
- 19 **Childs MA**, Mynderse LA, Rangel LJ, Wilson TM, Lingeman JE, Krambeck AE. Pathogenesis of bladder calculi in the presence of urinary stasis. *J Urol* 2013; **189**: 1347-1351 [PMID: [23159588](#) DOI: [10.1016/j.juro.2012.11.079](#)]
- 20 **Salah MA**, Holman E, Khan AM, Toth C. Percutaneous cystolithotomy for pediatric endemic bladder stone: experience with 155 cases from 2 developing countries. *J Pediatr Surg* 2005; **40**: 1628-1631 [PMID: [16226996](#) DOI: [10.1016/j.jpedsurg.2005.06.039](#)]



Published by **Baishideng Publishing Group Inc**  
7041 Koll Center Parkway, Suite 160, Pleasanton, CA 94566, USA

**Telephone:** +1-925-3991568

**E-mail:** [bpgoffice@wjgnet.com](mailto:bpgoffice@wjgnet.com)

**Help Desk:** <https://www.f6publishing.com/helpdesk>

<https://www.wjgnet.com>

