

World Journal of *Gastroenterology*

World J Gastroenterol 2023 May 21; 29(19): 2888-3047



REVIEW

- 2888 Radiomics in colorectal cancer patients

Inchingolo R, Maino C, Cannella R, Vernuccio F, Cortese F, Dezio M, Pisani AR, Giandola T, Gatti M, Giannini V, Ippolito D, Faletti R

MINIREVIEWS

- 2905 Branched chain amino acids in hepatic encephalopathy and sarcopenia in liver cirrhosis: Evidence and uncertainties

Marrone G, Serra A, Miele L, Biolato M, Liguori A, Grieco A, Gasbarrini A

- 2916 Assessment of delayed bleeding after endoscopic submucosal dissection of early-stage gastrointestinal tumors in patients receiving direct oral anticoagulants

Sugimoto M, Murata M, Kawai T

ORIGINAL ARTICLE

Basic Study

- 2932 TATA-box-binding protein-associated factor 15 is a novel biomarker that promotes cell proliferation and migration in gastrointestinal stromal tumor

Guo CM, Tang L, Li X, Huang LY

- 2950 Susceptibility patterns and virulence genotypes of *Helicobacter pylori* affecting eradication therapy outcomes among Egyptian patients with gastroduodenal diseases

Asaad AM, El-Azab G, Abdelsameea E, Elbahr O, Kamal A, Abdel-Samiee M, Abdelfattah A, Abdallah H, Maher D, El-Refaie A, Ghanem SE, Ansari S, Awad SM

- 2961 MMP14 is a diagnostic gene of intrahepatic cholangiocarcinoma associated with immune cell infiltration

Wu J, Guo Y, Zuo ZF, Zhu ZW, Han L

Case Control Study

- 2979 Machine learning model for prediction of low anterior resection syndrome following laparoscopic anterior resection of rectal cancer: A multicenter study

Wang Z, Shao SL, Liu L, Lu QY, Mu L, Qin JC

Retrospective Study

- 2992 Where is the optimal plane to mobilize the anterior rectal wall in female patients undergoing total mesorectal excision?

Jin W, Yang J, Li XY, Wang WC, Meng WJ, Li Y, Liang YC, Zhou YM, Yang XD, Li YY, Li ST

- 3003 Association of vitamin D and polymorphisms of its receptor with antiviral therapy in pregnant women with hepatitis B

Wang R, Zhu X, Zhang X, Liu H, Ji YL, Chen YH

Observational Study

- 3013** Gastrointestinal manifestations of long-term effects after COVID-19 infection in patients with dialysis or kidney transplantation: An observational cohort study

Chancharoenthana W, Kamolratanakul S, Leelahavanichkul A, Ariyanon W, Chinpraditsuk S, Saelim R, Vadcharavivad S, Phumratanaprapin W, Wilairatana P

META-ANALYSIS

- 3027** Short vs long-course antibiotic therapy in adults with acute cholangitis: A systematic review, meta-analysis, and evidence quality assessment

Kasparian K, Christou CD, Petidis K, Doumas M, Giouleme O

CASE REPORT

- 3040** Pulmonary hypertension, nephrotic syndrome, and polymyositis due to hepatitis C virus infection: A case report

Zhao YN, Liu GH, Wang C, Zhang YX, Yang P, Yu M

ABOUT COVER

Editorial Board Member of *World Journal of Gastroenterology*, John K Triantafillidis, MD, PhD, FEBGH, Associate Professor of Medicine, Staff Physician, Iasi University of Medicine and Pharmacy, Romania, "Metropolitan General" Hospital, Holargos, Athens 15562, Greece. jktrian@gmail.com

AIMS AND SCOPE

The primary aim of *World Journal of Gastroenterology* (WJG, *World J Gastroenterol*) is to provide scholars and readers from various fields of gastroenterology and hepatology with a platform to publish high-quality basic and clinical research articles and communicate their research findings online. WJG mainly publishes articles reporting research results and findings obtained in the field of gastroenterology and hepatology and covering a wide range of topics including gastroenterology, hepatology, gastrointestinal endoscopy, gastrointestinal surgery, gastrointestinal oncology, and pediatric gastroenterology.

INDEXING/ABSTRACTING

The WJG is now abstracted and indexed in Science Citation Index Expanded (SCIE, also known as SciSearch®), Current Contents/Clinical Medicine, Journal Citation Reports, Index Medicus, MEDLINE, PubMed, PubMed Central, Scopus, Reference Citation Analysis, China National Knowledge Infrastructure, China Science and Technology Journal Database, and Superstar Journals Database. The 2022 edition of Journal Citation Reports® cites the 2021 impact factor (IF) for WJG as 5.374; IF without journal self cites: 5.187; 5-year IF: 5.715; Journal Citation Indicator: 0.84; Ranking: 31 among 93 journals in gastroenterology and hepatology; and Quartile category: Q2. The WJG's CiteScore for 2021 is 8.1 and Scopus CiteScore rank 2021: Gastroenterology is 18/149.

RESPONSIBLE EDITORS FOR THIS ISSUE

Production Editor: Yi-Xuan Cai; Production Department Director: Xiang Li; Editorial Office Director: Jia-Ru Fan.

NAME OF JOURNAL

World Journal of Gastroenterology

ISSN

ISSN 1007-9327 (print) ISSN 2219-2840 (online)

LAUNCH DATE

October 1, 1995

FREQUENCY

Weekly

EDITORS-IN-CHIEF

Andrzej S Tarnawski

EDITORIAL BOARD MEMBERS

<http://www.wjgnet.com/1007-9327/editorialboard.htm>

PUBLICATION DATE

May 21, 2023

COPYRIGHT

© 2023 Baishideng Publishing Group Inc

INSTRUCTIONS TO AUTHORS

<https://www.wjgnet.com/bpg/gerinfo/204>

GUIDELINES FOR ETHICS DOCUMENTS

<https://www.wjgnet.com/bpg/GerInfo/287>

GUIDELINES FOR NON-NATIVE SPEAKERS OF ENGLISH

<https://www.wjgnet.com/bpg/gerinfo/240>

PUBLICATION ETHICS

<https://www.wjgnet.com/bpg/GerInfo/288>

PUBLICATION MISCONDUCT

<https://www.wjgnet.com/bpg/gerinfo/208>

ARTICLE PROCESSING CHARGE

<https://www.wjgnet.com/bpg/gerinfo/242>

STEPS FOR SUBMITTING MANUSCRIPTS

<https://www.wjgnet.com/bpg/GerInfo/239>

ONLINE SUBMISSION

<https://www.f6publishing.com>



Retrospective Study

Where is the optimal plane to mobilize the anterior rectal wall in female patients undergoing total mesorectal excision?

Wei Jin, Jun Yang, Xin-Yu Li, Wei-Cheng Wang, Wen-Jian Meng, You Li, Yi-Chao Liang, Yi-Ming Zhou, Xin-Dong Yang, Yang-Yang Li, Shao-Tang Li

Specialty type: Gastroenterology and hepatology

Provenance and peer review:

Unsolicited article; Externally peer reviewed.

Peer-review model: Single blind

Peer-review report's scientific quality classification

Grade A (Excellent): 0

Grade B (Very good): B, B, B

Grade C (Good): C, C, C

Grade D (Fair): 0

Grade E (Poor): 0

P-Reviewer: Bae SU, South Korea; Brisinda G, Italy; Luglio G, Italy; Martínez-Pérez A, Spain; M'Koma AE, United States; Tonelli F, Italy

Received: February 6, 2023

Peer-review started: February 6, 2023

First decision: March 20, 2023

Revised: April 3, 2023

Accepted: April 20, 2023

Article in press: April 20, 2023

Published online: May 21, 2023



Wei Jin, Jun Yang, Wei-Cheng Wang, Department of Colorectal and Anal Surgery, The First Affiliated Hospital of Wenzhou Medical University, Wenzhou 325000, Zhejiang Province, China

Xin-Yu Li, Department of Gastrointestinal Surgery, The First Hospital of Quanzhou Affiliated to Fujian Medical University, Quanzhou 362002, Fujian Province, China

Wen-Jian Meng, Department of Gastrointestinal Surgery, West China Hospital, Sichuan University, Chengdu 610041, Sichuan Province, China

You Li, Department of General Surgery, Shanghai Jiao Tong University Medical School Affiliated Ruijin, Shanghai 201800, China

Yi-Chao Liang, Department of General Surgery, Shengjing Hospital of China Medical University, Shenyang 111300, Liaoning Province, China

Yi-Ming Zhou, Department of General Surgery, Huashan Hospital Fudan University, Shanghai 201800, China

Xin-Dong Yang, School of Basic Medicine, Wenzhou Medical University, Wenzhou 325000, Zhejiang Province, China

Yang-Yang Li, Department of Pathology, the First Affiliated Hospital of Wenzhou Medical University, Wenzhou 325000, Zhejiang Province, China

Shao-Tang Li, National Key Clinical Specialty (General Surgery), The First Affiliated Hospital of Wenzhou Medical University, Wenzhou 325000, Zhejiang Province, China

Corresponding author: Shao-Tang Li, MD, PhD, Chief Doctor, Doctor, Instructor, Professor, Surgeon, National Key Clinical Specialty (General Surgery), The First Affiliated Hospital of Wenzhou Medical University, Nanbaixiang Street, Ouhai District, Wenzhou 325000, Zhejiang Province, China. lishaotang163@163.com

Abstract

BACKGROUND

Since Heald proposed the total mesorectal excision (TME) procedure, the prognosis of patients with rectal cancer has been significantly improved. But Heald did not specifically describe the anterior surgical plane in female patients.

And the surgical plane for mobilizing the anterior rectal wall during TME surgery in female patients remains controversial.

AIM

To investigate the anatomy of the female pelvis and identify the optimal plane for mobilizing the anterior rectal wall.

METHODS

We retrospectively collected surgical procedure videos and clinical data of female patients diagnosed with middle or low rectal cancer who underwent the TME procedure between January 2020 and October 2022 across six hospitals. The patients were divided into two groups based on the surgical approach used to mobilize the anterior rectal wall: The experimental group was to open the peritoneum at the lowest point of the peritonea reflection and enter the plane for mobilizing, while the control group was cut at 0.5-1 cm above the peritoneal reflection and enter another plan. Then, we compared the preoperative and postoperative information between the two groups. We also dissected and observed ten adult female pelvises to analyze the anatomic structure and compare the entry plane between the two approaches. Finally, we researched the pathological structure between the rectum and the vagina.

RESULTS

Finally, 77 cases that met the criteria were included in our study. Our observations revealed that the experimental group underwent a smooth procedure, entering the plane amidst the mesorectal fascia and adventitia of the vagina, whereas the control group entered the plane between the vaginal adventitia and muscle layers. Compared to the control group, the experimental group showed a significant decrease in intraoperative bleeding [22.5 (19.5-50) mL *vs* 17 (5-20) mL, $P = 0.01$], as well as a shorter duration of hospitalization [9 (7-11.25) d *vs* 7 (6-10) d, $P = 0.03$]. Through the examination of surgical videos and cadaveric studies, we discovered that Denonvilliers' fascia is absent in females. Additionally, pathological sections further revealed the absence of Denonvilliers' fascia in females, with only loose connective tissue present between the mesorectal fascia and adventitia of the vagina.

CONCLUSION

The plane amidst the mesorectal fascia and vaginal adventitia is the optimal surgical plane to mobilize the anterior rectal wall for female patients undergoing the TME procedure.

Key Words: Rectal cancer; Procedure; Female; Rectal surgery specialty; Fascia; Laparoscopic

©The Author(s) 2023. Published by Baishideng Publishing Group Inc. All rights reserved.

Core Tip: In combination with the macroscopic and microscopic perspectives, we discovered that liberating the anterior rectal wall within a certain plane not only guarantees negative perirectal margins but also mitigates the potential for hemorrhage. This plane, situated amidst the mesorectal fascia and vaginal adventitia, proves to be the most advantageous approach for female patients undergoing total mesorectal excision.

Citation: Jin W, Yang J, Li XY, Wang WC, Meng WJ, Li Y, Liang YC, Zhou YM, Yang XD, Li YY, Li ST. Where is the optimal plane to mobilize the anterior rectal wall in female patients undergoing total mesorectal excision? *World J Gastroenterol* 2023; 29(19): 2992-3002

URL: <https://www.wjgnet.com/1007-9327/full/v29/i19/2992.htm>

DOI: <https://dx.doi.org/10.3748/wjg.v29.i19.2992>

INTRODUCTION

In 1982, Heald proposed the total mesorectal excision (TME) procedure[1], which significantly improved the prognosis of patients with rectal cancer[2]. The local recurrence of rectal cancer in 5 years decreased from 25% to 5%, as compared to the traditional operation plus radiotherapy group in the TME operation group[3]. TME soon became a classical operation method and was widely accepted by colorectal surgeons. Heald subsequently described the bloodless planes of TME surgery, known as the "holy plane," as follows: "If we cut straight on to the vesicles we find an essentially bloodless plane between

them and the fascia of Denonvilliers and we can proceed down the enemy to this until it comes forward to become somewhat should come to the state, when we must cut through it to liberate the lower third of the correction enemy”[4].

Professor Heald believes that in male patients, the anterior plane of TME should be anterior to Denonvilliers' fascia, and the anterior aspect of the specimen should include the complete Denonvilliers' fascia and peritoneal folds[3]. However, he did not specifically describe the anterior surgical plane in female patients[1], and the presence of Denonvilliers' fascia in females (rectovaginal septum[5]) remains controversial[6,7]. We also haven't found any research describing the plane of TME for female patients when the front rectal wall performs mobilization till now[8-10]. Many colorectal surgeons struggle to find an ideal plane for mobilizing the anterior rectal wall during TME, which can result in intraoperative bleeding or vaginal damage.

Therefore, we conducted this study to explore the optimal plane to mobilize the anterior rectal wall in female patients. We retrospectively analyzed rectal cancer surgery videos collected from different medical centers and studied the anatomy of the female pelvis for the accurate determination of the optimal plane to mobilize the anterior rectal wall in female patients with rectal cancer.

MATERIALS AND METHODS

Clinical data and video review

We retrospectively collected clinical data and surgical videos from six hospitals between January 2020 and October 2022. The surgeries were performed by experienced colorectal surgeons, each of whom performed more than 100 colorectal cancer operations annually. Our study initially included female patients with middle or low rectal cancer who underwent laparoscopic TME. Patients who had preoperative magnetic resonance imaging assessment indicating invasion of the anterior rectal wall, a history of rectal surgery, absence of surgical videos or relevant clinical data, and the presence of distant metastases were excluded. And they were divided into two groups based on the surgical approaches used. In the experimental group, the peritoneum was incised at the lowest point of peritoneal reflection to access the mobilization plane, while in the control group, the peritoneum was incised 0.5-1 cm above the peritoneal reflection, accessing a different plane. The surgical procedures were reviewed by two experienced colorectal surgeons separately.

The patient's pre- and postoperative data were obtained from medical records, while intraoperative bleeding was measured as the total amount of blood loss recorded in surgical records. Postoperative complications were classified into postoperative bleeding, anastomotic leakage, and other complications (such as pleural effusion, fever, *etc.*). Anastomotic leakage was defined as a communication between the intra- and extraluminal compartments due to a defect in the integrity of the intestinal wall at the anastomosis between the colon and rectum or colon and anus[11], diagnosis through computed tomography (CT) imaging. Pleural effusion was confirmed through CT imaging to establish the diagnosis. Complications were graded by the Clavien-Dindo classification[12].

Cadaver specimens

Ten female cadavers were dissected in the anatomy laboratory of Wenzhou Medical University, which had been donated to the Department of Anatomy following ethical guidelines. The cadavers underwent arterial perfusion with 8% formalin and preservation with 30% alcohol. The corpses were well-preserved, without tissue decay and structural damage. All female cadavers were sourced from young adult females without a history of pelvic diseases. After separating the pelvis from the body, the pelvises were cut in the midsagittal position to expose the rectum and vagina. The pelvises were divided into two to show the rectum and vagina. After clearly exposing the rectal and vaginal structures, a skilled colorectal surgeon and anatomist performed the subsequent operations in accordance with the two different operation procedures of TME, on the same pelvis. At first, the peritoneum was cut at the lowest point of peritoneal reflection and entered the plane to mobilize as the procedure of the experimental group. Then, the surgeon incised the peritoneum at approximately 0.5-1 cm above the peritoneal reflection and started the separation as the procedure of the control group. Photos and records were taken during the dissection.

Pathological histochemistry

A pathologist participated in and supervised the pathological research. We separated the rectovaginal tissue from the other half of the complete pelvis and preserved it in 8% formalin. Then, the remaining tissue was used for pathology and immunohistochemistry analysis. Sections were stained with hematoxylin-eosin and observed under an electron microscope with a magnification of ten times. Microscopic examination of the rectal and vaginal structures enabled us to determine the presence of Denonvilliers' fascia. Immunohistochemical and pathological studies were completed by the Pathology Department of Wenzhou Medical University.

Statistical analysis

IBM SPSS Statistics 25 software was used for the analysis of clinical data, Two-sided $P < 0.05$ indicated significance. Continuous variables with normal distribution were summarized as mean (SD) and two independent samples *t*-test was used for the statistics. For continuous variables with non-normal distribution were summarized as median (IQR) and Mann-Whitney U test were used for the statistics. Categorical variables were summarized as numbers (percentages) and analyzed using the chi-square test, while the Mann-Whitney U test was used for the Statistics of ordered classification variables. The statistical review of this study was performed by a biomedical statistician.

RESULTS

Video review and clinical data

Seventy-seven patients who met the criteria were included in our study, with 35 in the experimental group and 42 in the control group. There were no significant differences in the general information between the two groups. The patients' general information is summarized in [Table 1](#).

In the experimental group, the peritoneum was cut at the lowest point of the peritoneal reflection to enter the anterior rectal space (as shown in [Figure 1](#)), in which the anterior rectal wall can be easily dissociated from the posterior wall of the vagina. The rectum was light yellow due to the light-yellow adipose tissue surrounded by the mesorectal fascia. Blood vessels could be seen in the mesorectum, and the mesorectum was dissected completely. It can be dissociated through blunt separation combined with sharp separation. In this process, the operation field could remain bloodless, and the vaginal structure and rectal structure were easy to distinguish from each other. The mesorectal fascia and vaginal were complete after dissection, and no Denonvilliers' fascia-like structure was present between them. In contrast, the control group cut the peritoneum at approximately 0.5–1 cm above the peritoneal reflection and freed the rectal wall between the vaginal muscular and the vaginal adventitia (as shown in [Figure 2](#)). Although a structure similar to Denonvilliers' fascia was found, it was closely connected to the vaginal muscular and could only be torn off through sharp separation. The muscular structure of the vagina was revealed after the operation, which often caused bleeding. Furthermore, the vaginal structure was no longer intact after dissection since the vaginal adventitia was separated from the muscular layer. After reviewing all the surgical procedures, finding an obvious membrane structure between the mesorectal fascia and vaginal adventitia in females was difficult. The fascial structure that we found during the operation was the vaginal adventitia, while the so-called female Denonvilliers' fascia does not exist.

Compared with the control group, the experimental group had less intraoperative bleeding [22.5 (19.5–50) mL *vs* 17 (5–20) mL; $P = 0.01$], and shorter length of hospitalization [9 (7–11.25) d *vs* 7 (6–10) d; $P = 0.03$]. Although the incidence of postoperative complications was lower than that of the control group, the results were not statistically significant. No deaths occurred in either group in the first 30 d after surgery. All Pathological specimens' Circumferential Resection Margins (CRM) were negative after the operation. Statistical result is summarized in [Table 2](#).

Gross anatomy

As depicted in [Figure 3A](#), the layers of the rectum and vagina were displayed, and the main structures could be distinguished. The vaginal muscular layer was brown, and the mucosal layer was gray. The mucosa of the rectum was yellowish, the submucosa was white, and the muscular layer was brown. However, distinguishing between the vaginal adventitia and the mesorectal fascia with the naked eye was difficult.

The dissociation process of the experimental group proceeded seamlessly. As depicted in [Figure 3B](#), the mobilization plane traversed the interface between the vaginal adventitia and the fascia of the mesorectum. A discernible space between the vaginal adventitia and the mesorectal fascia was observed, which could be adroitly separated through blunt dissection. The vaginal adventitia and the mesorectal fascia were generally white without fascia-like tissues or blood vessels between them. Occasionally, blood vessels were visible beneath the vaginal adventitia. The boundary between the muscular layer and the adventitia was clear, with the muscular layer appearing dark and the adventitia appearing white.

As shown in [Figure 3C](#), the mobilization plane entered the plane between the vaginal adventitia and the muscular layer by the procedure of the control group. When the vaginal adventitia was separated from the muscular layer, we found that the attachment between the vaginal adventitia and the muscular layer was stronger than the attachment between the vaginal adventitia and the mesorectal fascia, which could not be easily mobilized by blunt separation and can only be mobilized by sharp separation. After dissociation, the vaginal adventitia could be seen to be a single-layer fascia-like structure with a white color that was different and easy to distinguish from the dark muscle layer. No distinct or separate Denonvilliers' fascia was identified. At the same time, after the vaginal adventitia was forcibly torn off from the muscular layer, the muscular layer structure was damaged. Some residual muscle fiber tissue could be seen on the vaginal adventitia.

Table 1 General information of the patient

	Control group (n = 42)	Experimental group (n = 35)	P value
Height, mean (SD), cm	157.64 (6.03)	157.17 (5.29)	0.72
Weight, mean (SD), kg	57.02 (8.82)	57.37 (10.22)	0.87
BSA, mean (SD)	1.62 (0.14)	1.67 (0.15)	0.17
Age, mean (SD), y	60.50 (10.94)	63.86 (12.77)	0.22
Preoperative chemoradiotherapy	6 (14.3)	4 (11.4)	0.98

BSA: Body surface area.

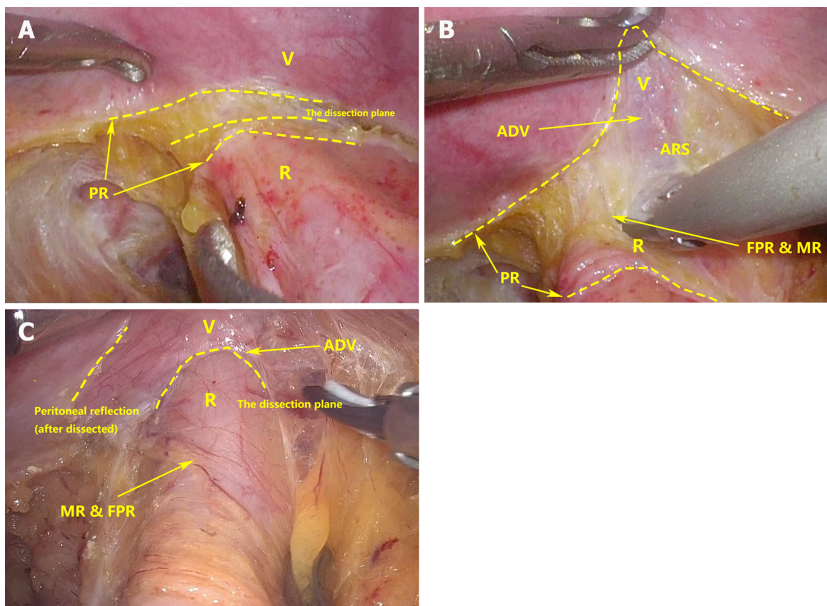
Table 2 Postoperative information of the patient

	Control group (n = 42)	Experimental group (n = 35)	P value
Operation time, mean (SD), min	233.14 (75.12)	228.66 (80.32)	0.8
IB, median (IQR), mL	22.5 (19.5-50)	17 (5-20)	0.01
NRL, median (IQR)	13.5 (10-16.5)	15 (13-19)	0.24
Hospital stays, median (IQR), days	9 (7-11.25)	7 (6-10)	0.03
Pathology stage			0.52
I	21 (50.0)	15 (42.8)	0.62
II	10 (23.8)	9 (25.7)	
III	11 (26.2)	11 (31.5)	
T			
1	12 (28.6)	8 (22.9)	
2	12 (28.6)	12 (34.3)	0.75
3	15 (35.7)	10 (28.6)	
4	3 (7.1)	5 (14.3)	
N			
0	32 (76.2)	24 (68.6)	
1	8 (19.0)	9 (25.7)	0.84
2	2 (4.8)	2 (5.7)	
CDC			
I	8 (19.0)	3 (8.6)	
II	2 (4.8)	1 (2.9)	
Postoperative complications	10 (23.81)	4 (11.43)	0.16
Postoperative bleeding	1	0	
Anastomotic leakage	3	2	
Other complications	8	4	

CDC: Clavien-Dindo classification; IB: Intraoperative bleeding; IQR: Inter-quartile range; NRL: Number of retrieved lymph nodes.

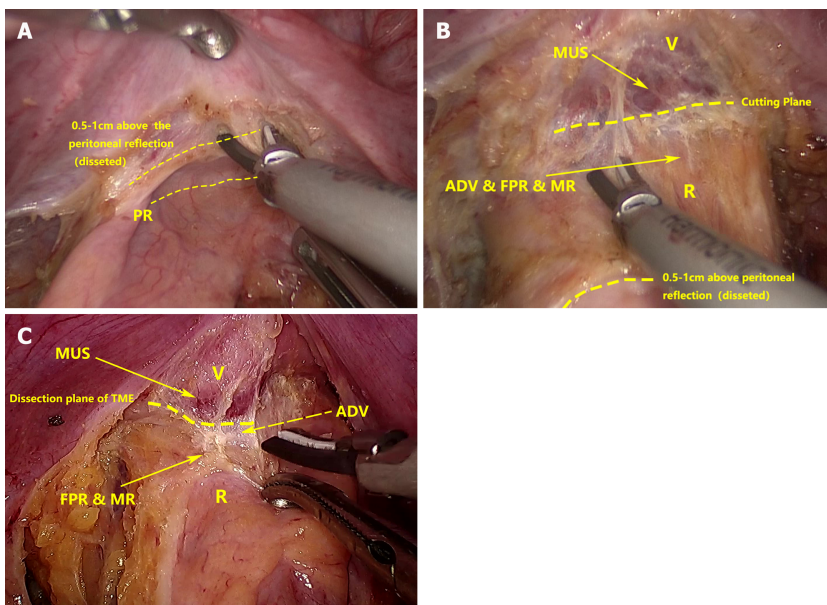
Pathological histochemistry

As shown in [Figure 4](#), the rectal and vaginal tissues showed clear stratification: The rectum was divided into the mucosa, submucosa, inner ring muscle layer, outer longitudinal muscle layer, mesorectum, and the mesorectal fascia surrounding the mesorectum. The vaginal wall was divided into three layers: Mucosa, muscular, and adventitia layers. The adventitia layer was composed of dense connective tissue with scattered loose connective tissue among it. A gap was present between the mesorectal fascia and the vaginal adventitia. Numerous loose connective tissue, but no obvious fascia-like structures, were



DOI: 10.3748/wjg.v29.i19.2992 Copyright ©The Author(s) 2023.


Figure 1 The procedure of the experimental group. A: The peritoneum was cut at the lowest point of the peritoneal reflection to enter the anterior rectal space; B: After the incision of the peritoneal reflection, a space can be seen, in which can we easily free the anterior rectal wall. This space is considered the rectovaginal space; C: No other fascial structure was present between the fascia propria of the rectum and the adventitia of the vagina, and these two fascial structures could be pushed away from each other by an ultrasonic knife through blunt separation. ADV: Adventitia of the vagina; FPR: Fascia propria of the rectum; MR: Mesorectum; PR: Peritoneal reflection; R: Rectum; V: Vagina; ARS: Anterior rectal space.



DOI: 10.3748/wjg.v29.i19.2992 Copyright ©The Author(s) 2023.

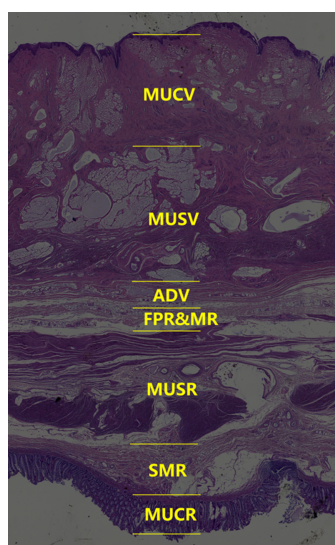
Figure 2 The procedure of the control group. A: The peritoneum was cut 0.5-1 cm above the peritoneal reflection. The peritoneal reflection was slightly white, and its texture was different from the texture of other structures during the operation; B: The cutting plane was between the vaginal muscle layer and the adventitia. The vaginal adventitia was closely adherent to the muscle layer; C: Bleeding occurred after stripping the vaginal adventitia from the muscle, and hemostasis was performed. ADV: Adventitia of the vagina; FPR: Fascia propria of the rectum; MR: Mesorectum; MUS: Muscle; PR: Peritoneal reflection; R: Rectum; V: Vagina.

present inside this gap. Occasionally, some scattered dense connective tissue and fragment-like fascial structure could be seen but were difficult to identify as fascial structures.



DOI: 10.3748/wjg.v29.i19.2992 Copyright ©The Author(s) 2023.

Figure 3 Gross anatomy. A: Observation of the female pelvis; B: The procedure of the experimental group; C: The procedure of the control group. Black arrow: Adventitia of the vagina; white arrow: Fascia propria of the rectum. ARS: Anterior rectal space; MR: Mesorectum; MUC: Mucosa; MUS: Muscle; PR: Peritoneal reflection; R: Rectum; SMUC: Submucosa; V: Vagina; FPR: Fascia propria of the rectum; MR: Mesorectum.



DOI: 10.3748/wjg.v29.i19.2992 Copyright ©The Author(s) 2023.

Figure 4 Pathological section of the rectovaginal structure. Pathological section showing the absence of an obvious fascia-like structure between the fascia propria of the rectum and the adventitia of the vagina. ADV: Adventitia of the vagina; FPR & MR: Fascia propria of the rectum and mesorectum; MUCV: Mucosa of the vagina; MUSR: Muscle of the rectum; MUSV: Muscle of the vagina; SMR: Submucosa of the rectum; MUCR: Mucosa of the rectum.

DISCUSSION

In 1836, after observing the anatomy of the male pelvis, Denonvillier found a single-layer membrane-like structure between the rectum and prostate that he called the “prostatoperitoneal membrane”[13]. Later, in memory of Denonvillier, people called this fascial structure Denonvilliers’ fascia, which is considered a structure that starts from the peritoneal reflection and ends at the perineum. The prostate and seminal vesicle glands are located in front of this structure. The rectum locates behind it, and vascular and nerve bundles are located on both sides of this structure. Undoubtedly, colorectal doctors have reached a consensus on the existence of Denonvilliers’ fascia in the male pelvis. However, whether this fascia exists in females remains highly debated. Denonvillier elaborated on this structure by dissecting the male pelvis but did not mention its relevance in females. Later researchers also encountered many contradictions and disputes regarding the description of this structure.

In 1969, after dissecting 143 bodies, Milley and Nichols[14] confirmed the presence of a rectovaginal septum. They found a rectovaginal septum in 23 of 25 adult females and all dissected female infants. Despite the individual differences, the existence of this structure appears to be unaffected by age and hormones. At the same time, a close adhesion existed between this diaphragm and the fascia surrounding the vagina, they believed that this close adhesion may be a major reason why some anatomists deny the existence of the vaginal rectal septum[14].

Zhai *et al*[5] proved the existence of the female rectovaginal septum by studying the whole pelvic viscera embedded in celloidin (25 female pelvic visceral organs). He pointed out that the rectovaginal septum could be divided into two layers: Denonvilliers' fascia and the mesorectal fascia from the traditional point of view. Denonvilliers' fascia tightly surrounds the posterior and lateral walls of the vagina, and the Denonvilliers' fascia and the mesorectal fascia are not attached to the rectouterine pouch. Instead, they extend upward along the peritoneum. In this anatomy, the anterior layer integrates into the uterus, and the posterior layer gradually thins and disappears. The rectovaginal septum plays an important role in preventing the spread of malignant tumors[5].

Bertrand *et al*[6] found that Denonvilliers' fascia is an independent structure of the mesorectal fascia and the cervix as well as the vagina by studying female fetuses' anatomy[6]. However, they were likely to mistake the vaginal adventitia for Denonvilliers' fascia (rectovaginal septum). In our study on adult females, we only found loose connective tissue in the plane between the mesorectal fascia and the adventitia of the vagina. No other fascia-like structures were found between these structures. Due to the absence of other structures in this plane, we were able to easily separate the rectum and vagina without causing damage to the vaginal structure during the complete removal of the mesorectum. And the vaginal adventitia seems like Denonvilliers' fascia if it was separated from the vaginal muscle. Recognizing the adventitia of the vagina as Denonvilliers' fascia and forcefully separating it from the muscular layer could often cause bleeding.

At the same time, some people proposed the opposite opinion. Zhang *et al*[15] found only some membrane-like fascial fragments in the adipose tissue between the rectum and the vagina in the frozen sections of the corpses of three adult females aged 58–86 years old. They believed that previous studies may have regarded these fascial fragments as Denonvilliers' fascia; however, considering the age limit of their samples, their results still need further research[15]. An analysis of surgical and pathological samples from three females showed that the so-called fascia and vaginal wall had the same histological manifestations under pathology and were not distinguishable[16]. Therefore, Farrell *et al*[16] believed that the so-called fascia was an artificial surgical separation from the vagina that occurred when separating the vagina and surrounding organs[16]. In 2005, through the analysis of four female anatomical samples, Kleeman *et al*[17] also obtained a similar conclusion, that is, no fascia exists between the rectum and vagina. The rectovaginal septum used to repair the rectocele is an artificial surgical separation of tears from the vagina[17]. Meanwhile, after dissecting twenty-five female cadavers, García-Gausi *et al*[7] came to the same conclusion as Farrell *et al*[16]: That an independent rectovaginal septum could only be produced by tearing the vaginal adventitia. They found only a layer of loose connective tissue between the vagina and the rectum[7]. This is consistent with the findings of our study.

Based on the anatomy of four cadavers, Fang proposed that for surgery in early rectal cancer, mobilizing the rectum behind Denonvilliers' fascia can not only ensure the integrity of the mesorectum but also control related postoperative complications[18]. Although his viewpoint on whether Denonvilliers' fascia exists in females is different from ours, his conclusion on the female surgical approach is similar to ours. Simultaneously, some researchers have discovered that in the case of early rectal cancer, mobilizing the rectal wall behind Denonvilliers' fascia results in similar 5-year local recurrence rates as the traditional TME approach, while also reducing the incidence of complications [19]. Nevertheless, we believe that these researchers may have misidentified the vaginal adventitia as Denonvilliers' fascia in female patients.

We found that in females, the plane between the vaginal adventitia and the mesorectal fascia is suitable for rectal cancer surgery. By dissecting the rectum along the plane between the mesorectal fascia and the vaginal adventitia, not only can the risk of bleeding and damage to physiological structures be minimized, resulting in a faster recovery and shorter hospitalization, but it can also guarantee complete removal of the mesorectum and negative CRM status. Thus, this plane is the optimal plane in female patients with rectal cancer undergoing TME. Our research focused on the macro- and microlevels, combined with clinical data to explore the anatomy of the rectum and the vagina from multiple angles to obtain a highly scientific conclusion. Not only did we provide stronger evidence supporting the absence of Denonvilliers' fascia as an independent structure in females, but we also discovered that the anterior rectal space is the optimal plane to mobilize the anterior rectal wall for female patients undergoing TME.

However, as this study was retrospective and had a limited sample size, the observed differences in complication rates between the two procedures were not statistically significant. Future studies with larger sample sizes may yield more conclusive results. Additionally, due to the relatively short follow-up period since the patients' surgeries, long-term prognostic and sexual function outcomes have not been thoroughly investigated. Nonetheless, we intend to address this limitation in our subsequent studies.

CONCLUSION

In adult females, Denonvilliers' fascia is absent, we could only find loose connective tissue between the mesorectal fascia and vaginal adventitia. The vaginal adventitia is tightly adherent to the vaginal muscular layer and was difficult to separate from the muscle layer. By incising the peritoneum at the lowest point of peritoneal reflection, a plane between the mesorectal fascia and vaginal adventitia can be accessed. Mobilizing the anterior rectal wall in this plane could not only ensure the integrity of the mesorectum but also reduces intraoperative bleeding and hospital stay. Dissecting in this plane follows a natural avascular space without damaging the vaginal structure and simplifies the surgical procedure. Therefore, this is the optimal plane for mobilizing the anterior rectal wall for female patients undergoing TME procedures.

ARTICLE HIGHLIGHTS

Research background

Currently, there are no comprehensive descriptions available regarding the approach for dissecting the anterior wall of the female rectum. Many surgeons encounter intraoperative bleeding due to the lack of an appropriate dissection plane.

Research motivation

The surgical approach for mobilizing the anterior rectal wall during total mesorectal excision surgery in female patients remains controversial. However, with a more profound comprehension of the pelvic anatomy, we can identify the avascular plane, reducing intraoperative bleeding and preventing harm to physiological structures.

Research objectives

We aim to gain a better understanding of the female pelvic anatomy to identify an optimal approach for dissecting the anterior wall of the rectum. This will facilitate improved surgical outcomes for female patients with middle or low rectal cancer.

Research methods

Firstly, we retrospectively grouped patients based on different approaches after reviewing surgical videos. Clinical information was collected and pre-and post-operative data were compared, along with reviewing surgical videos to understand the anatomy and intraoperative situation. Subsequently, the female pelvic structure was studied through cadaveric dissection and histological sections.

Research results

We discovered that opening the peritoneum at the lowest point of peritoneal reflection allows access to the plane between the vaginal adventitia and mesorectal fascia. Opening the peritoneum 0.5-1 cm above the peritoneal reflection enters another plane located between the vaginal adventitia and vaginal muscle layer. The first approach has lower intraoperative bleeding and shorter hospital stay compared to the second approach. Neither cadaveric dissection nor pathological examination revealed the existence of Denonvilliers' fascia. Only loose connective tissue exists between the rectosacral fascia and the vaginal adventitia.

Research conclusions

Denonvilliers' fascia is absent in females. The plane amidst the mesorectal fascia and vaginal adventitia is the optimal surgical plane to mobilize the anterior rectal wall for female patients.

Research perspectives

In future studies, we will explore the long-term prognosis of the two approaches for women, as well as the impact on postoperative sexual and vaginal function.

ACKNOWLEDGEMENTS

Thanks to Xin-Yu Li, Yang-Yang Li, and Xin-Dong Yang's great contributions to our work.

FOOTNOTES

Author contributions: Li ST contributed to the study conceptualization and completed the dissection of cadavers; Li XY, Li Y, Liang YC, Zhou YM and Li ST provide clinical data; Li XY and Li Y reviewed the surgical videos; Jin W wrote the original draft of the manuscript and made the figures; Wang WC and Jin W finished the analysis of the data; Li XY, Zhou YM, and Yang J directly accessed and verified the underlying data; Li YY finished the pathological research; Yang XD finished the biostatistics jobs; All authors critically revised and approved the final manuscript.

Supported by Huadong Medicine Joint Funds of the Zhejiang Provincial Natural Science Foundation of China, No. LHDMY22H160002.

Institutional review board statement: The study was reviewed and approved by the Ethics Committee in Clinical Research of the First Affiliated Hospital of Wenzhou Medical University Institutional Review Board, No. KY2022-R088.

Informed consent statement: All study participants, or their legal guardian, provided informed written consent prior to study enrollment.

Conflict-of-interest statement: All the authors report no relevant conflicts of interest for this article.

Data sharing statement: Technical appendix, statistical code, and dataset available from the corresponding author at lishaotang163@163.com.

Open-Access: This article is an open-access article that was selected by an in-house editor and fully peer-reviewed by external reviewers. It is distributed in accordance with the Creative Commons Attribution NonCommercial (CC BY-NC 4.0) license, which permits others to distribute, remix, adapt, build upon this work non-commercially, and license their derivative works on different terms, provided the original work is properly cited and the use is non-commercial. See: <https://creativecommons.org/licenses/by-nc/4.0/>

Country/Territory of origin: China

ORCID number: Wei Jin 0009-0001-0925-6016; Wen-Jian Meng 0000-0002-4578-0560; You Li 0000-0002-9560-9702; Shao-Tang Li 0000-0002-5385-2472.

S-Editor: Li L

L-Editor: A

P-Editor: Cai YX

REFERENCES

- Heald RJ, Husband EM, Ryall RD. The mesorectum in rectal cancer surgery--the clue to pelvic recurrence? *Br J Surg* 1982; **69**: 613-616 [PMID: 6751457 DOI: 10.1002/bjs.1800691019]
- Heald RJ, Ryall RD. Recurrence and survival after total mesorectal excision for rectal cancer. *Lancet* 1986; **1**: 1479-1482 [PMID: 2425199 DOI: 10.1016/s0140-6736(86)91510-2]
- MacFarlane JK, Ryall RD, Heald RJ. Mesorectal excision for rectal cancer. *Lancet* 1993; **341**: 457-460 [PMID: 8094488 DOI: 10.1016/0140-6736(93)90207-w]
- Heald RJ. The 'Holy Plane' of rectal surgery. *J R Soc Med* 1988; **81**: 503-508 [PMID: 3184105 DOI: 10.1177/014107688808100904]
- Zhai LD, Liu J, Li YS, Yuan W, He L. Denonvilliers' fascia in women and its relationship with the fascia propria of the rectum examined by successive slices of colloidal-embedded pelvic viscera. *Dis Colon Rectum* 2009; **52**: 1564-1571 [PMID: 19690483 DOI: 10.1007/DCR.0b013e3181a8f75c]
- Bertrand MM, Alsaid B, Droupy S, Benoit G, Prudhomme M. Biomechanical origin of the Denonvilliers' fascia. *Surg Radiol Anat* 2014; **36**: 71-78 [PMID: 23732391 DOI: 10.1007/s00276-013-1142-0]
- García-Gausí M, García-Armengol J, Mulas Fernández C, Pellino G, Roig JV, García-Granero A, Pla-Martí V, Martínez-Soriano F. Surgical Anatomy of the Rectovaginal Space: Does a Standalone Rectovaginal Septum or Denonvilliers Fascia Exist in Women? *Dis Colon Rectum* 2021; **64**: 576-582 [PMID: 33939388 DOI: 10.1097/DCR.0000000000001912]
- Stevenson AR, Solomon MJ, Lumley JW, Hewett P, Clouston AD, Gebbski VJ, Davies L, Wilson K, Hague W, Simes J; ALaCaRT Investigators. Effect of Laparoscopic-Assisted Resection vs Open Resection on Pathological Outcomes in Rectal Cancer: The ALaCaRT Randomized Clinical Trial. *JAMA* 2015; **314**: 1356-1363 [PMID: 26441180 DOI: 10.1001/jama.2015.12009]
- Fleshman J, Branda ME, Sargent DJ, Boller AM, George VV, Abbas MA, Peters WR Jr, Maun DC, Chang GJ, Herline A, Fichera A, Mutch MG, Wexner SD, Whiteford MH, Marks J, Birnbaum E, Margolin DA, Larson DW, Marcello PW, Posner MC, Read TE, Monson JRT, Wren SM, Pisters PWT, Nelson H. Disease-free Survival and Local Recurrence for Laparoscopic Resection Compared With Open Resection of Stage II to III Rectal Cancer: Follow-up Results of the ACOSOG Z6051 Randomized Controlled Trial. *Ann Surg* 2019; **269**: 589-595 [PMID: 30080730 DOI: 10.1097/SLA.0000000000003002]

- 10 **Fleshman J**, Branda M, Sargent DJ, Boller AM, George V, Abbas M, Peters WR Jr, Maun D, Chang G, Herline A, Fichera A, Mutch M, Wexner S, Whiteford M, Marks J, Birnbaum E, Margolin D, Larson D, Marcello P, Posner M, Read T, Monson J, Wren SM, Pisters PW, Nelson H. Effect of Laparoscopic-Assisted Resection vs Open Resection of Stage II or III Rectal Cancer on Pathologic Outcomes: The ACOSOG Z6051 Randomized Clinical Trial. *JAMA* 2015; **314**: 1346-1355 [PMID: [26441179](#) DOI: [10.1001/jama.2015.10529](#)]
- 11 **Rahbari NN**, Weitz J, Hohenberger W, Heald RJ, Moran B, Ulrich A, Holm T, Wong WD, Tiet E, Moriya Y, Laurberg S, den Dulk M, van de Velde C, Büchler MW. Definition and grading of anastomotic leakage following anterior resection of the rectum: a proposal by the International Study Group of Rectal Cancer. *Surgery* 2010; **147**: 339-351 [PMID: [20004450](#) DOI: [10.1016/j.surg.2009.10.012](#)]
- 12 **Dindo D**, Demartines N, Clavien PA. Classification of surgical complications: a new proposal with evaluation in a cohort of 6336 patients and results of a survey. *Ann Surg* 2004; **240**: 205-213 [PMID: [15273542](#) DOI: [10.1097/01.sla.0000133083.54934.ae](#)]
- 13 **Denonvilliers C**. Anatomie du perinee. *Bull Soc Anat Paris* 1836; **10**: 105-107
- 14 **Milley PS**, Nichols DH. A correlative investigation of the human rectovaginal septum. *Anat Rec* 1969; **163**: 443-451 [PMID: [5774728](#) DOI: [10.1002/ar.1091630307](#)]
- 15 **Zhang M**, Kaw A, Chapuis PH, Bokey L. Does Denonvilliers' fascia exist in women? *Am J Obstet Gynecol* 2016; **214**: 663-664 [PMID: [26767795](#) DOI: [10.1016/j.ajog.2015.12.057](#)]
- 16 **Farrell SA**, Dempsey T, Geldenhuys L. Histologic examination of "fascia" used in colporrhaphy. *Obstet Gynecol* 2001; **98**: 794-798 [PMID: [11704171](#) DOI: [10.1016/s0029-7844\(01\)01533-2](#)]
- 17 **Kleeman SD**, Westermann C, Karam MM. Rectoceles and the anatomy of the posteriorvaginal wall: revisited. *Am J Obstet Gynecol* 2005; **193**: 2050-2055 [PMID: [16325614](#) DOI: [10.1016/j.ajog.2005.07.096](#)]
- 18 **Fang J**, Zheng Z, Wei H. Reconsideration of the Anterior Surgical Plane of Total Mesorectal Excision for Rectal Cancer. *Dis Colon Rectum* 2019; **62**: 639-641 [PMID: [30964796](#) DOI: [10.1097/DCR.0000000000001358](#)]
- 19 **Killingback M**, Barron P, Dent OF. Local recurrence after curative resection of cancer of the rectum without total mesorectal excision. *Dis Colon Rectum* 2001; **44**: 473-83; discussion 483 [PMID: [11330574](#) DOI: [10.1007/BF02234317](#)]



Published by **Baishideng Publishing Group Inc**
7041 Koll Center Parkway, Suite 160, Pleasanton, CA 94566, USA

Telephone: +1-925-3991568

E-mail: bpgoffice@wjgnet.com

Help Desk: <https://www.f6publishing.com/helpdesk>

<https://www.wjgnet.com>

