

World Journal of *Clinical Cases*

World J Clin Cases 2023 June 6; 11(16): 3664-3931



Contents

Thrice Monthly Volume 11 Number 16 June 6, 2023

REVIEW

- 3664 Kikuchi-Fujimoto disease: A comprehensive review
Mahajan VK, Sharma V, Sharma N, Rani R
- 3680 Current diagnostic tools and treatment modalities for rectal prolapse
Oruc M, Erol T

MINIREVIEWS

- 3694 Application of laparoscopic surgery in gallbladder carcinoma
Wu X, Li BL, Zheng CJ
- 3706 Current research of idiopathic normal pressure hydrocephalus: Pathogenesis, diagnosis and treatment
Ishida T, Murayama T, Kobayashi S
- 3714 *Helicobacter pylori* plays a key role in gastric adenocarcinoma induced by spasmolytic polypeptide-expressing metaplasia
Li ML, Hong XX, Zhang WJ, Liang YZ, Cai TT, Xu YF, Pan HF, Kang JY, Guo SJ, Li HW
- 3725 Review of deep learning and artificial intelligence models in fetal brain magnetic resonance imaging
Vahedifard F, Adepoju JO, Supanich M, Ai HA, Liu X, Kocak M, Marathu KK, Byrd SE
- 3736 Diabetes more than retinopathy, it's effect on the anterior segment of eye
Morya AK, Ramesh PV, Kaur K, Gurnani B, Heda A, Bhatia K, Sinha A

ORIGINAL ARTICLE

Retrospective Cohort Study

- 3750 Long term outcomes of Cohen's cross trigonal reimplantation for primary vesicoureteral reflux in poorly functioning kidney
Ansari MS, Banthia R, Jain S, Kaushik VN, Danish N, Yadav P

Retrospective Study

- 3756 Dexmedetomidine-induced anesthesia in elderly patients undergoing hip replacement surgery
Li JQ, Yuan H, Wang XQ, Yang M

Observational Study

- 3765 Hypoperfusion context as a predictor of 28-d all-cause mortality in septic shock patients: A comparative observational study
Kataria S, Singh O, Juneja D, Goel A, Bhide M, Yadav D

- 3780** Psychological review of hemodialysis patients and kidney transplant recipients during the COVID-19 pandemic

Gundogmus AG, Oguz EG, Guler-Cimen S, Kocyigit Y, Dogan AE, Ayli MD

- 3791** Incidence and peri-operative risk factors for development of acute kidney injury in patients after cardiac surgery: A prospective observational study

Dimopoulos S, Zagkotsis G, Kinti C, Rouvali N, Georgopoulou M, Mavraki M, Tasouli A, Lyberopoulou E, Roussakis A, Vasileiadis I, Nanas S, Karabinis A

Randomized Controlled Trial

- 3802** Coaxial radiography guided puncture technique for percutaneous transforaminal endoscopic lumbar discectomy: A randomized control trial

Chen LP, Wen BS, Xu H, Lu Z, Yan LJ, Deng H, Fu HB, Yuan HJ, Hu PP

CASE REPORT

- 3813** Blood typing and transfusion therapy in a patient with A2 subtype acute myeloid leukemia M2: A case report

Kuang XC, Zhang SH, Cen YJ, Zhang JB, Liu YS

- 3822** Valve repair after infective endocarditis secondary to perforation caused by *Streptococcus gordonii*: A case report

Qu YF, Yang J, Wang JY, Wei B, Ye XH, Li YX, Han SL

- 3830** *Prevotella oris*-caused meningitis and spinal canal infection: A case report

Zhang WW, Ai C, Mao CT, Liu DK, Guo Y

- 3837** Severe liver trauma with complex portal and common bile duct avulsion: A case report and review of the literature

Mitricof B, Kraft A, Anton F, Barcu A, Barzan D, Haiducu C, Brasoveanu V, Popescu I, Moldovan CA, Botea F

- 3847** TACC diagnosed by transoesophageal endoscopic ultrasonography: A case report

Pu XX, Xu QW, Liu BY

- 3852** Ruptured teratoma mimicking a pelvic inflammatory disease and ovarian malignancy: A case report

Lai PH, Ding DC

- 3858** Purpura annularis telangiectodes of Majocchi: A case report

Pu YJ, Jiang HJ, Zhang L

- 3864** Giant cyst in heterotopic pregnancy: A case report

Kong YY, Chanda K, Ying XY

- 3870** High doses of dextromethorphan induced shock and convulsions in a 19-year-old female: A case report

Shimozawa S, Usuda D, Sasaki T, Tsuge S, Sakurai R, Kawai K, Matsubara S, Tanaka R, Suzuki M, Hotchi Y, Tokunaga S, Osugi I, Katou R, Ito S, Asako S, Mishima K, Kondo A, Mizuno K, Takami H, Komatsu T, Oba J, Nomura T, Sugita M

- 3877** Postpartum ovarian vein thrombosis after cesarean section and vaginal delivery: Two case reports

Zhu HD, Shen W, Wu HL, Sang X, Chen Y, Geng LS, Zhou T

- 3885** Traumatic pancreatic ductal injury treated by endoscopic stenting in a 9-year-old boy: A case report
Kwon HJ, Jung MK, Park J
- 3891** Novel mutation c.2090_2091del in neurodevelopmental-craniofacial syndrome with variable renal and cardiac abnormalities in an 18.5-mo-old boy: A case report
Li Y, Zhou Z, Xu Y, Wang ZR
- 3899** Reading impairment after neonatal hypoglycemia with parieto-temporo-occipital injury without cortical blindness: A case report
Kurahashi N, Ogaya S, Maki Y, Nonobe N, Kumai S, Hosokawa Y, Ogawa C, Yamada K, Maruyama K, Miura K, Nakamura M
- 3907** Unusual clinical presentation of oral pyogenic granuloma with severe alveolar bone loss: A case report and review of literature
Lomeli Martínez SM, Bocanegra Morando D, Mercado González AE, Gómez Sandoval JR
- 3915** Intraoperative photodynamic therapy for tracheal mass in non-small cell lung cancer: A case report
Jung HS, Kim HJ, Kim KW
- 3921** Coexistence of urinary tuberculosis and urothelial carcinoma: A case report
Tsai YC, Li CC, Chen BT, Wang CY

LETTER TO THE EDITOR

- 3929** Symmetric DWI hyperintensities in CMT1X patients after SARS-CoV-2 vaccination should not be classified as stroke-like lesions
Finsterer J

ABOUT COVER

Editorial Board Member of *World Journal of Clinical Cases*, Ashraf F Hefny, MD, MSc, Associate Professor, Surgeon, Department of Surgery, College of Medicine and Health Sciences, UAE University, Al Ain 00000, United Arab Emirates. ahefny@uaeu.ac.ae

AIMS AND SCOPE

The primary aim of *World Journal of Clinical Cases* (WJCC, *World J Clin Cases*) is to provide scholars and readers from various fields of clinical medicine with a platform to publish high-quality clinical research articles and communicate their research findings online.

WJCC mainly publishes articles reporting research results and findings obtained in the field of clinical medicine and covering a wide range of topics, including case control studies, retrospective cohort studies, retrospective studies, clinical trials studies, observational studies, prospective studies, randomized controlled trials, randomized clinical trials, systematic reviews, meta-analysis, and case reports.

INDEXING/ABSTRACTING

The WJCC is now abstracted and indexed in Science Citation Index Expanded (SCIE, also known as SciSearch®), Journal Citation Reports/Science Edition, Current Contents®/Clinical Medicine, PubMed, PubMed Central, Scopus, Reference Citation Analysis, China National Knowledge Infrastructure, China Science and Technology Journal Database, and Superstar Journals Database. The 2022 Edition of Journal Citation Reports® cites the 2021 impact factor (IF) for WJCC as 1.534; IF without journal self cites: 1.491; 5-year IF: 1.599; Journal Citation Indicator: 0.28; Ranking: 135 among 172 journals in medicine, general and internal; and Quartile category: Q4. The WJCC's CiteScore for 2021 is 1.2 and Scopus CiteScore rank 2021: General Medicine is 443/826.

RESPONSIBLE EDITORS FOR THIS ISSUE

Production Editor: Si Zhao; Production Department Director: Xu Guo; Editorial Office Director: Jin-Lei Wang.

NAME OF JOURNAL

World Journal of Clinical Cases

ISSN

ISSN 2307-8960 (online)

LAUNCH DATE

April 16, 2013

FREQUENCY

Thrice Monthly

EDITORS-IN-CHIEF

Bao-Gan Peng, Jerzy Tadeusz Chudek, George Kontogeorgos, Maurizio Serati, Ja Hyeon Ku

EDITORIAL BOARD MEMBERS

<https://www.wjgnet.com/2307-8960/editorialboard.htm>

PUBLICATION DATE

June 6, 2023

COPYRIGHT

© 2023 Baishideng Publishing Group Inc

INSTRUCTIONS TO AUTHORS

<https://www.wjgnet.com/bpg/gerinfo/204>

GUIDELINES FOR ETHICS DOCUMENTS

<https://www.wjgnet.com/bpg/GerInfo/287>

GUIDELINES FOR NON-NATIVE SPEAKERS OF ENGLISH

<https://www.wjgnet.com/bpg/gerinfo/240>

PUBLICATION ETHICS

<https://www.wjgnet.com/bpg/GerInfo/288>

PUBLICATION MISCONDUCT

<https://www.wjgnet.com/bpg/gerinfo/208>

ARTICLE PROCESSING CHARGE

<https://www.wjgnet.com/bpg/gerinfo/242>

STEPS FOR SUBMITTING MANUSCRIPTS

<https://www.wjgnet.com/bpg/GerInfo/239>

ONLINE SUBMISSION

<https://www.f6publishing.com>



TACC diagnosed by transoesophageal endoscopic ultrasonography: A case report

Xiao-Xin Pu, Qin-Wei Xu, Bao-Yi Liu

Specialty type: Oncology

Provenance and peer review:

Unsolicited article; Externally peer reviewed.

Peer-review model: Single blind

Peer-review report's scientific quality classification

Grade A (Excellent): 0
Grade B (Very good): B
Grade C (Good): C
Grade D (Fair): 0
Grade E (Poor): 0

P-Reviewer: Gokce E, Turkey;
Zharikov YO, Russia

Received: February 10, 2023

Peer-review started: February 10, 2023

First decision: April 10, 2023

Revised: April 14, 2023

Accepted: May 6, 2023

Article in press: May 6, 2023

Published online: June 6, 2023



Xiao-Xin Pu, Qin-Wei Xu, Bao-Yi Liu, Department of Respiratory and Critical Care Medicine, Qilu Hospital, Cheeloo College Medicine, Shandong University, Qingdao 266035, Shandong Province, China

Corresponding author: Xiao-Xin Pu, MD, Doctor, Department of Respiratory and Critical Care Medicine, Qilu Hospital, Cheeloo College Medicine, Shandong University, No. 758 Hefei Road, Shibei District, Qingdao 266035, Shandong Province, China. shirleypu1989@163.com

Abstract

BACKGROUND

Primary adenoid cystic carcinoma in the trachea (TACC) is a rare tumour. Tracheal bronchoscopy is always chosen as a routine approach to obtain a pathological diagnosis, but it can be associated with an increased risk of asphyxia.

CASE SUMMARY

We describe a case of TACC in a patient evaluated by chest computed tomography (CT) with three-dimensional reconstruction imaging and diagnosed by transoesophageal endoscopic ultrasonography. The pathological diagnosis confirmed tracheal adenoid cystic carcinoma.

CONCLUSION

We highlight the importance of CT and provide a successful exploration of transoesophageal biopsy as a safe alternative approach.

Key Words: Adenoid cystic carcinoma; Tracheal obstruction; Transoesophageal endoscopic ultrasonography; Three-dimensional computed tomography reconstruction; Case report

©The Author(s) 2023. Published by Baishideng Publishing Group Inc. All rights reserved.

Core Tip: For large tracheal masses, tracheal bronchoscopy has certain limitations. This case highlights the importance of chest computed tomography for radiological assessment and provides a successful exploration of transoesophageal endoscopic ultrasound biopsy as a safe alternative biopsy approach.

Citation: Pu XX, Xu QW, Liu BY. TACC diagnosed by transoesophageal endoscopic ultrasonography: A case report. *World J Clin Cases* 2023; 11(16): 3847-3851

URL: <https://www.wjgnet.com/2307-8960/full/v11/i16/3847.htm>

DOI: <https://dx.doi.org/10.12998/wjcc.v11.i16.3847>

INTRODUCTION

Adenoid cystic carcinoma (ACC) is a rare malignant tumour of the salivary gland, especially in the trachea. In tracheal tumours, the incidence is secondary to squamous cell carcinoma[1], which is mostly located in the distal trachea, while ACC is usually located in the proximal trachea[2]. ACC is slow growing and locally aggressive with a propensity for perineural invasion and haematogenous spread. Surgery is often the first choice unless the difficulty and risk of surgery are assessed to be high.

CASE PRESENTATION

Chief complaints

A 64-year-old male was admitted to our hospital with the chief complaint of paroxysmal cough for more than 10 mo.

History of present illness

The main clinical manifestations of this patient with no smoking history were paroxysmal without sputum production and wheezing for more than 10 mo.

Physical examination

Physical examination showed no abnormalities.

Laboratory examinations

Laboratory examinations showed no abnormalities.

Imaging examinations

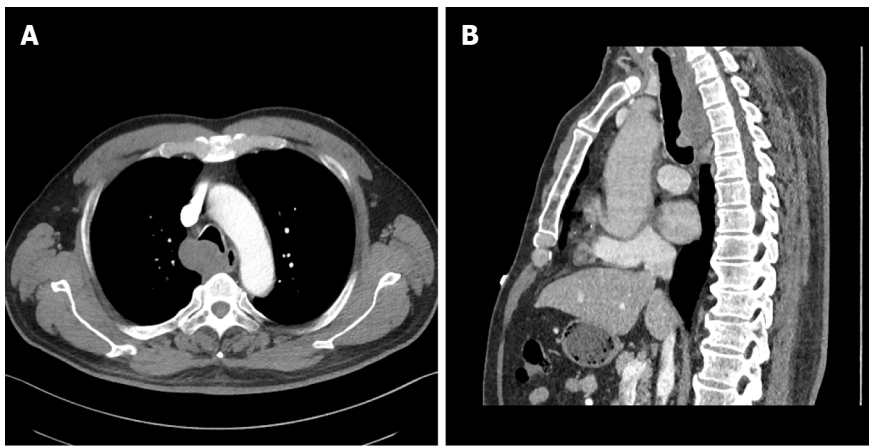
The chest X-ray showed no abnormal signs. Then, we performed a chest computed tomography (CT), which revealed airway occupation (Figure 1A). After a multidisciplinary consultation, we performed CT with three-dimensional (3D) airway reconstruction (Figure 1B) and completed tracheal bronchoscopy. However, bronchoscopy (Figure 2) showed that in the upper part of the trachea, the tumour protruded into the lumen from the membrane and extended to the carina, and the bronchoscope could barely pass through. The left and right main bronchi were unobstructed. As shown by bronchoscopy, the surface of the mass showed abundant vascularity.

MULTIDISCIPLINARY EXPERT CONSULTATION

Considering bleeding and the possibility of asphyxia, we decided to perform transoesophageal endoscopic ultrasonography after multidisciplinary treatment. A mucous eminence lesion was found on the right side of the oesophagus 25 cm away from the incisor. An ultrasound scan (Figure 3) revealed an extranuclear medium- and low-echo mass with an unclear boundary and uneven internal echo, with a size of 3.7 cm × 5.4 cm. Colour Doppler flow imaging showed few blood flow signals in this part of the mass, and a 22G puncture needle was used to repeatedly puncture the mass under ultrasound guidance. Finally, the tissue was successfully obtained.

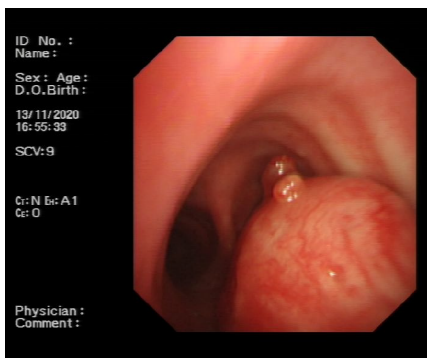
FINAL DIAGNOSIS

Cytological examination of the tracheal tumours (Figure 4A) showed small lamellar cells arranged in sacs and follicles containing myxoid substances and a few eosinophilic epithelioid cells forming tubules, which were considered salivary gland epithelial-myoepithelial tumours. Histological findings (Figure 4B) of the tracheal tumours revealed that the tumour cells arranged in the puncture tissue were microcystic, contained thin mucus and were surrounded by eosinophilic tubules. Morphological and immunomarker results supported epithelial-myoepithelial-derived tumours, which tend to be adenoid cystic carcinoma. Combined with CT scans, the diagnosis confirmed adenoid cystic carcinoma of the



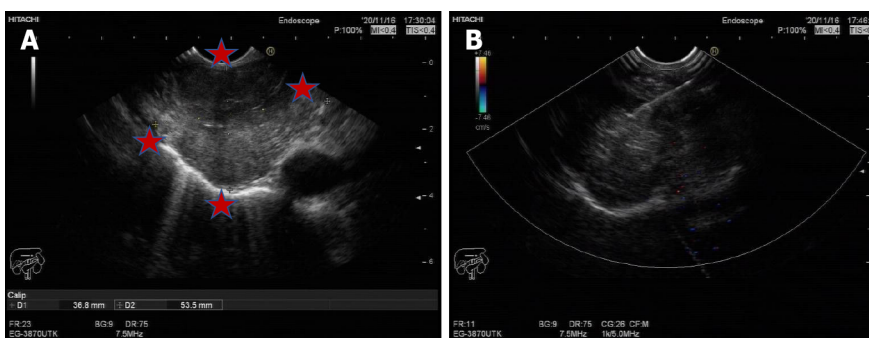
DOI: 10.12998/wjcc.v11.i16.3847 Copyright ©The Author(s) 2023.

Figure 1 Computed tomography scan of the airway occupation. A: Chest Computed tomography (CT); B: CT with three-dimensional airway reconstruction.



DOI: 10.12998/wjcc.v11.i16.3847 Copyright ©The Author(s) 2023.

Figure 2 Tracheal bronchoscopy. The masses originated from the trachea with expansive growth.



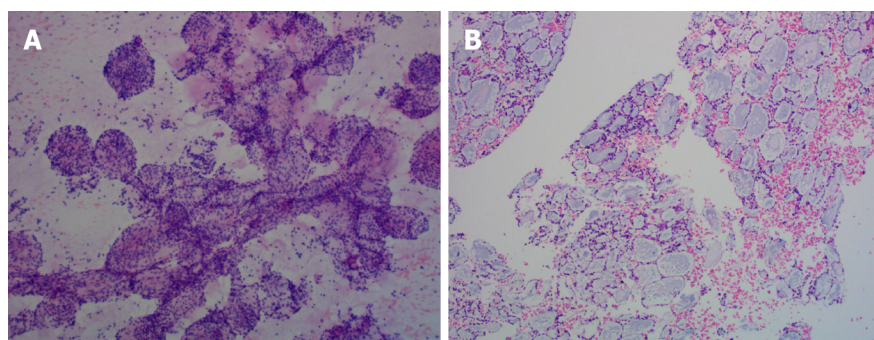
DOI: 10.12998/wjcc.v11.i16.3847 Copyright ©The Author(s) 2023.

Figure 3 Ultrasound scan. A and B: A mass with an unclear boundary.

trachea.

TREATMENT

Considering that aggressive resection of tracheal lesions may cause fatal complications and that the tumour was slow growing, after consulting other medical institutions, our patient received local radiotherapy in another hospital.



DOI: 10.12998/wjcc.v11.i16.3847 Copyright ©The Author(s) 2023.

Figure 4 Pathology (100 ×) of the tumour. A: Cytological pathology; B: Tissue pathology.

OUTCOME AND FOLLOW-UP

Our patient lost contact one year later.

DISCUSSION

Tracheal adenoid cystic carcinoma (TACC), originating in the tracheal submucous gland, is relatively rare[3,4]. The low incidence of TACC may be due to the vigorous cough reflex and the cleaning action of airway cilia. TACC is low-grade malignant, grows slowly, and can be polypoid or nodular and protrude into the trachea with a broad base. TACC can also invade the trachea and cause a soft tissue mass inside and outside the lumen, cause stenosis and obstruction of the lumen, and grow along the long axis of the tubular wall.

Microscopically, the tumour tissues show similar sieve and tubular structures, and the tumour cells are small and consistent, with little cytoplasm, an increased ratio of nucleus to cytoplasm, hyperchromatic nuclei, and rare mitosis. Pink-stained basement membrane-like substances can be seen in some lumens, blue-stained mucin-like substances can be seen in some lumens, and both substances can be found in some lumens[5]. Differential diagnoses includes squamous cell carcinoma, carcinoid, mucoepidermoid carcinoma, nonsquamous bronchial carcinoma, lymphoma, *etc.*[6].

The diagnosis is often delayed and early diagnosis is not obtained because of the absence of specific symptoms until the mass occludes most of the luminal diameter, and the tumour may cause symptoms such as cough, wheezing and exertional dyspnoea. TACC is often misdiagnosed as chronic obstructive pulmonary disease, asthma or airway inflammation. It is often difficult to detect lumps or eminences of the track on chest X-ray. Our case may be a good example. At the beginning, the patient presented with only a mild cough, and our community doctors thought it was bronchitis after completing the chest X-ray. Ten months later, we found the mass *via* a chest CT scan. Therefore, CT is particularly important [7]. In particular, CT with 3D reconstruction was used to assess airway involvement, and a combined enhancement scan was used to assess infiltration.

To obtain a pathological diagnosis and provide a better follow-up assessment, tissue biopsy was necessary. Tracheal bronchoscopy is always chosen as a routine approach to achieve this aim. The site can be confirmed visually, and enough prior information can be provided, including the appropriate size and position of the endotracheal intubation once asphyxia occurs. Conversely, the risk of asphyxia can be increased due to bleeding and mucosal oedema, especially when the tumour already causes almost 50% central airway obstruction; therefore, the bronchial approach may not be suitable. TEUS may be a safe alternative approach.

Surgical resection is the main treatment method at present, local mass resection is the main principle of radical treatment, and postoperative radiotherapy can reduce the recurrence rate[8]. However, due to the special location of the trachea, it is difficult to perform extended or complete resection, and aggressive resections may cause unpredictable and even fatal consequences, such as tracheoesophageal leakage. Therefore, partial resections with adjuvant therapy may help these patients obtain a promising prognosis. In addition to conventional radiation therapy, other treatment approaches have been attempted, such as radiotherapy with photons and hadron irradiation with carbon ions (C^{12})[9]. After consulting other medical institutions, the patient chose radiation therapy instead of a palliative operation.

There are several limitations in our report. First, rigid bronchoscopy may have been an alternative treatment option, but our team had limited experience with this approach. Second, our patient may have benefitted from undergoing palliative operation to treat the mass. Furthermore, we only provided short-term follow-up, and more detailed follow-up is needed.

CONCLUSION

In summary, we report a case of TACC. For tracheal masses, tracheal-bronchial biopsy is routine, but for large tracheal masses, tracheal bronchoscopy has certain limitations. This case highlights the importance of chest CT for radiological assessment and provides a successful exploration of transoesophageal endoscopic ultrasound biopsy as a safe alternative biopsy approach.

FOOTNOTES

Author contributions: Pu XX and Xu QW contributed to the data collection of the manuscript; Pu XX contributed to the writing of the manuscript; Liu BY helped shape the manuscript.

Informed consent statement: The patient provided informed written consent for his tissue samples to be used in this experimental research.

Conflict-of-interest statement: The authors declare that they have no competing interests.

CARE Checklist (2016) statement: The authors have read the CARE Checklist (2016), and the manuscript was prepared and revised according to the CARE Checklist (2016).

Open-Access: This article is an open-access article that was selected by an in-house editor and fully peer-reviewed by external reviewers. It is distributed in accordance with the Creative Commons Attribution NonCommercial (CC BY-NC 4.0) license, which permits others to distribute, remix, adapt, build upon this work non-commercially, and license their derivative works on different terms, provided the original work is properly cited and the use is non-commercial. See: <https://creativecommons.org/licenses/by-nc/4.0/>

Country/Territory of origin: China

ORCID number: Xiao-Xin Pu 0000-0003-2995-6586.

S-Editor: Ma YJ

L-Editor: A

P-Editor: Ma YJ

REFERENCES

- 1 Junker K. Pathology of tracheal tumors. *Thorac Surg Clin* 2014; **24**: 7-11 [PMID: 24295655 DOI: 10.1016/j.thorsurg.2013.09.008]
- 2 El Marjany M, Arsalane A, Sifat H, Andaloussi K, Oukabli M, Hadadi K, Kabiri el H, Mansouri H. Primary adenoid cystic carcinoma of the trachea: a report of two cases and literature review. *Pan Afr Med J* 2014; **19**: 32 [PMID: 25667694 DOI: 10.11604/pamj.2014.19.32.4878]
- 3 Djaković Ž, Janevski Z, Cesarec V, Slobodnjak Z, Stančić-Rokotov D. Adenoid cystic carcinoma of distal trachea: A case report. *Acta Clin Croat* 2019; **58**: 777-779 [PMID: 32595264 DOI: 10.20471/acc.2019.58.04.27]
- 4 Desai HM, Thakare R, Amonkar GP, Karkhanis V, Joshi JM. Adenoid cystic carcinoma of the trachea. *Indian J Pathol Microbiol* 2015; **58**: 516-518 [PMID: 26549080 DOI: 10.4103/0377-4929.168889]
- 5 Gao F, Zang L, He J, Xu W. A Case of Solid Variant of Adenoid Cystic Carcinoma from Trachea: A Case Report and Review of Literature. *Onco Targets Ther* 2021; **14**: 1997-2002 [PMID: 33776449 DOI: 10.2147/OTT.S296400]
- 6 Gaissert HA, Grillo HC, Shadmehr BM, Wright CD, Gokhale M, Wain JC, Mathisen DJ. Laryngotracheoplastic resection for primary tumors of the proximal airway. *J Thorac Cardiovasc Surg* 2005; **129**: 1006-1009 [PMID: 15867773 DOI: 10.1016/j.jtcvs.2004.07.043]
- 7 Gupta D, Singh I, Sakthivel P. Adenoid Cystic Carcinoma of Trachea: A Diagnostic and Therapeutic Challenge. *Indian J Otolaryngol Head Neck Surg* 2016; **68**: 94-96 [PMID: 27066420 DOI: 10.1007/s12070-015-0894-8]
- 8 Calzada AP, Miller M, Lai CK, Elashoff DA, Abemayor E, St John MA. Adenoid cystic carcinoma of the airway: a 30-year review at one institution. *Am J Otolaryngol* 2012; **33**: 226-231 [PMID: 21907453 DOI: 10.1016/j.amjoto.2011.07.003]
- 9 Högerle BA, Lasitschka F, Muley T, Bougatf N, Herfarth K, Adeberg S, Eichhorn M, Debus J, Winter H, Rieken S, Uhl M. Primary adenoid cystic carcinoma of the trachea: clinical outcome of 38 patients after interdisciplinary treatment in a single institution. *Radiat Oncol* 2019; **14**: 117 [PMID: 31272473 DOI: 10.1186/s13014-019-1323-z]



Published by **Baishideng Publishing Group Inc**
7041 Koll Center Parkway, Suite 160, Pleasanton, CA 94566, USA

Telephone: +1-925-3991568

E-mail: bpgoffice@wjgnet.com

Help Desk: <https://www.f6publishing.com/helpdesk>

<https://www.wjgnet.com>

