

World Journal of *Clinical Cases*

World J Clin Cases 2023 August 6; 11(22): 5193-5415



Contents

Thrice Monthly Volume 11 Number 22 August 6, 2023

MINIREVIEWS

- 5193 Research progress on reactive oxygen species production mechanisms in tumor sonodynamic therapy
Dong HQ, Fu XF, Wang MY, Zhu J

ORIGINAL ARTICLE

Retrospective Study

- 5204 Combining the age-male-albumin-bilirubin-platelets score and shear wave elastography stratifies carcinogenic risk in hepatitis C patients after viral clearance
Masaoka R, Gytoku Y, Shirahashi R, Suda T, Tamano M
- 5215 Changes in neurotransmitter levels, brain structural characteristics, and their correlation with PANSS scores in patients with first-episode schizophrenia
Xu XJ, Liu TL, He L, Pu B
- 5224 Five-year outcomes of immediate implant placement for mandibular molars with and without chronic apical periodontitis: A retrospective study
Yang H, Luo D, Yuan MJ, Yang JJ, Wang DS

Observational Study

- 5236 Standardization of apple cancellation test for neglect patients in Korea: An observational study
Jang WH, Jang JS

Prospective Study

- 5244 Diabetic neuropathy results in vasomotor dysfunction of medium sized peripheral arteries
Ege F, Kazci Ö, Aydin S

SYSTEMATIC REVIEWS

- 5252 COVID-19-induced gastrointestinal autonomic dysfunction: A systematic review
Elbeltagi R, Al-Beltagi M, Saeed NK, Bediwy AS

META-ANALYSIS

- 5273 Meta-analysis of outcomes from drug-eluting stent implantation in infrapopliteal arteries
Li MX, Tu HX, Yin MC

CASE REPORT

- 5288 Acute hepatitis of unknown etiology in an adult female: A case report
Dass L, Pacia AMM, Hamidi M

- 5296** Zimberelimab plus chemotherapy as the first-line treatment of malignant peritoneal mesothelioma: A case report and review of literature
Peng XD, You ZY, He LX, Deng Q
- 5303** Recurrent ventricular arrhythmia due to aconite intoxication successfully treated with landiolol: A case report
Matsuo C, Yamamoto K, Fukushima H, Yajima D, Inoue H
- 5309** Anti-phospholipase A2 receptor-associated membranous nephropathy with human immunodeficiency virus infection treated with telitacicept: A case report
Wang JL, Sun YL, Kang Z, Zhang SK, Yu CX, Zhang W, Xie H, Lin HL
- 5316** Rapid progression of heart failure secondary to radioactive iodine treatment of hyperthyroidism: A case report
Li ZH, Ni LJ, Liu YQ, Si DY
- 5322** Pathological complete response to neoadjuvant alectinib in unresectable anaplastic lymphoma kinase positive non-small cell lung cancer: A case report
Wang LM, Zhao P, Sun XQ, Yan F, Guo Q
- 5329** Hepatoid adenocarcinoma of the stomach with neuroendocrine differentiation: A case report and review of literature
Fei H, Li ZF, Chen YT, Zhao DB
- 5338** Acquired haemophilia as a complicating factor in treatment of non-muscle invasive bladder cancer: A case report
Ryšánková K, Gumulec J, Grepl M, Krhut J
- 5344** Persistent dysexecutive syndrome after pneumococcal meningitis complicated by recurrent ischemic strokes: A case report
Abbruzzese L, Martinelli G, Salti G, Basagni B, Damora A, Scarselli C, Peppoloni G, Podgorska A, Rosso G, Bacci M, Alfano AR, MANCUSO M
- 5351** Treatment of refractory anti-melanoma differentiation-associated gene 5 antibody-positive dermatomyositis complicated by rapidly progressing interstitial pulmonary disease: Two case reports
Wang QH, Chen LH
- 5358** TINAVI robot-assisted one-stage anteroposterior surgery in lateral position for severe thoracolumbar fracture dislocation: A case report
Ye S, Chen YZ, Zhong LJ, Yu CZ, Zhang HK, Hong Y
- 5365** Individual with concurrent chest wall tuberculosis and triple-negative essential thrombocythemia: A case report
Xu XY, Yang YB, Yuan J, Zhang XX, Kang L, Ma XS, Yang J
- 5373** Self-strangulation induced penile partial amputation: A case report
Maimaitiming ABLT, Mulati YLSD, Apizi ART, Li XD
- 5382** Long-term rare giant sialolithiasis for 30 years: A case report and review of literature
Mao JS, Lee YC, Chi JCY, Yi WL, Tsou YA, Lin CD, Tai CJ, Shih LC

- 5391** Kawasaki disease with peritonsillar abscess as the first symptom: A case report
Huo LM, Li LM, Peng HY, Wang LJ, Feng ZY
- 5398** Treatment of a patient with severe lactic acidosis and multiple organ failure due to mitochondrial myopathy: A case report
Chen L, Shuai TK, Gao YW, Li M, Fang PZ, Christian W, Liu LP
- 5407** Early esophageal carcinomas in achalasia patient after endoscopic submucosal dissection combined with peroral endoscopic myotomy: A case report
An BQ, Wang CX, Zhang HY, Fu JD

LETTER TO THE EDITOR

- 5412** Caution in the use of sedation and endomyocardial biopsy for the management of pediatric acute heart failure caused by endocardial fibroelastosis
Xin XX, Se YY

ABOUT COVER

Editorial Board Member of *World Journal of Clinical Cases*, Etienne Andrade Munhoz, PhD, Associate Professor, Department of Dentistry, Health Science Centre, Federal University of Santa Catarina, Florianopolis 88040-379, Brazil. etiamfob@yahoo.com

AIMS AND SCOPE

The primary aim of *World Journal of Clinical Cases* (*WJCC*, *World J Clin Cases*) is to provide scholars and readers from various fields of clinical medicine with a platform to publish high-quality clinical research articles and communicate their research findings online.

WJCC mainly publishes articles reporting research results and findings obtained in the field of clinical medicine and covering a wide range of topics, including case control studies, retrospective cohort studies, retrospective studies, clinical trials studies, observational studies, prospective studies, randomized controlled trials, randomized clinical trials, systematic reviews, meta-analysis, and case reports.

INDEXING/ABSTRACTING

The *WJCC* is now abstracted and indexed in Science Citation Index Expanded (SCIE, also known as SciSearch®), Journal Citation Reports/Science Edition, Current Contents®/Clinical Medicine, PubMed, PubMed Central, Reference Citation Analysis, China National Knowledge Infrastructure, China Science and Technology Journal Database, and Superstar Journals Database. The 2023 Edition of Journal Citation Reports® cites the 2022 impact factor (IF) for *WJCC* as 1.1; IF without journal self cites: 1.1; 5-year IF: 1.3; Journal Citation Indicator: 0.26; Ranking: 133 among 167 journals in medicine, general and internal; and Quartile category: Q4.

RESPONSIBLE EDITORS FOR THIS ISSUE

Production Editor: *Si Zhao*; Production Department Director: *Xu Guo*; Editorial Office Director: *Jin-Lei Wang*.

NAME OF JOURNAL

World Journal of Clinical Cases

ISSN

ISSN 2307-8960 (online)

LAUNCH DATE

April 16, 2013

FREQUENCY

Thrice Monthly

EDITORS-IN-CHIEF

Bao-Gan Peng, Jerzy Tadeusz Chudek, George Kontogeorgos, Maurizio Serati, Ja Hyeon Ku

EDITORIAL BOARD MEMBERS

<https://www.wjgnet.com/2307-8960/editorialboard.htm>

PUBLICATION DATE

August 6, 2023

COPYRIGHT

© 2023 Baishideng Publishing Group Inc

INSTRUCTIONS TO AUTHORS

<https://www.wjgnet.com/bpg/gerinfo/204>

GUIDELINES FOR ETHICS DOCUMENTS

<https://www.wjgnet.com/bpg/GerInfo/287>

GUIDELINES FOR NON-NATIVE SPEAKERS OF ENGLISH

<https://www.wjgnet.com/bpg/gerinfo/240>

PUBLICATION ETHICS

<https://www.wjgnet.com/bpg/GerInfo/288>

PUBLICATION MISCONDUCT

<https://www.wjgnet.com/bpg/gerinfo/208>

ARTICLE PROCESSING CHARGE

<https://www.wjgnet.com/bpg/gerinfo/242>

STEPS FOR SUBMITTING MANUSCRIPTS

<https://www.wjgnet.com/bpg/GerInfo/239>

ONLINE SUBMISSION

<https://www.f6publishing.com>



Anti-phospholipase A2 receptor-associated membranous nephropathy with human immunodeficiency virus infection treated with telitacicept: A case report

Jin-Ling Wang, Yan-Ling Sun, Zhe Kang, Sheng-Kun Zhang, Chun-Xin Yu, Wan Zhang, Hua Xie, Hong-Li Lin

Specialty type: Urology and nephrology

Provenance and peer review:

Unsolicited article; Externally peer reviewed.

Peer-review model: Single blind

Peer-review report's scientific quality classification

Grade A (Excellent): 0
Grade B (Very good): B
Grade C (Good): C
Grade D (Fair): 0
Grade E (Poor): 0

P-Reviewer: Koubaa M, Tunisia;
Thongon N, Thailand

Received: March 2, 2023

Peer-review started: March 2, 2023

First decision: June 12, 2023

Revised: July 7, 2023

Accepted: July 17, 2023

Article in press: July 17, 2023

Published online: August 6, 2023



Jin-Ling Wang, Yan-Ling Sun, Zhe Kang, Sheng-Kun Zhang, Chun-Xin Yu, Wan Zhang, Hua Xie, Department of Nephrology, Dalian Renal Care Hospital, Dalian 116000, Liaoning Province, China

Hong-Li Lin, Department of Nephrology, The First Affiliated Hospital of Dalian Medical University, Dalian 116000, Liaoning Province, China

Corresponding author: Hong-Li Lin, PhD, Chief Physician, Department of Nephrology, The First Affiliated Hospital of Dalian Medical University, No. 222 Zhongshan Road, Dalian 116000, Liaoning Province, China. linhongli1216@163.com

Abstract

BACKGROUND

The co-occurrence of Anti-phospholipase A2 receptor-associated membranous nephropathy (anti-PLA2R-MN) and human immunodeficiency virus (HIV) infection is a rare clinical scenario, presenting significant challenges in terms of management and treatment.

CASE SUMMARY

A 32-year-old Chinese male diagnosed with HIV infection presented with a clinical history of proteinuria persisting for over two years. A kidney biopsy demonstrated subepithelial immune complex deposition and a thickened glomerular basement membrane, indicative of stage I-II membranous nephropathy. Immunofluorescence staining revealed granular deposition of PLA2R (3+) along the glomerular capillary loops, corroborated by a strongly positive anti-PLA2R antibody test (1:320). Initial treatment involving losartan potassium, rivaroxaban, tacrolimus, and rituximab was discontinued due to either poor effectiveness or the occurrence of adverse events. Following a regimen of weekly subcutaneous injections of telitacicept (160 mg), a marked decline in the 24 h urine protein was observed within a three-month period, accompanied by a rise in serum albumin level. No significant reductions in peripheral blood CD3+CD4+T and CD3+CD8+T cell counts were detected. The patient's physical and psychological conditions showed significant improvements, with no adverse events reported during the treatment course.

CONCLUSION

Telitacicept might offer a potential therapeutic avenue for patients diagnosed with

anti-PLA2R-MN concomitant with HIV infection.

Key Words: Membranous nephropathy; PLA2R; Human immunodeficiency virus; Proteinuria; Telitacicept; Case report

©The Author(s) 2023. Published by Baishideng Publishing Group Inc. All rights reserved.

Core Tip: The clinical management of anti-phospholipase A2 receptor-associated membranous nephropathy concurrent with human immunodeficiency virus infection presents significant challenges, primarily due to potential unregulated immune responses. In this report, we demonstrated that a weekly subcutaneous injection of telitacicept (160 mg) could ameliorate the 24-h urinary protein levels and enhance serum albumin concentrations, with no discernible impact on T cell counts, showcasing its safety profile.

Citation: Wang JL, Sun YL, Kang Z, Zhang SK, Yu CX, Zhang W, Xie H, Lin HL. Anti-phospholipase A2 receptor-associated membranous nephropathy with human immunodeficiency virus infection treated with telitacicept: A case report. *World J Clin Cases* 2023; 11(22): 5309-5315

URL: <https://www.wjgnet.com/2307-8960/full/v11/i22/5309.htm>

DOI: <https://dx.doi.org/10.12998/wjcc.v11.i22.5309>

INTRODUCTION

Anti-phospholipase A2 receptor-associated membranous nephropathy (anti-PLA2R-MN) is a form of primary membranous nephropathy characterized by elevated levels of anti-PLA2R antibodies in plasma or tissue. The co-occurrence of anti-PLA2R-MN with human immunodeficiency virus (HIV) infection is uncommon. There are challenges in the clinical treatment of membranous nephropathy (MN) in such immunodeficient patients, due to immune functional status, and immunosuppressive therapy need to be taken into account[1]. We herein document a case of anti-PLA2R-MN concurrent with HIV infection, which was successfully treated with telitacicept.

CASE PRESENTATION

Chief complaints

A 32-year-old Chinese male was admitted to our hospital with a progressive increase in urine protein levels to 4000-5000 mg/24 h.

History of present illness

Roughly 2.5 years prior, the patient sought a nephrology consultation due to fever and low back pain. He exhibited 2+ proteinuria. Serum creatinine levels of 83 $\mu\text{mol/L}$ and a 24-h urinary protein quantification of 1835 mg. Antinuclear antibody, anti-Sm, anti-dsDNA, anti-PLA2R antibodies, and complement tests were all negative. The patient has been under regular follow-up since then.

History of past illness

He had been living with HIV for six years and had a prior history of successfully treated pulmonary tuberculosis five years prior.

Personal and family history

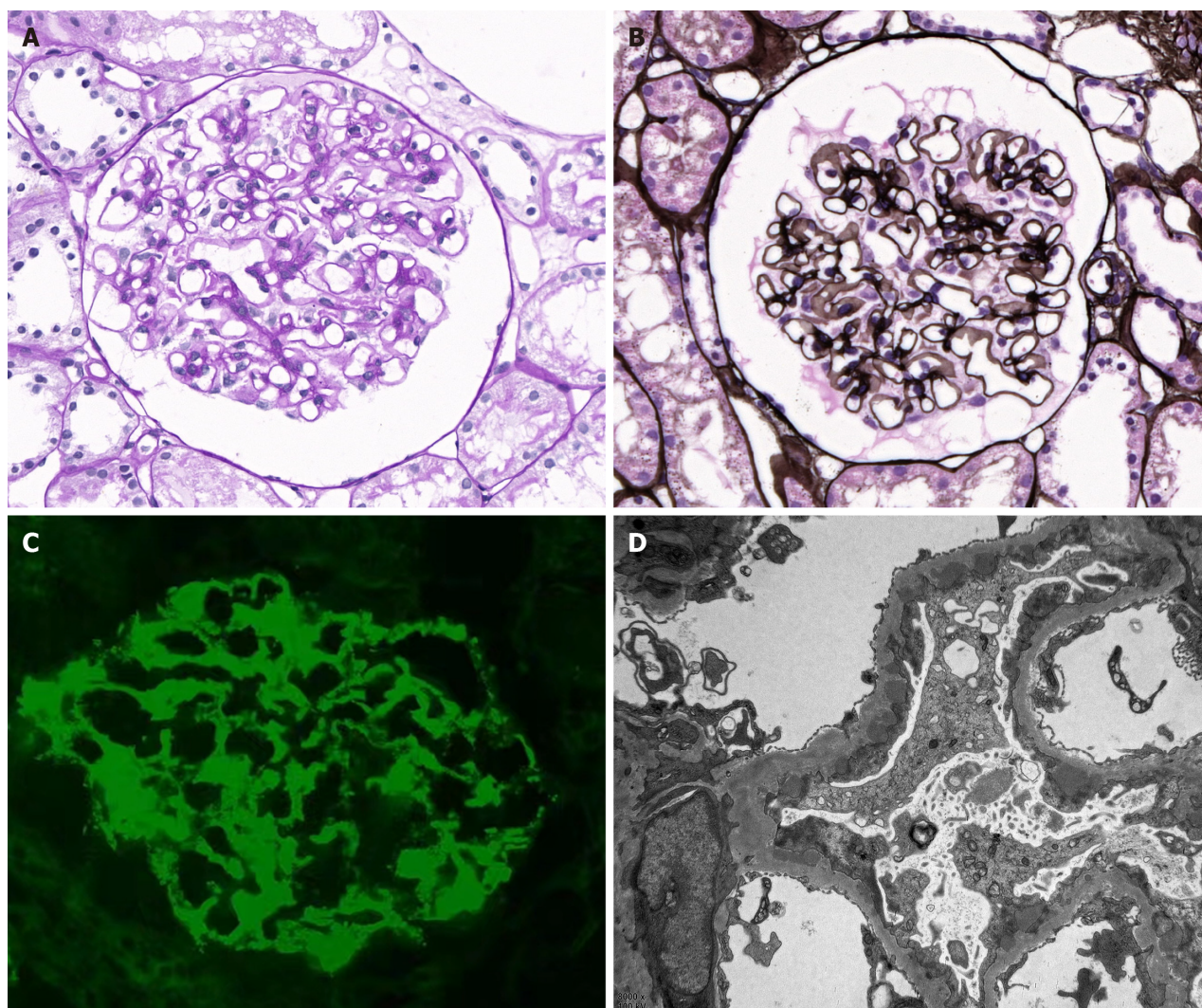
No relevant personal or family history was provided.

Physical examination

Vital signs, including body temperature, blood pressure, heart rate, and respiratory rate were within normal limits.

Laboratory examinations

Upon admission, a kidney biopsy showed that all 22 glomeruli had neither global nor segment sclerosis, and the capillary loops were patent. No glomerular cell proliferation or inflammatory cell infiltration were observed. Subepithelial immune complex deposition and glomerular basement membrane thickening were noted, but no spikes or double contours were seen. The renal tubular epithelial cells exhibited granular changes without significant atrophy. Mild protein casts were found in the tubules. Mild inflammatory cell infiltration was noted in the renal interstitium, but there was no significant fibrosis or edema. The arterioles walls showed thickening (Figure 1). Congo red staining was negative. Immunofluorescence staining demonstrated granular deposition of PLA2R (3+) and immunoglobulin G (IgG) (1+) (weak positive of



DOI: 10.12998/wjcc.v11.i22.5309 Copyright ©The Author(s) 2023.

Figure 1 Biopsy findings in patients with human immunodeficiency virus infection and membranous nephropathy. A: Histological analysis of biopsy tissues via light microscopy showed eosinophilic deposits under the epithelium and a thickening of the basement membrane with vacuoles and granules visualized by periodic acid-Schiff staining ($\times 400$); B: Periodic acid methenamine silver staining visualization also highlights vacuoles and granules ($\times 400$); C: Immunofluorescent evaluation of renal tissues ($\times 400$) showed granular phospholipase A2 receptor-associated deposition along capillary loops; D: Electron microscopy showed subepithelial electron-dense deposits with the associated basement membrane, consistent with stage I-II membranous nephropathy ($\times 8000$).

IgG4 and negative of IgG1) along the capillary loops. The findings of electron microscopy were compatible with membranous nephropathy (stage I-II).

Imaging examinations

No imaging studies were performed.

FINAL DIAGNOSIS

Based on the above clinical history and findings, the patient was diagnosed with anti-PLA2R-MN.

TREATMENT

The patient's initial treatment included losartan potassium and rivaroxaban, which corresponded with 24-h urinary protein levels of 2338-3826 mg and serum albumin concentrations of 33.3-39.8 g/L. However, a sudden surge in 24-h urinary protein level to 7838 mg led to the addition of tacrolimus (0.5 mg bid po). Plasma concentration level of tacrolimus was sub-therapeutic (1.8 ng/mL) two weeks later. Unfortunately, after three months on tacrolimus, 24-h urinary protein level still rose to 9224.17 mg, while fasting blood glucose level rose to 6.82 mmol/L.

Owing to side effects and suboptimal efficacy of tacrolimus, the treatment was discontinued and replaced with intravenous rituximab 2 mo later because his 24-h urine protein quantitative level increased to 9493.50 mg, serum albumin decreased to 26.13 g/L and anti-PLA2R antibody titer of 1:320. At that moment, his serum creatinine was 125.57 $\mu\text{mol/L}$; total T cell count was 828/ μL ; total B cell count was 158/ μL ; CD3+CD4+T cell count was 436/ μL ; and CD3+CD8+T cell count was 348/ μL .

Unfortunately, an allergic reaction occurred during rituximab administration, including body-wide itching, scattered small red papules on the back, and an elevated heart rate (100-110 times/min), leading to its discontinuation after 200 mg. Subsequently, treatment with subcutaneous injections of telitacicept (160 mg once a week) was initiated.

OUTCOME AND FOLLOW-UP

After three months of telitacicept treatment, the patient's 24-h urinary protein levels declined to 2869.76 mg, his serum albumin level rose from 22.35 g/L to 28.22 g/L, and serum creatinine decreased to 112.7 $\mu\text{mol/L}$ (Figure 2). A test for anti-PLA2R antibody titer was postponed due to the coronavirus disease 2019 epidemic, and no adverse events, such as respiratory infections or diarrhea, were observed during the treatment.

Throughout treatment, the patient's HIV remained in a state of low transcription. The latest cell count showed CD3+CD4+T cell count of 352/ μL and a CD3+CD8+T cell count of 375/ μL . Continued treatment and follow-up are ongoing.

DISCUSSION

Individuals positive for HIV demonstrated an elevated risk for kidney disease, including HIV-associated nephropathy, non-collapsing focal segmental glomerulosclerosis, immune-complex kidney disease, comorbid kidney disease, and kidney injury associated with prolonged exposure to antiretroviral therapy or opportunistic infection[2]. These conditions are the main contributors to end-stage renal disease in HIV-positive patients[3]. Literature reviews of HIV-associated MN cases frequently report identification of MN in the context of undetectable viral loads. In approximately 50% of cases, tissue reactivity with the PLA2R antigen can be identified, even in the absence of corresponding anti-PLA2R serum antibodies[1].

A proposed mechanism for the development of anti-PLA2R autoantibodies in HIV patients is "bystander activation", where tissue damage arises from an over-reactive antiviral immune response, followed by the release of self-antigens that perpetuate autoimmune-mediated harm *via* spreading epitopes[4]. Antiretroviral therapy is an important strategy to minimize the incidence of acute kidney injury and HIV-related kidney diseases[5]. However, the nephrotoxicity of antiretroviral drugs should also be taken into account. Therefore, chronic kidney disease (CKD) screening is recommended at the time of HIV diagnosis and ART initiation or modification. Effective blood pressure management, diabetes care, or the use of Angiotensin converting enzyme (ACE)-inhibitors and angiotensin receptor blockers may help mitigate the progression of CKD in HIV-positive individuals[3].

In this case, we encountered a refractory case of anti-PLA2R-MN associated with HIV infection. It is critical to identify the primary cause of progressive renal disease in HIV-positive patients. Differing treatments are needed depending on whether interstitial kidney injury resulting from prolonged exposure to antiretroviral therapy or from opportunistic infections. Other causes should also be ruled out. Kidney biopsy is the most definitive method to establish a diagnosis. Our patient's kidney biopsy is the most definitive method to establish a diagnosis. Our patient's kidney biopsy showed immune complex deposition in the subepithelial area and a thickened glomerular basement membrane, indicative of stage I-II membranous nephropathy. Immunofluorescence showed granular deposition of PLA2R (3+) along the capillary loops, and the test of anti-PLA2R antibody was strongly positive (1:320); these findings confirmed a diagnosis of anti-PLA2R-MN. About 50%-90% of anti-PLA2R-MN patients present with nephrotic syndrome and the degree of proteinuria remission is associated with the prognosis of renal function[6]. In our case, the main complaints were proteinuria, hypoalbuminemia, and fatigue.

The primary challenge in clinically treating anti-PLA2R-MN co-existing with HIV infection is the selection of immunosuppressants. In our case, the patient was in a status of immunodeficiency with a history of tuberculosis. Instead of utilizing a small dose of glucocorticoids or cyclophosphamide, we chose losartan potassium and tacrolimus to control the progression of kidney injury. Tacrolimus, a calcineurin inhibitor, could combine with immune avidin and suppress cytoplasm calcineurin activity, subsequently blocking the T cell proliferation and avoiding bone marrow suppression[7]. Studies have shown that calcineurin inhibitors have effects on the podocyte cytoskeleton, resulting in a non-specific reduction of proteinuria[8]. Furthermore, tacrolimus could induce a rapid decrease in anti-PLA2R levels[9,10]. A meta-analysis[11] found that tacrolimus therapy was associated with high total remission and low proteinuria level compared to cyclophosphamide for patients with MN. However, in our case, after three months of tacrolimus treatment, the 24-h urine protein continued to rise without remission. Due to the elevated blood glucose level, a side effects, tacrolimus was discontinued. According to the "Expert consensus on the application of rituximab in the treatment of membranous nephropathy"[12], rituximab has been applied to treat membranous nephropathy in recent years with favorable results. As a murine/human chimeric anti-CD20 monoclonal antibody that depletes B cells, rituximab has been reported to be effective in the treatment of MN by clearing B cells, inhibiting B cell-T cell interaction, or depleting CD20^{dim}T cells, contributing to decreased T-cell activation, or decreased effector T-cell generation, which, as a consequence, would result in rising Treg cell percentages among CD4 T cells[13] with the expert consensus' recommendation on rituximab in

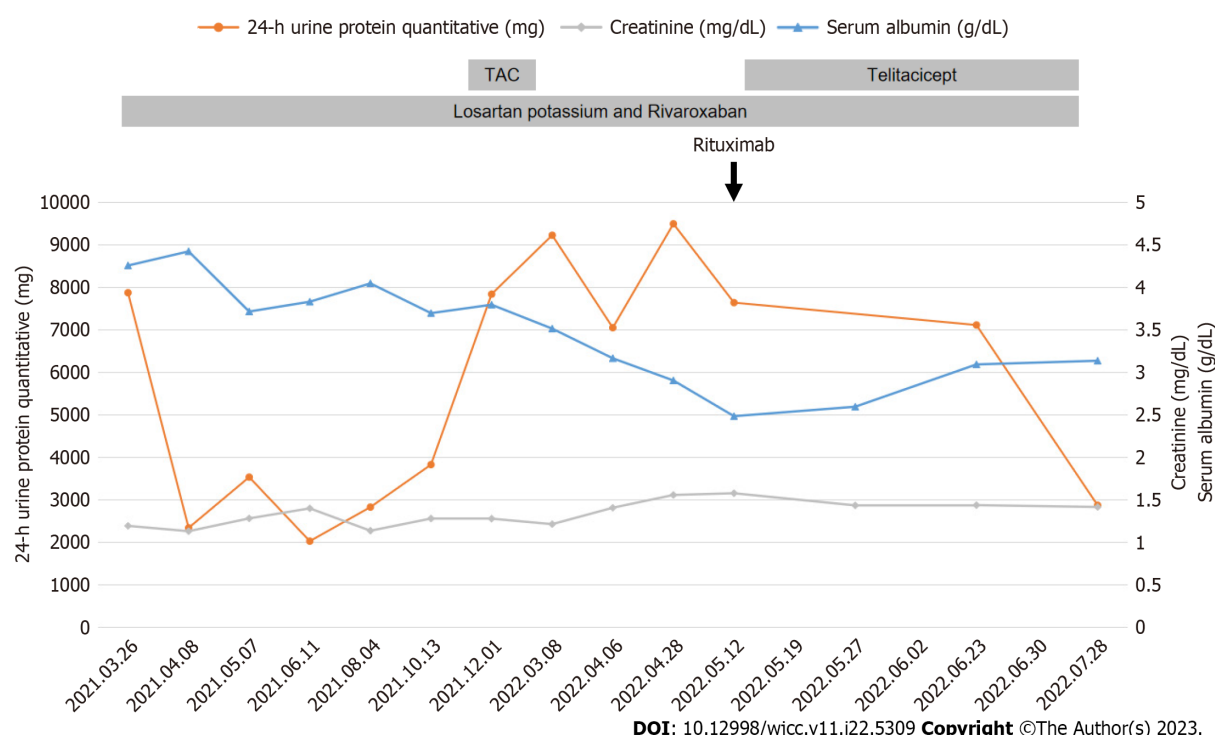


Figure 2 Patient's clinical course. TAC: Tacrolimus

treating anti-PLA2R-MN and refractory MN. Unfortunately, our patient showed an allergic reaction when we changed to rituximab therapy.

Telitacicept, a novel fusion protein comprising a recombinant transmembrane activator and calcium modulator and cyclophilin ligand interactor receptor fused to the fragment crystallizable domain of human immunoglobulin G (IgG) [14]. It's a dual inhibitor of B-lymphocyte stimulator and a proliferation-inducing ligand (APRIL). BlyS (B cell activator, BAFF) and APRIL are crucial in maintaining the B cell pool and humoral immunity. For example, BlyS regulates differentiation and maturation of immature B cells, while APRIL oversees the function and survival of long-lived plasma cells. Both play prominent roles in the pathogenesis of autoimmune diseases. By binding to and neutralizing the activity of these two cell-signaling molecules, BlyS and APRIL, Telitacicept suppresses the development and survival of plasma cells and mature B cells. Telitacicept has shown promising clinical outcomes in the treatment of B cell-mediated autoimmune diseases, such as systemic lupus erythematosus, rheumatoid arthritis, and multiple sclerosis, with good clinical outcomes [15].

A recent study demonstrated telitacicept's efficacy on lupus nephritis, with all 8 pediatric patients showing varying degrees of urine protein reduction, gradual normalization of albumin, and some improvement in renal function without further deterioration [16]. However, treating anti-PLA2R-MN with HIV infection with telitacicept has not been reported before. Our case has shown a surprising therapeutic effect with no obvious side effects till now. According to the 2021 KDIGO GN Guidelines [17], our patient's condition was reduced from high risk (proteinuria > 3.5 g/d, no decrease > 50% after six months of conservative therapy with ACEi, serum albumin < 25 g/L, and PLA2Rab > 50 RU/mL) to partial remission (proteinuria < 3.5 g/d and serum albumin > 25 g/L).

CONCLUSION

We report a case of anti-PLA2R-MN associated with HIV infection in which telitacicept was effective in reducing proteinuria. More comprehensive clinical and laboratory studies are required to assess the efficacy and safety of telitacicept in treating patients with anti-PLA2R-MN and HIV infection.

FOOTNOTES

Author contributions: Wang JL, Sun YL, Kang Z, Zhang SK, Yu CX, Zhang W, and Xie H participated in the acquisition of clinical data; Lin HL, Wang JL, Sun YL, and Xie H carried out analysis of patient's clinical course and data interpretation; Wang JL and Lin HL wrote a draft of the manuscript; Sun YL and Kang Z prepared figures; Zhang SK, Yu CX, Zhang W, and Xie H revised it critically; All authors read and approved the final manuscript.

Informed consent statement: The informed consent form was signed by patient.

Conflict-of-interest statement: The authors declare that there were no competing interests.

CARE Checklist (2016) statement: The authors have read the CARE Checklist (2016), and the manuscript was prepared and revised according to the CARE Checklist (2016).

Open-Access: This article is an open-access article that was selected by an in-house editor and fully peer-reviewed by external reviewers. It is distributed in accordance with the Creative Commons Attribution NonCommercial (CC BY-NC 4.0) license, which permits others to distribute, remix, adapt, build upon this work non-commercially, and license their derivative works on different terms, provided the original work is properly cited and the use is non-commercial. See: <https://creativecommons.org/licenses/by-nc/4.0/>

Country/Territory of origin: China

ORCID number: Hong-Li Lin 0000-0002-6584-9561; Hua Xie 0000-0003-4971-5333.

S-Editor: Liu JH

L-Editor: A

P-Editor: Ju JL

REFERENCES

- Charu V, Andeen N, Walavalkar V, Lapasia J, Kim JY, Lin A, Sibley R, Higgins J, Troxell M, Kambham N. Membranous nephropathy in patients with HIV: a report of 11 cases. *BMC Nephrol* 2020; **21**: 401 [PMID: 32948130 DOI: 10.1186/s12882-020-02042-x]
- Swanepoel CR, Atta MG, D'Agati VD, Estrella MM, Fogo AB, Naicker S, Post FA, Wearne N, Winkler CA, Cheung M, Wheeler DC, Winkelmayer WC, Wyatt CM; Conference Participants. Kidney disease in the setting of HIV infection: conclusions from a Kidney Disease: Improving Global Outcomes (KDIGO) Controversies Conference. *Kidney Int* 2018; **93**: 545-559 [PMID: 29398134 DOI: 10.1016/j.kint.2017.11.007]
- Prudhvi K, Schwartz D, Fisher M. Rituximab for Lupus-Like Membranous Nephropathy in the Setting of Well-Controlled HIV Infection. *Am J Ther* 2020; **28**: e732-e734 [PMID: 32769387 DOI: 10.1097/MJT.0000000000001220]
- Smatti MK, Cyprian FS, Nasrallah GK, Al Thani AA, Almishal RO, Yassine HM. Viruses and Autoimmunity: A Review on the Potential Interaction and Molecular Mechanisms. *Viruses* 2019; **11** [PMID: 31430946 DOI: 10.3390/v11080762]
- Booth JW, Hamzah L, Jose S, Horsfield C, O'Donnell P, McAdoo S, Kumar EA, Turner-Stokes T, Khatib N, Das P, Naftalin C, Mackie N, Kingdon E, Williams D, Hendry BM, Sabin C, Jones R, Levy J, Hilton R, Connolly J, Post FA; HIV/CKD Study and the UK CHIC Study. Clinical characteristics and outcomes of HIV-associated immune complex kidney disease. *Nephrol Dial Transplant* 2016; **31**: 2099-2107 [PMID: 26786550 DOI: 10.1093/ndt/gfv436]
- Di J, Qian Q, Yang M, Jiang Y, Zhou H, Li M, Zou Y. Efficacy and safety of long-course tacrolimus treatment for idiopathic membranous nephropathy. *Exp Ther Med* 2018; **16**: 979-984 [PMID: 30116348 DOI: 10.3892/etm.2018.6211]
- Huang H, Liang Z, Zheng X, Qing Q, Du X, Tang Z, Wei M, Wang C, Zhong Q, Lin X. Tacrolimus versus cyclophosphamide for patients with idiopathic membranous nephropathy and treated with steroids: a systematic review and meta-analysis of randomized controlled trials. *Ren Fail* 2021; **43**: 840-850 [PMID: 34016023 DOI: 10.1080/0886022X.2021.1914655]
- Faul C, Donnelly M, Merscher-Gomez S, Chang YH, Franz S, Delfgaauw J, Chang JM, Choi HY, Campbell KN, Kim K, Reiser J, Mundel P. The actin cytoskeleton of kidney podocytes is a direct target of the antiproteinuric effect of cyclosporine A. *Nat Med* 2008; **14**: 931-938 [PMID: 18724379 DOI: 10.1038/nm.1857]
- Ramachandran R, Yadav AK, Kumar V, Siva Tez Pinnamaneni V, Nada R, Ghosh R, Rathi M, Kohli HS, Gupta KL, Sakhuja V, Jha V. Two-Year Follow-up Study of Membranous Nephropathy Treated With Tacrolimus and Corticosteroids Versus Cyclical Corticosteroids and Cyclophosphamide. *Kidney Int Rep* 2017; **2**: 610-616 [PMID: 29142979 DOI: 10.1016/j.ekir.2017.02.004]
- Fernández-Juárez G, Rojas-Rivera J, Logt AV, Justino J, Sevillano A, Caravaca-Fontán F, Ávila A, Rabasco C, Cabello V, Varela A, Díez M, Martín-Reyes G, Diezhandino MG, Quintana LF, Agraz I, Gómez-Martino JR, Cao M, Rodríguez-Moreno A, Rivas B, Galeano C, Bonet J, Romera A, Shabaka A, Plaisier E, Espinosa M, Egidio J, Segarra A, Lambeau G, Ronco P, Wetzels J, Praga M; STARMEN Investigators. The STARMEN trial indicates that alternating treatment with corticosteroids and cyclophosphamide is superior to sequential treatment with tacrolimus and rituximab in primary membranous nephropathy. *Kidney Int* 2021; **99**: 986-998 [PMID: 33166580 DOI: 10.1016/j.kint.2020.10.014]
- Lin W, Li HY, Lin S, Zhou T. Efficacy and safety of tacrolimus vs cyclophosphamide in the therapy of patients with idiopathic membranous nephropathy: a meta-analysis. *Drug Des Devel Ther* 2019; **13**: 2179-2186 [PMID: 31308629 DOI: 10.2147/DDDT.S209211]
- Nephrology Expert Panel of the Peking University Health Science Center. [Expert consensus on the application of rituximab in the treatment of membranous nephropathy]. *Zhonghua Nei Ke Za Zhi* 2022; **61**: 282-290 [PMID: 35263969 DOI: 10.3760/cma.j.cn112138-20210927-00660]
- Rosenzweig M, Languille E, Debiec H, Hygino J, Dahan K, Simon T, Klatzmann D, Ronco P. B- and T-cell subpopulations in patients with severe idiopathic membranous nephropathy may predict an early response to rituximab. *Kidney Int* 2017; **92**: 227-237 [PMID: 28318628 DOI: 10.1016/j.kint.2017.01.012]
- Shi F, Xue R, Zhou X, Shen P, Wang S, Yang Y. Telitacicept as a BLyS/APRIL dual inhibitor for autoimmune disease. *Immunopharmacol Immunotoxicol* 2021; **43**: 666-673 [PMID: 34519594 DOI: 10.1080/08923973.2021.1973493]
- Dhillon S. Telitacicept: First Approval. *Drugs* 2021; **81**: 1671-1675 [PMID: 34463932 DOI: 10.1007/s40265-021-01591-1]
- Sun L, Shen Q, Gong Y, Li Y, Lv Q, Liu H, Zhao F, Yu H, Qiu L, Li X, He X, Chen Y, Xu Z, Xu H. Safety and efficacy of telitacicept in refractory childhood-onset systemic lupus erythematosus: A self-controlled before-after trial. *Lupus* 2022; **31**: 998-1006 [PMID: 35499216 DOI: 10.1177/09612033221097812]

- 17 **Rovin BH**, Adler SG, Barratt J, Bridoux F, Burdge KA, Chan TM, Cook HT, Fervenza FC, Gibson KL, Glasscock RJ, Jayne DRW, Jha V, Liew A, Liu ZH, Mejia-Vilet JM, Nester CM, Radhakrishnan J, Rave EM, Reich HN, Ronco P, Sanders JF, Sethi S, Suzuki Y, Tang SCW, Tesar V, Vivarelli M, Wetzels JFM, Lytvyn L, Craig JC, Tunncliffe DJ, Howell M, Tonelli MA, Cheung M, Earley A, Floege J. Executive summary of the KDIGO 2021 Guideline for the Management of Glomerular Diseases. *Kidney Int* 2021; **100**: 753-779 [PMID: [34556300](#) DOI: [10.1016/j.kint.2021.05.015](#)]



Published by **Baishideng Publishing Group Inc**
7041 Koll Center Parkway, Suite 160, Pleasanton, CA 94566, USA

Telephone: +1-925-3991568

E-mail: bpgoffice@wjgnet.com

Help Desk: <https://www.f6publishing.com/helpdesk>

<https://www.wjgnet.com>

