

# World Journal of *Clinical Cases*

*World J Clin Cases* 2023 July 6; 11(19): 4458-4733



## Contents

Thrice Monthly Volume 11 Number 19 July 6, 2023

### REVIEW

- 4458** Molecular signalling during cross talk between gut brain axis regulation and progression of irritable bowel syndrome: A comprehensive review  
*Singh SV, Ganguly R, Jaiswal K, Yadav AK, Kumar R, Pandey AK*
- 4477** Diffusion tensor imaging in the courtroom: Distinction between scientific specificity and legally admissible evidence  
*van Velkinburgh JC, Herbst MD, Casper SM*

### MINIREVIEWS

- 4498** Inequity in the global distribution of monkeypox vaccines  
*Tovani-Palone MR, Doshi N, Pedersini P*
- 4504** Long-term effectiveness, outcomes and complications of bariatric surgery  
*Gulinac M, Miteva DG, Peshevska-Sekulovska M, Novakov IP, Antovic S, Peruhova M, Snegarova V, Kabakchieva P, Assyov Y, Vasilev G, Sekulovski M, Lazova S, Tomov L, Velikova T*

### ORIGINAL ARTICLE

#### Retrospective Cohort Study

- 4513** Age, blood tests and comorbidities and AIMS65 risk scores outperform Glasgow-Blatchford and pre-endoscopic Rockall score in patients with upper gastrointestinal bleeding  
*Morarasu BC, Sorodoc V, Haisan A, Morarasu S, Bologa C, Haliga RE, Lionte C, Marciuc EA, Elsiddig M, Cimpoesu D, Dimofte GM, Sorodoc L*

#### Retrospective Study

- 4531** Application of cross-migration theory in limb rehabilitation of stroke patients with hemiplegia  
*Lu YH, Fu Y, Shu J, Yan LY, Shen HJ*
- 4544** Analysis of characteristic features in ultrasound diagnosis of fetal limb body wall complex during 11-13<sup>+</sup> weeks  
*Ye CH, Li S, Ling L*
- 4553** Network pharmacology and molecular docking-based analyses to predict the potential mechanism of Huangqin decoction in treating colorectal cancer  
*Li YJ, Tang DX, Yan HT, Yang B, Yang Z, Long FX*
- 4567** Assessment of functional prognosis of anterior cruciate ligament reconstruction in athletes based on a body shape index  
*Wang YJ, Zhang JC, Zhang YZ, Liu YH*

**EVIDENCE-BASED MEDICINE**

- 4579** Network pharmacology and molecular docking to explore Polygoni Cuspidati Rhizoma et Radix treatment for acute lung injury

*Zheng JL, Wang X, Song Z, Zhou P, Zhang GJ, Diao JJ, Han CE, Jia GY, Zhou X, Zhang BQ*

**ORIGINAL ARTICLE****Randomized Controlled Trial**

- 4601** Ulinastatin in the treatment of severe acute pancreatitis: A single-center randomized controlled trial

*Wang SQ, Jiao W, Zhang J, Zhang JF, Tao YN, Jiang Q, Yu F*

- 4612** Fecal microbiota transplantation in patients with metabolic syndrome and obesity: A randomized controlled trial

*da Ponte Neto AM, Clemente ACO, Rosa PW, Ribeiro IB, Funari MP, Nunes GC, Moreira L, Sparvoli LG, Cortez R, Taddei CR, Mancini MC, de Moura EGH*

**SYSTEMATIC REVIEWS**

- 4625** Combined medial patellofemoral ligament and medial patellotibial ligament reconstruction in recurrent patellar instability: A systematic review and meta-analysis

*Abbaszadeh A, Saeedi M, Hoveidaei AH, Dadgostar H, Razi S, Razi M*

**CASE REPORT**

- 4635** Unique Roberts syndrome with bilateral congenital glaucoma: A case report

*Almulhim A, Almoallem B, Alsirrhay E, Osman EA*

- 4640** CK5/6-positive, P63-positive lymphoepithelioma-like hepatocellular carcinoma: A case report and literature review

*Tang HT, Lin W, Zhang WQ, Qian JL, Li K, He K*

- 4648** Edaravone administration and its potential association with a new clinical syndrome in cerebral infarction patients: Three case reports

*Yang L, Xu X, Wang L, Zeng KB, Wang XF*

- 4655** CDKN1C gene mutation causing familial Silver-Russell syndrome: A case report and review of literature

*Li J, Chen LN, He HL*

- 4664** Hypothetical hypoxia-driven rapid disease progression in hepatocellular carcinoma post transarterial chemoembolization: A case report

*Yeo KF, Ker A, Kao PE, Wang CC*

- 4670** Metastatic colon cancer treated using traditional Chinese medicine combined with chemotherapy: A case report

*Deng CG, Tang MY, Pan X, Liu ZH*

- 4677** Rare cause of cerebral venous sinus thrombosis: Spontaneous intracranial hypotension syndrome: A case report

*Huang P*

- 4684** Integrated Chinese and Western medicine in the treatment of a patient with podocyte infolding glomerulopathy: A case report  
*Chang MY, Zhang Y, Li MX, Xuan F*
- 4692** Morbihan disease misdiagnosed as senile blepharoptosis and successfully treated with short-term minocycline and ketotifen: A case report  
*Na J, Wu Y*
- 4698** With two episodes of right retromandibular angle subcutaneous emphysema during right upper molar crown preparation: A case report  
*Bai YP, Sha JJ, Chai CC, Sun HP*
- 4707** Poststroke rehabilitation using repetitive transcranial magnetic stimulation during pregnancy: A case report  
*Jo J, Kim H*
- 4713** Tuberculosis-induced aplastic crisis and atypical lymphocyte expansion in advanced myelodysplastic syndrome: A case report and review of literature  
*Sun XY, Yang XD, Xu J, Xiu NN, Ju B, Zhao XC*
- 4723** Posterior reversible encephalopathy syndrome following uneventful clipping of an unruptured intracranial aneurysm: A case report  
*Hwang J, Cho WH, Cha SH, Ko JK*

**ACADEMIC WRITING**

- 4729** Revitalizing case reports: Standardized guidelines and mentorship  
*Jeyaraman M, Ramasubramanian S, Jeyaraman N, Nallakumarasamy A, Sharma S*

**ABOUT COVER**

Editorial Board Member of *World Journal of Clinical Cases*, Miroslav Vujasinovic, MD, PhD, Associate Professor, Department of Upper Abdominal Diseases, Karolinska University Hospital, Stockholm 14186, Sweden. mvujas@gmail.com

**AIMS AND SCOPE**

The primary aim of *World Journal of Clinical Cases* (WJCC, *World J Clin Cases*) is to provide scholars and readers from various fields of clinical medicine with a platform to publish high-quality clinical research articles and communicate their research findings online.

WJCC mainly publishes articles reporting research results and findings obtained in the field of clinical medicine and covering a wide range of topics, including case control studies, retrospective cohort studies, retrospective studies, clinical trials studies, observational studies, prospective studies, randomized controlled trials, randomized clinical trials, systematic reviews, meta-analysis, and case reports.

**INDEXING/ABSTRACTING**

The WJCC is now abstracted and indexed in Science Citation Index Expanded (SCIE, also known as SciSearch®), Journal Citation Reports/Science Edition, Current Contents®/Clinical Medicine, PubMed, PubMed Central, Reference Citation Analysis, China National Knowledge Infrastructure, China Science and Technology Journal Database, and Superstar Journals Database. The 2023 Edition of Journal Citation Reports® cites the 2022 impact factor (IF) for WJCC as 1.1; IF without journal self cites: 1.1; 5-year IF: 1.3; Journal Citation Indicator: 0.26; Ranking: 133 among 167 journals in medicine, general and internal; and Quartile category: Q4.

**RESPONSIBLE EDITORS FOR THIS ISSUE**

Production Editor: Si Zhao; Production Department Director: Xiang Li; Editorial Office Director: Jin-Lei Wang.

**NAME OF JOURNAL**

*World Journal of Clinical Cases*

**ISSN**

ISSN 2307-8960 (online)

**LAUNCH DATE**

April 16, 2013

**FREQUENCY**

Thrice Monthly

**EDITORS-IN-CHIEF**

Bao-Gan Peng, Jerzy Tadeusz Chudek, George Kontogeorgos, Maurizio Serati, Ja Hyeon Ku

**EDITORIAL BOARD MEMBERS**

<https://www.wjgnet.com/2307-8960/editorialboard.htm>

**PUBLICATION DATE**

July 6, 2023

**COPYRIGHT**

© 2023 Baishideng Publishing Group Inc

**INSTRUCTIONS TO AUTHORS**

<https://www.wjgnet.com/bpg/gerinfo/204>

**GUIDELINES FOR ETHICS DOCUMENTS**

<https://www.wjgnet.com/bpg/GerInfo/287>

**GUIDELINES FOR NON-NATIVE SPEAKERS OF ENGLISH**

<https://www.wjgnet.com/bpg/gerinfo/240>

**PUBLICATION ETHICS**

<https://www.wjgnet.com/bpg/GerInfo/288>

**PUBLICATION MISCONDUCT**

<https://www.wjgnet.com/bpg/gerinfo/208>

**ARTICLE PROCESSING CHARGE**

<https://www.wjgnet.com/bpg/gerinfo/242>

**STEPS FOR SUBMITTING MANUSCRIPTS**

<https://www.wjgnet.com/bpg/GerInfo/239>

**ONLINE SUBMISSION**

<https://www.f6publishing.com>



# Morbihan disease misdiagnosed as senile blepharoptosis and successfully treated with short-term minocycline and ketotifen: A case report

Jun Na, Yan Wu

**Specialty type:** Dermatology

**Provenance and peer review:**

Unsolicited article; Externally peer reviewed.

**Peer-review model:** Single blind

**Peer-review report's scientific quality classification**

Grade A (Excellent): 0  
Grade B (Very good): B  
Grade C (Good): C  
Grade D (Fair): 0  
Grade E (Poor): 0

**P-Reviewer:** Alkhatib AJ, Jordan; Emran TB, Bangladesh

**Received:** March 13, 2023

**Peer-review started:** March 13, 2023

**First decision:** May 19, 2023

**Revised:** May 31, 2023

**Accepted:** June 14, 2023

**Article in press:** June 14, 2023

**Published online:** July 6, 2023



**Jun Na, Yan Wu,** Department of Dermatology, Peking University First Hospital, Beijing 100034, China

**Corresponding author:** Yan Wu, MD, Chief Physician, Department of Dermatology, Peking University First Hospital, No. 8 Xishiku Street, Xicheng District, Beijing, China. [3437477565@qq.com](mailto:3437477565@qq.com)

## Abstract

### BACKGROUND

Morbihan disease is a rare skin condition with diagnostic and therapeutic challenges. Facial nonpitting erythematous edema is usually considered to be a characteristic manifestation and diagnostic clue for the Morbihan disease. Treatment of Morbihan disease remains a dilemma due to its long course, poor response, and high recurrence rate.

### CASE SUMMARY

We report the case of a 69-year-old man with Morbihan disease. The patient presented ptosis as the first and main symptom. There was no obvious edema or other skin lesions. The patient was misdiagnosed with senile blepharoptosis based on eyelid performance and no treatment was administered to him. After continuous progressive asthenia of eye-opening and ptosis for more than one year, a skin biopsy was recommended. Histopathological analysis showed edema in the dermis, lymphatic hyperplasia and dilatation, and perivascular lymphocytic infiltration. An obvious increase in toluidine blue-stained mast cells was observed. The patient was finally diagnosed with Morbihan disease. Minocycline and ketotifen were prescribed based on the increase of mast cells in skin tissue slices. The patient experienced rapid relief seven days later and complete remission after 40 d from the commencement of the treatment.

### CONCLUSION

Ptosis without obvious swelling could be the only or main clinical manifestation of Morbihan disease in rare conditions. An increase of mast cells was an important therapeutic clue to the rapid and remarkable efficiency of the combination therapy of minocycline and antihistamine.

**Key Words:** Morbihan disease; Ptosis; Minocycline; Mast cells; Treatment; Case report

**Core Tip:** Morbihan disease is a rare skin disease that is mainly characterized by nonpitting erythematous edema on the upper two-thirds of the face. We report an atypical case of progressive blepharoptosis without obvious edema, as a reminder of the existence of this uncommon condition to dermatologists, neurologists, and ophthalmologists to reduce chances of misdiagnosis. Usually long-term minocycline is used to treat Morbihan disease but has uncertain efficacy. We successfully treated our patient with a combination of minocycline and ketotifen. We also summarized previous reports on the use of minocycline in Morbihan disease and noted that mast cells might be key histological predictors of the treatment response to minocycline.

**Citation:** Na J, Wu Y. Morbihan disease misdiagnosed as senile blepharoptosis and successfully treated with short-term minocycline and ketotifen: A case report. *World J Clin Cases* 2023; 11(19): 4692-4697

**URL:** <https://www.wjgnet.com/2307-8960/full/v11/i19/4692.htm>

**DOI:** <https://dx.doi.org/10.12998/wjcc.v11.i19.4692>

## INTRODUCTION

So far, less than 100 cases of Morbihan disease have been reported. The clinical manifestation of this rare disease has not been fully described. Based on the limited available reports, Morbihan disease classically occurs in middle-aged to elderly males, with chronic persistent nonpitting erythematous edema on the upper two-thirds of the face being the main diagnostic clue in most cases[1]. Ptosis has rarely been considered as a hint of Morbihan disease unless accompanied by extreme periocular swelling[2]. However, diagnosis is more difficult for the atypical cases without obvious edema. The treatment of Morbihan disease also remains controversial. Therapeutic strategies that include drugs, laser, and surgical techniques have been used for Morbihan disease but these often end in long courses and unsatisfactory efficacy[3]. More evidence is urgently needed for the diagnosis and treatment of this disease. Here, we report a special case of Morbihan disease with misleading ptosis and without obvious erythematous edema in a 69-year-old man who was successfully treated with short-term minocycline combined with ketotifen.

## CASE PRESENTATION

### Chief complaints

A 69-year-old man presented to our Department of Dermatology with progressive asthenia of eye-opening and ptosis for more than one year.

### History of present illness

Ptosis for over one year was the only complaint that the patient presented. There were no obvious lesions on periocular skin or other areas of the face. The patient denied the existence of discomfort such as itching, swelling, or pain. He attended the Neurological Department and Ophthalmology Department frequently with no significant positive changes in his condition. Initial considerations of neurogenic and myogenic ptosis, for example, oculomotor paralysis, myasthenia gravis, and hyperthyroid ophthalmomyopathy, were excluded after a series of examinations including neuroelectromyography, neostigmine test, myasthenia gravis-related antibodies, thyroid function, and cranio-cerebral imaging. The patient was diagnosed with senile blepharoptosis, and he refused treatment. However, his ptosis aggravated so a skin biopsy was finally recommended.

### History of past illness

The patient reported well-controlled diabetes and hypertension. He denied other systemic diseases or any history of dermatoses such as rosacea, acne, erysipelas, contact dermatitis, angioedema, and skin lupus erythematosus. The patient also denied preceding periocular rash, trauma, surgery, or self-conscious swelling.

### Personal and family history

The patient denied bad personal habits and genetic diseases in his family. However, he reported that his father had similar progressive ptosis but did not attend a hospital for diagnosis and treatment before his death.



### Physical examination

Upon physical examination, moderate bilateral blepharoptosis was observed without obvious edema, erythema, papules, or masses on his face (Figure 1A). Further careful examination of the periocular and upper facial skin led to the observation of shallow glabellar wrinkles and obvious infiltration by touch. It was important to note that erythematous lesions were inspired for the first time after the skin biopsy of the upper eyelid and forehead (Figure 1B).

### Laboratory examinations

No abnormalities were observed after routine examination of the blood, liver and kidney function, and electrolyte levels. Antinuclear antibody, anti-DNA antibody, anti-ENA antibody, muscle enzymes, and immunoglobulin E (IgE) tests were all negative. There were no obvious abnormalities from neuroelectromyography, neostigmine test, myasthenia gravis-related antibodies, and thyroid function. Upper eyelid and forehead histopathological results showed manifestations such as edema in dermis, lymphatic hyperplasia and dilatation, as well as perivascular lymphocytic infiltration (Figure 2A). Toluidine blue-stained mast cells increased with a mean number of over five in each high-power field (Figure 2B).

### Imaging examinations

There were no significant abnormalities in craniocerebral imaging.

## FINAL DIAGNOSIS

By combining the typical pathological features with the less conspicuous skin manifestations, which included infiltration by touch, together with subsequent erythema and slight edema induced by biopsy, the patient was diagnosed with Morbihan disease. Given the less typical clinical appearance, differential diseases that could cause periorbital edema were considered, and these included blepharochalasis syndrome, angioedema, contact dermatitis, dermatomyositis, lupus erythematosus and Melkersson-Rosenthal Syndrome. However, the patient's inconsistent history (*e.g.* onset age, persistent course, no allergen exposure, no wheals, normal muscle strength, no tongue fissures or facial nerve defects) and associated examinations (*e.g.* normal eosinophils, IgE, muscle enzymes, autoantibodies, unsupported pathological findings) eliminated the possibility of these differential diseases.

## TREATMENT

The patient was treated with a combination therapy of oral minocycline at 100 mg/d and oral ketotifen at 1 mg/d. His ptosis was rapidly relieved and forehead wrinkles also deepened seven days later (Figure 1B), accompanied by progressive gradual improvement in the condition, overall (Figure 1C).

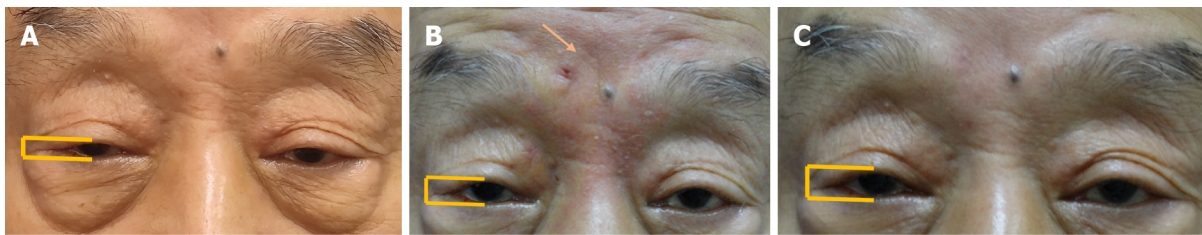
## OUTCOME AND FOLLOW-UP

Bilateral ptosis improved and the eyelids reassumed the pre-disease state. The administration of the drugs was stopped 40 days after the commencement of the treatment. No recurrence of the signs and symptoms was observed during a six-month follow-up period.

## DISCUSSION

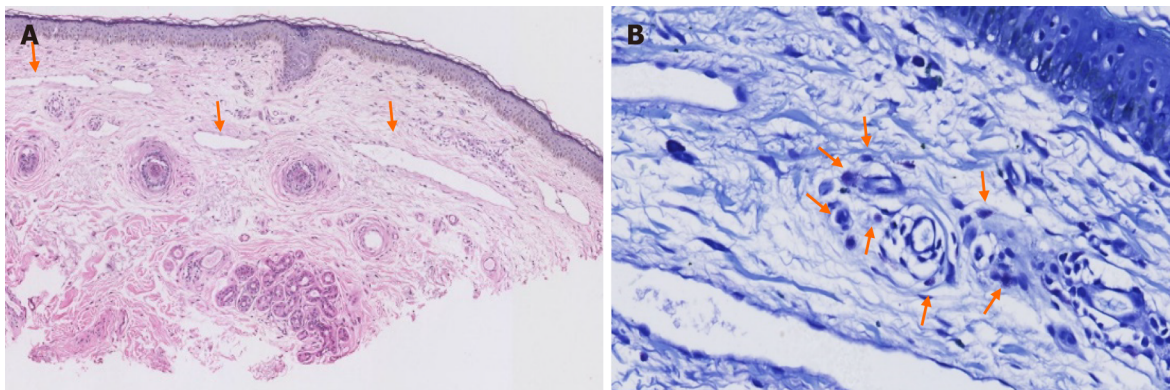
Morbihan disease, also known as rosacea lymphedema or solid persistent facial edema, is a rare entity and few cases have previously been reported. The precise diagnosis of Morbihan disease remains a challenge in clinical practice. Eyelids are most frequently involved, followed by the forehead, nose and cheeks[4]. Swelling can be found in almost all previous periocular Morbihan disease cases as the typical feature. There have been no reports of Morbihan disease with ptosis as the first or only manifestation. When ptosis exists without obvious edema, it is more likely to be overlooked and mislead ophthalmologists, neurologists and dermatologists to confused directions. Skin inflammation can also cause ptosis, which is attributed to transient dysfunction of aponeurosis or levator palpebrae. This dysfunction may be due to inflammatory cell infiltration or edema-induced mechanical weight increase[5]. The inflammatory ptosis should be considered as a diagnostic prompt in our atypical case. The histopathological features of Morbihan disease include dermal edema, lymphatic hyperplasia and dilatation, perivascular infiltration of lymphocytes, perifollicular fibrosis and occasionally perilymphatic or intralymphatic epithelioid cell granulomas[6]. The infiltration of increased mast cells was a histological feature in our





DOI: 10.12998/wjcc.v11.i19.4692 Copyright ©The Author(s) 2023.

**Figure 1 Clinical manifestations of the patient before and after treatment.** A: Initial clinical presentation. Moderate ptosis (yellow lines), suspected edema inside bilateral upper eyelids and shallow glabellar wrinkles were observed; B: Seven days after treatment of minocycline and ketotifen. Erythema (yellow arrow) triggered by biopsy and obvious improvement of ptosis and deepened glabellar wrinkles; C: 40 days after treatment of minocycline and ketotifen. The bilateral eyelids basically recovered to the pre-illness state.



DOI: 10.12998/wjcc.v11.i19.4692 Copyright ©The Author(s) 2023.

**Figure 2 Biopsy specimen from patient's upper eyelid.** A: Hematoxylin-eosin staining (×40) showing edema and dilated lymphatics in dermis (orange arrows). B: Increased infiltration of mast cell (orange arrows) in toluidine blue (×400).

patient. Activation of mast cells in Morbihan disease[7-9] can promote vasodilation, edema, and lymphocytic infiltration in the dermis. In addition, mast cells are a key mediator of cutaneous pathogenic fibrosis. These changes are associated with injury and obstruction of lymphatics, ultimately triggering dermal lymphedema and inflammatory ptosis when occurring in eyelids[10].

The treatment of Morbihan disease remains a dilemma with no recognized guidelines[11,12]. Corticosteroids, antihistamines, antibiotics, isotretinoin, and combination regimens have been used but these are long-term and are associated with unsatisfactory outcomes. Carbon dioxide laser blepharoplasty and surgical eyelid debulking[1,13] are other treatment options that are employed when drugs are ineffective. However, recurrence is common when these interventions are used, especially in patients with obvious inflammatory cell infiltration. Minocycline has been used in twelve patients with Morbihan disease in previous English language reports (Table 1), mainly as an oral monotherapy, but only six of twelve patients achieved significant improvement to variable extents. The histopathological features might guide and predict the therapeutic effects of various interventions. The positive effects of minocycline were associated with the presence of mast cells (4/6). The patients without mast cell infiltration failed in treatment with minocycline even at high doses or with long-term administration, except one patient who was infected with increased *Demodex* mites and was administered minocycline combined with topical metronidazole[14]. This suggested that mast cells might be a histological therapeutic clue for Morbihan disease. The anti-mast cell activities of minocycline indicate their significant role in the treatment of Morbihan disease[15]. Tetracycline can inhibit cytokine production of mast cells *in vitro*[8], and minocycline has been shown to inhibit IgE responses and mast cell mediated cutaneous edema[16]. However, treatment with minocycline often requires a long period of four to six months, which inevitably exposes the liver to toxicity issues. In our patient, a seven-day rapid response was observed, and a 40-d short course was achieved when minocycline was combined with ketotifen. Ketotifen is a strong mast cell stabilizer that is used in many allergic diseases. It can inhibit mast cell degranulation during the early stages of inflammation. It suppresses pathological edema and fibrosis by reducing the release of inflammatory factors IgE, tumor necrosis factor- $\alpha$ , interleukin (IL)-4, and IL-13 [17,18]. The success of the combination therapy of minocycline and ketotifen in our patient may be a good option that reduces the duration of antibiotic administration, especially in the early stages of the disease.

**Table 1 Use of minocycline and its effects in Morbihan disease**

| Sex/age (yr) | Clinical features   | Mast cell | Dose               | Course         | Effect   |
|--------------|---|-----------|--------------------|----------------|--|
| M/51[10]     | Erythema and edema on left upper eyelid with complete left ptosis                       | -         | N/A                | N/A            | Ineffective  |
| M/70[6]      | Erythematous edema on forehead, nose and periorbital areas                              | -         | 200 mg/d, 300 mg/d | Over 2 mo      | Ineffective  |
| M/54[12]     | Erythema and edema on cheek and periorbital area  | -         | N/A                | 6 to 7 mo      | Ineffective  |
| M/30[13]     | Edema on bilateral eyelids  | -         | 100 mg/d, 50 mg/d  | 7 mo           | Discontinued due to insignificant improvement and abnormal liver enzyme levels |
| M/74[7]      | Swelling on right cheek and left upper eyelid   | +         | 50 mg/d, 100 mg/d  | 4 mo           | Partially effective  |
| F/64[15]     | Swelling on entire face   | +         | 100 mg/d           | 6 mo           | Significantly effective  |
| M/38[18]     | Periorbital indurated edema   | +         | N/A                | 3 mo           | Ineffective  |
| M/56[8]      | Swelling on both eyelids and cheeks   | +         | 100 mg/d           | 7 mo           | Effective but discontinued due to abnormal liver enzyme levels                 |
| F/41[4]      | Erythematous edema on upper eyelids, forehead, nose and cheeks                          | +         | N/A                | N/A            | Effective  |
| F/40[11]     | Bilateral periorbital edema and intermittent blurry vision                              | -         | N/A                | A short period | Discontinued due to urticaria  |
| N/A/88[1]    | Swelling on left eyelid   | N/A       | N/A                | N/A            | Partially improved   |
| M/28[14]     | Edema and erythema on periorbital region, nose and cheeks; telangiectasias and pustules | -         | 100 mg/d           | Over 2 mo      | Partially improved   |

F: Female; M: Male; N/A: Not applicable.

## CONCLUSION

Morbihan disease with blepharoptosis as the only or main manifestation rather than facial edema has not been previously reported. This rare condition provided supplementary clinical manifestation and diagnostic clues of Morbihan disease for physicians in dermatology, neurology, and ophthalmology. There is no exact effective treatment strategy for Morbihan disease. However, histopathology is an important reference for the selection of treatment strategies. Based on literature review and the successful treatment of our patient, minocycline combined with antihistamines should be the prior treatment choice in Morbihan disease with increased mast cells.

## ACKNOWLEDGEMENTS

We are very grateful to the patient for agreeing to publish of case details.

## FOOTNOTES

**Author contributions:** Jun Na contributed to manuscript writing and editing, and data collection; Yan Wu contributed to conceptualization and supervision; all authors have read and approved the final manuscript.

**Informed consent statement:** Informed written consent was obtained from the patient for publication of this report and any accompanying images.

**Conflict-of-interest statement:** The authors declare that they have no conflict of interest to disclose.

**CARE Checklist (2016) statement:** The authors have read the CARE Checklist (2016), and the manuscript was prepared and revised according to the CARE Checklist (2016).

**Open-Access:** This article is an open-access article that was selected by an in-house editor and fully peer-reviewed by external reviewers. It is distributed in accordance with the Creative Commons Attribution NonCommercial (CC BY-NC 4.0) license, which permits others to distribute, remix, adapt, build upon this work non-commercially, and license

their derivative works on different terms, provided the original work is properly cited and the use is non-commercial. See: <https://creativecommons.org/licenses/by-nc/4.0/>

Country/Territory of origin: China

ORCID number: Jun Na 0000000200359545; Yan Wu 000900003582653X.

S-Editor: Ma YJ

L-Editor: A

P-Editor: Ma YJ

## REFERENCES

- 1 Yvon C, Mudhar HS, Fayers T, Siah WF, Malhotra R, Currie Z, Tan J, Rajak S. Morbihan Syndrome, a UK Case Series. *Ophthalmic Plast Reconstr Surg* 2020; **36**: 438-443 [PMID: 31990896 DOI: 10.1097/IOP.0000000000001589]
- 2 Kim JE, Sim CY, Park AY, Hong SA, Park YL, Jang SY, Lee SY. Case Series of Morbihan Disease (Extreme Eyelid Oedema Associated with Rosacea): Diagnostic and Therapeutic Approaches. *Ann Dermatol* 2019; **31**: 196-200 [PMID: 33911568 DOI: 10.5021/ad.2019.31.2.196]
- 3 Kim JH. Treatment of Morbihan disease. *Arch Craniofac Surg* 2021; **22**: 131-134 [PMID: 34225403 DOI: 10.7181/acfs.2021.00185]
- 4 Ramirez-Bellver JL, Pérez-González YC, Chen KR, Díaz-Recuero JL, Requena L, Carlson JA, Llamas-Velasco M. Clinicopathological and Immunohistochemical Study of 14 Cases of Morbihan Disease: An Insight Into Its Pathogenesis. *Am J Dermatopathol* 2019; **41**: 701-710 [PMID: 31567295 DOI: 10.1097/DAD.0000000000001378]
- 5 Koursh DM, Modjtahedi SP, Selva D, Leibovitch I. The blepharochalasis syndrome. *Surv Ophthalmol* 2009; **54**: 235-244 [PMID: 19298902 DOI: 10.1016/j.survophthal.2008.12.005]
- 6 Nagasaka T, Koyama T, Matsumura K, Chen KR. Persistent lymphoedema in Morbihan disease: formation of perilymphatic epithelioid cell granulomas as a possible pathogenesis. *Clin Exp Dermatol* 2008; **33**: 764-767 [PMID: 18627384 DOI: 10.1111/j.1365-2230.2008.02892.x]
- 7 Fujimoto N, Mitsuru M, Tanaka T. Successful treatment of Morbihan disease with long-term minocycline and its association with mast cell infiltration. *Acta Derm Venereol* 2015; **95**: 368-369 [PMID: 25510871 DOI: 10.2340/00015555-1954]
- 8 Okubo A, Takahashi K, Akasaka T, Amano H. Four cases of Morbihan disease successfully treated with doxycycline. *J Dermatol* 2017; **44**: 713-716 [PMID: 28150340 DOI: 10.1111/1346-8138.13756]
- 9 Ludgate M, Baker G. Unlocking the immunological mechanisms of orbital inflammation in thyroid eye disease. *Clin Exp Immunol* 2002; **127**: 193-198 [PMID: 11876739 DOI: 10.1046/j.1365-2249.2002.01792.x]
- 10 Lai TF, Leibovitch I, James C, Huilgol SC, Selva D. Rosacea lymphoedema of the eyelid. *Acta Ophthalmol Scand* 2004; **82**: 765-767 [PMID: 15606479 DOI: 10.1111/j.1600-0420.2004.00335.x]
- 11 Boparai RS, Levin AM, Lelli GJ Jr. Morbihan Disease Treatment: Two Case Reports and a Systematic Literature Review. *Ophthalmic Plast Reconstr Surg* 2019; **35**: 126-132 [PMID: 30252748 DOI: 10.1097/IOP.0000000000001229]
- 12 Hu SW, Robinson M, Meehan SA, Cohen DE. Morbihan disease. *Dermatol Online J* 2012; **18**: 27 [PMID: 23286817]
- 13 Kou K, Chin K, Matsukura S, Sasaki T, Nozawa A, Aihara M, Kambara T. Morbihan disease and extrafacial lupus miliaris disseminatus facie: a case report. *Ann Saudi Med* 2014; **34**: 351-353 [PMID: 25811210 DOI: 10.5144/0256-4947.2014.351]
- 14 Rizzo A, Fiorani D, Lazzeri L, Taddeucci P, Rubegni P, Flori ML, Russo F. Usefulness of *in vivo* reflectance confocal microscopy in Morbihan syndrome. *Skin Res Technol* 2021; **27**: 974-976 [PMID: 33455034 DOI: 10.1111/srt.13002]
- 15 Kabuto M, Fujimoto N, Honda S, Tanaka T. Successful treatment with long-term use of minocycline for Morbihan disease showing mast cell infiltration: A second case report. *J Dermatol* 2015; **42**: 827-828 [PMID: 25917342 DOI: 10.1111/1346-8138.12908]
- 16 Joks R, Durkin HG. Non-antibiotic properties of tetracyclines as anti-allergy and asthma drugs. *Pharmacol Res* 2011; **64**: 602-609 [PMID: 21501686 DOI: 10.1016/j.phrs.2011.04.001]
- 17 Yuan W, Hou S, Jia H, Qiu Z, Liu T, Chen X, Li H, Sun Y, Liang L, Sui X, Zhao X, Zhao Z. Ketotifen fumarate attenuates feline gingivitis related with gingival microenvironment modulation. *Int Immunopharmacol* 2018; **65**: 159-173 [PMID: 30316074 DOI: 10.1016/j.intimp.2018.10.006]
- 18 Rebello PR, Rezende CM, Battaglin ER, Lima BZ, Fillus Neto J. Syndrome in question. *An Bras Dermatol* 2015; **90**: 909-911 [PMID: 26734879 DOI: 10.1590/abd1806-4841.20153818]



Published by **Baishideng Publishing Group Inc**  
7041 Koll Center Parkway, Suite 160, Pleasanton, CA 94566, USA

**Telephone:** +1-925-3991568

**E-mail:** [bpgoffice@wjgnet.com](mailto:bpgoffice@wjgnet.com)

**Help Desk:** <https://www.f6publishing.com/helpdesk>

<https://www.wjgnet.com>

