

# World Journal of *Clinical Cases*

*World J Clin Cases* 2023 August 16; 11(23): 5416-5627



## REVIEW

- 5416 Recent progress in understanding mitokines as diagnostic and therapeutic targets in hepatocellular carcinoma

Wang J, Luo LZ, Liang DM, Guo C, Huang ZH, Jian XH, Wen J

## ORIGINAL ARTICLE

## Retrospective Cohort Study

- 5430 Clinical characteristics and risk factors of intracranial hemorrhage after spinal surgery

Yan X, Yan LR, Ma ZG, Jiang M, Gao Y, Pang Y, Wang WW, Qin ZH, Han YT, You XF, Ruan W, Wang Q

## Retrospective Study

- 5440 Application effect of phloroglucinol injection in elderly patients with spastic abdominal pain in emergency department

Liu YF, Chen J

- 5447 Efficacy and prognosis of adjuvant treatment of endometrial cancer with medroxyprogesterone acetate COX regression analysis

Wang DR

- 5455 Serum vascular endothelial growth factor and cortisol expression to predict prognosis of patients with hypertensive cerebral hemorrhage

Zhang CY, Wang B, Hua XT, Fan K, Li YF

- 5462 Progress of ulcerative colitis patients during the COVID-19 pandemic

Suda T, Takahashi M, Katayama Y, Soga K, Kobori I, Kusano Y, Tamano M

## Observational Study

- 5468 Effect of vitamin supplementation on polycystic ovary syndrome and key pathways implicated in its development: A Mendelian randomization study

Shen JY, Xu L, Ding Y, Wu XY

## Prospective Study

- 5479 Evaluation of childhood developing *via* optical coherence tomography-angiography in Qamdo, Tibet, China: A prospective cross-sectional, school-based study

Sun KX, Xiang YG, Zhang T, Yi SL, Xia JY, Yang X, Zheng SJ, Ji Y, Wan WJ, Hu K

## SYSTEMATIC REVIEWS

- 5494 Isolated left ventricular apical hypoplasia: Systematic review and analysis of the 37 cases reported so far

Bassareo PP, Duignan S, James A, Dunne E, McMahon CJ, Walsh KP

## META-ANALYSIS

- 5504 Identification of key genes and biological pathways in lung adenocarcinoma by integrated bioinformatics analysis

Zhang L, Liu Y, Zhuang JG, Guo J, Li YT, Dong Y, Song G

## CASE REPORT

- 5519 Clinical outcomes of robotic-assisted and manual total hip arthroplasty in the same patient: A case report  
Hu TY, Lin DC, Zhou YJ, Zhang ZW, Yuan JJ
- 5525 Emphysematous sloughed floating ball after prostate water vaporization Rezum: A case report  
Alnazari M, Bakhsh A, Rajih ES
- 5530 Imaged guided surgery during arteriovenous malformation of gastrointestinal stromal tumor using hyperspectral and indocyanine green visualization techniques: A case report  
Wagner T, Mustafov O, Hummels M, Grabenkamp A, Thomas MN, Schiffmann LM, Bruns CJ, Stippel DL, Wahba R
- 5538 Membranous nephropathy with systemic light-chain amyloidosis of remission after rituximab therapy: A case report  
Zhang J, Wang X, Zou GM, Li JY, Li WG
- 5547 Rhabdomyolysis-induced acute kidney injury after administration of a red yeast rice supplement: A case report  
Wang YH, Zhang SS, Li HT, Zhi HW, Wu HY
- 5554 Jackstone in the renal calyx: A rare case report  
Song HF, Liang L, Liu YB, Xiao B, Hu WG, Li JX
- 5559 Critical respiratory failure due to pregnancy complicated by COVID-19 and bacterial coinfection: A case report  
Zhou S, Liu MH, Deng XP
- 5567 Townes-Brooks syndrome with adult renal impairment in a Chinese family: A case report  
Wu J, Zhang J, Xiao TL, He T
- 5573 Nasopharyngeal carcinoma with synchronous breast metastasis: A case report  
Lei YY, Li DM
- 5580 Anti-melanoma differentiation-associated gene 5 and anti-Ro52 antibody-dual positive dermatomyositis accompanied by rapidly lung disease: Three case reports  
Ye WZ, Peng SS, Hu YH, Fang MP, Xiao Y
- 5589 Anaphylactic shock induced by polyethylene glycol after bowel preparation for the colorectal cancer surgery: A case report  
Park GW, Park N, Kuk JC, Shin EJ, Lim DR
- 5595 Knee locking caused by osteochondroma of the proximal tibia adjacent to the pes anserinus: A case report  
Sonobe T, Hakoziaki M, Matsuo Y, Takahashi Y, Yoshida K, Konno S

- 5602** Complex inferior vena cava reconstruction during *ex vivo* liver resection and autotransplantation: A case report  
*Humaerhan J, Jiang TM, Aji T, Shao YM, Wen H*
- 5610** Hemocholecyst caused by accidental injury associated with radiofrequency ablation for hepatocellular carcinoma: A case report  
*Tan YW, Zhang XY*
- 5615** Pancreatic cavernous hemangioma complicated with chronic intracapsular spontaneous hemorrhage: A case report and review of literature  
*Li T*
- 5622** Pyogenic liver abscess secondary to gastric perforation of an ingested toothpick: A case report  
*Park Y, Han HS, Yoon YS, Cho JY, Lee B, Kang M, Kim J, Lee HW*

**ABOUT COVER**

Editorial Board Member of *World Journal of Clinical Cases*, Ellis J Neufeld, MD, PhD, Chief Physician, Executive Vice President, Professor, Department of Hematology, St. Jude Children's Research Hospital, Memphis, TN 38105, United States. ellis.neufeld@stjude.org

**AIMS AND SCOPE**

The primary aim of *World Journal of Clinical Cases* (WJCC, *World J Clin Cases*) is to provide scholars and readers from various fields of clinical medicine with a platform to publish high-quality clinical research articles and communicate their research findings online.

WJCC mainly publishes articles reporting research results and findings obtained in the field of clinical medicine and covering a wide range of topics, including case control studies, retrospective cohort studies, retrospective studies, clinical trials studies, observational studies, prospective studies, randomized controlled trials, randomized clinical trials, systematic reviews, meta-analysis, and case reports.

**INDEXING/ABSTRACTING**

The WJCC is now abstracted and indexed in Science Citation Index Expanded (SCIE, also known as SciSearch®), Journal Citation Reports/Science Edition, Current Contents®/Clinical Medicine, PubMed, PubMed Central, Reference Citation Analysis, China National Knowledge Infrastructure, China Science and Technology Journal Database, and Superstar Journals Database. The 2023 Edition of Journal Citation Reports® cites the 2022 impact factor (IF) for WJCC as 1.1; IF without journal self cites: 1.1; 5-year IF: 1.3; Journal Citation Indicator: 0.26; Ranking: 133 among 167 journals in medicine, general and internal; and Quartile category: Q4.

**RESPONSIBLE EDITORS FOR THIS ISSUE**

Production Editor: Hua-Ge Yin; Production Department Director: Xiang Li; Editorial Office Director: Jin-Lei Wang.

**NAME OF JOURNAL**

*World Journal of Clinical Cases*

**ISSN**

ISSN 2307-8960 (online)

**LAUNCH DATE**

April 16, 2013

**FREQUENCY**

Thrice Monthly

**EDITORS-IN-CHIEF**

Bao-Gan Peng, Jerzy Tadeusz Chudek, George Kontogeorgos, Maurizio Serati, Ja Hyeon Ku

**EDITORIAL BOARD MEMBERS**

<https://www.wjgnet.com/2307-8960/editorialboard.htm>

**PUBLICATION DATE**

August 16, 2023

**COPYRIGHT**

© 2023 Baishideng Publishing Group Inc

**INSTRUCTIONS TO AUTHORS**

<https://www.wjgnet.com/bpg/gerinfo/204>

**GUIDELINES FOR ETHICS DOCUMENTS**

<https://www.wjgnet.com/bpg/GerInfo/287>

**GUIDELINES FOR NON-NATIVE SPEAKERS OF ENGLISH**

<https://www.wjgnet.com/bpg/gerinfo/240>

**PUBLICATION ETHICS**

<https://www.wjgnet.com/bpg/GerInfo/288>

**PUBLICATION MISCONDUCT**

<https://www.wjgnet.com/bpg/gerinfo/208>

**ARTICLE PROCESSING CHARGE**

<https://www.wjgnet.com/bpg/gerinfo/242>

**STEPS FOR SUBMITTING MANUSCRIPTS**

<https://www.wjgnet.com/bpg/GerInfo/239>

**ONLINE SUBMISSION**

<https://www.f6publishing.com>





## Emphysematous sloughed floating ball after prostate water vaporization Rezūm: A case report

Mansour Alnazari, Abdulaziz Bakhsh, Emad Sabri Rajih

**Specialty type:** Urology and nephrology

**Provenance and peer review:** Unsolicited article; Externally peer reviewed.

**Peer-review model:** Single blind

**Peer-review report's scientific quality classification**

Grade A (Excellent): 0  
Grade B (Very good): 0  
Grade C (Good): 0  
Grade D (Fair): 0  
Grade E (Poor): 0

**P-Reviewer:** Ichihara K, Japan

**Received:** March 19, 2023

**Peer-review started:** March 19, 2023

**First decision:** June 15, 2023

**Revised:** June 23, 2023

**Accepted:** July 19, 2023

**Article in press:** July 19, 2023

**Published online:** August 16, 2023



**Mansour Alnazari, Abdulaziz Bakhsh, Emad Sabri Rajih**, Department of Urology, Taibah University, Madinah 16655, Al Madinah, Saudi Arabia

**Emad Sabri Rajih**, Urology Section, Department of Surgery, King Faisal Specialist Hospital & Research Center, Madinah, Saudi Arabia

**Corresponding author:** Emad Sabri Rajih, MBBS, MPH, Associate Professor, Surgeon, Department of Urology, College of Medicine, Taibah University, Al Madinah, Saudi Arabia. [remad@taibahu.edu.sa](mailto:remad@taibahu.edu.sa)

### Abstract

#### BACKGROUND

Rezūm™ water vapor therapy is a new minimally invasive endoscopic technology for the management and treatment of benign prostatic hyperplasia.

#### CASE SUMMARY

A 63-year-old male presented to our department with severe dysuria, frequency, urgency, and interrupted stream 2 mo after receiving Rezūm™ therapy. The symptoms were caused by a retained floating emphysematous necrotic sloughed tissue. We also discovered a persistent bacterial infection that was resistant to parenteral antimicrobial therapy. The treatment of the patient included surgical removal of the necrotic tissue.

#### CONCLUSION

Despite the good safety profile and minimal adverse events related to Rezūm™ therapy, major complications can still occur.

**Key Words:** Benign prostatic hyperplasia; Rezūm; Lower urinary tract symptoms; Minimally invasive therapy; Water vapor therapy; Transurethral resection of the prostate; Case report

©The Author(s) 2023. Published by Baishideng Publishing Group Inc. All rights reserved.

**Core Tip:** The current report describes a new finding with infected emphysematous sloughed tissue ball after Rezum therapy that is secondary to gas forming organism. It predisposed the patient post operatively to frequent urine retention and severe lower urinary tract symptoms that is refractory to antimicrobial therapy that was managed successfully by endoscopic removal.

**Citation:** Alnazari M, Bakhsh A, Rajih ES. Emphysematous sloughed floating ball after prostate water vaporization Rezum: A case report. *World J Clin Cases* 2023; 11(23): 5525-5529

**URL:** <https://www.wjgnet.com/2307-8960/full/v11/i23/5525.htm>

**DOI:** <https://dx.doi.org/10.12998/wjcc.v11.i23.5525>

## INTRODUCTION

Benign prostatic hyperplasia (BPH) is one of the most common conditions affecting males that leads to lower urinary tract symptoms (LUTS). LUTS includes urgency, nocturia, frequency, weak urinary stream, intermittency, incomplete emptying of the bladder, and in some cases retention of urine[1,2]. BPH is first managed with lifestyle changes and drug therapy. Surgical management is indicated when symptoms are not relieved after lifestyle changes and drug therapy or if the patient is unable to take medications[3]. Transurethral resection of the prostate (TURP) has been the gold standard surgical option for patients with a prostate size less than 80 mL. TURP results in significant improvement of LUTS, urinary flow rate, and quality of life[4].

Over the last 10 years several minimally invasive methods have been introduced to the market. One of these techniques is called Rezūm™ water vapor therapy. This water vapor ablation technology generates thermal energy *via* radiofrequency delivered to prostatic tissue by sterile water injections. This causes immediate cell necrosis, leading to significant improvement of LUTS while preserving ejaculatory and sexual function[5]. Rezūm™ typically has mild and transient postoperative complications. However, rare major postoperative events have been reported including encapsulated hematoma, bladder neck contracture, bladder stone, sexual dysfunction, and urinary retention[6,7]. In the current report, we present a new complication that arose after Rezūm™ therapy and was successfully managed.

## CASE PRESENTATION

### Chief complaints

A 63-year-old male presented with severe urinary frequency and urgency, interrupted stream, and dysuria. He reported a fever of 38.6°C.

### History of present illness

The patient represented a known case of BPH on medical therapy. He had presented to an outpatient clinic 2 mo prior to this presentation for acute urinary retention with preoperative prostate volume 54 mL with prostatic urethral angulation and no median lobe enlargement. The patient underwent Rezūm™ therapy with water vaporization of both lateral prostatic lobes with three waves for each lobe (9 s for each) and two vapor ablations at 5 and 7 o'clock 1 cm from bladder neck. He was given prophylactic dose of Gentamycin 240 mg intravenous preoperatively. His preoperative urine culture is negative. He did not experience any intraoperative or immediate postoperative events. He was kept on suprapubic catheter after the procedure for 14 d which is based upon the treating urological practice in the center. The patient experienced successful voiding with no residual urine on day 15 after the procedure. The patient continued his medication (alpha-blocker and 5-alpha reductase) for 2 mo following Rezūm™ therapy.

### History of past illness

The patient had a diagnosis of diabetes mellitus. It was successfully managed with oral hypoglycemic agents.

### Personal and family history

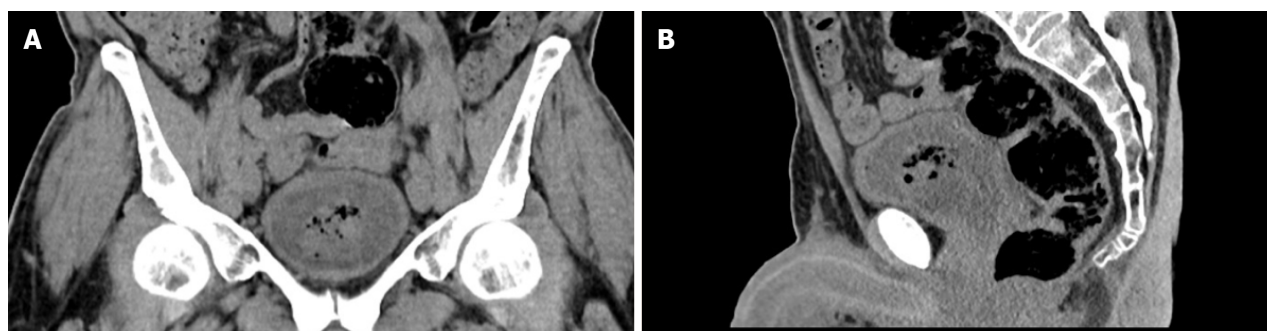
The patient had no relevant family history.

### Physical examination

Physical examination showed normal vital signs with mild tenderness in the suprapubic area. The urinary bladder was not palpable, and genital examination provided normal findings.

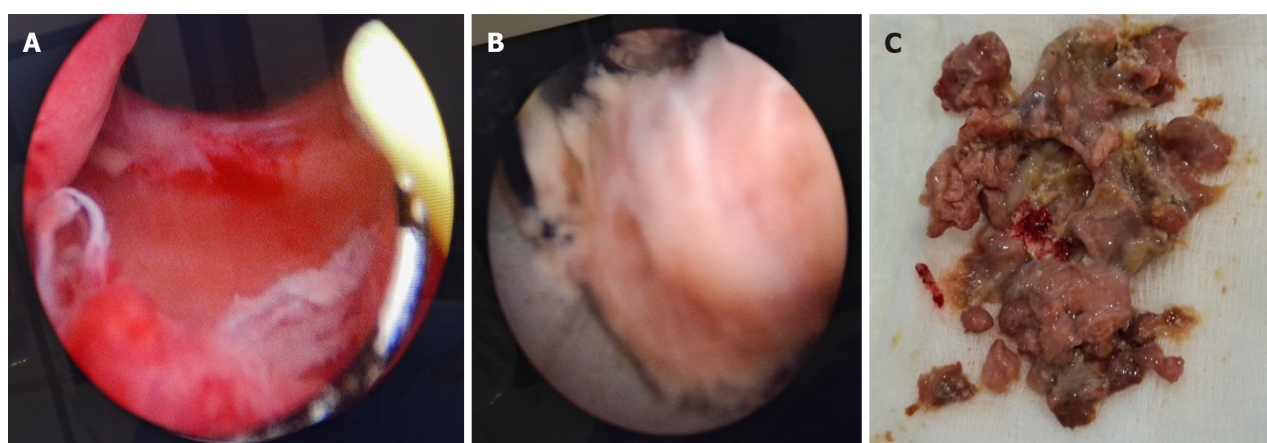
### Laboratory examinations

Urine analysis showed elevated white blood cells (22-24 cells/HPF; normal range: 0-4 cells/HPF) and normal red blood cells (2 cells/HPF). The urine analysis also showed positivity for nitrates and negativity for leukocyte esterase. We also discovered that the urine was positive for *Klebsiella* (> 100000 colony-forming units), which was sensitive to carbapenems.



DOI: 10.12998/wjcc.v11.i23.5525 Copyright ©The Author(s) 2023.

**Figure 1 Computed tomography.** An emphysematous sloughed tissue within the urinary bladder was observed. A: Front view; B: Side view.



DOI: 10.12998/wjcc.v11.i23.5525 Copyright ©The Author(s) 2023.

**Figure 2 Transurethral removal.** A: Cystoscopy revealed a wide, unobstructed prostatic urethra; B: Cystoscopic view of sloughed Prostatic tissue post Rezum therapy, removed with the loop of a resectoscope; C: Postoperative view of the sloughed Prostatic tissue.

### Imaging examinations

Bedside ultrasound showed multiple hypoechoic gas areas within a retained soft tissue in the urinary bladder. Computed tomography of the kidney, ureter, and bladder was performed. It confirmed the presence of retained soft tissue within the urinary bladder with multiple air pockets. The urinary bladder wall was intact (Figure 1).

## FINAL DIAGNOSIS

Complicated urinary tract infection; acute bacterial cystitis.

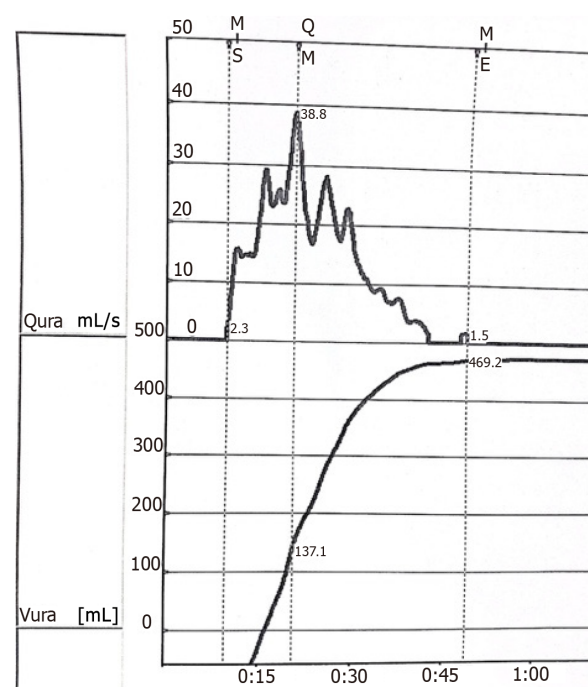
## TREATMENT

The patient received intravenous ertapenem (1 g) daily in the peripheral primary health care center outside country as an outpatient till he was admitted to the treating center. A urethral catheter was inserted. Cystoscopy and necrotic tissue evacuation were performed under general anesthesia 3 d after presentation. Cystoscopy revealed a wide prostatic urethra without obstruction (Figure 2A). The retained necrotic tissue (Figure 2B and C) was submitted for culture and revealed *Klebsiella* colonization. The patient completed 2 wk of intravenous antimicrobial therapy, and his symptoms resolved.

## OUTCOME AND FOLLOW-UP

At the 1-mo follow-up (3 mo after Rezūm™ therapy), the patient reported retrograde ejaculation. However, he voided successfully without LUTS. His International Prostate Symptom Score was 2, indicating mild symptoms. The prostate size decreased from 54 mL to 7 mL. Pre-void urine volume was 335 mL, and post-void residual urine was 0 mL. His uroflowmetry showed a maximum flow rate of 38 mL/s, voiding time of 39 s, and voided volume of 599 mL (Figure 3).





DOI: 10.12998/wjcc.v11.i23.5525 Copyright ©The Author(s) 2023.

Average flow rate	15.9	mL/s
Maximum flow rate	38.8	mL/s
Flow at 2 seconds	14.7	mL/s
Acceleration	3.6	mL/s <sup>2</sup>
Time to max flow	0: 10.8	min: s
Total volume	599.6	mL
Flow time	0: 33.8	min: s
Voiding time	0: 39.0	min: s
Voiding delay	0: 9.6	min: s

Figure 3 Uroflowmetry after removal of sloughed prostatic tissue.

The International Prostate Symptoms Index Score postoperatively is 3 (mild symptoms) with Quality-of-Life QoL from urinary symptoms is equal 0 (Delighted).

## DISCUSSION

Rezūm™ therapy represents a new minimally invasive technique for the treatment of BPH. It is safe, has a quick patient recovery and low complication rate, and preserves sexual and ejaculatory functions. It is an attractive surgical option compared to TURP, which has been the gold standard of surgical management of BPH for decades[8]. Despite the safety of Rezūm™ therapy, several adverse events have been reported; for example, urinary tract infection is one of the most common complications following Rezūm™ therapy, with an incidence of 17% in some reports. It is unclear if the positive cultures are due true bacterial infections or LUTS with bacteriuria as a result of tissue necrosis following vaporization[9].

The current report described a new complication of infected emphysematous sloughed tissue after Rezūm™ therapy. After treatment, the patient reported frequent urine retention and severe LUTS that was refractory to antimicrobial therapy and required endoscopic removal of the tissue. This complication likely occurred when the necrotic tissue after Rezūm™ therapy was infected. The infection may have occurred from the indwelling catheter, which increased the risk of bacteriuria. Other rare adverse effects reported after Rezūm™ therapy include urinary incontinence, urethral stricture, bladder stone, retrograde ejaculation, erectile dysfunction, bladder neck contracture, urinary retention due to blood clots, and prostatic edema[9].

Previously, sloughed prostatic tissue has been reported in the literature. However, in all reported cases the sloughed tissue was attached to the prostatic bed, which is different from our report. The other cases were managed with TURP. Maqboul *et al*[10] described a large sloughed prostatic tissue floating inside the bladder following prostatic embolization, and the tissue was subsequently resected by endoscopy. In our report, the patient developed emphysematous sloughed floating prostatic tissue that has never been described before. This type of complication should be considered when a patient presents with persistent bacteriuria and LUTS after Rezūm™ therapy.

## CONCLUSION

Rezūm™ therapy is a safe and effective new technology for the management of BPH. The occurrence of complications is rare after Rezūm™ therapy. However, unexpected and unusual adverse events could occur similar to the retained emphysematous floating necrotic tissue experienced by our patient.

## FOOTNOTES

**Author contributions:** All authors contributed equally to this paper.

**Informed consent statement:** Written informed consent was obtained from the patient.

**Conflict-of-interest statement:** The authors declare having no conflicts of interest.

**CARE Checklist (2016) statement:** The authors have read the CARE Checklist (2016), and the manuscript was prepared and revised according to the CARE Checklist (2016).

**Open-Access:** This article is an open-access article that was selected by an in-house editor and fully peer-reviewed by external reviewers. It is distributed in accordance with the Creative Commons Attribution NonCommercial (CC BY-NC 4.0) license, which permits others to distribute, remix, adapt, build upon this work non-commercially, and license their derivative works on different terms, provided the original work is properly cited and the use is non-commercial. See: <https://creativecommons.org/licenses/by-nc/4.0/>

**Country/Territory of origin:** Saudi Arabia

**ORCID number:** Mansour Alnazari 0009-0000-2215-8878; Emad Sabri Rajih 0000-0002-4641-8248.

**S-Editor:** Liu JH

**L-Editor:** A

**P-Editor:** Ju JL

## REFERENCES

- 1 Lokeshwar SD, Harper BT, Webb E, Jordan A, Dykes TA, Neal DE Jr, Terris MK, Klaassen Z. Epidemiology and treatment modalities for the management of benign prostatic hyperplasia. *Transl Androl Urol* 2019; **8**: 529-539 [PMID: 31807429 DOI: 10.21037/tau.2019.10.01]
- 2 Platz EA, Smit E, Curhan GC, Nyberg LM, Giovannucci E. Prevalence of and racial/ethnic variation in lower urinary tract symptoms and noncancer prostate surgery in U.S. men. *Urology* 2002; **59**: 877-883 [PMID: 12031373 DOI: 10.1016/s0090-4295(01)01673-9]
- 3 Malde S, Lam W, Adwin Z, Hashim H. Pharmacological and interventional treatment of benign prostatic obstruction: An evidence-based comparative review. *BJUI Compass* 2021; **2**: 238-259 [PMID: 35475299 DOI: 10.1002/bco2.74]
- 4 Tanneru K, Jazayeri SB, Alam MU, Kumar J, Bazargani S, Kuntz G, Palayapalayam Ganapathi H, Bandyk M, Marino R, Koochekpour S, Gautam S, Balaji KC, Costa J. An Indirect Comparison of Newer Minimally Invasive Treatments for Benign Prostatic Hyperplasia: A Network Meta-Analysis Model. *J Endourol* 2021; **35**: 409-416 [PMID: 32962442 DOI: 10.1089/end.2020.0739]
- 5 Green Z, Westwood J, Somani BK. What's New in Rezum: a Transurethral Water Vapour Therapy for BPH. *Curr Urol Rep* 2019; **20**: 39 [PMID: 31152253 DOI: 10.1007/s11934-019-0903-7.]
- 6 McVary KT, Roehrborn CG. Three-Year Outcomes of the Prospective, Randomized Controlled Rezūm System Study: Convective Radiofrequency Thermal Therapy for Treatment of Lower Urinary Tract Symptoms Due to Benign Prostatic Hyperplasia. *Urology* 2018; **111**: 1-9 [PMID: 29122620 DOI: 10.1016/j.urol.2017.10.023]
- 7 Alothman A, Alharbi R, Alasker A, Ghazwani Y. Sloughing Prostatic Tissue, a Rare Complication Post Rezum Therapy: A Case Report. *Cureus* 2020; **12**: e11722 [PMID: 33403159 DOI: 10.7759/cureus.11722]
- 8 Rowaiee R, Akhras A, Janahi FK. Rezum therapy, a feasible and safe treatment for the larger prostate. *Int J Surg Case Rep* 2021; **82**: 105871 [PMID: 33878673 DOI: 10.1016/j.ijscr.2021.105871]
- 9 Mollengarden D, Goldberg K, Wong D, Roehrborn C. Convective radiofrequency water vapor thermal therapy for benign prostatic hyperplasia: a single office experience. *Prostate Cancer Prostatic Dis* 2018; **21**: 379-385 [PMID: 29282358 DOI: 10.1038/s41391-017-0022-9]
- 10 Maqboul F, Umranikar S. Retention by sloughed prostatic tissue: A rare complication after prostate artery embolization. *J Clin Urol* 2021; 1-4 [DOI: 10.1177/20514158211018133]



Published by **Baishideng Publishing Group Inc**  
7041 Koll Center Parkway, Suite 160, Pleasanton, CA 94566, USA

**Telephone:** +1-925-3991568

**E-mail:** [bpgoffice@wjgnet.com](mailto:bpgoffice@wjgnet.com)

**Help Desk:** <https://www.f6publishing.com/helpdesk>

<https://www.wjgnet.com>

