

World Journal of *Psychiatry*

World J Psychiatry 2023 June 19; 13(6): 262-401



OPINION REVIEW

- 262 Pharmacotherapy in autism spectrum disorders, including promising older drugs warranting trials
Hellings J

REVIEW

- 278 Operational definitions and measurement of externalizing behavior problems: An integrative review including research models and clinical diagnostic systems
Torres-Rosado L, Lozano OM, Sanchez-Garcia M, Fernández-Calderón F, Diaz-Batanero C
- 298 Psychiatrists' occupational stigma conceptualization, measurement, and intervention: A literature review
Shi XL, Li LY, Fan ZG

MINIREVIEWS

- 319 Epigenetics in psychiatry: Beyond DNA methylation
Kouter K, Šalamon Arčan I, Videtič Paska A
- 331 Psychological trauma, posttraumatic stress disorder and trauma-related depression: A mini-review
Wang SK, Feng M, Fang Y, Lv L, Sun GL, Yang SL, Guo P, Cheng SF, Qian MC, Chen HX

ORIGINAL ARTICLE**Basic Study**

- 340 Acupuncture at Back-Shu point improves insomnia by reducing inflammation and inhibiting the ERK/NF- κ B signaling pathway
Zhang MM, Zhao JW, Li ZQ, Shao J, Gao XY

Observational Study

- 351 Psychological impact of cancer scale: Turkish validity and reliability study
Bahçecioglu Turan G, Karaman S, Aksoy M
- 361 Relationship between depression, smartphone addiction, and sleep among Chinese engineering students during the COVID-19 pandemic
Gao WJ, Hu Y, Ji JL, Liu XQ
- 376 Prevalence of posttraumatic stress disorder following acute coronary syndrome and clinical characteristics of patients referred to cardiac rehabilitation
Sopek Merkaš I, Lakušić N, Sonicki Z, Koret B, Vuk Pisk S, Filipčić I
- 386 Abnormal volumetric brain morphometry and cerebral blood flow in adolescents with depression
Fu YJ, Liu X, Wang XY, Li X, Dai LQ, Ren WY, Zeng YM, Li ZL, Yu RQ

LETTER TO THE EDITOR

- 397 Digital interventions empowering mental health reconstruction among students after the COVID-19 pandemic

Liu XQ, Guo YX, Zhang XR, Zhang LX, Zhang YF

ABOUT COVER

Editorial Board Member of *World Journal of Psychiatry*, Lenin Pavón, PhD, Professor, Laboratory of Psychoimmunology, National Institute of Psychiatry, “Ramón de la Fuente”, Mexico City 14070, Mexico.
lkuriaki@gmail.com

AIMS AND SCOPE

The primary aim of *World Journal of Psychiatry (WJP, World J Psychiatry)* is to provide scholars and readers from various fields of psychiatry with a platform to publish high-quality basic and clinical research articles and communicate their research findings online.

WJP mainly publishes articles reporting research results and findings obtained in the field of psychiatry and covering a wide range of topics including adolescent psychiatry, biological psychiatry, child psychiatry, community psychiatry, ethnopsychology, psychoanalysis, psychosomatic medicine, etc.

INDEXING/ABSTRACTING

The *WJP* is now abstracted and indexed in Science Citation Index Expanded (SCIE, also known as SciSearch®), Current Contents/Clinical Medicine, Journal Citation Reports/Science Edition, PubMed, PubMed Central, Reference Citation Analysis, China National Knowledge Infrastructure, China Science and Technology Journal Database, and Superstar Journals Database. The 2022 Edition of Journal Citation Reports® cites the 2021 impact factor (IF) for *WJP* as 3.500; IF without journal self cites: 3.313; 5-year IF: 7.380; Journal Citation Indicator: 0.62; Ranking: 89 among 155 journals in psychiatry; and Quartile category: Q3.

RESPONSIBLE EDITORS FOR THIS ISSUE

Production Editor: *Yu-Xi Chen*; Production Department Director: *Xu Guo*; Editorial Office Director: *Jia-Ping Yan*.

NAME OF JOURNAL

World Journal of Psychiatry

ISSN

ISSN 2220-3206 (online)

LAUNCH DATE

December 31, 2011

FREQUENCY

Monthly

EDITORS-IN-CHIEF

Rajesh R Tampi, Ting-Shao Zhu, Panteleimon Giannakopoulos

EDITORIAL BOARD MEMBERS

<https://www.wjgnet.com/2220-3206/editorialboard.htm>

PUBLICATION DATE

June 19, 2023

COPYRIGHT

© 2023 Baishideng Publishing Group Inc

INSTRUCTIONS TO AUTHORS

<https://www.wjgnet.com/bpg/gerinfo/204>

GUIDELINES FOR ETHICS DOCUMENTS

<https://www.wjgnet.com/bpg/GerInfo/287>

GUIDELINES FOR NON-NATIVE SPEAKERS OF ENGLISH

<https://www.wjgnet.com/bpg/gerinfo/240>

PUBLICATION ETHICS

<https://www.wjgnet.com/bpg/GerInfo/288>

PUBLICATION MISCONDUCT

<https://www.wjgnet.com/bpg/gerinfo/208>

ARTICLE PROCESSING CHARGE

<https://www.wjgnet.com/bpg/gerinfo/242>

STEPS FOR SUBMITTING MANUSCRIPTS

<https://www.wjgnet.com/bpg/GerInfo/239>

ONLINE SUBMISSION

<https://www.f6publishing.com>



Observational Study

Abnormal volumetric brain morphometry and cerebral blood flow in adolescents with depression

Yu-Jia Fu, Xiao Liu, Xing-Yu Wang, Xiao Li, Lin-Qi Dai, Wen-yu Ren, Yong-Ming Zeng, Zhen-Lin Li, Ren-Qiang Yu

Specialty type: Psychiatry

Provenance and peer review:

Unsolicited article; Externally peer reviewed.

Peer-review model: Single blind

Peer-review report's scientific quality classification

Grade A (Excellent): 0

Grade B (Very good): B, B

Grade C (Good): 0

Grade D (Fair): 0

Grade E (Poor): 0

P-Reviewer: Bernstein HG, Germany; Stoyanov D, Bulgaria

Received: March 31, 2023

Peer-review started: March 31, 2023

First decision: May 9, 2023

Revised: May 15, 2023

Accepted: May 24, 2023

Article in press: May 24, 2023

Published online: June 19, 2023



Yu-Jia Fu, Xiao Liu, Xing-Yu Wang, Wen-yu Ren, Ren-Qiang Yu, Department of Radiology, the First Affiliated Hospital of Chongqing Medical University, Chongqing 400016, China

Xiao Li, Lin-Qi Dai, Department of Psychiatry, the First Affiliated Hospital of Chongqing Medical University, Chongqing 400016, China

Yong-Ming Zeng, Department of Radiology, Chongqing HongRen Yi Hospital, Chongqing 408400, China

Zhen-Lin Li, Department of Radiology, West China Hospital, Chengdu 610041, Sichuan Province, China

Corresponding author: Ren-Qiang Yu, Doctor, Doctor, Department of Radiology, the First Affiliated Hospital of Chongqing Medical University, Yixueyuan Road, Yuzhong District, Chongqing 400016, China. yurenqiang@hospital.cqmu.edu.cn

Abstract

BACKGROUND

Prior research has demonstrated that the brains of adolescents with depression exhibit distinct structural alterations. However, preliminary studies have documented the pathophysiological changes in certain brain regions, such as the cerebellum, highlighting a need for further research to support the current understanding of this disease.

AIM

To study brain changes in depressed adolescents.

METHODS

This study enrolled 34 adolescents with depression and 34 age-, sex-, and education-level-matched healthy control (HC) individuals. Structural and functional alterations were identified when comparing the brains of these two participant groups through voxel-based morphometry and cerebral blood flow (CBF) analysis, respectively. Associations between identified brain alterations and the severity of depressive symptoms were explored through Pearson correlation analyses.

RESULTS

The cerebellum, superior frontal gyrus, cingulate gyrus, pallidum, middle frontal gyrus, angular gyrus, thalamus, precentral gyrus, inferior temporal gyrus, superior temporal gyrus, inferior frontal gyrus, and supplementary motor areas of adolescents with depression showed an increase in brain volume compared to HC individuals. These patients with depression further presented with a pronounced drop in CBF in the left pallidum (group = 98, and peak $t = -4.4324$), together with increased CBF in the right precentral gyrus (PerCG) (group = 90, and peak $t = 4.5382$). In addition, 17-item Hamilton Depression Rating Scale scores were significantly correlated with the increased volume in the opercular portion of the left inferior frontal gyrus ($r = -0.5231$, $P < 0.01$).

CONCLUSION

The right PerCG showed structural and CBF changes, indicating that research on this part of the brain could offer insight into the pathophysiological causes of impaired cognition.

Key Words: Voxel-based morphometry; Cerebral blood flow; Arterial spin labeling; Adolescent; Depression; The right precentral gyrus

©The Author(s) 2023. Published by Baishideng Publishing Group Inc. All rights reserved.

Core Tip: In this study, we first combined cerebral blood flow (CBF) and voxel-based morphometry (VBM) to study brain alterations in adolescent depression. We also found that the brain function (CBF) changes were mainly in the left pallidum and right precentral gyrus. Meanwhile, we detected alterations in the cerebellum. Our finding about a wide range of brain structure (VBM) changes in adolescent depression contributes to better treatment and prevention strategies for depression.

Citation: Fu YJ, Liu X, Wang XY, Li X, Dai LQ, Ren WY, Zeng YM, Li ZL, Yu RQ. Abnormal volumetric brain morphometry and cerebral blood flow in adolescents with depression. *World J Psychiatry* 2023; 13(6): 386-396

URL: <https://www.wjgnet.com/2220-3206/full/v13/i6/386.htm>

DOI: <https://dx.doi.org/10.5498/wjp.v13.i6.386>

INTRODUCTION

Adolescents suffer from high rates of depression that contribute to adverse outcomes, including academic difficulties, substance abuse, behavioral issues, parental conflict, impaired peer interactions, and suicidality[1-3]. Depression rates are exceptionally high among children in middle school, with an incidence of up to 24.3%[4]. Clinical symptoms of depression include feelings of sadness, hopelessness, cognitive impairments, and reductions in motivation and pleasure. Overcoming depression can be particularly challenging among adolescents, with treatment failing to have any pronounced effect in 30%-50% of cases[5]. Recurrence rates are also very high[6], with most adolescents experiencing relapses multiple times in adulthood[7,8]. Adolescence is also a critical period for brain growth[9], and this disease can have a profound negative impact on such development[10]. Despite this fact, many studies have focused on the mental health of adults rather than exploring outcomes in vulnerable adolescent populations[11,12]. As a result, there is an urgent need for in-depth neurobiological research that investigates the pathophysiology of depression to develop effective treatments that can help free adolescents from the symptoms of this debilitating condition.

The results of imaging studies suggest that adolescents suffering from depression exhibit severe structural changes within their brains[13-15]. However, these reported findings have been inconsistent with some studies documenting the thinning of brain regions[16], whereas others note the thickening of certain areas[17]. These inconsistencies may result from a range of patient-specific confounding factors or pharmacological treatment effects. While cerebellar dysfunction has been documented in many disease states[18], changes in the cerebellum in depression remain overlooked mainly[19]. Recent research supports the cerebellum's function in the processing of emotion and its widely recognized role in the context of motor control[20]. Reductions in the gray matter volume in the cerebellum and anterior cerebellar vermis have been documented among adults with depression[21], and some evidence suggests the ability of cerebellar neurons to regulate depression-like behavioral development actively[22].

Given the poorly understood nature of the pathophysiological basis for depression among adolescents, efforts to detect and clarify morphological alterations associated with functional changes provide an opportunity to define these underlying pathogenic processes better. In a previous publication, we used cerebral blood flow (CBF) to assess Major Depressive Disorder(MDD) in adolescents and reported CBF alterations after treatment[22]. Voxel-based morphometry (VBM) is a

technique that is frequently applied to detect structural changes within the brain[23], allowing for the voxel-by-voxel classification of brain volumes in different regions to enable the systematic, reproducible comparison of regions among multiple individuals more effectively than the traditional region of interest (ROI)-based strategies. VBM can assess anatomical differences throughout the brain with a short execution time[23,24] and is widely used in studies of alterations in depressed brains[25-27]. Still, there are also conflicting and heterogeneous results reported by VBM and magnetic resonance imaging (MRI) whole brain analysis[16,17]. These examples encourage the further development of VBM in MDD investigations. CBF can also be detected noninvasively and quantitatively through arterial spin labeling (ASL), in which arterial blood magnetic labeling is leveraged as an endogenous tracer[28]. Investigations have utilized VBM and voxel-based pathophysiology to analyze MDD[29]. Because structural alterations are usually accompanied by functional abnormalities[30,31], we decided to extend our study approach to incorporate VBM with CBF. The current study's findings are consistent with the high repetitive rate of change obtained so far regarding depression[32-34]. The cerebellum's role in depressive symptoms was confirmed in a recent study[35], and elevated pallidum CBF was also detected in patients with mild traumatic brain injury that may lead to cognitive decline[36]. These repeats suggest a potential association between the changes we detected using VBM combined with CBF and MDD dysfunction. Accordingly, in the present study, VBM and CBF strategies were used to evaluate changes in the brains of adolescents with depression.

Regular examinations of a broader range of brain regions are required to understand the pathophysiology of depression in adolescents properly, and unmedicated young people diagnosed with first-episode depression are the perfect model for studies of disease-related brain alterations. For the present analysis, these patients were thus the primary subjects of interest in hopes of detecting previously unrecognized yet clinically significant abnormalities present in depressed adolescents that have yet to undergo pharmacological treatment. These approaches offer a promising means of exploring the pathophysiology of adolescent depression while also validating and expanding upon previously published results[37].

Through the application of VBM and CBF techniques, a series of complex structural and functional alterations were documented within the brains of adolescent patients with depression compared to a healthy control (HC) population. The cerebellum was expected to undergo alterations because of its crucial involvement in developmental processes, and depression-related structural and functional changes were anticipated to coincide in several brain regions. These were the two primary outcomes that were expected from the present research.

MATERIALS AND METHODS

Participants

From August 2020 to July 2022, adolescents with depression were recruited from the Department of Psychiatry at Chongqing Medical University's First Affiliated Hospital. The Mini International Neuropsychiatric Interview for Children and Adolescents (MINI-KID) was used by senior psychiatrists to confirm the diagnosis of depression in all cases, and symptom severity was assessed with the 17-item Hamilton Depression Rating Scale (HAMD-17). Patients eligible for study participation were individuals of Han ethnicity who were right-handed, exhibited a HAMD score ≥ 17 , had no history of antidepressant treatment, were experiencing first-episode depression, had no history of psychotropic drug use, and had no history of anesthetic or sedative, or analgesic drug use within 1 mo before the study initiation. Patients were excluded if they had a history of prior mental health conditions, including schizophrenia or bipolar disorder, a history of drug abuse or dependence, exhibited MRI contraindications, or had been diagnosed with organic brain diseases or severe physical ailments.

Participants in the HC trial were selected from age-, gender-, and education-level-matched subjects with no personal history of mental illness or psychosis among first-degree relatives. The same exclusion criteria were applied for both patients with depression and HCs. In total, 34 treatment-naïve first-episode adolescent depression patients and 34 HCs from 12-17 years of age were recruited for study participation.

The First Affiliated Hospital of Chongqing Medical University approved this study (NO. 2017-157). The legal guardians of all participants provided written informed consent, and all participants were provided with a comprehensive overview of the details of the study.

General data collection

Sociodemographic data were collected using a questionnaire regarding participant age, sex, and educational status. For the MINI-KID, the parents of eligible study participants were contacted and informed about this study, after which questionnaire and interview responses were obtained electronically. One professional interviewer conducted the interview processing, which was completed in under two days[38].

HAMD-17 surveys were administered by two psychiatrists with similar levels of training to assess symptom severity based on appropriate guidelines. Two examiners blinded to participant details independently performed all subsequent scoring to ensure the absence of subjectivity.

MRI data collection

MRI scanning was performed with a Signa 3.0 Tesla MRI instrument (GE Medical Systems, WI, United States), yielding T1-weighted, T2-weighted, and T2-fluid-attenuated inversion recovery (T2-Flair) imaging sequences. T2-Flair data were used to detect any evidence of potential brain disorders, with patients exhibiting such conditions being eliminated from further study inclusion.

Structural images were acquired with no gap using the following settings: the number of axial slices = 156, time repetition (TR) = 8.4 ms, echo time (TE) = 3.3 ms, flip angle (FA) = 12°, slice thickness = 1.0 mm, the field of view (FOV) = 240 mm × 240 mm, matrix = 240 × 240, and voxel dimension = 1 mm × 1 mm × 1 mm. Parameters used for ASL image acquisition were as follows: NEX 3, TE 9.8 ms, TR 4639 ms, FOV 240 mm × 240 mm, slice thickness 4.0 mm, post label delay time 1525 ms, 3D spiral k-space filling, points 512, arms 8, acquisition scan slices 40. During imaging, participants were directed to remain awake with their eyes closed, and foam padding was employed to restrict head movement.

Image processing

FSL-VBM was used to analyze structural images[39]. After the initial recovery of these images, they were segmented into white matter (WM), gray matter (GM), and cerebrospinal fluid regions, followed by nonlinear registration-based alignment of these images to the Montreal Neurological Institute (MNI) standard space. Native GM images were then re-registered nonlinearly to the resultant averaged images to produce a template specific to the present study. Native GM images were then registered to this template and modified as appropriate based on local contraction or expansion associated with nonlinear spatial transformation. The altered GM images were then smoothed with an isotropic Gaussian kernel with a sigma of 3 mm (FWHM = 6.9 mm) as per FSL recommendations[39].

ASL images were analyzed following the earlier reported studies[22,28].

Statistical analysis

SPSS 22.0 (IL, United States) was used to analyze all data. Data are reported as means ± SD and were compared between groups with two-way ANOVA, while comparisons between males and females were made using chi-square tests.

Analyses of GM and WM volumes included group-based comparisons of larger and smaller volumes in HC individuals relative to adolescents with depression. These analyses employed grand mean scaling and absolute threshold masking. Voxel-level GM and WM density were compared between these groups with two-sample t-tests using SPM5. Random Gaussian field theory was used to estimate significant differences among groups using a familywise error-corrected alpha of 0.05. Clusters were displayed as statistical parametric maps in standard anatomical space. Participant age, education status, and total intracranial volume were utilized as covariates when conducting two-way ANOVA analyses of smoothed CBF images, with an initial $P < 0.001$ thresholds for cluster-level false discovery rate (FDR) multiple comparison correction ($P < 0.05$). Regions of the brain affected by sex or group interactions for CBF perfusion were then acquired with the xjview software (<https://www.alivelearn.net/xjview>). Brain areas with interactive effects were selected as ROIs, and the CBF values for these ROIs were extracted using DPABI[40].

Relationships between brain alterations and depressive symptom severity were explored through Pearson correlation analyses with $P < 0.05$ as the significance threshold.

RESULTS

Participant characteristics

Table 1 provides details regarding the characteristics of the study participants. No differences in age, sex, or education level were detected between depressed adolescents and HCs ($P > 0.05$), whereas HAMD-17 scores differed significantly between these groups ($P < 0.001$).

Depression-related changes in VBM

FSL-VBM analyses exploring differences between groups highlighted increases in the volume of several regions of the brain following correction for multiple testing ($P < 0.05$), including the cerebellum, superior frontal gyrus, cingulate gyrus, pallidum, middle frontal gyrus, angular gyrus, thalamus, precentral gyrus, inferior temporal gyrus, superior temporal gyrus, inferior frontal gyrus, and supplementary motor area (Table 2, Figure 1). No regions of the brain exhibited depression-related decreases in brain volume.

Table 1 Participant demographic and clinical characteristics

Item	depressed adolescents (n = 34)	healthy controls (n = 34)	t/χ^2	P value
Gender (F/M)	23/11	23/11	0 ^a	1.00
Age (yr)	15.26 ± 0.99	15.68 ± 1.77	- 1.18 ^b	0.24
Education (yr)	10.06 ± 1.98	10.44 ± 1.97	- 0.80 ^b	0.43
HAMD-17	26.12 ± 4.43	1.03 ± 1.70	30.84 ^b	< 0.001

^a χ^2 test.^bTwo sample *t*-test.

The values are illustrated as mean ± SD. F: Female; M: Male; HAMD-17: 17-item Hamilton Depression Rating Scale.

Table 2 Whole-brain group statistics for healthy controls and adolescents with depression

Brain sub-region	Peak (MNI)			Number of voxels	P value (FWE corrected)
	X	Y	Z		
HCs > depressed adolescents					
Cerebellum_6_L	73	64	56	973	0
Frontal_sup_medial_L	81	16292	101106	925	0.01
Cingulum_mid_R	103	120	67	221	0.02
Pallidum_R	113	-6	49	211	0.02
Cingulum_mid_L	-4	168	92	146	0.04
Frontal_mid_L	67	70	118	113	0.03
Angular_R	119	116	92	88	0.03
Thalamus_L	85	136	102	74	0.03
Precentral_R	151	134	27	57	0.04
Temporal_inf_R	127	142	46	55	0.04
Temporal_Pole_Sup_L	61	130	98	42	0.04
Frontal- Inf_Oper_L	51	66	105	25	0.04
Occipital_Mid_L	63	126	148	24	0.04
Supp_Motor_Area_L	79	88	52	14	0.04
Cerebellum_3_R	101			13	0.04

HCs: Healthy controls; MNI: Montreal Neurological Institute; FWE: Family wise error.

Depression-related changes in CBF

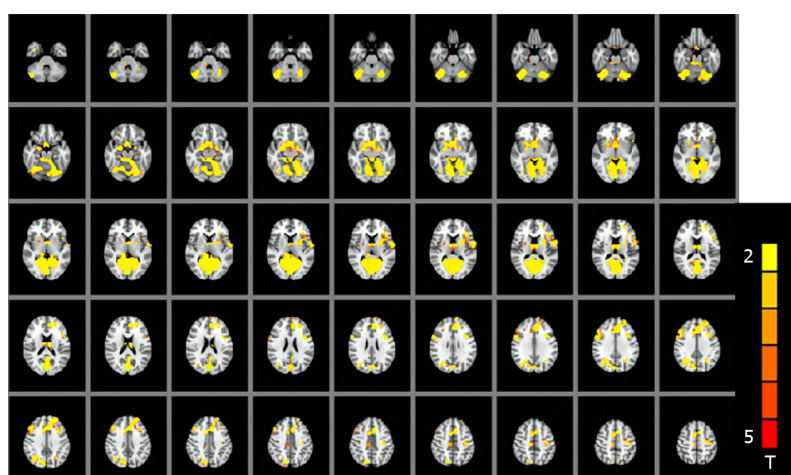
Adolescents with depression exhibited pronounced decreases in CBF in the left pallidum as compared to HCs (group = 98, and peak $t = -4.4324$), together with an increase in the right percental gyrus (PerCG) (group = 90, and peak $t = 4.5382$) (Figure 2). This analysis was performed using a cluster cut-off *P*-value < 0.001.

Correlations between brain alterations and depression severity

In patients with depression, HAMD-17 scores were significantly correlated with the increased volume of the opercular part of the left inferior frontal gyrus (IFG) ($r = -0.5231$, $P < 0.01$). No correlations were detected between HAMD-17 scores and other changes in brain volume or CBF ($P > 0.05$).

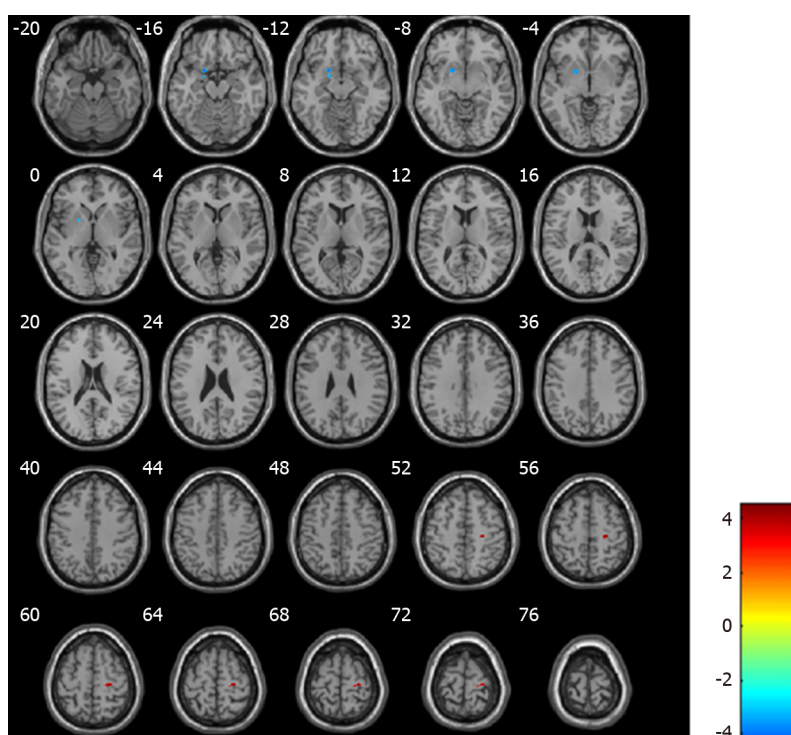
DISCUSSION

The current findings showed that, in contrast to HCs, treatment-naïve first-episode depression in adolescents is associated with CBF and brain volume modifications. Notably, increased volume of many



DOI: 10.5498/wjpv.13.i6.386 Copyright ©The Author(s) 2023.

Figure 1 Two-sample tests comparing healthy controls and adolescents with depression based on a whole-brain mask.



DOI: 10.5498/wjpv.13.i6.386 Copyright ©The Author(s) 2023.

Figure 2 Differences in cerebral blood flow when comparing healthy controls and adolescents with depression. Blue and red indicate reductions and increases in cerebral blood flow, respectively.

brain regions was observed in adolescent depression patients, with increased CBF in the PerCG and decreased CBF in the left pallidum. HAMD-17 scores in these patients were also negatively correlated with the volume of the opercular portion of the left IFG. In particular, decreases in both volume and CBF were observed in the right PerCG, suggesting that this region may be an important area for future research to understand the pathophysiological bases of depression.

The PreCG regulates primary motor behaviors and has been reported to exhibit alterations in individuals with movement-related disorders, including amyotrophic lateral sclerosis[41] and akinetic-rigid Parkinson's disease[42]. Increased PreCG CBF is correlated with increased reaction time[43], pure apraxia of speech and other forms of impaired verbal fluency[44], and autism[45]. Several studies suggest a relationship between PreCG and emotion[46]. Depression can impair neural plasticity in the motor cortex, contributing to behavioral and cognitive alterations in affected patients[47]. Pathological alterations in the PreCG may thus be functionally linked to depression. An increase in PreCG GM volume has been reported[48,49], with the present results confirming these prior reports and

highlighting a link between these changes and altered CBF.

The left IFG plays a crucial role in the functional and structural brain network that underlies language in neurocognitive models of language perception[50]. The opercular portion of the left IFG is a crucial node connected to multiple cerebellar, cortical, and subcortical structures within the language network [51]. In the present study, adolescents with depression exhibited a correlation between HAM-D-17 scores and the volume of this opercular portion of the left IFG, consistent with its potential association with depression severity.

The cerebellum is thought to be closely related to movement, with additional experimental evidence highlighting its association with attention and motor systems[52], as well as with cognition[53]. This link could explain depression-related symptoms, such as cognitive impairment, disinterest, and poor attention. Adolescent depression may affect the cerebellum, contributing to frequent episodes in adulthood. However, it is essential to highlight that the reported increase in the cerebellum in the present study contradicts other published studies in which cerebellar volume was shown to be reduced [54,55]. These differences may be attributable to variations in disease severity, assessment methodology, diagnoses, or treatment approaches.

Other regions exhibiting abnormal findings included the cingulate gyrus, an essential component of the pathophysiological basis for depression related to the makeup of the default mode network[56]. In clinical research, cingulate gyrus abnormalities have been reported in various psychiatric disorders[57]. Altered WM connectivity in adolescent depression patients has also been described[58], contributing to reduced default mode network connectivity closely related to depression incidence[59-61].

There are various drawbacks to this study. Firstly, the number of participants was relatively small, partly due to parental reservations about fMRI examinations. Secondly, the effects of resting state physiological noise derived from the heart and respiratory rhythms cannot be eliminated from these analyses. Lastly, this cross-sectional analysis could not detect disease progression-related changes in brain morphological characteristics, underscoring a need for future longitudinal research with multiple follow-up visits per patient to monitor better such changes and how they respond to treatment.

CONCLUSION

In summary, the present results demonstrate that adolescent depression patients exhibited various structural changes in the brain and altered CBF in the left pallidum and right PerCG. Considering the finding that the right PerCG demonstrated structural and CBF changes associated with depression in these adolescent subjects, research on the right PerCG may provide fresh perspectives on the pathophysiology of this devastating psychological disorder. This identification of novel evidence regarding changes in the cerebellum and other brain areas provides robust imaging evidence supporting the hypothesis that these regions are involved in cognition and disease-related pathogenesis. The future application of these findings has the potential to guide the better prevention and treatment of depression among adolescents.

ARTICLE HIGHLIGHTS

Research background

The prevalence of depression in adolescents is high and research is scarce. Therefore, it is urgent to investigate depressed adolescents.

Research motivation

In-depth neurobiological studies investigating the pathophysiology of depression are urgently needed to develop effective treatments to help adolescents escape the symptoms of this debilitating illness. Several studies have documented the role of the cerebellum in psychiatric disorders, which is rarely mentioned in the imaging of depression, emphasizing the need for further research on the depressed brain.

Research objectives

We aimed to detect structural and functional changes in depressed adolescents. These changes may be relevant to better prevention and treatment of adolescent depression. We found that adolescents with depression exhibit various structural changes in the brain and alter cerebral blood flow in the left syphilitic spiral and right percent gyrus.

Research methods

This study recruited 34 adolescents with depression and 34 matched healthy control (HC) individuals. Voxel-based morphometry (VBM) discovers structural changes in the brain; Cerebral blood flow (CBF)

explore functional changes in the brain; 17-item Hamilton Depression Rating Scale (HAMD-17) measures depression; *t*-test assess statistical differences.

Research results

We found that patients with adolescent depression exhibit various structural changes in the brain and altered CBF in the left pallidum and right percental gyrus. These findings may provide new insights into the pathophysiology of this disruptive psychological disorder and provide strong imaging evidence to support the hypothesis that these regions are involved in cognition and disease-related pathogenesis. Future applications of these findings have the potential to guide better prevention and treatment of depression in adolescents.

Research conclusions

New theory: Our study provides imaging evidence that supports the hypothesis that cerebellum is involved in cognition and disease-related pathogenesis. New method: We first combined VBM and CBF to examine the brains of depressed adolescents.

Research perspectives

Incorporating imaging data into the diagnosis of psychiatric disorders.

FOOTNOTES

Author contributions: Fu YJ and Liu X contributed to writing the original draft; Fu YJ and Liu X contributed to the work equally; Liu X, Wang XY, and Ren WY contributed to scanning magnetic resonance imaging data; Liu X analyzed the data; Li X and Dai LQ contributed to investigation; Zeng YM and Li ZL contributed to conceptualization and checking the data; Yu RQ contributed to methodology, and writing – review, and editing; All authors contributed to the article and approved the submitted version.

Supported by The Project of Scientific Research and Innovative Experiment for College Students in Chongqing Medical University, No. 202215; and the Provincial Project of University Students Innovation and Entrepreneurship Training Program, No. 202210631015.

Institutional review board statement: The study was reviewed and approved by the First Affiliated Hospital of Chongqing Medical University Institutional Review Board, No. 20214801.

Informed consent statement: The legal guardians of all participants provided written informed consent, and all participants were provided with a comprehensive overview of the details of the study.

Conflict-of-interest statement: All the authors report no relevant conflicts of interest for this article.

Data sharing statement: Technical appendix, statistical code, and dataset available from the corresponding author at yurenqiang@hospital.cqmu.edu.cn. Participants gave informed consent for data sharing.

Open-Access: This article is an open-access article that was selected by an in-house editor and fully peer-reviewed by external reviewers. It is distributed in accordance with the Creative Commons Attribution NonCommercial (CC BY-NC 4.0) license, which permits others to distribute, remix, adapt, build upon this work non-commercially, and license their derivative works on different terms, provided the original work is properly cited and the use is non-commercial. See: <https://creativecommons.org/licenses/by-nc/4.0/>

Country/Territory of origin: China

ORCID number: Yu-Jia Fu 0009-0006-7006-6859; Ren-Qiang Yu 0000-0002-3756-450X.

S-Editor: Li L

L-Editor: A

P-Editor: Li L

REFERENCES

- 1 Hauenstein EJ. Depression in adolescence. *J Obstet Gynecol Neonatal Nurs* 2003; **32**: 239-248 [PMID: 12685676 DOI: 10.1177/0884217503252133]
- 2 Frankish H, Boyce N, Horton R. Mental health for all: a global goal. *Lancet* 2018; **392**: 1493-1494 [PMID: 30314858 DOI: 10.1016/S0140-6736(18)32271-2]
- 3 Stringaris A, Vidal-Ribas P. Probing the Irritability-Suicidality Nexus. *J Am Acad Child Adolesc Psychiatry* 2019; **58**: 18-

- 19 [PMID: [30577933](#) DOI: [10.1016/j.jaac.2018.08.014](#)]
- 4 **Tang X**, Tang S, Ren Z, Wong DFK. Prevalence of depressive symptoms among adolescents in secondary school in mainland China: A systematic review and meta-analysis. *J Affect Disord* 2019; **245**: 498-507 [PMID: [30439677](#) DOI: [10.1016/j.jad.2018.11.043](#)]
- 5 **Liu FF**, Adrian MC. Is Treatment Working? Detecting Real Change in the Treatment of Child and Adolescent Depression. *J Am Acad Child Adolesc Psychiatry* 2019; **58**: 1157-1164 [PMID: [30825497](#) DOI: [10.1016/j.jaac.2019.02.011](#)]
- 6 **Thapar A**, Collishaw S, Pine DS, Thapar AK. Depression in adolescence. *Lancet* 2012; **379**: 1056-1067 [PMID: [22305766](#) DOI: [10.1016/S0140-6736\(11\)60871-4](#)]
- 7 **Clayborne ZM**, Varin M, Colman I. Systematic Review and Meta-Analysis: Adolescent Depression and Long-Term Psychosocial Outcomes. *J Am Acad Child Adolesc Psychiatry* 2019; **58**: 72-79 [PMID: [30577941](#) DOI: [10.1016/j.jaac.2018.07.896](#)]
- 8 **Johnson D**, Dupuis G, Piche J, Clayborne Z, Colman I. Adult mental health outcomes of adolescent depression: A systematic review. *Depress Anxiety* 2018; **35**: 700-716 [PMID: [29878410](#) DOI: [10.1002/da.22777](#)]
- 9 **Fuhrmann D**, Knoll LJ, Blakemore SJ. Adolescence as a Sensitive Period of Brain Development. *Trends Cogn Sci* 2015; **19**: 558-566 [PMID: [26419496](#) DOI: [10.1016/j.tics.2015.07.008](#)]
- 10 **Sacchet MD**, Ho TC, Connolly CG, Tymofiyeva O, Lewinn KZ, Han LK, Blom EH, Tapert SF, Max JE, Frank GK, Paulus MP, Simmons AN, Gotlib IH, Yang TT. Large-Scale Hypoconnectivity Between Resting-State Functional Networks in Unmedicated Adolescent Major Depressive Disorder. *Neuropsychopharmacology* 2016; **41**: 2951-2960 [PMID: [27238621](#) DOI: [10.1038/npp.2016.76](#)]
- 11 **Rice F**, Eyre O, Riglin L, Potter R. Adolescent depression and the treatment gap. *Lancet Psychiatry* 2017; **4**: 86-87 [PMID: [28087200](#) DOI: [10.1016/S2215-0366\(17\)30004-4](#)]
- 12 **Coles ME**, Ravid A, Gibb B, George-Denn D, Bronstein LR, McLeod S. Adolescent Mental Health Literacy: Young People's Knowledge of Depression and Social Anxiety Disorder. *J Adolesc Health* 2016; **58**: 57-62 [PMID: [26707229](#) DOI: [10.1016/j.jadohealth.2015.09.017](#)]
- 13 **Pagliaccio D**, Alqueza KL, Marsh R, Auerbach RP. Brain Volume Abnormalities in Youth at High Risk for Depression: Adolescent Brain and Cognitive Development Study. *J Am Acad Child Adolesc Psychiatry* 2020; **59**: 1178-1188 [PMID: [31634568](#) DOI: [10.1016/j.jaac.2019.09.032](#)]
- 14 **Redlich R**, Opel N, Bürger C, Dohm K, Grotegerd D, Förster K, Zaremba D, Meinert S, Reppe J, Enneking V, Leehr E, Böhnlein J, Winters L, Froböse N, Thrun S, Emtmann J, Heindel W, Kugel H, Arolt V, Romer G, Postert C, Dannlowski U. The Limbic System in Youth Depression: Brain Structural and Functional Alterations in Adolescent In-patients with Severe Depression. *Neuropsychopharmacology* 2018; **43**: 546-554 [PMID: [29039414](#) DOI: [10.1038/npp.2017.246](#)]
- 15 **Wu B**, Li X, Zhou J, Zhang M, Long Q. Altered Whole-Brain Functional Networks in Drug-Naïve, First-Episode Adolescents With Major Depression Disorder. *J Magn Reson Imaging* 2020; **52**: 1790-1798 [PMID: [32618061](#) DOI: [10.1002/jmri.27270](#)]
- 16 **Fan S**, Lippard ETC, Sankar A, Wallace A, Johnston JAY, Wang F, Pittman B, Spencer L, Oquendo MA, Blumberg HP. Gray and white matter differences in adolescents and young adults with prior suicide attempts across bipolar and major depressive disorders. *J Affect Disord* 2019; **245**: 1089-1097 [PMID: [30699851](#) DOI: [10.1016/j.jad.2018.11.095](#)]
- 17 **Straub J**, Brown R, Malejko K, Bonenberger M, Grön G, Plener PL, Abler B. Adolescent depression and brain development: evidence from voxel-based morphometry. *J Psychiatry Neurosci* 2019; **44**: 237-245 [PMID: [30720261](#) DOI: [10.1503/jpn.170233](#)]
- 18 **Stoodley CJ**. The Cerebellum and Neurodevelopmental Disorders. *Cerebellum* 2016; **15**: 34-37 [PMID: [26298473](#) DOI: [10.1007/s12311-015-0715-3](#)]
- 19 **Konarski JZ**, McIntyre RS, Grupp LA, Kennedy SH. Is the cerebellum relevant in the circuitry of neuropsychiatric disorders? *J Psychiatry Neurosci* 2005; **30**: 178-186 [PMID: [15944742](#)]
- 20 **Huang M**, de Koning TJ, Tijssen MAJ, Verbeek DS. Cross-disease analysis of depression, ataxia and dystonia highlights a role for synaptic plasticity and the cerebellum in the pathophysiology of these comorbid diseases. *Biochim Biophys Acta Mol Basis Dis* 2021; **1867**: 165976 [PMID: [33011198](#) DOI: [10.1016/j.bbadis.2020.165976](#)]
- 21 **Arnone D**, Job D, Selvaraj S, Abe O, Amico F, Cheng Y, Colloby SJ, O'Brien JT, Frodl T, Gotlib IH, Ham BJ, Kim MJ, Koolschijn PC, Périco CA, Salvatore G, Thomas AJ, Van Tol MJ, van der Wee NJ, Veltman DJ, Wagner G, McIntosh AM. Computational meta-analysis of statistical parametric maps in major depression. *Hum Brain Mapp* 2016; **37**: 1393-1404 [PMID: [26854015](#) DOI: [10.1002/hbm.23108](#)]
- 22 **Yu RQ**, Zhang ZJ, Chen RS, Wang XY, Li X, Dai LQ, Li ZL. Electroconvulsive therapy-induced neuroimaging alterations measured by cerebral blood flow in adolescents with major depressive disorder. *J Affect Disord* 2023; **327**: 385-390 [PMID: [36758871](#) DOI: [10.1016/j.jad.2023.02.027](#)]
- 23 **Ashburner J**, Friston KJ. Voxel-based morphometry--the methods. *Neuroimage* 2000; **11**: 805-821 [PMID: [10860804](#) DOI: [10.1006/nimg.2000.0582](#)]
- 24 **Matsuda H**. MRI morphometry in Alzheimer's disease. *Ageing Res Rev* 2016; **30**: 17-24 [PMID: [26812213](#) DOI: [10.1016/j.arr.2016.01.003](#)]
- 25 **Serra-Blasco M**, Radua J, Soriano-Mas C, Gómez-Benlloch A, Porta-Casteràs D, Carulla-Roig M, Albajes-Eizaguirre A, Arnone D, Klauser P, Canales-Rodríguez EJ, Hilbert K, Wise T, Cheng Y, Kandilarova S, Mataix-Cols D, Vieta E, Via E, Cardoner N. Structural brain correlates in major depression, anxiety disorders and post-traumatic stress disorder: A voxel-based morphometry meta-analysis. *Neurosci Biobehav Rev* 2021; **129**: 269-281 [PMID: [34256069](#) DOI: [10.1016/j.neubiorev.2021.07.002](#)]
- 26 **Zhao W**, Zhang X, Zhou X, Song X, Zhang Z, Xu L, Zhou F, Kendrick KM. Depression mediates the association between insula-frontal functional connectivity and social interaction anxiety. *Hum Brain Mapp* 2022; **43**: 4266-4273 [PMID: [35596617](#) DOI: [10.1002/hbm.25952](#)]
- 27 **Du M**, Liu J, Chen Z, Huang X, Li J, Kuang W, Yang Y, Zhang W, Zhou D, Bi F, Kendrick KM, Gong Q. Brain grey matter volume alterations in late-life depression. *J Psychiatry Neurosci* 2014; **39**: 397-406 [PMID: [24949867](#) DOI: [10.1503/jpn.130275](#)]

- 28 **Xiong Y**, Chen RS, Wang XY, Li X, Dai LQ, Yu RQ. Cerebral blood flow in adolescents with drug-naïve, first-episode major depressive disorder: An arterial spin labeling study based on voxel-level whole-brain analysis. *Front Neurosci* 2022; **16**: 966087 [PMID: 35968369 DOI: 10.3389/fnins.2022.966087]
- 29 **Gray JP**, Müller VI, Eickhoff SB, Fox PT. Multimodal Abnormalities of Brain Structure and Function in Major Depressive Disorder: A Meta-Analysis of Neuroimaging Studies. *Am J Psychiatry* 2020; **177**: 422-434 [PMID: 32098488 DOI: 10.1176/appi.ajp.2019.19050560]
- 30 **Albajara Sáenz A**, Villemonteix T, Massat I. Structural and functional neuroimaging in attention-deficit/hyperactivity disorder. *Dev Med Child Neurol* 2019; **61**: 399-405 [PMID: 30276811 DOI: 10.1111/dmcn.14050]
- 31 **Lenka A**, Jhunjhunwala KR, Saini J, Pal PK. Structural and functional neuroimaging in patients with Parkinson's disease and visual hallucinations: A critical review. *Parkinsonism Relat Disord* 2015; **21**: 683-691 [PMID: 25920541 DOI: 10.1016/j.parkreldis.2015.04.005]
- 32 **Wise T**, Radua J, Via E, Cardoner N, Abe O, Adams TM, Amico F, Cheng Y, Cole JH, de Azevedo Marques Périco C, Dickstein DP, Farrow TFD, Frodl T, Wagner G, Gotlib IH, Gruber O, Ham BJ, Job DE, Kempton MJ, Kim MJ, Koolschijn PCMP, Malhi GS, Mataix-Cols D, McIntosh AM, Nugent AC, O'Brien JT, Pezzoli S, Phillips ML, Sachdev PS, Salvatore G, Selvaraj S, Stanfield AC, Thomas AJ, van Tol MJ, van der Wee NJA, Veltman DJ, Young AH, Fu CH, Cleare AJ, Arnott D. Common and distinct patterns of grey-matter volume alteration in major depression and bipolar disorder: evidence from voxel-based meta-analysis. *Mol Psychiatry* 2017; **22**: 1455-1463 [PMID: 27217146 DOI: 10.1038/mp.2016.72]
- 33 **Li J**, Wang Z, Hwang J, Zhao B, Yang X, Xin S, Wang Y, Jiang H, Shi P, Zhang Y, Wang X, Lang C, Park J, Bao T, Kong J. Anatomical brain difference of subthreshold depression in young and middle-aged individuals. *Neuroimage Clin* 2017; **14**: 546-551 [PMID: 28331801 DOI: 10.1016/j.nicl.2017.02.022]
- 34 **Ramasubbu R**, Brown EC, Marcil LD, Talai AS, Forkert ND. Automatic classification of major depression disorder using arterial spin labeling MRI perfusion measurements. *Psychiatry Clin Neurosci* 2019; **73**: 486-493 [PMID: 31077500 DOI: 10.1111/pcn.12862]
- 35 **Back SJ**, Park JS, Kim J, Yamamoto Y, Tanaka-Yamamoto K. VTA-projecting cerebellar neurons mediate stress-dependent depression-like behaviors. *Elife* 2022; **11** [PMID: 35156922 DOI: 10.7554/eLife.72981]
- 36 **Xiong F**, Li T, Pan Y, Liu Y, Zhang J, Bai L. [Arterial spin labeling magnetic resonance evaluates changes of cerebral blood flow in patients with mild traumatic brain injury]. *Zhongnan Daxue Xuebao Yixueban* 2022; **47**: 1016-1024 [PMID: 36097769 DOI: 10.11817/j.issn.1672-7347.2022.210754]
- 37 **Müller VI**, Cieslik EC, Serbanescu I, Laird AR, Fox PT, Eickhoff SB. Altered Brain Activity in Unipolar Depression Revisited: Meta-analyses of Neuroimaging Studies. *JAMA Psychiatry* 2017; **74**: 47-55 [PMID: 27829086 DOI: 10.1001/jamapsychiatry.2016.2783]
- 38 **McDonald E**, Whitney S, Horricks L, Lipman EL, Ferro MA. Parent-Child Agreement on the Mini International Neuropsychiatric Interview for Children and Adolescents (MINI-KID). *J Can Acad Child Adolesc Psychiatry* 2021; **30**: 264-272 [PMID: 34777509]
- 39 **Douaud G**, Smith S, Jenkinson M, Behrens T, Johansen-Berg H, Vickers J, James S, Voets N, Watkins K, Matthews PM, James A. Anatomically related grey and white matter abnormalities in adolescent-onset schizophrenia. *Brain* 2007; **130**: 2375-2386 [PMID: 17698497 DOI: 10.1093/brain/awm184]
- 40 **Yan CG**, Wang XD, Zuo XN, Zang YF. DPABI: Data Processing & Analysis for (Resting-State) Brain Imaging. *Neuroinformatics* 2016; **14**: 339-351 [PMID: 27075850 DOI: 10.1007/s12021-016-9299-4]
- 41 **Mezzapesa DM**, D'Errico E, Tortelli R, Distaso E, Cortese R, Tursi M, Federico F, Zoccollella S, Logroscino G, Dicuonzo F, Simone IL. Cortical thinning and clinical heterogeneity in amyotrophic lateral sclerosis. *PLoS One* 2013; **8**: e80748 [PMID: 24278317 DOI: 10.1371/journal.pone.0080748]
- 42 **Wang J**, Shen Y, Peng J, Wang A, Wu X, Chen X, Liu J, Wei M, Zou D, Han Y, Cheng O. Different functional connectivity modes of the right fronto-insular cortex in akinetic-rigid and tremor-dominant Parkinson's disease. *Neurol Sci* 2021; **42**: 2937-2946 [PMID: 33236247 DOI: 10.1007/s10072-020-04917-1]
- 43 **Iacoboni M**, Woods RP, Lenzi GL, Mazziotta JC. Merging of oculomotor and somatomotor space coding in the human right precentral gyrus. *Brain* 1997; **120** (Pt 9): 1635-1645 [PMID: 9313645 DOI: 10.1093/brain/120.9.1635]
- 44 **Silva AB**, Liu JR, Zhao L, Levy DF, Scott TL, Chang EF. A Neurosurgical Functional Dissection of the Middle Precentral Gyrus during Speech Production. *J Neurosci* 2022; **42**: 8416-8426 [PMID: 36351829 DOI: 10.1523/JNEUROSCI.1614-22.2022]
- 45 **Anderson JS**, Druzgal TJ, Froehlich A, DuBray MB, Lange N, Alexander AL, Abildskov T, Nielsen JA, Cariello AN, Cooperrider JR, Bigler ED, Lainhart JE. Decreased interhemispheric functional connectivity in autism. *Cereb Cortex* 2011; **21**: 1134-1146 [PMID: 20943668 DOI: 10.1093/cercor/bhq190]
- 46 **Chen XF**, He P, Xu KH, Jin YH, Chen Y, Wang B, Hu X, Qi L, Wang MW, Li J. Disrupted Spontaneous Neural Activity and Its Interaction With Pain and Emotion in Temporomandibular Disorders. *Front Neurosci* 2022; **16**: 941244 [PMID: 36090263 DOI: 10.3389/fnins.2022.941244]
- 47 **Player MJ**, Taylor JL, Weickert CS, Alonzo A, Sachdev P, Martin D, Mitchell PB, Loo CK. Neuroplasticity in depressed individuals compared with healthy controls. *Neuropsychopharmacology* 2013; **38**: 2101-2108 [PMID: 23676792 DOI: 10.1038/npp.2013.126]
- 48 **Wehry AM**, McNamara RK, Adler CM, Eliassen JC, Croarkin P, Cerullo MA, DelBello MP, Strawn JR. Neurostructural impact of co-occurring anxiety in pediatric patients with major depressive disorder: a voxel-based morphometry study. *J Affect Disord* 2015; **171**: 54-59 [PMID: 25285899 DOI: 10.1016/j.jad.2014.09.004]
- 49 **Long X**, Li L, Wang X, Cao Y, Wu B, Roberts N, Gong Q, Kemp GJ, Jia Z. Gray matter alterations in adolescent major depressive disorder and adolescent bipolar disorder. *J Affect Disord* 2023; **325**: 550-563 [PMID: 36669567 DOI: 10.1016/j.jad.2023.01.049]
- 50 **Schell M**, Zaccarella E, Friederici AD. Differential cortical contribution of syntax and semantics: An fMRI study on two-word phrasal processing. *Cortex* 2017; **96**: 105-120 [PMID: 29024818 DOI: 10.1016/j.cortex.2017.09.002]
- 51 **Bulut T**. Meta-analytic connectivity modeling of the left and right inferior frontal gyri. *Cortex* 2022; **155**: 107-131 [PMID: 35156922 DOI: 10.1016/j.cortex.2022.09.002]

- 35985123 DOI: [10.1016/j.cortex.2022.07.003](https://doi.org/10.1016/j.cortex.2022.07.003)
- 52 **Allen G**, Buxton RB, Wong EC, Courchesne E. Attentional activation of the cerebellum independent of motor involvement. *Science* 1997; **275**: 1940-1943 [PMID: [9072973](https://pubmed.ncbi.nlm.nih.gov/9072973/) DOI: [10.1126/science.275.5308.1940](https://doi.org/10.1126/science.275.5308.1940)]
- 53 **Diedrichsen J**, King M, Hernandez-Castillo C, Sereno M, Ivry RB. Universal Transform or Multiple Functionality? Understanding the Contribution of the Human Cerebellum across Task Domains. *Neuron* 2019; **102**: 918-928 [PMID: [31170400](https://pubmed.ncbi.nlm.nih.gov/31170400/) DOI: [10.1016/j.neuron.2019.04.021](https://doi.org/10.1016/j.neuron.2019.04.021)]
- 54 **Moberget T**, Alnæs D, Kaufmann T, Doan NT, Córdova-Palomera A, Norbom LB, Rokicki J, van der Meer D, Andreassen OA, Westlye LT. Cerebellar Gray Matter Volume Is Associated With Cognitive Function and Psychopathology in Adolescence. *Biol Psychiatry* 2019; **86**: 65-75 [PMID: [30850129](https://pubmed.ncbi.nlm.nih.gov/30850129/) DOI: [10.1016/j.biopsych.2019.01.019](https://doi.org/10.1016/j.biopsych.2019.01.019)]
- 55 **Gur RE**, Moore TM, Rosen AFG, Barzilay R, Roalf DR, Calkins ME, Ruparel K, Scott JC, Almasy L, Satterthwaite TD, Shinohara RT, Gur RC. Burden of Environmental Adversity Associated With Psychopathology, Maturation, and Brain Behavior Parameters in Youths. *JAMA Psychiatry* 2019; **76**: 966-975 [PMID: [31141099](https://pubmed.ncbi.nlm.nih.gov/31141099/) DOI: [10.1001/jamapsychiatry.2019.0943](https://doi.org/10.1001/jamapsychiatry.2019.0943)]
- 56 **Smallwood J**, Bernhardt BC, Leech R, Bzdok D, Jefferies E, Margulies DS. The default mode network in cognition: a topographical perspective. *Nat Rev Neurosci* 2021; **22**: 503-513 [PMID: [34226715](https://pubmed.ncbi.nlm.nih.gov/34226715/) DOI: [10.1038/s41583-021-00474-4](https://doi.org/10.1038/s41583-021-00474-4)]
- 57 **Bubb EJ**, Metzler-Baddeley C, Aggleton JP. The cingulum bundle: Anatomy, function, and dysfunction. *Neurosci Biobehav Rev* 2018; **92**: 104-127 [PMID: [29753752](https://pubmed.ncbi.nlm.nih.gov/29753752/) DOI: [10.1016/j.neubiorev.2018.05.008](https://doi.org/10.1016/j.neubiorev.2018.05.008)]
- 58 **Cullen KR**, Klimes-Dougan B, Muetzel R, Mueller BA, Camchong J, Hourri A, Kurma S, Lim KO. Altered white matter microstructure in adolescents with major depression: a preliminary study. *J Am Acad Child Adolesc Psychiatry* 2010; **49**: 173-83.e1 [PMID: [20215939](https://pubmed.ncbi.nlm.nih.gov/20215939/) DOI: [10.1097/00004583-201002000-00011](https://doi.org/10.1097/00004583-201002000-00011)]
- 59 **Höflich A**, Michenthaler P, Kasper S, Lanzenberger R. Circuit Mechanisms of Reward, Anhedonia, and Depression. *Int J Neuropsychopharmacol* 2019; **22**: 105-118 [PMID: [30239748](https://pubmed.ncbi.nlm.nih.gov/30239748/) DOI: [10.1093/ijnp/pyy081](https://doi.org/10.1093/ijnp/pyy081)]
- 60 **Zhou HX**, Chen X, Shen YQ, Li L, Chen NX, Zhu ZC, Castellanos FX, Yan CG. Rumination and the default mode network: Meta-analysis of brain imaging studies and implications for depression. *Neuroimage* 2020; **206**: 116287 [PMID: [31655111](https://pubmed.ncbi.nlm.nih.gov/31655111/) DOI: [10.1016/j.neuroimage.2019.116287](https://doi.org/10.1016/j.neuroimage.2019.116287)]
- 61 **Dutta A**, McKie S, Downey D, Thomas E, Juhasz G, Arnone D, Elliott R, Williams S, Deakin JFW, Anderson IM. Regional default mode network connectivity in major depressive disorder: modulation by acute intravenous citalopram. *Transl Psychiatry* 2019; **9**: 116 [PMID: [30877271](https://pubmed.ncbi.nlm.nih.gov/30877271/) DOI: [10.1038/s41398-019-0447-0](https://doi.org/10.1038/s41398-019-0447-0)]



Published by **Baishideng Publishing Group Inc**
7041 Koll Center Parkway, Suite 160, Pleasanton, CA 94566, USA

Telephone: +1-925-3991568

E-mail: bpgoffice@wjgnet.com

Help Desk: <https://www.f6publishing.com/helpdesk>

<https://www.wjgnet.com>

