

# World Journal of *Clinical Cases*

*World J Clin Cases* 2023 June 26; 11(18): 4210-4457



## REVIEW

- 4210 Should gastroenterologists prescribe cannabis? The highs, the lows and the unknowns  
*Samuel S, Michael M, Tadros M*

## MINIREVIEWS

- 4231 Application of artificial intelligence in trauma orthopedics: Limitation and prospects  
*Salimi M, Parry JA, Shahrokhi R, Mosalamiaghili S*
- 4241 Weight loss maintenance after bariatric surgery  
*Cho YH, Lee Y, Choi JI, Lee SR, Lee SY*
- 4251 Bicuspid aortic valve with associated aortopathy, significant left ventricular hypertrophy or concomitant hypertrophic cardiomyopathy: A diagnostic and therapeutic challenge  
*Sopek Merkaš I, Lakušić N, Predrijevac M, Štambuk K, Hrabak Paar M*
- 4258 Application experience and research progress of different emerging technologies in plastic surgery  
*Yang B, Yang L, Huang WL, Zhou QZ, He J, Zhao X*

## ORIGINAL ARTICLE

## Case Control Study

- 4267 Multimodal integrated intervention for children with attention-deficit/hyperactivity disorder  
*Lv YB, Cheng W, Wang MH, Wang XM, Hu YL, Lv LQ*

## Retrospective Study

- 4277 Portal vein computed tomography imaging characteristics and their relationship with bleeding risk in patients with liver cirrhosis undergoing interventional therapy  
*Song XJ, Liu JL, Jia SY, Zhang K*

## Observational Study

- 4287 Wrist-ankle acupuncture combined with pain nursing for the treatment of urinary calculi with acute pain  
*Wu LM, Liu Q, Yin XH, Yang LP, Yuan J, Zhang XQ, Wang YL*

## CASE REPORT

- 4295 Coexistence of diffuse large B-cell lymphoma, acute myeloid leukemia, and untreated lymphoplasmacytic lymphoma/waldenström macroglobulinemia in a same patient: A case report  
*Zhang LB, Zhang L, Xin HL, Wang Y, Bao HY, Meng QQ, Jiang SY, Han X, Chen WR, Wang JN, Shi XF*
- 4306 Collagen fleece (Tachosil®) for treating testis torsion: A case report  
*Kim KM, Kim JH*

- 4313** Morphological features and endovascular repair for type B multichanneled aortic dissection: A case report  
*Lu WF, Chen G, Wang LX*
- 4318** Hepatic inflammatory myofibroblastic tumor: A case report  
*Tong M, Zhang BC, Jia FY, Wang J, Liu JH*
- 4326** Endometriosis of the lung: A case report and review of literature  
*Yao J, Zheng H, Nie H, Li CF, Zhang W, Wang JJ*
- 4334** Delayed dislocation of the radial head associated with malunion of distal radial fracture: A case report  
*Kim KB, Wang SI*
- 4341** Synchronous endometrial and ovarian cancer: A case report  
*Žilovič D, Čiurlienė R, Šidlovská E, Vaicekauskaitė I, Sabaliauskaitė R, Jarmalaitė S*
- 4350** Nivolumab-induced tumour-like gastritis: A case report  
*Cijauskaite E, Kazenaite E, Strainiene S, Sadauskaite G, Kurlinkus B*
- 4360** Solitary thyroid gland metastasis from rectal cancer: A case report and review of the literature  
*Chen Y, Kang QS, Zheng Y, Li FB*
- 4368** Anesthesia for extracorporeal membrane oxygenation-assisted thoracoscopic lower lobe subsegmental resection in a patient with a single left lung: A case report  
*Wang XF, Li ZY, Chen L, Chen LX, Xie F, Luo HQ*
- 4377** Indium chloride bone marrow scintigraphy for hepatic myelolipoma: A case report  
*Sato A, Saito K, Abe K, Sugimoto K, Nagao T, Sukeda A, Yunaiyama D*
- 4384** Fibromatosis-like metaplastic carcinoma of the breast: Two case reports  
*Bao WY, Zhou JH, Luo Y, Lu Y*
- 4392** Perforating and ophthalmic artery variants from the anterior cerebral artery: Two case reports  
*Mo ZX, Li W, Wang DF*
- 4397** Diagnostic use of superb microvascular imaging in evaluating septic arthritis of the manubriosternal joint: A case report  
*Seskute G, Kausaite D, Chalkovskaja A, Bulotaite E, Butrimiene I*
- 4406** Primary prostate Burkitt's lymphoma resected with holmium laser enucleation of the prostate: A rare case report  
*Wu YF, Li X, Ma J, Ma DY, Zeng XM, Yu QW, Chen WG*
- 4412** Pancreatitis, panniculitis and polyarthrititis syndrome: A case report  
*Pichler H, Stumpner T, Schiller D, Bischofreiter M, Ortmaier R*
- 4419** Acute neck tendonitis with dyspnea: A case report  
*Wu H, Liu W, Mi L, Liu Q*

- 4425** Next-generation sequencing technology for the diagnosis of *Pneumocystis* pneumonia in an immunocompetent female: A case report  
*Huang JJ, Zhang SS, Liu ML, Yang EY, Pan Y, Wu J*
- 4433** Superior laryngeal nerve block for treatment of throat pain and cough following laryngeal herpes zoster: A case report  
*Oh J, Park Y, Choi J, Jeon Y*
- 4438** Removal of unexpected schwannoma with superficial parotidectomy using modified-Blair incision and superficial musculoaponeurotic system folding: A case report  
*Nam HJ, Choi HJ, Byeon JY, Wee SY*
- 4446** Simultaneously metastatic cholangiocarcinoma and small intestine cancer from breast cancer misdiagnosed as primary cholangiocarcinoma: A case report  
*Jiao X, Zhai MM, Xing FZ, Wang XL*

**LETTER TO THE EDITOR**

- 4454** Erroneous presentation of respiratory-hemodynamic disturbances and postsurgical inflammatory responses in patients having undergone abdominal cavity cancer surgery  
*Idrissov KS, Mynbaev OA*



**ABOUT COVER**

Editorial Board Member of *World Journal of Clinical Cases*, Guoping Zheng, MD, PhD, Associate Professor, Faculty of Medicine and Health, Sydney Medical School-Westmead Clinical School, The University of Sydney, Sydney 2145, Australia. [guoping.zheng@sydney.edu.au](mailto:guoping.zheng@sydney.edu.au)

**AIMS AND SCOPE**

The primary aim of *World Journal of Clinical Cases* (WJCC, *World J Clin Cases*) is to provide scholars and readers from various fields of clinical medicine with a platform to publish high-quality clinical research articles and communicate their research findings online.

WJCC mainly publishes articles reporting research results and findings obtained in the field of clinical medicine and covering a wide range of topics, including case control studies, retrospective cohort studies, retrospective studies, clinical trials studies, observational studies, prospective studies, randomized controlled trials, randomized clinical trials, systematic reviews, meta-analysis, and case reports.

**INDEXING/ABSTRACTING**

The WJCC is now abstracted and indexed in Science Citation Index Expanded (SCIE, also known as SciSearch®), Journal Citation Reports/Science Edition, Current Contents®/Clinical Medicine, PubMed, PubMed Central, Reference Citation Analysis, China National Knowledge Infrastructure, China Science and Technology Journal Database, and Superstar Journals Database. The 2022 Edition of Journal Citation Reports® cites the 2021 impact factor (IF) for WJCC as 1.534; IF without journal self cites: 1.491; 5-year IF: 1.599; Journal Citation Indicator: 0.28; Ranking: 135 among 172 journals in medicine, general and internal; and Quartile category: Q4.

**RESPONSIBLE EDITORS FOR THIS ISSUE**

Production Editor: *Ying-Yi Yuan*; Production Department Director: *Xu Guo*; Editorial Office Director: *Jin-Lei Wang*.

**NAME OF JOURNAL**

*World Journal of Clinical Cases*

**ISSN**

ISSN 2307-8960 (online)

**LAUNCH DATE**

April 16, 2013

**FREQUENCY**

Thrice Monthly

**EDITORS-IN-CHIEF**

Bao-Gan Peng, Jerzy Tadeusz Chudek, George Kontogeorgos, Maurizio Serati, Ja Hyeon Ku

**EDITORIAL BOARD MEMBERS**

<https://www.wjgnet.com/2307-8960/editorialboard.htm>

**PUBLICATION DATE**

June 26, 2023

**COPYRIGHT**

© 2023 Baishideng Publishing Group Inc

**INSTRUCTIONS TO AUTHORS**

<https://www.wjgnet.com/bpg/gerinfo/204>

**GUIDELINES FOR ETHICS DOCUMENTS**

<https://www.wjgnet.com/bpg/GerInfo/287>

**GUIDELINES FOR NON-NATIVE SPEAKERS OF ENGLISH**

<https://www.wjgnet.com/bpg/gerinfo/240>

**PUBLICATION ETHICS**

<https://www.wjgnet.com/bpg/GerInfo/288>

**PUBLICATION MISCONDUCT**

<https://www.wjgnet.com/bpg/gerinfo/208>

**ARTICLE PROCESSING CHARGE**

<https://www.wjgnet.com/bpg/gerinfo/242>

**STEPS FOR SUBMITTING MANUSCRIPTS**

<https://www.wjgnet.com/bpg/GerInfo/239>

**ONLINE SUBMISSION**

<https://www.f6publishing.com>



# Removal of unexpected schwannoma with superficial parotidectomy using modified-Blair incision and superficial musculoaponeurotic system folding: A case report

Ha-Jong Nam, Hwan Jun Choi, Je-Yeon Byeon, Syeo-Young Wee

**Specialty type:** Surgery

**Provenance and peer review:**

Unsolicited article; Externally peer reviewed.

**Peer-review model:** Single blind

**Peer-review report's scientific quality classification**

Grade A (Excellent): 0

Grade B (Very good): B

Grade C (Good): 0

Grade D (Fair): D

Grade E (Poor): 0

**P-Reviewer:** Pisani P, Italy; Tajiri K, Japan

**Received:** April 15, 2023

**Peer-review started:** April 15, 2023

**First decision:** April 28, 2023

**Revised:** May 8, 2023

**Accepted:** May 23, 2023

**Article in press:** May 23, 2023

**Published online:** June 26, 2023



**Ha-Jong Nam, Syeo-Young Wee**, Department of Plastic and Reconstructive Surgery, Soonchunhyang University Gumi Hospital, Gumi-si 39371, Gyeongsangbuk-do, South Korea

**Hwan Jun Choi, Je-Yeon Byeon**, Department of Plastic and Reconstructive Surgery, Soonchunhyang University Cheonan Hospital, Cheonan-si 31151, Chungcheongnam-do, South Korea

**Corresponding author:** Syeo-Young Wee, MD, PhD, Doctor, Professor, Department of Plastic and Reconstructive Surgery, Soonchunhyang University Gumi Hospital, 1 Gongdan-ro 179, Gumi-si 39371, Gyeongsangbuk-do, South Korea. [94061@schmc.ac.kr](mailto:94061@schmc.ac.kr)

## Abstract

### BACKGROUND

When a firm facial mass in the cheek region is associated with a high index of clinical suspicion of its being of parotid gland origin, preventive parotidectomy is invariably performed. We report a rare case of a schwannoma that was suspected to be of parotid gland origin in a patient, who underwent successful surgical management using a modified-Blair incision and superficial musculoaponeurotic system (SMAS) layer folding method.

### CASE SUMMARY

A 27-year-old woman presented to the hospital for evaluation of a firm, fixed, non-tender mass (2.5 cm × 3.5 cm), located anterior to the right ear, of 1 year's duration. Contrast-enhanced facial computed tomography revealed a well-encapsulated, low-density mass adherent to the superficial lobe of the right parotid gland, with a high index of clinical suspicion of an accessory parotid gland mass. The patient was scheduled to undergo resection of the mass and superficial parotidectomy. She underwent surgery using a modified-Blair incision, and the SMAS layer was folded posteriorly to reconstruct the defect. Histopathological examination confirmed the diagnosis of a schwannoma, and we observed no postoperative complications such as hematoma, infection, or abnormal facial expressions. The incision scar was unnoticeable 2 mo postoperatively, and the facial contour was maintained without any differences between the affected and unaffected sides.

### CONCLUSION

We used a modified-Blair incision and SMAS layer folding method to achieve

aesthetically good results following resection of a rare schwannoma with superficial parotidectomy in the cheek region.

**Key Words:** Schwannoma; Parotid gland; Superficial musculoaponeurotic system; Case report

©The Author(s) 2023. Published by Baishideng Publishing Group Inc. All rights reserved.

**Core Tip:** Schwannoma in the face region is a rare type of tumor that originates from the Schwann cells of ectodermal origin. It can develop in any cranial nerve but rarely originates from peripheral nerves. Masses in the cheek region are usually suspected to be of parotid gland origin, and preventive parotidectomy is usually performed. In our case, the mass was initially diagnosed as arising from the parotid gland, but was finally confirmed to be a schwannoma. Therefore, we should keep in mind the possibility of schwannoma, although rare.

**Citation:** Nam HJ, Choi HJ, Byeon JY, Wee SY. Removal of unexpected schwannoma with superficial parotidectomy using modified-Blair incision and superficial musculoaponeurotic system folding: A case report. *World J Clin Cases* 2023; 11(18): 4438-4445

**URL:** <https://www.wjgnet.com/2307-8960/full/v11/i18/4438.htm>

**DOI:** <https://dx.doi.org/10.12998/wjcc.v11.i18.4438>

## INTRODUCTION

A firm facial mass anterior to the ear in the cheek region is associated with a high index of clinical suspicion of being derived from the parotid gland. Typically, a mass originating from the parotid gland is most commonly a pleomorphic adenoma (among benign tumors), whereas mucoepidermoid carcinoma is the most common malignant tumor; the main treatment is preventive superficial or total parotidectomy. However, parotidectomy is associated with a risk of scar formation owing to the wide surgical incision and cavity formation after parotid gland resection, which can result in a depressed facial contour postoperatively[1-3].

Accurate preoperative evaluation of facial masses, particularly those in the cheek region, is necessary; however, in most cases, the diagnosis relies on preoperative radiological assessments, and the final diagnosis is confirmed by postoperative histopathological findings. Therefore, preventive parotidectomy is recommended to avoid reoperation in patients with preoperative imaging findings suggestive of a mass that likely originates from the parotid gland[2].

In this report, we describe a rare case of a facial schwannoma and discuss our surgical approach for successful mass extirpation and preventive parotidectomy accompanied by a modified-Blair incision to minimize scarring, and the superficial musculoaponeurotic system (SMAS) layer folding method to restore the facial contour.

## CASE PRESENTATION

### Chief complaints

A 27-year-old woman presented for evaluation of a mass in the region of the cheek anterior to the right ear.

### History of present illness

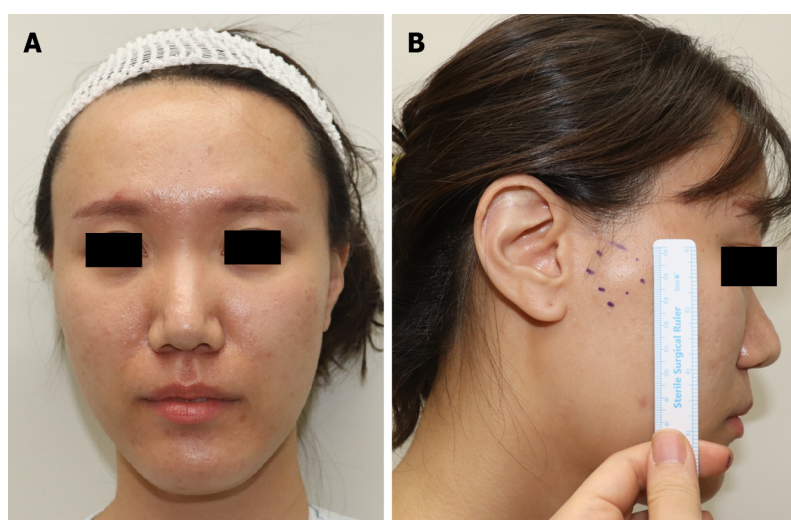The mass had gradually increased in size over the year prior to presentation. The patient did not report any local symptoms such as pain or heat sensation and did not complain of any general health problems.

### History of past illness

The patient denied any medical, medication, or surgical history, and reported no history of external trauma to the right side of the face.

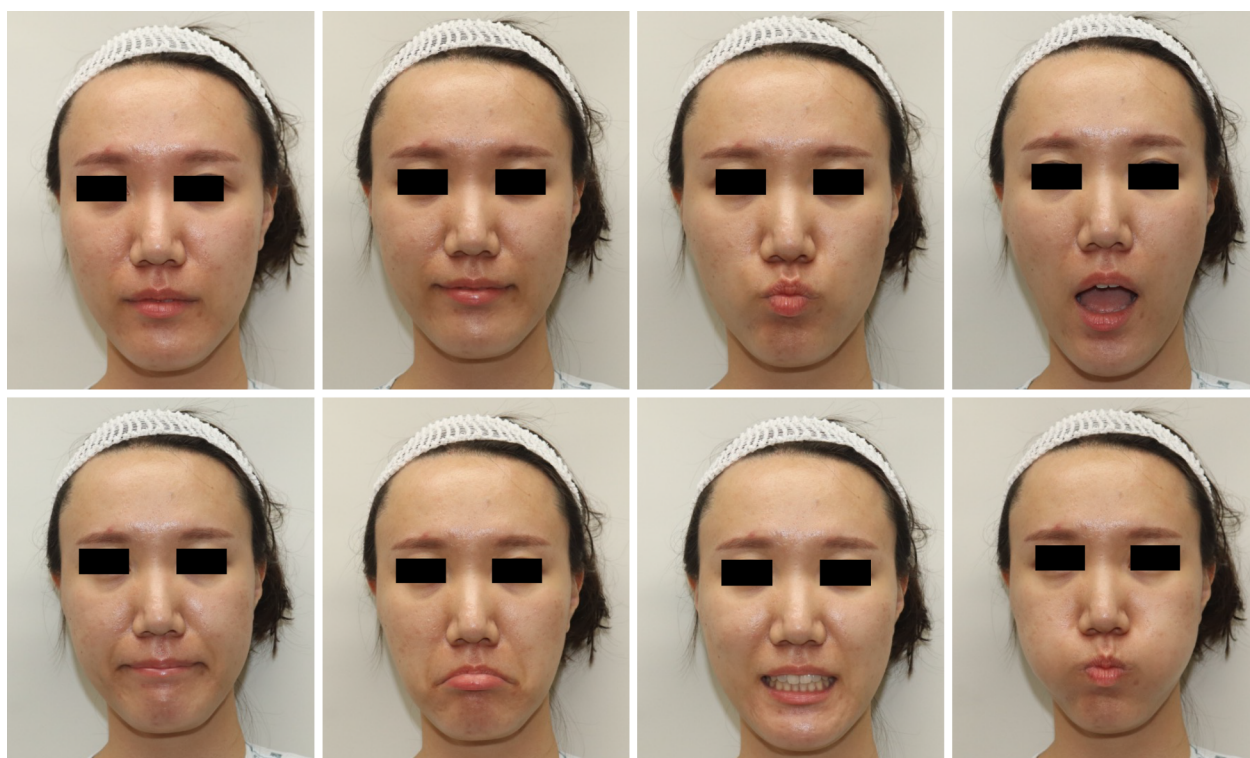### Personal and family history

There was no significant personal or family history.



DOI: 10.12998/wjcc.v11.i18.4438 Copyright ©The Author(s) 2023.

**Figure 1 Preoperative findings.** Image showing a normal skin-colored mass measuring 2.5 cm × 3.5 cm. The patient did not show symptoms of tenderness, swelling, infection, or any abnormal sensation of the skin surface. A: Anterior view; B: Lateral view.



DOI: 10.12998/wjcc.v11.i18.4438 Copyright ©The Author(s) 2023.

**Figure 2 Preoperative facial animation test results.** No abnormalities of facial expression are observed.

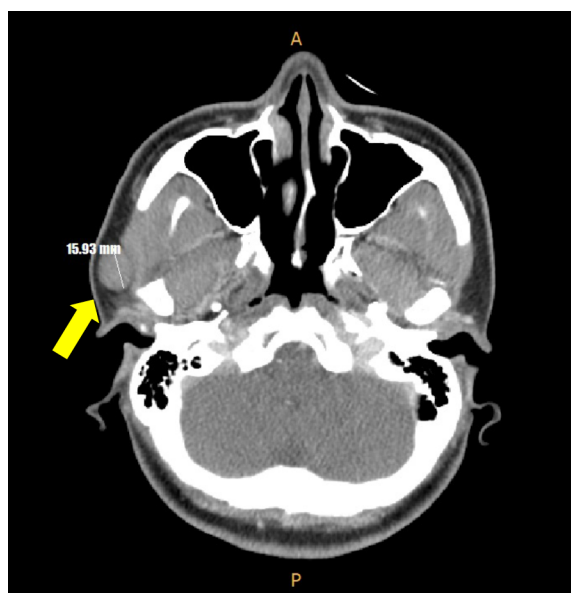
### Physical examination

Physical examination of the mass revealed a firm and fixed mass (2.5 cm × 3.5 cm) without any signs of infection, such as tenderness, swelling, induration, or any abnormal skin surface sensation (Figure 1). We observed a local bulge secondary to a mass effect; however, the facial expressions were normal (Figure 2).

### Laboratory examinations

There were no abnormal findings on evaluation of laboratory samples. The blood results were within normal limits; the serum amylase level was 30 U/L (normal range is 30 to 110 U/L).





DOI: 10.12998/wjcc.v11.i18.4438 Copyright ©The Author(s) 2023.

**Figure 3 Facial computed tomography scan (axial view) findings.** Image showing a well-encapsulated low-density mass (yellow arrow) adherent to the inferior portion of the superficial lobe of the parotid gland.

### Imaging examinations

Contrast-enhanced facial computed tomography (CT) revealed a well-encapsulated low-density mass (1.6 cm × 1.3 cm) adherent to the inferior portion of the superficial lobe of the right parotid gland (Figure 3).

### Informed consents

The patient was thoroughly informed regarding the potential for a mass originating from the parotid gland and the necessity of prophylactic parotidectomy and gave informed consent. Additionally, the definitive diagnosis was established through histological examination of the excised mass, and the patient was informed of alternative diagnoses.

## TREATMENT

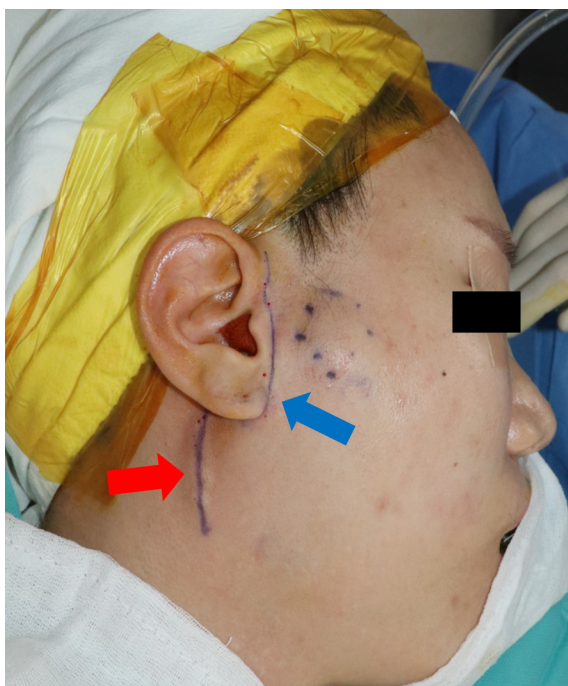### Surgical procedure

Considering the possibility of an accessory parotid gland mass, we performed complete resection with superficial parotidectomy. The surgical procedure involved the creation of a modified-Blair incision[4]. The incision line was drawn along the preauricular skin crease, commencing from the anterior and superior tragus and extending below the earlobe to the postauricular area, but not to the mandibular border of the chin (Figure 4). After creating the incision, the skin flap was dissected along the plane of the SMAS layer and elevated anteriorly, with exposure of the superficial lobe of the parotid gland, which revealed a mass in the fascia. The mass was encapsulated below the superficial lobe of the parotid gland and measured 2 cm × 2 cm. No parotid gland invasion was observed; however, the mass was firmly adherent to the gland. There was no clear evidence of feeding vessels or nerves supplying the mass (Figure 5A).

After superficial parotidectomy, we confirmed that the facial nerve branches coursing through the glands were intact (Figure 5B). The lateral portion of the elevated SMAS layer is separated by approximately 2 cm and folded to fit into the dead space. The defect was filled and closure was performed layer-by-layer (Figure 6).

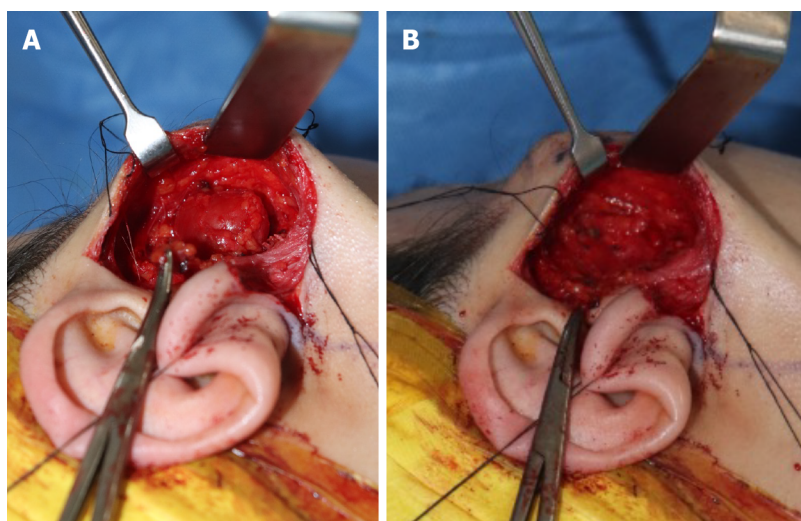
## FINAL DIAGNOSIS

Histopathological evaluation of the resected specimen revealed a multilobular neural lesion, which was specifically diagnosed as a schwannoma (Figure 7).



DOI: 10.12998/wjcc.v11.i18.4438 Copyright ©The Author(s) 2023.

**Figure 4 Photograph showing superficial parotidectomy using a modified-Blair incision.** The incision commences from the anterior and superior aspects of the tragus along the preauricular skin crease and extends to the lower earlobe and postauricular area (blue arrow). The drawn incision marking line extends up to the mandibular border of the chin but not incised in operation (red arrow).

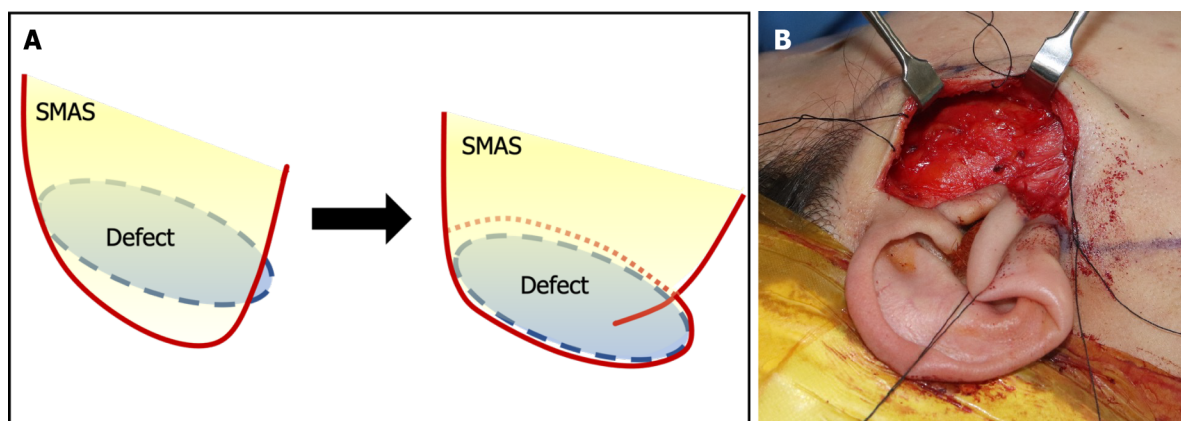


DOI: 10.12998/wjcc.v11.i18.4438 Copyright ©The Author(s) 2023.

**Figure 5 Photographs showing intraoperative findings.** A: Intracapsular enucleation of the schwannoma with preservation of the facial nerve fibers; B: Post-excision photograph showing that branches of the facial nerve coursing through the parotid gland are intact.

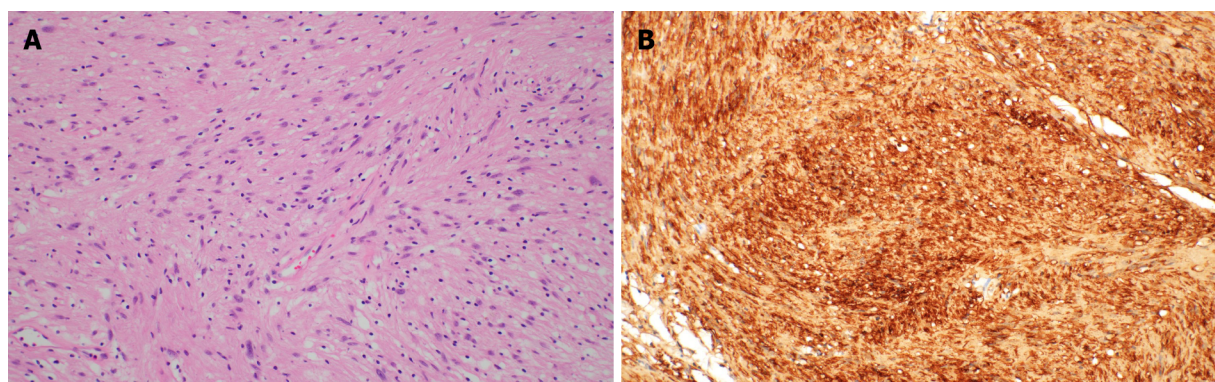
## OUTCOME AND FOLLOW-UP

The patient showed satisfactory postoperative healing without any signs of hematoma, infection, skin necrosis abnormalities in facial expression, or any neuropathies. The incision scar was unnoticeable, and no scar-induced complications were observed at the 2-mo follow-up. The facial contour was maintained without any differences compared to the contralateral face (Figure 8).



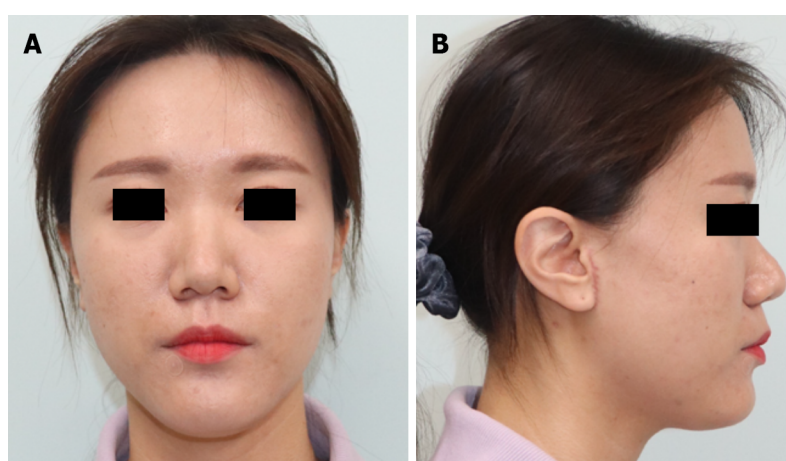
DOI: 10.12998/wjcc.v11.i18.4438 Copyright ©The Author(s) 2023.

**Figure 6 Photographs showing the superficial musculoaponeurotic system folding procedure.** A: Image showing folding of the lateral portion of the superficial musculoaponeurotic system (SMAS) layer (approximately 2 cm) to fill the post-parotidectomy defect; B: The defect is completely covered after being filled with the folded SMAS (blue circle). SMAS: Superficial musculoaponeurotic system.



DOI: 10.12998/wjcc.v11.i18.4438 Copyright ©The Author(s) 2023.

**Figure 7 Histopathological findings of the resected specimen.** A: The tumor is composed of spindle cells with bland-looking nuclei and abundant cytoplasm (hematoxylin & eosin,  $\times 200$ ); B: Tumor showing diffuse strong immunoreactivity for the S100 protein ( $\times 200$ ).



DOI: 10.12998/wjcc.v11.i18.4438 Copyright ©The Author(s) 2023.

**Figure 8 Photographs obtained at the 2-mo postoperative follow-up.** The incision scar is unnoticeable, and no specific complication is detected. The right cheek contour is maintained, and no differences are observed compared with the contralateral side. A: Anterior view; B: Lateral view.

## DISCUSSION

Schwannomas are benign encapsulated tumors of the peripheral nerve sheath that originate from



Schwann cells of the motor or sensory nerves. Facial schwannomas are rare; fewer than 100 cases have been reported in the literature and usually originate from the peripheral facial nerve or other nerves within the parotid gland. No sex-based differences are observed in the incidence, and the peak incidence is observed in patients aged 30-60 years[5,6].

Facial schwannomas of the cheek region typically present as painless, slow-growing lumps. The lesion typically has a well-demarcated border and is hard to touch. The symptoms are usually nonspecific[7,8]. Imaging tests such as Contrast-enhanced facial CT reveal a well-defined mass containing a cystic lesion and displacement of the surrounding structures. They are typically homogeneous and may contain cystic or necrotic regions. Magnetic resonance imaging (MRI) is another imaging modality that can be used to visualize schwannomas. On MRI finding, schwannomas typically appear as well-defined, encapsulated masses. The signal intensity of the mass may be heterogeneous, reflecting areas of cystic degeneration or hemorrhage. However, it is difficult to diagnose based on these findings. Schwannomas that originate from the facial nerve or its branches may manifest with the clinical symptoms of facial nerve paralysis, although the incidence of such lesions is low. They may originate from nerves other than the facial nerve, and the preoperative diagnosis is inaccurate in more than 75% of cases[9].

Our patient presented with a painless mass without any abnormalities in facial expression or symptoms during the preoperative physical examination. The contrast-enhanced facial CT scan of the patient revealed a well-defined, round-shaped mass, which is a typical pattern for schwannomas on CT imaging. The MRI was recommended; however, the patient refused owing to the cost issue, and therefore, a definitive diagnosis could not be established through imaging examinations. Additionally, no evidence of facial nerve branch impingement was observed intraoperatively, suggesting that the schwannoma did not originate from the facial nerve or its branches.

Usually, preventive parotidectomy is performed to avoid the risk of recurrence or malignant transformation in patients with a suspected parotid gland mass in cheek region, even in cases of benign lesions[2,10]. In this case, we considered the possibility of an accessory parotid gland and performed preventive superficial parotidectomy using a modified-Blair incision and the SMAS layer folding method to address the potential issues of scarring and contour deformity derived from dead space after parotid gland resection.

In the cheek region, the modified-Blair incision is commonly used in surgical treatment to minimize scarring compared to the conventional Blair incision and simultaneously reduce the risk of facial nerve injury[11-13]. In this case, we used the modified-Blair incision line superior to jawline, so that we could avoid facial nerve injury during parotidectomy and minimize scarring. Additionally, the SMAS layer was folded into the defect after extirpation of the mass, so we could successfully minimize facial contour deformities and achieve a more aesthetically favorable outcome postoperatively.

Our study has several limitations. First, we overlooked the possibility of a schwannoma and performed preventive parotidectomy, owing to limited preoperative radiological evaluations. In addition, we did not detect any nerve impingement intraoperatively, and consequently only the mass was excised, despite it being a basic surgical principle for schwannomas that the fascicle should be preserved. However, despite these pre-and intraoperative diagnostic limitations, the entire mass was successfully excised, and the patient did not show any evidence of surgery-induced neuropathy. For superficial parotidectomy, a modified-Blair incision was used to minimize incisional scarring, and the SMAS layer folding method was performed to fill the dead space so that surgical complications were minimal.

## CONCLUSION

Facial schwannomas in the cheek region are rare and preoperative evaluation has some limitations. Despite these limitations, our surgical approach of superficial parotidectomy using a modified-Blair incision and the SMAS layer-folding method achieved aesthetically good postoperative outcomes.

## FOOTNOTES

**Author contributions:** Nam HJ contributed to manuscript writing, visualization, and data collection; Byeon JY contributed to conceptualization and methodology; Choi HJ contributed to project administration; Wee SY contributed to manuscript review, editing, and supervision; all authors have read and approved the final manuscript.

**Supported by** Soonchunhyang Research Fund, No. 2023-0030.

**Informed consent statement:** The patient provided written informed consent for the publication and use of her images.

**Conflict-of-interest statement:** No potential conflict of interest relevant to this article was reported.



**CARE Checklist (2016) statement:** The authors have read the CARE Checklist (2016), and the manuscript was prepared and revised according to the CARE Checklist (2016).

**Open-Access:** This article is an open-access article that was selected by an in-house editor and fully peer-reviewed by external reviewers. It is distributed in accordance with the Creative Commons Attribution NonCommercial (CC BY-NC 4.0) license, which permits others to distribute, remix, adapt, build upon this work non-commercially, and license their derivative works on different terms, provided the original work is properly cited and the use is non-commercial. See: <https://creativecommons.org/licenses/by-nc/4.0/>

**Country/Territory of origin:** South Korea

**ORCID number:** Ha-Jong Nam 0000-0002-2494-0991; Hwan Jun Choi 0000-0002-0752-0389; Je-Yeon Byeon 0000-0002-1948-0687; Syeo-Young Wee 0000-0002-1787-9715.

**S-Editor:** Yan JP

**L-Editor:** A

**P-Editor:** Yan JP

## REFERENCES

- 1 Lin CC, Tsai MH, Huang CC, Hua CH, Tseng HC, Huang ST. Parotid tumors: a 10-year experience. *Am J Otolaryngol* 2008; **29**: 94-100 [PMID: 18314019 DOI: 10.1016/j.amjoto.2007.03.002]
- 2 Sungur N, Akan IM, Ulusoy MG, Ozdemir R, Kiling H, Ortak T. Clinicopathological evaluation of parotid gland tumors: a retrospective study. *J Craniofac Surg* 2002; **13**: 26-30 [PMID: 11886987 DOI: 10.1097/00001665-200201000-00004]
- 3 Maahs GS, Oppermann Pde O, Maahs LG, Machado Filho G, Ronchi AD. Parotid gland tumors: a retrospective study of 154 patients. *Braz J Otorhinolaryngol* 2015; **81**: 301-306 [PMID: 25934418 DOI: 10.1016/j.bjorl.2015.03.007]
- 4 Bailey H. The tumors of the parotid gland with special reference to total parotidectomy. *Br J Surg* 1941; **28**: 337-346 [DOI: 10.1002/bjs.18002811102]
- 5 Simone M, Vesperini E, Viti C, Camaioni A, Lepanto L, Raso F. Intraparotid facial nerve schwannoma: two case reports and a review of the literature. *Acta Otorhinolaryngol Ital* 2018; **38**: 73-77 [PMID: 29756618 DOI: 10.14639/0392-100X-1170]
- 6 Bhaker P, Chatterjee D, Gochhait D, Radotra BD, Dey P. Schwannoma of the parotid gland: Diagnosis by fine-needle aspiration cytology. *J Cytol* 2014; **31**: 196-198 [PMID: 25745284 DOI: 10.4103/0970-9371.151130]
- 7 Neely JG, Alford BR. Facial nerve neuromas. *Arch Otolaryngol* 1974; **100**: 298-301 [PMID: 4413411 DOI: 10.1001/archotol.1974.00780040308012]
- 8 Avery AP, Sprinkle PM. Benign intraparotid schwannomas. *Laryngoscope* 1972; **82**: 199-203 [PMID: 5014385 DOI: 10.1288/00005537-197202000-00006]
- 9 Guzzo M, Ferraro L, Ibba T, Quattrone P, Bianchi R, Rezzonico S, Scaramellini G. Schwannoma in the parotid gland. Experience at our institute and review of the literature. *Tumori* 2009; **95**: 846-851 [PMID: 20210258 DOI: 10.1177/030089160909500636]
- 10 Shashinder S, Tang IP, Velayutham P, Prepageran N, Gopala KG, Kuljit S, Anura MM, Chong SY. A review of parotid tumours and their management: a ten-year-experience. *Med J Malaysia* 2009; **64**: 31-33 [PMID: 19852317 DOI: 10.1097/00007611-198012000-00045]
- 11 Hwang JH, Lee DG, Sim HS, Kim KS, Lee SY. Intramasseptic schwannoma treated with facelift incision and retrograde facial nerve dissection. *Arch Craniofac Surg* 2019; **20**: 388-391 [PMID: 31914494 DOI: 10.7181/acfs.2019.00549]
- 12 Baliga M, Uppal N, Ramanathan A. Schwannomas of the head and neck: a case series. *J Maxillofac Oral Surg* 2009; **8**: 283-286 [PMID: 23139527 DOI: 10.1007/s12663-009-0069-9]
- 13 Rigante M, Petrelli L, DE Corso E, Paludetti G. Intracapsular microenucleation technique in a case of intraparotid facial nerve schwannoma. Technical notes for a conservative approach. *Acta Otorhinolaryngol Ital* 2015; **35**: 49-52 [PMID: 26015652 DOI: 10.1016/j.jcms.2016.09.012]



Published by **Baishideng Publishing Group Inc**  
7041 Koll Center Parkway, Suite 160, Pleasanton, CA 94566, USA

**Telephone:** +1-925-3991568

**E-mail:** [bpgoffice@wjgnet.com](mailto:bpgoffice@wjgnet.com)

**Help Desk:** <https://www.f6publishing.com/helpdesk>

<https://www.wjgnet.com>

