

World Journal of *Clinical Cases*

World J Clin Cases 2023 October 6; 11(28): 6670-6973



MINIREVIEWS

- 6670 Neurotransmitters regulate β cells insulin secretion: A neglected factor
Kong CC, Cheng JD, Wang W

ORIGINAL ARTICLE

Case Control Study

- 6680 Factors influencing the surveillance of re-emerging intracranial infections in elective neurosurgical patients: A single-center retrospective study
Wang JL, Wu XW, Wang SN, Liu X, Xiao B, Wang Y, Yu J

Retrospective Study

- 6688 Clinical value of chemiluminescence method for detection of antinuclear antibody profiles
Xiang HY, Xiang XY, Ten TB, Ding X, Liu YW, Luo CH
- 6698 Value of ultrasound guided biopsy combined with Xpert *Mycobacterium tuberculosis*/resistance to rifampin assay in the diagnosis of chest wall tuberculosis
Yan QH, Chi JY, Zhang L, Xue F, Cui J, Kong HL
- 6707 Research on the intelligent internet nursing model based on the child respiratory and asthma control test scale for asthma management of preschool children
Pei CF, Zhang L, Xu XY, Qin Z, Liang HM
- 6715 Effects of different doses of long-acting growth hormone in treating children with growth hormone deficiency
Xia W, Wang T, Pan JY
- 6725 Efficacy and anti-inflammatory analysis of glucocorticoid, antihistamine and leukotriene receptor antagonist in the treatment of allergic rhinitis
Qiu C, Feng D
- 6733 Subchondral fatigue fracture of the femoral head in young military recruits: Potential risk factors
Yang JZ, Chen P, Chen BH, Zhao B
- 6744 Anemia status of infants and young children aged six to thirty-six months in Ma'anshan City: A retrospective study
Wang XM, Wang QY, Huang J
- Observational Study
- 6754 Impact of coronary artery bypass grafting surgery on the chorioretinal biomicroscopic characteristics
Shahriari M, Nikkhah H, Mahjoob MP, Behnaz N, Barkhordari S, Cheraqpour K

Prospective Study

- 6763** Effects of humanized nursing care on negative emotions and complications in patients undergoing hysteromyoma surgery
Liu L, Xiao YH, Zhou XH

Randomized Controlled Trial

- 6774** Randomized controlled trial on the efficacy and safety of autologous serum eye drops in dry eye syndrome
Zheng N, Zhu SQ

SYSTEMATIC REVIEWS

- 6782** Primary adrenal Ewing sarcoma: A systematic review of the literature
Manatakis DK, Tsouknidas I, Mylonakis E, Tasis N, Antonopoulou MI, Acheimastos V, Mastoropoulou A, Korkolis DP

CASE REPORT

- 6792** Pulmonary artery aneurysm protruding into the bronchus as an endobronchial mass: A case report
Li M, Zhu WY, Wu RR, Wang L, Mo MT, Liu SN, Zhu DY, Luo Z
- 6797** Rare rectal gastrointestinal stromal tumor case: A case report and review of the literature
Dong RX, Wang C, Zhou H, Yin HQ, Liu Y, Liang HT, Pan YB, Wang JW, Cao YQ
- 6806** Bilateral retinal nerve fiber layer thickness reduction in a 9-year-old myopic boy suffering from unilateral optic neuritis: A case report
Zhao FF, Yao SQ, Wang Y, Li TP, Yang JF, Pang CP, Cen LP
- 6812** Application of negative pressure wound therapy after skin grafting in the treatment of skin cancer: A case report
Huang GS, Xu KC
- 6817** Diagnosis and treatment of McCune-Albright syndrome: A case report
Lin X, Feng NY, Lei YJ
- 6823** Paraneoplastic myopathy-related rhabdomyolysis and pancreatic cancer: A case report and review of the literature
Costantini A, Moletta L, Pierobon ES, Serafini S, Valmasoni M, Sperti C
- 6831** Multi-organ hereditary hemorrhagic telangiectasia: A case report
Chen YL, Jiang HY, Li DP, Lin J, Chen Y, Xu LL, Gao H
- 6841** Hyperprogression after anti-programmed death-1 therapy in a patient with urothelial bladder carcinoma: A case report
Yang HY, Du YX, Hou YJ, Lu DR, Xue P
- 6850** Effectiveness of antidepressant repetitive transcranial magnetic stimulation in a patient with refractory psychogenic dysphagia: A case report and review of literature
Woo CG, Kim JH, Lee JH, Kim HJ

- 6857** Entrapment neuropathy of common peroneal nerve by fabella: A case report
Lin JC, Tsai MH, Lin WP, Kuan TS, Lien WC
- 6864** Importance of accurate diagnosis of congenital agenesis of the gallbladder from atypical gallbladder stone presentations: A case report
Sun HJ, Ge F, Si Y, Wang Z, Sun HB
- 6871** Dorsal approach for isolated volar fracture-dislocation of the base of the second metacarpal: A case report
Kurozumi T, Saito M, Odachi K, Masui F
- 6877** Rotationplasty type BIIIb as an effective alternative to limb salvage procedure in adults: Two case reports
Chen ZX, Guo XW, Hong HS, Zhang C, Xie W, Sha M, Ding ZQ
- 6889** Primary cutaneous anaplastic large cell lymphoma with over-expressed Ki-67 transitioning into systemic anaplastic large cell lymphoma: A case report
Mu HX, Tang XQ
- 6895** Confusing finding of quantitative fluorescent polymerase chain reaction analysis in invasive prenatal genetic diagnosis: A case report
Chen C, Tang T, Song QL, He YJ, Cai Y
- 6902** Testicular mixed germ cell tumor: A case report
Xiao QF, Li J, Tang B, Zhu YQ
- 6908** Leukemic transformation during anti-tuberculosis treatment in aplastic anemia-paroxysmal nocturnal hemoglobinuria syndrome: A case report and review of literature
Xiu NN, Yang XD, Xu J, Ju B, Sun XY, Zhao XC
- 6920** Pancreatic arteriovenous malformation treated with transcatheter arterial embolization: Two case reports and review of literature
Shin SH, Cho CK, Yu SY
- 6931** Cecal duplication cyst in an infant presenting as shock: A case report
Kim SM, Lee SH, Park GY, Kim SS, Lee CG, Jin SJ
- 6938** Pulmonary reversed halo cycles and consolidations after immunotherapy: A case report
Suo H, Shi YJ, Huang ZD, Xu K, Huang H
- 6943** Unusual case of emphysematous cystitis mimicking intestinal perforation: A case report
Kang HY, Lee DS, Lee D
- 6949** Malignant proliferative ependymoma of the neck with lymph node metastasis: A case report
Wang K, Wen JZ, Zhou SX, Ye LF, Fang C, Chen Y, Wang HX, Luo X
- 6955** Wandering spleen torsion with portal vein thrombosis: A case report
Zhu XY, Ji DX, Shi WZ, Fu YW, Zhang DK

- 6961** Intracranial infection and sepsis in infants caused by *Salmonella derby*: A case report
Yu JL, Jiang LL, Dong R, Liu SY
- 6967** Large gastric hamartomatous inverted polyp accompanied by advanced gastric cancer: A case report
Park G, Kim J, Lee SH, Kim Y

ABOUT COVER

Editorial Board Member of *World Journal of Clinical Cases*, Hao Wang, MD, PhD, Associate Professor, Department of Emergency Medicine, John Peter Smith Health Network, Texas Christian University and University of North Texas Health Science Center, School of Medicine, Fort Worth, TX 76104, United States. hwang@ies.healthcare

AIMS AND SCOPE

The primary aim of *World Journal of Clinical Cases* (*WJCC*, *World J Clin Cases*) is to provide scholars and readers from various fields of clinical medicine with a platform to publish high-quality clinical research articles and communicate their research findings online.

WJCC mainly publishes articles reporting research results and findings obtained in the field of clinical medicine and covering a wide range of topics, including case control studies, retrospective cohort studies, retrospective studies, clinical trials studies, observational studies, prospective studies, randomized controlled trials, randomized clinical trials, systematic reviews, meta-analysis, and case reports.

INDEXING/ABSTRACTING

The *WJCC* is now abstracted and indexed in Science Citation Index Expanded (SCIE, also known as SciSearch®), Journal Citation Reports/Science Edition, Current Contents®/Clinical Medicine, PubMed, PubMed Central, Reference Citation Analysis, China National Knowledge Infrastructure, China Science and Technology Journal Database, and Superstar Journals Database. The 2023 Edition of Journal Citation Reports® cites the 2022 impact factor (IF) for *WJCC* as 1.1; IF without journal self cites: 1.1; 5-year IF: 1.3; Journal Citation Indicator: 0.26; Ranking: 133 among 167 journals in medicine, general and internal; and Quartile category: Q4.

RESPONSIBLE EDITORS FOR THIS ISSUE

Production Editor: *Si Zhao*; Production Department Director: *Xu Guo*; Editorial Office Director: *Jin-Lei Wang*.

NAME OF JOURNAL

World Journal of Clinical Cases

ISSN

ISSN 2307-8960 (online)

LAUNCH DATE

April 16, 2013

FREQUENCY

Thrice Monthly

EDITORS-IN-CHIEF

Bao-Gan Peng, Jerzy Tadeusz Chudek, George Kontogeorgos, Maurizio Serati, Ja Hyeon Ku

EDITORIAL BOARD MEMBERS

<https://www.wjgnet.com/2307-8960/editorialboard.htm>

PUBLICATION DATE

October 6, 2023

COPYRIGHT

© 2023 Baishideng Publishing Group Inc

INSTRUCTIONS TO AUTHORS

<https://www.wjgnet.com/bpg/gerinfo/204>

GUIDELINES FOR ETHICS DOCUMENTS

<https://www.wjgnet.com/bpg/GerInfo/287>

GUIDELINES FOR NON-NATIVE SPEAKERS OF ENGLISH

<https://www.wjgnet.com/bpg/gerinfo/240>

PUBLICATION ETHICS

<https://www.wjgnet.com/bpg/GerInfo/288>

PUBLICATION MISCONDUCT

<https://www.wjgnet.com/bpg/gerinfo/208>

ARTICLE PROCESSING CHARGE

<https://www.wjgnet.com/bpg/gerinfo/242>

STEPS FOR SUBMITTING MANUSCRIPTS

<https://www.wjgnet.com/bpg/GerInfo/239>

ONLINE SUBMISSION

<https://www.f6publishing.com>



Primary adrenal Ewing sarcoma: A systematic review of the literature

Dimitrios K Manatakis, Ioannis Tsouknidas, Emmanouil Mylonakis, Nikolaos Tasis, Maria Ioanna Antonopoulou, Vasileios Acheimastos, Aikaterini Mastoropoulou, Dimitrios P Korkolis

Specialty type: Medicine, research and experimental

Provenance and peer review: Invited article; Externally peer reviewed.

Peer-review model: Single blind

Peer-review report's scientific quality classification

Grade A (Excellent): 0
Grade B (Very good): B
Grade C (Good): 0
Grade D (Fair): D
Grade E (Poor): 0

P-Reviewer: Ma X, China; Wiemer EA, Netherlands

Received: April 20, 2023

Peer-review started: April 20, 2023

First decision: June 12, 2023

Revised: July 18, 2023

Accepted: September 12, 2023

Article in press: September 12, 2023

Published online: October 6, 2023



Dimitrios K Manatakis, Emmanouil Mylonakis, Nikolaos Tasis, Vasileios Acheimastos, 2nd
Department of Surgery, Athens Naval and Veterans Hospital, Athens 11521, Greece

Ioannis Tsouknidas, General Surgery, Lankenau Medical Center, Main Line Health, Wynnewood, PA 19096, United States

Nikolaos Tasis, Dimitrios P Korkolis, Department of Surgical Oncology, St Savvas Cancer Hospital, Athens 11522, Greece

Maria Ioanna Antonopoulou, Department of Surgery, Naval Hospital of Crete, Chania 73200, Greece

Aikaterini Mastoropoulou, Department of Pediatrics, Stony Brook University Hospital, Stony Brook, NY 11794, United States

Corresponding author: Ioannis Tsouknidas, MD, MSc, Research Fellow, Surgeon, General Surgery, Lankenau Medical Center, Main Line Health, No. 100E Lancaster Ave, Wynnewood, PA 19096, United States. tsouknidasioannis@gmail.com

Abstract

BACKGROUND

Ewing sarcoma (ES) is a malignant neoplasm of neuroectodermal origin and is commonly observed in children and young adults. The musculoskeletal system is the main body system impacted and ES is rarely seen in the visceral organs particularly the adrenal gland.

AIM

To present a comprehensive review of primary adrenal ES, with emphasis on diagnosis, therapy and oncological outcomes.

METHODS

A systematic review of the literature was performed according to the Preferred Reporting Items for Systematic reviews and Meta-Analyses 2020. PubMed/MEDLINE, EMBASE and Google Scholar bibliographic databases were searched to identify articles from 1989 to 2022 and included patients with ES/primitive neuroectodermal tumor (PNET) of the adrenal gland. PubMed, Google Scholar and EMBASE medical databases were searched, combining the terms "adrenal", "ES" and "PNET". Demographic, clinical, pathological and oncological data of

patients were analyzed by SPSS version 29.0.

RESULTS

A total of 52 studies were included for review (47 case reports and 5 case series) with 66 patients reported to have primary adrenal ES. Mean age at diagnosis was 26.4 ± 15.4 years (37.9% males, 57.6% females, sex not reported in 3 cases). The most frequent complaint was abdominal/flank pain or discomfort (46.4%) followed by a palpable mass (25.0%), and the average duration of symptoms was 2.6 ± 3.1 mo. The imaging modality of choice was computed tomography scan (81.5%), followed by magnetic resonance imaging (20.4%). Preoperative staging revealed that 17 tumors (27.9%) were metastatic and 14 patients had inferior vena cava or renal vein neoplastic thrombus at initial diagnosis. Open adrenalectomy was performed in the majority of cases (80.0%), of which 27.9% required more extensive resection. Minimally invasive surgery was attempted in 8.2% of tumors. Complete surgical resection was achieved in 89.4% of the patients. Adjuvant therapy was administered to 32 patients, in the form of chemotherapy (62.5%), radiotherapy (3.1%) or combination (34.4%). Median overall survival was 15 mo and 24-mo overall survival was 40.5%. Median disease-free survival was 10 mo and 24-mo disease-free survival was 33.3%.

CONCLUSION

The significant progress in molecular biology and genetics of ES does not reflect on patient outcomes. ES remains an aggressive tumor with a poor prognosis and high mortality.

Key Words: Ewing sarcoma; Primary adrenal tumor; Adrenalectomy

©The Author(s) 2023. Published by Baishideng Publishing Group Inc. All rights reserved.

Core Tip: Primary adrenal Ewing sarcoma (ES) is uncommon with 66 cases reported in the literature since 1989. Patients usually present within the first year from the initiation of symptoms, most frequently complaining of abdominal/flank pain or discomfort, followed by a palpable mass. Open adrenalectomy is the procedure of choice, while minimally invasive techniques are anticipated to be performed more frequently in the future. Regardless of the technique, surgical resection is achieved in the vast majority of cases. The significant progress in molecular biology and genetics of ES over the past decade does not reflect on patient outcomes. ES remains an aggressive tumor with a poor prognosis and high mortality.

Citation: Manatakis DK, Tsouknidas I, Mylonakis E, Tasis N, Antonopoulou MI, Acheimastos V, Mastoropoulou A, Korkolis DP. Primary adrenal Ewing sarcoma: A systematic review of the literature. *World J Clin Cases* 2023; 11(28): 6782-6791

URL: <https://www.wjgnet.com/2307-8960/full/v11/i28/6782.htm>

DOI: <https://dx.doi.org/10.12998/wjcc.v11.i28.6782>

INTRODUCTION

First described by James Ewing in 1921 as “diffuse endothelioma of bone,” Ewing sarcoma (ES) is the second most common primary bone malignancy during childhood and adolescence[1,2]. Along with primitive neuroectodermal tumors (PNET) and Askin tumors, ESs belong to the ES family of tumors (ESFT). The ESFT are aggressive childhood cancers, which histologically belong to the small round blue cell sarcomas[3].

Although the cell of origin of ES remains unknown, ESFT are characterized by chromosomal translocation between the TET/FET family genes and E26 transformation specific family genes[4]. Approximately 85% of ESs exhibit the reciprocal translocation $t(11; 22)(q24; q12)$. This genetic alteration results in the chimeric fusion protein EWS RNA binding protein 1-Friend leukemia integration 1 (EWSR1-FLI1), which allows the N-terminus of EWSR1 and the C-terminus of FLI1 to bind transcriptional complexes and target genes. The target genes are involved in tumor cell immortalization, angiogenesis, cancer stemness, tumor growth, chemotherapy resistance, transcriptional regulation, and cell-to-cell signaling. NR0B1 (DAX1), GLI1 and FOXO1 have been shown in the literature to be the genes involved in the tumorigenesis of ES[4].

The majority of ES/PNET tumors are found in the skeletal system, with only 10%-20% arising in extra-skeletal sites[5]. Visceral and particularly adrenal occurrence is even more infrequent. The morphology between ESFT may vary; however, skeletal and extra-skeletal ESFT are molecularly indistinguishable[6]. Despite recent advances in molecular biology, therapeutic protocols are not standardized due to limited knowledge and are derived from other types of sarcomas. The aim of the current study is to present an up-to-date, systematic review of the literature on primary adrenal ES/PNET, with emphasis on diagnosis, therapy and oncological outcomes.

MATERIALS AND METHODS

A systematic review of the English literature was performed according to the Preferred Reporting Items for Systematic reviews and Meta-Analyses 2020 statement[7]. PubMed/MEDLINE, EMBASE and Google Scholar bibliographic databases were searched to identify patients with ES/PNET of the adrenal gland from 1989 to 2022. The keywords “Ewing sarcoma”, “primitive neuroectodermal tumor”, “PNET” and “adrenal” were used in all possible combinations. Furthermore, the reference lists of all eligible papers were assessed for additional articles.

All study designs except conference abstracts and commentaries were considered eligible. Both adult and pediatric cases were included in the review. Non-English articles were excluded. Titles and abstracts of all articles from the initial search were independently screened by two authors. Articles, including case reports, case series, observational and clinical trial studies, were considered eligible for full text review, as long as they reported on cases of primary ES/PNET. Any discrepancies were arbitrated by all authors. A flow chart of the search strategy is shown in Figure 1.

For each eligible patient, demographic data (age, sex), clinical characteristics (presenting symptom, duration of symptoms, hormone hypersecretion, imaging modalities, size, laterality), treatment (preoperative staging, neoadjuvant treatment, extent of surgery, adjuvant treatment), histopathology (completeness of resection, immunohistochemistry, molecular testing) and oncological outcomes (overall and disease-free survival) were collected.

Statistical analysis was performed by SPSS version 29.0. All data were tabulated and outcomes were cumulatively analyzed. Continuous variables were expressed as mean±standard deviation, while categorical variables were expressed as frequencies or percentages. Kaplan-Meier survival analysis was applied to calculate 24-mo overall and disease-free survival. A descriptive approach was followed, due to limited data.

RESULTS

Fifty-two studies (47 case reports and 5 case series) were included in the final analysis, describing a total of 66 patients (Supplementary Table 1)[8-59]. The demographic and clinical characteristics are shown in Table 1. As shown in Figure 2, a majority of the reported cases were from China, United States and India. Twenty-five patients were males (37.9%) and 38 were females (57.6%) (sex not reported in 3 cases). Mean age at diagnosis was 26.4 ± 15.4 years (range 2-74). The most frequent complaint was abdominal/flank pain or discomfort (26 cases, 46.4%) followed by a palpable mass (14 cases, 25.0%). In 10 patients (17.9%), the tumor was an incidental finding during imaging studies for an unrelated reason. Mean duration of symptoms was 2.6 ± 3.1 mo (range 2 d to 1 year). Preoperative hormone panels were reported in 42 patients and hormonal hypersecretion was observed in 5 cases (11.9%). The imaging modality of choice was computed tomography (CT) scan (44 cases, 81.5%), followed by magnetic resonance imaging (MRI) (11 cases, 20.4%). Further imaging with positron emission tomography-CT (PET-CT) was required in 6 cases (11.1%) (data not reported in 12 cases). Mean tumor size at diagnosis was 11.4 ± 4.8 cm (range 3-24 cm). Twenty-seven patients had right-sided tumors, 28 patients had left-sided tumors (48.2% and 50.0%, respectively), and one patient had bilateral tumors (1.8%) (data not reported in 10 cases).

Preoperative staging revealed that 17 tumors (27.9%) were metastatic at initial diagnosis, and 14 patients (23.0%) presented with inferior vena cava (IVC) or renal vein neoplastic thrombus. Ten patients (18.9%) received neoadjuvant chemotherapy preoperatively. Operative and pathological characteristics are shown in Table 2. Open adrenalectomy was the procedure of choice in the majority of cases (48 cases, 80.0%). Of the patients in the open adrenalectomy group, 17 patients (27.9%) required more extensive resections (usually ipsilateral nephrectomy). Minimally invasive laparoscopic and robotic approaches were attempted in 4 (6.6%) and 1 case (1.6%), respectively. Seven patients (11.7%) underwent biopsy instead of resection. Complete surgical resection (R0) was achieved in 89.4% (42/47). Immunohistochemistry staining for CD99 was positive in 98.4% (60/61) of patients. Molecular testing for the translocation EWSR1-FLI1 was performed in 27 patients, all of which were positive. Adjuvant therapy was reported in 32 patients, in the form of chemotherapy (62.5%), radiotherapy (3.1%) or chemoradiotherapy (34.4%).

Survival data were available for 42 patients. Median overall survival was 15 mo (95%CI: 9.4-20.6). 24-mo overall survival was 40.5%. Median disease-free survival was 10 mo (95%CI: 4.3-15.7). 24-mo disease-free survival was 33.3%.

DISCUSSION

ES is an aggressive primary osseous tumor[60]. Extra-skeletal sites involving soft tissue and visceral tumors constitute only 10%-20% of ESs. Soft tissue ES/PNET can be found in the muscle, connective tissue, lymph nodes, and other tissue of mesenchymal origin. Visceral ES/PNET sites include the lungs, gastrointestinal tract, prostate, brain, endometrium, thyroid and adrenal gland[45]. Our review is the first systematic review focusing on primary adrenal ES/PNET. This study yielded 66 cases between 1989 and 2022, showcasing the low prevalence of this disorder.

Clinical presentation of ES/PNET varies depending on the location of the tumor. A large, rapidly growing, solitary mass, can cause mass effects or invade nearby structures. Symptoms include constitutional symptoms, such as fever, weight loss, anorexia, pain and bleeding[61]. Our study showed that pain and discomfort were the primary complaints, followed by a palpable mass.

All patients in our study were diagnosed within one year from onset of symptoms (mean duration 2.6 mo). Half of the patients were found to have metastasis or IVC/renal vein neoplastic thrombus at the time of diagnosis. This shows that diagnosis typically occurs when these tumors have reached an advanced stage, suggesting its aggressive nature. Only

Table 1 Demographics and clinical characteristics

| | Number of patients | Percentage (%) |
|---------------------------|------------------------------|----------------|
| Gender | | |
| Male | 25 | 37.9 |
| Female | 38 | 57.6 |
| Not reported | 3 | 4.5 |
| Age (yr) | 26.4 ± 15.4 (range 2-74) | |
| Presentation | Reported in 56 patients | |
| Abdominal/flank pain | 26 | 46.4 |
| Palpable mass | 14 | 25.0 |
| Incidentaloma | 10 | 17.9 |
| Mean duration of symptoms | 2.6 ± 3.1 mo (range 2-365 d) | |
| Hormone hypersecretion | 5/42 | 11.9 |
| Imaging modality | Reported in 54 patients | |
| CT scan | 44 | 81.5 |
| MRI | 11 | 20.4 |
| PET-CT | 6 | 11.1 |
| Not reported | 12 | |
| Laterality | Reported in 56 patients | |
| Right | 27 | 48.2 |
| Left | 28 | 50.0 |
| Bilateral | 1 | 1.8 |
| Not reported | 10 | |
| Mean tumor size (cm) | 11.4 ± 4.8 range 3-24 | |

CT: Computed tomography; MRI: Magnetic resonance imaging; PET-CT: Positron emission tomography-computed tomography.

17.9% of our cases were diagnosed incidentally, which is in contrast to other adrenocortical tumors[62].

A CT scan, MRI and PET-CT are the first line imaging modalities performed to detect the tumor. Adrenal ES/PNET can present as a large size, nonfunctional mass[61]. However, imaging is limited to staging of the patient, differentiate metastatic from primary ES/PNET, and to assist with the surgical planning.

Tissue examination, immunohistochemical and genetic tests are necessary for diagnostic purposes. Histopathologically, ES/PNETs can be differentiated from other adrenocortical carcinomas. ES/PNETs are seen as small round cell tumors. The 32-kDa cell surface glycoprotein has also demonstrated significant use as a screening tool given its high sensitivity (as high as 95%), although specificity is low[63]. Immunohistochemical staining for CD99 is essential to support the diagnosis of ES/PNET from other small round cell tumors. In our review, immunohistochemistry staining for CD99 was tested in the majority of cases assisting in diagnosis (61 cases). Molecular testing to identify the most common mutations, such as *t* (11; 22) (q24; q12) (80% to 90% of ES/PNET), *t* (21; 12) (22; 12) (10%), could provide meaningful data for diagnostic purposes. However it is currently not the standard of care.

Specific instructions for the treatment of ES/PNET have not been published to date. In the majority of cases, these tumors are treated according to the soft tissue sarcoma guidelines. These guidelines are published by the European Society of Medical Oncology and the National Comprehensive Cancer Network, which includes recommendations for the treatment of visceral sarcomas[64,65]. According to the guidelines, surgical excision with negative R0 is the preferred initial treatment. If R0 margins are not obtained with the index procedure, a second excision can be performed. Planned close margins or even microscopically positive margins (R1) may be acceptable in certain cases, to preserve critical neurovascular structures. Post-operative radiation should be considered in tumors with R0 or R1 margins in order to reduce recurrence. This is especially indicated when the soft tissue tumor margin or the microscopic margin are positive proximal to bone tissue, major blood vessels or major nerves. Other adjuvant options include systemic therapy and/or chemotherapy. Neoadjuvant treatment, with radiation and/or systemic treatment, is performed in tumors deemed unresectable, to downsize the cancer or provide palliative measures.

In our review, the majority of the patients were treated surgically in accordance to the existing guidelines. Open adrenalectomy (80.0%) or more extensive resection (27.9%) were the procedures performed most frequently. Laparoscopic

Table 2 Operative and pathological characteristics

| | Number of patients | Percentage (%) |
|---|-------------------------|----------------|
| Metastatic disease | | |
| Metastatic during initial diagnosis | 17/61 | 27.9 |
| Inferior vena cava/renal vein neoplastic thrombus | 14/61 | 23.0 |
| Treatment | | |
| Neoadjuvant chemotherapy | 10/53 | 18.9 |
| Open adrenalectomy | 48/60 | 80.0 |
| Extensive resection | 17/60 | 27.9 |
| Laparoscopic resection | 4/60 | 6.6 |
| Robotic resection | 1/60 | 1.6 |
| Biopsy without resection | 7/60 | 11.7 |
| Complete surgical resection | 42/47 | 89.4 |
| Tumor confirmation testing | | |
| Positive CD99 immunohistochemistry staining | 60/61 | 98.4 |
| Positive molecular EWSR1-FLI1 translocation | 27/27 patients | 100 |
| Adjuvant therapy | Required in 32 patients | |
| Chemotherapy | 20/32 | 62.5 |
| Radiotherapy | 1/32 | 3.1 |
| Chemoradiotherapy | 11/32 | 34.4 |
| Outcomes | | |
| Survival data | 42 patients | |
| Median overall survival | 15 mo | |
| 24-mo overall survival | 17/42 | 40.5 |
| Median disease-free survival | 10 mo | |
| 24-mo disease-free survival | 14/42 | 33.3 |

EWSR1-FLI1: EWS RNA binding protein 1-Friend leukemia integration 1.

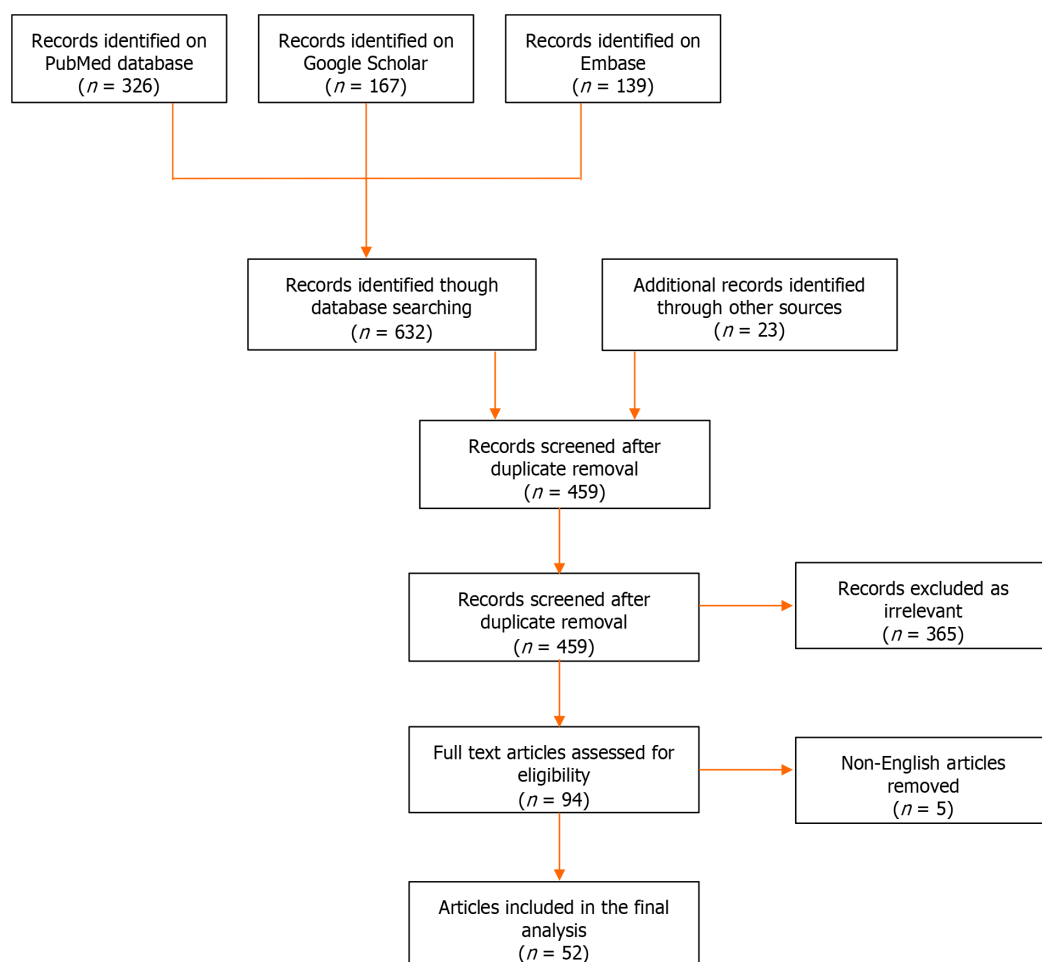
or robotic surgery was selected in a small number of tumors (8.2%). These were observed mostly in the last decade, although this is anticipated to become more frequent in the future, as technology advances and minimal invasive surgical techniques become more dominant. Neoadjuvant treatment was administered in 18.9% of patients, to downsize the tumor, prior to surgical excision. Negative margins were obtained in the vast majority of the patients (89.4%). Adjuvant therapy was performed, mostly with chemotherapy or chemoradiation, in order to eliminate micrometastases and increase the 5-year survival rate[66].

Despite multisystem treatment modalities, the average survival rate was found to be approximately 15 mo in our study. Less than half of the population demonstrated 24-mo survival and one-third of patients were deemed free of disease at that time. This shows the high recurrence rate of the disease.

Research in ES during the last years has focused on the identification of DNA fragments, which could potentially detect and distinguish between different cancer types and subcategories, monitor disease progression over time, as well as estimate survival and relapse probabilities at the time of diagnosis[67]. In addition, artificial intelligence has led to the development of large databases, biobanks and radiomics. In the future, both biomarkers and artificial intelligence science are anticipated to assist with stratifying patients into specific groups by creating patient profiles who share common features. These tools will lead to the development of individualized treatments and prognostic treatment-response scores in chemotherapy and/or radiotherapy[68,69].

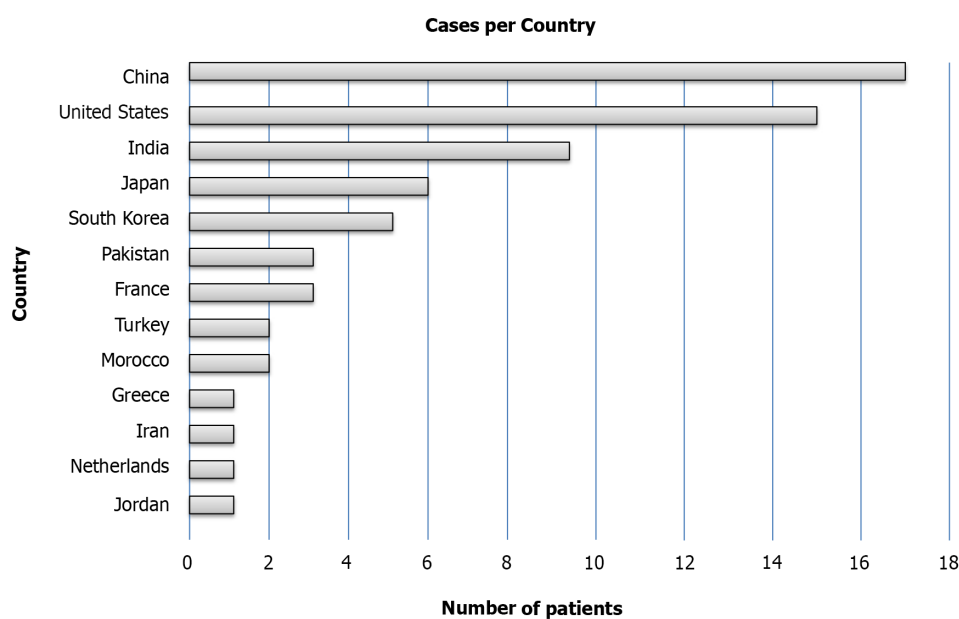
CONCLUSION

Primary adrenal ES is uncommon with 67 cases reported in the literature since 1990. Diagnosis is usually achieved within one year from the onset of symptoms. Open adrenalectomy has been the procedure of choice, although minimally



DOI: 10.12998/wjcc.v11.i28.6782 Copyright ©The Author(s) 2023.

Figure 1 Flow chart of the search strategy.



DOI: 10.12998/wjcc.v11.i28.6782 Copyright ©The Author(s) 2023.

Figure 2 Regional distribution of reported cases.

invasive techniques are anticipated to be performed more frequently in the near future. The recurrence rate within 24 mo is quite high, which proves the aggressive character of the tumor. The significant progress in molecular biology and artificial intelligence promises big achievements in the future in terms of diagnosis and treatment of ES.

ARTICLE HIGHLIGHTS

Research background

Ewing sarcoma (ES) is an aggressive malignant primary osseous tumor, which is commonly observed in the young population. Visceral organs and particularly adrenal glands are rarely impacted.

Research motivation

Therapeutic protocols for the treatment of ES/primitive neuroectodermal tumor (PNET) are not standardized and these tumors are treated according to the soft tissue sarcoma guidelines of the European Society of Medical Oncology (ESMO) and National Comprehensive Cancer Network (NCCN), due to limited knowledge.

Research objectives

The aim of the present study is to present an up-to-date, systematic review of the literature on primary adrenal ES/PNET, with emphasis on diagnosis, therapy and oncological outcomes.

Research methods

A systematic review of the literature was performed according to the Preferred Reporting Items for Systematic reviews and Meta-Analyses 2020 statement. PubMed/MEDLINE, EMBASE and Google Scholar bibliographic databases were searched to identify articles that included patients with ES/PNET of the adrenal gland from 1989 to 2022. Demographic, clinical, pathological and oncological data of patients were analyzed by SPSS version 29.0.

Research results

Fifty-two studies were included in the current systematic review, describing a total of 66 patients. The mean age at diagnosis was 26.4 years and the most frequent complaint was abdominal or flank pain/discomfort. At the time of diagnosis, average tumor size was 11.4 cm. 27.9% of the tumors were metastatic and 23.0% had inferior vena cava or renal vein neoplastic thrombus. Open adrenalectomy was the procedure of choice (80.0% of patients), and a more extensive resection was required in 27.0% of these patients. Immunohistochemistry staining for CD99 was positive in 98.4%, and molecular testing for the translocation EWS RNA binding protein 1-Friend leukemia integration 1 was positive in all the patients tested. Median overall survival was 15 mo and 24-mo overall survival was 40.5%.

Research conclusions

Primary adrenal ES/PNET is a tumor with low prevalence. Diagnosis typically occurs when the tumor has reached an advanced stage. Immunohistochemical staining for CD99 is essential to support the diagnosis of ES/PNET from other small round cell tumors. To date, these tumors are treated according to the soft tissue sarcoma guidelines of ESMO and NCCN, with surgical excision and negative surgical margins being the preferred treatment of choice, when feasible. Unfortunately, the disease has a high recurrence rate, and a relatively low survival rate.

Research perspectives

In the future, minimally invasive techniques will be used more frequently in the surgical treatment of primary Ewing adrenal sarcoma. In addition, research in biomarkers and artificial intelligence science will assist with stratifying patients into groups, and lead to the development of individualized treatments and prognostic treatment-response scores in chemotherapy and/or radiotherapy.

FOOTNOTES

Author contributions: Manatakis DK and Tasis NP designed the study; Antonopoulou MI, Acheimastos V and Mylonakis E performed the research; Mylonakis E, Tsouknidas I and Mastoropoulou A wrote and revised the manuscript; Manatakis DK and Korkolis DP coordinated the project; All authors have read and approved the final manuscript.

Conflict-of-interest statement: The authors deny any conflict of interest.

PRISMA 2020 Checklist statement: The authors have read the PRISMA 2020 Checklist, and the manuscript was prepared and revised according to the PRISMA 2020 Checklist.

Open-Access: This article is an open-access article that was selected by an in-house editor and fully peer-reviewed by external reviewers. It is distributed in accordance with the Creative Commons Attribution NonCommercial (CC BY-NC 4.0) license, which permits others to distribute, remix, adapt, build upon this work non-commercially, and license their derivative works on different terms, provided the

original work is properly cited and the use is non-commercial. See: <https://creativecommons.org/licenses/by-nc/4.0/>

Country/Territory of origin: Greece

ORCID number: Dimitrios K Manatakis 0000-0002-1263-8488; Ioannis Tsouknidas 0000-0002-5958-0404; Emmanouil Mylonakis 0000-0003-2671-9569; Nikolaos Tasis 0000-0002-8523-6316; Maria Ioanna Antonopoulou 0000-0002-0911-128X; Vasileios Acheimastos 0000-0002-6996-169X; Aikaterini Mastoropoulou 0009-0006-8596-4256; Dimitrios P Korkolis 0000-0003-0682-2374.

S-Editor: Qu XL

L-Editor: Webster JR

P-Editor: Zhao S

REFERENCES

- Theisen ER**, Pishas KI, Saund RS, Lessnick SL. Therapeutic opportunities in Ewing sarcoma: EWS-FLI inhibition *via* LSD1 targeting. *Oncotarget* 2016; **7**: 17616-17630 [PMID: 26848860 DOI: 10.18632/oncotarget.7124]
- Balamuth NJ**, Womer RB. Ewing's sarcoma. *Lancet Oncol* 2010; **11**: 184-192 [PMID: 20152770 DOI: 10.1016/S1470-2045(09)70286-4]
- Machado I**, Navarro L, Pellin A, Navarro S, Agaimy A, Tardio JC, Karseladze A, Petrov S, Scotlandi K, Picci P, Llombart-Bosch A. Defining Ewing and Ewing-like small round cell tumors (SRCT): The need for molecular techniques in their categorization and differential diagnosis. A study of 200 cases. *Ann Diagn Pathol* 2016; **22**: 25-32 [PMID: 27180056 DOI: 10.1016/j.anndiagpath.2016.03.002]
- Kim SK**, Park YK. Ewing sarcoma: a chronicle of molecular pathogenesis. *Hum Pathol* 2016; **55**: 91-100 [PMID: 27246176 DOI: 10.1016/j.humpath.2016.05.008]
- Koscielniak E**, Sparber-Sauer M, Scheer M, Vokuhl C, Kazanowska B, Ladenstein R, Niggli F, Ljungman G, Paulussen M, Bielack SS, Seitz G, Fuchs J, Hallmen E, Klingebiel T; On Behalf Of The Cws Study Group. Extraskelatal Ewing sarcoma in children, adolescents, and young adults. An analysis of three prospective studies of the Cooperative Weichteilsarkomstudiengruppe (CWS). *Pediatr Blood Cancer* 2021; **68**: e29145 [PMID: 34089219 DOI: 10.1002/pbc.29145]
- Murthy SS**, Challa S, Raju K, Rajappa SJ, Fonseca D, Gundimeda SD, Rao BV, Ahmed F, Kodandapani S, Nambaru L, Mundada MC, Sharma R, Mallavarapu KM, Koppula VC, Rao TS. Ewing Sarcoma With Emphasis on Extra-skeletal Ewing Sarcoma: A Decade's Experience From a Single Centre in India. *Clin Pathol* 2020; **13**: 2632010X20970210 [PMID: 33241208 DOI: 10.1177/2632010X20970210]
- Page MJ**, McKenzie JE, Bossuyt PM, Boutron I, Hoffmann TC, Mulrow CD, Shamseer L, Tetzlaff JM, Akl EA, Brennan SE, Chou R, Glanville J, Grimshaw JM, Hróbjartsson A, Lalu MM, Li T, Loder EW, Mayo-Wilson E, McDonald S, McGuinness LA, Stewart LA, Thomas J, Tricco AC, Welch VA, Whiting P, Moher D. The PRISMA 2020 statement: an updated guideline for reporting systematic reviews. *BMJ* 2021; **372**: n71 [PMID: 33782057 DOI: 10.1136/bmj.n71]
- Marina NM**, Etcubanas E, Parham DM, Bowman LC, Green A. Peripheral primitive neuroectodermal tumor (peripheral neuroepithelioma) in children. A review of the St. Jude experience and controversies in diagnosis and management. *Cancer* 1989; **64**: 1952-1960 [PMID: 2551479 DOI: 10.1002/1097-0142(19891101)64:9<1952::aid-cnrc2820640931>3.0.co;2-w]
- Renshaw AA**, Perez-Atayde AR, Fletcher JA, Granter SR. Cytology of typical and atypical Ewing's sarcoma/PNET. *Am J Clin Pathol* 1996; **106**: 620-624 [PMID: 8929472 DOI: 10.1093/AJCP/106.5.620]
- Kim MS**, Kim B, Park CS, Song SY, Lee EJ, Park NH, Kim HS, Kim SH, Cho KS. Radiologic findings of peripheral primitive neuroectodermal tumor arising in the retroperitoneum. *AJR Am J Roentgenol* 2006; **186**: 1125-1132 [PMID: 16554591 DOI: 10.2214/AJR.04.1688]
- Zhang Y**, Li H. Primitive neuroectodermal tumors of adrenal gland. *Jpn J Clin Oncol* 2010; **40**: 800-804 [PMID: 20430773 DOI: 10.1093/jjco/hyq050]
- Gonin J**, Larousserie F, Dousset B, Rousseau J, Delattre O, Waintrop C, Tsatsaris V, Pierga JY, Vacher-Lavenu MC, Tissier F. [An unusual adrenal tumor: Ewing tumor]. *Ann Pathol* 2011; **31**: 28-31 [PMID: 21349385 DOI: 10.1016/j.annpat.2010.07.043]
- Mohsin R**, Hashmi A, Mubarak M, Sultan G, Shehzad A, Qayum A, Naqvi SA, Rizvi SA. Primitive neuroectodermal tumor/Ewing's sarcoma in adult uro-oncology: A case series from a developing country. *Urol Ann* 2011; **3**: 103-107 [PMID: 21747604 DOI: 10.4103/0974-7796.82180]
- Stephenson J**, Gow KW, Meehan J, Hawkins DS, Avansino J. Ewing sarcoma/primitive neuroectodermal tumor arising from the adrenal gland in an adolescent. *Pediatr Blood Cancer* 2011; **57**: 691-692 [PMID: 21681923 DOI: 10.1002/pbc.23034]
- Saboo SS**, Krajewski KM, Jagannathan JP, Ramaiya N. IVC tumor thrombus: an advanced case of rare extrasosseous Ewing sarcoma of the adrenal gland. *Urology* 2012; **79**: e77-e78 [PMID: 22656426 DOI: 10.1016/j.urology.2012.03.008]
- Abi-Raad R**, Manetti GJ, Colberg JW, Hornick JL, Shah JG, Prasad ML. Ewing sarcoma/primitive neuroectodermal tumor arising in the adrenal gland. *Pathol Int* 2013; **63**: 283-286 [PMID: 23714257 DOI: 10.1111/pin.12063]
- Blas JV**, Smith ML, Wasif N, Cook CB, Schlinkert RT. Ewing sarcoma of the adrenal gland: a rare entity. *BMJ Case Rep* 2013; **2013** [PMID: 23853184 DOI: 10.1136/bcr-2012-007753]
- Dutta D**, Shivaprasad KS, Das RN, Ghosh S, Chowdhury S. Primitive neuroectodermal tumor of adrenal: clinical presentation and outcomes. *J Cancer Res Ther* 2013; **9**: 709-711 [PMID: 24518722 DOI: 10.4103/0973-1482.126459]
- Lim SH**, Lee JY, Kim JH, Choi KH, Hyun JY, Ko YH, Lee J, Kim SJ, Kim WS. Unusual presentation of Ewing sarcoma in the adrenal gland: a secondary malignancy from a survivor of Burkitt lymphoma. *Jpn J Clin Oncol* 2013; **43**: 676-680 [PMID: 23564674 DOI: 10.1093/jjco/hyt047]
- Matsuoka Y**, Fujii Y, Akashi T, Gosehi N, Kihara K. Primitive neuroectodermal tumour of the adrenal gland. *BJU Int* 1999; **83**: 515-516 [PMID: 10210585 DOI: 10.1046/J.1464-410X.1999.00040.X]
- Phukan C**, Nirmal TJ, Kumar RM, Kekre NS. Peripheral primitive neuroectodermal tumor of the adrenal gland: A rare entity. *Indian J Urol* 2013; **29**: 357-359 [PMID: 24235803 DOI: 10.4103/0970-1591.120128]
- Sasaki T**, Onishi T, Yabana T, Hoshina A. Ewing's sarcoma/primitive neuroectodermal tumor arising from the adrenal gland: a case report and

- literature review. *Tumori* 2013; **99**: e104-e106 [PMID: 24158076 DOI: 10.1177/030089161309900326]
- 23 **Yamamoto T**, Takasu K, Emoto Y, Umehara T, Ikematsu K, Shikata N, Iino M, Matoba R. Latent adrenal Ewing sarcoma family of tumors: A case report. *Leg Med (Tokyo)* 2013; **15**: 96-98 [PMID: 22981088 DOI: 10.1016/j.legalmed.2012.08.008]
 - 24 **Zahir MN**, Ansari TZ, Moatter T, Memon W, Pervaz S. Ewing's sarcoma arising from the adrenal gland in a young male: a case report. *BMC Res Notes* 2013; **6**: 533 [PMID: 24330865 DOI: 10.1186/1756-0500-6-533]
 - 25 **Somarouthu BS**, Shinagare AB, Rosenthal MH, Tirumani H, Hornick JL, Ramaiya NH, Tirumani SH. Multimodality imaging features, metastatic pattern and clinical outcome in adult extraskelatal Ewing sarcoma: experience in 26 patients. *Br J Radiol* 2014; **87**: 20140123 [PMID: 24734938 DOI: 10.1259/bjr.20140123]
 - 26 **Tsang YP**, Lang BH, Tam SC, Wong KP. Primitive neuroectodermal adrenal gland tumour. *Hong Kong Med J* 2014; **20**: 444-446 [PMID: 25307073 DOI: 10.12809/hkmj134127]
 - 27 **Yoon JH**, Kim H, Lee JW, Kang HJ, Park HJ, Park KD, Park BK, Shin HY, Park JD, Park SH, Ahn HS. Ewing sarcoma/peripheral primitive neuroectodermal tumor in the adrenal gland of an adolescent: a case report and review of the literature. *J Pediatr Hematol Oncol* 2014; **36**: e456-e459 [PMID: 24276043 DOI: 10.1097/MPH.000000000000058]
 - 28 **Priya D**, Kumar RV, Appaji L, Aruna Kumari BS, Padma M, Kumari P. Histological diversity and clinical characteristics of Ewing sarcoma family of tumors in children: A series from a tertiary care center in South India. *Indian J Cancer* 2015; **52**: 331-335 [PMID: 26905130 DOI: 10.4103/0019-509X.176700]
 - 29 **Batahar SA**, Elidrissi S, Berrada S, Rais H, Amro L. Extraskelatal Ewing's sarcoma: An adrenal localization. *Int J Case Reports Images* 2016; **7**: 770-773 [DOI: 10.5348/IJCRI-2016134-CR-10722]
 - 30 **Kumar S**, Govinda V, Singh SK, Singh J. Bilateral Adrenal PNET: A Rare Presentation. *J Clin Diagn Res* 2016; **10**: XD01-XD02 [PMID: 27790563 DOI: 10.7860/JCDR/2016/9260.8397]
 - 31 **Pirani JF**, Woolums CS, Dishop MK, Herman JR. Primitive neuroectodermal tumor of the adrenal gland. *J Urol* 2000; **163**: 1855-1856 [PMID: 10799198]
 - 32 **Pal DK**, Chandra V, Ranjan KR, Chakraborty D, Banerjee M. Ewing's Sarcoma of the Adrenal Gland. *APSP J Case Rep* 2016; **7**: 20 [PMID: 27398321 DOI: 10.21699/ajcr.v7i3.406]
 - 33 **Zhang L**, Yao M, Hisaoka M, Sasano H, Gao H. Primary Ewing sarcoma/primitive neuroectodermal tumor in the adrenal gland. *APMIS* 2016; **124**: 624-629 [PMID: 27197626 DOI: 10.1111/apm.12544]
 - 34 **de Groot S**, Gelderblom H, Fiocco M, Bovée JV, van der Hoeven JJ, Pijl H, Kroep JR. Serum levels of IGF-1 and IGF-BP3 are associated with event-free survival in adult Ewing sarcoma patients treated with chemotherapy. *Oncotargets Ther* 2017; **10**: 2963-2970 [PMID: 28652778 DOI: 10.2147/OTT.S123726]
 - 35 **Guo H**, Chen S, Liu S, Wang K, Liu E, Li F, Hou Y. Rare adrenal gland incidentaloma: an unusual Ewing's sarcoma family of tumor presentation and literature review. *BMC Urol* 2017; **17**: 24 [PMID: 28376845 DOI: 10.1186/s12894-017-0217-3]
 - 36 **Soydan L**, Demir AA, Sayman E, Onomay Celik B, Oven Ustaalioglu BB. Adrenal mass of unusual etiology: Ewing sarcoma in a young man. *Radiol Case Rep* 2017; **12**: 838-844 [PMID: 29484083 DOI: 10.1016/j.radcr.2017.07.002]
 - 37 **Zhang Y**, Cai P, Chen M, Yi X, Li L, Xiao D, Liu W, Li W, Li Y. Imaging findings of adrenal primitive neuroectodermal tumors: a series of seven cases. *Clin Transl Oncol* 2017; **19**: 641-649 [PMID: 27878756 DOI: 10.1007/s12094-016-1580-3]
 - 38 **Afridi ZU**, Haleem A, Khan MA, Ahmad R, Rashid M, Arooj S, Arifeen S U, Ullah A. EWING SARCOMA OF ADRENAL GLAND CAUSING CUSHING'S SYNDROME; AN EXCEPTIONALLY RARE TUMOR. *J Med Sci* 2018; **26**: 178-180 Available from: <https://jmedsci.com/index.php/Jmedsci/article/view/548>
 - 39 **Eddaualline H**, Mazouz K, Rafiq B, El Mghari Tabib G, El Ansari N, Belbaraka R, El Omrani A, Khouchani M. Ewing sarcoma of the adrenal gland: a case report and review of the literature. *J Med Case Rep* 2018; **12**: 69 [PMID: 29544549 DOI: 10.1186/s13256-018-1601-7]
 - 40 **Goudarzipour K**, Farahmandi F, Mohammadi A, Taherian R. Ewing Sarcoma/Peripheral Primitive Neuroectodermal Tumor in the Adrenal Gland of a Child. *Iran J Kidney Dis* 2018; **12**: 190-192 [PMID: 29891750]
 - 41 **Toda K**, Ishii S, Yasuoka H, Nishioka M, Kobayashi T, Horiguchi K, Tomaru T, Ozawa A, Shibusawa N, Satoh T, Koshi H, Segawa A, Shimizu SI, Oyama T, Yamada M. Adrenal Ewing's Sarcoma in an Elderly Man. *Intern Med* 2018; **57**: 551-555 [PMID: 29269639 DOI: 10.2169/internalmedicine.8892-17]
 - 42 **Jung SP**, Oh CG, Lim IS, Lee DK, Yoo BH. A Case of Primitive Neuroectodermal Tumor of the Adrenal Gland. *J Korean Pediatr Soc* 2001; **44**: 1459-1462
 - 43 **Patnaik S**, Yarlagaadda J, Susarla R. Imaging features of Ewing's sarcoma: Special reference to uncommon features and rare sites of presentation. *J Cancer Res Ther* 2018; **14**: 1014-1022 [PMID: 30197341 DOI: 10.4103/jcrt.JCRT_1350_16]
 - 44 **Koufopoulos N**, Kokkali S, Manatakis D, Balalis D, Nasi D, Ardavanis A, Korkolis D, Khaldi L. Primary peripheral neuroectodermal tumor (PNET) of the adrenal gland: a rare entity. *J BUON* 2019; **24**: 770-778 [PMID: 31128035]
 - 45 **Ibabao C**, Tsetse C, Sheth Y, Maitland C, Mohammed M. Primary Ewing sarcoma of the adrenal gland: A rare cause of abdominal mass. *Radiol Case Rep* 2020; **15**: 1-6 [PMID: 31737137 DOI: 10.1016/j.radcr.2019.09.019]
 - 46 **Maity K**, Agrawal A, Datta C, Pal DK. Primary Ewing's Sarcoma of Adrenal Gland-A Rare Case. *J Clin Diagnostic Res* 2019; **13**: PD01-02 [DOI: 10.7860/JCDR/2019/40481.12702]
 - 47 **Dai J**, He HC, Huang X, Sun FK, Zhu Y, Xu DF. Long-term survival of a patient with a large adrenal primitive neuroectodermal tumor: A case report. *World J Clin Cases* 2019; **7**: 340-346 [PMID: 30746375 DOI: 10.12998/wjcc.v7.i3.340]
 - 48 **Gaujoux S**, Hain É, Marcellin L, de Carbonnieres A, Goffinet F, Bertherat J, Dousset B. Adrenalectomy during pregnancy: A 15-year experience at a tertiary referral center. *Surgery* 2020; **168**: 335-339 [PMID: 32434659 DOI: 10.1016/j.surg.2020.03.019]
 - 49 **Sari M**, Ekenei M, Ozluk MY, Basaran M. Clinical and Pathological Features of Ewing Sacoma Family Tumors in Uro-oncology: A Single-Institute Experience. *Eurasian J Med Investig* 2020; **4**: 247-252 [DOI: 10.14744/EJMI.2020.34964]
 - 50 **Bradford K**, Nobori A, Johnson B, Allen-Rhoades W, Naik-Mathuria B, Panosyan EH, Gotesman M, Lasky J, Cheng J, Ikeda A, Goldstein J, Singh A, Federman N. Primary Renal Ewing Sarcoma in Children and Young Adults. *J Pediatr Hematol Oncol* 2020; **42**: 474-481 [PMID: 32282650 DOI: 10.1097/MPH.0000000000001804]
 - 51 **Salah S**, Abuhijla F, Ismail T, Yaser S, Sultan I, Halalsheh H, Shehadeh A, Abdelal S, Almousa A, Jaber O, Abu-Hijlih R. Outcomes of extraskelatal vs. skeletal Ewing sarcoma patients treated with standard chemotherapy protocol. *Clin Transl Oncol* 2020; **22**: 878-883 [PMID: 31429039 DOI: 10.1007/s12094-019-02202-y]
 - 52 **Jagdale R V**, Pol JN. Primary primitive neuroectodermal tumor of the adrenal gland: A unique tumor at an unusual site. *Indian J Pathol Oncol*

- 2021; **8**: 420-423 [DOI: [10.18231/J.IJPO.2021.085](https://doi.org/10.18231/J.IJPO.2021.085)]
- 53 **Kato K**, Kato Y, Ijiri R, Misugi K, Nanba I, Nagai J, Nagahara N, Kigasawa H, Toyoda Y, Nishi T, Tanaka Y. Ewing's sarcoma family of tumor arising in the adrenal gland--possible diagnostic pitfall in pediatric pathology: histologic, immunohistochemical, ultrastructural, and molecular study. *Hum Pathol* 2001; **32**: 1012-1016 [PMID: [11567233](https://pubmed.ncbi.nlm.nih.gov/11567233/) DOI: [10.1053/hupa.2001.27121](https://doi.org/10.1053/hupa.2001.27121)]
 - 54 **Wang JL**, Xu CY, Geng CJ, Liu L, Zhang MZ, Wang H, Xiao RT, Zhang G, Ni C, Guo XY. Anesthesia and perioperative management for giant adrenal Ewing's sarcoma with inferior vena cava and right atrium tumor thrombus: A case report. *World J Clin Cases* 2022; **10**: 643-655 [PMID: [35097090](https://pubmed.ncbi.nlm.nih.gov/35097090/) DOI: [10.12998/wjcc.v10.i2.643](https://doi.org/10.12998/wjcc.v10.i2.643)]
 - 55 **Roy D**, Pereira M, Shivdasani D, Singh N. (18) F-FDG PET-CT Evaluation of Primary Adrenal Ewing Sarcoma with Venous Thrombosis: An Unusual Presentation. *World J Nucl Med* 2023; **22**: 26-28 [PMID: [36923977](https://pubmed.ncbi.nlm.nih.gov/36923977/) DOI: [10.1055/s-0042-1757251](https://doi.org/10.1055/s-0042-1757251)]
 - 56 **Girot V**, Johann M, Sahyoun A, Platini C, Fery N, Khalife K. [Primitive Ewing sarcoma presenting as a left adrenal mass associated with a vena cava thrombus]. *Prog Urol* 2002; **12**: 668-671 [PMID: [12463131](https://pubmed.ncbi.nlm.nih.gov/12463131/)]
 - 57 **Khong PL**, Chan GC, Shek TW, Tam PK, Chan FL. Imaging of peripheral PNET: common and uncommon locations. *Clin Radiol* 2002; **57**: 272-277 [PMID: [12014872](https://pubmed.ncbi.nlm.nih.gov/12014872/) DOI: [10.1053/crad.2001.0807](https://doi.org/10.1053/crad.2001.0807)]
 - 58 **Ahmed AA**, Nava VE, Pham T, Taubenberger JK, Lichy JH, Sorbara L, Raffeld M, Mackall CL, Tsokos M. Ewing sarcoma family of tumors in unusual sites: confirmation by rt-PCR. *Pediatr Dev Pathol* 2006; **9**: 488-495 [PMID: [17163788](https://pubmed.ncbi.nlm.nih.gov/17163788/) DOI: [10.2350/06-01-0007.1](https://doi.org/10.2350/06-01-0007.1)]
 - 59 **Komatsu S**, Watanabe R, Naito M, Mizusawa T, Obara K, Nishiyama T, Takahashi K. Primitive neuroectodermal tumor of the adrenal gland. *Int J Urol* 2006; **13**: 606-607 [PMID: [16771733](https://pubmed.ncbi.nlm.nih.gov/16771733/) DOI: [10.1111/J.1442-2042.2006.01361.X](https://doi.org/10.1111/J.1442-2042.2006.01361.X)]
 - 60 **Grünewald TGP**, Cidre-Aranaz F, Surdez D, Tomazou EM, de Álava E, Kovar H, Sorensen PH, Delattre O, Dirksen U. Ewing sarcoma. *Nat Rev Dis Primers* 2018; **4**: 5 [PMID: [29977059](https://pubmed.ncbi.nlm.nih.gov/29977059/) DOI: [10.1038/s41572-018-0003-x](https://doi.org/10.1038/s41572-018-0003-x)]
 - 61 **Wright A**, Desai M, Bolan CW, Badawy M, Guccione J, Rao Korivi B, Pickhardt PJ, Mellnick VM, Lubner MG, Chen L, Elsayes KM. Extraskeletal Ewing Sarcoma from Head to Toe: Multimodality Imaging Review. *Radiographics* 2022; **42**: 1145-1160 [PMID: [35622491](https://pubmed.ncbi.nlm.nih.gov/35622491/) DOI: [10.1148/rg.210226](https://doi.org/10.1148/rg.210226)]
 - 62 **Latronico AC**, Chrousos GP. Extensive personal experience: adrenocortical tumors. *J Clin Endocrinol Metab* 1997; **82**: 1317-1324 [PMID: [9141510](https://pubmed.ncbi.nlm.nih.gov/9141510/) DOI: [10.1210/JCEM.82.5.3921](https://doi.org/10.1210/JCEM.82.5.3921)]
 - 63 **Yan D**, Zhang J, Zhong D. Ewing's sarcoma in the spinal canal of T12-L3: A case report and review of the literature. *Oncol Lett* 2019; **18**: 6157-6163 [PMID: [31788090](https://pubmed.ncbi.nlm.nih.gov/31788090/) DOI: [10.3892/ol.2019.10958](https://doi.org/10.3892/ol.2019.10958)]
 - 64 **Gronchi A**, Miah AB, Dei Tos AP, Abecassis N, Bajpai J, Bauer S, Biagini R, Bielack S, Blay JY, Bolle S, Bonvalot S, Boukovinas I, Bovee JVMG, Boye K, Brennan B, Brodowicz T, Buonadonna A, De Álava E, Del Muro XG, Dufresne A, Eriksson M, Fagioli F, Fedenko A, Ferraresi V, Ferrari A, Frezza AM, Gasperoni S, Gelderblom H, Gouin F, Grignani G, Haas R, Hassan AB, Hecker-Nolting S, Hindi N, Hohenberger P, Joensuu H, Jones RL, Jungels C, Jutte P, Kager L, Kasper B, Kawai A, Kopeckova K, Krákorová DA, Le Cesne A, Le Grange F, Legius E, Leithner A, Lopez-Pousa A, Martin-Broto J, Merimsky O, Messiou C, Mir O, Montemurro M, Morland B, Morosi C, Palmerini E, Pantaleo MA, Piana R, Piperno-Neumann S, Reichardt P, Rutkowski P, Safwat AA, Sangalli C, Sbaraglia M, Scheipl S, Schöffski P, Sleijfer S, Strauss D, Strauss S, Sundby Hall K, Trama A, Unk M, van de Sande MAJ, van der Graaf WTA, van Houdt WJ, Frebourg T, Casali PG, Stacchiotti S; ESMO Guidelines Committee, EURACAN and GENTURIS. Soft tissue and visceral sarcomas: ESMO-EURACAN-GENTURIS Clinical Practice Guidelines for diagnosis, treatment and follow-up. *Ann Oncol* 2021; **32**: 1348-1365 [PMID: [34303806](https://pubmed.ncbi.nlm.nih.gov/34303806/) DOI: [10.1016/j.annonc.2021.07.006](https://doi.org/10.1016/j.annonc.2021.07.006)]
 - 65 National Comprehensive Cancer Network. Soft Tissue Sarcoma (version 2.2023). Available from: https://www.nccn.org/professionals/physician_gls/pdf/sarcoma.pdf
 - 66 **Abboud A**, Masrouha K, Saliba M, Haidar R, Saab R, Khoury N, Tawil A, Saghiel S. Extraskeletal Ewing sarcoma: Diagnosis, management and prognosis. *Oncol Lett* 2021; **21**: 354 [PMID: [33747211](https://pubmed.ncbi.nlm.nih.gov/33747211/) DOI: [10.3892/ol.2021.12615](https://doi.org/10.3892/ol.2021.12615)]
 - 67 **Peneder P**, Stütz AM, Surdez D, Krumbholz M, Semper S, Chicard M, Sheffield NC, Pierron G, Lapouble E, Tötzl M, Ergüner B, Barreca D, Rendeiro AF, Agaimy A, Boztug H, Engstler G, Dworzak M, Bernkopf M, Taschner-Mandl S, Ambros IM, Myklebost O, Marec-Bérard P, Burchill SA, Brennan B, Strauss SJ, Whelan J, Schleiermacher G, Schaefer C, Dirksen U, Hutter C, Boye K, Ambros PF, Delattre O, Metzler M, Bock C, Tomazou EM. Multimodal analysis of cell-free DNA whole-genome sequencing for pediatric cancers with low mutational burden. *Nat Commun* 2021; **12**: 3230 [PMID: [34050156](https://pubmed.ncbi.nlm.nih.gov/34050156/) DOI: [10.1038/s41467-021-23445-w](https://doi.org/10.1038/s41467-021-23445-w)]
 - 68 **Zöllner SK**, Amatruda JF, Bauer S, Collaud S, de Álava E, DuBois SG, Hards J, Hartmann W, Kovar H, Metzler M, Shulman DS, Streitbürger A, Timmermann B, Toretsky JA, Uhlenbruch Y, Vieth V, Grünewald TGP, Dirksen U. Ewing Sarcoma-Diagnosis, Treatment, Clinical Challenges and Future Perspectives. *J Clin Med* 2021; **10** [PMID: [33919988](https://pubmed.ncbi.nlm.nih.gov/33919988/) DOI: [10.3390/jcm10081685](https://doi.org/10.3390/jcm10081685)]
 - 69 **Li G**, Wu X, Ma X. Artificial intelligence in radiotherapy. *Semin Cancer Biol* 2022; **86**: 160-171 [PMID: [35998809](https://pubmed.ncbi.nlm.nih.gov/35998809/) DOI: [10.1016/j.semcancer.2022.08.005](https://doi.org/10.1016/j.semcancer.2022.08.005)]



Published by **Baishideng Publishing Group Inc**
7041 Koll Center Parkway, Suite 160, Pleasanton, CA 94566, USA

Telephone: +1-925-3991568

E-mail: bpgoffice@wjgnet.com

Help Desk: <https://www.f6publishing.com/helpdesk>

<https://www.wjgnet.com>

