

World Journal of *Clinical Cases*

World J Clin Cases 2023 September 26; 11(27): 6318-6669



MINIREVIEWS

- 6318 Characteristics of amino acid metabolism in colorectal cancer

Xu F, Jiang HL, Feng WW, Fu C, Zhou JC

ORIGINAL ARTICLE**Clinical and Translational Research**

- 6327 Exploring the pharmacological mechanism of Wuzhuyu decoction on hepatocellular carcinoma using network pharmacology

Ouyang JY, Lin WJ, Dong JM, Yang Y, Yang HK, Zhou ZL, Wang RQ

- 6344 Identification of potential diagnostic and prognostic biomarkers for breast cancer based on gene expression omnibus

Zhang X, Mi ZH

Retrospective Cohort Study

- 6363 Treatment of proximal humeral fractures accompanied by medial calcar fractures using fibular autografts: A retrospective, comparative cohort study

Liu N, Wang BG, Zhang LF

Retrospective Study

- 6374 Effectiveness of out-fracture of the inferior turbinate with reduction nasal bone fracture

Kim SY, Nam HJ, Byeon JY, Choi HJ

- 6383 Prognostic model of hepatocellular carcinoma based on cancer grade

Zhang GX, Ding XS, Wang YL

- 6398 Oncologic efficacy of gonadotropin-releasing hormone agonist in hormone receptor-positive very young breast cancer patients treated with neoadjuvant chemotherapy

Choi HJ, Lee JH, Jung CS, Ryu JM, Chae BJ, Lee SK, Yu JH, Kim SW, Nam SJ, Lee JE, Jung YJ, Kim HY

- 6407 Correlation analysis of serum thyroglobulin, thyroid-stimulating hormone levels, and thyroid-cancer risk in thyroid nodule surgery

Shuai JH, Leng ZF, Wang P, Ji YC

- 6415 Closed thoracic drainage in elderly patients with chronic obstructive pulmonary disease complicated with spontaneous pneumothorax: A retrospective study

Wang W, Zhu DN, Shao SS, Bao J

Observational Study

- 6424 *Helicobacter pylori* eradication treatment for primary gastric diffuse large B-cell lymphoma: A single-center analysis

Saito M, Mori A, Kajikawa S, Yokoyama E, Kanaya M, Izumiyama K, Morioka M, Kondo T, Tanei ZI, Shimizu A

Prospective Study

- 6431** Effect of polyene phosphatidylcholine/ursodeoxycholic acid/ademetionine on pregnancy outcomes in intrahepatic cholestasis
Dong XR, Chen QQ, Xue ML, Wang L, Wu Q, Luo TF

SYSTEMATIC REVIEWS

- 6440** Maternal diaphragmatic hernia in pregnancy: A systematic review with a treatment algorithm
Augustin G, Kovač D, Karadjole VS, Zajec V, Herman M, Hrbač P

META-ANALYSIS

- 6455** Laparoscopic *vs* open radical resection in management of gallbladder carcinoma: A systematic review and meta-analysis
He S, Yu TN, Cao JS, Zhou XY, Chen ZH, Jiang WB, Cai LX, Liang X

CASE REPORT

- 6476** Acute acquired concomitant esotropia with congenital paralytic strabismus: A case report
Zhang MD, Liu XY, Sun K, Qi SN, Xu CL
- 6483** Tumor recurrence after pathological complete response in locally advanced gastric cancer after neoadjuvant therapy: Two case reports
Xing Y, Zhang ZL, Ding ZY, Song WL, Li T
- 6491** Acute peritonitis secondary to post-traumatic appendicitis: A case report and literature review
Habachi G, Aziza B, Ben-Ammar S, Maherzi O, Houas Y, Kerkeni Y, Sahli S, Jouini R
- 6498** Fournier's gangrene after insertion of thermo-expandable prostatic stent for benign prostatic hyperplasia: A case report
Jung HC, Kim YU
- 6505** Methyl-CpG-Binding protein 2 duplication syndrome in a Chinese patient: A case report and review of the literature
Xing XH, Takam R, Bao XY, Ba-alwi NA, Ji H
- 6515** Blood purification for treatment of non-liquefied multiple liver abscesses and improvement of T-cell function: A case report
Tang ZQ, Zhao DP, Dong AJ, Li HB
- 6523** Eosinophilic granulomatosis with polyangiitis, asthma as the first symptom, and subsequent Loeffler endocarditis: A case report
He JL, Liu XY, Zhang Y, Niu L, Li XL, Xie XY, Kang YT, Yang LQ, Cai ZY, Long H, Ye GF, Zou JX
- 6531** Left atrium veno-arterial extra corporeal membrane oxygenation as temporary mechanical support for cardiogenic shock: A case report
Lamastra R, Abbott DM, Degani A, Pellegrini C, Veronesi R, Pelenghi S, Dezza C, Gazzaniga G, Belliato M

- 6537** Successful treatment of eyebrow intradermal nevi by shearing combined with electrocautery and curettage: Two case reports
Liu C, Liang JL, Yu JL, Hu Q, Li CX
- 6543** Amniotic membrane mesenchymal stromal cell-derived secretome in the treatment of acute ischemic stroke: A case report
Lin FH, Yang YX, Wang YJ, Subbiah SK, Wu XY
- 6551** Managing spindle cell sarcoma with surgery and high-intensity focused ultrasound: A case report
Zhu YQ, Zhao GC, Zheng CX, Yuan L, Yuan GB
- 6558** Triplet regimen as a novel modality for advanced unresectable hepatocellular carcinoma: A case report and review of literature
Zhao Y, He GS, Li G
- 6565** Acute diquat poisoning case with multiorgan failure and a literature review: A case report
Fan CY, Zhang CG, Zhang PS, Chen Y, He JQ, Yin H, Gong XJ
- 6573** Fungal corneal ulcer after repair of an overhanging filtering bleb: A case report
Zhao J, Xu HT, Yin Y, Li YX, Zheng YJ
- 6579** Combination therapy with toripalimab and anlotinib in advanced esophageal squamous cell carcinoma: A case report
Chen SC, Ma DH, Zhong JJ
- 6587** Removal of a pulmonary artery foreign body during pulse ablation in a patient with atrial fibrillation: A case report
Yan R, Lei XY, Li J, Jia LL, Wang HX
- 6592** Delayed-onset *micrococcus luteus*-induced postoperative endophthalmitis several months after cataract surgery: A case report
Nam KY, Lee HW
- 6597** Anesthetic management of a pregnant patient with Eisenmenger's syndrome: A case report
Zhang Y, Wei TT, Chen G
- 6603** Recurrence of unilateral angioedema of the tongue: A case report
Matsuhisa Y, Kenzaka T, Shimizu H, Hirose H, Gotoh T
- 6613** Transverse mesocolic hernia with intestinal obstruction as a rare cause of acute abdomen in adults: A case report
Zhang C, Guo DF, Lin F, Zhan WF, Lin JY, Lv GF
- 6618** Compound heterozygous mutations in tripeptidyl peptidase 1 cause rare autosomal recessive spinocerebellar ataxia type 7: A case report
Liu RH, Wang XY, Jia YY, Wang XC, Xia M, Nie Q, Guo J, Kong QX

- 6624** Treatment of posterior interosseous nerve entrapment syndrome with ultrasound-guided hydrodissection: A case report
Qin LH, Cao W, Chen FT, Chen QB, Liu XX
- 6631** Rapidly growing extensive polypoid endometriosis after gonadotropin-releasing hormone agonist discontinuation: A case report
Zhang DY, Peng C, Huang Y, Cao JC, Zhou YF
- 6640** Preserving finger length in a patient with symmetric digital gangrene under local anesthesia: A case report
Kim KH, Ko IC, Kim H, Lim SY
- 6646** Reconstruction of the lower back wound with delayed infection after spinal surgery: A case report
Kim D, Lim S, Eo S, Yoon JS
- 6653** Solitary intraosseous neurofibroma in the mandible mimicking a cystic lesion: A case report and review of literature
Zhang Z, Hong X, Wang F, Ye X, Yao YD, Yin Y, Yang HY
- 6664** Complete response of metastatic *BRAF* V600-mutant anaplastic thyroid cancer following adjuvant dabrafenib and trametinib treatment: A case report
Lee SJ, Song SY, Kim MK, Na HG, Bae CH, Kim YD, Choi YS

ABOUT COVER

Editorial Board Member of *World Journal of Clinical Cases*, Alexandru Corlateanu, MD, PhD, Reader (Associate Professor), Department of Respiratory Medicine, Nicolae Testemitanu State University of Medicine and Pharmacy, Chisinau 2001, Moldova. alexandru_corlateanu@yahoo.com

AIMS AND SCOPE

The primary aim of *World Journal of Clinical Cases* (WJCC, *World J Clin Cases*) is to provide scholars and readers from various fields of clinical medicine with a platform to publish high-quality clinical research articles and communicate their research findings online.

WJCC mainly publishes articles reporting research results and findings obtained in the field of clinical medicine and covering a wide range of topics, including case control studies, retrospective cohort studies, retrospective studies, clinical trials studies, observational studies, prospective studies, randomized controlled trials, randomized clinical trials, systematic reviews, meta-analysis, and case reports.

INDEXING/ABSTRACTING

The WJCC is now abstracted and indexed in Science Citation Index Expanded (SCIE, also known as SciSearch®), Journal Citation Reports/Science Edition, Current Contents®/Clinical Medicine, PubMed, PubMed Central, Reference Citation Analysis, China National Knowledge Infrastructure, China Science and Technology Journal Database, and Superstar Journals Database. The 2023 Edition of Journal Citation Reports® cites the 2022 impact factor (IF) for WJCC as 1.1; IF without journal self cites: 1.1; 5-year IF: 1.3; Journal Citation Indicator: 0.26; Ranking: 133 among 167 journals in medicine, general and internal; and Quartile category: Q4.

RESPONSIBLE EDITORS FOR THIS ISSUE

Production Editor: *Ying-Yi Yuan*; Production Department Director: *Xiang Li*; Editorial Office Director: *Jin-Lei Wang*.

NAME OF JOURNAL

World Journal of Clinical Cases

ISSN

ISSN 2307-8960 (online)

LAUNCH DATE

April 16, 2013

FREQUENCY

Thrice Monthly

EDITORS-IN-CHIEF

Bao-Gan Peng, Jerzy Tadeusz Chudek, George Kontogeorgos, Maurizio Serati, Ja Hyeon Ku

EDITORIAL BOARD MEMBERS

<https://www.wjgnet.com/2307-8960/editorialboard.htm>

PUBLICATION DATE

September 26, 2023

COPYRIGHT

© 2023 Baishideng Publishing Group Inc

INSTRUCTIONS TO AUTHORS

<https://www.wjgnet.com/bpg/gerinfo/204>

GUIDELINES FOR ETHICS DOCUMENTS

<https://www.wjgnet.com/bpg/GerInfo/287>

GUIDELINES FOR NON-NATIVE SPEAKERS OF ENGLISH

<https://www.wjgnet.com/bpg/gerinfo/240>

PUBLICATION ETHICS

<https://www.wjgnet.com/bpg/GerInfo/288>

PUBLICATION MISCONDUCT

<https://www.wjgnet.com/bpg/gerinfo/208>

ARTICLE PROCESSING CHARGE

<https://www.wjgnet.com/bpg/gerinfo/242>

STEPS FOR SUBMITTING MANUSCRIPTS

<https://www.wjgnet.com/bpg/GerInfo/239>

ONLINE SUBMISSION

<https://www.f6publishing.com>



Triplet regimen as a novel modality for advanced unresectable hepatocellular carcinoma: A case report and review of literature

Ying Zhao, Guo-Sheng He, Gong Li

Specialty type: Gastroenterology and hepatology

Provenance and peer review: Unsolicited article; Externally peer reviewed.

Peer-review model: Single blind

Peer-review report's scientific quality classification

Grade A (Excellent): 0
Grade B (Very good): B
Grade C (Good): C
Grade D (Fair): 0
Grade E (Poor): 0

P-Reviewer: Masaki N, Japan; Yeo SG, South Korea

Received: June 6, 2023

Peer-review started: June 6, 2023

First decision: August 8, 2023

Revised: August 22, 2023

Accepted: August 31, 2023

Article in press: August 31, 2023

Published online: September 26, 2023



Ying Zhao, Guo-Sheng He, Gong Li, Department of Radiation Oncology, Beijing Tsinghua Changgung Hospital, School of Clinical Medicine, Tsinghua University, Beijing 102218, China

Corresponding author: Gong Li, MD, Doctor, Researcher, Department of Radiation Oncology, Beijing Tsinghua Changgung Hospital, School of Clinical Medicine, Tsinghua University, No. 168 Litang Road, Changping District, Beijing 102218, China. dr_gongli@163.com

Abstract

BACKGROUND

Portal vein tumor thrombus (PVTT) is a common complication, accounting for 44%-62.2% of Hepatocellular carcinoma (HCC), and often indicates the poor prognosis. There is no global consensus for the treatment of unresectable HCC with PVTT. In the present case, we reported a novel strategy of radiotherapy-antiangiogenesis-immune checkpoint blockade combination, which showed better response and prolonged survival.

CASE SUMMARY

A 51-year-old male diagnosed with HCC (Child-Pugh class A), chronic hepatitis B virus infection and Cheng's type III PVTT, was given radiotherapy to part of the lesion plus targeted therapy as the first-line therapy, and achieved partial remission. After radiotherapy, lenvatinib plus pembrolizumab was used as maintenance therapy, and complete remission was achieved. The patient remains alive 46 months after the diagnosis of the HCC with PVTT.

CONCLUSION

This case of unresectable HCC patient with PVTT treated by radiation-lenvatinib-pembrolizumab combination therapy shows apparent clinical efficacy, which demonstrates that local radiotherapy plus antiangiogenesis and immune checkpoint blockade could also benefit patients with advanced HCC.

Key Words: Hepatocellular carcinoma; Portal vein tumor thrombosis; Radiotherapy; Combination therapy; RACIB; Case report

©The Author(s) 2023. Published by Baishideng Publishing Group Inc. All rights reserved.

Core Tip: Primary hepatoma patients with inferior vena cava tumor thrombus and portal vein tumor thrombus are rare, and both are inferior prognostic factors for such patients. There are no worldwide consensus or guidelines on the diagnosis and treatment of hepatocellular carcinoma patients with macrovascular invasion. We used a new treatment model for this patient: radiotherapy combined with target therapy followed by immune maintenance therapy; and achieved extended survival.

Citation: Zhao Y, He GS, Li G. Triplet regimen as a novel modality for advanced unresectable hepatocellular carcinoma: A case report and review of literature. *World J Clin Cases* 2023; 11(27): 6558-6564

URL: <https://www.wjgnet.com/2307-8960/full/v11/i27/6558.htm>

DOI: <https://dx.doi.org/10.12998/wjcc.v11.i27.6558>

INTRODUCTION

The incidence of portal vein tumor thrombus (PVTT) among patients with hepatocellular carcinoma (HCC) has been reported to be 44%-62.2% [1], which is well-known poor prognostic factor for HCC [2-6]. For patients with tumor thrombus involving only the segmental branches of portal vein, or left/right portal vein (Cheng's type I/II), surgical resection provides the only chance for radical treatment if the primary tumor can be resected. However, for patients whose tumor thrombus has invaded the main portal vein trunk and above (Cheng's type III/IV), surgery is not possible and the median overall survival (OS) is usually only 6-8 mo [7].

There is no global consensus or guideline for the treatment of HCC patients with PVTT. European and American guidelines followed the Barcelona Clinic Liver Cancer Staging (BCLC), regarded HCC with macroscopic vascular invasion at BCLC Stage C, and recommended systemic therapy as the therapeutic strategy, including atezolizumab plus bevacizumab, sorafenib or lenvatinib [6-10]. On the contrary, experts from Asian countries (*e.g.*, China) recommended multidisciplinary therapies, including surgery, transcatheter arterial chemoembolization (TACE), radiotherapy (RT), and molecular targeted therapy, which may achieve satisfactory outcomes [11-14].

However, the best comprehensive treatment is still inconclusive and the clinical needs of such patients need to be met urgently. In the present case report, we found that radiotherapy-antiangiogenesis-immune checkpoint blockade combination therapy showed a marked response and prolonged survival, contributing to promising outcomes.

CASE PRESENTATION

Chief complaints

A 51-year-old male was admitted to our hospital with chief complaints of anorexia and fatigue of 2 mo duration.

History of present illness

In February 2018, the patient felt anorexia and fatigue without any apparent inducements, accompanied by a weight loss of 5 kg during 2 mo. Routine blood tests showed no abnormalities, while biochemical tests showed albumin (ALB) level of 32 g/L, total bilirubin (TBIL) level of 23.3 μ mol/L, and prothrombin time (PT) of 13.9 s, which were all abnormal. Besides, alpha-fetoprotein (AFP) level was significantly higher than the expected value (8875 ng/mL). Ultrasonography showed multiple lesions in the liver, of which the largest one was about 10 cm in the left lobe of the liver, and tumor thrombus was expanded into the portal vein. The dynamic contrast enhanced-magnetic resonance imaging (DCE-MRI) revealed a 10.6 cm \times 8.3 cm mass in the left lobe of the liver (Figure 1A, ellipse), and multiple metastases were found in the right lobe of the liver. Tumor thrombus was detected in the inferior vena cava and major portal vein (Figure 1B and C).

History of past illness

The patient had a history of chronic hepatitis B virus (HBV) infection for 20 years, and underwent regular antiviral therapy with Entecavir that reduced HBV-DNA level to the normal range.

Personal and family history

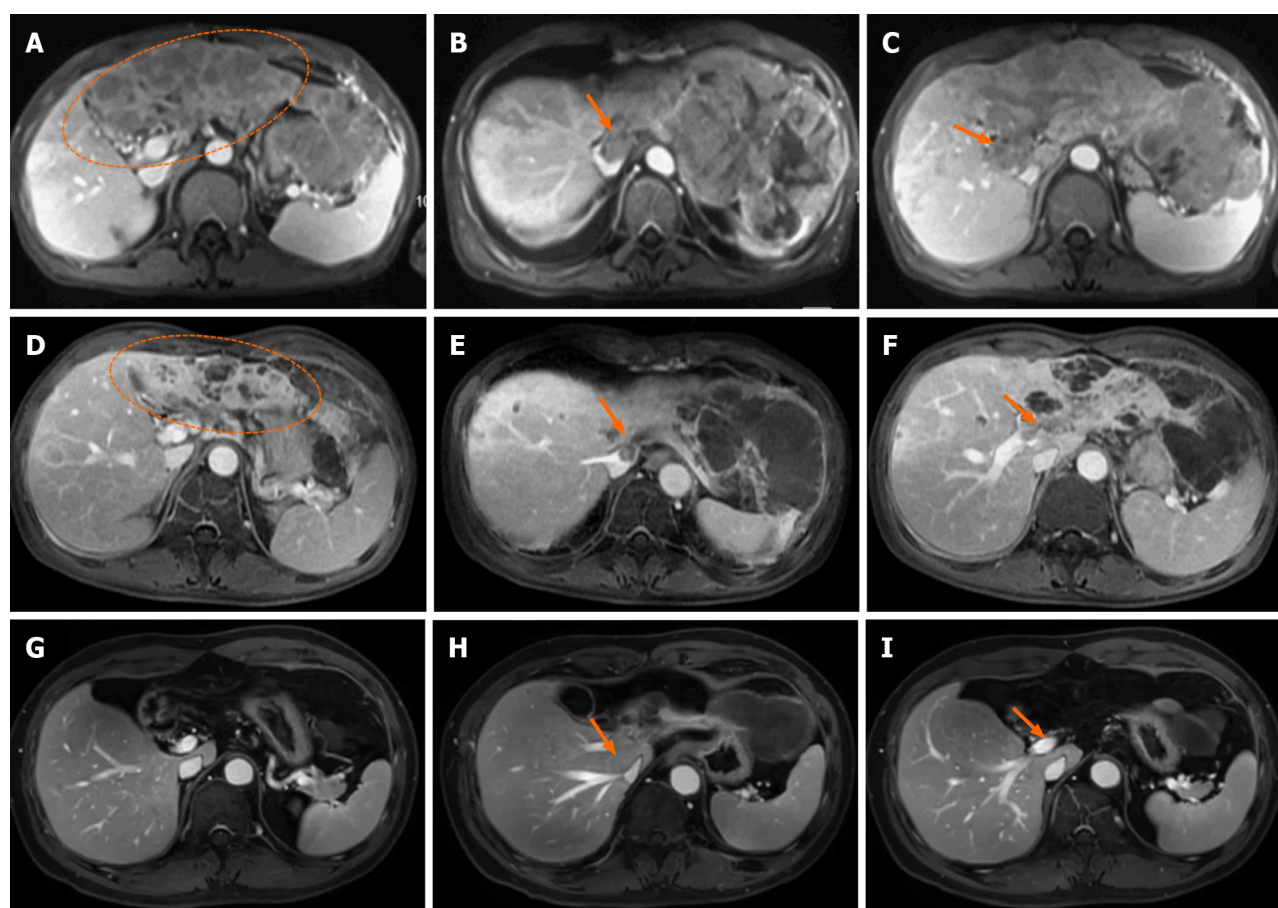
No special notes.

Physical examination

The abdominal examination revealed epigastric tenderness. The patient's body temperature was 38.3 $^{\circ}$ C, with blood pressure of 130/85 mmHg, heart rate of 93 beats per min, respiratory rate of 18 breaths per min, and oxygen saturation on room air was 99%.

Laboratory examinations

Routine blood tests showed no noticeable abnormalities, and biochemical tests showed ALB of 32 g/L, TBIL of 23.3 μ mol/L, and PT of 13.9 s, which were all abnormal.



DOI: 10.12998/wjcc.v11.i27.6558 Copyright ©The Author(s) 2023.

Figure 1 The dynamic contrast-enhanced magnetic resonance imaging showed hepatocellular carcinoma, inferior vena cava tumor thrombus and main portal vein tumor thrombus before and after therapy. A-C: Images before treatment (March 2018), the liver tumor (A, ellipse): Inferior vena cava tumor thrombus (IVCTT) (B, arrow), the main portal vein tumor thrombus (MPVTT) (C, arrow); D-F: Images of 2 mo after radiotherapy (June 2018), partial remission of the tumor (D, ellipse), partial remission of the IVCTT (E, arrow), and partial remission of the MPVTT (F, arrow); G-I: Images of 36 mo after radiotherapy (May 2021), complete remission of tumor (G), complete remission of IVCTT (H), and complete remission of MPVTT (I).

Imaging examinations

The DCE-MRI revealed a 10.6 cm × 8.3 cm mass in the left lobe of the liver, and multiple metastases were found in the right lobe of the liver. Tumor thrombus was detected in the inferior vena cava and major portal vein.

FINAL DIAGNOSIS

The final diagnosis of the present case was hepatocellular carcinoma (Child-Pugh class A), chronic hepatitis B virus infection and Cheng's type III PVTT.

TREATMENT

The patient underwent four-dimensional computed tomography simulations. The respiratory cycle was divided into 0%-90% respiratory phase images based on the respiratory signal, which were reconstructed by the system (Elekta, Sweden) for treatment planning. Thermoplastic shell was used as custom immobilization device in the simulation. RT was delivered to lesion using the volumetric modulated arc therapy technique. Cone-beam computed tomography (CT) images matching the target volume were used for daily imaging guidance.

The gross tumor volume (GTV) of liver lesion was defined as a visible tumor on fusion images of CT with magnetic resonance imaging (MRI). The internal target volume (ITV) was the envelope of all GTVs from the ten respiratory phases. The clinical tumour volume (CTV) of the primary tumour was generated by adding 5 mm to the ITV in all directions. The PTV of the primary tumour was expanded to include a 5 mm margin from the CTV. At least 95% of the PTV was covered by the prescribed dose, which was prescribed to the periphery of the PTV.

As PVTT can cause HCC cells to be disseminated, and considering the dose constraints of normal liver and neighboring organs at risk, meanwhile reducing disease burden to the greatest possible extent for helping to optimize responses to immune checkpoint inhibitors, we had partial irradiation. RT, which irradiated only on the whole PVTT and left part of the tumor (Figure 2), was started on March 15, 2018, with a prescription dose of 300 cGy×12F and oral administration of lenvatinib (12 mg, QD). Lenvatinib was used not only during radiotherapy, but also continuously for 2 mo after radiotherapy. In June 2018, 2 mo after RT, the DCE-MRI scan showed that the size of lesions in the left lobe of the liver was significantly reduced (Figure 1D, ellipse), a part of the primary tumor had become cystic lesions and necrotic, the metastatic lesions were decreased and narrowed, and the tumor thrombus was shrunk (Figure 1E and F, arrow). No side effect of grade III or above was observed during treatment. The patient achieved partial remission according to the Response Evaluation Criteria in Solid Tumors (RECIST, Ver. 1.1). From June 2018, maintenance therapy with pembrolizumab (200 mg IV, 1/3W) and lenvatinib (12 mg, QD) was performed for 41 months, and no severe side effect was recorded in this period.

OUTCOME AND FOLLOW-UP

Two months after RT, the size of the liver tumor was significantly reduced, and the tumor thrombus was shrunk. All symptoms were relieved after radiotherapy. During the follow-up (until December 2021), the tumor was well controlled (complete remission) without recurrence (Figure 1G-I), and the AFP level was reduced to 1.92 ng/mL. The patient has been survived for 46 months since the diagnosis of advanced HCC with PVTT.

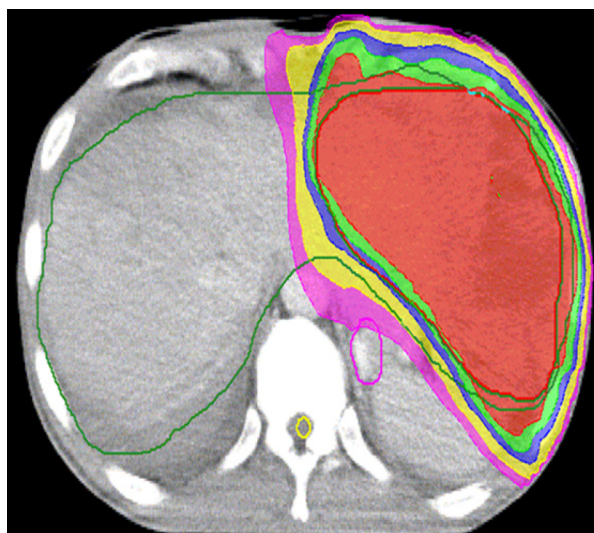DISCUSSION

Surgical resection is the radical treatment method for initially resectable HCC and good survival can be achieved in R0 patients. However, unresectable advanced stage HCC accounts for more than two-thirds of newly diagnosed HCC. In this case, the patient was unsuitable for radical resection because of the tumor thrombus in the main vessels. European and American guidelines followed the BCLC, regarded HCC with PVTT at BCLC Stage C, and recommended systemic treatments based on the positive outcomes of phase III randomized trials[15].

However, radiotherapy is an effective treatment for HCC with PVTT. Patients with type III/IV PVTT receiving radiotherapy alone could achieve an objective response rate (ORR) of 40%-57.7% and a median survival of 9.2-9.6 mo, which is the best level achievable with all single treatments[16]. The partial or complete disappearance of tumor thrombus after radiotherapy can effectively improve intrahepatic blood supply and facilitate the efficacy of drug therapy. A randomized controlled study conducted at the Shanghai Oriental Hepatobiliary Hospital compared the efficacy of neoadjuvant radiotherapy followed by surgery with direct surgery in patients with hepatocellular carcinoma combined with PVTT. Of the 164 patients enrolled, half were randomized to receive neoadjuvant radiotherapy. The results showed that the neoadjuvant radiotherapy group had significantly lower liver cancer-related mortality (HR 0.35, 95%CI 0.23-0.54) and recurrence rates (HR 0.45, 95%CI 0.31-0.64) than the surgical group[17]. Kamiyama *et al*[18] compared preoperative RT to PVTT in the main trunk or first branch in patients who underwent hepatectomy with those without preoperative RT, the total dose was 30-36 Gy in 10-12 fractions, and found that preoperative RT improved the prognosis of patients, and complete necrosis of PVTT was 53.3%, which showed that radiation is sensitive to PVTT.

In basic research, anti-VEGF therapy improves local intra-tumor oxygenation by improving vascular endothelial status, which can have a synergistic effect with radiation therapy. A phase II study enrolled 40 patients with unresectable locally advanced hepatocellular carcinoma who were not suitable for TACE treatment and were given conventional radiotherapy to the liver lesion in combination with sorafenib in parallel and sequential administration of sorafenib until disease progression. The 1 mo ORR after radiotherapy for the entire group was 55%, and the 2-year OS and PFS in the irradiated field were 32% and 39%, respectively[19]. Considering that complete resection was extremely difficult in this patient, to further reduce tumor loading, we combined RT with lenvatinib. Unexpectedly, the therapeutic response was significantly improved, and the majority of lesions achieved remission. The existing evidence suggested a positive correlation between total radiation dose and tumor response[20]. The effects of RT on the survival of cancer patients are generally interpreted as the consequence of improving local control of the tumor, directly attenuating systemic spread. Experimental data from multiple cancer models have provided sufficient evidence to propose a paradigm shift, whereby some of the effects of radiation contribute to systemic antitumor immunity[21,22]. We used fractionated RT, because it has been reported that fractionated RT could more noticeably enhance immunomodulation[23]. Meanwhile, considering the radiation sensitivity of PVTT, the dose constraints of normal liver and neighboring organs at risk, and radiation immunogenicity, we have chosen a total radiation dose of 36 Gy delivered in 12 fractions.

Multiple studies have confirmed that RT has a modulatory effect on the immune system. First, RT mediates immunogenic cell death, which releases tumor-specific antigens in the form of apoptotic vesicles, along with damage-associated molecular patterns[24,25]. It promotes tumor recruitment of dendritic cells (DCs) and the capture of tumor cell antigens by DCs, activating tumor-specific T cells[26]. Second, DNA damage caused by RT activates the cytoplasmic DNA-sensing cyclic GMP-AMP synthase-stimulator of interferon genes (STING) pathway[27], which induces the production of type I interferons (IFN- α and IFN- β). In addition, RT can reprogram the immune microenvironment, which ultimately makes tumor-infiltrating lymphocytes (TILs) to increase and activate cytotoxic T lymphocytes[28,29].



DOI: 10.12998/wjcc.v11.i27.6558 Copyright ©The Author(s) 2023.

Figure 2 Target area in radiotherapy was the left part of the tumor.

Mounting evidence suggests that radiation stimulates the immune system and this contributes to the abscopal effect, which is defined as “response at a distance from the irradiated volume.” Although this phenomenon was first described by Mole in 1953, it only gained widespread clinical attention recently[30]. Preclinical trials support the phenomenon of the abscopal effect, but there are few clinical reports, which suggesting that the immune system activated to translate into clinically visible therapeutic responses that still need to be further explored. Dagoglu *et al*[31] reported 94 cases in 52 articles between 1960 and November 2018 and found a total of 24 cases in 15 reports that demonstrated an abscopal effect finally. In our case, the therapeutic strategy of radiation-immunotherapy combination showed remarkable response-complete remission, including the disappeared right part of the lesion which was not in the irradiation area.

However, the optimal combinations to generate an abscopal effect are unclear. Fortunately, many clinical trials are reported as ongoing or planned investigating the use of RT with immunotherapy. The PACIFIC study concentrated on patients with stage III unresectable non-small cell lung cancer, in which maintenance therapy combined with durvalumab after chemoradiotherapy was associated with a significantly improved survival compared with placebo as the maintenance therapy (4-year survival rates of 49.6% and 38.3%, respectively)[32]. To date, few studies have concentrated on maintenance treatment for HCC, as RT could induce upregulation of immune checkpoint gene expression, elevate mutational load and neoantigen load, and increase the number of CD8+ TILs in the microenvironment. Pembrolizumab was used as maintenance treatment in our case report. In addition, lenvatinib was continued during maintenance therapy, which referred to another combination therapy for advanced HCC with promising early-phase data (KEYNOTE-524)[33], and reported an ORR of 46.0% (95%CI, 36.0% to 56.3%) and a median duration of response of 8.6 mo (95%CI, 6.9 mo to not estimable). The median OS was 22 mo, and this study included portal vein invasion with Vp1-3. To our knowledge, this is the first report on immunotherapy combined with maintenance therapy after RT of HCC patients.

CONCLUSION

Based on the characteristics of this case and other reports in the literature for advanced HCC with PVTT, radiation plus antiangiogenesis and immunotherapy combination can achieve good local control and prolonged survival, which was markedly greater than our expectation. To our knowledge, this is the first patient who was treated by the mentioned therapy, and our findings may provide new insights into the therapy of such patients.

ACKNOWLEDGEMENTS

The authors appreciate Dr. Chen Wenting from MSD China for his significant suggestions and proofreading of the manuscript.

FOOTNOTES

Author contributions: Zhao Y analyzed the data and wrote the manuscript; He GS collected the data; Li G edited and approved the manuscript.

Informed consent statement: Informed written consent was obtained from the patient for publication of this report and any accompanying images.

Conflict-of-interest statement: All the authors declare that they have no conflict of interest.

CARE Checklist (2016) statement: The authors have read the CARE Checklist (2016), and the manuscript was prepared and revised according to the CARE Checklist (2016).

Open-Access: This article is an open-access article that was selected by an in-house editor and fully peer-reviewed by external reviewers. It is distributed in accordance with the Creative Commons Attribution NonCommercial (CC BY-NC 4.0) license, which permits others to distribute, remix, adapt, build upon this work non-commercially, and license their derivative works on different terms, provided the original work is properly cited and the use is non-commercial. See: <https://creativecommons.org/licenses/by-nc/4.0/>

Country/Territory of origin: China

ORCID number: Gong Li 0000-0002-6437-7785.

S-Editor: Liu JH

L-Editor: A

P-Editor: Liu JH

REFERENCES

- 1 Zhang ZM, Lai EC, Zhang C, Yu HW, Liu Z, Wan BJ, Liu LM, Tian ZH, Deng H, Sun QH, Chen XP. The strategies for treating primary hepatocellular carcinoma with portal vein tumor thrombus. *Int J Surg* 2015; **20**: 8-16 [PMID: 26026424 DOI: 10.1016/j.ijssu.2015.05.009]
- 2 Kokudo T, Hasegawa K, Matsuyama Y, Takayama T, Izumi N, Kadoya M, Kudo M, Ku Y, Sakamoto M, Nakashima O, Kaneko S, Kokudo N; Liver Cancer Study Group of Japan. Survival benefit of liver resection for hepatocellular carcinoma associated with portal vein invasion. *J Hepatol* 2016; **65**: 938-943 [PMID: 27266618 DOI: 10.1016/j.jhep.2016.05.044]
- 3 Pawarode A, Voravud N, Sriuranpong V, Kullavanijaya P, Patt YZ. Natural history of untreated primary hepatocellular carcinoma: a retrospective study of 157 patients. *Am J Clin Oncol* 1998; **21**: 386-391 [PMID: 9708639 DOI: 10.1097/00000421-199808000-00014]
- 4 Sekino Y, Okumura T, Fukumitsu N, Izumi T, Numajiri H, Mizumoto M, Nakai K, Nonaka T, Ishikawa H, Sakurai H. Proton beam therapy for hepatocellular carcinoma associated with inferior vena cava tumor thrombus. *J Cancer Res Clin Oncol* 2020; **146**: 711-720 [PMID: 31776663 DOI: 10.1007/s00432-019-03096-7]
- 5 Cheng S, Chen M, Cai J, Sun J, Guo R, Bi X, Lau WY, Wu M. Chinese Expert Consensus on Multidisciplinary Diagnosis and Treatment of Hepatocellular Carcinoma with Portal Vein Tumor Thrombus (2018 Edition). *Liver Cancer* 2020; **9**: 28-40 [PMID: 32071907 DOI: 10.1159/000503685]
- 6 Llovet JM, Kelley RK, Villanueva A, Singal AG, Pikarsky E, Roayaie S, Lencioni R, Koike K, Zucman-Rossi J, Finn RS. Hepatocellular carcinoma. *Nat Rev Dis Primers* 2021; **7**: 6 [PMID: 33479224 DOI: 10.1038/s41572-020-00240-3]
- 7 Yoon SM, Ryoo BY, Lee SJ, Kim JH, Shin JH, An JH, Lee HC, Lim YS. Efficacy and Safety of Transarterial Chemoembolization Plus External Beam Radiotherapy vs Sorafenib in Hepatocellular Carcinoma With Macroscopic Vascular Invasion: A Randomized Clinical Trial. *JAMA Oncol* 2018; **4**: 661-669 [PMID: 29543938 DOI: 10.1001/jamaoncol.2017.5847]
- 8 European Association for the Study of the Liver. European Association for the Study of the Liver. EASL Clinical Practice Guidelines: Management of hepatocellular carcinoma. *J Hepatol* 2018; **69**: 182-236 [PMID: 29628281 DOI: 10.1016/j.jhep.2018.03.019]
- 9 Luo XY, Wu KM, He XX. Advances in drug development for hepatocellular carcinoma: clinical trials and potential therapeutic targets. *J Exp Clin Cancer Res* 2021; **40**: 172 [PMID: 34006331 DOI: 10.1186/s13046-021-01968-w]
- 10 Rimassa L, Personeni N, Czauderna C, Foerster F, Galle P. Systemic treatment of HCC in special populations. *J Hepatol* 2021; **74**: 931-943 [PMID: 33248171 DOI: 10.1016/j.jhep.2020.11.026]
- 11 Lu J, Zhang XP, Zhong BY, Lau WY, Madoff DC, Davidson JC, Qi X, Cheng SQ, Teng GJ. Management of patients with hepatocellular carcinoma and portal vein tumour thrombosis: comparing east and west. *Lancet Gastroenterol Hepatol* 2019; **4**: 721-730 [PMID: 31387735 DOI: 10.1016/S2468-1253(19)30178-5]
- 12 Yarchoan M, Agarwal P, Villanueva A, Rao S, Dawson LA, Llovet JM, Finn RS, Groopman JD, El-Serag HB, Monga SP, Wang XW, Karin M, Schwartz RE, Tanabe KK, Roberts LR, Gunaratne PH, Tsung A, Brown KA, Lawrence TS, Salem R, Singal AG, Kim AK, Rabiee A, Resar L, Hoshida Y, He AR, Ghoshal K, Ryan PB, Jaffee EM, Guha C, Mishra L, Coleman CN, Ahmed MM. Recent Developments and Therapeutic Strategies against Hepatocellular Carcinoma. *Cancer Res* 2019; **79**: 4326-4330 [PMID: 31481419 DOI: 10.1158/0008-5472.CAN-19-0803]
- 13 Cheng S, Wei X, Shi J, Guo W, Feng S, Zhai J, Huang B. A Multidisciplinary Team Approach to the Management of Patients with Hepatocellular Carcinoma with Portal Vein Tumor Thrombus. *Oncologist* 2020; **25**: e998 [PMID: 32141691 DOI: 10.1634/theoncologist.2019-0196]
- 14 De Mattia E, Cecchin E, Guardascione M, Foltran L, Di Raimo T, Angelini F, D'Andrea M, Toffoli G. Pharmacogenetics of the systemic treatment in advanced hepatocellular carcinoma. *World J Gastroenterol* 2019; **25**: 3870-3896 [PMID: 31413525 DOI: 10.3748/wjg.v25.i29.3870]
- 15 Kuzuya T, Ishigami M, Ito T, Ishizu Y, Honda T, Ishikawa T, Fujishiro M. Sorafenib vs. Lenvatinib as First-line Therapy for Advanced Hepatocellular Carcinoma With Portal Vein Tumor Thrombosis. *Anticancer Res* 2020; **40**: 2283-2290 [PMID: 32234927 DOI: 10.21873/anticancer.14193]
- 16 Kim JY, Chung SM, Choi BO, Kay CS. Hepatocellular carcinoma with portal vein tumor thrombosis: Improved treatment outcomes with external beam radiation therapy. *Hepatol Res* 2011; **41**: 813-824 [PMID: 21696524 DOI: 10.1111/j.1872-034X.2011.00826.x]

- 17 **Wei X**, Jiang Y, Zhang X, Feng S, Zhou B, Ye X, Xing H, Xu Y, Shi J, Guo W, Zhou D, Zhang H, Sun H, Huang C, Lu C, Zheng Y, Meng Y, Huang B, Cong W, Lau WY, Cheng S. Neoadjuvant Three-Dimensional Conformal Radiotherapy for Resectable Hepatocellular Carcinoma With Portal Vein Tumor Thrombus: A Randomized, Open-Label, Multicenter Controlled Study. *J Clin Oncol* 2019; **37**: 2141-2151 [PMID: 31283409 DOI: 10.1200/JCO.18.02184]
- 18 **Kamiyama T**, Nakanishi K, Yokoo H, Tahara M, Nakagawa T, Kamachi H, Taguchi H, Shirato H, Matsushita M, Todo S. Efficacy of preoperative radiotherapy to portal vein tumor thrombus in the main trunk or first branch in patients with hepatocellular carcinoma. *Int J Clin Oncol* 2007; **12**: 363-368 [PMID: 17929118 DOI: 10.1007/s10147-007-0701-y]
- 19 **Chen SW**, Lin LC, Kuo YC, Liang JA, Kuo CC, Chiou JF. Phase 2 study of combined sorafenib and radiation therapy in patients with advanced hepatocellular carcinoma. *Int J Radiat Oncol Biol Phys* 2014; **88**: 1041-1047 [PMID: 24661657 DOI: 10.1016/j.ijrobp.2014.01.017]
- 20 **Huang BS**, Tsang NM, Lin SM, Lin DY, Lien JM, Lin CC, Chen WT, Chen WY, Hong JH. High-dose hypofractionated X-ray radiotherapy for hepatocellular carcinoma: Tumor responses and toxicities. *Oncol Lett* 2013; **6**: 1514-1520 [PMID: 24179551 DOI: 10.3892/ol.2013.1582]
- 21 **Kang J**, Demaria S, Formenti S. Current clinical trials testing the combination of immunotherapy with radiotherapy. *J Immunother Cancer* 2016; **4**: 51 [PMID: 27660705 DOI: 10.1186/s40425-016-0156-7]
- 22 **Lee YH**, Tai D, Yip C, Choo SP, Chew V. Combinational Immunotherapy for Hepatocellular Carcinoma: Radiotherapy, Immune Checkpoint Blockade and Beyond. *Front Immunol* 2020; **11**: 568759 [PMID: 33117354 DOI: 10.3389/fimmu.2020.568759]
- 23 **Savage T**, Pandey S, Guha C. Postablation Modulation after Single High-Dose Radiation Therapy Improves Tumor Control via Enhanced Immunomodulation. *Clin Cancer Res* 2020; **26**: 910-921 [PMID: 31757878 DOI: 10.1158/1078-0432.CCR-18-3518]
- 24 **Shi Y**, Evans JE, Rock KL. Molecular identification of a danger signal that alerts the immune system to dying cells. *Nature* 2003; **425**: 516-521 [PMID: 14520412 DOI: 10.1038/nature01991]
- 25 **Lotze MT**, Zeh HJ, Rubartelli A, Sparvero LJ, Amoscato AA, Washburn NR, Devera ME, Liang X, Tör M, Billiar T. The grateful dead: damage-associated molecular pattern molecules and reduction/oxidation regulate immunity. *Immunol Rev* 2007; **220**: 60-81 [PMID: 17979840 DOI: 10.1111/j.1600-065X.2007.00579.x]
- 26 **Obeid M**, Tesniere A, Ghiringhelli F, Fimia GM, Apetoh L, Perfettini JL, Castedo M, Mignot G, Panaretakis T, Casares N, Métivier D, Larochette N, van Endert P, Ciccocanti F, Piacentini M, Zitvogel L, Kroemer G. Calreticulin exposure dictates the immunogenicity of cancer cell death. *Nat Med* 2007; **13**: 54-61 [PMID: 17187072 DOI: 10.1038/nm1523]
- 27 **Deng L**, Liang H, Xu M, Yang X, Burnette B, Arina A, Li XD, Mauceri H, Beckett M, Darga T, Huang X, Gajewski TF, Chen ZJ, Fu YX, Weichselbaum RR. STING-Dependent Cytosolic DNA Sensing Promotes Radiation-Induced Type I Interferon-Dependent Antitumor Immunity in Immunogenic Tumors. *Immunity* 2014; **41**: 843-852 [PMID: 25517616 DOI: 10.1016/j.immuni.2014.10.019]
- 28 **Lugade AA**, Sorensen EW, Gerber SA, Moran JP, Frelinger JG, Lord EM. Radiation-induced IFN-gamma production within the tumor microenvironment influences antitumor immunity. *J Immunol* 2008; **180**: 3132-3139 [PMID: 18292536 DOI: 10.4049/jimmunol.180.5.3132]
- 29 **Chen B**, Alvarado DM, Iticovici M, Kau NS, Park H, Parikh PJ, Thotala D, Ciorba MA. Interferon-Induced IDO1 Mediates Radiation Resistance and Is a Therapeutic Target in Colorectal Cancer. *Cancer Immunol Res* 2020; **8**: 451-464 [PMID: 32127391 DOI: 10.1158/2326-6066.CIR-19-0282]
- 30 **Salama AK**, Postow MA, Salama JK. Irradiation and immunotherapy: From concept to the clinic. *Cancer* 2016; **122**: 1659-1671 [PMID: 26914620 DOI: 10.1002/ncr.29889]
- 31 **Dagoglu N**, Karaman S, Caglar HB, Oral EN. Abscopal Effect of Radiotherapy in the Immunotherapy Era: Systematic Review of Reported Cases. *Cureus* 2019; **11**: e4103 [PMID: 31057997 DOI: 10.7759/cureus.4103]
- 32 **Hui R**, Özgüroğlu M, Villegas A, Daniel D, Vicente D, Murakami S, Yokoi T, Chiappori A, Lee KH, de Wit M, Cho BC, Gray JE, Rydén A, Viviers L, Poole L, Zhang Y, Dennis PA, Antonia SJ. Patient-reported outcomes with durvalumab after chemoradiotherapy in stage III, unresectable non-small-cell lung cancer (PACIFIC): a randomised, controlled, phase 3 study. *Lancet Oncol* 2019; **20**: 1670-1680 [PMID: 31601496 DOI: 10.1016/S1470-2045(19)30519-4]
- 33 **Finn RS**, Ikeda M, Zhu AX, Sung MW, Baron AD, Kudo M, Okusaka T, Kobayashi M, Kumada H, Kaneko S, Pracht M, Mamontov K, Meyer T, Kubota T, Dutkus CE, Saito K, Siegel AB, Dubrovsky L, Mody K, Llovet JM. Phase Ib Study of Lenvatinib Plus Pembrolizumab in Patients With Unresectable Hepatocellular Carcinoma. *J Clin Oncol* 2020; **38**: 2960-2970 [PMID: 32716739 DOI: 10.1200/JCO.20.00808]



Published by **Baishideng Publishing Group Inc**
7041 Koll Center Parkway, Suite 160, Pleasanton, CA 94566, USA

Telephone: +1-925-3991568

E-mail: bpgoffice@wjgnet.com

Help Desk: <https://www.f6publishing.com/helpdesk>

<https://www.wjgnet.com>

