

World Journal of *Clinical Cases*

World J Clin Cases 2023 September 6; 11(25): 5840-6030



Contents

Thrice Monthly Volume 11 Number 25 September 6, 2023

REVIEW

- 5840 Mechanism and recent updates on insulin-related disorders
Kumar S, Senapati S, Bhattacharya N, Bhattacharya A, Maurya SK, Husain H, Bhatti JS, Pandey AK

MINIREVIEWS

- 5857 Progress in the study and treatment of peri-device leak after left atrial appendage closure
Qi YB, Chu HM

ORIGINAL ARTICLE

Case Control Study

- 5863 Application of lesser trochanteric reduction fixator in the treatment of unstable intertrochanteric fractures
Hui YM, Zeng G, Liu PY, Chai B
- 5870 Risk factors for post-traumatic stress disorder among young and middle-aged cancer patients in the intensive care unit: A case-control study
Chen L, Wang GZ, Chi YY, Zhao J

Retrospective Cohort Study

- 5878 Effect of different ventilation methods combined with pulmonary surfactant on neonatal acute respiratory distress syndrome
Qing Q, Zha P, Dai LY, Wang Y

Retrospective Study

- 5887 Hepatic MR imaging using IDEAL-IQ sequence: Will Gd-EOB-DTPA interfere with reproductivity of fat fraction quantification?
Tian Y, Liu PF, Li JY, Li YN, Sun P
- 5897 Conservative management of multi-trauma induced peritonitis: Experience, outcomes, and indications
Chen Q, Zhu T, Liu JK, Ding J, Chen L
- 5903 Analysis of prognostic factors in patients with emergency sepsis
Ning XL, Shao M

CASE REPORT

- 5910 Clinicopathological study of malignant peripheral nerve sheath tumors in the head and neck: Case reports and review of literature
Li L, Ma XK, Gao Y, Wang DC, Dong RF, Yan J, Zhang R

- 5919** Synchronous multiple lung cancers with hilar lymph node metastasis of small cell carcinoma: A case report
Yoshino R, Yoshida N, Yasuda S, Ito A, Nakatsubo M, Yuzawa S, Kitada M
- 5926** Ultrasound-guided carotid angioplasty and stenting in a patient with iodinated contrast allergy: A case report
Li L, Wang ZY, Liu B
- 5934** Parathyroid carcinoma: Three case reports
Shi C, Lu N, Yong YJ, Chu HD, Xia AJ
- 5941** Median neuropathy after multiple punctures of the forearm for catheterization: A case report
Suzuki T, Matsui Y, Momma D, Endo T, Iwasaki N
- 5947** Novel COL4A3 synonymous mutation causes Alport syndrome coexistent with immunoglobulin A nephropathy in a woman: A case report
Chen YT, Jiang WZ, Lu KD
- 5954** Non-retroareolar male mucinous breast cancer without gynecomastia development in an elderly man: A case report
Sun Q, Liu XY, Zhang Q, Jiang H
- 5962** Autosomal dominant non-syndromic hearing loss caused by a novel mutation in MYO7A: A case report and review of the literature
Xia CF, Yan R, Su WW, Liu YH
- 5970** Predicting apical hypertrophic cardiomyopathy using T-wave inversion: Three case reports
Kang L, Li YH, Li R, Chu QM
- 5977** Bilateral thigh pyomyositis in an otherwise healthy middle-aged woman: A case report
Cui M, Zhang G, Zhang N, Han L, Ma ZQ
- 5982** Creutzfeldt-Jakob disease presenting as Korsakoff syndrome caused by E196A mutation in PRNP gene: A case report
Zhang YK, Liu JR, Yin KL, Zong Y, Wang YZ, Cao YM
- 5988** Incomplete distal renal tubular acidosis uncovered during pregnancy: A case report
Seong EY, Kim DW, Kim HJ, Rhee H, Song SH
- 5994** Single omental metastasis of renal cell carcinoma after radical nephrectomy: A case report
Chung JW, Kang JK, Lee EH, Chun SY, Ha YS, Lee JN, Kim TH, Kwon TG, Yoon GS
- 6000** Myeloid sarcoma as the only manifestation in a rare mixed lineage leukemia-fusion-driven acute myeloid leukemia: A case report
Tang SJ, Zhang QG
- 6005** Carotid-cavernous fistula following mechanical thrombectomy of the tortuous internal carotid artery: A case report
Qu LZ, Dong GH, Zhu EB, Lin MQ, Liu GL, Guan HJ

- 6012** Successful treatment of a case of COVID-19 pneumonia following kidney transplantation using paxlovid and tocilizumab
Chen Q, Niu YL
- 6019** Diagnosis and treatment of Whipple disease after kidney transplantation: A case report
Chen Q, Niu YL, Zhang T
- 6025** Monkeypox presenting as a chancre-like rash: A case report
Zhu WF, Song SJ, Wei LW, Qiao JJ

ABOUT COVER

Editorial Board Member of *World Journal of Clinical Cases*, Yuan-Liang Yan, MD, PhD, Academic Research, Assistant Professor, Associate Chief Pharmacist, Department of Pharmacy, Xiangya Hospital, Central South University, Changsha 410000, Hunan Province, China. yanyuanliang@csu.edu.cn

AIMS AND SCOPE

The primary aim of *World Journal of Clinical Cases* (WJCC, *World J Clin Cases*) is to provide scholars and readers from various fields of clinical medicine with a platform to publish high-quality clinical research articles and communicate their research findings online.

WJCC mainly publishes articles reporting research results and findings obtained in the field of clinical medicine and covering a wide range of topics, including case control studies, retrospective cohort studies, retrospective studies, clinical trials studies, observational studies, prospective studies, randomized controlled trials, randomized clinical trials, systematic reviews, meta-analysis, and case reports.

INDEXING/ABSTRACTING

The WJCC is now abstracted and indexed in Science Citation Index Expanded (SCIE, also known as SciSearch®), Journal Citation Reports/Science Edition, Current Contents®/Clinical Medicine, PubMed, PubMed Central, Reference Citation Analysis, China National Knowledge Infrastructure, China Science and Technology Journal Database, and Superstar Journals Database. The 2023 Edition of Journal Citation Reports® cites the 2022 impact factor (IF) for WJCC as 1.1; IF without journal self cites: 1.1; 5-year IF: 1.3; Journal Citation Indicator: 0.26; Ranking: 133 among 167 journals in medicine, general and internal; and Quartile category: Q4.

RESPONSIBLE EDITORS FOR THIS ISSUE

Production Editor: Si Zhao; Production Department Director: Xiang Li; Editorial Office Director: Jin-Lei Wang.

NAME OF JOURNAL

World Journal of Clinical Cases

ISSN

ISSN 2307-8960 (online)

LAUNCH DATE

April 16, 2013

FREQUENCY

Thrice Monthly

EDITORS-IN-CHIEF

Bao-Gan Peng, Jerzy Tadeusz Chudek, George Kontogeorgos, Maurizio Serati, Ja Hyeon Ku

EDITORIAL BOARD MEMBERS

<https://www.wjgnet.com/2307-8960/editorialboard.htm>

PUBLICATION DATE

September 6, 2023

COPYRIGHT

© 2023 Baishideng Publishing Group Inc

INSTRUCTIONS TO AUTHORS

<https://www.wjgnet.com/bpg/gerinfo/204>

GUIDELINES FOR ETHICS DOCUMENTS

<https://www.wjgnet.com/bpg/GerInfo/287>

GUIDELINES FOR NON-NATIVE SPEAKERS OF ENGLISH

<https://www.wjgnet.com/bpg/gerinfo/240>

PUBLICATION ETHICS

<https://www.wjgnet.com/bpg/GerInfo/288>

PUBLICATION MISCONDUCT

<https://www.wjgnet.com/bpg/gerinfo/208>

ARTICLE PROCESSING CHARGE

<https://www.wjgnet.com/bpg/gerinfo/242>

STEPS FOR SUBMITTING MANUSCRIPTS

<https://www.wjgnet.com/bpg/GerInfo/239>

ONLINE SUBMISSION

<https://www.f6publishing.com>



Myeloid sarcoma as the only manifestation in a rare mixed lineage leukemia-fusion-driven acute myeloid leukemia: A case report

Sheng-Jie Tang, Qi-Guo Zhang

Specialty type: Medicine, research and experimental

Provenance and peer review: Unsolicited article; Externally peer reviewed.

Peer-review model: Single blind

Peer-review report's scientific quality classification

Grade A (Excellent): 0
Grade B (Very good): 0
Grade C (Good): C, C, C
Grade D (Fair): 0
Grade E (Poor): 0

P-Reviewer: Akbulut S, Turkey; Salvadori M, Italy

Received: June 26, 2023

Peer-review started: June 26, 2023

First decision: July 4, 2023

Revised: July 7, 2023

Accepted: August 8, 2023

Article in press: August 8, 2023

Published online: September 6, 2023



Sheng-Jie Tang, The First Clinical Medical College of Xuzhou Medical University, Xuzhou 221004, Jiangsu Province, China

Qi-Guo Zhang, Department of Hematology, Chuzhou Hospital affiliated to Anhui Medical University, Chuzhou 239001, Anhui Province, China

Corresponding author: Qi-Guo Zhang, MD, Chief Physician, Department of Hematology, Chuzhou Hospital affiliated to Anhui Medical University, No. 369 Zuiwen Road, Chuzhou 239001, Anhui Province, China. qgzhang8@sina.com

Abstract

BACKGROUND

The mixed lineage leukemia (MLL)-eleven-nineteen lysine-rich leukemia (ELL) fusion gene is a rare occurrence among the various MLL fusion genes. We present the first case in which myeloid sarcoma (MS) was the only manifestation of adult MLL-ELL-positive acute myeloid leukemia (AML).

CASE SUMMARY

We report a case of a 33-year-old male patient who was admitted in June 2022 with a right occipital area mass measuring approximately 7 cm × 8 cm. Blood work was normal. The patient underwent right occipital giant subscalp mass excision and incisional flap grafting. Immunohistochemistry was positive for myeloperoxidase, CD43 and CD45 and negative for CD3, CD20, CD34, and CD56. The bone marrow aspirate showed hypercellularity with 20% myeloblasts. Flow cytometry showed that myeloblasts accounted for 27.21% of the nucleated cells, which expressed CD33, CD38, and CD117. The karyotype was 46, XY, t(11, 19)(q23; p13.1), -12, + mar/46, XY. Next-generation sequencing showed a fusion of MLL exon 7 to exon 2 of ELL. A diagnosis of MLL-ELL-positive AML (M2 subtype) with subcutaneous MS was made.

CONCLUSION

MLL-ELL-positive AML with MS is a rare clinical entity. Additional research is needed to elucidate the molecular mechanisms of the pathogenesis of MS.

Key Words: Myeloid sarcoma; Acute myeloid leukemia; Mixed lineage leukemia-eleven-nineteen lysine-rich leukemia; Transplantation; Case report

©The Author(s) 2023. Published by Baishideng Publishing Group Inc. All rights reserved.

Core Tip: This study described myeloid sarcoma as the first and only manifestation in an adult patient with mixed lineage leukemia-eleven-nineteen lysine-rich leukemia-positive acute myeloid leukemia. Based on our findings and information from a few previous reports, we speculate that our patient had (1): Transformation of preleukemia cells in the marrow followed by spread to extramedullary sites; or (2) homing of preleukemia cells to extramedullary sites, followed by spreading back to bone marrow. The current study helps increase the awareness of this particular disease and reduce the clinical underdiagnosis rate.

Citation: Tang SJ, Zhang QG. Myeloid sarcoma as the only manifestation in a rare mixed lineage leukemia-fusion-driven acute myeloid leukemia: A case report. *World J Clin Cases* 2023; 11(25): 6000-6004

URL: <https://www.wjgnet.com/2307-8960/full/v11/i25/6000.htm>

DOI: <https://dx.doi.org/10.12998/wjcc.v11.i25.6000>

INTRODUCTION

Myeloid sarcoma (MS) is a rare disease characterized by an extramedullary tumor composed of immature myeloid cells. When differentiating any extramedullary lesion infiltrated by heterogeneous cells, clinicians should consider the possibility of MS[1]. Mixed lineage leukemia (MLL) gene rearrangements define a unique leukemia with distinctive pathophysiology and phenotype. The MLL gene encodes a large histone methyltransferase that directly binds and actively regulates gene transcription. In MLL rearrangement leukemia, menin acts as an oncogenic cofactor leading to leukemogenesis by mediating aberrant gene expression through the HOX gene and cofactor meis homeobox 1[2]. A chromosomal translocation *t* (11; 19) (q23; P13), with breakpoints mainly located within the 19p13.1 subband, generates the MLL-eleven-nineteen lysine-rich leukemia (ELL) fusion gene and is predominantly found in acute myeloid leukemia (AML)[3]. We present a rare case in which MS was the only manifestation of adult MLL-ELL-positive AML.

CASE PRESENTATION

Chief complaints

A 33-year-old male patient was admitted in June 2022 with a right occipital area mass measuring approximately 7 cm × 8 cm.

History of present illness

The patient had scalp swelling for 4 mo prior to this presentation.

History of past illness

The patient had no history of chronic conditions.

Personal and family history

The patients' personal and family histories were not significant.

Physical examination

A hard, immobile mass measuring approximately 7 cm × 8 cm was observed in the right occipital region of the skull. The local scalp color appeared dark brown with no abnormalities in the surrounding area.

Laboratory examinations

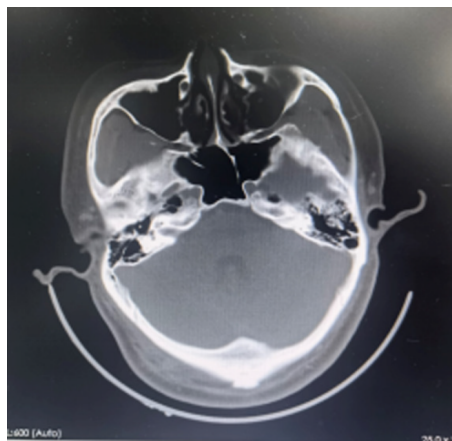Blood work was normal. No malignant cells were seen in the cerebrospinal fluid.

Imaging examinations

No bone erosion or abnormalities were detected in the brain parenchyma by computed tomography scan (Figure 1). The cranial magnetic resonance imaging also showed no significant abnormalities.

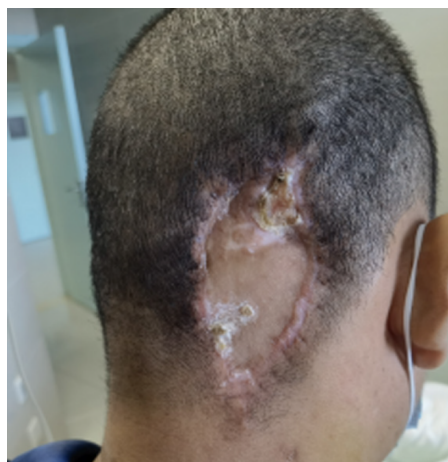Further diagnostic work-up

The patient underwent right occipital giant subscalp mass excision and incisional flap grafting (Figure 2). Resection tissue staining showed a small round-cell tumor, which was suspected to be lymphoma. Immunohistochemistry was positive for myeloperoxidase, CD43 and CD45 and negative for CD3, CD20, CD34, and CD56. The bone marrow (BM) aspirate showed hypercellularity with 20% myeloblasts. Flow cytometry showed that myeloblasts accounted for 27.21% of the nucleated cells, which expressed CD33, CD38, and CD117 (Figure 3). The karyotype was 46, XY, *t* (11, 19) (q23; p13.1), -12, + mar[4]/46, XY[5]. Next-generation sequencing showed a fusion of MLL exon 12 to exon 1 of ELL.



DOI: 10.12998/wjcc.v11.i25.6000 Copyright ©The Author(s) 2023.

Figure 1 Head computed tomography. Anomalous density shadow of the right occipital subcutaneous region.



DOI: 10.12998/wjcc.v11.i25.6000 Copyright ©The Author(s) 2023.

Figure 2 Skin grafting after myeloid sarcoma resection.

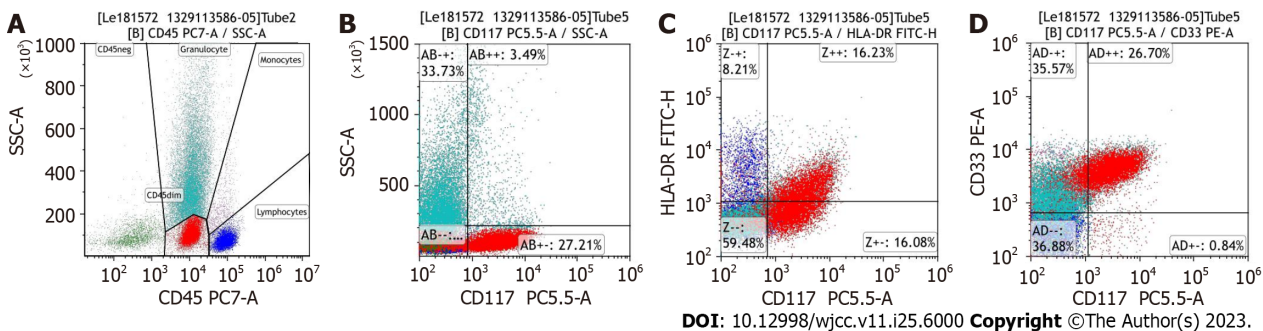


Figure 3 Flow cytometric analysis of the bone marrow aspirate. A: Expression of CD45 of all cell populations; B: Increase of CD117 positive cells was demonstrated; C: Increase of CD117/HLA-DR positive cells was demonstrated; D: Increase of CD117/CD33 positive cells was demonstrated.

FINAL DIAGNOSIS

A diagnosis of MLL-ELL-positive AML (M2 subtype) with subcutaneous MS was made.

TREATMENT

Complete remission (CR) was achieved after the first course of standard 7 + 3 (idarubicin and cytarabine) induction

chemotherapy. He then received 2 cycles of high-dose cytarabine-based consolidation therapy followed by a myeloablative, allogeneic, matched, unrelated-donor hematopoietic stem cell transplant.

OUTCOME AND FOLLOW-UP

When last seen in May 2023, he was still in CR.

DISCUSSION

To our knowledge, we present the first case in which MS was the only manifestation of adult MLL-ELL-positive AML. The molecular mechanisms underlying extramedullary involvement remain unknown, but 70% of MS cases have concurrent AML. "extramedullary AML tumor" may be a more accurate term for MS[6].

The MLL-ELL fusion gene is a rare occurrence among the various MLL fusion genes. It is associated with the genesis of AML in a mouse model[7]. MLL-ELL fusions are present in 12% of adult AML patients, 7% of pediatric AML patients and 15% of infant AML patients[8]. No concurrent MLL-ELL-positive MS cases have been mentioned in the literature, although two cases of MLL-ELL-positive MS with no evidence of AML have been reported[9,10]. Based on our findings and information from a few previous reports, we speculate that our patient had (1): Transformation of preleukemia cells in the marrow followed by spread to extramedullary sites; or and (2) homing of preleukemia cells to extramedullary sites, followed by spreading back to BM. This hypothesis has been proven in the development of blastic plasmacytoid dendritic cell neoplasm[4].

MLL-ELL-positive AML is associated with high response rates to conventional chemotherapy, but relapse is common, and some patients may benefit from allogeneic hematopoietic stem cell transplantation (allo-HSCT)[11]. Our patient achieved BM minimal residual disease-negative CR, and concurrently, 10% hematogones[5] existed in his BM, which may imply longer overall survival and a lower rate of acute graft-versus-host disease after HSCT.

CONCLUSION

In conclusion, MLL-ELL-positive AML with MS is a rare clinical entity. Additional research is needed to elucidate the molecular mechanisms of the pathogenesis of MS.

FOOTNOTES

Author contributions: Tang SJ performed the study, collected the data, analyzed/interpreted the data, and drafted the article; Zhang QG supervised the study, contributed to the experimental design, and revised the paper.

Supported by Scientific Research Project of Anhui Provincial Health Commission, No. AHWJ2021b005.

Informed consent statement: Informed written consent was obtained from the patient and her parents for the publication of this report and any accompanying images.

Conflict-of-interest statement: All the authors report no relevant conflicts of interest for this article.

CARE Checklist (2016) statement: The authors have read the CARE Checklist (2016), and the manuscript was prepared and revised according to the CARE Checklist (2016).

Open-Access: This article is an open-access article that was selected by an in-house editor and fully peer-reviewed by external reviewers. It is distributed in accordance with the Creative Commons Attribution NonCommercial (CC BY-NC 4.0) license, which permits others to distribute, remix, adapt, build upon this work non-commercially, and license their derivative works on different terms, provided the original work is properly cited and the use is non-commercial. See: <https://creativecommons.org/licenses/by-nc/4.0/>

Country/Territory of origin: China

ORCID number: Sheng-Jie Tang 0009-0000-3563-2567.

S-Editor: Qu XL

L-Editor: A

P-Editor: Zhao S

REFERENCES

- 1 **Almond LM**, Charalampakis M, Ford SJ, Gourevitch D, Desai A. Myeloid Sarcoma: Presentation, Diagnosis, and Treatment. *Clin Lymphoma Myeloma Leuk* 2017; **17**: 263-267 [PMID: [28342811](#) DOI: [10.1016/j.clml.2017.02.027](#)]
- 2 **Krivtsov AV**, Evans K, Gadrey JY, Eschle BK, Hatton C, Uckelmann HJ, Ross KN, Perner F, Olsen SN, Pritchard T, McDermott L, Jones CD, Jing D, Braytee A, Chacon D, Earley E, McKeever BM, Claremon D, Gifford AJ, Lee HJ, Teicher BA, Pimanda JE, Beck D, Perry JA, Smith MA, McGeehan GM, Lock RB, Armstrong SA. A Menin-MLL Inhibitor Induces Specific Chromatin Changes and Eradicates Disease in Models of MLL-Rearranged Leukemia. *Cancer Cell* 2019; **36**: 660-673.e11 [PMID: [31821784](#) DOI: [10.1016/j.ccell.2019.11.001](#)]
- 3 **Panagopoulos I**, Gorunova L, Kerndrup G, Spetalen S, Tierens A, Osnes LT, Andersen K, Müller LS, Hellebostad M, Zeller B, Heim S. Rare MLL-ELL fusion transcripts in childhood acute myeloid leukemia-association with young age and myeloid sarcomas? *Exp Hematol Oncol* 2015; **5**: 8 [PMID: [26949571](#) DOI: [10.1186/s40164-016-0037-2](#)]
- 4 **Griffin GK**, Booth CAG, Togami K, Chung SS, Ssozi D, Verga JA, Bouyssou JM, Lee YS, Shanmugam V, Hornick JL, LeBoeuf NR, Morgan EA, Bernstein BE, Hovestadt V, van Galen P, Lane AA. Ultraviolet radiation shapes dendritic cell leukaemia transformation in the skin. *Nature* 2023; **618**: 834-841 [PMID: [37286599](#) DOI: [10.1038/s41586-023-06156-8](#)]
- 5 **Chantepie SP**, Cornet E, Salaün V, Reman O. Hematogones: an overview. *Leuk Res* 2013; **37**: 1404-1411 [PMID: [23932356](#) DOI: [10.1016/j.leukres.2013.07.024](#)]
- 6 **Shallis RM**, Gale RP, Lazarus HM, Roberts KB, Xu ML, Seropian SE, Gore SD, Podoltsev NA. Myeloid sarcoma, chloroma, or extramedullary acute myeloid leukemia tumor: A tale of misnomers, controversy and the unresolved. *Blood Rev* 2021; **47**: 100773 [PMID: [33213985](#) DOI: [10.1016/j.blre.2020.100773](#)]
- 7 **Lavau C**, Luo RT, Du C, Thirman MJ. Retrovirus-mediated gene transfer of MLL-ELL transforms primary myeloid progenitors and causes acute myeloid leukemias in mice. *Proc Natl Acad Sci U S A* 2000; **97**: 10984-10989 [PMID: [10995463](#) DOI: [10.1073/pnas.190167297](#)]
- 8 **Meyer C**, Burmeister T, Gröger D, Tsaar G, Fechina L, Renneville A, Sutton R, Venn NC, Emerenciano M, Pombo-de-Oliveira MS, Barbieri Blunck C, Almeida Lopes B, Zuna J, Trka J, Ballerini P, Lapillonne H, De Braekeleer M, Cazzaniga G, Corral Abascal L, van der Velden VHJ, Delabesse E, Park TS, Oh SH, Silva MLM, Lund-Aho T, Juvonen V, Moore AS, Heidenreich O, Vormoor J, Zerkalenkova E, Olshanskaya Y, Bueno C, Menendez P, Teigler-Schlegel A, Zur Stadt U, Lentjes J, Göhring G, Kustanovich A, Aleinikova O, Schäfer BW, Kubetzko S, Madsen HO, Gruhn B, Duarte X, Gameiro P, Lippert E, Bidet A, Cayuela JM, Clappier E, Alonso CN, Zwaan CM, van den Heuvel-Eibrink MM, Izraeli S, Trakhtenbrot L, Archer P, Hancock J, Möricke A, Alten J, Schrappe M, Stanulla M, Strehl S, Attarbaschi A, Dworzak M, Haas OA, Panzer-Grümayer R, Sedek L, Szczepański T, Caye A, Suarez L, Cavé H, Marschalek R. The MLL recombinome of acute leukemias in 2017. *Leukemia* 2018; **32**: 273-284 [PMID: [28701730](#) DOI: [10.1038/leu.2017.213](#)]
- 9 **Ouansafi I**, Arabadjief M, Mathew S, Srivastara S, Orazi A. Myeloid sarcoma with t(11;19)(q23;p13.3) (MLL-ELL) in the uterine cervix. *Br J Haematol* 2011; **153**: 679 [PMID: [21501132](#) DOI: [10.1111/j.1365-2141.2010.08411.x](#)]
- 10 **Bao H**, Gao J, Chen YH, Altman JK, Frankfurt O, Wilson AL, Sukhanova M, Chen Q, Lu X. Rare myeloid sarcoma with KMT2A (MLL)-ELL fusion presenting as a vaginal wall mass. *Diagn Pathol* 2019; **14**: 26 [PMID: [30922345](#) DOI: [10.1186/s13000-019-0804-6](#)]
- 11 **Muto T**, Takeuchi M, Yamazaki A, Sugita Y, Tsukamoto S, Sakai S, Takeda Y, Mimura N, Ohwada C, Sakaida E, Aotsuka N, Iseki T, Nakaseko C. Efficacy of myeloablative allogeneic hematopoietic stem cell transplantation in adult patients with MLL-ELL-positive acute myeloid leukemia. *Int J Hematol* 2015; **102**: 86-92 [PMID: [25758097](#) DOI: [10.1007/s12185-015-1779-z](#)]



Published by **Baishideng Publishing Group Inc**
7041 Koll Center Parkway, Suite 160, Pleasanton, CA 94566, USA

Telephone: +1-925-3991568

E-mail: bpgoffice@wjgnet.com

Help Desk: <https://www.f6publishing.com/helpdesk>

<https://www.wjgnet.com>

