

# World Journal of *Radiology*

*World J Radiol* 2023 December 28; 15(12): 338-369



**ORIGINAL ARTICLE****Retrospective Study**

- 338 Deep learning-based magnetic resonance imaging reconstruction for improving the image quality of reduced-field-of-view diffusion-weighted imaging of the pancreas

*Takayama Y, Sato K, Tanaka S, Murayama R, Goto N, Yoshimitsu K*

**Observational Study**

- 350 Factors associated with gastrointestinal stromal tumor rupture and pathological risk: A single-center retrospective study

*Liu JZ, Jia ZW, Sun LL*

- 359 Methods for improving colorectal cancer annotation efficiency for artificial intelligence-observer training

*Grudza M, Salinel B, Zeien S, Murphy M, Adkins J, Jensen CT, Bay C, Kodibagkar V, Koo P, Dragovich T, Choti MA, Kundranda M, Syeda-Mahmood T, Wang HZ, Chang J*

**ABOUT COVER**

Peer Reviewer of *World Journal of Radiology*, Lee K Rousslang, MD, Resident Physician, Department of Radiology, Tripler Army Medical Center, Honolulu, HI 96859, United States. lee.k.rousslang.civ@mail.mil

**AIMS AND SCOPE**

The primary aim of *World Journal of Radiology* (WJR, *World J Radiol*) is to provide scholars and readers from various fields of radiology with a platform to publish high-quality basic and clinical research articles and communicate their research findings online.

WJR mainly publishes articles reporting research results and findings obtained in the field of radiology and covering a wide range of topics including state of the art information on cardiopulmonary imaging, gastrointestinal imaging, genitourinary imaging, musculoskeletal imaging, neuroradiology/head and neck imaging, nuclear medicine and molecular imaging, pediatric imaging, vascular and interventional radiology, and women's imaging.

**INDEXING/ABSTRACTING**

The WJR is now abstracted and indexed in PubMed, PubMed Central, Emerging Sources Citation Index (Web of Science), Reference Citation Analysis, China Science and Technology Journal Database, and Superstar Journals Database. The 2023 Edition of Journal Citation Reports® cites the 2022 impact factor (IF) for WJR as 2.5; IF without journal self cites: 2.3; 5-year IF: 2.5; Journal Citation Indicator: 0.54.

**RESPONSIBLE EDITORS FOR THIS ISSUE**

Production Editor: Si Zhao; Production Department Director: Xu Guo; Editorial Office Director: Jia-Ping Yan.

**NAME OF JOURNAL**

*World Journal of Radiology*

**ISSN**

ISSN 1949-8470 (online)

**LAUNCH DATE**

January 31, 2009

**FREQUENCY**

Monthly

**EDITORS-IN-CHIEF**

Thomas J Vogl

**EDITORIAL BOARD MEMBERS**

<https://www.wjgnet.com/1949-8470/editorialboard.htm>

**PUBLICATION DATE**

December 28, 2023

**COPYRIGHT**

© 2023 Baishideng Publishing Group Inc

**INSTRUCTIONS TO AUTHORS**

<https://www.wjgnet.com/bpg/gerinfo/204>

**GUIDELINES FOR ETHICS DOCUMENTS**

<https://www.wjgnet.com/bpg/gerinfo/287>

**GUIDELINES FOR NON-NATIVE SPEAKERS OF ENGLISH**

<https://www.wjgnet.com/bpg/gerinfo/240>

**PUBLICATION ETHICS**

<https://www.wjgnet.com/bpg/gerinfo/288>

**PUBLICATION MISCONDUCT**

<https://www.wjgnet.com/bpg/gerinfo/208>

**ARTICLE PROCESSING CHARGE**

<https://www.wjgnet.com/bpg/gerinfo/242>

**STEPS FOR SUBMITTING MANUSCRIPTS**

<https://www.wjgnet.com/bpg/gerinfo/239>

**ONLINE SUBMISSION**

<https://www.f6publishing.com>

## Observational Study

## Factors associated with gastrointestinal stromal tumor rupture and pathological risk: A single-center retrospective study

Jia-Zheng Liu, Zhong-Wen Jia, Ling-Ling Sun

**Specialty type:** Radiology, nuclear medicine and medical imaging**Provenance and peer review:** Unsolicited article; Externally peer reviewed.**Peer-review model:** Single blind**Peer-review report's scientific quality classification**Grade A (Excellent): 0  
Grade B (Very good): B  
Grade C (Good): C  
Grade D (Fair): D  
Grade E (Poor): E**P-Reviewer:** Dimofte GM, Romania; Nishida T, Japan**Received:** August 26, 2023**Peer-review started:** August 26, 2023**First decision:** October 9, 2023**Revised:** October 26, 2023**Accepted:** December 12, 2023**Article in press:** December 12, 2023**Published online:** December 28, 2023**Jia-Zheng Liu, Zhong-Wen Jia, Ling-Ling Sun**, Department of Radiology, The Fourth Affiliated Hospital of China Medical University, Shenyang 110033, Liaoning Province, China**Corresponding author:** Zhong-Wen Jia, PhD, Chief Physician, Department of Radiology, The Fourth Affiliated Hospital of China Medical University, No. 4 Chongshan East Road, Huanggu District, Shenyang 110033, Liaoning Province, China. [jjazhongwen@126.com](mailto:jjazhongwen@126.com)

## Abstract

## BACKGROUND

Gastrointestinal stromal tumor (GIST) is a rare gastrointestinal mesenchymal tumor with potential malignancy. Once the tumor ruptures, regardless of tumor size and mitotic number, it can be identified into a high-risk group. It is of great significance for the diagnosis, treatment, and prognosis of GIST if non-invasive examination can be performed before surgery to accurately assess the risk of tumor.

## AIM

To identify the factors associated with GIST rupture and pathological risk.

## METHODS

A cohort of 50 patients with GISTs, as confirmed by postoperative pathology, was selected from our hospital. Clinicopathological and computed tomography data of the patients were collected. Logistic regression analysis was used to evaluate factors associated with GIST rupture and pathological risk grade.

## RESULTS

Pathological risk grade, tumor diameter, tumor morphology, internal necrosis, gas-liquid interface, and Ki-67 index exhibited significant associations with GIST rupture ( $P < 0.05$ ). Gender, tumor diameter, tumor rupture, and Ki-67 index were found to be correlated with pathological risk grade of GIST ( $P < 0.05$ ). Multifactorial logistic regression analysis revealed that male gender and tumor diameter  $\geq 10$  cm were independent predictors of a high pathological risk grade of GIST [odds ratio (OR) = 11.12, 95% confidence interval (95%CI): 1.81-68.52,  $P = 0.01$ ; OR = 22.96, 95%CI: 2.19-240.93,  $P = 0.01$ ]. Tumor diameter  $\geq 10$  cm, irregular shape, internal necrosis, gas-liquid interface, and Ki-67 index  $\geq 10$  were identified as independent predictors of a high risk of GIST rupture (OR = 9.67, 95%CI: 2.15-43.56,  $P = 0.01$ ; OR = 35.44, 95%CI: 4.01-313.38,  $P < 0.01$ ; OR = 18.75, 95%CI: 3.40-103.34,  $P < 0.01$ ; OR = 27.00, 95%CI: 3.10-235.02,  $P < 0.01$ ; OR = 4.43, 95%CI: 1.10-

17.92,  $P = 0.04$ ).

## CONCLUSION

Tumor diameter, tumor morphology, internal necrosis, gas-liquid, and Ki-67 index are associated with GIST rupture, while gender and tumor diameter are linked to the pathological risk of GIST. These findings contribute to our understanding of GIST and may inform non-invasive examination strategies and risk assessment for this condition.

**Key Words:** Gastrointestinal stromal tumors; Imaging findings; Tumor rupture; Pathological risk grades

©The Author(s) 2023. Published by Baishideng Publishing Group Inc. All rights reserved.

**Core Tip:** Gastrointestinal stromal tumor (GIST) biopsy is inconvenient, has a low yield, and easily leads to tumor metastasis. It is of great significance for the diagnosis, treatment, and prognosis of GIST if non-invasive examination can be performed before surgery to accurately assess the risk of tumor. The results of our study found that tumor diameter, tumor morphology, internal necrosis, and gas-liquid interface are related to the rupture of GIST, and sex and tumor diameter are related to the pathological risk of GIST. The results of this study provides ideas for non-invasive examination and risk assessment of GIST.

**Citation:** Liu JZ, Jia ZW, Sun LL. Factors associated with gastrointestinal stromal tumor rupture and pathological risk: A single-center retrospective study. *World J Radiol* 2023; 15(12): 350-358

**URL:** <https://www.wjgnet.com/1949-8470/full/v15/i12/350.htm>

**DOI:** <https://dx.doi.org/10.4329/wjr.v15.i12.350>

## INTRODUCTION

Gastrointestinal stromal tumor (GIST), a rare mesenchymal tumor of the gastrointestinal tract, presents a potential for malignancy and constitutes 1%-3% of gastrointestinal malignancies[1,2]. Immunohistochemical analysis of GIST typically reveals positive expression of CD117, CD34, or DOG-1[3,4]. Due to its invasive nature and propensity for recurrence and metastasis, the clinical assessment of prognosis following GIST surgery heavily relies on pathological evaluation. However, preoperative selection of appropriate treatment methods lacks a foundation based on pathological assessment. Notably, imaging characteristics of GIST have been observed, and significant disparities in postoperative pathological risk grades have been identified between GISTs exhibiting distinct computed tomography (CT) features prior to surgery, thereby highlighting the crucial role of CT in GIST diagnosis[5,6].

GISTs display unpredictable and variable biological behavior, rendering the distinction between benign and malignant tumors challenging[2,7]. In the early stages, GISTs were classified as either benign or malignant; however, clinical experience has revealed that tumors initially determined as "benign" by histopathology may later metastasize. Consequently, many pathologists advocate for grouping based on pathological risk grades[8,9]. Once the tumor ruptures, irrespective of size and mitotic count, it can be classified into a high-risk group.

GIST biopsy is inconvenient and has a limited yield, and open biopsies can potentially induce tumor metastasis, precluding risk assessment in such cases. Risk assessment cannot be performed for biopsied cases. Therefore, needle biopsy is not recommended prior to surgery for GISTs that can be completely resected[10]. Given the divergent treatment and prognosis of GISTs compared to non-epithelial tumors like lymphoma and schwannoma, preoperative imaging diagnosis and evaluation assume paramount importance. The ability to perform non-invasive examinations before surgery to accurately assess tumor risk would hold significant implications for GIST diagnosis, treatment, and prognosis. In light of this, we postulated that imaging findings possess clinical utility in predicting GIST rupture and pathological risk. Consequently, this study aimed to offer insights into non-invasive examination strategies and risk assessment for GISTs by examining the correlation between imaging findings and GIST rupture and pathological risk.

## MATERIALS AND METHODS

### Patients

Fifty patients diagnosed with GISTs were included in this retrospective study, following confirmation of the diagnosis through postoperative pathology at our institution. The patients' clinicopathological and CT data were systematically collected. The study cohort consisted of individuals aged between 18 and 84 years, comprising 28 males and 22 females. In order to ensure the reliability and relevance of the data, specific inclusion and exclusion criteria were applied. The inclusion criteria encompassed patients who had undergone biopsy or surgery at our hospital, with complete and well-documented pathological data, clear risk grading, and comprehensive clinical and CT data available. Furthermore, only

primary tumors were considered. Patients who had not undergone CT examination prior to surgery or whose CT image quality was deemed inadequate were excluded. Additionally, cases with uncertain tumor pathological risk grading or those involving tumor relapse were also excluded from the study cohort.

### Data collected

In this investigation, we meticulously gathered a comprehensive set of clinical and pathological data from a cohort of 50 patients diagnosed with GISTs. The dataset encompassed crucial patient demographics such as age and gender, as well as pivotal pathological indicators including risk grade, tumor diameter, morphology, necrosis, rupture status, gas-liquid interface, tumor location, mitotic figures, and Ki-67 index. The assessment of pathological risk was meticulously categorized into four distinct levels, namely, very low, low, moderate, and high, enabling a comprehensive evaluation of the disease severity [8,11,12] (Supplementary Table 1).

### CT scanning and indicators

Contrast-enhanced CT scanning was performed using a 256-slice computed tomography scanner (Brilliance iCT, Philips) with the following scanning conditions: Peak kilovoltage of 120 and tube current (mA) ranging from 138 to 458. The following parameters were assessed: (1) Tumor diameter: The maximum diameter of the tumor was measured on the coronal image; (2) Tumor morphology: The shape of the tumor was evaluated to determine if it exhibited a regular shape. A tumor with an elliptical or round shape was considered regular; (3) Boundary: The boundary of the tumor was assessed based on the presence of a clear boundary or an unclear boundary. An unclear boundary indicated a potential for invasion; (4) Primary tumor site: The primary tumor site was determined based on the location of the initial lesion; (5) Necrosis: The presence of a necrotic area was determined based on the CT results; and (6) Gas-liquid interface: The presence of a gas-liquid interface was assessed based on the imaging results. These parameters were evaluated to assess the risk factors associated with GIST rupture and pathological risk.

### Criteria for tumor rupture

The criteria for tumor rupture included: (1) Tumor rupture or overflow; (2) Presence of bloody ascites; (3) Gastrointestinal perforation at the tumor site; (4) Microscopic infiltration of adjacent organs; (5) Intra-lesional dissection or segmental resection; and (6) Incisional biopsy [12,13].

### Statistical analysis

SPSS 26.0 (IBM Corp, Armonk, NY) software was used for statistical analyses. Enumeration data are expressed as frequencies, and statistical analysis was performed by the  $\chi^2$  test. Pearson correlation was used to analyze the correlation between age, gender, pathological risk grade, tumor diameter, tumor morphology, internal necrosis, tumor rupture, gas-liquid interface, tumor site, mitotic figures, and Ki-67 index.  $P < 0.05$  was considered statistically significant.

## RESULTS

### Analysis of related factors of GIST rupture

The results of the comparison of clinical data between the unruptured and ruptured GISTs are shown in Table 1. Statistical analysis showed that pathological risk, tumor diameter, tumor morphology, internal necrosis, and gas-liquid interface were associated with GIST rupture ( $P < 0.05$ ). The differences in age, gender, primary site, mitotic count, and Ki-67 index of the ruptured group and the unruptured group were not statistically significant ( $P > 0.05$ ). GISTs with a high pathological risk grade, large tumor diameter, irregular shape, internal tumor necrosis, and gas-fluid interface were prone to rupture.

### Analysis of risk factors in GIST patients

The pathological risk grade assessment of GISTs was carried out through various observation indicators of CT images. The results showed that there were 24 cases of low risk, 6 cases of intermediate risk, and 20 cases of high risk. The analysis results showed that gender, tumor diameter, tumor rupture, and Ki-67 index were associated with the pathological risk grade of GISTs ( $P < 0.05$ ) (Table 2). We found that male GIST patients had a higher pathological risk grade, and the longer the tumor diameter, the higher the pathological risk of GISTs. GIST patients whose tumors were prone to rupture had a higher pathological risk grade, multiple gas shadows were common in the central necrotic area of ruptured tumors (Figure 1A), gas-liquid interface (Figure 1B) was visible in the tumor, and pus coating was formed next to the tumor (Figure 1C).

### Logistic regression analysis of factors associated with pathologic risk grade of GISTs

The results of the logistic regression analysis of the factors associated with the pathological risk grade of GISTs are shown in Table 3. Multifactorial logistic regression analysis showed that male gender and tumor diameter  $\geq 10$  cm were independently correlated with a high pathological risk grade of GISTs [odds ratio (OR) = 11.12, 95% confidence interval (95%CI): 1.81-68.52,  $P = 0.01$ ; OR = 22.96, 95%CI: 2.19-240.93,  $P = 0.01$ ].

**Table 1 Comparison of clinical data between unruptured and ruptured gastrointestinal stromal tumors**

	Unruptured group (n = 38)	Rupture group (n = 12)	Statistical value	P value
Age (yr)	64.79 ± 9.75	57.17 ± 20.61	1.24	0.24
Gender			2.31	0.13
Male	19	9		
Female	19	3		
Pathological risk grade			8.47	0.02
Low risk	21	3		
Intermediate risk	6	0		
High risk	11	9		
Tumor diameter (cm)	3.25 (2, 5.25)	9.0 (4.5, 13.63)	2.60	0.01
Tumor shape			17.56	< 0.01
Irregular	9	11		
Regular	29	1		
Internal necrosis			15.35	< 0.01
No	30	2		
Yes	8	10		
Gas-liquid interface			23.68	< 0.01
Absence	27	1		
Presence	11	11		
Primary site			0.23	0.63
Gastric	22	6		
Small bowel	16	6		
Mitotic count (50/HPF)	6.11 ± 2.60	6.17 ± 1.64	0.08	0.94
Ki-67 index (%)	5.50 (4.75, 8.00)	7.50 (5.00, 14.25)	1.15	0.25

HPF: High-power field.

**Logistic regression analysis of factors associated with GIST rupture**

The results of the logistic regression analysis of the factors associated with the tumor rupture of GIST are shown in Table 4. Multifactorial logistic regression analysis showed that tumor diameter ≥ 10 cm, irregular shape, internal necrosis, gas-liquid interface, and Ki-67 index ≥ 10 were independently correlated with a high risk of tumor rupture of GISTs (OR = 9.67, 95%CI: 2.15-43.56, *P* = 0.01; OR = 35.44, 95%CI: 4.01-313.38, *P* < 0.01; OR = 18.75, 95%CI: 3.40-103.34, *P* < 0.01; OR = 27.00, 95%CI: 3.10-235.02, *P* < 0.01; OR = 4.43, 95%CI: 1.10-17.92, *P* = 0.04).

**DISCUSSION**

In this study, our findings indicated that certain factors are associated with the rupture of GISTs in the patients that we screened. These factors include tumor diameter, tumor shape, internal necrosis, and gas-liquid interface. Additionally, we found that being male and having a tumor diameter ≥ 10 cm are independent correlates of a high pathological risk grade of GISTs.

GIST is a gastrointestinal tumor that has seen a significant increase in the incidence and diagnosis rate in recent years. Rupture and bleeding of GISTs are considered to be serious and dangerous complications that require urgent attention[2, 14]. The clinical manifestations of spontaneous tumor rupture and hemorrhage are atypical, characterized by a rapid onset. Many patients are admitted to the hospital with acute abdomen, resulting in delayed surgery. Therefore, timely diagnosis and treatment are crucial for improving patient prognosis[15,16].

Tumor rupture is an important risk factor for recurrence after GIST resection and is also an indicator for adjuvant imatinib therapy[13]. Numerous studies have confirmed that tumor rupture is associated with an increased risk of recurrence. For example, Yanagimoto *et al*[17] identified that tumor size, mitotic count, tumor location, and tumor rupture were important prognostic factors for GIST. Hølmekjær *et al*[18] and Nishida *et al*[19] found that tumor rupture was an



**Table 2 Analysis of related factors of pathological risk grade of gastrointestinal stromal tumors**

	Low risk (n = 24)	Intermediate risk (n = 6)	High risk (n = 20)	$\chi^2$ value	P value
Age (yr)				1.94	0.38
< 60	5	2	8		
≥ 60	19	4	12		
Gender				8.10	0.02
Male	9	3	16		
Female	15	3	4		
Tumor diameter (cm)				10.47	0.01
< 10	22	6	11		
≥ 10	2	0	9		
Tumor shape				2.26	0.32
Irregular	9	1	10		
Regular	15	5	10		
Internal necrosis				5.37	0.07
No	18	5	9		
Yes	6	1	11		
Tumor rupture				8.47	0.02
No	21	6	11		
Yes	3	0	9		
Gas-liquid interface				0.79	0.67
Absence	15	3	10		
Presence	9	3	10		
Primary site				3.46	0.18
Gastric	16	4	8		
Small bowel	8	2	12		
Mitotic count (50/HPF)				4.49	0.11
< 5	8	3	3		
≥ 5	16	2	17		
Ki-67 index (%)				6.30	0.04
< 10	21	5	11		
≥ 10	3	1	9		

HPF: High-power field.

independent prognostic factor for recurrence-free survival. These findings highlight the significance of tumor rupture in evaluating the prognosis of GIST patients and its association with the poor outcomes.

Furthermore, approximately half of GIST ruptures are spontaneous and cannot be prevented. Therefore, there is growing interest in studying factors related to tumor rupture[19-22]. Our study identified tumor diameter, tumor shape, internal necrosis, and the presence of gas-liquid interface as factors associated with GIST rupture. Previous research has also reported that larger tumor diameters are associated with a higher risk of rupture[19], and that larger tumors are more likely to experience necrosis in the central region[23]. Positive resection margins have also been strongly linked to tumor rupture[24]. Moreover, the clinical presentation of GISTs, such as an unclear tumor boundary, irregular tumor shape, and the presence of a gas-liquid interface in imaging scans, can indicate aggressive behavior and malignancy. Gas-liquid interface detection in GISTs is currently uncommon, but researchers believe that it predicts severe disease in GIST patients[25-27]. Our study found that necrosis and rupture were more likely to occur when an air-liquid interface was present, and these factors were important indicators of poor prognosis in GIST patients. However, it is important to note that the definition of tumor rupture remains controversial, and consistent standards have yet to be established[18]. Some



**Table 3 Logistic regression analysis of factors associated with the pathological risk grade of gastrointestinal stromal tumors**

	B	S.E.	Wald	Sig.	Exp (B)	95%CI for Exp (B)	
						Lower	Upper
Age ≥ 60 yr	0.44	0.90	0.24	0.63	1.55	0.27	9.07
Male gender	2.41	0.93	6.75	0.01	11.12	1.81	68.52
Tumor diameter ≥ 10 cm	3.13	1.20	6.83	0.01	22.96	2.19	240.93
Irregular shape	0.50	1.12	0.20	0.65	1.65	0.18	14.92
Internal necrosis	-1.40	1.21	1.35	0.25	0.25	0.02	2.62
Gas-liquid interface	0.50	1.26	0.16	0.69	1.64	0.14	19.48
Small bowel tumor	-0.15	0.87	0.03	0.87	0.87	0.16	4.76
50/HPF ≥ 5	-0.33	0.87	0.14	0.71	0.72	0.13	3.96
Ki-67 index ≥ 10	2.18	1.15	3.56	0.06	8.82	0.92	84.49

95%CI: 95% confidence interval; HPF: High-power field.

**Table 4 Logistic regression analysis of factors associated with rupture of gastrointestinal stromal tumors**

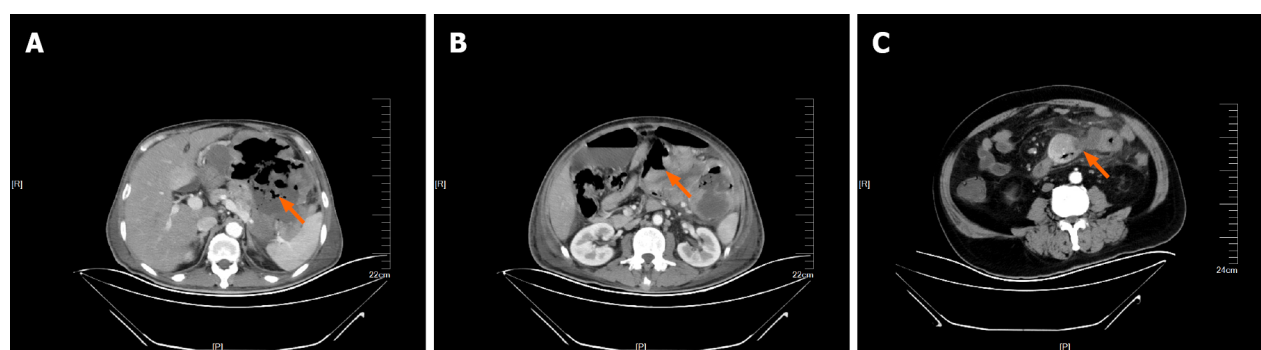
	B	S.E.	Wald	Sig.	Exp (B)	95%CI for Exp (B)	
						Lower	Upper
Age ≥ 60 yr	0.21	0.71	0.08	0.77	1.23	0.31	4.93
Male gender	-1.10	0.74	2.20	0.14	0.33	0.08	1.43
Tumor diameter ≥ 10 cm	2.27	0.77	8.72	< 0.01	9.67	2.15	43.56
Irregular shape	3.57	1.11	10.30	< 0.01	35.44	4.01	313.38
Internal necrosis	2.93	0.87	11.33	< 0.01	18.75	3.40	103.34
Gas-liquid interface	3.30	1.10	8.91	< 0.01	27.00	3.10	235.02
Small bowel tumor	-0.32	0.66	0.23	0.63	0.73	0.20	2.67
50/HPF ≥ 5	-0.84	0.85	0.97	0.33	0.43	0.08	2.29
Ki-67 index ≥ 10	1.49	0.71	4.36	0.04	4.43	1.10	17.92
High pathological risk grade	-1.31	0.74	3.12	0.08	0.27	0.06	1.16

95%CI: 95% confidence interval; HPF: High-power field.

researchers consider macroscopic damage of tumor pseudocapsule as tumor rupture[19].

In cases of GISTs with high pathological risk grades, CT signs of malignancy include invasive tumor growth, large size with uneven density and unclear boundaries, hemorrhage, liquefaction, necrosis or cystic degeneration, inhomogeneous enhancement on CT enhancement, and the presence of thick tumor blood vessels around the tumor in the arterial phase. Additionally, GISTs metastasizing to other organs and extra-GISTs located outside the gastrointestinal tract are prone to malignancy. Our study found that gender, tumor diameter, rupture, and Ki-67 index were closely associated with pathological risk grades. Lower pathological risk grades of GIST are characterized by slow tumor growth, smaller tumor diameters (usually less than 5.0 cm), round or oval shapes, uniform enhancement on scans, no invasion of surrounding tissues, and no distant organ metastasis. Conversely, higher pathological risk grades indicate worse growth and larger tumor diameters. These tumors are more likely to experience liquefaction and necrosis due to a relative lack of blood supply. Our study suggests that combining CT examination with tumor diameter, morphology, internal necrosis, gas-liquid interface, and Ki-67 index can facilitate early non-invasive assessment of GIST tumor rupture risk, providing valuable information for clinical decision-making. Additionally, clinical diagnostic information can be used to predict the pathological risk grades of GISTs, aiding in further clinical diagnosis and treatment.

There are some limitations to this study that should be acknowledged. First, the small number of GIST samples included warrants further studies with larger sample sizes. Second, the study primarily focused on GIST cases occurring in the gastric and small bowel, which may not fully reflect the relationship between tumor location and tumor rupture and pathological risk grade. Therefore, it is necessary to include more GIST cases in uncommon sites. Lastly, the study lacks information on treatment modalities and the presence of metastases.



DOI: 10.4329/wjr.v15.i12.350 Copyright ©The Author(s) 2023.

**Figure 1** Computed tomography images of ruptured gastrointestinal stromal tumors. A: Rupture of a giant gastrointestinal stromal tumor at the colosplenic flexure, with multiple gas shadows (arrow) seen in the central necrotic zone; B: Rupture of a small intestinal stromal tumor. The arrow points to the ruptured opening of the tumor, and the gas-liquid interface was seen in the abdominal cavity; C: A ruptured small intestinal stromal tumor. Gas can be seen in the tumor, and the arrow points to the formation of pus coating around the tumor.

## CONCLUSION

In summary, our study has substantiated the association between tumor diameter, tumor shape, internal necrosis, and gas-liquid interface with the occurrence of GIST rupture. Furthermore, we have identified gender and tumor diameter as independent factors influencing the pathological risk grade of GISTs. By leveraging the power of CT detection and integrating the aforementioned factors, we have successfully demonstrated the potential of non-invasive early assessment for GIST rupture and pathological risk grade. These findings hold significant promise in enhancing the clinical decision-making process by providing valuable insights.

## ARTICLE HIGHLIGHTS

### Research background

Gastrointestinal stromal tumor (GIST) is a rare gastrointestinal mesenchymal tumor. It is of great significance for the diagnosis, treatment, and prognosis of GIST if non-invasive examination can be performed before surgery to accurately assess the risk of tumor.

### Research motivation

If accurate assessment of GIST tumor risk through non-invasive examination is the focus of this study, it can provide valuable insights into non-invasive examination strategies and risk assessment of GISTs.

### Research objectives

To investigate the factors associated with GIST rupture and pathological risk, and provide insights into non-invasive examination techniques and risk assessment for GISTs.

### Research methods

A cohort of 50 GIST patients was selected from our hospital. Clinicopathological and CT data of the patients were collected. Logistic regression analysis was used to evaluate factors associated with GIST rupture and pathological risk grade.

### Research results

Male gender and tumor diameter  $\geq 10$  cm were independent predictors of a high pathological risk grade of GISTs [odds ratio (OR) = 11.12, 95% confidence interval (95%CI): 1.81-68.52,  $P = 0.01$ ; OR = 22.96, 95%CI: 2.19-240.93,  $P = 0.01$ ]. Tumor diameter  $\geq 10$  cm, irregular shape, internal necrosis, gas-liquid interface, and Ki-67 index  $\geq 10$  were identified as independent predictors of a high risk of GIST rupture (OR = 9.67, 95%CI: 2.15-43.56,  $P = 0.01$ ; OR = 35.44, 95%CI: 4.01-313.38,  $P < 0.01$ ; OR = 18.75, 95%CI: 3.40-103.34,  $P < 0.01$ ; OR = 27.00, 95%CI: 3.10-235.02,  $P < 0.01$ ; OR = 4.43, 95%CI: 1.10-17.92,  $P = 0.04$ ).

### Research conclusions

Tumor diameter, tumor morphology, internal necrosis, gas-liquid interface, and Ki-67 index are associated with GIST rupture, while gender and tumor diameter are linked to the pathological risk of GISTs. These findings contribute to our understanding of GISTs and may inform non-invasive examination strategies and risk assessment for this condition.

## Research perspectives

In later studies, we can further verify our conclusions in large-sample clinical studies to better guide clinical non-invasive examination and risk assessment of GISTs.

## FOOTNOTES

**Author contributions:** Jia ZW conceived the idea; Liu JZ and Sun LL collected and analyzed the data; Liu JZ wrote the paper; all the authors discussed the results and contributed to the final manuscript.

**Institutional review board statement:** The study was reviewed and approved by The Fourth Affiliated Hospital of China Medical University Institutional Review Board.

**Informed consent statement:** Patients were not required to give informed consent to the study because the analysis used anonymous clinical data that were obtained after each patient agreed to treatment by written consent.

**Conflict-of-interest statement:** All the authors have no conflicts of interest to disclose.

**Data sharing statement:** The data used to support the findings of this study are available from the corresponding author upon request.

**STROBE statement:** The authors have read the STROBE Statement—checklist of items, and the manuscript was prepared and revised according to the STROBE Statement—checklist of items.

**Open-Access:** This article is an open-access article that was selected by an in-house editor and fully peer-reviewed by external reviewers. It is distributed in accordance with the Creative Commons Attribution NonCommercial (CC BY-NC 4.0) license, which permits others to distribute, remix, adapt, build upon this work non-commercially, and license their derivative works on different terms, provided the original work is properly cited and the use is non-commercial. See: <https://creativecommons.org/licenses/by-nc/4.0/>

**Country/Territory of origin:** China

**ORCID number:** Zhong-Wen Jia 0009-0003-3835-1666.

**S-Editor:** Lin C

**L-Editor:** Wang TQ

**P-Editor:** Lin C

## REFERENCES

- Gastrointestinal stromal tumours. *Nat Rev Dis Primers* 2021; **7**: 21 [PMID: 33737509 DOI: 10.1038/s41572-021-00262-5]
- Ho MY, Blanke CD. Gastrointestinal stromal tumors: disease and treatment update. *Gastroenterology* 2011; **140**: 1372-6.e2 [PMID: 21420965 DOI: 10.1053/j.gastro.2011.03.017]
- Koo DH, Ryu MH, Kim KM, Yang HK, Sawaki A, Hirota S, Zheng J, Zhang B, Tzen CY, Yeh CN, Nishida T, Shen L, Chen LT, Kang YK. Asian Consensus Guidelines for the Diagnosis and Management of Gastrointestinal Stromal Tumor. *Cancer Res Treat* 2016; **48**: 1155-1166 [PMID: 27384163 DOI: 10.4143/crt.2016.187]
- Qi ZP, Shi Q, Liu JZ, Yao LQ, Xu MD, Cai SL, Li B, Take I, Zhang YQ, Chen WF, Zhong YS, Zhou PH. Efficacy and safety of endoscopic submucosal dissection for submucosal tumors of the colon and rectum. *Gastrointest Endosc* 2018; **87**: 540-548.e1 [PMID: 28987548 DOI: 10.1016/j.gie.2017.09.027]
- Choi YR, Kim SH, Kim SA, Shin CI, Kim HJ, Han JK, Choi BI. Differentiation of large ( $\geq 5$  cm) gastrointestinal stromal tumors from benign subepithelial tumors in the stomach: radiologists' performance using CT. *Eur J Radiol* 2014; **83**: 250-260 [PMID: 24325848 DOI: 10.1016/j.ejrad.2013.10.028]
- Teoh WC, Teo SY, Ong CL. Gastrointestinal stromal tumors presenting as gynecological masses: usefulness of multidetector computed tomography. *Ultrasound Obstet Gynecol* 2011; **37**: 107-109 [PMID: 20737452 DOI: 10.1002/uog.8801]
- Ibrahim A, Chopra S. Succinate Dehydrogenase-Deficient Gastrointestinal Stromal Tumors. *Arch Pathol Lab Med* 2020; **144**: 655-660 [PMID: 31169996 DOI: 10.5858/arpa.2018-0370-RS]
- Raut CP, Espat NJ, Maki RG, Araujo DM, Trent J, Williams TF, Purkayastha DD, DeMatteo RP. Efficacy and Tolerability of 5-Year Adjuvant Imatinib Treatment for Patients With Resected Intermediate- or High-Risk Primary Gastrointestinal Stromal Tumor: The PERSIST-5 Clinical Trial. *JAMA Oncol* 2018; **4**: e184060 [PMID: 30383140 DOI: 10.1001/jamaoncol.2018.4060]
- Chu H, Pang P, He J, Zhang D, Zhang M, Qiu Y, Li X, Lei P, Fan B, Xu R. Value of radiomics model based on enhanced computed tomography in risk grade prediction of gastrointestinal stromal tumors. *Sci Rep* 2021; **11**: 12009 [PMID: 34103619 DOI: 10.1038/s41598-021-91508-5]
- Wei ZG, Han C, Li JD. Treatment Experts Group for Gastrointestinal Stromal. *Shijie Huaren Xiaohua Zazhi* 2010; **18**: 65-69 [DOI: 10.11569/wjcd.v18.i1.65]
- Wei SC, Xu L, Li WH, Li Y, Guo SF, Sun XR, Li WW. Risk stratification in GIST: shape quantification with CT is a predictive factor. *Eur Radiol* 2020; **30**: 1856-1865 [PMID: 31900704 DOI: 10.1007/s00330-019-06561-6]
- Fletcher CD, Berman JJ, Corless C, Gorstein F, Lasota J, Longley BJ, Miettinen M, O'Leary TJ, Remotti H, Rubin BP, Shmookler B, Sobin

- LH, Weiss SW. Diagnosis of gastrointestinal stromal tumors: A consensus approach. *Hum Pathol* 2002; **33**: 459-465 [PMID: [12094370](#) DOI: [10.1053/hupa.2002.123545](#)]
- 13 Nishida T, Holmebakk T, Raut CP, Rutkowski P. Defining Tumor Rupture in Gastrointestinal Stromal Tumor. *Ann Surg Oncol* 2019; **26**: 1669-1675 [PMID: [30868512](#) DOI: [10.1245/s10434-019-07297-9](#)]
- 14 Faigel DO, Abulhawa S. Gastrointestinal stromal tumors: the role of the gastroenterologist in diagnosis and risk stratification. *J Clin Gastroenterol* 2012; **46**: 629-636 [PMID: [22858511](#) DOI: [10.1097/MCG.0b013e3182548f6c](#)]
- 15 Blay JY, Kang YK, Nishida T, von Mehren M. Gastrointestinal stromal tumours. *Nat Rev Dis Primers* 2021; **7**: 22 [PMID: [33737510](#) DOI: [10.1038/s41572-021-00254-5](#)]
- 16 Fan X, Han H, Sun Z, Zhang L, Chen G, Mzee SAS, Yang H, Chen J. Prognostic Value of Bleeding in Gastrointestinal Stromal Tumors: A Meta-Analysis. *Technol Cancer Res Treat* 2021; **20**: 15330338211034259 [PMID: [34323156](#) DOI: [10.1177/15330338211034259](#)]
- 17 Yanagimoto Y, Takahashi T, Muguruma K, Toyokawa T, Kusanagi H, Omori T, Masuzawa T, Tanaka K, Hirota S, Nishida T. Re-appraisal of risk classifications for primary gastrointestinal stromal tumors (GISTs) after complete resection: indications for adjuvant therapy. *Gastric Cancer* 2015; **18**: 426-433 [PMID: [24853473](#) DOI: [10.1007/s10120-014-0386-7](#)]
- 18 Holmebakk T, Hompland I, Bjerkehaugen B, Stoldt S, Bruland ØS, Hall KS, Boye K. Recurrence-Free Survival After Resection of Gastric Gastrointestinal Stromal Tumors Classified According to a Strict Definition of Tumor Rupture: A Population-Based Study. *Ann Surg Oncol* 2018; **25**: 1133-1139 [PMID: [29435684](#) DOI: [10.1245/s10434-018-6353-5](#)]
- 19 Nishida T, Cho H, Hirota S, Masuzawa T, Chiguchi G, Tsujinaka T; Kinki GIST Study Group. Clinicopathological Features and Prognosis of Primary GISTs with Tumor Rupture in the Real World. *Ann Surg Oncol* 2018; **25**: 1961-1969 [PMID: [29752602](#) DOI: [10.1245/s10434-018-6505-7](#)]
- 20 Hacking S, Jackson K, Johnston R, Grogan E, Walmsley R, Armstrong L, Coleman J, Grieve J, Robinson S, Frew K, Aujayeb A. GIST-related malignant ascites with large-volume paracentesis complicated by myocardial infarction and tumour rupture. *BMJ Support Palliat Care* 2023; **13**: e93-e95 [PMID: [32792419](#) DOI: [10.1136/bmjspcare-2020-002506](#)]
- 21 Misawa S, Takeda M, Sakamoto H, Kirii Y, Ota H, Takagi H. Spontaneous rupture of a giant gastrointestinal stromal tumor of the jejunum: a case report and literature review. *World J Surg Oncol* 2014; **12**: 153 [PMID: [24885725](#) DOI: [10.1186/1477-7819-12-153](#)]
- 22 Santoyo-Villalba J, Triguero-Cabrera J, García-Jiménez A. Acute abdomen secondary to massive bleeding due to rupture of liver metastases of a gastrointestinal stroma tumor. *Cir Cir* 2021; **89**: 93-96 [PMID: [34762635](#) DOI: [10.24875/CIRU.20001313](#)]
- 23 Miettinen M, Lasota J. Gastrointestinal stromal tumors: pathology and prognosis at different sites. *Semin Diagn Pathol* 2006; **23**: 70-83 [PMID: [17193820](#) DOI: [10.1053/j.semdp.2006.09.001](#)]
- 24 Holmebakk T, Bjerkehaugen B, Hompland I, Stoldt S, Boye K. Relationship between R1 resection, tumour rupture and recurrence in resected gastrointestinal stromal tumour. *Br J Surg* 2019; **106**: 419-426 [PMID: [30507040](#) DOI: [10.1002/bjs.11027](#)]
- 25 Sureka B, Bansal K, Arora A. Torricelli-Bernoulli Sign in Gastrointestinal Stromal Tumor. *AJR Am J Roentgenol* 2015; **205**: W468 [PMID: [26397359](#) DOI: [10.2214/AJR.15.14926](#)]
- 26 Fortman BJ. Torricelli-Bernoulli sign in an ulcerating gastric leiomyosarcoma. *AJR Am J Roentgenol* 1999; **173**: 199-200 [PMID: [10397126](#) DOI: [10.2214/ajr.173.1.10397126](#)]
- 27 Liu T, Lin G, Peng H, Huang L, Jiang X, Li H, Cai K, Jiang J, Guo L, Du X, Tang J, Zhang W, Chen J, Ye Y. Clinicopathological characteristics and prognosis of gastrointestinal stromal tumors containing air-fluid levels. *PLoS One* 2021; **16**: e0261566 [PMID: [34919581](#) DOI: [10.1371/journal.pone.0261566](#)]



Published by **Baishideng Publishing Group Inc**  
7041 Koll Center Parkway, Suite 160, Pleasanton, CA 94566, USA

**Telephone:** +1-925-3991568

**E-mail:** [bpgoffice@wjgnet.com](mailto:bpgoffice@wjgnet.com)

**Help Desk:** <https://www.f6publishing.com/helpdesk>

<https://www.wjgnet.com>

