

World Journal of *Clinical Oncology*

World J Clin Oncol 2023 November 24; 14(11): 445-548



ORIGINAL ARTICLE**Retrospective Study**

- 445 Analysis of clinicopathological features and prognostic factors of breast cancer brain metastasis
Chen YR, Xu ZX, Jiang LX, Dong ZW, Yu PF, Zhang Z, Gu GL

- 459 Clinical study of standard residual liver volume and transient elastography in predicting poor prognosis of patients after hemihepatectomy
Yue ZQ, Zhang P, Yan S, Ju LL, Wang HX, Yuan LX, Chen L, Wu JZ, Cao YL

Observational Study

- 471 System describing surgical field extension associated with flap reconstruction after resection of a superficial malignant soft tissue tumor
Sakamoto A, Noguchi T, Matsuda S

Basic Study

- 479 Computational exploration of the significance of COPS6 in cancer: Functional and clinical relevance across tumor types
Wang SL, Zhuo GZ, Wang LP, Jiang XH, Liu GH, Pan YB, Li YR

META-ANALYSIS

- 504 Circulating tumor cells as potential prognostic biomarkers for early-stage pancreatic cancer: A systematic review and meta-analysis
Zhang ZH, Bao YW, Zhao YJ, Wang JQ, Guo JT, Sun SY

SCIENTOMETRICS

- 518 Bibliometric analysis of the global research status and trends of mechanotransduction in cancer
Zhang YZ, Li MZ, Wang GX, Wang DW

CASE REPORT

- 535 Autoimmune diabetes from pembrolizumab: A case report and review of literature
Bhandari H, Khalid F, Bodla ZH, Muhammad T, Du D, Meghal T
- 544 Calcitriol induced hypercalcemia - a rare phenomenon in lung cancer: A case report
Prakash A, Khalid F, Alalwan A, Bader H, Du D, Meghal T

ABOUT COVER

Peer Reviewer of *World Journal of Clinical Oncology*, Bene Ekine-Afolabi, PhD, Research Associate, Department of Biomedical Sciences, School of Health, Sport and Biosciences, University of East London, Stratford-London E15 4LZ, Universal Scientific Education & Research Network (USERN), London, United Kingdom.
dcr@zeabtherapeutic.com

AIMS AND SCOPE

The primary aim of *World Journal of Clinical Oncology* (WJCO, *World J Clin Oncol*) is to provide scholars and readers from various fields of oncology with a platform to publish high-quality basic and clinical research articles and communicate their research findings online.

WJCO mainly publishes articles reporting research results and findings obtained in the field of oncology and covering a wide range of topics including art of oncology, biology of neoplasia, breast cancer, cancer prevention and control, cancer-related complications, diagnosis in oncology, gastrointestinal cancer, genetic testing for cancer, gynecologic cancer, head and neck cancer, hematologic malignancy, lung cancer, melanoma, molecular oncology, neurooncology, palliative and supportive care, pediatric oncology, surgical oncology, translational oncology, and urologic oncology.

INDEXING/ABSTRACTING

The WJCO is now abstracted and indexed in PubMed, PubMed Central, Emerging Sources Citation Index (Web of Science), Reference Citation Analysis, China National Knowledge Infrastructure, China Science and Technology Journal Database, and Superstar Journals Database. The 2023 Edition of Journal Citation Reports® cites the 2022 impact factor (IF) for WJCO as 2.8; IF without journal self cites: 2.8; 5-year IF: 3.0; Journal Citation Indicator: 0.36.

RESPONSIBLE EDITORS FOR THIS ISSUE

Production Editor: Xiang-Di Zhang; Production Department Director: Xu Guo; Editorial Office Director: Xu Guo.

NAME OF JOURNAL

World Journal of Clinical Oncology

ISSN

ISSN 2218-4333 (online)

LAUNCH DATE

November 10, 2010

FREQUENCY

Monthly

EDITORS-IN-CHIEF

Hiten RH Patel, Stephen Safe, Jian-Hua Mao, Ken H Young

EDITORIAL BOARD MEMBERS

<https://www.wjgnet.com/2218-4333/editorialboard.htm>

PUBLICATION DATE

November 24, 2023

COPYRIGHT

© 2023 Baishideng Publishing Group Inc

INSTRUCTIONS TO AUTHORS

<https://www.wjgnet.com/bpg/gerinfo/204>

GUIDELINES FOR ETHICS DOCUMENTS

<https://www.wjgnet.com/bpg/GerInfo/287>

GUIDELINES FOR NON-NATIVE SPEAKERS OF ENGLISH

<https://www.wjgnet.com/bpg/gerinfo/240>

PUBLICATION ETHICS

<https://www.wjgnet.com/bpg/GerInfo/288>

PUBLICATION MISCONDUCT

<https://www.wjgnet.com/bpg/gerinfo/208>

ARTICLE PROCESSING CHARGE

<https://www.wjgnet.com/bpg/gerinfo/242>

STEPS FOR SUBMITTING MANUSCRIPTS

<https://www.wjgnet.com/bpg/GerInfo/239>

ONLINE SUBMISSION

<https://www.f6publishing.com>



Observational Study

System describing surgical field extension associated with flap reconstruction after resection of a superficial malignant soft tissue tumor

Akio Sakamoto, Takashi Noguchi, Shuichi Matsuda

Specialty type: Orthopedics

Provenance and peer review:

Unsolicited article; Externally peer reviewed.

Peer-review model: Single blind

Peer-review report's scientific quality classification

Grade A (Excellent): 0
Grade B (Very good): 0
Grade C (Good): C
Grade D (Fair): 0
Grade E (Poor): 0

P-Reviewer: Gupta R, India

Received: August 29, 2023

Peer-review started: August 29, 2023

First decision: September 14, 2023

Revised: September 24, 2023

Accepted: October 13, 2023

Article in press: October 13, 2023

Published online: November 24, 2023



Akio Sakamoto, Takashi Noguchi, Shuichi Matsuda, Department of Orthopaedic Surgery, Graduate School of Medicine, Kyoto University, Kyoto 606-8507, Japan

Corresponding author: Akio Sakamoto, MD, PhD, Adjunct Professor, Department of Orthopaedic Surgery, Graduate School of Medicine, Kyoto University, Shogoin, Kawahara-cho 54, Sakyo-ku, Kyoto 606-8507, Japan. akiosaka@kuhp.kyoto-u.ac.jp

Abstract

BACKGROUND

Flap reconstruction after resection of a superficial malignant soft tissue tumor extends the surgical field and is an indicator for potential recurrence sites.

AIM

To describe a grading system for surgical field extension of soft tissue sarcomas.

METHODS

Grading system: CD-grading is a description system consisting of C and D values in the surgical field extension, which are related to the compartmental position of the flap beyond the nearby large joint and deeper extension for the pedicle, respectively. C1/D1 are positive values and C0/D0 are negative. With a known location, 1/0 values can be "p" (proximal), "d" (distal), and "b" (in the tumor bed), and the description method is as follows: flap type, CxDx [x = 0, 1, p, d or b].

RESULTS

Four representative patients with subcutaneous sarcomas who underwent reconstruction using fasciocutaneous flaps are presented. The cases involved a distal upper arm (elbow) synovial sarcoma reconstructed using a pedicled latissimus dorsi (pedicled flap: CpDp); a distal upper arm (elbow) pleomorphic rhabdomyosarcoma reconstructed using a transpositional flap from the forearm (transpositional flap: CdD0); an undifferentiated pleomorphic sarcoma in the buttocks reconstructed using a transpositional flap (transpositional flap: C0D0); and a myxofibrosarcoma in the buttocks reconstructed using a propeller flap from the thigh (pedicled flap: CdDd).

CONCLUSION

The reconstruction method is chosen by the surgeon based on size, location, and

other tumor characteristics; however, the final surgical field cannot be determined based on preoperative images alone. CD-grading is a description system consisting of C and D values in the surgical field extension that are related to the compartmental position of the flap beyond the nearby large joint and deeper extension for the pedicle, respectively. The CD-grading system gives a new perspective to the flap reconstruction classification. The CD-grading system also provides important information for follow-up imaging of a possible recurrence.

Key Words: Soft tissue; Sarcoma; Surgery; Sarcoma; Grading system; Surgical flap

©The Author(s) 2023. Published by Baishideng Publishing Group Inc. All rights reserved.

Core Tip: Flap reconstruction after resection of a superficial malignant soft tissue tumor extends the surgical field and is an indicator for potential recurrence sites. CD-grading is a description system consisting of C and D values in the surgical field extension that are related to the compartmental position of the flap beyond the nearby large joint and deeper extension for the pedicle, respectively. C1/D1 and C0/D0 are positive and negative values, respectively. The CD-grading system gives a new perspective to flap reconstruction classification. The CD-grading system also provides important information for follow-up imaging of a possible recurrence.

Citation: Sakamoto A, Noguchi T, Matsuda S. System describing surgical field extension associated with flap reconstruction after resection of a superficial malignant soft tissue tumor. *World J Clin Oncol* 2023; 14(11): 471-478

URL: <https://www.wjgnet.com/2218-4333/full/v14/i11/471.htm>

DOI: <https://dx.doi.org/10.5306/wjco.v14.i11.471>

INTRODUCTION

Soft tissue sarcomas comprise a group of rare heterogeneous neoplasms that account for < 1% of all cancers[1]. Soft tissue sarcomas can occur in any soft tissue, but are most common in the extremities. Wide resection of the sarcoma and the surrounding normal tissue is necessary to reduce the recurrence rate[2]. Flap reconstruction is used to repair soft tissue defects after resection of a soft tissue sarcoma, especially a superficial soft tissue sarcoma[3,4].

The term "tumor bed" refers to the area of tissue remaining after a malignant tumor is removed. The tumor bed includes the tumor and surrounding healthy tissues where cancer cells may exist[5]. Use of a reconstruction flap following soft tissue sarcoma resection can extend the surgical field or tumor bed because of flap elevation or dissection of recipient vessels.

The current Cancer Staging Manual of the American Joint Committee on Cancer (AJCC) of soft tissue sarcoma is widely used based upon tumor size, histologic grade, and the presence of metastasis[6]. AJCC supports the *R classification*, which categorizes surgical margins as negative (R0), microscopically positive (R1), or grossly positive (R2)[7,8]. Flaps can be classified based on several factors (pedicled, free, or the tissue type from which the flap is made). Classification of flaps according to clinical complications has also been reported[9]; however, there is no system describing surgical field extension related to flap reconstruction.

In the current report we propose a grading classification, the CD-grading system, to describe extension of the surgical field related to flap reconstruction after superficial soft tissue sarcoma resection. Representative cases are also presented.

MATERIALS AND METHODS

Classification: CD-grading system for a superficial sarcoma in the extremities

The new grading system (CD-grading system) was used herein for superficial soft tissue sarcomas with extremity resection reconstructed by fascio-(musculo)-cutaneous flaps. Upper extremity tumors are defined as lesions arising distal to the acromioclavicular joint and include tumors of the shoulder girdle and axilla. Lower extremity tumors are defined as lesions arising distal to the iliac crest, including tumors of the gluteal region[9]. Additional skin grafting does not affect the grade; the skin grafting cases were not excluded.

The CD-grading system consists of C- and D-values. The C-value indicates the "compartmental position of the flap beyond the nearby large joint " and when the flap crosses a nearby large joint, the C-value is positive (C1). When the flap is within the compartment, the C-value is negative (C0). Large joints include the shoulders, elbows, wrists, hips, knees, and ankles. If the location of a flap crossing the joint location is proximal, the C-value is Cp (p = proximal) and when crossing a distal large joint the C-value is Cd (d = distal).

D-value means "deeper extension for the pedicle." The pedicle is already exposed, and the negative D-value is D0. If dissection of the pedicle is necessary, the positive D-value is D1. When the dissected pedicle is located proximal to the surgical field, the D-value is Dp (p = proximal), when the dissected pedicle is located distally, the D-value is Dd (d = distal), and when the pedicle dissection is within the surgical bed, the D-value is Db (b = surgical bed; Tables 1 and 2).

Table 1 C-value for flap location beyond the nearby large joint

	C-value	Description
Within the compartment	0	C0
Extra compartment	1: any	C1
	p: proximal	Cp
	d: distal	Cd

Table 2 D-value for surgical field extension for the pedicle dissection

Pedicle	D-value	Description
Already exposed	0	D0
Dissection of the pedicle	1: Any	D1
	p: Proximal	Dp
	d: Distal	Dd
	b: Within tumor bed	Db

The flap type is described before the CD-values as “flap type, CxDx,” in which x can be 0, 1, p, d, or b. There is no strict rule in the description of the flap type; however, an easy and understandable description, such as distinguishing between a local or free flap, would be required.

Transpositional fascial flap/propeller flap

In cases involving transpositional fasciocutaneous or propeller flaps[10], the flap is located within the compartment, the C-value is C0, the D-value is D0, and the CD-grade is C0D0. When the flap is from the extra compartment across the large joint, the C-value is C1, the D-value is D0, and the CD-grade is C1D0. When the flap is obtained proximally and crosses a large joint, the CD-grade is CpD0, and when the flap is derived distally and crosses a large joint, the CD-grade is CdD0 (Tables 3 and 4).

Pedicled flap

The C-value in the pedicle flap is the same as the transpositional flap. The flap is located within the compartment and the C-value is C0. When the flap comes from the extra compartment across the joint, the C-value is C1. C1 can be Cp or Cd depending on the flap location (proximal or distal). The D-value reflects the location of the pedicle. The pedicle flap needs extension of the surgical field to deeper tissues, therefore the D-value is always D1. When the pedicle is located proximal to the surgical field, D1 can be Dp (p = proximal), and when the pedicle is located distal to the surgical field, the D1 can be Dd (d = distal; Tables 3 and 5).

Free flap

The donated area of the flap does not affect the surgical field in terms of tumor contamination, and the C-value in the free flap is always C0. When the pedicle is already exposed at the surgical field, the D-value is D0. When the pedicle is not exposed, and the pedicle needs to be exposed, then the D-value is D1. When the pedicle is located proximal to the surgical field, D1 can be Dp (p = proximal), and when the pedicle is located distal to the surgical field, the D1 can be Dd (d = distal). When the pedicle is exposed at the deeper tissues within the surgical field, the D-value is Db (Tables 3 and 6).

RESULTS

Herein we present four cases of superficial soft tissue sarcomas. Two elbow soft tissue sarcomas and two buttock soft-tissue sarcomas are presented. One elbow soft tissue sarcoma patient was a 47-year-old female with a synovial sarcoma at the elbow (distal upper arm) reconstructed with a pedicled latissimus dorsi; the CD-grade was CpDp (pedicled flap, CpDp; Figure 1). The second elbow soft tissue sarcoma patient was an 85-year-old male with a pleomorphic rhabdomyosarcoma at the elbow (distal upper arm) reconstructed using a transpositional flap from the forearm; the CD-grade was CdD0 (transpositional flap, CdD0; Figure 2). The first patient with a buttock soft tissue sarcoma was a 65-year-old female with an undifferentiated pleomorphic sarcoma at the buttock reconstructed using a transpositional flap; the CD-grade was C0D0 (transpositional flap, C0D0[11]; Figure 3). The second patient with a buttock sarcoma was a 46-year-old male with a myxofibrosarcoma that was reconstructed using a propeller flap from the thigh; the CD-grade was CdDd (pedicled flap, CdDd; Figure 4).

Table 3 Possible classification of flap reconstruction

CD-grade	Transpositional flap	Pedicled flap	Free flap
C0D0	C0D0	Not applied	C0D0
C0D1	NA	C0Dp, C0Dd	C0Dp, C0Dd, C0Db
C1D0	CpD0, CdD0	NA	NA
C1D1	NA	CpDp, CdDd	NA

NA: Not available.

Table 4 Transpositional fasciocutaneous flap/propeller flap

Flap location	C-value	D-value	CD-grade
Within the compartment	0	0	C0D0
Extra compartment: from any	1	0	C1D0
From proximal	p	0	CpD0
From distal	d	0	CdD0

Table 5 Pedicled flap

Flap location	C-value	D-value (pedicle location)	CD-grade
Within the compartment	0	1 (any)	C0D1
From proximal	0	p (proximal)	C0Dp
From distal	0	d (distal)	C0Dd
Extra compartment	1	1 (any)	C1D1
From proximal	p	p (proximal)	CpDp
From distal	d	d (distal)	CdDd

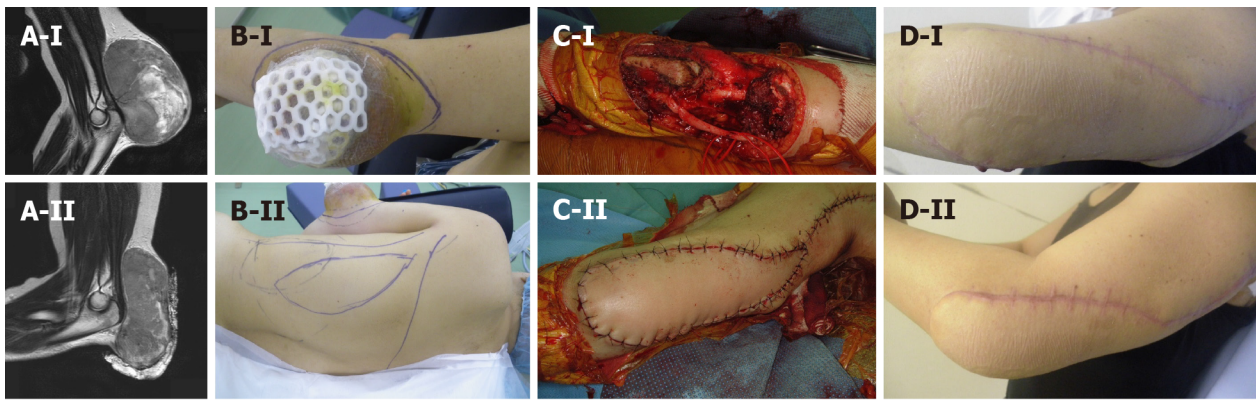
Table 6 Free flap

Pedicle location	C-value	D-value (pedicle location)	CD-grade
Already exposed	0	0	C0D0
Necessary for dissection	0	1 (any)	C0D1
From proximal	0	p (proximal)	C0Dp
From distal	0	d (distal)	C0Dd
Within tumor bed	0	b (within tumor bed)	C0Db

DISCUSSION

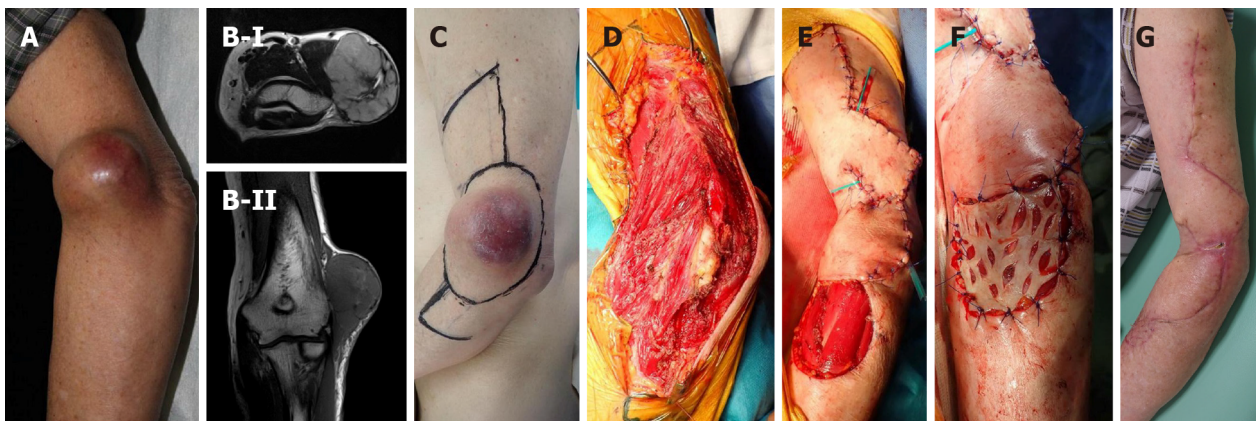
Soft tissue sarcomas require wide resection with healthy tissue margins[12,13]. Thus, the surgical field is wider than the tumor size. The extension of the tumor bed has the possibility of tumor contamination. Therefore, recognition of tumor bed extension is necessary. Discrepancies between the preoperative tumor burden and postoperative tumor bed contour have been identified after tumor burden replacement with a latissimus dorsi flap[14]. Flap reconstruction increases the surgical field during superficial soft tissue sarcoma resection[15].

A flap is applied to the defect after resection of a soft tissue sarcoma, especially a superficial soft tissue sarcoma. The choice of flap is often determined by the surgeon's preference, as well as the location of the tumor. The tumor bed after resection of soft tissue sarcomas cannot be predicted solely based on preoperative imaging. If amputation is necessary in the case of a re-occurrence, the level of amputation is important. Extension of the tumor bed due to flap reconstruction carries the risk of tumor contamination and may require more proximal amputation. The C-value gives information that indicates the likelihood of tumor contamination across the greater joint.



DOI: 10.5306/wjco.v14.i11.471 Copyright ©The Author(s) 2023.

Figure 1 Synovial sarcoma at the distal upper arm (elbow) reconstructed by a pedicled latissimus dorsi (pedicled flap, CpDp). A: A 47-year-old female with a synovial sarcoma at the elbow (distal upper arm). Magnetic resonance imaging showed a tumor with heterogenous low-to-high signal intensity on the T2-weighted image. Before (A-I) and after (A-II) chemotherapy of doxorubicin and ifosfamide, the tumor size was reduced. B-D: A wide surgical resection was performed with a pedicled latissimus dorsi. The CD-grade was CpDp (pedicled flap, CpDp).

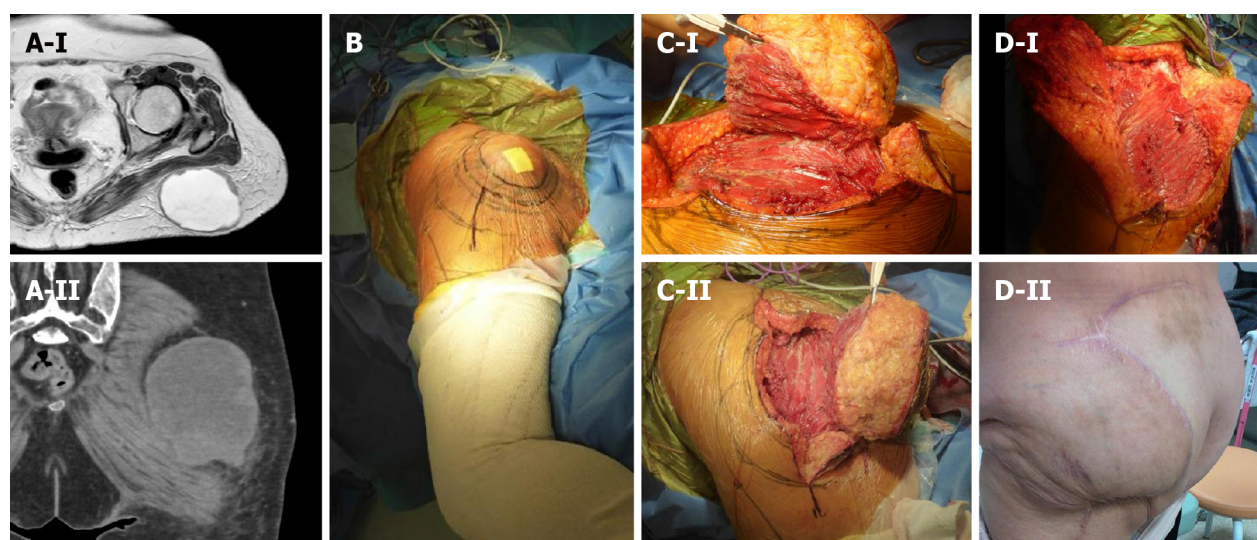


DOI: 10.5306/wjco.v14.i11.471 Copyright ©The Author(s) 2023.

Figure 2 Pleomorphic rhabdomyosarcoma at the distal upper arm (elbow) reconstructed by transpositional flap (transpositional flap, CdD0). A: An 85-year-old male with a pleomorphic rhabdomyosarcoma at the elbow (distal upper arm); B: Magnetic resonance imaging showed a tumor with homogenous high-signal intensity on T2-weighted images (B-I) and low-signal intensity on T1-weighted images (B-II). A wide surgical resection was performed. The transpositional flap was obtained from the upper arm and forearm; C-G: Skin grafting was performed at the forearm. The CD-grade was CdD0 (transpositional flap, CdD0).

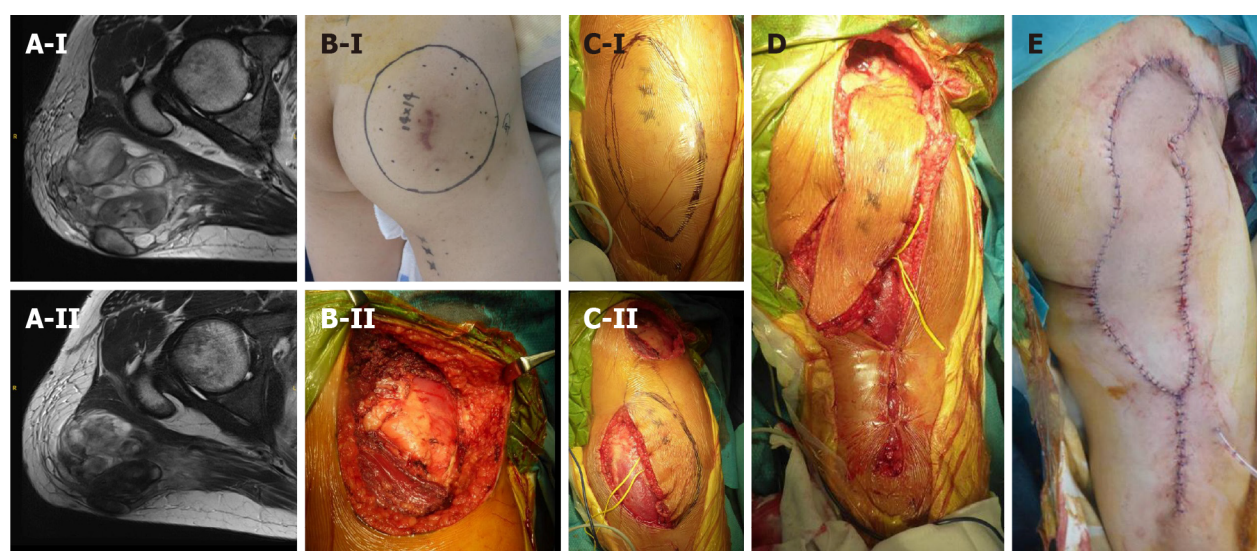
There is a risk of tumor contamination if deep tissues are created in the surgical field. The D-value represents the location of the pedicle. Dissection of the pedicle and recipient vessels requires dissection to the deeper layers, resulting in extension of the surgical field, with a D-value of D1. Transposition flaps in the compartment do not require exposure of the donor vessels, therefore less deep tissue exposure is advantageous in terms of reducing the potential for tumor recurrence, with a D-value of D0. Similarly, even in cases of a free flap requiring microsurgery, if the recipient vessels are already exposed, the D-value is D0 because deeper tissue dissection is not necessary.

The AJCC Staging of Soft Tissue Sarcomas (eighth edition) is based upon the tumor size, histologic grade, and the presence of metastasis. Tumor size is classified into four categories with border values of 5, 10, and 15 cm. The notation regarding tumor depth (superficial or deep from the superficial fascia) has been eliminated from the seventh edition of the AJCC Staging of Soft Tissue Sarcomas[6]. The surgical staging of musculoskeletal sarcomas has 4 types of surgical margins [intralesional, marginal, wide, and radical (compartmental)], as proposed by Enneking *et al*[16]. A 2-3 cm surgical margin provides reasonable local control of soft tissue sarcomas[17]. The AJCC supports the *R* classification, which categorizes margins as negative (R0), microscopically positive (R1), or grossly positive (R2)[7,8]. Furthermore, the Union Against Cancer (UICC) proposed a *R + 1 mm* classification that requires 1 mm of healthy tissue between the tumor and margin to define a negative margin (R0)[18,19], thus resulting in more resections being considered microscopically positive (R1). Radiation therapy can be performed as adjuvant therapy, especially if cancer cells remain after the resection. Radiation has a role in reducing the risk of recurrence in soft tissue sarcoma resection[5]. The term, tumor bed, refers to the area of tissue remaining after a malignant tumor is removed. The tumor bed may have cancer cells[5]. Recognition of tumor bed extension is necessary for postoperative radiation. Without flap reconstruction following soft tissue sarcoma resection, the tumor bed can largely be predicted with the preoperative staging based upon the images



DOI: 10.5306/wjco.v14.i11.471 Copyright ©The Author(s) 2023.

Figure 3 Undifferentiated pleomorphic sarcoma at the buttock reconstructed by a transpositional flap (transpositional flap, C0D0). A: A 65-year-old female with an undifferentiated pleomorphic sarcoma at the buttock. Magnetic resonance imaging revealed a subcutaneous tumor. The tumor had a cystic appearance and contained liquid with slightly high signal intensity on the T2-weighted image. The periphery of the cystic wall was thick with a solid neoplastic lesion and intermediate signal intensity on T2-weighted images (A-I). Computed tomography showed that the lesion is located at the buttock (A-II); B: A resection of the tumor was designed; C and D: The tumor was resected and the defect was reconstructed with a transpositional flap donated from the lateral abdomen. The CD-grade was C0D0 (transpositional flap, C0D0).



DOI: 10.5306/wjco.v14.i11.471 Copyright ©The Author(s) 2023.

Figure 4 Myxofibrosarcoma at the buttock reconstructed by a propeller flap (pedicled flap, CdDd). A: A 46-year-old male with a myxofibrosarcoma at the buttock. Magnetic resonance imaging revealed that the tumor showed heterogeneous low-to-high signal intensity on the T2-weighted image. Before (A-I) and after (A-II) chemotherapy of doxorubicin and ifosfamide, the tumor size was reduced; B: The resection of the tumor was designed (B-I) and performed (B-II); C and E: A propeller flap from the thigh was designed (C-I) and the pedicle was preserved (C-II) and performed. The CD-grade was CdDd (pedicled flap, CdDd).

and the histologic findings. With flap reconstruction, tumor bed prediction is difficult without the surgical method information. Indeed, the new grading system can give information of surgical field extension associated with flap reconstruction.

There are several limitations in the new grading system. First, this classification is completely new and still theoretical. Clinical use of the assembled clinical data would be necessary, and some modification may be required for improvement. Second, the new grading system was used for superficial soft tissue sarcomas resected in the extremities and fascio-(musculo)-cutaneous flaps, in which hands and feet were not included. The new grading system might be modified for any part of bones and soft tissue sarcomas. Third, flap type description is not strictly defined in the new grading system, which may result in ambiguity; however, according to the flap technique improvement, description of the flap would be diverse. Therefore, no flap description restrictions were used in the new grading system. Finally, the new grading system cannot describe the length or area required for postoperative radiation. Excessive information in the grading system,

however, would make the new grading system difficult for clinical use.

CONCLUSION

We have proposed a method to describe extension of the surgical field in reconstruction after superficial soft tissue sarcoma resection. The method described can give values for tumor bed extension after flap reconstruction. The description of whether or not the operative field has been extended due to reconstruction is considered to be important information for image evaluation of recurrence.

ARTICLE HIGHLIGHTS

Research background

Flap reconstruction can extend the surgical field or tumor bed because of flap elevation or dissection of recipient vessels during resection of superficial soft tissue sarcomas. There is currently no method describing extension of the surgical field.

Research motivation

Extension of the surgical field cannot be predicted based on preoperative images for flap reconstruction after superficial soft tissue sarcoma resection. Knowledge of the surgical field extension is important information for evaluation of recurrence images or possible postoperative radiation.

Research objectives

A theoretical CD-grading system was developed consisting of C and D values in the surgical field extension. The C-value represents the flap beyond the nearby large joint and the D-value pertains to a deeper extension.

Research methods

C1/D1 and C0/D0 are positive and negative values, respectively. With a known location, C values are "p" (proximal), "d" (distal), and "b" (in the tumor bed). The description method is as follows: flap type, CxDx [x = 0, 1, p, d or b].

Research results

Classification and possible values are shown in the tables (transpositional fascial flap/propeller, pedicled, and free flaps). Four representative patients with subcutaneous sarcomas who underwent reconstruction using fasciocutaneous flaps are presented.

Research conclusions

The new grading system can give values for tumor bed extension after flap reconstruction following superficial soft tissue sarcoma resection. The description of whether or not the operative field has been extended due to reconstruction is thought to be important information for evaluation of recurrence images.

Research perspectives

Clinical use of assembled clinical data would be necessary and some modification may be required for improvement, especially if the new grading system is modified for any part of bone and soft tissue sarcomas.

FOOTNOTES

Author contributions: Sakamoto A developed the classification and drafted the manuscript; Noguchi T and Matsuda S participated in the study design; All authors read and approved the final manuscript.

Institutional review board statement: Analysis of clinical data accumulation in patients with bone and soft tissue tumors. Retrospective study.

Informed consent statement: The patients represented in this study were informed that the data from the case would be de-identified and used in a journal publication. There is a specific signed document because the analysis used anonymous clinical data that were obtained after each patient had been notified at the Kyoto University home page that the data could be used for a clinical study.

Conflict-of-interest statement: We, the authors, declare no conflicts of interest regarding our manuscript entitled "A system describing surgical field extension associated with flap reconstruction after resection of a malignant soft tissue tumor."

Data sharing statement: No additional data are available.

STROBE statement: The authors have read the STROBE Statement—checklist of items, and the manuscript was prepared and revised according to the STROBE Statement—checklist of items.

Open-Access: This article is an open-access article that was selected by an in-house editor and fully peer-reviewed by external reviewers. It is distributed in accordance with the Creative Commons Attribution NonCommercial (CC BY-NC 4.0) license, which permits others to distribute, remix, adapt, build upon this work non-commercially, and license their derivative works on different terms, provided the original work is properly cited and the use is non-commercial. See: <https://creativecommons.org/licenses/by-nc/4.0/>

Country/Territory of origin: Japan

ORCID number: Akio Sakamoto 0000-0002-7518-1606; Takashi Noguchi 0000-0003-2965-4772; Shuichi Matsuda 0000-0003-0802-1255.

S-Editor: Liu JH

L-Editor: A

P-Editor: Liu JH

REFERENCES

- 1 Nijhuis PH, Schaapveld M, Otter R, Molenaar WM, van der Graaf WT, Hoekstra HJ. Epidemiological aspects of soft tissue sarcomas (STS)—consequences for the design of clinical STS trials. *Eur J Cancer* 1999; **35**: 1705-1710 [PMID: 10674017 DOI: 10.1016/s0959-8049(99)00152-5]
- 2 Samà L, Binder JP, Darrigues L, Couturaud B, Boura B, Helfre S, Chiche L, Nicolas N, Tzanis D, Bouhadiba T, Gentile D, Perlberg-Samson J, Bonvalot S. Safe-margin surgery by plastic reconstruction in extremities or parietal trunk soft tissue sarcoma: A tertiary single centre experience. *Eur J Surg Oncol* 2022; **48**: 526-532 [PMID: 34702592 DOI: 10.1016/j.ejso.2021.10.010]
- 3 Slump J, Hofer SOP, Ferguson PC, Wunder JS, Griffin AM, Hoekstra HJ, Bastiaannet E, O'Neill AC. Flap choice does not affect complication rates or functional outcomes following extremity soft tissue sarcoma reconstruction. *J Plast Reconstr Aesthet Surg* 2018; **71**: 989-996 [PMID: 29706552 DOI: 10.1016/j.bjps.2018.04.002]
- 4 Koulaxouzidis G, Schlagnitweit P, Anderl C, Braig D, Märdian S. Microsurgical Reconstruction in Orthopedic Tumor Resections as Part of a Multidisciplinary Surgical Approach for Sarcomas of the Extremities. *Life (Basel)* 2022; **12** [PMID: 36362956 DOI: 10.3390/life12111801]
- 5 Brinkmann EJ, Ahmed SK, Houdek MT. Extremity Soft Tissue Sarcoma: Role of Local Control. *Curr Treat Options Oncol* 2020; **21**: 13 [PMID: 32025823 DOI: 10.1007/s11864-020-0703-9]
- 6 Tanaka K, Ozaki T. New TNM classification (AJCC eighth edition) of bone and soft tissue sarcomas: JCOG Bone and Soft Tissue Tumor Study Group. *Jpn J Clin Oncol* 2019; **49**: 103-107 [PMID: 30423153 DOI: 10.1093/jjco/hyy157]
- 7 Hermanek P, Wittekind C. The pathologist and the residual tumor (R) classification. *Pathol Res Pract* 1994; **190**: 115-123 [PMID: 8058567 DOI: 10.1016/S0344-0338(11)80700-4]
- 8 Hoang K, Gao Y, Miller BJ. The Variability in Surgical Margin Reporting in Limb Salvage Surgery for Sarcoma. *Iowa Orthop J* 2015; **35**: 181-186 [PMID: 26361463]
- 9 O'Neill AC, Roy M, Boucher A, Fitzpatrick AM, Griffin AM, Tsoi K, Ferguson PC, Wunder JS, Hofer SOP. The Toronto Sarcoma Flap Score: A Validated Wound Complication Classification System for Extremity Soft Tissue Sarcoma Flap Reconstruction. *Ann Surg Oncol* 2021; **28**: 3345-3353 [PMID: 33005992 DOI: 10.1245/s10434-020-09166-2]
- 10 Pignatti M, Ogawa R, Mateev M, Georgescu AV, Balakrishnan G, Ono S, Cubison T, Pinto V, D'Arpa S, Koshima I, Hyakusoku H, Hallock GG. Our Definition of Propeller Flaps and Their Classification. *Semin Plast Surg* 2020; **34**: 139-144 [PMID: 33041682 DOI: 10.1055/s-0040-1715158]
- 11 Sakamoto A, Noguchi T, Matsuda S. A Transposition Flap Reconstruction after Resection of a Soft-Tissue Sarcoma in the Buttock. *J Orthop Case Rep* 2021; **11**: 38-40 [PMID: 35415100 DOI: 10.13107/jocr.2021.v11.i10.2458]
- 12 Garreffa E, Hughes-Davies L, Russell S, Lightowers S, Agrawal A. Definition of Tumor Bed Boost in Oncoplastic Breast Surgery: An Understanding and Approach. *Clin Breast Cancer* 2020; **20**: e510-e515 [PMID: 32284305 DOI: 10.1016/j.clbc.2020.03.003]
- 13 Tse T, Knowles S, Bélec J, Caudrelier JM, Lock M, Brackstone M, Arnaout A. Consensus statement on tumour bed localization for radiation after oncoplastic breast surgery. *Curr Oncol* 2020; **27**: e326-e331 [PMID: 32669940 DOI: 10.3747/co.27.5977]
- 14 Alço G, Igdem S, Okkan S, Dincer M, Sarsenov D, Ilgun AS, Agacayak F, Elbüken F, Ercan T, Selamoglu D, Ozmen V. Replacement of the tumor bed following oncoplastic breast-conserving surgery with immediate latissimus dorsi mini-flap. *Mol Clin Oncol* 2016; **5**: 365-371 [PMID: 27699027 DOI: 10.3892/mco.2016.984]
- 15 Pu LL. Reconstruction of a large gluteal soft-tissue defect with the double-opposing V-Y fasciocutaneous advancement flap. *Plast Reconstr Surg* 2007; **119**: 599-603 [PMID: 17230096 DOI: 10.1097/01.prs.0000246508.21562.fl]
- 16 Enneking WF, Spanier SS, Goodman MA. A system for the surgical staging of musculoskeletal sarcoma. *Clin Orthop Relat Res* 1980; **106**: 120 [PMID: 7449206]
- 17 Sampo M, Tarkkanen M, Huuhtanen R, Tukiainen E, Böhring T, Blomqvist C. Impact of the smallest surgical margin on local control in soft tissue sarcoma. *Br J Surg* 2008; **95**: 237-243 [PMID: 17703500 DOI: 10.1002/bjs.5906]
- 18 Gronchi A, Miceli R, Fiore M, Collini P, Lozza L, Grosso F, Mariani L, Casali PG. Extremity soft tissue sarcoma: adding to the prognostic meaning of local failure. *Ann Surg Oncol* 2007; **14**: 1583-1590 [PMID: 17260106 DOI: 10.1245/s10434-006-9325-0]
- 19 Wittekind C, Compton CC, Greene FL, Sobin LH. TNM residual tumor classification revisited. *Cancer* 2002; **94**: 2511-2516 [PMID: 12015777 DOI: 10.1002/cncr.10492]



Published by **Baishideng Publishing Group Inc**
7041 Koll Center Parkway, Suite 160, Pleasanton, CA 94566, USA

Telephone: +1-925-3991568

E-mail: bpgoffice@wjgnet.com

Help Desk: <https://www.f6publishing.com/helpdesk>

<https://www.wjgnet.com>

