

# World Journal of *Clinical Cases*

*World J Clin Cases* 2023 November 6; 11(31): 7508-7740



## Contents

Thrice Monthly Volume 11 Number 31 November 6, 2023

## REVIEW

- 7508 Gut microbiome: New perspectives for type 2 diabetes prevention and treatment  
*Li SX, Guo Y*

## MINIREVIEWS

- 7521 Endoscopic management of benign biliary strictures: Looking for the best stent to place  
*Colombo M, Forcignanò E, Da Rio L, Spadaccini M, Andreozzi M, Giacchetto CM, Carrara S, Maselli R, Galtieri PA, Pellegatta G, Capogreco A, Massimi D, Khalaf K, Hassan C, Anderloni A, Repici A, Fugazza A*
- 7530 Antibiotic resistance in patients with liver cirrhosis: Prevalence and current approach to tackle  
*Liakina V*

## ORIGINAL ARTICLE

## Retrospective Study

- 7543 Analysis of risk factors for postoperative deep vein thrombosis after craniotomy and nomogram model construction  
*Su ZJ, Wang HR, Liu LQ, Li N, Hong XY*
- 7553 Value of ultrasound and magnetic resonance imaging combined with tumor markers in the diagnosis of ovarian tumors  
*Yang Q, Zhang H, Ma PQ, Peng B, Yin GT, Zhang NN, Wang HB*
- 7562 Measurement of combined flap thickness for reconstruction of decubitus ulcer using computed tomography  
*Kim EC, Park JD, Wee SY, Kim SY*
- 7570 Does the advantage of transcutaneous oximetry measurements in diabetic foot ulcer apply equally to free flap reconstruction?  
*Lee DW, Hwang YS, Byeon JY, Kim JH, Choi HJ*

## Clinical Trials Study

- 7583 Effects of ulinastatin therapy in deep vein thrombosis prevention after brain tumor surgery: A single-center randomized controlled trial  
*Tao YN, Han Q, Jiao W, Yang LK, Wang F, Xue S, Shen M, Wang YH*

## Observational Study

- 7593 Network pharmacological and molecular docking study of the effect of Liu-Wei-Bu-Qi capsule on lung cancer  
*Yang Q, Li LY*

- 7610** Efficacy of  $\beta_2$ -adrenergic receptor agonist combined with corticosteroid in the treatment of children with cough variant asthma

*Cao JY, Wang YC, Deng XX*

#### Randomized Controlled Trial

- 7619** Protective effect of sevoflurane on lung function of elderly chronic obstructive pulmonary disease patients undergoing total hip arthroplasty

*Yao Y, Zhang MS, Li YB, Zhang MZ*

#### CASE REPORT

- 7629** Sunitinib-induced hyperammonemic encephalopathy in metastatic gastrointestinal stromal tumors: A case report

*Hayakawa T, Funakoshi S, Hamamoto Y, Hirata K, Kanai T*

- 7635** Simultaneous lateral and subxiphoid access methods for safe and accurate resection of a superior vena cava aneurysm: A case report

*Kim SP, Son J*

- 7640** Ultrafast power Doppler imaging for ischemic encephalopathy: A case report

*Huang LJ, Jiao JF, He Q, Luo JW, Guo Y*

- 7647** Intermittent spontaneous ovulation in patients with premature ovarian failure: Three case reports and review of literature

*Zhang WY, Wang HB, Deng CY*

- 7656** Sneddon's syndrome concurrent with cerebral venous sinus thrombosis: A case report

*Heng Y, Tang YF, Zhang XW, Duan JF, Shi J, Luo Q*

- 7663** Carcinosarcoma of the deep lobe of the parotid gland in the parapharyngeal region: A case report

*Tang YY, Zhu GQ, Zheng ZJ, Yao LH, Wan ZX, Liang XH, Tang YL*

- 7673** Malignant peripheral nerve sheath tumor with hemophilic syndrome and bone marrow fibrosis: A rare case report

*Li H, Wang L, Wu YH, Chen G, Li HX, Fan LF, Gu M, Jiang CH*

- 7680** Comparison of drug concentrations in blood and gastric lavage fluid before and after gastric lavage: A case report

*Zhou Y, Tong JL, Peng AH, Xu SY*

- 7684** Recurred forehead osteoma disseminated after previous osteoma excision: A case report

*Lee DY, Lim S, Yoon JS, Eo S*

- 7690** Renal pelvis sarcomatoid carcinoma with renal vein tumor thrombus: A case report and literature review

*Guan HY, Wang J, Wang JX, Chen QH, Lu J, He L*

- 7699** Ultrasonographic identification of lateral femoral cutaneous nerve anatomical variation in persistent meralgia paresthetica: A case report

*Park HW, Ji KS, Kim JH, Kim LN, Ha KW*

- 7706** Biliary hemorrhage caused by a malignant small round cell tumor in the common bile duct: A case report  
*Jin YL, Ruan YJ, Lu GR*
- 7712** Successive development of ischemic malignant strokes in a patient with multiple fusiform aneurysms: A case report  
*Shin DS, Yeo DK, Choi EJ*
- 7718** Isolated axillary tumor deposit consistent with primary breast carcinoma: A case report  
*Li T, Zhang WH, Liu J, Mao YL, Liu S*
- 7724** Multiple inflammatory pseudotumor formation after craniopharyngioma resection *via* an extended nasal endoscopic approach: A case report  
*Wu H, Ding YW, Yan ZC, Wei M, Wang XD, Zhang HZ*
- 7732** Huge Bartholin's cyst managed by primary marsupialization: A case report  
*Li HY, Ding DC*

**LETTER TO THE EDITOR**

- 7738** Do not forget diet and exercise during Ramadan  
*Ilias I, Tselebis A*

**ABOUT COVER**

Editorial Board Member of *World Journal of Clinical Cases*, How-Ran Guo, DSc, MD, MSc, Full Professor, Department of Environmental and Occupational Health, College of Medicine, National Cheng Kung University, Tainan 70428, Taiwan. [hrguo@mail.ncku.edu.tw](mailto:hrguo@mail.ncku.edu.tw)

**AIMS AND SCOPE**

The primary aim of *World Journal of Clinical Cases* (WJCC, *World J Clin Cases*) is to provide scholars and readers from various fields of clinical medicine with a platform to publish high-quality clinical research articles and communicate their research findings online.

WJCC mainly publishes articles reporting research results and findings obtained in the field of clinical medicine and covering a wide range of topics, including case control studies, retrospective cohort studies, retrospective studies, clinical trials studies, observational studies, prospective studies, randomized controlled trials, randomized clinical trials, systematic reviews, meta-analysis, and case reports.

**INDEXING/ABSTRACTING**

The WJCC is now abstracted and indexed in Science Citation Index Expanded (SCIE, also known as SciSearch®), Journal Citation Reports/Science Edition, Current Contents®/Clinical Medicine, PubMed, PubMed Central, Reference Citation Analysis, China National Knowledge Infrastructure, China Science and Technology Journal Database, and Superstar Journals Database. The 2023 Edition of Journal Citation Reports® cites the 2022 impact factor (IF) for WJCC as 1.1; IF without journal self cites: 1.1; 5-year IF: 1.3; Journal Citation Indicator: 0.26; Ranking: 133 among 167 journals in medicine, general and internal; and Quartile category: Q4.

**RESPONSIBLE EDITORS FOR THIS ISSUE**

Production Editor: Si Zhao; Production Department Director: Xiang Li; Editorial Office Director: Jin-Lei Wang.

**NAME OF JOURNAL**

*World Journal of Clinical Cases*

**ISSN**

ISSN 2307-8960 (online)

**LAUNCH DATE**

April 16, 2013

**FREQUENCY**

Thrice Monthly

**EDITORS-IN-CHIEF**

Bao-Gan Peng, Salim Surani, Jerzy Tadeusz Chudek, George Kontogeorgos, Maurizio Serati

**EDITORIAL BOARD MEMBERS**

<https://www.wjgnet.com/2307-8960/editorialboard.htm>

**PUBLICATION DATE**

November 6, 2023

**COPYRIGHT**

© 2023 Baishideng Publishing Group Inc

**INSTRUCTIONS TO AUTHORS**

<https://www.wjgnet.com/bpg/gerinfo/204>

**GUIDELINES FOR ETHICS DOCUMENTS**

<https://www.wjgnet.com/bpg/GerInfo/287>

**GUIDELINES FOR NON-NATIVE SPEAKERS OF ENGLISH**

<https://www.wjgnet.com/bpg/gerinfo/240>

**PUBLICATION ETHICS**

<https://www.wjgnet.com/bpg/GerInfo/288>

**PUBLICATION MISCONDUCT**

<https://www.wjgnet.com/bpg/gerinfo/208>

**ARTICLE PROCESSING CHARGE**

<https://www.wjgnet.com/bpg/gerinfo/242>

**STEPS FOR SUBMITTING MANUSCRIPTS**

<https://www.wjgnet.com/bpg/GerInfo/239>

**ONLINE SUBMISSION**

<https://www.f6publishing.com>



## Isolated axillary tumor deposit consistent with primary breast carcinoma: A case report

Tian Li, Wei-Hong Zhang, Juan Liu, Yi-Ling Mao, Sheng Liu

**Specialty type:** Oncology

**Provenance and peer review:**

Unsolicited article; Externally peer reviewed.

**Peer-review model:** Single blind

**Peer-review report's scientific quality classification**

Grade A (Excellent): 0

Grade B (Very good): 0

Grade C (Good): C

Grade D (Fair): 0

Grade E (Poor): 0

**P-Reviewer:** D'Orazi V, Italy

**Received:** September 11, 2023

**Peer-review started:** September 11, 2023

**First decision:** September 28, 2023

**Revised:** October 8, 2023

**Accepted:** October 16, 2023

**Article in press:** October 16, 2023

**Published online:** November 6, 2023



**Tian Li, Wei-Hong Zhang**, Department of Breast Surgery, Shanghai Baoshan Hospital of Integrated Traditional Chinese and Western Medicine, Shanghai 201900, China

**Juan Liu**, Department of Pathology, Shanghai Baoshan Hospital of Integrated Traditional Chinese and Western Medicine, Shanghai 201900, China

**Yi-Ling Mao**, Department of Radiology, Shanghai Baoshan Hospital of Integrated Traditional Chinese and Western Medicine, Shanghai 201900, China

**Sheng Liu**, Graduate School, Shanghai University of Traditional Chinese Medicine, Shanghai 201203, China

**Corresponding author:** Sheng Liu, Doctor, PhD, Chief Doctor, Graduate School, Shanghai University of Traditional Chinese Medicine, No. 725 South Wanping Road, Shanghai 201203, China. [lshtcm@163.com](mailto:lshtcm@163.com)

### Abstract

#### BACKGROUND

We all know that lymph-node metastasis is an important factor for poor clinical outcome in breast cancer prognosis. Tumor deposit refers to a discrete collection of cancer cells that is found in the lymph nodes or other tissues adjacent to the primary tumor site. These tumor deposits are separate from the primary tumor and are often considered as a manifestation of lymph node metastasis. In gastric and colorectal cancer, tumor deposits in the lymph node drainage area have been included as independent prognostic factors. The question arises whether tumor deposits should also be considered as prognostic factors in breast cancer patients. This article aims to provoke some thoughts on this matter through a case study and literature review.

#### CASE SUMMARY

A 70-year-old female patient was found to have a right breast lump for over 2 years. On January 3, 2023, a core needle biopsy of the right breast lump was performed, and the pathology report indicated invasive carcinoma. Subsequently, on January 17, 2023, the patient underwent right breast-conserving surgery, sentinel lymph node biopsy, and right axillary lymph node dissection. The postoperative pathological staging was determined as stage IIB. The patient received chemotherapy, radiotherapy, and endocrine therapy. At present, nearly one year after the surgery, no obvious signs of metastasis have been observed in the follow-up examinations, but the long-term prognosis is still unknown.

## CONCLUSION

There is a need for increased focus on the matter of tumor deposits in the lymph node drainage region, as well as a requirement for further clinical investigation to ascertain the relevance of tumor deposits in the prognosis of individuals with breast carcinoma.

**Key Words:** Tumor deposit; Breast cancer; Axillary; Case report

©The Author(s) 2023. Published by Baishideng Publishing Group Inc. All rights reserved.

**Core Tip:** Further investigation is warranted to ascertain the potential underestimation of breast cancer patients' prognosis for survival in the absence of tumor deposits. Additional research is necessary to elucidate the influence of tumor deposits on the survival prognosis of breast cancer patients. The inclusion of tumor deposits in the tumor-node-metastasis staging of the axillary lymph node drainage area necessitates further exploration.

**Citation:** Li T, Zhang WH, Liu J, Mao YL, Liu S. Isolated axillary tumor deposit consistent with primary breast carcinoma: A case report. *World J Clin Cases* 2023; 11(31): 7718-7723

**URL:** <https://www.wjgnet.com/2307-8960/full/v11/i31/7718.htm>

**DOI:** <https://dx.doi.org/10.12998/wjcc.v11.i31.7718>

## INTRODUCTION

The prognosis of breast cancer is usually determined using the tumor-node-metastasis (TNM) staging system. The TNM staging system takes into account the size of the tumor (T), involvement of lymph nodes (N), and the presence of distant metastasis (M). In the American Joint Committee on Cancer (AJCC)[1] 8<sup>th</sup> edition of breast cancer staging, the status of hormone receptors estrogen receptor (ER), progesterone receptor (PR), and HER2 (human epidermal growth factor receptor)[2] is also considered to more accurately predict the patient's prognosis and develop personalized treatment plans. According to the latest research, there is a proposal to include the immunohistochemistry of lymph nodes in the prognostic staging system[2]. Researchers are continuously seeking ways to further enhance the prognostic staging system, it is expected to improve the accuracy of tumor prognosis assessment and provide better individualized treatment for patients. The recent discovery of tumor deposits in the axillary lymph node drainage area, consistent with the origin of the primary tumor, has prompted me to consider whether the inclusion of this region's tumor deposits (TD) should be incorporated into the prognostic TNM staging. According to the NCCN breast cancer guidelines, tumor deposits are not included in the N staging. However, in this location, it is highly likely that the tumor cells have invaded the lymph nodes. Although lymph node tissue cannot be observed, the location is within the lymph node region. If tumor deposits are not considered as metastatic lymph nodes, it is likely to underestimate the prognosis staging of the tumor, and subsequent treatment plans may be inadequate. Studies on tumor deposits can also be found in gastrointestinal tumors, where tumor deposits have been identified as independent factors for predicting early recurrence and poor prognosis in gastric cancer[3]. The prognostic value of adjuvant chemotherapy in isolated tumor deposits suggested that adjuvant chemotherapy can significantly improve the overall survival and cancer-specific survival of patients with isolated tumor deposits in colon cancer[4]. There is also research indicating that combining tumor deposit counts with positive lymph nodes for N staging in stage III colon cancer patients provides a more accurate prediction of disease-free survival than the current staging system[5]. The contemplation regarding the inclusion of TD in the prognostic staging system for breast cancer patients has been sparked by the case of this patient with a maximum tumor deposit diameter measuring 5cm. It is worthwhile for us to further investigate this matter.

## CASE PRESENTATION

### Chief complaints

A painless palpable lump in the right breast has been present for a duration exceeding two years. The mass has exhibited a gradual increase in size, devoid of any indications of erythema, edema, calor, thoracic constriction, or thoracic discomfort.

### History of present illness

The patient initially detected a lump in the right breast two years ago, but did not pursue medical intervention until her visit to our hospital on January 3, 2023. Utilizing ultrasound guidance, a core needle biopsy was conducted on the aforementioned lump in the right breast. The subsequent postoperative pathology report (pathology number: 230005, Shanghai Baoshan Hospital of Integrated Traditional Chinese and Western Medicine, January 6, 2023) revealed the presence of invasive carcinoma of non-specific subtype. Immunohistochemical staining analysis demonstrated the



following results: CK7(+), CK5/6(-), ER (approximately 80% +), PR (approximately 70% +), C-erbB-2(-), P63(-), CD10(-), and Ki-67 (approximately 30%+).

### History of past illness

The patient has a documented medical record of hypertension spanning over a decade. Presently, they are undergoing treatment with sustained-release nifedipine tablets, taking one tablet per day. The patient's blood pressure is effectively managed. There is no reported history of additional chronic internal medicine ailments, including coronary heart disease. Furthermore, the patient denies any past occurrences of infectious diseases such as hepatitis or tuberculosis. Nevertheless, they do possess a medical history of fractures in the left hip joint and rib bones, resulting in the presence of residual fixation devices within their body.

### Personal and family history

The patient had a family history of breast cancer.

### Physical examination

On physical examination, a palpable mass is found in the upper outer quadrant of the right breast. The size of the mass is approximately 2.5 cm × 3.0 cm. It is hard in consistency, poorly mobile, and has an indistinct border with the surrounding tissue. There are no signs of skin changes, such as the “orange peel” appearance. No significantly enlarged lymph nodes are palpable in the bilateral axilla.

### Laboratory examinations

Liver and kidney function, as well as tumor markers, show no significant abnormalities.

### Imaging examinations

Dynamic contrast enhanced magnetic resonance imaging showed there is a mass in the upper outer quadrant and outer upper quadrant of the right breast is observed (Figure 1A and B), suggesting a possible malignant tumor. The Breast Imaging Reporting and Data System assessment is 4c. A mass-like enhancing lesion is also identified in the right axilla and adjacent to the pectoralis muscle, raising suspicion of metastatic lesions (Figure 2A and B).

### Histological findings

Pathology Report (pathology number: 2300526, Shanghai Baoshan Hospital of Integrated Traditional Chinese and Western Medicine, 2023-01-20): (right breast): Invasive carcinoma, non-special type, Scarff-Richardson grade III (Figure 3A and B). The tumor has infiltrated into the surrounding adipose tissue, with evidence of tumor emboli within blood vessels. No signs of neural invasion are observed. Sentinel lymph node (1/4): Carcinoma metastasis is observed (Figure 3C). One tumor deposit from right axillary area measuring 5 cm × 4 cm × 3 cm is observed (Figure 3D), along with eight additional lymph nodes that show no evidence of cancer metastasis. Immunohistochemical markers results: (Right breast) tumor: CK7(+), CK5/6(-), ER(3+, approximately 90%), PR (3+, approximately 80%), C-erbB-2(-), ECAD(+), P63(-), CD10(-), Ki67 (approximately 50%+). (Right axillary tumor deposit): ER (3+, approximately 90%), PR (3+, approximately 40%), C-erbB-2(-).

## FINAL DIAGNOSIS

The patient has been diagnosed with invasive carcinoma of the right breast, pTNM stage was pT2, N1, M0 (clinical stage: IIB).

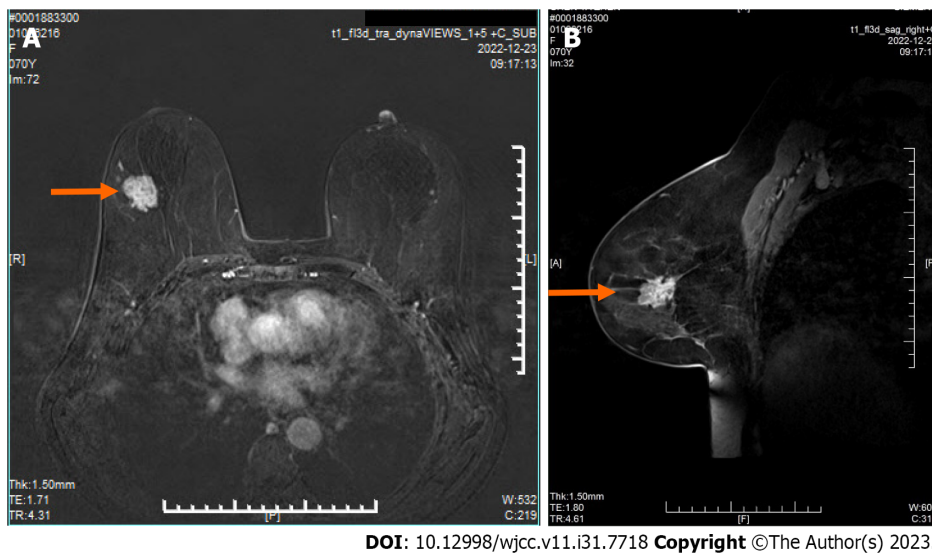
## TREATMENT

The patient underwent right breast-conserving surgery with sentinel lymph node biopsy and right axillary lymph node dissection on January 17, 2023. The patient received 6 cycles of chemotherapy with TC regimen, consisting of Docetaxel 130 mg and Cyclophosphamide 1000 mg. Post-chemotherapy, the patient exhibited normal liver and kidney functions, albeit with a decrease in white blood cell count. To restore the white blood cell count to normal levels, the patient was administered granulocyte colony-stimulating factor. Following chemotherapy, the patient underwent 25 sessions of radiotherapy. At present, the patient is undergoing treatment with oral Letrozole and Abemaciclib for endocrine therapy.

## OUTCOME AND FOLLOW-UP

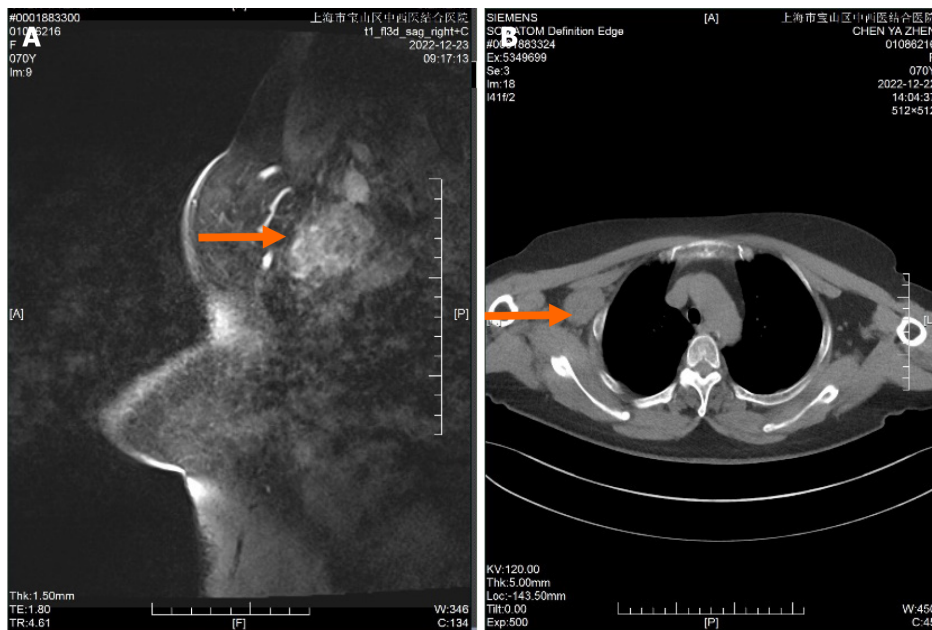
In the past year after the surgery, this patient has been undergoing a comprehensive examination every three months. No signs of recurrence or metastasis have been found.





DOI: 10.12998/wjcc.v11.i31.7718 Copyright ©The Author(s) 2023.

**Figure 1** Dynamic contrast enhanced magnetic resonance imaging results. A mass-like abnormal signal in the upper outer quadrant and outer upper quadrant. The size is approximately 29 mm × 21 mm × 25 mm, with irregular margins and spicules. A: Represents the sagittal view; B: Represents the coronal view.



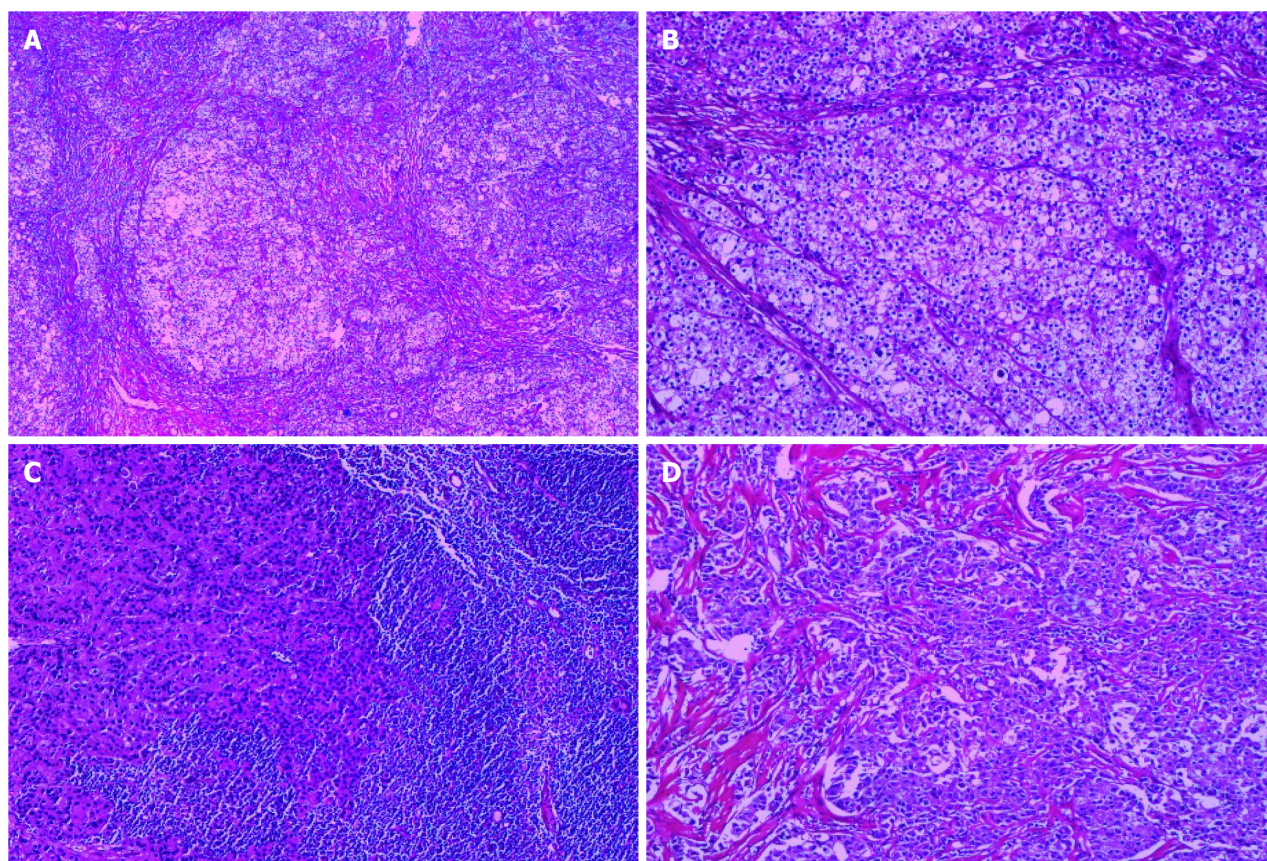
DOI: 10.12998/wjcc.v11.i31.7718 Copyright ©The Author(s) 2023.

**Figure 2** Enhancing lesion identified in the right axilla. A: Magnetic resonance imaging sagittal view; B: Chest computed tomography in the coronal plane view

## DISCUSSION

There is limited research on tumor deposits in breast cancer. However, based on the development and definition of tumor deposits, they are deposits of cancer that have spread through lymphatic channels to distant soft tissues. According to the definition, this indicates regional metastasis. However, these nodules are not included in lymph node staging and prognosis due to the lack of lymph node morphology in pathological HE staining. For this patient, if this 5 cm tumor deposit is included as a metastatic axillary lymph node, the prognosis stage would become pT2N2M0 (clinical stage: IIIA), according to the eighth edition of the TNM staging system which incorporates biomarkers. In this case, the chemotherapy regimen may involve EC\*4-T\*4 instead of TC\*6. Advanced imaging techniques and treatment methods are constantly improving and have an impact on patients' survival outcomes, the tumor deposits originating from the lymph node drainage area also need to be taken seriously. This is crucial for assessing patients' prognosis and guiding subsequent treatment.

To conduct research on whether tumor deposits should be included in the staging of breast cancer prognosis, we can consider adopting some methods used in gastric cancer and colorectal cancer studies. There have been numerous studies



DOI: 10.12998/wjcc.v11.i31.7718 Copyright ©The Author(s) 2023.

**Figure 3 Hematoxylin and eosin.** A: Pathological image of tumor tissue stained with hematoxylin and eosin (HE) at a magnification of  $\times 40$ ; B: Pathological image of tumor tissue stained with HE at a magnification of  $\times 100$ ; C: Pathological image of metastatic lymph node in the right axilla stained with HE at a magnification of  $\times 100$ ; D: Pathological image of tumor deposit from right axillary area stained with HE at a magnification of  $\times 100$ .

on tumor deposits in gastric cancer and colorectal cancer. A national cohort study from Sweden found that TDs are considered a risk factor for postoperative recurrence in colon cancer, suggesting the need for adjuvant chemotherapy[6]. A Delphi consensus study also supported the notion that TDs are indeed associated with worse prognosis compared to cases without TDs[7]. Even in the presence of lymph node metastasis, extramural venous invasion, perineural invasion, and lymphatic invasion, the number of TDs should be recorded[8]. Similarly, a retrospective study found that in gastric cancer[3], patients with positive tumor deposits had poorer 5-year disease-free survival rates (32.60% *vs* 92.45%) and overall survival rates (41.22% *vs* 89.37%) compared to those with negative tumor deposits. Tumor deposits are a strong and independent predictor of lower recurrence rates and survival rates in gastric tumors. These studies have made us realize the significance of tumor deposits in other types of cancer, and we can also consider these studies in defining whether to include tumor deposits in the prognosis staging and guiding treatment for breast cancer patients.

## CONCLUSION

We should pay more attention to the presence of axillary tumor deposits and there is a need for further clinical research to discuss whether to include axillary tumor deposits in the prognostic criteria for breast cancer.

## FOOTNOTES

**Co-first authors:** Tian Li and Wei-Hong Zhang.

**Author contributions:** Li T responsible for paper writing and data organization; Zhang WH responsible for the design of the paper, literature review; Mao YL responsible for organizing imaging data; Liu J responsible for collection and imaging of pathological data; Liu S responsible for the designing of the overall structure of the article, providing ideas, and revising the article.

**Informed consent statement:** All study participants, or their legal guardian, provided informed written consent prior to study enrollment.



**Conflict-of-interest statement:** The authors declare that they have no financial or personal interests that could be perceived as influencing the research findings or biasing the interpretation.

**CARE Checklist (2016) statement:** The authors have read the CARE Checklist (2016), and the manuscript was prepared and revised according to the CARE Checklist (2016).

**Open-Access:** This article is an open-access article that was selected by an in-house editor and fully peer-reviewed by external reviewers. It is distributed in accordance with the Creative Commons Attribution NonCommercial (CC BY-NC 4.0) license, which permits others to distribute, remix, adapt, build upon this work non-commercially, and license their derivative works on different terms, provided the original work is properly cited and the use is non-commercial. See: <https://creativecommons.org/licenses/by-nc/4.0/>

**Country/Territory of origin:** China

**ORCID number:** Tian Li 0000-0001-8582-2115; Wei-Hong Zhang 0000-0003-0681-7751; Sheng Liu 0000-0002-0972-1512.

**S-Editor:** Liu JH

**L-Editor:** A

**P-Editor:** Zhao S

## REFERENCES

- 1 **Giuliano AE**, Edge SB, Hortobagyi GN. Eighth Edition of the AJCC Cancer Staging Manual: Breast Cancer. *Ann Surg Oncol* 2018; **25**: 1783-1785 [PMID: 29671136 DOI: 10.1245/s10434-018-6486-6]
- 2 **Fischer JR**, Jackson HW, de Souza N, Varga Z, Schraml P, Moch H, Bodenmiller B. Multiplex imaging of breast cancer lymph node metastases identifies prognostic single-cell populations independent of clinical classifiers. *Cell Rep Med* 2023; **4**: 100977 [PMID: 36921599 DOI: 10.1016/j.xcrm.2023.100977]
- 3 **Fujikawa K**, Omori T, Shinno N, Hara H, Yamamoto M, Yasui M, Matsuda C, Wada H, Nishimura J, Haraguchi N, Akita H, Ohue M, Miyata H. Tumor Deposit Is an Independent Factor Predicting Early Recurrence and Poor Prognosis in Gastric Cancer. *J Gastrointest Surg* 2023; **27**: 1336-1344 [PMID: 37014588 DOI: 10.1007/s11605-023-05668-y]
- 4 **Lin Q**, Zhou H, Shi S, Lin J, Yan W. The Prognostic Value of Adjuvant Chemotherapy in Colon Cancer With Solitary Tumor Deposit. *Front Oncol* 2022; **12**: 916091 [PMID: 35912212 DOI: 10.3389/fonc.2022.916091]
- 5 **Pyo DH**, Kim SH, Ha SY, Yun SH, Cho YB, Huh JW, Park YA, Shin JK, Lee WY, Kim HC. Revised Nodal Staging Integrating Tumor Deposit Counts With Positive Lymph Nodes in Patients With Stage III Colon Cancer. *Ann Surg* 2023; **277**: e825-e831 [PMID: 34954753 DOI: 10.1097/SLA.0000000000005355]
- 6 **Agger E**, Jörgen F, Jöud A, Lydrup ML, Buchwald P. Negative Prognostic Impact of Tumor Deposits in Rectal Cancer: A National Study Cohort. *Ann Surg* 2023; **278**: e526-e533 [PMID: 36538637 DOI: 10.1097/SLA.0000000000005755]
- 7 **Lord A**, Brown G, Abulafi M, Bateman A, Frankel W, Goldin R, Gopal P, Kirsch R, Loughrey MB, Märkl B, Moran B, Puppa G, Rasheed S, Shimada Y, Snaebjornsson P, Svrcek M, Washington K, West N, Wong N, Nagtegaal I. Histopathological diagnosis of tumour deposits in colorectal cancer: a Delphi consensus study. *Histopathology* 2021; **79**: 168-175 [PMID: 33511676 DOI: 10.1111/his.14344]
- 8 **Pei JP**, Zhang CD, Liang Y, Zhang C, Wu KZ, Li YZ, Zhao ZM, Dai DQ. A Modified Pathological N Stage Including Status of Tumor Deposits in Colorectal Cancer With Nodal Metastasis. *Front Oncol* 2020; **10**: 548692 [PMID: 33262940 DOI: 10.3389/fonc.2020.548692]



Published by **Baishideng Publishing Group Inc**  
7041 Koll Center Parkway, Suite 160, Pleasanton, CA 94566, USA

**Telephone:** +1-925-3991568

**E-mail:** [bpgoffice@wjgnet.com](mailto:bpgoffice@wjgnet.com)

**Help Desk:** <https://www.f6publishing.com/helpdesk>

<https://www.wjgnet.com>

