

World Journal of *Gastrointestinal Surgery*

World J Gastrointest Surg 2023 December 27; 15(12): 2674-2961



Contents

Monthly Volume 15 Number 12 December 27, 2023

REVIEW

- 2674 Antimicrobial approach of abdominal post-surgical infections
Fiore M, Corrente A, Di Franco S, Alfieri A, Pace MC, Martora F, Petrou S, Mauriello C, Leone S

MINIREVIEWS

- 2693 Indocyanine green fluorescence in gastrointestinal surgery: Appraisal of current evidence
Kalayarasan R, Chandrasekar M, Sai Krishna P, Shanmugam D
- 2709 Post-cholecystectomy iatrogenic bile duct injuries: Emerging role for endoscopic management
Emara MH, Ahmed MH, Radwan MI, Emara EH, Basheer M, Ali A, Elfert AA

ORIGINAL ARTICLE

Case Control Study

- 2719 Multidisciplinary diagnosis and treatment nutritional support intervention for gastrointestinal tumor radiotherapy: Impact on nutrition and quality of life
Hui L, Zhang YY, Hu XD

Retrospective Cohort Study

- 2727 Association between the early high level of serum tacrolimus and recurrence of hepatocellular carcinoma in ABO-incompatible liver transplantation
Han JW, Choi JY, Jung ES, Kim JH, Cho HS, Yoo JS, Sung PS, Jang JW, Yoon SK, Choi HJ, You YK
- 2739 Determining the need for a thoracoscopic approach to treat a giant hiatal hernia when abdominal access is poor
Pérez Lara FJ, Zubizarreta Jimenez R, Prieto-Puga Arjona T, Gutierrez Delgado P, Hernández Carmona JM, Hernández Gonzalez JM, Pitarch Martinez M
- 2747 Predictive value of Hajibandeh index in determining peritoneal contamination in acute abdomen: A cohort study and meta-analysis
Hajibandeh S, Hajibandeh S, Evans L, Miller B, Waterman J, Ahmad SJ, Hale J, Higgi A, Johnson B, Pearce D, Helmy AH, Naguib N, Maw A

Retrospective Study

- 2757 Efficacy of pantoprazole plus perforation repair for peptic ulcer and its effect on the stress response
Leng ZY, Wang JH, Gao L, Shi K, Hua HB
- 2765 Application of electroacupuncture in the prevention of low anterior resection syndrome after rectal cancer surgery
Xu LL, Xiang NJ, Cheng TC, Li YX, Chen P, Jiang ZW, Liu XX

- 2774** Effects of remifentanyl combined with propofol on hemodynamics and oxidative stress in patients undergoing resection of rectal carcinoma
Huang J, Tian WJ
- 2783** Percutaneous microwave ablation and transcatheter arterial chemoembolization for serum tumor markers and prognostics of middle-late primary hepatic carcinoma
Lin ZP, Huang DB, Zou XG, Chen Y, Li XQ, Zhang J
- 2792** Novel invagination procedure for pancreaticojejunostomy using double purse string sutures: A technical note
Li J, Niu HY, Meng XK
- 2799** Laparoscopic resection and endoscopic submucosal dissection for treating gastric ectopic pancreas
Zheng HD, Huang QY, Hu YH, Ye K, Xu JH
- 2809** Prediction of the lymphatic, microvascular, and perineural invasion of pancreatic neuroendocrine tumors using preoperative magnetic resonance imaging
Liu YL, Zhu HB, Chen ML, Sun W, Li XT, Sun YS
- 2820** Impact of hepatectomy and postoperative adjuvant transarterial chemoembolization on serum tumor markers and prognosis in intermediate-stage hepatocellular carcinoma
Hu YD, Zhang H, Tan W, Li ZK

Observational Study

- 2831** Analysis of nutritional risk, skeletal muscle depletion, and lipid metabolism phenotype in acute radiation enteritis
Ma CY, Zhao J, Qian KY, Xu Z, Xu XT, Zhou JY

Randomized Controlled Trial

- 2844** Holistic conditions after colon cancer: A randomized controlled trial of systematic holistic care *vs* primary care
Wang J, Qiao JH

Basic Study

- 2855** Mutational separation and clinical outcomes of *TP53* and *CDH1* in gastric cancer
Liu HL, Peng H, Huang CH, Zhou HY, Ge J
- 2866** Hepatic vagotomy blunts liver regeneration after hepatectomy by downregulating the expression of interleukin-22
Zhou H, Xu JL, Huang SX, He Y, He XW, Lu S, Yao B

META-ANALYSIS

- 2879** Recent evidence for subcutaneous drains to prevent surgical site infections after abdominal surgery: A systematic review and meta-analysis
Ishinuki T, Shinkawa H, Kouzu K, Shinji S, Goda E, Ohyanagi T, Kobayashi M, Kobayashi M, Suzuki K, Kitagawa Y, Yamashita C, Mohri Y, Shimizu J, Uchino M, Haji S, Yoshida M, Ohge H, Mayumi T, Mizuguchi T

- 2890** Prognostic role of serum carcinoembryonic antigen in patients receiving liver resection for colorectal cancer liver metastasis: A meta-analysis
Tang F, Huang CW, Tang ZH, Lu SL, Bai T, Huang Q, Li XZ, Zhang B, Wu FX
- 2907** Significance of carcinoembryonic antigen detection in the early diagnosis of colorectal cancer: A systematic review and meta-analysis
Wang R, Wang Q, Li P

CASE REPORT

- 2919** Primary repair of esophageal atresia gross type C *via* thoracoscopic magnetic compression anastomosis: A case report
Zhang HK, Li XQ, Song HX, Liu SQ, Wang FH, Wen J, Xiao M, Yang AP, Duan XF, Gao ZZ, Hu KL, Zhang W, Lv Y, Zhou XH, Cao ZJ
- 2926** Portal vein embolization for closure of marked arteriportal shunt of hepatocellular carcinoma to enable radioembolization: A case report
Wang XD, Ge NJ, Yang YF
- 2932** Removal of a large rectal polyp with endoscopic submucosal dissection-trans-anal rectoscopic assisted minimally invasive surgery hybrid technique: A case report
Polese L
- 2938** Successful treatment of invasive liver abscess syndrome caused by *Klebsiella variicola* with intracranial infection and septic shock: A case report
Zhang PJ, Lu ZH, Cao LJ, Chen H, Sun Y
- 2945** Duodenojejunostomy treatment of groove pancreatitis-induced stenosis and obstruction of the horizontal duodenum: A case report
Zhang Y, Cheng HH, Fan WJ
- 2954** Awake robotic liver surgery: A case report
Delvecchio A, Pavone G, Conticchio M, Piacente C, Varvara M, Ferraro V, Stasi M, Casella A, Filippo R, Tedeschi M, Pullano C, Inchingolo R, Delmonte V, Memeo R

ABOUT COVER

Editorial Board Member of *World Journal of Gastrointestinal Surgery*, Lapo Bencini, PhD, General Surgery Unit, AOUC, Department of Oncology and Robotics, Careggi University Hospital, Florence 350134, Italy. lapbenc@tin.it

AIMS AND SCOPE

The primary aim of *World Journal of Gastrointestinal Surgery* (WJGS, *World J Gastrointest Surg*) is to provide scholars and readers from various fields of gastrointestinal surgery with a platform to publish high-quality basic and clinical research articles and communicate their research findings online.

WJGS mainly publishes articles reporting research results and findings obtained in the field of gastrointestinal surgery and covering a wide range of topics including biliary tract surgical procedures, biliopancreatic diversion, colectomy, esophagectomy, esophagostomy, pancreas transplantation, and pancreatectomy, etc.

INDEXING/ABSTRACTING

The WJGS is now abstracted and indexed in Science Citation Index Expanded (SCIE, also known as SciSearch®), Current Contents/Clinical Medicine, Journal Citation Reports/Science Edition, PubMed, PubMed Central, Reference Citation Analysis, China Science and Technology Journal Database, and Superstar Journals Database. The 2023 Edition of Journal Citation Reports® cites the 2022 impact factor (IF) for WJGS as 2.0; IF without journal self cites: 1.9; 5-year IF: 2.2; Journal Citation Indicator: 0.52; Ranking: 113 among 212 journals in surgery; Quartile category: Q3; Ranking: 81 among 93 journals in gastroenterology and hepatology; and Quartile category: Q4.

RESPONSIBLE EDITORS FOR THIS ISSUE

Production Editor: Rui-Rui Wu, Production Department Director: Xu Guo, Editorial Office Director: Jia-Ru Fan.

NAME OF JOURNAL

World Journal of Gastrointestinal Surgery

ISSN

ISSN 1948-9366 (online)

LAUNCH DATE

November 30, 2009

FREQUENCY

Monthly

EDITORS-IN-CHIEF

Peter Schemmer

EDITORIAL BOARD MEMBERS

<https://www.wjgnet.com/1948-9366/editorialboard.htm>

PUBLICATION DATE

December 27, 2023

COPYRIGHT

© 2023 Baishideng Publishing Group Inc

INSTRUCTIONS TO AUTHORS

<https://www.wjgnet.com/bpg/gerinfo/204>

GUIDELINES FOR ETHICS DOCUMENTS

<https://www.wjgnet.com/bpg/GerInfo/287>

GUIDELINES FOR NON-NATIVE SPEAKERS OF ENGLISH

<https://www.wjgnet.com/bpg/gerinfo/240>

PUBLICATION ETHICS

<https://www.wjgnet.com/bpg/GerInfo/288>

PUBLICATION MISCONDUCT

<https://www.wjgnet.com/bpg/gerinfo/208>

ARTICLE PROCESSING CHARGE

<https://www.wjgnet.com/bpg/gerinfo/242>

STEPS FOR SUBMITTING MANUSCRIPTS

<https://www.wjgnet.com/bpg/GerInfo/239>

ONLINE SUBMISSION

<https://www.f6publishing.com>



Awake robotic liver surgery: A case report

Antonella Delvecchio, Gaetano Pavone, Maria Conticchio, Claudia Piacente, Miriam Varvara, Valentina Ferraro, Matteo Stasi, Annachiara Casella, Rosalinda Filippo, Michele Tedeschi, Carmine Pullano, Riccardo Inchingolo, Vito Delmonte, Riccardo Memeo

Specialty type: Gastroenterology and hepatology

Provenance and peer review:

Invited article; Externally peer reviewed.

Peer-review model: Single blind

Peer-review report's scientific quality classification

Grade A (Excellent): 0
Grade B (Very good): 0
Grade C (Good): C, C
Grade D (Fair): 0
Grade E (Poor): 0

P-Reviewer: Alzerwi NAN, Saudi Arabia; Navarrete Arellano M, Mexico

Received: September 22, 2023

Peer-review started: September 22, 2023

First decision: October 17, 2023

Revised: October 30, 2023

Accepted: December 6, 2023

Article in press: December 6, 2023

Published online: December 27, 2023



Antonella Delvecchio, Maria Conticchio, Valentina Ferraro, Matteo Stasi, Annachiara Casella, Rosalinda Filippo, Michele Tedeschi, Riccardo Memeo, Unit of Hepato-Pancreatic-Biliary Surgery, “F. Miulli” Regional General Hospital, Bari 70021, Italy

Gaetano Pavone, Claudia Piacente, Miriam Varvara, Vito Delmonte, Unit of Anesthesia and Perioperative Medicine, “F. Miulli” Regional General Hospital, Bari 70021, Italy

Carmine Pullano, Villa Pia Hospital, Rome 00151, Italy

Riccardo Inchingolo, Unit of Interventional Radiology, “F. Miulli” Regional General Hospital, Bari 70021, Italy

Corresponding author: Riccardo Inchingolo, MD, Director, Doctor, Unit of Interventional Radiology, “F. Miulli” Regional General Hospital, Strada per Santeramo, Bari 70021, Italy.
riccardoin@hotmail.it

Abstract

BACKGROUND

In recent years, minimally invasive liver resection has become a standard of care for liver tumors. Considering the need to treat increasingly fragile patients, general anesthesia is sometimes avoided due to respiratory complications. Therefore, surgical treatment with curative intent is abandoned in favor of a less invasive and less radical approach. Epidural anesthesia has been shown to reduce respiratory complications, especially in elderly patients with pre-existing lung disease.

CASE SUMMARY

A 77-year-old man with hepatitis-C-virus-related chronic liver disease underwent robotic liver resection for hepatocellular carcinoma. The patient was suffering from hypertension, diabetes and chronic obstructive pulmonary disease. The National Surgical Quality Improvement Program score for developing pneumonia was 9.2%. We planned a combined spinal-epidural anesthesia with conscious sedation to avoid general anesthesia. No modification of the standard surgical technique was necessary. Hemodynamics were stable and bleeding was minimal. The postoperative course was uneventful.

CONCLUSION

Robotic surgery in locoregional anesthesia with conscious sedation could be considered a safe and suitable approach in specialized centers and in selected

patients.

Key Words: Robotic surgery; Awake surgery; Liver resection; Frail patient; Locoregional anesthesia; Conscious sedation; Case report

©The Author(s) 2023. Published by Baishideng Publishing Group Inc. All rights reserved.

Core Tip: Liver resection represents a gold standard for the treatment of liver malignancies. Minimally invasive approach guarantees less invasiveness and faster postoperative recovery. Frail and older patients undergoing liver resection under general anesthesia have a high risk of respiratory and cardiac complications. Locoregional anesthesia preserves better intestinal, cardiac and pulmonary function compared to general anesthesia. The combination of robotic surgery and locoregional anesthesia guarantees minimal surgical and anesthetic invasiveness and could be considered a safe approach in selected patients and specialized centers.

Citation: Delvecchio A, Pavone G, Conticchio M, Piacente C, Varvara M, Ferraro V, Stasi M, Casella A, Filippo R, Tedeschi M, Pullano C, Inchingolo R, Delmonte V, Memeo R. Awake robotic liver surgery: A case report. *World J Gastrointest Surg* 2023; 15(12): 2954-2961

URL: <https://www.wjgnet.com/1948-9366/full/v15/i12/2954.htm>

DOI: <https://dx.doi.org/10.4240/wjgs.v15.i12.2954>

INTRODUCTION

Liver resection is a gold standard for the treatment of liver malignancies. In recent years, first laparoscopic and then robotic approaches have emerged as first-line options for liver resection[1,2]. The minimally invasive approach guarantees less invasiveness and faster postoperative recovery. This kind of surgery is usually performed under general or combined general and epidural anesthesia.

In most cases, liver resection was performed on frail patients with many comorbidities and liver diseases[3]. The surgical approach is not the only one to ensure a good perioperative course but also the type of anesthetic approach. In frail and older patients with many comorbidities, general anesthesia is associated with a high risk of respiratory and cardiac complications.

Sometimes the high perioperative risk excludes the possibility to perform surgery with curative intent. In this type of patient, compared with general anesthesia, locoregional anesthesia reduces cardiac and pulmonary complications and the use of opioids, while preserving better intestinal, cardiac and pulmonary function[4,5]. Locoregional anesthesia is integrated with conscious sedation to avoid patient movements under the robotic platform, as reported for robotic partial nephrectomy[6].

The combination of robotic surgery and locoregional anesthesia guarantees both surgical and anesthetic minimal invasiveness. We report a case of robotic liver resection under epidural and spinal anesthesia in a frail patient with many comorbidities.

CASE PRESENTATION

Chief complaints

A 77-year-old man with hepatocellular carcinoma (HCC) and hepatitis-C-virus-related chronic liver disease was enrolled for robotic wedge resection of segment II.

History of present illness

During the 6-monthly follow-up for chronic liver disease, investigations revealed a liver lesion in segment II.

History of past illness

The patient had previously undergone subtotal gastrectomy for peptic ulcer disease, lumbar discectomy for disc herniation, and bilateral carotid endarterectomy with stenting. The patient had: Hypertension, diabetes, peripheral vascular disease, chronic obstructive pulmonary disease (COPD). The home medications were: Olmesartan, clopidogrel, insulin, doxazosin, and pravastatin. No COPD therapy had ever been started.

Personal and family history

The patient denied any family history of malignant tumors.

Physical examination

Body mass index was 28 kg/m². Chest auscultation revealed mild rhonchi on expiration in both lung bases. No pathological sounds were heard on cardiac auscultation. The abdomen was treatable over the entire area.

Laboratory examinations

Levels of serum tumor markers were: Carcinoembryonic antigen, 5.3 ng/mL; carbohydrate antigen 19-9, 5.0 U/mL; and -fetoprotein, 50 ng/mL. No abnormality was found in routine blood analyses.

Imaging examinations

Computed tomography and magnetic resonance imaging detected a 3-cm lesion in liver segment II characterized by wash in in the arterial phase and wash out in the portal phase.

Further diagnostic work-up

Preoperative diagnosis was based on the noninvasive criteria established by the European Association for the Study of the Liver[7].

FINAL DIAGNOSIS

After combining the patient's medical history, and laboratory and imaging examinations, the final diagnosis was HCC.

TREATMENT

Anesthetic procedure

Before the procedures, we performed a thromboelastography (TEG) platelet mapping test (TEG 6s), which showed normal values for ADP and arachidonic acid (AA) test; ADP test: 64.4 mm (normal values: 45–69 mm) and AA test: 66.4 mm (normal values: 51–71 mm).

Noninvasive monitoring with multiparameter monitoring (Figure 1) was initiated: Electrocardiography, noninvasive blood pressure and pulse oximetry. The mechanical ventilation monitor was turned off, as shown in Figure 2. A combined spinal-epidural anesthetic was planned.

An epidural catheter was inserted at T6–T7, followed by subarachnoid anesthesia at T12–L1 with ropivacaine 10 mg + dexmedetomidine 10 g (total volume 5 mL, diluted with distilled water). After patient positioning, an epidural bolus of ropivacaine 0.2% + midazolam 5 mg (total volume 10 mL) was administered. Ten minutes after the epidural bolus, the pinprick was negative at C4, with Bromage IV. We added intravenous sedation with dexmedetomidine 100 g + ketamine 50 mg + remifentanyl 1 mg in 50 mL saline at 3 mL/h and with a Richmond Agitation-Sedation Scale 2/3 target around remifentanyl at 0.01 g/kg/min, dexmedetomidine 0.07 g/kg/h, ketamine 0.03 mg/kg/h. Supplemental oxygen was administered *via* nasal cannula at 2 L/min. We did not routinely monitor central venous pressure for liver resection[8], but intra-arterial cannulation of the left radial artery was placed without local anesthesia and patient discomfort. We use the FloTrac® sensor for intraoperative monitoring[9].

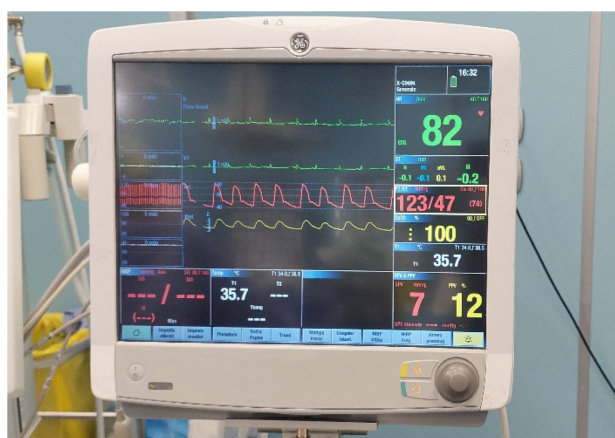Given the unreliability of stroke volume variation in spontaneous respiration in the resection phase, we aimed to have a 10% reduction in stroke volume until the end of the resection, with restrictive fluid therapy and using diuretics. Anesthesia, in spontaneous respiration, was maintained with epidural injection of ropivacaine 0.2%, 10 mL every 1 h.

The hemodynamics remained stable throughout the entire operation. Continuous infusion of crystalloid solution 1 mg/kg/h was given until the end of the liver resection. The cardiac index was in the normal range and the stroke volume index decreased from the initial 50 mL/m² to 30–35 mL/m² at the end of the resection (Figure 3). We aimed for a mean arterial pressure of 65 mmHg and four boluses of 5 mg ephedrine were required (Figure 4).

Surgical procedure

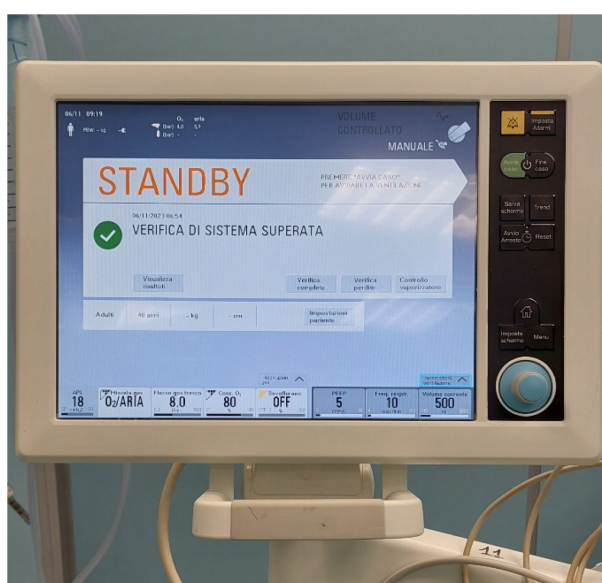
Robotic surgery was performed using the Da Vinci Xi robotic platform. The patient was awake and placed in a supine position with 30° reverse Trendelenburg position (Figure 5). A pneumoperitoneum was created using an open technique through a supraumbilical incision. Insufflation of pneumoperitoneum at 12 mmHg was uneventful. The other three robotic trocars and two laparoscopic 12-mm trocar assistants were inserted under direct vision. The trocar position was standardized as shown in Figure 6. The surgeon was sitting at the robotic console and the assistant surgeon was between the patient's legs. The assistant performed retraction, suction, cutting and stapling.

The procedure began with exploration of the abdominal cavity and intraoperative ultrasound to check the liver tumor. Transection of the hepatoduodenal and falciform ligaments was performed for preparation of the hepatic hilum for the Pringle maneuver. We placed the Foley catheter around the hepatic hilum for intermittent intracorporeal clamping. Liver parenchymal transection was performed with double crash clamping and vessel sealing for the main pedicle. Indocyanine green was administered the day before the procedure and used in positive staining in association with intraoperative ultrasound to better highlight the parenchymal transection margin. Hem-o-lock clips were used for resection of vascular and biliary structures. Specimens were placed in a laparoscopic extraction bag and removed through enlargement of the trocar. No modification of the usually adopted surgical technique was necessary and no Pringle maneuver was used to



DOI: 10.4240/wjgs.v15.i12.2954 Copyright ©The Author(s) 2023.

Figure 1 Multiparameter monitor. Monitor was turned on with parameter detection: electrocardiogram, noninvasive blood pressure and pulse oximetry.



DOI: 10.4240/wjgs.v15.i12.2954 Copyright ©The Author(s) 2023.

Figure 2 Mechanical ventilation monitor. Monitor was turned off because the patient was breathing spontaneously.

minimize blood loss. The patient had an uneventful postoperative course and was discharged on postoperative day 4.

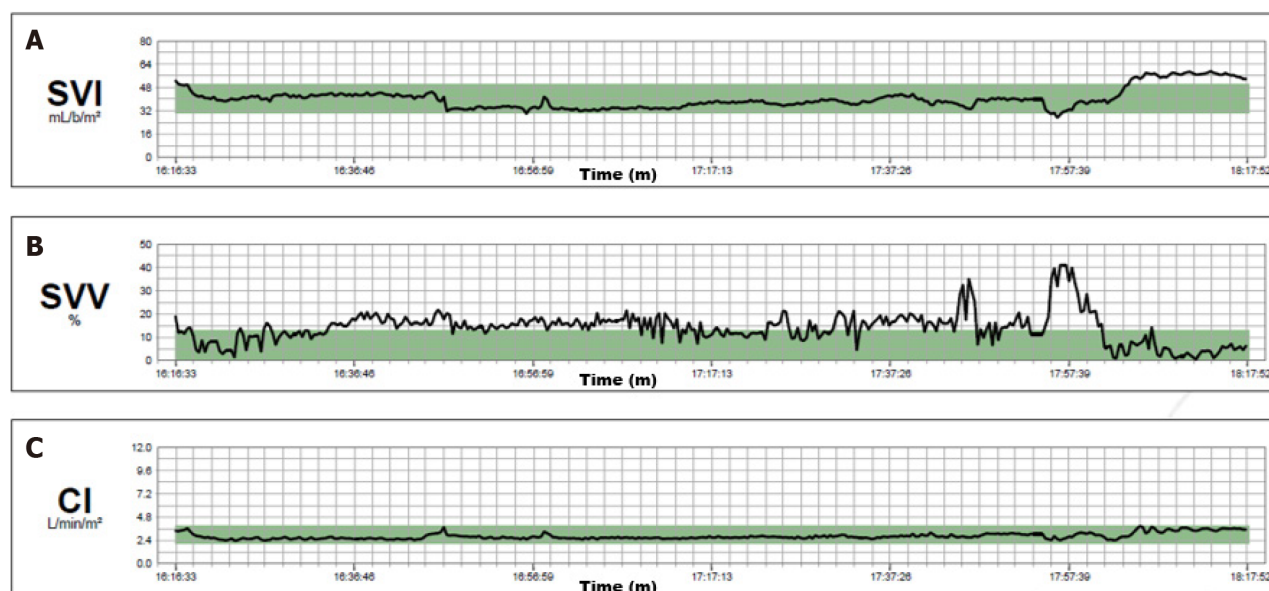
OUTCOME AND FOLLOW-UP

At 1 year postoperatively, the patient was still alive and free of disease.

DISCUSSION

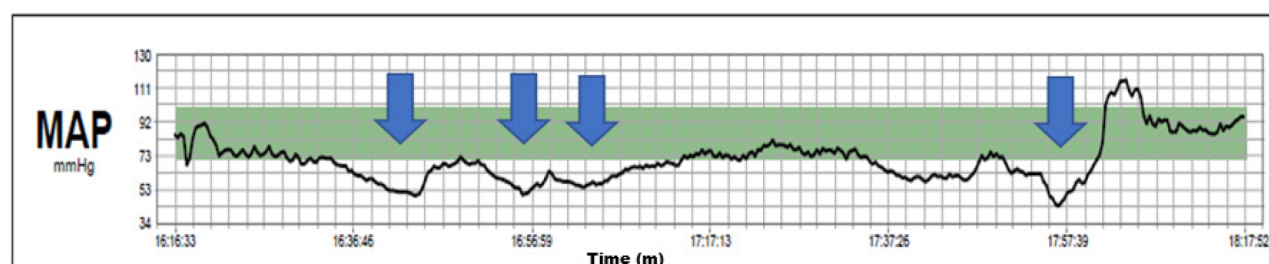
In the last few decades, minimally invasive surgery has emerged as the gold standard for treatment of liver tumor. During the Consensus Conferences of Louisville in 2008[10] and Morioka in 2014[11], and the Southampton Guidelines Meeting in 2017[1], the minimally invasive techniques were standardized also for complex procedures. The minimally invasive approach guarantees less invasiveness, reduction of postoperative complications and faster postoperative recovery.

Despite technological advances, laparoscopic liver resection is still limited by rigid instruments and 2D vision, resulting in steep learning curves and difficulties in performing major hepatectomy and resection of lesions located in posterosuperior segments[12].



DOI: 10.4240/wjgs.v15.i12.2954 Copyright ©The Author(s) 2023.

Figure 3 Intraoperative hemodynamic monitoring. A: Stroke volume index curve; B: Stroke volume variation curve; C: Cardiac index curve. SVI: Stroke volume index curve; SVV: Stroke volume variation curve; CI: Cardiac Index curve.



DOI: 10.4240/wjgs.v15.i12.2954 Copyright ©The Author(s) 2023.

Figure 4 Intraoperative mean arterial pressure: mean arterial pressure. MAP curve. Arrows indicate four boluses of ephedrine. MAP: Mean arterial pressure.

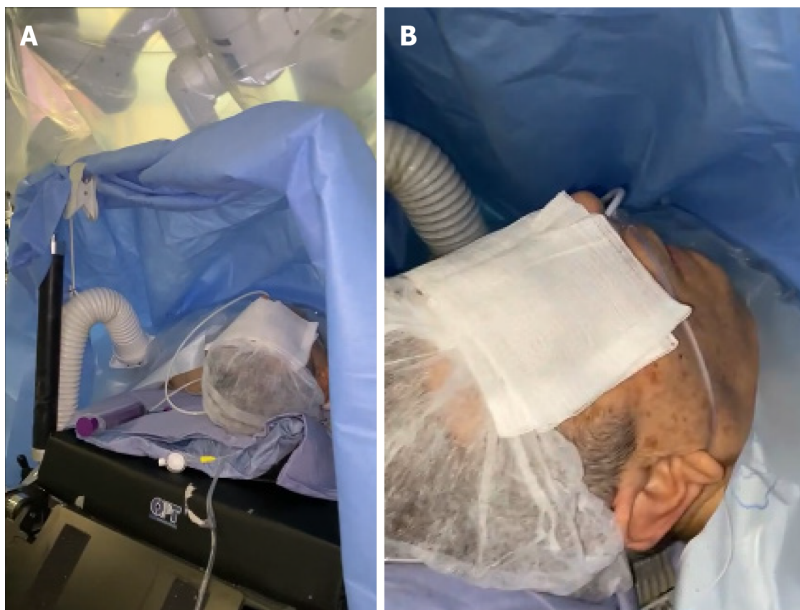
The robotic platform overcomes some limits of laparoscopic surgery thanks to the high definition of 3D vision, magnified field of vision, tremor filter, EndoWrist articulated instruments, and improved surgeon's ergonomics. This allows surgeons to perform some complex procedures, such as hilar dissection or biliary-enteric anastomosis and resection of posterosuperior segments[13]. These technical properties guarantee a lower estimated blood loss, less narcotic use, shorter length of hospital stay, and improved short-term quality of life for complex liver resection[13].

However, the benefits of the robotic approach in liver surgery have not yet been clearly defined and some recently published studies comparing robotic and laparoscopic techniques have not provided conclusive results in favor of either approach[14,15]. Use of the robotic platform has increased exponentially in the last 10 years and, in 2018, the first international consensus statement on robotic liver surgery was published[2].

In most cases, liver resection has been performed on frail patients with many comorbidities and liver diseases[3]. The surgical approach is not the only way to ensure a good perioperative course, and the anesthetic approach is also important. Liver resection is usually performed under general or combined general and epidural anesthesia. In more frail and older patients with many comorbidities, general anesthesia is associated with a high risk of respiratory and cardiac complications. Sometimes, the high perioperative risk excludes the possibility of surgery with curative intent. General anesthesia for high-risk surgical patients with significant lung disease may trigger some adverse effects, including: Pneumonia, heart failure, biotrauma and barotrauma, and subsequently, intra- and postoperative hypoxemia[4,16].

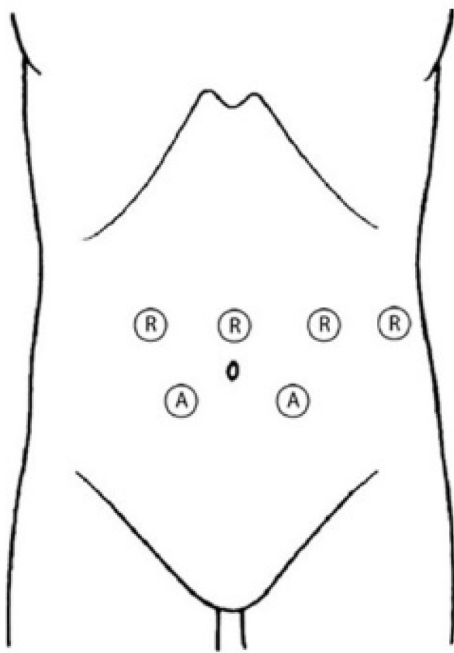
Epidural anesthesia reduces the decrease in tissue oxygen tension caused by surgical stress and adrenergic vasoconstriction during major abdominal surgery, which provides sufficient oxygenation of organs with improved cardiac, respiratory and gastrointestinal function[17]. Locoregional anesthesia reduces the invasiveness of general anesthesia and the use of opioids, preserving better intestinal and pulmonary function, and could be used in frail patients. The reduction in postoperative pulmonary complications with epidural anesthesia has been confirmed by two systemic reviews[5,18].

Awake surgery is a specialized surgical technique performed on patients who remains awake and conscious during the procedure. The patient receives sedative drugs to help them feel relaxed and less anxious during the operation. The decision to perform awake abdominal surgery depends on several factors, including the type of surgery, the patient's medical condition and the surgeon's expertise. This approach may be preferred in certain situations, such as for gynecological



DOI: 10.4240/wjgs.v15.i12.2954 Copyright ©The Author(s) 2023.

Figure 5 Patient awake in a supine position. A: The patient was awake and placed in the supine position with 30° reverse Trendelenburg under the robotic arms; B: The patient was awake in the absence of an endotracheal tube.



DOI: 10.4240/wjgs.v15.i12.2954 Copyright ©The Author(s) 2023.

Figure 6 Trocar positions. Patient was placed in a supine position with 30° reverse Trendelenburg position. A pneumoperitoneum was created using an open technique through a supraumbilical incision. The other three robotic trocar, right pararectal, left pararectal and left flank, and two laparoscopic 12-mm trocar assistants, right and left iliac fossa, were inserted under direct vision.

logical procedures, brain surgery, hernia repair or appendectomy. In 1994, a case of colectomy under awake epidural anesthesia was reported in a patient with high perioperative risk. The procedure was safe and effective[19]. Since then, other awake procedures under epidural anesthesia have been reported including awake laparoscopic cholecystectomy in COPD patients[20].

During the COVID-19 pandemic, the surgical community focused on the potential risks of minimally invasive surgery and general anesthesia because they are both aerosol-generating procedures that could cause the spread of contamination in operating theaters[21]. For these reasons, increased use of regional anesthesia was supported and encouraged during the pandemic. Locoregional anesthesia was reported also for emergency abdominal surgery in high-risk patients with decreased morbidity and mortality[22,23]. The combination of robotic surgery and locoregional anesthesia guarantees minimal surgical and anesthetic invasiveness, excellent quality of surgery and enhanced recovery[17].

There are cases in the literature of awake robotic cardiac surgery[24], awake robotic partial nephrectomy[6] and awake video-assisted thoracic surgery[25]. However, to our knowledge, there are no cases in the literature of awake robotic liver resection, but just a case series of awake open hepatectomy[26]. Our patient was frail with liver cirrhosis, and cardiac, vascular and lung diseases. In other hospitals, the patient was not a candidate for radical surgery because of the high perioperative risk. Our patient received the least invasive treatment possible, thanks to the close collaboration between surgeons and anesthesiologists. The patient had an uneventful postoperative course and was discharged on postoperative day 4, which was average for our robotic liver resection procedures.

CONCLUSION

We believe that spinal epidural anesthesia and analgesia are suitable techniques, especially for selected frail patients. These techniques, associated with robotic surgery, offer a better short-term outcome, especially in comorbid patients with severe lung disease. The patients benefit from a quicker return home and hospital costs are also reduced. Robotic surgery associated with locoregional anesthesia and conscious sedation could be considered a safe and suitable approach but only in specialized centers and in selected patients.

FOOTNOTES

Author contributions: All authors equally contributed to this paper with conception and design of the study, literature review and analysis, drafting and critical revision and editing, and final approval of the final version.

Informed consent statement: Informed written consent was obtained from the patient for publication of this report and any accompanying images.

Conflict-of-interest statement: The authors declare that they have no conflict of interest to disclose.

CARE Checklist (2016) statement: The authors have read the CARE Checklist (2016), and the manuscript was prepared and revised according to the CARE Checklist (2016).

Open-Access: This article is an open-access article that was selected by an in-house editor and fully peer-reviewed by external reviewers. It is distributed in accordance with the Creative Commons Attribution NonCommercial (CC BY-NC 4.0) license, which permits others to distribute, remix, adapt, build upon this work non-commercially, and license their derivative works on different terms, provided the original work is properly cited and the use is non-commercial. See: <https://creativecommons.org/licenses/by-nc/4.0/>

Country/Territory of origin: Italy

ORCID number: Antonella Delvecchio 0000-0002-7759-4340; Maria Conticchio 0000-0003-3177-5274; Valentina Ferraro 0000-0003-1895-6230; Annachiara Casella 0000-0001-6541-7390; Michele Tedeschi 0000-0002-2101-5418; Riccardo Inchingolo 0000-0002-0253-5936.

S-Editor: Fan JR

L-Editor: Kerr C

P-Editor: Zhao S

REFERENCES

- 1 **Abu Hilal M**, Aldrighetti L, Dagher I, Edwin B, Troisi RI, Alikhanov R, Aroori S, Belli G, Besselink M, Briceno J, Gayet B, D'Hondt M, Lesurtel M, Menon K, Lodge P, Rotellar F, Santoyo J, Scatton O, Soubrane O, Sutcliffe R, Van Dam R, White S, Halls MC, Cipriani F, Van der Poel M, Ciria R, Barkhatov L, Gomez-Luque Y, Ocana-Garcia S, Cook A, Buell J, Clavien PA, Dervenis C, Fusai G, Geller D, Lang H, Primrose J, Taylor M, Van Gulik T, Wakabayashi G, Asbun H, Cherqui D. The Southampton Consensus Guidelines for Laparoscopic Liver Surgery: From Indication to Implementation. *Ann Surg* 2018; **268**: 11-18 [PMID: 29064908 DOI: 10.1097/SLA.0000000000002524]
- 2 **Liu R**, Wakabayashi G, Kim HJ, Choi GH, Yiengpruksawan A, Fong Y, He J, Boggi U, Troisi RI, Efanov M, Azoulay D, Panaro F, Pessaux P, Wang XY, Zhu JY, Zhang SG, Sun CD, Wu Z, Tao KS, Yang KH, Fan J, Chen XP. International consensus statement on robotic hepatectomy surgery in 2018. *World J Gastroenterol* 2019; **25**: 1432-1444 [PMID: 30948907 DOI: 10.3748/wjg.v25.i12.1432]
- 3 **Story DA**. Postoperative complications in elderly patients and their significance for long-term prognosis. *Curr Opin Anaesthesiol* 2008; **21**: 375-379 [PMID: 18458558 DOI: 10.1097/ACO.0b013e3282f889f8]
- 4 **Jin F**, Chung F. Minimizing perioperative adverse events in the elderly. *Br J Anaesth* 2001; **87**: 608-624 [PMID: 11878732 DOI: 10.1093/bja/87.4.608]
- 5 **Jayr C**, Thomas H, Rey A, Farhat F, Lasser P, Bourgain JL. Postoperative pulmonary complications. Epidural analgesia using bupivacaine and opioids versus parenteral opioids. *Anesthesiology* 1993; **78**: 666-76; discussion 22A [PMID: 8466067 DOI: 10.1097/00005542-199304000-00009]
- 6 **Gontero P**, Oderda M, Callaris G, Allasia M, Balagna R, Gobbi F. Awake Da Vinci robotic partial nephrectomy: First case report ever in a situation of need. *Urol Case Rep* 2022; **42**: 102008 [PMID: 35127455 DOI: 10.1016/j.eucr.2022.102008]
- 7 **European Association for the Study of the Liver**. EASL Clinical Practice Guidelines: Management of hepatocellular carcinoma. *J Hepatol*

- 2018; **69**: 182-236 [PMID: [29628281](#) DOI: [10.1016/j.jhep.2018.03.019](#)]
- 8 **Dunk-Jacobs EM**, Philips P, Scoggins CR, McMasters KM, Martin RC 2nd. Stroke volume variation in hepatic resection: a replacement for standard central venous pressure monitoring. *Ann Surg Oncol* 2014; **21**: 473-478 [PMID: [24150192](#) DOI: [10.1245/s10434-013-3323-9](#)]
- 9 **Ratti F**, Cipriani F, Reineke R, Catena M, Paganelli M, Comotti L, Beretta L, Aldrighetti L. Intraoperative monitoring of stroke volume variation versus central venous pressure in laparoscopic liver surgery: a randomized prospective comparative trial. *HPB (Oxford)* 2016; **18**: 136-144 [PMID: [26902132](#) DOI: [10.1016/j.hpb.2015.09.005](#)]
- 10 **Buell JF**, Cherqui D, Geller DA, O'Rourke N, Iannitti D, Dagher I, Koffron AJ, Thomas M, Gayet B, Han HS, Wakabayashi G, Belli G, Kaneko H, Ker CG, Scatton O, Laurent A, Abdalla EK, Chaudhury P, Dutson E, Gamblin C, D'Angelica M, Nagorney D, Testa G, Labow D, Manas D, Poon RT, Nelson H, Martin R, Clary B, Pinson WC, Martinie J, Vauthey JN, Goldstein R, Roayaie S, Barlet D, Espat J, Abecassis M, Rees M, Fong Y, McMasters KM, Broelsch C, Busuttill R, Belghiti J, Strasberg S, Chari RS; World Consensus Conference on Laparoscopic Surgery. The international position on laparoscopic liver surgery: The Louisville Statement, 2008. *Ann Surg* 2009; **250**: 825-830 [PMID: [19916210](#) DOI: [10.1097/sla.0b013e3181b3b2d8](#)]
- 11 **Wakabayashi G**, Cherqui D, Geller DA, Buell JF, Kaneko H, Han HS, Asbun H, O'Rourke N, Tanabe M, Koffron AJ, Tsung A, Soubrane O, Machado MA, Gayet B, Troisi RI, Pessaux P, Van Dam RM, Scatton O, Abu Hilal M, Belli G, Kwon CH, Edwin B, Choi GH, Aldrighetti LA, Cai X, Cleary S, Chen KH, Schön MR, Sugioka A, Tang CN, Herman P, Pekolj J, Chen XP, Dagher I, Jarnagin W, Yamamoto M, Strong R, Jagannath P, Lo CM, Clavien PA, Kokudo N, Barkun J, Strasberg SM. Recommendations for laparoscopic liver resection: a report from the second international consensus conference held in Morioka. *Ann Surg* 2015; **261**: 619-629 [PMID: [25742461](#) DOI: [10.1097/SLA.0000000000001184](#)]
- 12 **Lee SY**, Goh BKP, Sepideh G, Allen JC, Merkow RP, Teo JY, Chandra D, Koh YX, Tan EK, Kam JH, Cheow PC, Chow PKH, Ooi LLPJ, Chung AYY, D'Angelica MI, Jarnagin WR, Peter Kingham T, Chan CY. Laparoscopic Liver Resection Difficulty Score-a Validation Study. *J Gastrointest Surg* 2019; **23**: 545-555 [PMID: [30421119](#) DOI: [10.1007/s11605-018-4036-y](#)]
- 13 **Lafaro KJ**, Stewart C, Fong A, Fong Y. Robotic Liver Resection. *Surg Clin North Am* 2020; **100**: 265-281 [PMID: [32169180](#) DOI: [10.1016/j.suc.2019.11.003](#)]
- 14 **Montalti R**, Scuderi V, Patriti A, Vivarelli M, Troisi RI. Robotic versus laparoscopic resections of posterosuperior segments of the liver: a propensity score-matched comparison. *Surg Endosc* 2016; **30**: 1004-1013 [PMID: [26123328](#) DOI: [10.1007/s00464-015-4284-9](#)]
- 15 **Troisi RI**, Patriti A, Montalti R, Casciola L. Robot assistance in liver surgery: a real advantage over a fully laparoscopic approach? Results of a comparative bi-institutional analysis. *Int J Med Robot* 2013; **9**: 160-166 [PMID: [23526589](#) DOI: [10.1002/rcs.1495](#)]
- 16 **Strøm C**, Rasmussen LS, Sieber FE. Should general anaesthesia be avoided in the elderly? *Anaesthesia* 2014; **69** Suppl 1: 35-44 [PMID: [24303859](#) DOI: [10.1111/anae.12493](#)]
- 17 **Abd Elrazek E**, Thornton M, Lannigan A. Effective awake thoracic epidural anesthetic for major abdominal surgery in two high-risk patients with severe pulmonary disease--a case report. *Middle East J Anaesthesiol* 2010; **20**: 891-895 [PMID: [21526681](#)]
- 18 **Rodgers A**, Walker N, Schug S, McKee A, Kehlet H, van Zundert A, Sage D, Futter M, Saville G, Clark T, MacMahon S. Reduction of postoperative mortality and morbidity with epidural or spinal anaesthesia: results from overview of randomised trials. *BMJ* 2000; **321**: 1493 [PMID: [11118174](#) DOI: [10.1136/bmj.321.7275.1493](#)]
- 19 **Koltun WA**, McKenna KJ, Rung G. Awake epidural anesthesia is effective and safe in the high-risk colectomy patient. *Dis Colon Rectum* 1994; **37**: 1236-1241 [PMID: [7995150](#) DOI: [10.1007/BF02257788](#)]
- 20 **Pursnani KG**, Bazza Y, Calleja M, Mughal MM. Laparoscopic cholecystectomy under epidural anesthesia in patients with chronic respiratory disease. *Surg Endosc* 1998; **12**: 1082-1084 [PMID: [9685547](#) DOI: [10.1007/s004649900785](#)]
- 21 **Romanzi A**, Boleso N, Di Palma G, La Regina D, Mongelli F, Milanese M, Putorti A, Rossi F, Scolaro R, Zanardo M, Vannelli A. Awake Major Abdominal Surgeries in the COVID-19 Era. *Pain Res Manag* 2021; **2021**: 8763429 [PMID: [33688385](#) DOI: [10.1155/2021/8763429](#)]
- 22 **Le Roux JJ**, Wakabayashi K, Jooma Z. Emergency Awake Abdominal Surgery Under Thoracic Epidural Anaesthesia in a High-Risk Patient Within a Resource-Limited Setting. *Cureus* 2023; **15**: e34856 [PMID: [36923189](#) DOI: [10.7759/cureus.34856](#)]
- 23 **Niraj G**, Basar SHM, Warusawitharana C, Sebastian S, Camacho E. Continuous Spinal Anaesthesia (CSA) for Emergency Laparotomy in High-Risk Elderly patients: Technique and Outcomes of a Prospective Service Evaluation. *J Anesth Surg* 2017; **4**: 130-133 [DOI: [10.15436/2377-1364.17.097](#)]
- 24 **Ishikawa N**, Watanabe G. Ultra-minimally invasive cardiac surgery: robotic surgery and awake CABG. *Surg Today* 2015; **45**: 1-7 [PMID: [25274467](#) DOI: [10.1007/s00595-014-0961-x](#)]
- 25 **Zheng H**, Hu XF, Jiang GN, Ding JA, Zhu YM. Nonintubated-Awake Anesthesia for Uniportal Video-Assisted Thoracic Surgery Procedures. *Thorac Surg Clin* 2017; **27**: 399-406 [PMID: [28962712](#) DOI: [10.1016/j.thorsurg.2017.06.008](#)]
- 26 **Yamamoto K**, Fukumori D, Yamamoto F, Yamamoto M, Igimi H, Yamashita Y. First report of hepatectomy without endotracheal general anesthesia. *J Am Coll Surg* 2013; **216**: 908-914 [PMID: [23490541](#) DOI: [10.1016/j.jamcollsurg.2013.01.002](#)]



Published by **Baishideng Publishing Group Inc**
7041 Koll Center Parkway, Suite 160, Pleasanton, CA 94566, USA

Telephone: +1-925-3991568

E-mail: bpgoffice@wjgnet.com

Help Desk: <https://www.f6publishing.com/helpdesk>

<https://www.wjgnet.com>

