

Reviewer #1:

Scientific Quality: Grade A (Excellent)

Language Quality: Grade A (Priority publishing)

Conclusion: Accept (High priority)

Specific Comments to Authors: The treatment of giant hiatal hernia has the risk of many complications and high recurrence rate. At present, laparoscopic repair of hiatal hernia is generally used. Basic procedures are defect closure, fundoplication, and mesh enhancement. Thoracoscopic treatment of hiatal hernia is feasible, depending on the professional background of the surgeon. A good question raised by the authors in this paper is whether a transthoracic approach should be chosen if the laparoscopic approach does not meet the requirements. At the same time, through the measurement of CT coronal scan, the quantitative index is calculated by mathematical formula. Obviously, this article enriches the selection of treatment strategies for hiatal hernia. Data on 112 patients from 2006 to 2020 were collected and divided into three groups. The result is that for patients with giant hiatal hernias, it is essential to conduct a preoperative evaluation of the angle of vision and the working area for surgery. When parts of the intrathoracic sac are inaccessible laparoscopically, the thoracoscopic approach should be considered. However, due to the large time span, surgical techniques have changed greatly during this time, so there is a gap between early-stage surgical techniques and current surgical techniques in the treatment of patients. In addition, is the skill of the surgeons for these patients homogeneous? The author should mention and discuss it in the article. In view of the novelty of this article, I agree to publish this article in original work.

As you told us we have mentioned your consideration in "Discussion", you can see it in yellow.

Thank you for your interest

Reviewer #2:

Scientific Quality: Grade C (Good)

Language Quality: Grade B (Minor language polishing)

Conclusion: Minor revision

Specific Comments to Authors:

1 Title reflect the main subject of the manuscript

2 Abstract summarize and reflect the work described in the manuscript

3 Key Words reflect the focus of the manuscript

4 Background adequately describe the background, present status and significance of the study

5 Methods is described adequately

6 Results : not presented well tables not clear table 2 and table 3 not needed please try to present table one in clear way and omit table 2and3

We have removed tables 2 and 3 and present table 1 in clear way

7 Discussion : is too long it can be shortened and concise and become clear

We have shortened discusión removing this content:

1. The essential technical steps in this procedure consist of achieving a complete reduction of the hiatal hernia, excision of the hernial sac, extensive mediastinal mobilisation of the oesophagus and tension-free femoral closure. When effecting the abdominal reduction of the hiatal hernia content, it is very important to exert gentle traction on the hernial sac, proceeding gradually with an extensive mediastinal mobilisation of the oesophagus, using blunt dissection to obtain 2-2.5 cm of intra-abdominal oesophageal length (23).

2. During dissection of the hernial sac, caution should be exercised to avoid injury to the vagal nerves in the anterior and posterior aspects of the oesophagus, pleura and adjacent vascular structures (24). The most common intraoperative complication reported is visceral injury (oesophageal and gastric perforations), observed in up to 11% of cases, followed by vagus nerve injury and pulmonary complications (pneumonia) (25).

A recent study showed that the larger the hiatal defect, the greater the probability of reherniation. Accordingly, many authors recommend the use of a mesh for hiatal closure to reduce the recurrence rate in the repair of giant hiatal hernias, noting that the indication for the use of mesh would depend on the size of the hiatal defect (26).

In view of these considerations, possible complications arising from the use of mesh must be taken into account (35). The most serious potential complication of mesh hiatoplasty is that of mesh erosion and migration. Studies have also reported mesh-associated infection, stenosis, erosion and dysphagia. Such complications can occur with any type of mesh, even biological ones (27,36). Severe complications such as oesophagectomy and gastrectomy following the use of mesh have also been reported (27).

as you told us we believe it is more clear now

8 self References. noted

9 minimal grammar and spelling mistake

Our native translator has reviewed text and he made some changes (yellow colour), we send the certificate of it.

Thank you for your interest

Title: Determining the need for a thoracoscopic approach to treat a giant hiatal hernia when abdominal access is poor

Key words: Hiatal hernia, Laparoscopy, Thoracic surgery, Abdominal surgery

Running head: Determining approach for giant hiatal hernia

Authors:

F.J. Pérez Lara¹, R. Zubizarreta Jimenez², T. Prieto-Puga³, P. Gutierrez Delgado⁴, J.M. Hernández Carmona³, J.M. Hernández González³, M. Pitarch Martínez³.

¹ Chief of Surgery Service. Hospital de Antequera. Málaga. Spain

² CEO in DOXA microfluidics (mechanical engineer). Malaga. Spain

³ Digestive Surgeon. Service of Surgery. Hospital de Antequera. Málaga. Spain

⁴ Digestive Surgeon. Service of Surgery. Hospital de Antequera. Málaga. Spain

Authors' contributions:

FJ Pérez Lara: made a substantial contribution to the concept and design, drafted the article or revised it critically for important intellectual content, approved the version to be published.

R. Zubizarreta Jimenez: drafted the article or revised it critically for important intellectual content, approved the version to be published.

T. Prieto-Puga: approved the version to be published.

P. Gutierrez Delgado: approved the version to be published.

J.M. Hernández Carmona: approved the version to be published.

J.M. Hernández González: approved the version to be published.

M. Pitarch Martínez: approved the version to be published.

Contact information: Francisco Javier Pérez Lara. Hospital de Antequera. Secretaría de Cirugía (3º planta). Avenida Poeta Muñoz Rojas s/n. Antequera. Málaga. 29200. Tlf:668830533. E-mail: javinewyork@hotmail.com.

Disclosure statement: N/A

Text word count: 3154 words

Category: Original Article

The authors state they have no conflicts of interest to declare regarding this paper.

ABSTRACT

BACKGROUND

Giant hernias present a significant challenge for digestive surgeons. The approach taken (laparoscopic vs. thoracoscopic) depends largely on the preferences and skills of each surgeon, although in most cases today the laparoscopic approach is preferred.

AIM

Our study aim, based on retrospective analysis, is to determine whether patients presenting inadequate laparoscopic access to the intrathoracic hernial sac obtain poorer postoperative results than those with no such problem, in order to assess the need for a thoracoscopic approach.

METHODS

For the retrospective series of patients treated in our hospital for hiatal hernia (n=112), we calculated the laparoscopic field of view and the working area accessible to surgical instruments, by means of preoperative imaging tests, to assess the likely outcome for cases inaccessible to laparoscopy.

RESULTS

Patients with giant hiatal hernias for whom a preoperative calculation suggested that the laparoscopic route would not access all areas of the intrathoracic sac presented higher rates of perioperative complication, complications during follow-up and recurrence than those for whom laparoscopy was unimpeded. The difference was statistically significant. Moreover, the insertion of mesh did not improve results for the non-laparoscopy group.

CONCLUSION

For patients with giant hiatal hernias, it is essential to conduct a preoperative evaluation of the angle of vision and the working area for surgery. When parts of the intrathoracic sac are inaccessible laparoscopically, the thoracoscopic approach should be considered.

Keywords: Hiatal hernia; Abdominal surgery; Laparoscopy; Thoracoscopy surgery.

Authors: Lara FJP, Zubizarreta Jimenez R, Prieto-Puga Arjona T, Gutierrez Delgado P, Hernández Carmona JM, Hernández Gonzalez, Pitarch Martinez M.

Running title: Determining approach to treat a giant hiatal hernia

Core Tip: In a previous study, we presented a series of mathematical formulas that can be used to assess the accessibility of large hiatal hernias to a laparoscopic approach, concluding that for some patients this technique was not viable. In the present retrospective study, we examine whether outcomes are poorer among patients whose hiatal hernias are deemed inaccessible to laparoscopy (according to the mathematical formulation applied to the preoperative imaging results).

Introduction

A hiatal hernia is the protrusion of an abdominal organ into the mediastinum through the diaphragmatic hiatus. This condition is relatively common and, given the progressive aging of the population, its prevalence is expected to increase (1).

A giant hiatal hernia is characterised by the presence of more than one third of the stomach in the chest (2). This pathology is much less common, representing 5-10% of all hiatal hernias (3,4). It is associated with a wide spectrum of symptoms (4,5), typically involving chest pain, vomiting and postprandial dysphagia, due to the mechanical effect of the translocation of the stomach.

In 1919, Soresi performed the first operation to reduce a hiatal hernia and to close the diaphragmatic pillars (6) and during the past hundred years many conceptual and technical innovations have been introduced (7-10). In 1998, the first completely laparoscopic operation based on Collis gastroplasty and Nissen fundoplication was described (11).

The basic principles for hiatal hernia repair include the complete reduction of the hernial sac and herniated structures, with sufficient dissection to optimise oesophageal mobility, followed by primary closure of the crura with nonabsorbable sutures, and then fundoplication to reduce the risk of postoperative reflux. To achieve all these goals, it is essential to properly visualise the sac at all points of intrathoracic attachment.

Recurrence during primary laparoscopic fundoplication, after hiatal repair, ranges from 1-7%, but can reach 50% in cases of large or paraoesophageal hernias (12-15). In this type of large hernia, we believe, as postulated in prior research (16), that it is essential to calculate working angles and angles of vision in order to determine whether the abdominal approach is feasible and safe. In the present study, we examine whether the inability to access all areas of the hernial sac might be a key factor in the recurrence of large hiatal hernias.

Material and method

In this retrospective study, we evaluate all the patients operated on for hiatal hernia at our hospital from May 2006 to September 2020. The guidelines of our hospital's ethical committee for human studies were followed at all times.

The following parameters were included in the data collected: sex, age, surgical technique, mesh placement, second intervention, type of hernia, perioperative complications, complications during follow-up, recurrence, mortality and duration of follow-up.

Perioperative complications are viewed as major conditions such as pneumothorax, oesophageal perforation or splenic injury, and exclude relatively minor problems such as wound infection, ileus or mild dysphagia.

Our study hypothesis is that in large hernias where from the abdominal cavity it is not possible to access all areas of the hernia within the thoracic cavity in order to dissect the hernial sac, the risk of recurrence is much greater than when the surgeon is able to access the entire volume of the hernial sac.

Exclusion criteria

The following types of case were excluded from the study:

- When the patient was lost to follow up.
- When no coronal imaging test was performed.
- When the patient had previously been operated on for a hiatal hernia and therefore presented a recurrence, not a primary hernia.

For all patients included in the study, preoperative imaging techniques were employed, in the coronal plane, by CT or oesophago-gastroduodenal transit, to evaluate the angles of vision and working angles available during the intervention (angle of vision: the visual field obtained of the intrathoracic content when the laparoscope is inserted through the hernial orifice; working angle: amplitude of instrumental access to the intrathoracic hernial content via the hiatal orifice). In this respect, the following parameters were determined: the camera angle, the diameter of the orifice and the positioning of the trocars with respect to the orifice. These data provided the basis for detailed mathematical calculations, as described previously (16), to determine the potential access, visual and/or instrumental, to the thoracic cavity (Figure 1).

The patients were classed as follows, according to the type of hernia presented: Group A, orifice <4 cm; Group B, orifice >4 cm and accessible (i.e., enabling access both visually and with surgical instruments to all areas of the intrathoracic hernial sac); Group C, orifice >4 cm and inaccessible (not permitting visual and/or instrumental access to all areas of the intrathoracic hernial sac (Figure 2)).

Statistical analysis

The relation between each of the qualitative variables (sex, mesh placement technique, second intervention, type of hernia, perioperative complications, complications during follow-up, recurrence and mortality) and the study group (A, B and C) variable was determined by the chi-square test, under the condition that the expected values of at least 80% of the cells in the

contingency table were greater than 5. If this condition was not met, Fisher's exact test was applied.

We then determined the association between each of the quantitative variables (age and duration of follow-up) and the study group (A, B and C) variable), using the Anova test for the age variable (when the normality condition and the homogeneity of variance were fulfilled). For the non-parametric variable (the duration of follow-up), the Kruskal-Wallis test was applied.

Finally, we examined the association between recurrence and mesh placement technique, for Groups B and C (logically, no mesh was employed for the cases in Group A, due to the size of the hernia). For each group, Fisher's test was applied, and the overall association was determined by the Cochran-Mantel-Haenszel method.

Results

Table 1 summarises the results obtained, organised in contingency tables showing both absolute and relative frequencies, with each study group (A, B and C) in its respective column. The remaining qualitative variables are listed in the rows. Our analysis shows there were no significant differences among the groups in terms of sex, mesh placement technique, second intervention or mortality. On the other hand, there were differences in terms of the type of hernia treated, the perioperative complications that occurred, complications during follow-up and recurrence. The complications and recurrences were higher in Group C than in the other two groups.

Regarding the results for the other quantitative variables:

- Duration of follow up (Kruskal-Wallis - the mean and the interquartile range in each case) Group A 120 (52, 156), Group B 100 (40.5, 155.8), Group C 120 (84, 145), $p=0.66$
- Age (Anova - means and standard deviations) Group A 51.9 (13.8), Group B 62.1 (13.8), Group C 59.1 (14.9), $p=0.0026$.

By duration of follow up, there were no significant differences among the groups. However, there were statistically significant differences according to the mean age of the patients, which was lower in Group A.

Finally, we analysed the association between recurrence and mesh placement technique, by groups. For Group B, Fisher's test of the association between recurrence and mesh obtained $p=0.5668$, from which we conclude that in this group there was no significant association between these parameters. For Group C, the corresponding value was $p=1$, which also reflects independence between recurrence and mesh.

The Cochran-Mantel-Haenszel test obtained the result of $p=0.4233 > 0.05$. Therefore, we cannot reject the null hypothesis that the relative proportions of recurrence are independent of the mesh placement technique, within Groups B and C.

Discussion

Hiatal hernias have been described in 2.9-20% of patients undergoing gastroscopies (17), but could be much more frequent, rising to perhaps 10-50% of the general population. Four types have been distinguished: sliding (type I), paraoesophageal (type II), combined (type III) and giant paraoesophageal (type IV) (18). A giant hiatal hernia is characterised by the presence of more than one third of the stomach within the chest (2). It is a rare pathology, representing just 5-10% of all hiatal hernias (3,4).

Worldwide, rising numbers of surgical interventions are being performed to treat gastrooesophageal reflux disease and/or hiatal hernias, and surgeons are encountering increasingly complicated cases, often presenting large hiatal defects.

In recent years, laparoscopic or thoracoscopic techniques involving the complete separation of the hernial sac from the thoracic cavity (19) have gradually replaced the open repair of giant hiatal hernias, to become the standard approach, resulting in lower mortality and a better quality of life, according to the GIQLI outcomes instrument (20-22). However, since no randomised controlled trials have been performed to demonstrate which method (thoracoscopic vs. laparoscopic) is superior, the choice of approach still depends largely on the

preferences and skills of each surgeon, although the vast majority of surgeons currently employ the laparoscopic approach to treat hiatal hernias.

Nevertheless, the laparoscopic repair of giant hiatal hernias remains a challenging task for digestive surgeons. These defects have a high recurrence rate, ranging from 10-42%, and can reach 50% in larger or paraoesophageal hernias (12-15).

A relevant factor in recurrences is that with the laparoscopic approach the anatomic elements may not all be clearly visible. This consideration motivated our previous study (16), in which we proposed a preoperative procedure to assess the visibility of the working area, with particular interest in determining access to the intrathoracic sac and whether the positioning of the trocars allowed us to reach the necessary intrathoracic aspects. This determination would enable us to identify the patients for whom a laparoscopic approach would not be safe and who, therefore, would require a thoracoscopic intervention. Indeed, surgeons who advocate the preferential use of transthoracic repair argue that this method provides a better visualisation of the herniated structure and thus facilitates the dissection and resection of the sac.

In the present study we examine whether these theoretical postulates are confirmed in routine clinical activity. The results obtained show that **patients** whose condition is considered inaccessible via the abdominal approach (according to preoperative imaging tests) are exposed to extremely high rates of complications and recurrence (76.9% and 69.2%, respectively). Therefore, for this type of patient we propose a thoracic or combined thoracic-abdominal approach in order to access all the locations of the intrathoracic sac where adhesions to adjacent tissues must be released. Such an approach could improve the outcomes obtained by this group of patients, approximating them to those of Group B patients with accessible giant hernias (among whom the rate of recurrence in our earlier study was 16.7%).

In our study, the rate of recurrence observed for patients with giant hiatal hernias (Groups B and C) is close to that published in the literature (29.1%). However, we also identified the type of hernias that most strongly influences this rate in the global computation as Group C, in which 69.2% of patients are subject to recurrence. Therefore, if we could bring the level of recurrence in this group in line with that presented by Group B patients, by adopting the thoracic approach, and thus achieving direct visibility of all aspects of the sac, our recurrence figures would probably be 16.7% for patients with giant hiatal hernias (Groups B and C) and 10.7% for the complete series (Groups A + B + C). The adoption of such an approach, therefore, would significantly reduce the level of recurrence that is commonly reported for these patients.

When performing this type of intervention on large hiatal hernias, in order to safely perform the complete separation of the hernial sac, the surgical instruments employed must be able to reach all areas of the intrathoracic sac and the surgeon must have an unimpeded view of these areas.

If there is no direct vision of the area to be addressed, it will be more difficult for the surgeon to follow the steps described in point one above, thus increasing the probability of postoperative recurrence. Moreover, the dissection described in point two will be less safe, thus producing more peri- and postoperative complications. Our study confirms these consequences, showing that peri- and postoperative complications and recurrences are significantly more common in patients presenting non-accessible hernias (Group C).

Despite certain advances, rates of recurrence for non-mesh large hiatal hernia repairs remain high (14). Although the use of synthetic mesh prostheses could reduce these rates to 12% (23), their widespread adoption is limited by the fact that they can provoke potentially life-

threatening complications, a risk that is often unacceptable with respect to a condition that is, in itself, benign (24-30).

In our study, the mesh improved outcomes in Group B, although these findings were not statistically significant (this significance might be achieved with a larger study sample). In Group C, however, the use or otherwise of mesh produced no differences, since the mesh did not address the fundamental problem considered, namely the visibility and accessibility of the intrathoracic sac.

We believe it important to note the significant period of time that has elapsed since the initial implementation of the surgical techniques discussed. Nevertheless, there has been almost no variability in the surgical technique, which in 96.5% of the patients in our study was performed by laparoscopic Nissen fundoplication, a technique that has remained the gold standard throughout this period. The only notable variation in the technique was the decision on whether to insert the mesh. We also address this question and analyse the results obtained.

Another factor that must be considered is that of the homogeneity in surgical skills when treating these patients. In our case, the patients were operated on by three surgeons, all of whom have great experience in this type of intervention and periodically refresh their technique; no patient was operated on by a surgical resident, and so we believe there is no study bias in this respect.

In conclusion, we believe that a preoperative sagittal CT imaging study should be performed for all patients with giant hiatal hernias. Among those whose condition impedes access to laparoscopic entry points, a thoracic or combined approach to the hernia should be considered. We suggest this method would reduce the risk of complication and recurrence.

BIBLIOGRAPHY

1. Davis SS Jr. Current controversies in paraesophageal hernia repair. *Surg Clin North Am* 2008; 88(5):959-78.
2. Morino M, Giaccone C, Pellegrino L & Rebecchi F. Laparoscopic management of giant hiatal hernia: factors influencing long-term outcome, *Surg. Endosc.* 2007; 1011–1016.
3. Pearson FG, Cooper JD, Ilves R, Todd TRJ & Jamieson WRE. Massive hiatal hernia with incarceration: a report of 53 cases, *Ann. Thorac. Surg* 1983;35:45–51.
4. Mercer CD. The esophagus: medical and surgical management, W.B. Saunders, Philadelphia, 2018:148–156.
5. Hill LD. Incarcerated paraesophageal hernia: a surgical emergency, *Am. J.Surg* 1973;126:286–291.
6. Stylopoulos N, Rattner DW. The history of hiatal hernia surgery: from Bowditch to laparoscopy. *Ann Surg.* 2005;241:185-93.
7. Nissen R. A simple operation for control of reflux esophagitis. *Schweiz Med Wochenschr.* 1956;86(suppl 20):590-2.
8. Collis JL. An operation for hiatus hernia with short oesophagus. *J Thorac Cardiovasc Surg.* 1957;14:768-88.
9. Skinner DB, Belsey RH. Surgical management of esophageal reflux and hiatus hernia. Long-term results with 1,030 patients. *J Thorac Cardiovasc Surg.* 1967;53:33-54.
10. Maziak DE, Todd TR, Pearson FG. Massive hiatus hernia. *J Thorac Cardiovasc Surg.* 1998;115:53-60; discussion 61-2.
11. Johnson AB, Oddsdottir M, Hunter JG. Laparoscopic Collis gastroplasty and Nissen fundoplication. A new technique for the management of esophageal foreshortening. *Surg Endosc.* 1998;12:1055-60.
12. Basso N, Rosato P, De Leo A, Genco A, Rea S, Neri T. “Tension-free” hiatoplasty, gastrophrenic anchorage, and 360-degree fundoplication in the laparoscopic treatment of paraesophageal hernia. *Surg Laparosc Endosc Percutan Tech* 1999;9: 257– 262
13. Carlson MA, Condon RE, Ludwig KA, Schulte WJ. Management of intrathoracic stomach with polypropylene mesh prosthesis reinforced transabdominal hiatus hernia repair. *J Am Coll Surg* 1998;187: 227–230
14. Hashemi M, Peters JH, DeMeester TR, Huprich JE, Quek M, Hagen JA, Crookes PF, Theisen J, DeMeester SR, Sillin LF, Bremner CG. Laparoscopic repair of large type III hiatal hernia: objective follow-up reveals high recurrence rate. *J Am Coll Surg* 2000;190: 553–560
15. Paul MG, DeRosa RP, Petrucci PE, Palmer ML, Danovitch SH. Laparoscopic tension-free repair of large paraesophageal hernias. *Surg Endosc* 1997;11: 303–307.
16. Pérez Lara FJ, Zubizarreta Jimenez R, Moya Donoso FJ, Hernández Gonzalez JM, Prieto-Puga Arjona T, del Rey Moreno A, Pitarch Martinez M. Preoperative calculation of angles of vision and working area in laparoscopic surgery to treat a giant hiatal hernia. *World J Gastrointest Surg* 2021; 13(12): 1638-1650.
17. Kang JY. Systematic review: geographical and ethnic differences in gastro-oesophageal reflux disease. *Aliment Pharmacol Ther.* 2004; 20(7): 705–717, doi: 10.1111/j.1365-2036.2004.02165.x, indexed in Pubmed: 15379831.
18. Dean C, Etienne D, Carpentier B, et al. Hiatal hernias. *Surg Radiol Anat.* 2012; 34(4): 291–299, doi: 10.1007/s00276-011-0904-9, indexed in Pubmed: 2210568-

19. Lococo F, Cesario A, Meacci E, et al. Intrathoracic gastric perforation: a late complication of an unknown postpartum recurrent hiatal hernia. *Interact Cardiovasc Thorac Surg* 2012;15:317-8.
20. Fullum TM, Oyetunji TA, Gezzar O, et al. Open versus laparoscopic hiatal hernia repair. *JSLs* 2013;17:23-9.
21. Hazebroek EJ, Gananadha S, Koak Y, et al. Laparoscopic paraesophageal hernia repair: quality of life outcomes in the elderly. *Dis Esophagus* 2008;21:737-41.
22. Oor JE, Koetje JH, Roks DJ, et al. Laparoscopic hiatal hernia repair in the elderly patient. *World J Surg* 2016;40:1404-11.
23. B. P. Müller-Stich, H. G. Kenngott, M. Gondan et al. Use of mesh in laparoscopic paraesophageal hernia repair: a metaanalysis and risk-benefit analysis. *PLoS One*, 2015;10(10): article e0139547.
24. Tatum RP, Shalhub S, Oelschlager BK, Pellegrini CA. Complications of PTFE mesh at the diaphragmatic hiatus. *J Gastrointest Surg* 2008;12:953–957.
25. J. R. Huddy, S. R. Markar, M. Z. Ni et al. Laparoscopic repair of hiatus hernia: does mesh type influence outcome? A metaanalysis and European survey study. *Surgical Endoscopy* 2016;30(12):5209–5221.
26. E. Virgilio, P. Mercantini, and M. Cavallini. Partial transmural gastroesophageal migration of polypropylene mesh after surgery for a recurrent hiatal hernia. *European Review for Medical and Pharmacological Sciences* 2016;20(17):3515-3516.
27. Bognár L, Horváth ÖP, Solt J, Jancsó G & Vereczkei A. Intraesophageal mesh migration following laparoscopic hiatal hernia repair. *Magyar Sebészeti* 2016;68(4):176–180.
28. Porziella V, Cesario A, Lococo F et al. Complete transmural gastric migration of PTFE mesh after surgery for a recurrent hiatal hernia. *European Review for Medical and Pharmacological Sciences* 2012;16(4):42-43.
29. Carpelan-Holmström M, Kruuna O, Salo J, Kylänpää L & Scheinin T. Late mesh migration through the stomach wall after laparoscopic refundoplication using a dual-sided PTFE/ePTFE mesh. *Hernia* 2011;15(2):217–220.
30. Juhasz A, Sundaram A, Hoshino M, Lee TH & Mittal SK. Outcomes of surgical management of symptomatic large recurrent hiatus hernia. *Surgical Endoscopy* 2012;26(6):1501–1508, 2012.

Table 1. Quantitative variables for the three types of hernia

		GROUP						n_{ALL}	% ALL
		n_A	% A	n_B	% B	n_C	% c		
Sex p= 0.23 (a)	Female	26	45.6	26	61.9	8	61.5	60	53.6
	Male	31	54.4	16	38.1	5	38.5	52	46.4
Surgery p= 0.11 (b)	Dor	0	0.0	0	0.0	1	7.7	1	0.9
	Nissen	55	96.5	41	97.6	12	92.3	108	96.4
	Reduction	0	0.0	1	2.4	0	0.0	1	0.9
	Toupet	2	3.5	0	0.0	0	0.0	2	1.8
Perioperative complication p= 0.006 (b)	No	56	98.2	35	83.3	10	76.9	101	90.2
	Yes	1	1.8	7	16.7	3	23.1	11	9.8
Complications during follow-up p= 0.03 (a)	No	36	63.2	25	59.5	3	23.1	64	57.1
	Yes	21	36.8	17	40.5	10	76.9	48	42.9
Recurrence p= 0.0005 (b)	No	54	94.7	35	83.3	4	30.8	93	83.0
	Yes	3	5.3	7	16.7	9	69.2	19	17.0
Mortality p= 0.13 (a)	No	57	100.0	42	100.0	13	100.0	112	100.0
	Yes	57	100.0	42	100.0	13	100.0	112	100.0
Mesh p= 0.0005 (b)	No	57	100.0	36	85.7	8	61.5	101	90.2
	Yes	0	0.0	6	14.3	5	38.5	11	9.8
Paraesophageal hernia p= 0.001 (b)	No	57	100.0	33	78.6	10	76.9	100	89.3
	Yes	0	0.0	9	21.4	3	23.1	12	10.7
Secondary procedure p= 0.28 (b)	No	50	87.7	40	95.2	13	100.0	103	92.0
	Yes	7	12.3	2	4.8	0	0.0	9	8.0

(a) Chi square test

(b) Fisher's test

Figure 1. Working area with lateral displacement of the trocar

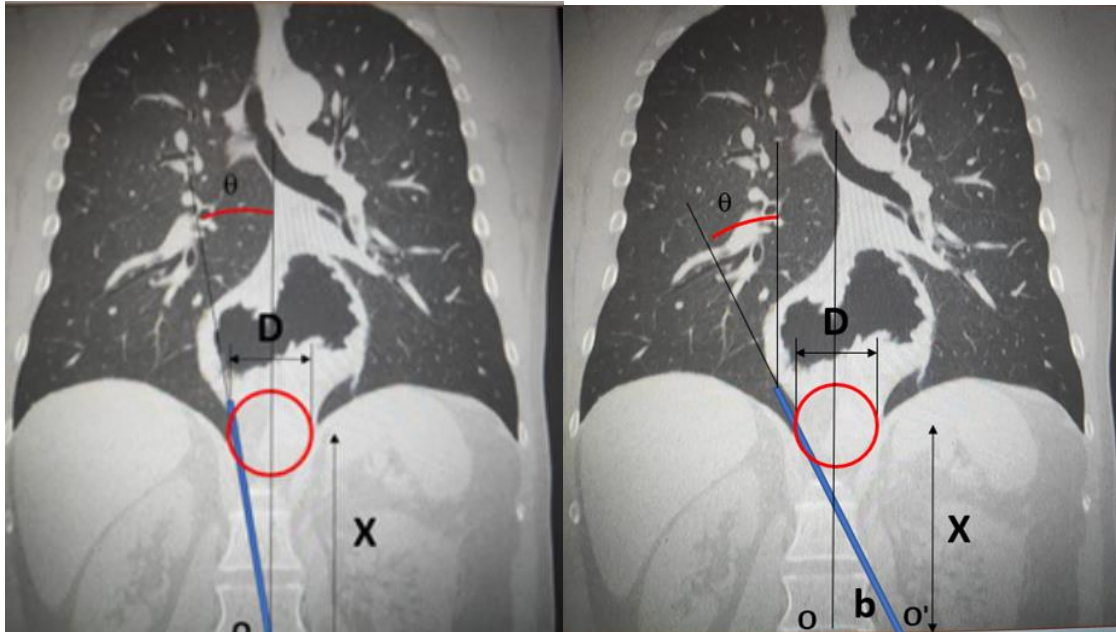


Figure 2. Simulation of the working area with different entry trocars, in a giant hiatal hernia for which the laparoscopic approach is impractical (the arrow shows the area non-accessible to instruments)

